

We are IntechOpen, the world's leading publisher of Open Access books Built by scientists, for scientists

6,900

Open access books available

186,000

International authors and editors

200M

Downloads

Our authors are among the

154

Countries delivered to

TOP 1%

most cited scientists

12.2%

Contributors from top 500 universities



WEB OF SCIENCE™

Selection of our books indexed in the Book Citation Index
in Web of Science™ Core Collection (BKCI)

Interested in publishing with us?
Contact book.department@intechopen.com

Numbers displayed above are based on latest data collected.
For more information visit www.intechopen.com



Surgical Anatomy of the Tonsils

Gülay Açar

Abstract

The tonsils represent a circular band of mucosa associated with lymphoid tissues, Waldeyer's ring, which is located at the entrance of the upper aerodigestive tract, with a significant role in the immune defense system. Waldeyer's ring is composed of the pharyngeal, tubal, palatine, and lingual tonsils acting as secondary lymphoid tissues. Particularly, the palatine tonsils are the largest of the tonsils with deep branching crypts and contain B and T lymphocytes and M cell which plays a role in the uptake and transport of antigens. Because of the tonsil enlargement during childhood, upper airway obstruction and obstructive sleep apnea syndrome are mostly seen. Knowledge of the surgical anatomy of the tonsils and variations of the neurovascular and muscular structures around it allows optimal choice of surgical technique to avoid iatrogenic complications during tonsillectomy. Recent medical studies reported that a detailed understanding of the anatomic risk factors in upper airway obstruction allows to predict treatment response to surgical intervention. Due to the penetration of benign or malign lesions of the tonsil into the lateral wall of the pharynx, transoral robotic approach to this region is necessary to identify the surgical anatomic landmarks which are required to perform safe and effective surgical intervention.

Keywords: palatine tonsil, parapharyngeal space, surgical anatomy, transoral robotic surgery, Waldeyer's ring

1. Introduction

As part of secondary lymphoid organs, mucosa-associated lymphoid tissue (MALT) is an aggregate of unencapsulated lymphoid tissue that is located diffusely in the mucosa of the aerodigestive tract and consists of the tonsils, vermiform appendix, and Peyer's patch [1]. As part of MALT, the tonsils serve as a protection ring including nasopharynx-associated lymphoid tissue (NALT), which is known as Waldeyer's tonsillar ring, around the entrance of the upper aerodigestive tract to start the initial immunological barrier to infections [1, 2]. This annular-shaped lymphoid ring contains four types of tonsils in a fixed position [3].

1. Pharyngeal (adenoid) tonsil
2. Eustachian tube tonsils (Gerlach's tonsils)
3. Lingual tonsils and lymphoid aggregations close to the epiglottis
4. The palatine (faucial) tonsils

Due to the close proximity of the palatine tonsil with the surrounding spaces including parapharyngeal, retropharyngeal, masticator, and parotid spaces, the tumors and inflammation of the tonsil commonly spread into these spaces and result in secondary lesions [4, 5]. A detailed knowledge of the surgical anatomic landmarks in the tonsillar region and the spaces around it is required for preoperative planning and to prevent iatrogenic complications.

2. Immune function of the tonsils in Waldeyer's ring

The tonsils are lymphoepithelial organs acting as a guardian at the entrance of the upper aerodigestive tract. Lymphoid system, as a component of the immune system, consists of lymph vessels, nodes, and organs that regulate the immune response directly or indirectly. The lymph vessels play a key role in the drainage of interstitial fluid from the tissues to the blood and fat absorption, whereas the lymphoid organs mediate the proliferation and maturation of the cells of the immune system, which protect the body against ingested or inhaled foreign pathogens. The cell groups of the immune system, which is known as the ability to distinguish self from nonself, produce two reactions that are called the innate (natural) and adaptive (acquired) immunity [1, 2]. Initially, lymphocytes and accessory cells are developed and matured to the stage of antigen recognition in primary lymphoid organs including the thymus and bone marrow, and then they are activated and differentiated to effector cells of the immune response by antigen presentation in secondary lymphoid organs. The lymph nodes, the spleen, and mucosa-associated lymphoid tissue are secondary lymphoid organs which allow lymphocytes to become functional to produce a defense mechanism against microorganisms such as viruses, parasites, and bacteria. The structures of MALT have 70% of all the cells of the immune system, and the percentages of the lymphocytes in each of them are variable [1].

3. Anatomical localization of the tonsils in the pharynx

As part of the upper aerodigestive tract, the pharynx is located between the skull base and the inferior border of cricoid cartilage and consists of three portions; the nasopharynx (upper nasal), oropharynx (middle oral), and laryngopharynx (lower laryngeal). It is a musculomembranous tube covered with three external (circular, the superior, middle, and inferior constrictors) and three internal (longitudinal, voluntary) muscles, which play a key role in swallowing, respiration, and phonation [6]. The tonsils are located posterior to the nasal and oral portions of the pharynx to form a circumferential ring, known as the Waldeyer's tonsillar ring, which was first described by German anatomist Heinrich Wilhelm Gottfried von Waldeyer-Hartz [3]. The unpaired nasopharyngeal and lingual tonsils and the paired palatine and tubal tonsils form Waldeyer's lymphoid ring at the opening of the upper aerodigestive tract and are responsible for both innate and adaptive immunological responses which have a crucial role in the defense mechanism of the pharynx (**Figure 1**) [7].

3.1 Nasopharynx

As a part of the upper respiratory system, the nasopharynx is bounded by the choanae anteriorly, the upper surface of the soft palate inferiorly, and the

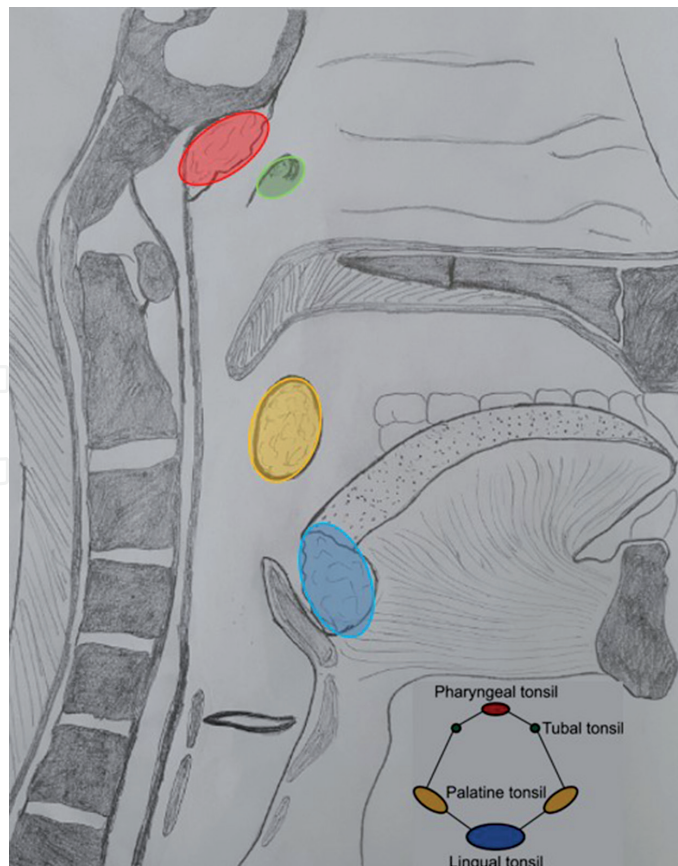


Figure 1.
 The localization of the tonsils in Waldeyer's tonsillar ring.

oropharyngeal isthmus (OPI) posterolaterally. The nasopharyngeal and tubal tonsils are located in the posterolateral wall of the nasopharynx [6]. The palatoglossal arch (PGa) and palatopharyngeal arch (PPa) join with each other to form the OPI which allows the communication with the oropharynx. The boundaries of the OPI are formed by the soft palate (velum) anteriorly and the lateral and posterior pharyngeal walls posterolaterally. During swallowing and speaking, the levator veli palatini (LVPm), palatopharyngeus (PPm), superior pharyngeal constrictor (SPCm), salpingopharyngeus (SPm), and the uvula, which are called a velopharyngeal sphincter, play a role in the closure of the OPI. During velopharyngeal function, a transverse mucosal ridge called Passavant's ridge (palatopharyngeal sphincter) runs along the posterior wall of the OPI between the most lateral part (transverse fibers) of the PPm and the most superior part of the SPCm [7, 8].

3.2 Pharyngeal tonsil

Pharyngeal tonsil is the superior-most of the Waldeyer's ring and located above the soft palate in the posterosuperior roof of the nasopharynx as a single median unencapsulated mass with 12–15 shallow, crypt-like invaginations. The pharyngeal bursa, a blind mucosal sac, may be seen in the posterior median wall of the nasopharynx above the SPCm. A median longitudinal groove extends from this sac inferiorly [6]. Anterosuperiorly, the pharyngeal tonsil is usually lined by pseudostratified ciliated columnar epithelium (respiratory epithelium), whereas posteroinferiorly the areas adjacent to the oropharynx is covered by stratified epithelium. These mucosal folds containing numerous lymphoid

nodules commonly enlarge and become adenoid which results in respiratory difficulties and nasal obstruction during childhood and often start to involute after 7 years of age or even atrophied in the adult. Chronic inflammation of the pharyngeal tonsil results in hyperplasia and hypertrophy of the lymphoid tissue known as adenoid [7].

The arterial supply of it comes from ascending pharyngeal artery, pharyngeal branch of the maxillary artery, artery of the pterygoid canal, basisphenoid artery, ascending palatine, and tonsillar branch of the facial artery. It has a lymphatic drainage into upper deep cervical within the parapharyngeal space (PPS) and retropharyngeal lymph nodes [7].

3.3 Tubal tonsils

Eustachian tube (ET) tonsils, small aggregates of lymphoid tissue, form the upper lateral aspect of the ring and are located bilaterally around the pharyngeal ostium of the ET (torus tubarius) which is below and in front of the pharyngeal recess (fossa of Rosenmüller) in the posterolateral wall of the nasopharynx [6]. Because of their close relationship to the torus tubarius, they are called tubal or Gerlach's (German anatomist) tonsils. This triangular pharyngeal ostium has three prominences: anterior, posterior, and inferior. The anterior fold continues as a plica salpingopalatina descends into the soft palate. The posterior prominence is conspicuous and formed by the projecting cartilage of the auditory tube, called the torus tubarius, and also lies as plica salpingopharyngeus which is composed of the SPm. The torus tubarius can be used for ET catheterization. On the lower aspect of the ostium, the LVPm insertion forms a slightly rounded prominence [6, 7].

Tubal tonsils are covered by pseudostratified ciliated columnar epithelium with no crypts. They receive arterial supply via the ascending pharyngeal artery. Their lymphatic drainage is the same as the pharyngeal tonsil's [6, 7].

3.4 Oropharynx

The oropharynx extends from the OPI at the level of the soft palate to hyoid bone (C3 vertebra level). Anteriorly, the oropharynx communicates with the oral cavity via isthmus faucium which is limited by the PGa bilaterally, the uvula superiorly, and the posterior one third of the tongue that is in line with the sulcus terminalis inferiorly. According to the oncologic description, the oropharynx consists of four parts: the soft palate, the pharyngeal wall, the base of the tongue, and the palatine tonsillar fossa. So, a thorough understanding of the anatomy of oropharyngeal parts and adjacent structures is paramount in differential diagnosis and surgical interventions. It contains the palatine tonsils laterally and lingual tonsil in the retrolingual region anteriorly [6, 9].

3.5 Lingual tonsil

Lingual tonsils are the inferior-most of the ring and composed of numerous lymphoid nodules in the posterior third of the tongue. The stratified squamous nonkeratinized epithelium covers this lymphoid tissue aggregates forming large, irregular protrusions. Also, they have less branching shallow crypts which are covered by the reticulated epithelium and mucous salivary glands which are drained through several ducts into these crypts which appear after birth [6, 9].

Vascular supply to the lingual tonsils is provided with the dorsal lingual branches of the lingual artery and vein. Efferent lymphatic vessels of the lingual tonsil passing through the pharyngeal wall drain into the deep cervical lymph nodes [6, 7, 9].

3.6 Anatomy of the palatine tonsils

The palatine tonsils are two large, conspicuous almond-shaped mass of the lymphoid tissue forming the lower lateral aspect of the ring and localized in a triangular tonsillar fossa along the anterolateral border of the oropharynx on each side. The dimensions of the tonsils are about 10–15 mm in width and 20–25 mm in length in adults, but increase in children. The surface landmark of the tonsil corresponds to the lower part of masseter muscle in front of the angle of mandible [3, 6, 9]. The palatoglossal (anterior pillar) and palatopharyngeal (posterior pillar) mucosal folds diverge from the soft palate to form the boundaries of the tonsillar fossa, which lodges the palatine tonsils. These mucosal arches consist of the palatoglossal muscle (PGm) anteriorly and the PPm posteriorly. The palatine tonsil has two poles, upper and lower; two borders, anterior and posterior; two surfaces, medial and lateral; three mucosal folds, plica semilunaris, plica triangularis, and plica retrotonsillaris; and two depressions, supratonsillar and anterior tonsillar fossa [3, 6, 7].

3.6.1 Poles

Superiorly, the tonsil is free and expands into the soft palate where both arches join.

Inferiorly, the suspensory ligament, a band of fibrous tissue, connects the lower pole with the posterior one third of the tongue. Most of carcinomas develop in the tonsillolingual sulcus which separates the tonsil from tongue anteroinferiorly [3, 6].

3.6.2 Borders

The tonsillar fossa or sinus is a triangular space between the anterior pillar in front, the posterior pillar behind, and the dorsal surface of the posterior one third of the tongue inferiorly (**Figure 2**). Because the tonsils are positioned in it, its borders also limit the tonsil [7].

The anterior boundary is formed by the PGa which is composed of the PGm. A cylindrical muscle extends from the palatine aponeurosis to the posterolateral surface of the tongue and becomes continuous with the intrinsic transverse muscles [6, 7]. It acts as an antagonist of the LVPm and constricts the OPI during swallowing. All of the muscles of the tongue derive from the occipital myotomes except the PGm which is derivation of the fourth branchial arch. According to the variations of the origin of the PGm, the tongue elevator's function increases or decreases. During lateral pharyngoplasty, the relaxation of the SPCm and PGm is provided by the myotomy of these muscles [3, 10].

The posterior boundary is formed by the PPa including the PPm which originates from the palatine aponeurosis and the median part of soft palate by two heads and consists of muscle bundles medial and lateral to the LVPm. The lateral fibers of the PPm are composed of the longitudinal and transverse parts. The transverse part inserts into the pharyngeal raphe to join with the contralateral side, whereas the longitudinal part joins with the medial fibers at the posterior border of the soft palate and afterward are merged by the SPm [7, 8, 11]. This muscle bundle is observed to course downward along the inner surface of pharyngeal wall and inserts into

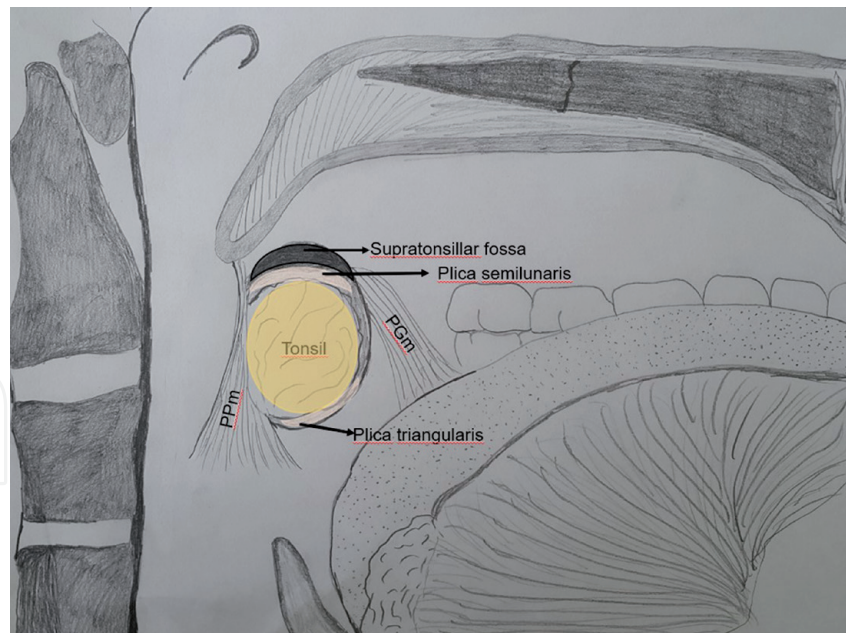


Figure 2.
The mucosal folds and arches of the palatine tonsil.

the palatal tonsil to form the posterior pillar. Also, some of its fibers insert into the posterior border of the thyroid cartilage with the stylopharyngeus muscle (StPm) and into the SPCm [11].

During velopharyngeal closure, the PPm performs various functions such as a sphincter with the SPCm, a puller of the pharyngeal wall medially in collaboration with the SPCm and StPm, and an elevator with the StPm because of the fibers of the PPm running in various directions [8, 11].

3.6.3 Mucosal folds

In the 14th–15th week of gestation, the primitive tonsil and tonsillar fossa develop indirectly from the endoderm part of the second pharyngeal arch. At first, the tonsil has two lobes and a plica intratonsillaris (intratonsillar cleft) between them. This plica later usually disappears, but it may infrequently transform into crypta magna [6, 12]. Because the tonsil does not completely fill this fossa, two small depressions exist at the upper and anteroinferior parts of the tonsillar fossa. They are separated from the tonsil by mucosal folds, known as the plica semilunaris and triangularis, which are remnants of the primitive tonsillar fossa (**Figure 2**) [6, 7].

Superiorly the plica semilunaris originates from the upper aspect of the PGa and extends backward toward the PPa along the upper pole of the tonsil. It encloses a small depression that is known as supratonsillar fossa which separates the tonsil from the uvula [6, 7].

Anteroinferiorly the plica triangularis, an inconstant mucosal fold, arises from the PGa and covers the anteroinferior part of the tonsil. It encloses a smaller fossa that is known as anterior tonsillar fossa, which is then obscured by its walls and forms the imbedded portion of the tonsil [6, 7].

Also, the plica infratonsillaris or retrotonsillaris may extend to the PPa at the posteroinferior part of the tonsil [7]. At first there is no lymphoid tissue in these fossae, but in childhood, they are usually transformed into lymphoid tissues, which are an exclusive hiding place for a constant lithified secretion and foreign bodies, causing an inflammation or quinsy [6, 7].

3.6.4 Surfaces

Medial surface is the free mucosal part of the tonsil that faces the oropharynx and contains bulging lymphoid projects. It is lined by stratified squamous nonkeratinized epithelium which contains polygonal superficial cells with microridges and numerous tubule-like long invaginations or orifices leading into tonsillar crypts. There are about 10–30 branching (primary and secondary) and anastomosing crypts, small pores, ranging in size between 5 and 25 μm . They increase the surface area of the tonsil up to 300 cm^2 except the anterior part for interactions between antigens and the nodular lymphoid tissue. Secondary crypts are branching part of the primary crypts and continue deeply into the lymphoid tissue and forms the lymphoid fronds. The largest and deepest crypt is called crypta magna or intratonsillar cleft which is localized near the upper part of the tonsil [6, 7, 9].

The transitional type nonkeratinized stratified epithelium, reticulated lymphoepithelium, with a discontinuous basement membrane covers the crypts with fenestrated capillaries and represents pores that are filled with large oval microvillus cells (M cells or dendritic cells) or lymphocytes (T and B cells). Dendritic cells play a role in the uptake and transport of antigens to extrafollicular T cell and B cell follicles [9, 12].

At about 5th month of gestation, there are no germinal centers, and the lymphocytes develop from the connective tissue cells or are relocated in the blood and lymph vessels [13]. After birth, the exogenous antigens cause immune response which is represented by the transformation of effector B cell into extrafollicular plasma cell in 2 weeks, and secondary follicles containing active germinal centers develop and rapidly expand not invade the surrounding tissue in the first decade of life [7, 12]. The tonsillar lymphoid follicles consist of the lymphoid (germinal centers) and non-lymphoid cells (reticular cells and dendritic cells/macrophages). The germinal center is composed of a central area of proliferating B cells which is surrounded by resting B and T cells. Between these follicles, high endothelial venules allow the entrance of T and B cells from the blood and the release of mature lymphocytes into blood [6, 9, 13]. So, the tonsils have efferent lymphatic vessels to connect to lymph nodes, but no afferent vessels unlike a lymph node. The lymphoid fronds are separated from the tonsillar bed by a capsule, which is firmly coherent to the lymphoid tissue by multiple septa or trabeculae that dissect the tonsillar parenchyma. The trabeculae consist of elastin fibers and reticular fibers that are composed of type III collagen and provide cytoskeletal support. So, each tonsil is in a fixed position, in contrast to other MALTs, which are distributed throughout the body, and to disconnect the tonsil from its capsule is impossible. Also, the nerves, lymphatic and blood vessels, pass through the trabeculae [6, 9, 12].

The tonsils are most immunologically active at 4–10 years of age, whereas the adenoids are at 4–6 years. Age-dependent involution of the tonsil which refers to the regression of the germinal centers and the proliferation of fibrous tissue including the capsule and trabeculae occurs by adolescence. Also, fat deposition in tonsils starts and increases after 25 years of age [12, 13].

Lateral surface is a base of the tonsil that is covered by well-defined fibrous capsule at the lateral wall of the tonsillar fossa, which is composed of five layers from within outward (**Figure 3**):

1. Tonsillar capsule, a thin false or surgical sheet, covers the tonsillar fossa as an appendage of the pharyngobasilar fascia. The upper part of this condensed

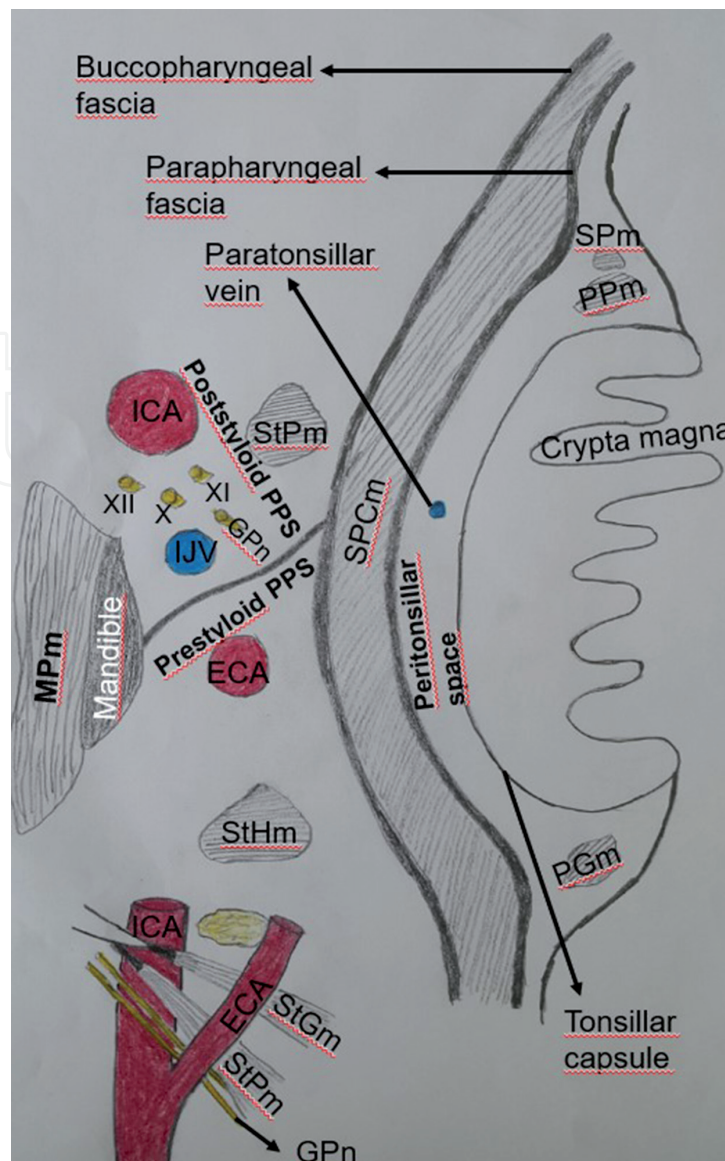


Figure 3.

The layers of the lateral pharyngeal wall at the level of tonsillar fossa, the parapharyngeal space compartments, and the structures between external and internal carotid arteries: SPm, salpingopharyngeus muscle; SPCm, superior pharyngeal constrictor muscle; PPm, palatopharyngeus muscle; PGm, palatoglossal muscle; StPm, stylopharyngeus muscle; StHm, stylohyoid muscle; StGm, styloglossus muscle; MPm, medial pterygoid muscle; GPn, glossopharyngeal nerve; PPS, parapharyngeal space; ICA, internal carotid artery; ECA, external carotid artery; X, vagus nerve; XI, accessory nerve; XII, hypoglossal nerve.

capsule is even and loosely fixed, whereas the lower part is irregular and intermingled with the pharyngeal muscle fibers and is firmly attached anteroinferiorly by the suspensory ligament to the posterior one third of the tongue. The tonsillar artery enters near this ligament. So, the surgical removal of the upper part of the capsule up to the lower third is very easy, but the lower part requires cautious resection [6, 7, 14].

2. Loose areolar tissue refers to the peritonsillar space between the tonsillar capsule and the pharyngobasilar fascia and contains the paratonsillar veins. A collection of pus in this space result in peritonsillar abscess or quinsy. It allows free movement of the pharyngeal muscles in the bed and makes easy to dissect the tonsil with capsule during tonsillectomy [6, 7].
3. Pharyngobasilar fascia or pharyngeal aponeurosis originates from the pharyngeal tubercle and covers the first layer of the SPCm and is limited with the

inferior fibers of the muscle. Efferent lymphatic vessels from the tonsil pierce through the buccopharyngeal fascia [7, 15].

4. The lateral wall of tonsillar fossa or tonsillar bed is mostly made up of the SPCm and pharyngobasilar fascia superiorly, the StPm posteriorly, and the stylohyoid ligament, middle pharyngeal constrictor (MPCm), the glossopharyngeal nerve (GPn), and styloglossus (StGm) muscles anteroinferiorly [7, 14, 15].

The SPCm narrows the superior part of the pharynx and is composed of four portions depending on their origins;

- a. The pterygopharyngeal portion originates from the posterior margin of the medial pterygoid plate and pterygoid hamulus.
- b. The buccopharyngeal portion arises from the pterygomandibular raphe.
- c. The mylopharyngeal portion originates from the posterior end of the mylohyoid line of the mandible.
- d. The glossopharyngeal portion arises from the side of the tongue.

All of the muscle fibers are inserted into the median pharyngeal raphe posteriorly [7, 11]. Frequently, there is a space of 1–3 cm between the SPCm and MPCm. The GPn between the stylohyoid ligament and StGm curve forward and medially and pass through this space at the level of the lower pole of the palatine tonsil. The StGm and stylohyoid ligament originate from the anterior margin of the styloid process near its apex. The StGm inserts into the inferolateral surface of the tongue and interdigitates with intrinsic longitudinal lingual muscle, whereas the stylohyoid ligament lies between the StPm and StGm and attaches to the hyoid bone medially [7, 14, 16]. The StGm functions to elevate and retract the base of the tongue. Inferolaterally the lingual artery crosses the StGm and gives the dorsal lingual branches medial to the attachment of the StGm to the base of tongue [16].

At the junction of pharyngeal constrictor muscles beneath the tonsil, the GPn gives tonsillar branch and afterward, extends into the base of tongue between the StGm and the stylohyoid ligament posteroinferiorly. The StPm originates from the posterior margin of the styloid process and courses downward along the posterolateral part of the stylohyoid ligament. Between the SPCm and MPCm, it passes and inserts to the PPM, MPCm, and pharyngeal mucosa [14, 17].

5. The buccopharyngeal fascia covers the lateral aspect of the SPCm medially and the medial pterygoid muscle anterolaterally. It forms anteromedial wall of the PPS and contains the pharyngeal plexus of nerves and vessels. The PPS like an inverted pyramid is situated between the lateral pharyngeal wall and the pterygoid musculature (**Figure 3**) [4, 15].

3.7 Anatomy of the parapharyngeal space

The base of the parapharyngeal pyramid is located at the skull base and its apex at the greater cornu of the hyoid bone. The PPS is bounded by the following structures:

- a. The buccopharyngeal fascia which covers the SPCm, the LVPm, and tensor veli palatini muscles medially,

- b. The fascia overlying the masticator space, the medial pterygoid muscle, the sphenomandibular ligament, the ramus of the mandible, and the deep lobe of the parotid gland anterolaterally,
- c. The styloid process, the StGm and StPm posterolaterally,
- d. The pterygomandibular raphe between the medial pterygoid plate and the mylohyoid line of the mandible and interpterygoid fascia anteriorly,
- e. The prevertebral fascia and muscles posteriorly.

Inferiorly, the direct communication of the PPS with the submandibular space may be seen at the apex [4, 7, 10, 15].

3.7.1 Parapharyngeal space compartments

Prasad et al. reported that the PPS is composed of three compartments as follows: the upper part of the PPS is located between the skull base and the axial plane passing through the inferior border of the lateral pterygoid muscle, the lower border of the middle part is formed by the axial plane passing through the mandibular insertion of medial pterygoid muscle, and the lower part is limited with the hyoid bone. The middle part of the PPS is situated at the level of the tonsillar fossa. Also, the upper and middle parts are divided into prestyloid and poststyloid compartments in relation to the styloid diaphragm. Thus, the PPS consists of five parapharyngeal subspaces [18].

The styloid diaphragm is a thick gray fascia which is composed of the posterior belly of the digastric muscle, the styloid musculature (StPm, StGm and stylohyoid muscle-StHm), and the stylohyoid and stylomandibular ligaments. It divides the lower PPS into the prestyloid and poststyloid compartments by extending from the styloid process to the parotid fascia (**Figure 3**). The prestyloid space is localized between the medial pterygoid muscle and SPCm [7, 15, 18].

In the prestyloid part of the upper PPS, minor salivary glands, the posterior division of the mandibular nerve, the internal maxillary artery, fat pad, and tensor veli palatini muscle are located. In the poststyloid part of the upper PPS, the carotid sheath which consists of the internal carotid artery (ICA), internal jugular vein (IJV), vagus nerve, and also just in this superior section the ascending pharyngeal artery, cervical sympathetic chain, and the lower cranial nerves, IX, XI, and XII, are situated [7, 18].

In the prestyloid part of the middle PPS, the fat pad, a deep lobe of the parotid gland, from superior to inferior numerous tonsillar branches of the descending palatine, the ascending pharyngeal, and the ascending palatine arteries between the StGm and StPm are located. In the poststyloid part of the middle PPS, the curves of the internal maxillary, facial, and lingual arteries, cervical sympathetic chain, and the carotid sheath which consists of the ICA, IJV, and the lower cranial nerves (CNIX–CNXII) are situated [5, 7, 18].

3.7.2 Surgical landmarks in the parapharyngeal space in relation to the palatine tonsil

Different surgical procedures can be used in treatment of the upper airway obstruction due to tonsillar or adeno-tonsillar hypertrophy and peritonsillar abscess. Classic tonsillectomy consists of full removal of the tonsil with its capsule by dissecting the peritonsillar space with or without adenoidectomy. In the post-acute

tonsillitis, a peritonsillar abscess may spread into the PPS through the buccopharyngeal fascia. Due to the close proximity of the PPS with the surrounding spaces including pharyngeal mucosal, retropharyngeal, masticator, and parotid spaces, the lesions in these spaces commonly spread into the PPS and result in secondary lesions [4, 5].

Sun et al. reported that the localization of the tumors in the PPS can be identified by some anatomical landmarks during surgical approaches. Because of the tumors in the upper PPS are mostly benign and located in the prestyloid space, the endoscopic transnasal transpterygoid approaches to this region require detailed anatomic knowledge of the surgical anatomic landmarks in this space. They demonstrated that the surgical anatomic landmarks in the prestyloid part of the upper PPS are as follows: the pterygoid process with medial and lateral plates, the tensor veli palatini, the SPCm, the lateral and medial pterygoid muscles, and the fat pad. In the prestyloid part of the lower PPS, the PGa, the SPCm, the pterygomandibular raphe, fat tissue, and the styloid diaphragm could be used as surgical anatomical landmarks during endoscopic transoral approach (**Figure 3**) [19].

Approximately 80% of primary oropharyngeal tumors originate from the tonsillar fossa and their incidence in younger patients increases. The tumors in the tonsillar fossa and the PPS can be removed by endoscope-assisted lateral oropharyngectomy approaches, transoral robotic surgery, or laser microsurgery. The lateral pharyngeal wall is composed of three deep fascia layers from inward to outward: the capsule of the tonsil, the pharyngobasilar fascia, and the buccopharyngeal fascia [5, 15, 19]. Depending on these fascia layers, De Virgilio et al. reported their lateral oropharyngectomy classification based on three types of surgical procedures and four possible extensions (superior, soft palate; posterior, pharyngeal wall; inferior, base of the tongue; anterior, retromolar trigone) [5].

Type 1 contains the removal of the palatine tonsil deep to the pharyngobasilar fascia with the resection of all or part of the anterior pillar excluding the SPCm. The aim of this procedure is mostly diagnostic, but it can be used in surgical treatment of noninvasive hyperplasia, dysplasia, or carcinoma in situ of the tonsil.

Type 2 is resection of the palatine tonsil, the PGm, the PPm, and the SPCm deep to the buccopharyngeal fascia. It can be therapeutic for invasive malignant tumors not grossly infiltrating the SPCm.

Type 3 includes the resection of the buccopharyngeal fascia with extension to the pterygoid muscle and PPS adipose corpus in addition to Type 2 contents. According to the extension of the tumor, the resection of the PPS tissue up to the exposure of the ICA could be included, and also a flap coverage for the ICA is required [5].

Similarly, Mirapeix et al. identified an applicable dissection method based on the anatomic stratification and evident anatomic landmarks [4]. They performed the dissections layer by layer from within outward and described this technique by dividing the lateral oropharyngeal wall into three layers:

The first layer, medial to styloid muscles, includes important surgical landmarks such as the SPCm, PGm, PPm, and StGm, the pharyngobasilar fascia, and a vascular network, which is composed of the branches of the descending and ascending palatine arteries and the ascending pharyngeal artery. The vascular supply of the tonsillar fossa can be identified by the PGm and PPm, and also the lingual branch of the GPn mostly crosses at the midpoint between PGm and PPm or along the posteroinferior edge of the StGm.

The second layer is observed after resection of the constrictor muscles and located in the PPS medial to the styloid diaphragm. The surgical landmarks are composed of the styloid musculature, the buccopharyngeal fascia, the stylohyoid ligament, the pharyngeal venous plexus, and the GPn. The insertion point of the

StGm refers to junction of the tongue with anterior pillar, and the lingual branch of the GPn can be identified along the posteroinferior border of the StGm. The pharyngeal venous plexus is located in a space between the StGm and SPCm. The facial artery and the hypoglossal nerve cross the StHm which extends parallel to the stylohyoid ligament. The GPn travels downward along the posterolateral aspect of the StPm.

The third layer lateral to styloid diaphragm refers to the poststyloid part of the PPS. Surgical landmarks in this layer consist of the styloid musculature, the posterior belly of the digastric muscle, the ICA, the hypoglossal nerve, and lingual and facial arteries. Especially, the StGm is an essential landmark to identify the localization of the ICA posterolaterally, the lingual nerve anteriorly, and the submandibular gland inferolaterally. The hypoglossal nerve crosses laterally to medially over the ascending pharyngeal originating from the superolateral border of the external carotid artery (ECA) in the poststyloid part of the lower PPS [4].

During transoral robotic surgery (TORS), the dissection of the SPCm from the pterygomandibular raphe refers to a window into the prestyloid compartment of the PPS. The tendon of the medial pterygoid muscle leads to identification of the buccopharyngeal fascia and indicates a safe plane in the prestyloid compartment of the PPS [7, 19]. Also, the plane that is constituted by the styloid musculature and the stylohyoid ligament is an essential surgical landmark for ICA identification. Wang et al. demonstrated that the styloid process, styloid diaphragm, pharyngeal venous plexus, GPn, and pharyngeal branch of the vagus are located between the ECA and the ICA and subdivide the PPS into prestyloid and poststyloid spaces (**Figure 3**). The curves of the branches of the ECA (lingual, facial, ascending pharyngeal, internal maxillary arteries) are located in the prestyloid space, and also the ascending pharyngeal artery crosses the StGm at the distal third near the tonsillar fossa surgical field [20]. In addition, the lingual artery and hypoglossal nerve are located lateral to the StGm, and the lingual artery passes between greater cornu of hyoid and the StGm where it has high risk of hemorrhage during the resection of the base of the tongue [21]. The fact that in the PPS the facial artery is located inferolateral to the StGm is of great importance, because a dissection lateral to the StGm or resection of tonsillar malignancy may result in significant hemorrhage. In PPS after branching from the facial artery, the tonsillar and ascending palatine arteries course between the StGm and the StPm and then pierce the SPCm to supply the tonsil [22]. So, the fact that the StGm is in close relationship with the branches of the ECA should be kept in mind when the transoral dissection space at the level of the tonsillar fossa is dissected in the superolateral direction, and the dissection deep into the plane of this muscle must be performed rigorously and accurately [16, 20].

In the PPS lateral to the styloid diaphragm, the ICA lies about 10–20 mm behind the palatine tonsil at the level of the epiglottis apex, whereas its distance to the ET is approximately 23.5 mm. So, it is closer to the lateral pharyngeal wall in the poststyloid part of the lower PPS than in the upper PPS, and the risk of arterial trauma during tonsillectomy increases with a decrease in the distance to the pharyngeal wall. Also, the level of the common carotid artery bifurcation higher than the epiglottis apex is more susceptible to common carotid artery trauma during surgery [23]. During radical tonsillectomy, because the lingual nerve lies lateral to the SPCm, it may be injured at the anterior border of the medial pterygoid muscle [15].

The GPn extends from the jugular foramen to the base of the tongue in the lateral wall of the pharynx. Because of the close relationship of the GPn with the StPm, it is divided into three parts: upper (jugular foramen, upper border of the StPm), middle

(upper-lower borders of the StPm), and lower (lower borders of the StPm, the base of the tongue) [17].

The upper part travels between the ICA and IJV behind the styloid process and gives the carotid body and carotid sinus branches in the poststyloid part of the upper PPS.

The middle part extends downward along the inferolateral border of the StPm and gives off branches to the StPm and pharyngeal wall in the poststyloid part of the lower PPS. Particularly, this part passes obliquely anterior to the distal segment of the ICA and may result in vascular injury.

The lower part passes through a space or slit between the SPCm and MPCm to enter the pharynx. Between the StGm and StPm, it lies along the inferior border of the palatine tonsil or beneath the capsule and gives the tonsillar branch. Generally, it gives terminal branches at the junction of the PPa with the base of tongue, known as glossotonsillar sulcus, which is anatomic landmark for the terminal part of the GPn deep to the SPCm [17].

During surgical interventions including transoral tonsillectomy, tumor resection, and the SPCm block, the integrity of this nerve may be damaged and result in dysphagia and taste disturbance. In recurrent tonsillitis, the adherence of the capsule with surrounding structures makes it difficult to remove the hypertrophic tonsillar capsule from the tonsillar bed, or the dissection of the capsule which is firmly adherent with the lingual branch of this nerve causes disturbance of the nerve functions [3, 7, 17]. During transoral surgery, early description of the StPm allows to specify the GPn which crosses over the ICA and serves as a surgical landmark to protect it in the PPS. Also, the surgeon should keep in mind the association of the GPn with a venous plexus in the glossotonsillar sulcus to prevent iatrogenic bleeding during surgical dissection.

3.8 Vascular network and innervation of the tonsils

3.8.1 Arterial supply

The tonsil and tonsillar fossa with boundaries are supplied by the branches of the ECA including lingual, facial, ascending pharyngeal, and internal maxillary arteries (**Figure 4**).

The upper part is supplied by descending palatine artery branch of the internal maxillary artery and the middle and inferior branches of the ascending pharyngeal artery.

The middle part is supplied by tonsillar branch of the facial artery.

The lower part is supplied by an ascending palatine artery branch of the facial artery and dorsal lingual branch of the lingual artery [20, 23].

3.8.2 Venous drainage

The veins of the tonsil and tonsillar fossa drain into the paratonsillar vein and then into the pharyngeal venous plexus. This plexus drains through the facial vein into the IJV (**Figure 4**) [6, 7].

3.8.3 Lymphatic drainage

The lymphatics pierce the SPCm and drain into the upper deep cervical lymph nodes principally jugulodigastric lymph nodes which are located below the angle of the mandible posteriorly [6, 7].

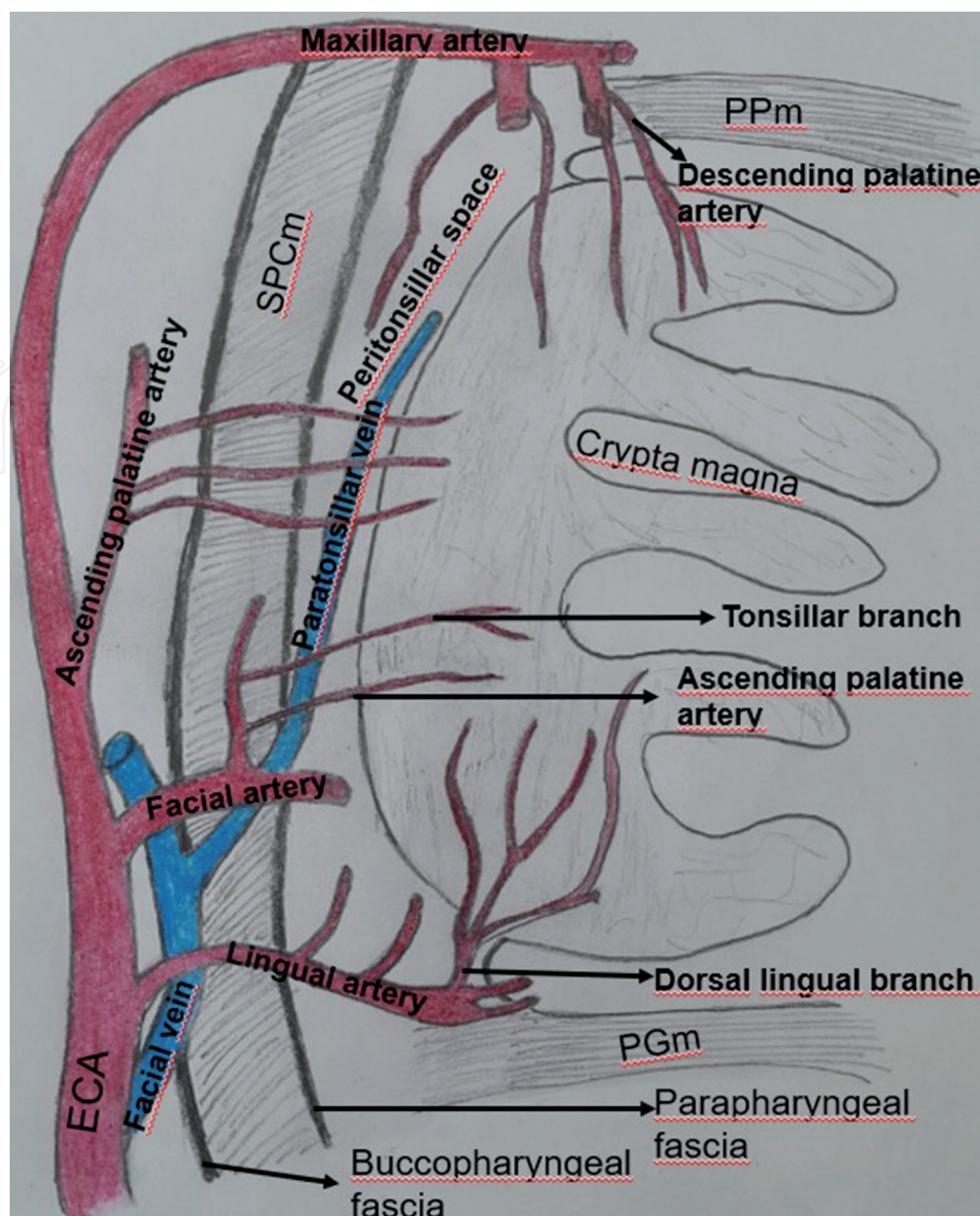


Figure 4.
The vascular supply of the tonsil: PPm, palatopharyngeus muscle; PGm, palatoglossal muscle; SPCm, superior pharyngeal constrictor muscle.

3.8.4 Nerve supply

General sensation of the tonsil and tonsillar fossa is supplied by the tonsillar branches of the GPN and the lesser palatine branch of the pterygopalatine ganglion (the maxillary division of the trigeminal nerve) [6, 7].

4. Conclusions

Benign or malign lesions in the tonsil and tonsillar fossa may penetrate the lateral wall of the pharynx, or the PPS may be distorted evidently by the tumors. Due to the anatomical complexity with vital neurovascular structures in the PPS, transoral robotic approach to this region makes it necessary to identify the surgical anatomic landmarks which are required to perform effective surgical intervention quickly and accurately. The detailed and precise anatomic knowledge of the tonsillar region and the PPS allows surgeon to carry out wide resections in a confined

space. In transoral approaches, the classification of the dissection method based on the anatomic stratification or the surgical procedures which is oriented to cardinal points is essential for preoperative planning and to prevent the iatrogenic complications.

Conflict of interest


The author reports no conflict of interest concerning the materials used in this paper. And the author has no personal financial or institutional interest in this article.

Author details

Gülay Açar
Necmettin Erbakan University, Meram Faculty of Medicine, Department of
Anatomy, Konya, Turkey

Address all correspondence to: gulayzeynep73@gmail.com

IntechOpen

© 2020 The Author(s). Licensee IntechOpen. This chapter is distributed under the terms of the Creative Commons Attribution License (<http://creativecommons.org/licenses/by/3.0>), which permits unrestricted use, distribution, and reproduction in any medium, provided the original work is properly cited. 

References

- [1] Ruddle NH, Akirav EM. Secondary lymphoid organs: Responding to genetic and environmental cues in ontogeny and the immune response. *Journal of Immunology*. 2009;**183**(4):2205-2212. DOI: 10.4049/jimmunol.0804324
- Review
- [2] Masieri S, Trabatttoni D, Incorvaia C, De Luca MC, Dell’Albani I, Leo G, et al. A role for Waldeyer’s ring in immunological response to allergens. *Current Medical Research and Opinion*. 2014;**30**(2):203-205. DOI: 10.1185/03007995.2013.855185
- [3] Masters KG, Lasrado S. *Anatomy, Head and Neck, Tonsils*. StatPearls [Internet]. Treasure Island (FL): StatPearls Publishing; 2020
- [4] Mirapeix RM, Tobed Secall M, Pollán Guisasola C, Garcia Lorenzo J, Lluansí Planella J, Viña Soria C, et al. Anatomic landmarks in transoral oropharyngeal surgery. *The Journal of Craniofacial Surgery*. 2019;**30**(2):e101-e106. DOI: 10.1097/SCS.00000000000004935
- [5] De Virgilio A, Kim SH, Magnuson JS, Holsinger C, Remacle M, Lawson G, et al. Anatomical-based classification for transoral lateral oropharyngectomy. *Oral Oncology*. 2019;**99**:104450. DOI: 10.1016/j.oraloncology.2019.104450
- [6] Regauer S. Nasopharynx and Waldeyer’s ring. In: Cardesa A, Slootweg PJ, editors. *Pathology of the Head & Neck*. New York: Springer; 2006. pp. 183-189.ch6
- [7] Brodsky L, Poje C. Tonsillitis, tonsillectomy, and adenoidectomy. In: Bailey BJ, Johnson JT, Newlands SD, editors. *Head and Neck Surgery -Otolaryngology*. 4th ed. Philadelphia: Lippincott Williams & Wilkins; 2006. pp. 1183-1195
- [8] Fukino K, Tsutsumi M, Sanudo J, Ono T, Akita K. Anatomical significance of the spatial distribution of the palatopharyngeus with regard to velopharyngeal closure. *The Cleft Palate-Craniofacial Journal*. 2019;**56**(6):744-750. DOI: 10.1177/1055665618813082
- [9] Fossum CC, Chintakuntlawar AV, Price DL, Garcia JJ. Characterization of the oropharynx: Anatomy, histology, immunology, squamous cell carcinoma and surgical resection. *Histopathology*. 2017;**70**(7):1021-1029. DOI: 10.1111/his.13140
- [10] Goyal N, Yoo F, Goldenberg D. Oropharyngeal anatomy and radical tonsillectomy. In: Goldenberg D, Goyal N, editors. *Robotic Head and Neck Surgery: An Anatomical and Surgical Atlas*. 1st ed. New York, Stuttgart: Thieme Publishers; 2017. pp. 1-4. DOI: 10.1055/b-0038-149746.ch1
- [11] Sakamoto Y. Spatial relationship between the palatopharyngeus and the superior constrictor of the pharynx. *Surgical and Radiologic Anatomy*. 2015;**37**(6):649-655. DOI: 10.1007/s00276-015-1444-5
- [12] Isaacson G, Parikh T. Developmental anatomy of the tonsil and its implications for intracapsular tonsillectomy. *International Journal of Pediatric Otorhinolaryngology*. 2008;**72**(1):89-96
- [13] Noussios G, Xanthopoulos J, Zaraboukas T, Vital V, Konstantinidis I. Morphological study of development and functional activity of palatine tonsils in embryonic age. *Acta Otorhinolaryngologica*. 2003;**23**(2):98-101
- [14] Ohtsuka K, Tomita H, Murakami G. Anatomy of the tonsillar bed: Topographical relationship between the palatine tonsil and the lingual branch of

the glossopharyngeal nerve. *Acta Otolaryngologica*. 2002;**546**:99-109

[15] Gun R, Durmus K, Kucur C, Carrau RL, Ozer E. Transoral surgical anatomy and clinical considerations of lateral oropharyngeal wall, parapharyngeal space, and tongue base. *Otolaryngology and Head and Neck Surgery*. 2016;**154**(3):480-485. DOI: 10.1177/0194599815625911

[16] Laccourreye O, Orosco RK, Rubin F, Holsinger FC. Styloglossus muscle: A critical landmark in head and neck oncology. *European Annals of Otorhinolaryngology, Head and Neck Diseases*. 2018;**135**(6):421-425. DOI: 10.1016/j.anorl.2017.11.012 Review

[17] Wang C, Kundaria S, Fernandez-Miranda J, Duvvuri U. A description of the anatomy of the glossopharyngeal nerve as encountered in transoral surgery. *Laryngoscope*. 2016;**126**(9):2010-2015. DOI: 10.1002/lary.25706

[18] Prasad SC, Piccirillo E, Chovanec M, La Melia C, De Donato G, Sanna M. Lateral skull base approaches in the management of benign parapharyngeal space tumors. *Auris Nasus Larynx*. 2015;**42**(3):189-198

[19] Sun X, Yan B, Truong HQ, Borghei-Razavi H, Snyderman CH, Fernandez-Miranda JC. A comparative analysis of endoscopic-assisted transoral and transnasal approaches to parapharyngeal space: A cadaveric study. *Journal of Neurological Surgery B Skull Base*. 2018;**79**(3):229-240. DOI: 10.1055/s-0037-1606551

[20] Wang C, Kundaria S, Fernandez-Miranda J, Duvvuri U. A description of arterial variants in the transoral approach to the parapharyngeal space. *Clinical Anatomy*. 2014;**27**(7):1016-1022. DOI: 10.1002/ca.22273

[21] Gun R, Ozer E. Surgical anatomy of oropharynx and supraglottic larynx

for transoral robotic surgery. *Journal of Surgical Oncology*. 2015;**112**(7):690-696. DOI: 10.1002/jso.24020 Review

[22] Mohamed A, Paleri V, George A. A cadaveric study quantifying the anatomical landmarks of the facial artery and its parapharyngeal branches for safe transoral surgery. *Head & Neck*. 2019;**41**(9):3389-3394. DOI: 10.1002/hed.25862

[23] Zajac HJ, Lachowski K, Lis A, Kręcicki T, Garcarek J, Guziński M, et al. The anatomical relation of the extracranial internal carotid artery in the parapharyngeal space. *Advances in Clinical and Experimental Medicine*. 2019;**28**(5):601-607. DOI: 10.17219/acem/78350