

# We are IntechOpen, the world's leading publisher of Open Access books Built by scientists, for scientists

6,900

Open access books available

185,000

International authors and editors

200M

Downloads

Our authors are among the

154

Countries delivered to

TOP 1%

most cited scientists

12.2%

Contributors from top 500 universities



WEB OF SCIENCE™

Selection of our books indexed in the Book Citation Index  
in Web of Science™ Core Collection (BKCI)

Interested in publishing with us?  
Contact [book.department@intechopen.com](mailto:book.department@intechopen.com)

Numbers displayed above are based on latest data collected.  
For more information visit [www.intechopen.com](http://www.intechopen.com)



# Diagnosis and Treatment of Midface Trauma in the Context of Polytrauma: Characteristics during COVID-19 Pandemic Conditions

*Daniela Vrinceanu, Bogdan Banica and Mihai Dumitru*

## Abstract

Midfacial trauma is never an immediate therapeutic emergency excepting cases with nasal bleeding and risk of aspiration or requiring a permeable airway that will allow intubation when appropriate. The patient with polytraumas and mid-facial fractures who needs ear, nose, and throat (ENT) or oral and maxillofacial (OMF) surgery should be reassessed at 24 and 48 hours to determine the optimal operating time. The surgical indication should be established according to esthetic and functional deficits. We consider that the optimal operative moment for the lesions of the midface is at 4–5 days after the trauma, under the conditions of a stable hemodynamic, respiratory, and afebrile patient. We propose the schematic presentation of the principles of diagnosis and treatment for midface trauma. We will discuss also some aspects of midfacial trauma during coronavirus disease-2019 (COVID-19) pandemic conditions. We must assume every patient with polytrauma as a COVID-19-positive patient. So, it is necessary to have a special circuit for a suspect COVID-19 polytrauma patient between emergency room (ER) department, operating room, and intensive care unit (ICU). All medical team must wear high-level personal protective equipment (PPE) during emergency treatment of a craniofacial trauma in the context of polytrauma until we get the result of RT-PCR testing.

**Keywords:** face, trauma, diagnosis, treatment, COVID-19

## 1. Introduction

Trauma at the level of the head and neck represents a public health problem due to the esthetic and functional complications with major social and economic impacts. Among the possible causes for trauma stand car accidents, domestic violence, work-associated accidents, and even terrorist attacks [1].

These cases often have a legal consequence, and in this aspect, the ear, nose, and throat (ENT) surgeon represents a source of medical information important in establishing the degree of judiciary responsibility. The ENT surgeon must bear this in mind and keep accurate records of the procedures performed. Also different

pathologies before trauma along with alcohol consumption and high-risk drug intoxication are mentioned [2].

Photographically documenting the case before and after surgical procedures with subsequent electronic storage for later use is particularly important. In each department, there should be a person assigned to archiving images in potential legal and scientific cases of interest associating tumors or deep neck infections with the patient's death [3].

Patients with multiple trauma lesions admitted to the emergency department undergo assessment according to the ABCDE algorithm: A, airway plus spinal cord control; B, breath and ventilation; C, circulation and hemorrhage control; D, disability/neurologic status; and E, complete exposure but preventing hypothermia [4].

Facing a patient with multiple trauma lesions, a thorough head-to-toe lesion inventory with additional consults performed by the abdominal surgeon, thoracic surgeon, orthopedic surgeon, and others is necessary. For the head lesions, opinions from the neurosurgeon, ENT surgeon, OMF surgeon, ophthalmologist, and plastic surgeon should be gathered. The central pawn in this endeavor is the emergency specialist in the first stage and afterward the anesthesiologist supervising the case in the intensive care unit (ICU). Other lesions have a priority before facial fractures unless there is massive nasal bleeding with cerebrospinal fluid (CSF) leak or lesions hindering the oral intubation for general anesthesia. In the first case, the ENT surgeon must perform emergency nasal packing and in the other scenario must submit the patient to an emergency tracheostomy [5].

## **2. Principles of diagnosis in craniofacial trauma in cases with multiple trauma**

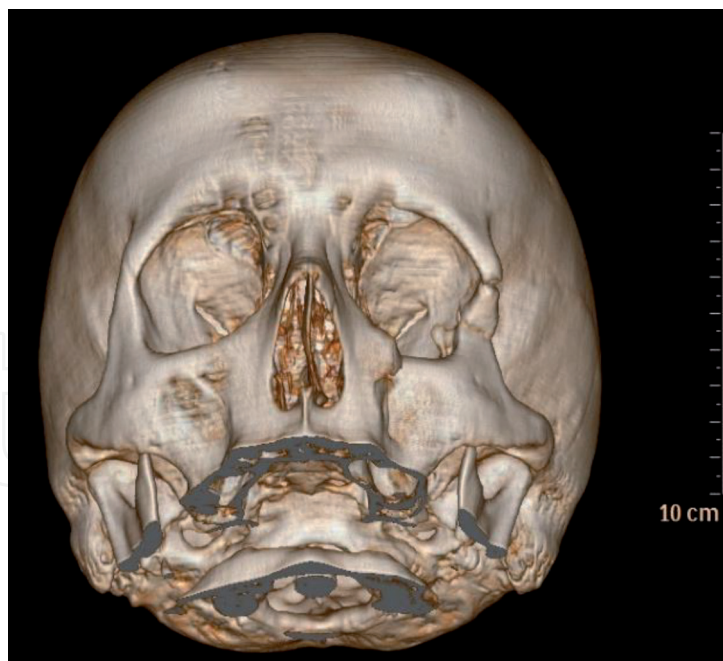
The diagnosis must be correct and complete without the pressure of emergency, life-threatening bleeding, or from the patient's relatives or even other surgical specialties. After stopping any nasal bleeding and securing airway patency, perform head and neck computed tomography (CT) scan [6].

While performing the clinical examination in head trauma cases, pay attention to important nasal pyramid deviations, abnormal motility of the maxillary, trismus, facial hematomas surrounding both orbital regions, and exophthalmia. Especially important is vision assessment performed by the ophthalmologist. The clinical examination should be performed in a gentle but secure fashion with a predefined succession of maneuvers from the upper third of the face downward and ending with visualizing the nasal and oral cavities [7].

Do not forget to assess the presence of blood in the ear canal because it could be a sign of skull base fracture. ENT endoscopy should be reserved for the 24- to 48-hour follow-up to confirm the presence of a nasal cerebrospinal fluid leak. CSF leak is confirmed also through a lab workup by collecting the seeping clear fluid in a sterile recipient and looking for beta-transferrin levels [8].

Head CT scan in axial and coronal sections is compulsory, but frequently sagittal section reconstructions offer useful data about the anterior segment of the skull base and orbital floor. 3D reconstructions are useful for surgical planning and even explaining the patient the complexity of the trauma and improve informed consent (**Figure 1**) [9].

While formulating the complete diagnosis of cranial and facial trauma, one must take into consideration the various classification systems, imaging data, and even the cause and mechanism of trauma production. There are still limitations in



**Figure 1.**  
*CT scan with a complex maxillary-orbital-zygomatic fracture on the left side.*

prediction with high accuracy of the functional and esthetic outcomes of the case. Afterward, perform a complete inventory of the other trauma lesions [10].

## **2.1 Classification of midfacial fractures according to LeFort**

In 1901 LeFort described the midfacial fracture types I, II, and III after previous experimentally induced models. This classification is in use even nowadays because it is practical in nature and enables a common language between the trauma specialists. Often fracture lines are not complete bilaterally but still enable correct assessment of middle vault head trauma [11].

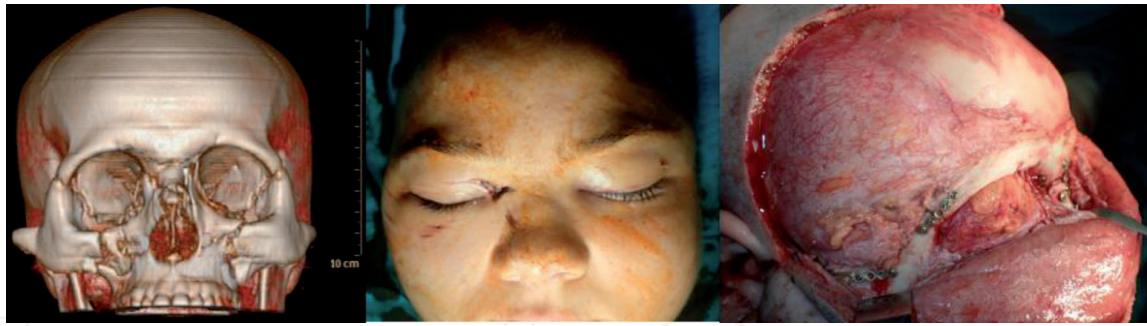Low-transverse fracture LeFort type I has a direct mechanism of production through frontal and lateral impact or indirect by applying pressure in the mental region with the mouth closed. Fracture lines begin in the lower third of the nasal vault, above the dental roots through the canine fossa, along the zygomatic ridge through the maxillary tuberosity, and the lower third of the pterygoid. Also, there could be two possible scenarios with fixed or mobile fragments [12].

The clinical facial exam is scarce. The oral cavity presents chemosis in the labial groove and oral vestibule with dental occlusion dysfunctions and specific pain-triggering points behind the third molar teeth on the external pterygoid plate. In the case of a mobile fractured fragment, there is a supplementary fracture line in the vomer bone. Therefore, the physical examination will record the upper mobile alveolar bone along with the hard palate [13].

Middle-level transverse fracture LeFort type II presents a direct mechanism of production through a frontal impact in the middle vault of the viscerocranium. Fracture lines begin in the middle third of the nasal opening through the nasal bones bilaterally, the ascending arch of the maxillary bone, the lacrimal bone, the ethmoid bone, the floor of the orbit till the speno-maxillary junction, the anterior wall of the maxillary sinus, and the middle third of the pterygoid plate [14].

The physical examination is marked by the presence of marked swelling of the face, inferior eyelid chemosis with epiphora, depression of anteroposterior facial landmarks with preservation of the zygomatic bones, depression of the nasal bones, nasal





**Figure 2.**

*Fracture LeFort type III—CT scan with 3D reconstruction, clinical aspect before surgery, and surgical reconstruction with titanium plates.*

bleeding, subcutaneous emphysema, and infraorbital groove numbness. The oral cavity exam shows swelling of the superior vestibule, dental occlusion difficulties in vertical and sagittal planes, maxillary depression, and lack of lateral teeth superposition [15].

High-level transverse fracture LeFort type III has a violent mechanism of production at the level of the glabella or from lateral. The trajectory of such a fracture passes through the vomer, upper third of the nasal bones, ascending arch of the maxillary, ethmoid bone, floor of the orbit, external orbital wall, upper third of the pterygoid plate, and zygomatic arch [16].

At physical examination, the case presents depression of the nasal vault, tumefaction around both orbits, blood in the anterior eye pole, nasal bleeding, double vision, and facial subcutaneous emphysema. The oral cavity exam shows an abnormal movement in vertical and transverse planes of the mandible with retrognathic maxillary bone and abnormal teeth occlusion (**Figure 2**) [17].

An emergency CT scan is compulsory in both axial and coronal planes with 3D reconstructions extremely helpful in planning surgery [18].

## **2.2 Classification of fractures of the middle facial vault according to the bones involved**

There are nasal fractures, combined nasal-orbital-ethmoid fractures, and complex maxillary-orbital-zygomatic fractures. This classification has a clinical importance and eases communication between clinicians [19].

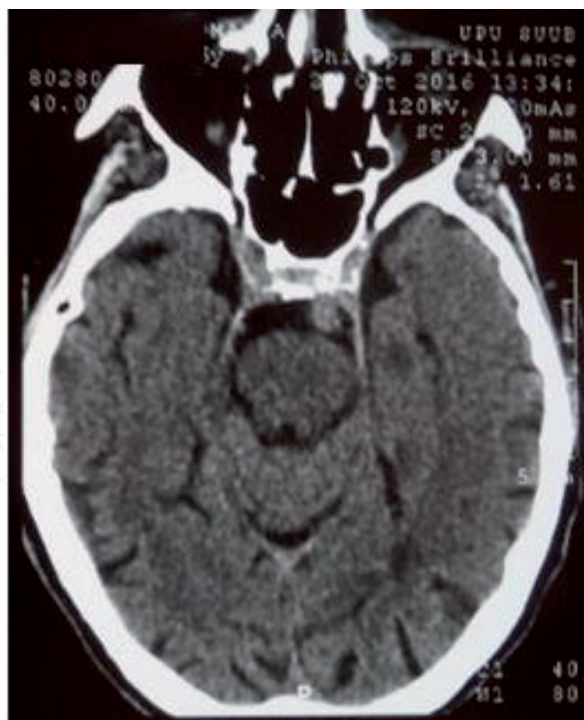
## **2.3 Classification of midfacial fractures given the impact energy**

From this point of view, we encounter fractures with high energy and low energy. So, the diagnosis should include the landmarks in the midface affected according to the clinical exam, along with the information provided by the CT scan and ideally visualizing pretreatment 3D reconstructions [20].

# **3. Principles of treatment in craniofacial multiple trauma cases**

## **3.1 Preliminary data**

First, we have to secure the airway. Then, control nasal bleeding and other hemorrhages at the level of head and neck (**Figure 3**). Exclude any lesion at the level of the cervical spine. Also, check for any other occult life-threatening lesions such as spleen ruptures. This implies a second top-to-toe complete evaluation in 48 hours from the admission time and before any surgical interventions at the level



**Figure 3.**  
 CT scan performed for a nasal vault concussion without fracture of the nasal bones but with a fracture at the level of the ethmoid perpendicular plate associated with CSF leak (accidental fall on the stairs).

of the head and neck along with a complete inventory of all the lesions presented by the patient. Moreover, question the patient if possible or the relatives about prior associated pathology which could have an essential role in the prognosis and treatment outcome [21].

### 3.2 Clinical signs requiring a dynamic evaluation in the early stage of admission

Some clinical signs are requiring recurrent analysis during the early time of admission of multiple trauma patients: state of consciousness or drowsiness, increase in facial hematomas, increase pressure in orbital hematomas, high fever, the appearance of CSF at the level of the nasal cavity or the external ear canal, double vision, aggravation of mastication impairment, and loss of sensitivity in trigeminal nerve territory [22].

### 3.3 Treatment plan in craniofacial trauma cases

This sequence of steps should focus on repairing all the lesions with full restoration of function and the esthetic aspect before the trauma. The therapy plan should focus initially on clinical signs and secondarily on the CT exam. Global management of the case should benefit from the input of various specialists such as ICU specialists, anesthesia specialists, and surgeons from all other backgrounds available in the healthcare unit on call. Recent photos of the patient along with dental X-rays before trauma may be useful in lesion assessment and clear future legal aspects. Surgical interventions may be postponed due to increasing facial hematomas, nasal CSF leak, high fever, and thoracic concussions [23].

### 3.4 Specific considerations regarding the midface trauma

In cases with severe deformity, our experience recommends avoiding a conservative approach via small multiple regional “conservative/cosmetic” incisions. For

a successful outcome, it is best to achieve a complete regional exposure through a coronal or hemicoronal flap (**Figure 4**) combined with a lower eyelid or intraoral incision if necessary [24].

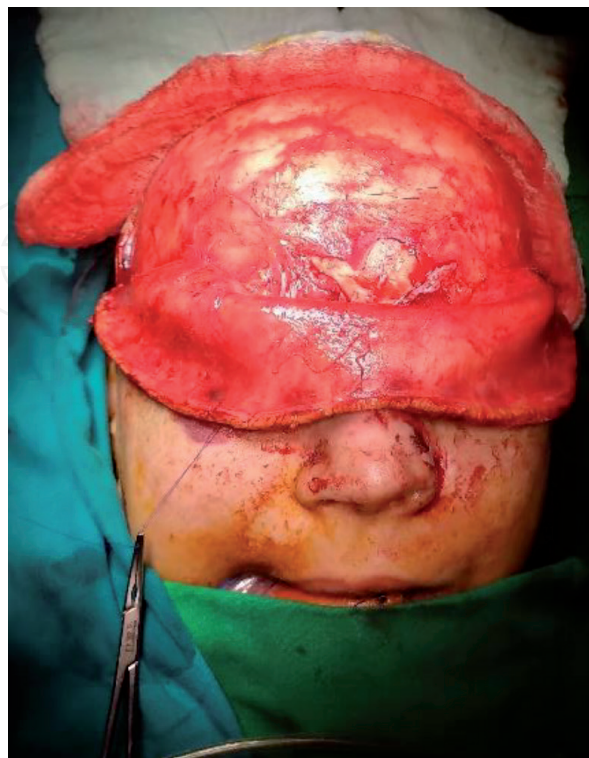The reduction of the zygomatic bone is best achieved via an intraoral vestibular approach as opposed to a temporalis approach, due to the loosening of the periosteum over the anterior surface of the maxilla and zygomatic buttress. Also, it allows sinus cavity exploration, evacuation of the sinus hematoma with an antiseptic irrigation, and, if necessary, plating along the maxilla-zygomatic buttress [25].

In orbital floor reconstruction, the reconstruction material should extend posteriorly to the orbital ridge of the palatine bone with a slight upward contour. A short, inferiorly inclined plate leads to persistent hypoglobus. In large orbital floor defects, we believe that it is important to avoid using other alloplastic materials than titanium due to the risk of globe mispositioning and possible local inflammatory response due to lack of rigid fixation and mobility (**Figure 5**) [26].

Do not delay the surgical intervention for more than 14 days. Except in a few numbers of severe polytrauma cases, the general condition of the patient should be stabilized in this time frame, and definitive treatment should be undertaken. After 14 days the case must follow the protocol of secondary reconstruction, because of the consolidation of the fractures and the treatment is incomparably more difficult [27].

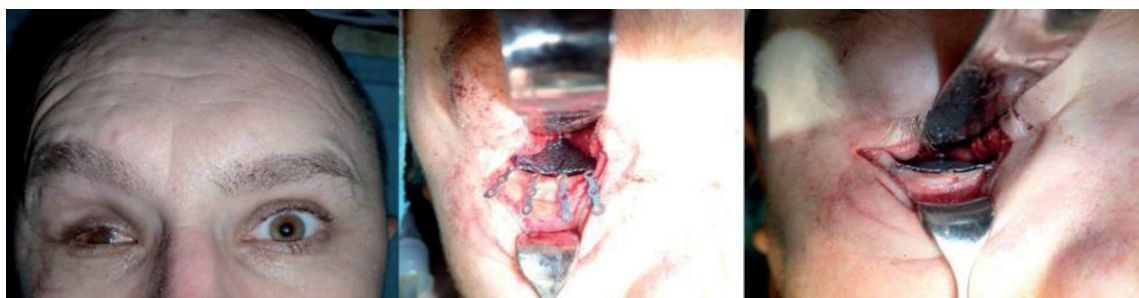### 3.5 Nasal bone fractures

These fractures require closure early within 24–48 hours except the cases with massive facial swelling and presenting nasal CSF leak. A clinical examination of the modified aspect of the nasal vault should be completed with plain X-ray of the nasal bones. Bear in mind the risk of secondary skull base fractures appearing during maneuvers for closing the nasal fracture. From the beginning of this chapter, we emphasized the importance of photos before and after the surgical procedure to prevent subsequent legal actions [28].



**Figure 4.**  
*Coronal approach for a complex nasal-orbital-ethmoid fracture.*





**Figure 5.**  
*Clinical aspect before surgery in a case with trauma on the right side with unfunctional eyeball—reconstruction of the orbit floor with a modified titanium mesh for sustaining the artificial eye prosthesis introduced subsequently.*

General anesthesia is compulsory to relax the muscles and gain comfort for both the patient and the surgical team. Performing any maneuver on a shocked patient is forbidden. In cases of multiple fractures, the surgery may be scheduled in 4–5 days to give time for all the edema to resolute. A nasal fracture forms a callus in 8–10 days, so closed reduction is viable because the bones are still mobile in the fracture site during this time frame [29].

Open reduction of the fractures is reserved only for specific cases such as open fractures with fragments penetrating the skin or in cases of animal attacks requiring rabies or antitetanic treatment. The surgical steps will focus on direct closure of the fracture site with or without metal plates, nasal packing, and the reconstruction of tissues and sutures. Preserving the fracture site is obtained by both internal nasal packing and external metal splint placing [30].

### 3.6 Nasal-orbital-ethmoid complex fractures

These are overly complex fractures in the midface compartment with possible serious consequences from an esthetic and functional point of view. These cases frequently present a CSF leak. Clinically a quite easy assessment of the suspicion of a CSF leak is performed by observing the appearance of a pink hallow around the nasal blood droplets collected on a clean tissue [31].

Moreover, the persistent nasal bleeding should raise the question of a nasal CSF leak. Panda eyes sign of orbital hematomas is frequently associated with nasal CSF leak. In these cases, it is compulsory to perform a nasal endoscopy in the first 24 hours from the trauma to exclude CSF leak (**Figure 6**) [32].

When suspecting a CSF leak, we must postpone surgical closure of the nasal vault fractures because the maneuvers can aggravate the lesions in the skull base. The CT scan confirms the fractures at the level of the nasal and ethmoid bones [33].

Consequently, imaging studies should gather data in all three axial planes with thin slices and 3D reconstructions (**Figure 7**). Particularly useful is close cooperation with the radiologist to perform serial images of the skull base and visualize the associated lesions of the lacrimal sack. In this type of fractures, open reduction after the resolution of edema under general anesthesia is recommended (**Figure 8**) [34].

### 3.7 Principles of osteosynthesis (internal fixation) in midface trauma

The general principles of osteosynthesis were formulated in 1958 by the Association for Osteosynthesis (AO) and are the guidelines for osteosynthesis. The principles of osteosynthesis in midface trauma respect general principles, and they are as follows:



- **Rigid fixation**—rigid fixation will produce a three-dimensional stability of the fracture site, promoting primary fracture healing. The healing is extremely susceptible to mechanical influences. Mobility at the fracture site is one of the main causes of healing disturbances, and stability is considered the best protection against fracture site contamination and malunion [35].
- **Preservation of blood supply**—it is achieved by gentle handling and reduction of bone and soft tissue and by careful cold irrigation during the drilling phase, which must be performed at low rotation less than 1500 rpm to prevent the overheating of the bone structures. Good-quality instruments and osteosynthesis materials are mandatory [36].
- **Anatomical reduction/repositioning**—one must achieve anatomical correct repositioning of all midfacial bones. The height, width, and projection must be reestablished. The fracture lines must be surgically exposed and reduced before osteosynthesis [37].
- **Early mobilization**—early mobilization of the operated area and the patient allows a functional aftercare [38].

### 3.8 Medical treatment in cranial-facial trauma

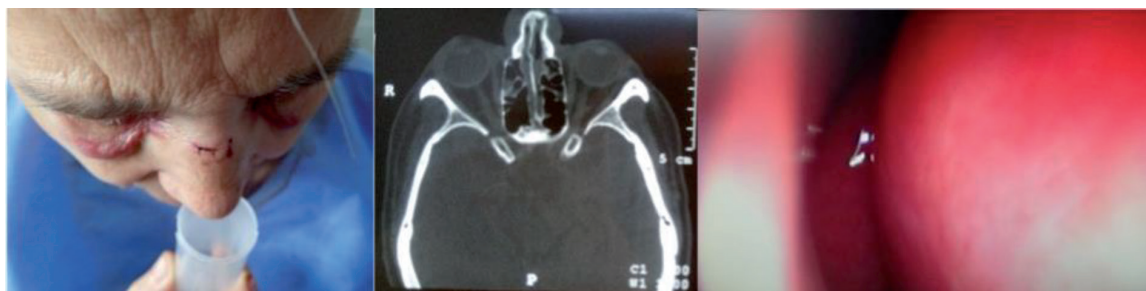
#### 3.8.1 Antibiotics

The treatment scheme should include third-generation cephalosporins, along with metronidazole due to oral bacteria contamination. This association of antibiotics has many advantages: it covers the spectrum of gram-positive bacteria encountered in ENT practice and also anaerobic bacteria and penetrates the blood–brain barrier [39].

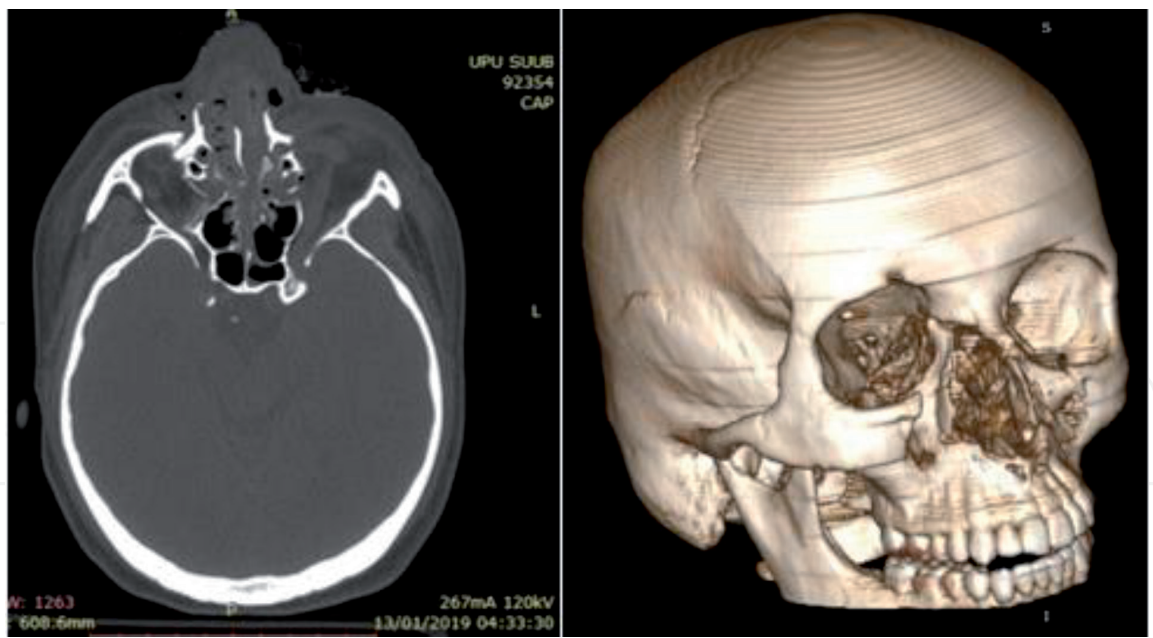
These should be administered for at least 48 hours during nasal packing but better for 5–7 days including surgery and up to 14 days in cases with nasal CSF leaks. Meropenem or carbapenems after discussing with the neurosurgeon in cases with brain lesions or following local treatment protocols are also associated [40].

#### 3.8.2 Corticoids

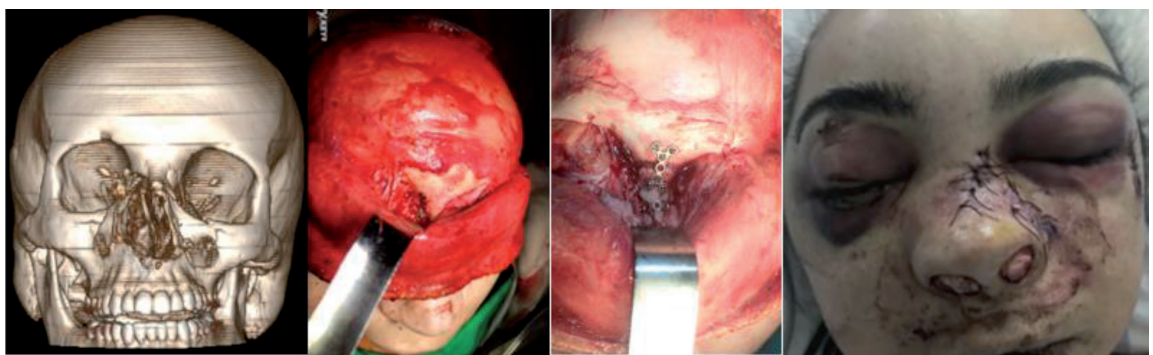
In this case, the neurosurgeon may prevent administering these compounds due to cerebral trauma. But for other lesions at the level of the viscerocranium, corticoids are beneficent reducing facial swelling and edema along the cranial nerve



**Figure 6.**  
*Combined fracture of nasal vault and septum with CSF leak on the left side—clinical aspect, CT scan revealing fracture lines through the nasal septum and left nasal bone, also the endoscopic aspect of the CSF leak in a case with accidental fall from the same level.*



**Figure 7.**  
*A complex fracture involving the nasal vault, orbit, and ethmoid in axial section and 3D reconstruction imaging.*



**Figure 8.**  
*A complex fracture involving the nasal vault, orbit, and ethmoid bone—CT scan with 3D reconstruction, surgical aspects of the coronal approach, and closing the fracture with titanium plates mounted in a Y pattern and final aspect at the end of the surgical procedure.*

endings and preventing major functional deficits completely assessed many days after the trauma [41].

Such situations are facial palsy with inner ear lesions or eyesight impairment due to indirect compression or elongation of the optic nerve. Sometimes efficient corticoid regimens can even reduce the need for surgical treatment [42].

*3.8.3 Analgesics*

Painkillers from various classes may be used ranging from paracetamol to non-steroids and opioids or morphine if the patient is transferred to ICU with the help and continuous adjustment of the anesthesia and pain specialist [43].

*3.8.4 Gastric secretion modulators*

These compounds are proton pump inhibitors used to diminish the impact of traumatic stress and because of lack of oral food intake in the first 24 hours, but also to control the interactions between corticoids and analgesic compounds [44].

Other treatments in managing midfacial trauma include the following:

- **Early removal of nasal packing in the first 24 hours** enables clearing the paranasal sinuses of blood clots [45].
- **Nasal sprays** enable correct daily cleaning of the nasal cavity and drainage of secretions [46].
- **Vitamins B** are useful for preserving neural functions affected by trauma [47].
- **Injectable vitamin C** in high quantity quickens the resolution of facial swelling [48].
- **Psychological support** is compulsory in head and neck trauma cases, and the attending surgeon and specialized clinical psychologist should be involved or even psychiatric support in self-inflicted lesions [49].

### **3.9 Indication of surgical treatment in craniofacial trauma**

Surgical treatment should focus on functional and esthetic deficits. Regarding early intervention in facial trauma, neurosurgeons consider the risks greater than the benefits. Therefore, surgery in these cases should be scheduled within 4–7 days to enable remission of edema and patient stabilization [50].

An exception from this rule is nasal bone fractures which require reduction within the first 24–48 hours from the accident to prevent secondary skull base fractures. We emphasized previously that this is possible under general anesthesia along with solving other fractures within 4–5 days from trauma [51].

Given the presence of CSF leak, the surgery must be postponed, and surgical reduction of fractures is possible within 10 days without a major change of the outcome [52].

## **4. Management of cranial-facial trauma in the context of COVID-19 pandemics**

Trauma is an emergency pathology requiring urgent admission with quick analysis and treatment even in the context of current SARS-COV2 pandemics. Therefore, each hospital must establish a clear circuit of the patient from presentation to emergency distribution, operating room, and designated ICU compartment [53].

Cases with multiple traumas must be considered a highly COVID-19 suspect case, and the medical personnel attending the patient should wear level 3 personal protective equipment (PPE). These cases require testing with both rapid serological tests for SARS-COV2 and nasopharynx swab for RT-PCR testing before any maneuver in the emergency department [54].

In cases requiring CPR, the protocol has changed requiring paramedics to wear at least level 2 PPE and to restrain from performing external cardiac compressions and mouth-to-mouth breathing. These maneuvers should be performed by designated personnel equipped according to the national guidelines. The ENT and OMF surgeon is solicited in emergency cases with nasal bleeding, cases with difficult intubation due to neck-associated trauma, or mandible complex fractures. Regardless of the type of emergency, the ENT or OMF surgeon must be equipped with high-level PPE due to the high risk of contamination with SARS-COV2 attending trauma patients [55].



After examining the fractures, the patient is often transferred directly into the operating room allotted to COVID-19 cases due to its still uncertain virologic status. A major problem is that the results from the RT-PCR test are available only after some hours in the best-case scenario if not even the next day in some medical facilities. The operating room assigned for COVID-19 suspects must be isolated from operating rooms used in other elective surgeries. Following the example of Singapore, this operating room should be remotely placed and equipped with negative air pressure if possible. Moreover, it should be equipped with designated mobile imaging equipment. The access circuit in this operating theater should be specially designed and prevent cross-contamination of patients and personnel. The surgery should be performed with level 3 PPE equipment for the entire staff.

From the operating room, the patient is taken to the ICU specially designed for the COVID-19 suspect cases until obtaining the results of the RT-PCR test.

If the result of the test is negative, the patient will be transferred to the ICU designated for non-COVID cases and undergo the management of a usual multiple trauma victim. Craniofacial fractures need reassessment after 48 hours according to the previously stated guidelines. If the result of the RT-PCR is positive, the case needs to be stabilized and transferred to a designated COVID-19 support hospital. In this case, an examination of an infectious disease specialist is also necessary.

The current COVID-19 pandemics changes the type of emergency healthcare provided considering any trauma case as positive from the very beginning and requiring all personnel to wear level 3 PPE along with allotting separate diagnosis and treatment circuits with a reduced number of doctors but highly trained and referral as quickly as possible toward the COVID-19 designated healthcare facility for further management.

## 5. Conclusions

In complex cases with severe deformity, avoid a conservative approach via small multiple regional “conservative” incisions. For a successful outcome, it is best to achieve a complete regional exposure through a coronal or hemicoronal flap combined with lower eyelid or intraoral incision if necessary. Do not delay the surgical intervention for more than 14 days. Except in a few numbers of severe polytrauma cases, the general condition of the patient should be stabilized in this time frame, and definitive treatment should be undertaken. After 14 days the case has to follow the protocol of secondary reconstruction, because of the consolidation of the fractures and the treatment is incomparably more difficult. Do not evaluate the CT scan only in the axial view. For a complete assessment, it is mandatory to examine the CT scan in coronal, frontal, and 3D reconstruction views. If the clinical signs are not convergent with the CT scan interpretation, or if the fractures visible on the CT scan are associated with very little or no functional deficit, the “wait-and-see” or “conservative” approach should be taken into consideration, with the focus on glucocorticoid treatment. Surgical techniques should be tailored taking into consideration the functional and esthetic deficits and using a complex team of trained specialists. The principles of osteosynthesis in midface trauma respect the general principles of osteosynthesis. The prognosis depends on the associated pathology, age, social status, and correct assessment of viscerocranium lesions able to provide surgical and postop care. The current COVID-19 pandemic modifies the level of emergency care toward conservative attitude for trauma cases. Consider every trauma case as a possible COVID-19 suspect, and train the staff to equip quickly level 3 PPE. Keys to success are



designing special access circuits for trauma cases reducing the time spent in the ER and subsequent referral of the case to specialized medical facilities treating COVID-19 cases.

IntechOpen

### Author details

Daniela Vrinceanu<sup>1</sup>, Bogdan Banica<sup>2</sup> and Mihai Dumitru<sup>1,3\*</sup>

1 ENT Department, Bucharest Emergency University Hospital, Bucharest, Romania

2 OMF Surgery Department, Bucharest Emergency University Hospital, Bucharest, Romania

3 Anatomy Department, Carol Davila University of Medicine and Pharmacy, Bucharest, Romania

\*Address all correspondence to: orldumitrumihai@yahoo.com

### IntechOpen

© 2020 The Author(s). Licensee IntechOpen. This chapter is distributed under the terms of the Creative Commons Attribution License (<http://creativecommons.org/licenses/by/3.0>), which permits unrestricted use, distribution, and reproduction in any medium, provided the original work is properly cited. 

## References

- [1] Scheyerer MJ, Döring R, Fuchs N, Metzler P, Sprengel K, Werner CML, et al. Maxillofacial injuries in severely injured patients. *Journal of Trauma Management & Outcomes*. 2015;9:4. DOI: 10.1186/s13032-015-0025-2
- [2] Gadre KS, Halli R, Joshi S, Ramanojam S, Gadre PK, Kunchur R, et al. Incidence and pattern of cranio-maxillofacial injuries: A 22 year retrospective analysis of cases operated at major trauma hospitals/centres in Pune, India. *Journal of Maxillofacial and Oral Surgery*. 2013;12(4):372-378. DOI: 10.1007/s12663-012-0446-7
- [3] Vrinceanu D, Banica B. Principles of surgical treatment in the midface trauma—Theory and practice. *Maedica – a Journal of Clinical Medicine*. 2014;9(4):361-366
- [4] Sina C, Castoldi L, D’Orto O, Castaldi S. The value of protocols: The experience about a facial trauma protocol applied in the emergency room in a research and teaching hospital in the north part of Italy. *Journal of Public Health Research*. 2012;1(3):240-242. DOI: 10.4081/jphr.2012.e38
- [5] Kraft A, Abermann E, Stigler R, Zsifkovits C, Pedross F, Kloss F, et al. Craniomaxillofacial trauma: Synopsis of 14,654 cases with 35,129 injuries in 15 years. *Craniomaxillofacial Trauma & Reconstruction*. 2012;5(1):41-50. DOI: 10.1055/s-0031-1293520
- [6] Bajwa SJ, Kaur J, Singh A, Kapoor V, Bindra GS, Ghai GS. Clinical and critical care concerns of cranio-facial trauma: A retrospective study in a tertiary care institute. *National Journal of Maxillofacial Surgery*. 2012;3(2):133-138. DOI: 10.4103/0975-5950.111343
- [7] Koryczan P, Zapła J, Wyszynska-Pawelec G. Reduction in visual acuity and intraocular injuries in orbital floor fracture. *Folia Medica Cracoviensia*. 2015;55(3):49-56
- [8] Mishra RK, Munivenkatappa A, Prathyusha V, Shukla DP, Devi BI. Clinical predictors of abnormal head computed tomography scan in patients who are conscious after head injury. *Journal of Neuroscience in Rural Practice*. 2017;8(1):64-67. DOI: 10.4103/0976-3147.193538
- [9] Roman R, Hedeşiu M, Fildan F, Ileşan R, Mitea D, Dinu C, et al. The use of reformatted cone beam CT images in assessing mid-face trauma, with a focus on the orbital floor fractures. *Clujul Medical*. 2016;89(4):519-524
- [10] Anghel I, Anghel AG, Soreanu CC, Dumitru M. Craniofacial trauma produced by a violent mechanism. Coltea ENT Clinic experience. *Romanian Journal of Legal Medicine*. 2012;20:215-218. DOI: 10.4323/rjlm.2012.215
- [11] Roumeliotis G, Ahluwalia R, Jenkyn T, Yazdani A. The Le Fort system revisited: Trauma velocity predicts the path of Le Fort I fractures through the lateral buttress. *Plastic Surgery (Oakv)*. 2015;23(1):40-42
- [12] Chandra L, Deepa D, Atri M, Pandey SM, Passi D, Goyal J, et al. A retrospective cross-sectional study of maxillofacial trauma in Delhi-NCR region. *Journal of Family Medicine and Primary Care*. 2019;8(4):1453-1459. DOI: 10.4103/jfmpc.jfmpc\_89\_19
- [13] Chin YP, Leno MB, Dumrongwongsiri S, Chung KH, Lin HH, Lo LJ. The pterygomaxillary junction: An imaging study for surgical information of LeFort I osteotomy. *Scientific Reports*. 2017;7(1):9953. DOI: 10.1038/s41598-017-10592-8

- [14] Louis M, Agrawal N, Truong TA. Midface fractures II. Seminars in Plastic Surgery. 2017;**31**(2):94-99. DOI: 10.1055/s-0037-1601373
- [15] Rajkumar GC, Ashwin DP, Singh R, Prashanth R, Rudresh KB. Ocular injuries associated with midface fractures: A 5 year survey. Journal of Maxillofacial and Oral Surgery. 2015;**14**(4):925-929. DOI: 10.1007/s12663-015-0778-1
- [16] Menon S, Sham ME, Kumar V, Archana S, Nath P, Shivakotee S, et al. Maxillofacial fracture patterns in road traffic accidents. Annals of Maxillofacial Surgery. 2019;**9**(2):345-348. DOI: 10.4103/ams.ams\_136\_19
- [17] Septa D, Newaskar VP, Agrawal D, Tibra S. Etiology, incidence and patterns of mid-face fractures and associated ocular injuries. Journal of Maxillofacial and Oral Surgery. 2014;**13**(2):115-119. DOI: 10.1007/s12663-012-0452-9
- [18] Abiodun A, Atinuke A, Yvonne O. Computerized tomography assessment of cranial and mid-facial fractures in patients following road traffic accident in south-west Nigeria. Annals of African Medicine. 2012;**11**(3):131-138. DOI: 10.4103/1596-3519.96860
- [19] Pappachan B, Alexander M. Biomechanics of cranio-maxillofacial trauma. Journal of Maxillofacial and Oral Surgery. 2012;**11**(2):224-230. DOI: 10.1007/s12663-011-0289-7
- [20] Businger AP, Krebs J, Schaller B, Zimmermann H, Exadaktylos AK. Cranio-maxillofacial injuries in victims of interpersonal violence. Swiss Medical Weekly. 2012;**142**:w13687. DOI: 10.4414/smw.2012.13687
- [21] Waterkamp V, Ricklin M, Schaller B, Katsoulis K, Exadaktylos A. Severity and pattern of injuries caused by the traditional Swiss team sport 'Hornussen': First retrospective study at a level I trauma centre in Switzerland. BMJ Open Sport & Exercise Medicine. 2016;**2**(1):e000122
- [22] Ghabach MB, Abou Rouphael MA, Roumoulian CE, Helou MR. Airway management in a patient with Le Fort III fracture. Saudi Journal of Anaesthesia. 2014;**8**(1):128-130. DOI: 10.4103/1658-354X.125974
- [23] Olayemi AB, Adeniyi AO, Samuel U, Emeka OA. Pattern, severity, and management of cranio-maxillofacial soft-tissue injuries in Port Harcourt, Nigeria. Journal of Emergencies, Trauma, and Shock. 2013;**6**(4):235-240. DOI: 10.4103/0974-2700.120362
- [24] Vrinceanu D, Banica B, Dumitru M, Musat G. Advantages of the open approach in sinonasal tract tumors with midfacial and suprastructure invasion. R.j. of Rhinology. 2020;**10**(37):30-34. DOI: 10.2478/rjr-2020-0007
- [25] Giran G, Paré A, Croisé B, Koudougou C, Mercier JM, Laure B, et al. Radiographic evaluation of percutaneous transfacial wiring versus open internal fixation for surgical treatment of unstable zygomatic bone fractures. PLoS One. 2019;**14**(8):e0220913. DOI: 10.1371/journal.pone.0220913
- [26] Hartwig S, Nissen MC, Voss JO, Doll C, Adolphs N, Heiland M, et al. Clinical outcome after orbital floor fracture reduction with special regard to patient's satisfaction. Chinese Journal of Traumatology. 2019;**22**(3):155-160. DOI: 10.1016/j.cjtee.2019.01.002
- [27] Nekooei S, Sardabi M, Razavi ME, Nekooei A, Kiarudi MY. Implantation of customized, preshaped implant for orbital fractures with the aid of three-dimensional printing. Middle East African Journal of Ophthalmology.

2018;**25**(1):56-58. DOI: 10.4103/meajo.MEAJO\_262\_16

[28] Han DG. Considerations for nasal bone fractures: Preoperative, perioperative, and postoperative. *Archives of Craniofacial Surgery*. 2020;**21**(1):3-6. DOI: 10.7181/acfs.2020.00031

[29] Kang BH, Kang HS, Han JJ, Jung S, Park HJ, Oh HK, et al. A retrospective clinical investigation for the effectiveness of closed reduction on nasal bone fracture. *Maxillofacial Plastic and Reconstructive Surgery*. 2019;**41**(1):53. DOI: 10.1186/s40902-019-0236-y

[30] Onişor-Gligor F, Ţeţ PA, Bran S, Juncar M. A naso-orbito-ethmoid (NOE) fracture associated with bilateral anterior and posterior frontal sinus wall fractures caused by a horse kick-case report and short literature review. *Medicina (Kaunas, Lithuania)*. 2019;**55**(11). pii: E731. DOI: 10.3390/medicina55110731

[31] Park CH, Chung KJ, Kim TG, Lee JH, Kim IK, Kim YH. Big data statistical analysis of facial fractures in Korea. *Journal of Korean Medical Science*. 2020;**35**(7):e57. DOI: 10.3346/jkms.2020.35.e57

[32] Teng TS, Ishak NL, Subha ST, Bakar SA. Traumatic transnasal penetrating injury with cerebral spinal fluid leak. *EXCLI Journal*. 2019;**18**:223-228. DOI: 10.17179/excli2018-1971

[33] Mourad M, Inman JC, Chan DM, Ducic Y. Contemporary trends in the management of posttraumatic cerebrospinal fluid leaks. *Craniofacial Trauma & Reconstruction*. 2018;**11**(1):71-77. DOI: 10.1055/s-0036-1584890

[34] Hasheminia D, Kalantar Motamedi MR, Hashemzahi H,

Nazeri R, Movahedian B. A 7-year study of 1,278 patients with maxillofacial trauma and cerebrospinal fluid leak. *Journal of Maxillofacial and Oral Surgery*. 2015;**14**(2):258-262. DOI: 10.1007/s12663-014-0630-z

[35] Lee EI, Mohan K, Koshy JC, Hollier LH Jr. Optimizing the surgical management of zygomaticomaxillary complex fractures. *Seminars in Plastic Surgery*. 2010;**24**(4):389-397. DOI: 10.1055/s-0030-1269768

[36] Borrelli MR, Hu MS, Longaker MT, Lorenz HP. Tissue engineering and regenerative medicine in craniofacial reconstruction and facial aesthetics. *The Journal of Craniofacial Surgery*. 2020;**31**(1):15-27. DOI: 10.1097/SCS.00000000000005840

[37] Olsson P, Nysjö F, Hirsch JM, Carlbom IB. A haptics-assisted cranio-maxillofacial surgery planning system for restoring skeletal anatomy in complex trauma cases. *International Journal of Computer Assisted Radiology and Surgery*. 2013;**8**(6):887-894. DOI: 10.1007/s11548-013-0827-5

[38] Sharma S, Nanda A, Koli D, Daksh S, Verma M. Role of a dentist in comprehensive management of a comatose patient with post traumatic head injury and neuropathological chewing. *Indian Journal of Palliative Care*. 2014;**20**(2):146-152. DOI: 10.4103/0973-1075.132639

[39] Mottini M, Wolf R, Soong PL, Lieger O, Nakahara K, Schaller B. The role of postoperative antibiotics in facial fractures: Comparing the efficacy of a 1-day versus a prolonged regimen. *Journal of Trauma and Acute Care Surgery*. 2014;**76**(3):720-724. DOI: 10.1097/TA.0000000000000123

[40] Campos GB, Lucena EE, da Silva JS, Gomes PP, Germano AR. Efficacy assessment of two antibiotic prophylaxis regimens in oral and maxillofacial



trauma surgery: Preliminary results. *International Journal of Clinical and Experimental Medicine*. 2015;**8**(2):2846-2852

[41] Ikeda K, Sakurada T, Takasaka T, Okitsu T, Yoshida S. Anosmia following head trauma: Preliminary study of steroid treatment. *The Tohoku Journal of Experimental Medicine*. 1995;**177**(4):343-351

[42] Vrinceanu D, Dumitru M, Banica B, Nica A. Foreign body in maxillary sinus with skin fistula. *Journal of Surgical Sciences*. 2019;**6**(3):82-84. DOI: 10.33695/jss.v6i3.278

[43] Alwani M, Jones AJ, Sandelski M, Bandali E, Lancaster B, Sim MW, et al. Facing facts: Facial injuries from stand-up electric scooters. *Cureus*. 2020;**12**(1):e6663. DOI: 10.7759/cureus.6663

[44] Breeze J, Bowley DM, Combes JG, Baden J, Rickard RF, DuBose J, et al. Facial injury management undertaken at US and UK medical treatment facilities during the Iraq and Afghanistan conflicts: A retrospective cohort study. *BMJ Open*. 2019;**9**(11):e033557. DOI: 10.1136/bmjopen-2019-033557

[45] Choi DS, Lee JW, Yang JD, Chung HY, Cho BC, Choi KY. Minimal packing duration in close reduction for nasal bone fracture treatment. *Journal of Plastic Surgery and Hand Surgery*. 2015;**49**(5):275-279. DOI: 10.3109/2000656X.2015.1034726

[46] Koh JH, Bhatti O, Mahmood A, Agar N. Traumatic nasal injuries in general practice. *Australian Family Physician*. 2016;**45**(9):650-653

[47] Ehmedah A, Nedeljkovic P, Dacic S, Repac J, Draskovic Pavlovic B, Vucevic D, et al. Vitamin B complex treatment attenuates local inflammation

after peripheral nerve injury. *Molecules*. 2019;**24**(24). pii: E4615. DOI: 10.3390/molecules24244615

[48] Pullar JM, Carr AC, Vissers MCM. The roles of vitamin C in skin health. *Nutrients*. 2017;**9**(8). pii: E866. DOI: 10.3390/nu9080866

[49] Wilson N, Heke S, Holmes S, Dain V, Priebe S, Bridle C, et al. Prevalence and predictive factors of psychological morbidity following facial injury: A prospective study of patients attending a maxillofacial outpatient clinic within a major UK city. *Dialogues in Clinical Neuroscience*. 2018;**20**(4):327-339

[50] Zeiderman MR, Pu LLQ. Contemporary reconstruction after complex facial trauma. *Burns Trauma*. 2020;**8**:tkaa003. DOI: 10.1093/burnst/tkaa003

[51] Gómez Roselló E, Quiles Granado AM, Artajona Garcia M, Juanpere Martí S, Laguillo Sala G, Beltrán Mármol B, et al. Facial fractures: Classification and highlights for a useful report. *Insights Into Imaging*. 2020;**11**(1):49. DOI: 10.1186/s13244-020-00847-w

[52] Liu FC, Halsey JN, Oleck NC, Lee ES, Granick MS. Facial fractures as a result of falls in the elderly: Concomitant injuries and management strategies. *Craniofacial Trauma & Reconstruction*. 2019;**12**(1):45-53. DOI: 10.1055/s-0038-1642034

[53] Coccolini F, Perrone G, Chiarugi M, Di Marzo F, Ansaloni L, Scandroglio I, et al. Surgery in COVID-19 patients: Operational directives. *World Journal of Emergency Surgery*. 2020;**15**(1):25. DOI: 10.1186/s13017-020-00307-2

[54] Livingston DH, Bonne S, Morello C, Fox A. Optimizing the trauma resuscitation bay during the covid-19 pandemic. *Trauma Surgery &*

Acute Care Open. 2020;5(1):e000488.  
DOI: 10.1136/tsaco-2020-000488

[55] Gok AFK, Eryılmaz M, Ozmen MM, Alimoglu O, Ertekin C, Kurtoglu MH. Recommendations for trauma and emergency general surgery practice during COVID-19 pandemic. Ulusal Travma ve Acil Cerrahi Dergisi. 2020;26(3):335-342. DOI: 10.14744/tjtes.2020.79954