

# We are IntechOpen, the world's leading publisher of Open Access books Built by scientists, for scientists

6,900

Open access books available

186,000

International authors and editors

200M

Downloads

Our authors are among the

154

Countries delivered to

TOP 1%

most cited scientists

12.2%

Contributors from top 500 universities



WEB OF SCIENCE™

Selection of our books indexed in the Book Citation Index  
in Web of Science™ Core Collection (BKCI)

Interested in publishing with us?  
Contact [book.department@intechopen.com](mailto:book.department@intechopen.com)

Numbers displayed above are based on latest data collected.  
For more information visit [www.intechopen.com](http://www.intechopen.com)



# Surgical Anatomy of Acetabulum and Biomechanics

*Sachin Kumar Sharma and Hemant Mathur*

## Abstract

Both column acetabular fractures are challenging articular injuries. Majority of them are treated operatively. The concept of “secondary congruence” was introduced by Letournel. Despite this, biomechanical data on secondary congruence indicate that nonoperative treatment leads to an increase in peak pressures in the supra-acetabular region with the potential risk of developing posttraumatic degenerative osteoarthritis. Operative management is therefore justified. A cohort of 10 patients having both column (anterior and posterior) acetabular fractures managed using bicolumnar plating between Jan 2016 and Dec 2017 were enrolled in the study and were analyzed during follow-up period. Eighty percent of the patients had excellent to good result. Average postoperative score was 85.7. Assessment was done using Modified Harris Hip score.

**Keywords:** anterior and posterior column fracture, modified Harris Hip score, corona mortis, secondary congruence

## 1. Introduction

Hip arthroscopy requires a thorough knowledge of acetabular and pelvic anatomy. Acetabular and pelvic anatomy is complex yet important for any procedure to be done on hip joint. The articular surface of acetabulum can be visualized as being supported between the limbs of an inverted “Y”. These two limbs are considered anterior and posterior columns of acetabulum. On radiographic view, anterior column is represented by iliopectineal line and posterior column by ilioischial line. Discontinuity in any of these lines is considered fracture of anterior or posterior column. The external iliac and internal iliac arteries lie in close relation to these columns. An anomalous connection of these two arteries called circle of death or corona mortis should be identified and ligated properly as injury to this artery can lead to catastrophic results. Lumbar plexus and its various nerve roots traverses the lesser and greater sciatic notches and are vulnerable to injury in portal placement and various other hip surgeries. This chapter mainly focuses on various aspects of surgical anatomy of acetabulum and biomechanics relevant to hip arthroscopy in detail.

## 2. Surgical and applied anatomy of the acetabulum

Treatment of acetabular fractures requires a deep understanding of pelvic anatomy. With advent of various minimally invasive approaches and fixation methods, knowledge of acetabular anatomy plays a pivotal role in treatment of displaced acetabular

fractures. This chapter focuses on various aspects of acetabular anatomy, which are very vital in acetabular fracture fixation and also in other pelvic surgeries [1–5].

## 2.1 Osseous anatomy

The pelvis is the bony structure that transmits the weight of the upper axial skeleton to both the lower extremities via hip joint [1–5]. It comprises of the sacrum and three bones on each side that coalesce during adolescence to form the innominate bone of the adult pelvis. The iliosacral joint connects the sacrum to ilium. The ilium becomes the pubis anteriorly and the ischium inferiorly. Two pubic bones are connected to one another via the symphysis.

### 2.1.1 Acetabulum

The three bones, the ilium, ischium and pubis, join each other centrally to form the acetabular cavity. The blood supply to the femoral head traverses through the cotyloid fossa and ligamentum teres in childhood. The horse shoe-shaped cartilaginous portion of acetabulum is the main region through which the weight is transmitted from lower limb to innominate bone [4–6].

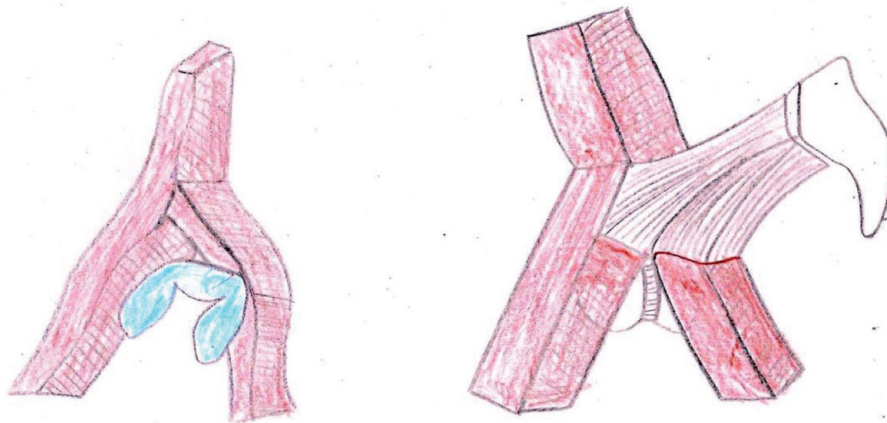
#### 2.1.1.1 Column concept of the acetabulum

The acetabulum is an incomplete hemispherical socket with an inverted horse shoe-shaped articular surface surrounding the nonarticular cotyloid fossa. Two columns of bone which form an inverted ‘Y’, form and support the cotyloid fossa anteriorly and posteriorly [6–8] (**Figure 1**).

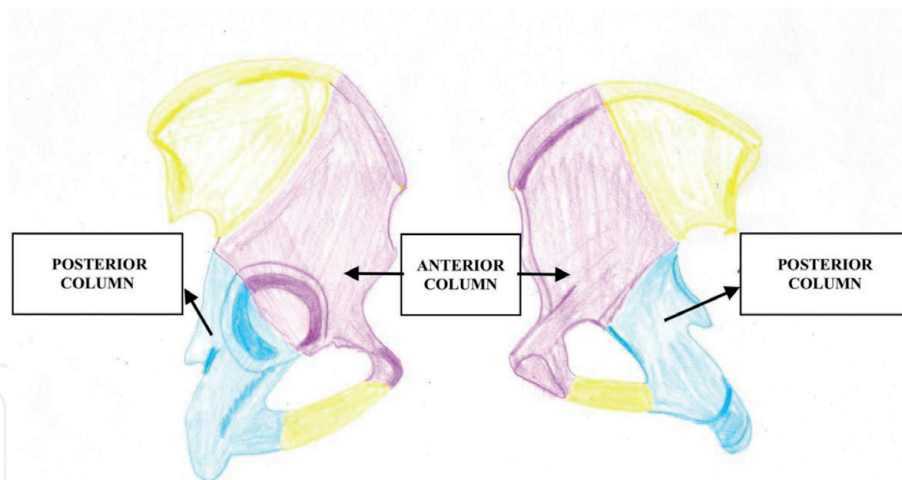
The anterior half of the iliac crest, the iliac spines, the anterior half of the acetabulum and the pubis form the anterior column.

The ischium, the ischial spine, the posterior half of the acetabulum and the dense bone forming the sciatic notch form the posterior column.

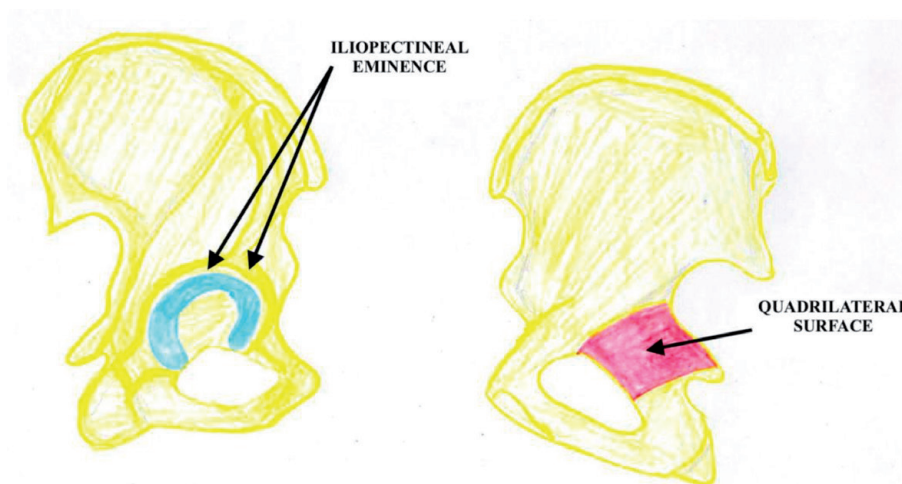
The shorter posterior column meets with the anterior column at the top of the sciatic notch. The column concept is very vital not only for classification of acetabular fractures but also in deciding the operative approach and hence the management. The weight-bearing portion of the articular surface is known as the dome or roof that supports the femoral head. The goal of both operative and nonoperative treatment is the anatomic restoration of roof or dome with concentric reduction of femoral head [8–10] (**Figure 2**).



**Figure 1.**  
*Column concept of the acetabulum by Letournel and Judet.*



**Figure 2.**  
*Anterior column and posterior column.*



**Figure 3.**  
*Quadrilateral surface and iliopectineal eminence.*

The flat plate of bone forming the lateral border of true pelvic cavity is known as quadrilateral surface. It lies adjacent to the medial wall of the acetabulum. The iliopectineal eminence is the prominence in the anterior column that lies directly over the femoral head. Both these structures limit the fixation of anterior column fractures of acetabulum [10] (**Figure 3**).

### *2.1.2 Iliac wing and innominate bone*

The external iliac fossa is marked with two semi-circular lines dividing it into three zones [1–5]:

- Posterior (gluteus maximus)
- Middle (gluteus medius)
- Anterior (gluteus minimus)

Looking from above iliac wing appears S shaped. It begins anteriorly with a slight medial oblique orientation. Posteriorly it forms posterior iliac spine which is sagittally oriented. The iliac wing contains hematopoietic and osteogenic

marrow elements and is the primary source of autogenous bone graft. Various structures are attached on different sides of iliac crest. The lower extremity hip motors are attached on the outer side. Along the inner portions, the iliacus and obturator internus and the pelvic floor musculatures are attached. The abdominal (anteriorly) and paraspinal (posteriorly) muscles are attached on the top [11, 12].

There is a strong buttress of bone extending from the iliosacral joint toward the acetabulum known as the sciatic buttress. The lumbosacral plexus as well as the gluteal vasculature lies in the vicinity. These vessels are the main source of bleeding and they can also be injured during surgical approach. The posterior superior iliac spine is adjacent to the sacroiliac joint and outer ilium.

The neurovascular structures exit the pelvis along with the piriformis muscle through sciatic notch. Sacrospinous ligament, the gemellus superior and the levator ani are inserted on the ischial spine. On the inferior side of ischial spine is the lesser sciatic notch, which contains the obturator internus tendon. The pudendal vessels and nerves pass through this area first exiting the pelvis via greater sciatic notch and then re-entering the pelvis via lesser sciatic notch.

The anterior-most border of the iliac bone begins with the anterosuperior iliac spine (ASIS), which gives origin to:

- Fascia Lata
- Sartorius
- Inguinal ligament

The antero-inferior iliac spine (AIIS) lies just below the ASIS where the *direct head of the rectus femoris* is inserted. The *iliopsoas muscle* passes just medial to AIIS under which lies the iliopectineal eminence. Indirect head of the rectus femoris is attached inferior to AIIS.

The boundaries of obturator foramen is formed by the pubis superiorly, the ischium inferiorly, and the anterior horn of the acetabulum posteriorly. Medially, the ischial and pubic rami join to form the symphyseal pubic junction. At its superolateral border, the obturator duct is present, which is occupied by obturator vessels and nerve. Obturator membrane covers the foramen circumferentially, which is a thick fascial structure. The integrity of the inguinal ligament and obturator membrane prevents the separation of rami fractures during reduction and fixation of symphyseal plate.

## 2.2 Ligament anatomy: the joints

The iliosacral joint is a fibrocartilaginous joint that acts as a dual wedge in axial and antero-posterior directions [12–15]. It acts as a keystone during the transmission of force to the lower limbs. The joint is supported anteriorly and posteriorly by strong ligaments. The posterior sacroiliac ligament consists of

- The superficial part going from the posterior iliac crest and posterior iliac spines to the posterior tubercles of the sacrum made up of several fascicles.
- The deep portion or interosseous ligament, which is the strongest ligament in the human body.

The sacrotuberous ligament connects sacrum to the ischial tuberosity (Figure 4).

The sacrospinous ligament connects the border of sacrum and coccyx and sciatic spine deep to sacrotuberous ligament. This ligament divides the ischial area into two foramens:

- i. The Greater Sciatic Foramen: contains the piriformis muscle, superior glutei nerves, sciatic nerve, ischial vessels, and internal pudendal vessels and nerve.
- ii. The Lesser Sciatic Foramen: contains the obturator internus muscle and internal pudendal vessels. These structures exit the pelvis via greater sciatic foramen and after crossing over the sacrospinous ligament re-enters the pelvis via lesser sciatic foramen [13–15].

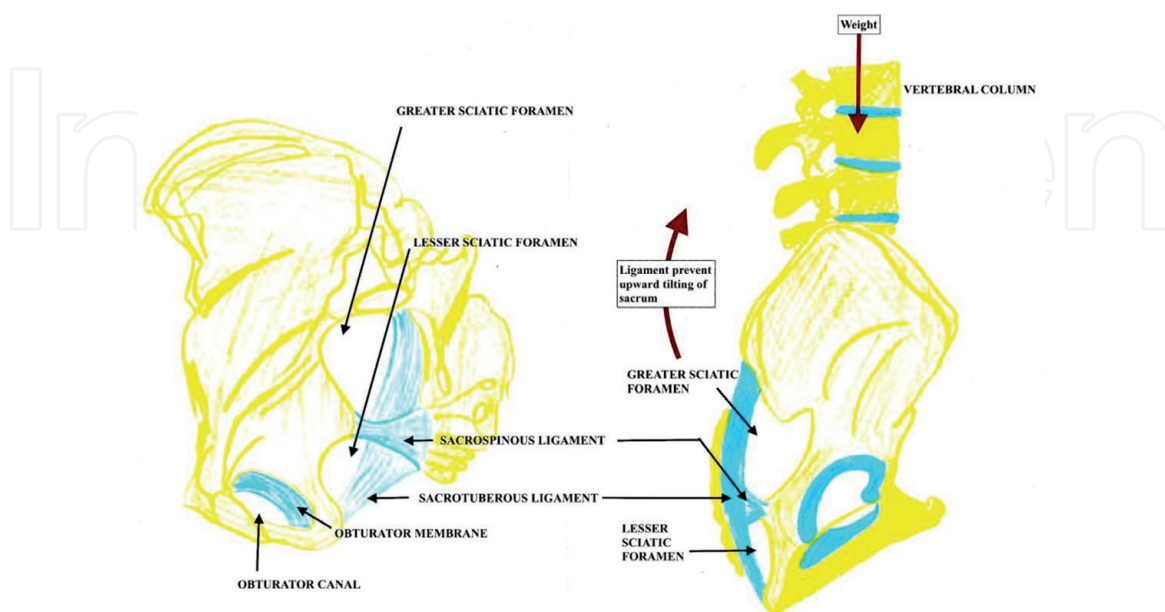
## 2.3 Vascular anatomy

The aorta bifurcates in the lower peritoneal region into the common iliac arteries. The common iliac artery begins at around L4 and divides at around the L5–S1 junction into the external and internal iliac arteries.

The *internal iliac artery* also known as hypogastric artery, branches to form the superior and inferior gluteal vessels, the obturator, the pudendal, and the coccygeal, the sacral and vesicular vessels. The internal pudendal artery exits the pelvis underneath the piriformis and re-enters the pelvis through the lesser sciatic notch and terminates as the dorsal artery of the penis and clitoris and cavernous artery [16, 17].

The *external iliac artery* just proximal to the inguinal ligament branches to form the femoral artery.

The femoral artery has three rami: urethral inferior, epigastric and iliac circumflex. The epigastric travels deep and then anastomoses with obturator vessels. The corona



**Figure 4.**  
 The sacrotuberous and sacrospinous ligaments.

mortis is the anomalous connection between epigastric and obturator vessels. It can cause fatal bleeding if not identified and ligated during surgery [17, 18] (**Figure 5**).

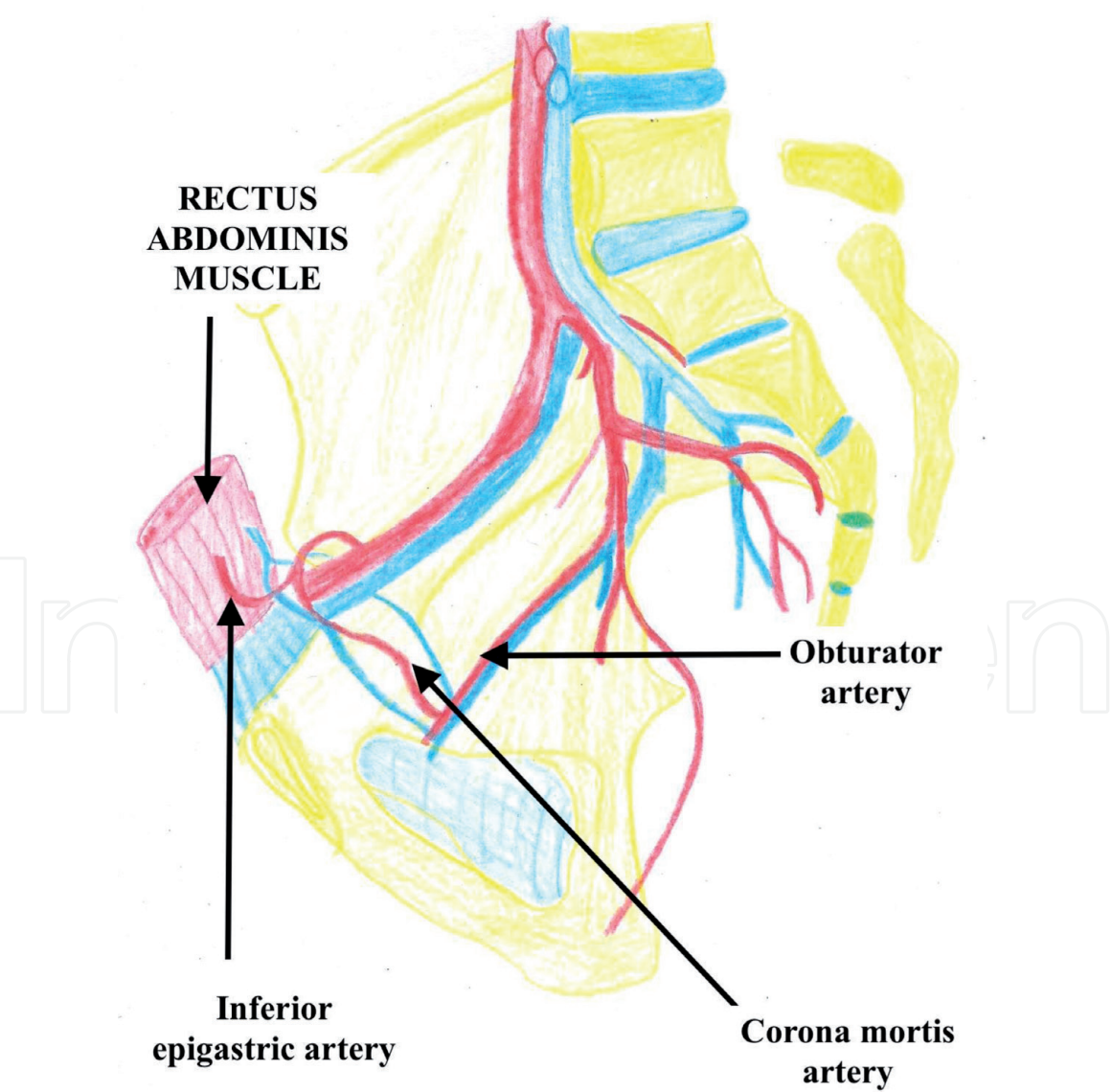
2.4 Neurologic anatomy

There are two important plexus: lumbar plexus and sacral plexus.

*The Lumbar plexus* consists of the first three lumbar anterior rami and a portion of the anterior ramus of the fourth lumbar nerve. There are also short collateral rami, which include the hypogastric, ilioinguinal, genitofemoral, and lateral femoral cutaneous nerve. Femoral and obturator nerves are the terminal rami of lumbar plexus.

*The obturator nerve* receives contributions from the L2, L3, and L4 trunks. It continues into the pelvis underneath the iliopectineal line, reaches the obturator orifice. It exits the pelvis together with the obturator vessels.

*The femoral nerve* receives contributions from the L2, L3, and L4 trunks [19–21].

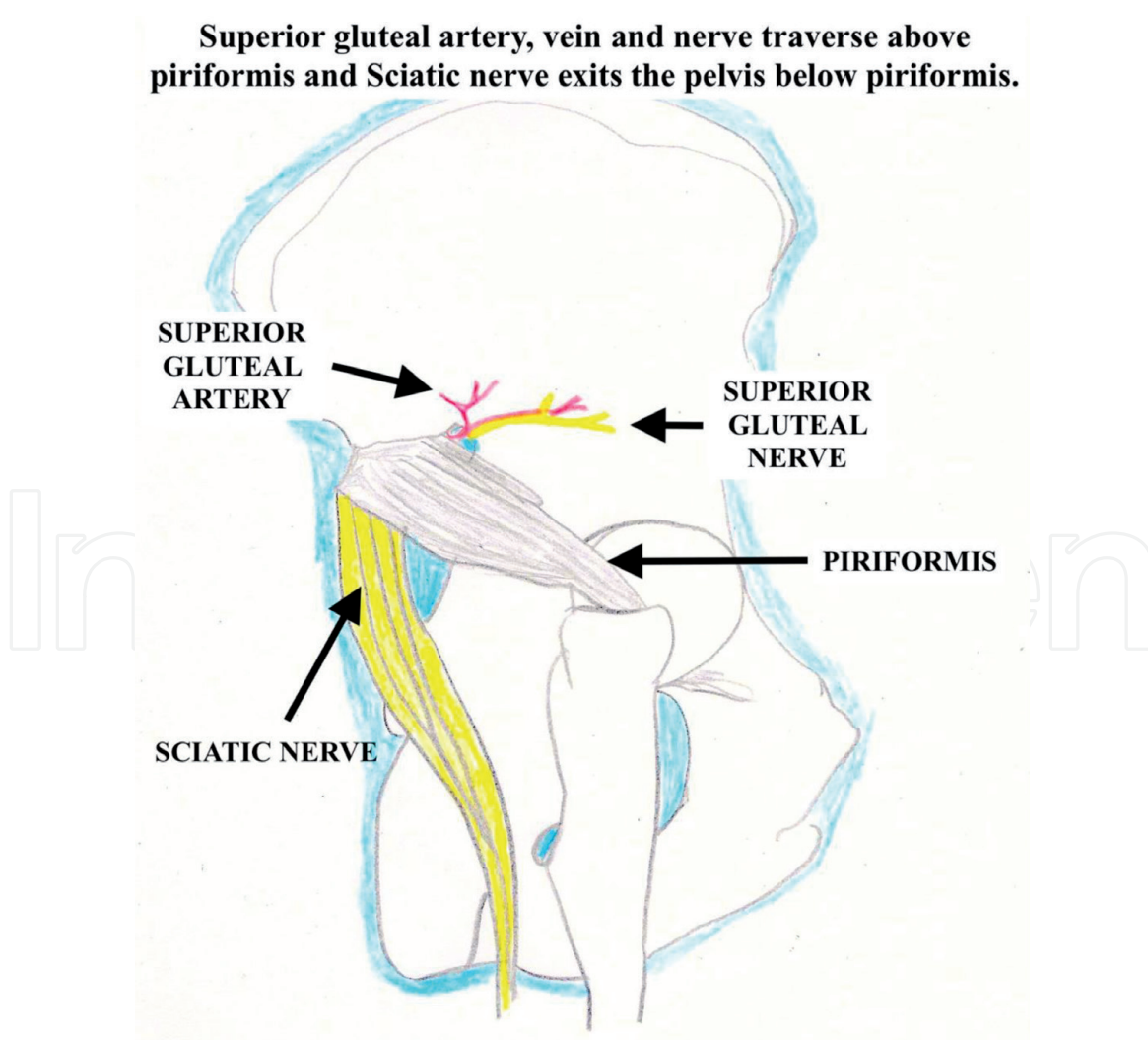


**Figure 5.**  
*Corona mortis artery.*

The *Sacral Plexus* is formed by the coalescence of the lumbosacral trunk (L5 anterior ramus with L4 anastomotic ramus) and the anterior rami of the first four sacral roots. The plexus ultimately becomes the sciatic nerve (posterior tibial and peroneal nerve). The posterior branches relevant to orthopedic surgery are the superior gluteal nerve, branches to the external rotators and inferior gluteal nerve. The sciatic nerve exits the greater sciatic notch. In 85% of the cases, it courses in front of the piriformis. The other variants include penetration and splitting around the muscle. After exiting through greater sciatic notch, it courses behind the obturator internus, under the gluteal sling to enter the thigh. The sciatic nerve is a vital structure that is encountered during posterior approaches to the acetabulum. Due to proximity of sciatic nerve and its branches to the posterior part of acetabulum, fractures and dislocations in this area have very high incidence of sciatic nerve injury. Most common to be involved is the peroneal division of sciatic nerve [21, 22] (**Figure 6**).

### 3. Radiographic evaluation

The classification and subsequent treatment of acetabular fractures are based on imaging studies that have been derived from a thorough understanding of the



**Figure 6.**  
*The greater sciatic notch is divided by the piriformis.*

anatomy of the innominate bone [17–19]. Two limbs of an inverted “Y” of bone support the articular surface of acetabulum. These columns are connected to the sacroiliac articulation by a thick strut of bone lying above the greater sciatic notch known as the sciatic buttress.

The radiographic anatomy of the acetabulum can be determined using AP pelvis and two 45-degree oblique radiographs as proposed by Judet and Letournel. Therefore, three radiographic projections of the pelvis that are used to evaluate the fractures of acetabulum are as follows:

- The antero-posterior view of the pelvis
- The obturator (or 45-degree internal, Judet) oblique view
- The iliac (or 45-degree external, Judet) oblique view

These plain films are interpreted based on the understanding of normal radiographic landmarks of the acetabulum, and disruption of these landmarks represents a fracture involving that portion of the bone. These landmarks are referred to as “lines”. They are generated by the tangency of the applied x-ray beam to a region of cortical bone.

### 3.1 Antero-posterior radiograph

There are six basic landmarks (**Figure 7**)

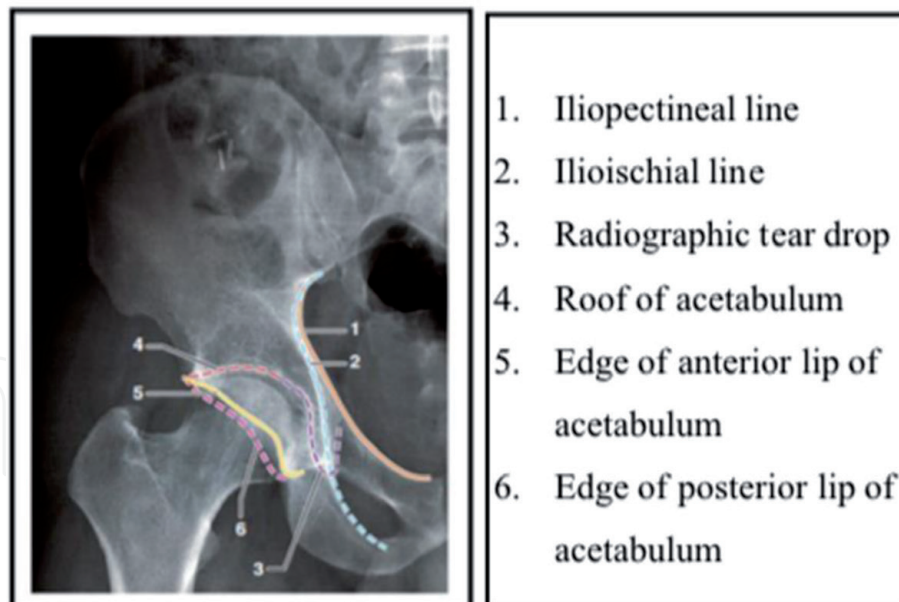
- Iliopectineal line
- The ilioischial line
- The radiographic teardrop
- The roof of the acetabulum
- The anterior rim of the acetabulum
- The posterior rim of the acetabulum

*The Iliopectineal Line* is the major landmark of the anterior column. The pelvic brim is represented by anterior three-quarters of the iliopectineal line. The posterior quarter of this line is formed by the tangency of the x-ray beam to the internal cortical surface of the sciatic buttress and the internal part of the roof of the greater sciatic notch.

*The Ilioischial Line* is considered a radiographic landmark of the posterior column. It is formed by the tangency of the x-ray beam to the posterior portion of the quadrilateral surface.

*The Radiographic Tear drop* is not a true anatomic structure. It represents a radiographic finding and consists of a medial and lateral limb. The lateral limb represents the inferior aspect of the anterior wall in the acetabulum whereas the medial limb is formed by the obturator canal and the antero inferior portion of the quadrilateral surface. Dissociation of the teardrop and the ilioischial line indicates a fracture of the quadrilateral surface.

*The Roof of the Acetabulum* is a radiographic landmark that results from the tangency of the x-ray beam to a narrow portion of the subchondral bone of the superior acetabulum. Dissociation of the radiographic line of the roof indicates a fracture involving the superior acetabulum.



**Figure 7.**  
*Radiographic landmarks on AP radiograph of hip.*

*The Anterior Rim of the Acetabulum* represents the lateral margin in the anterior wall of the acetabulum and is contiguous with the inferior margin of the superior pubic ramus. The anterior rim is typically medial to the posterior rim and has a characteristic undulation in its midcontour in the AP pelvis view.

*The Posterior Rim of the Acetabulum* represents a lateral margin in the posterior wall of the acetabulum. Inferiorly, the posterior rim is contiguous with the thickened condensation of the posterior horn of the acetabulum and approximates a straight line, being more vertical than the anterior wall.

### **3.2 The iliac oblique view (also known as external oblique view)**

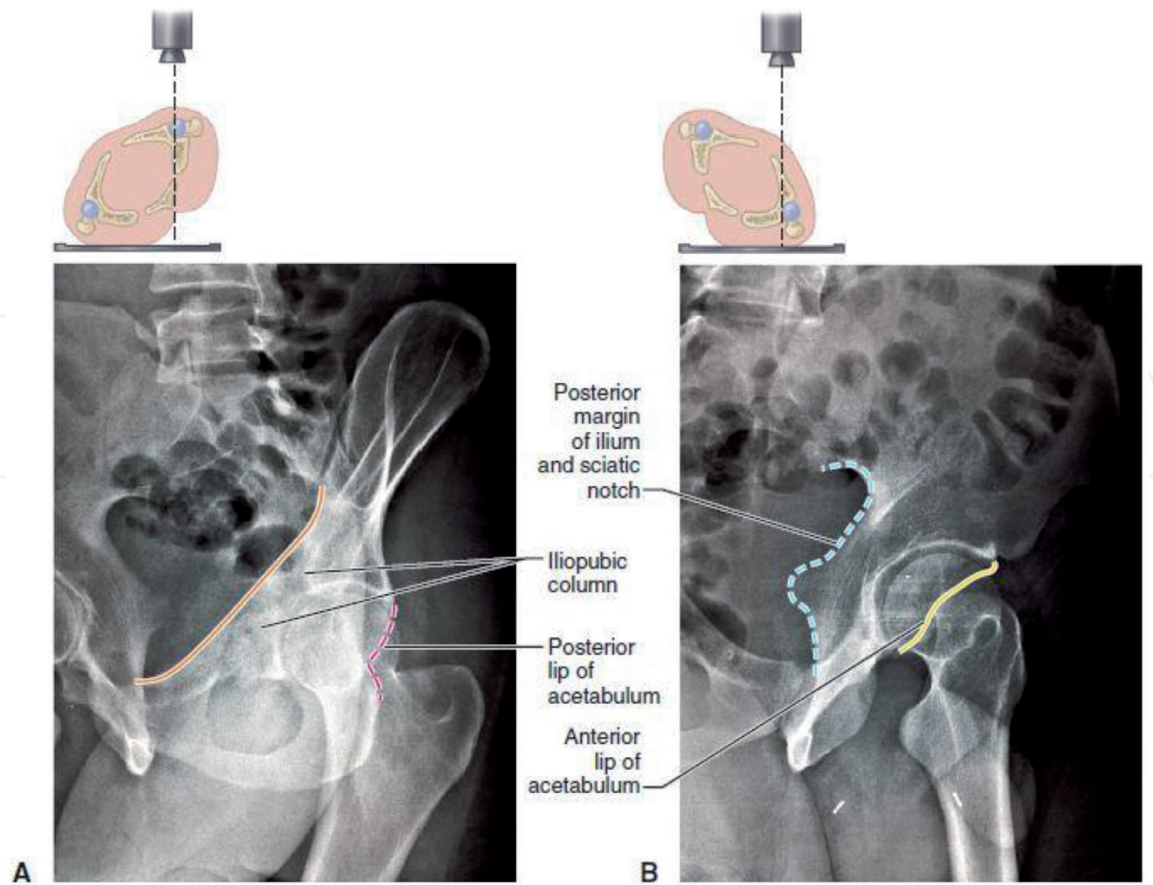
This view is obtained by rotating the patient so that the injured hemipelvis is tilted 45 degrees away from the x-ray beam. Structures visible on this view are greater and lesser sciatic notches, anterior rim of acetabulum and iliac wing in its largest dimension. This is the best view to see the fractures involving posterior column. Fractures of the anterior column traversing the iliac wing can also be detected.

### **3.3 The obturator oblique view (also known as internal oblique view)**

This view is obtained by rotating the patient so that the injured hemipelvis is rotated 45 degrees toward the x-ray beam. This view shows the obturator foramen in its largest dimension and profiles the anterior column. The posterior rim of the acetabulum is best visualized in the obturator oblique view.

Posterior subluxation of femoral head can be detected by comparing the relationship of the femoral head with the posterior wall on the normal hip and the injured hip on the obturator oblique view. A dislocated hip will become more obvious in the obturator oblique view, and this view has been advocated for routine evaluation of all posterior fracture dislocations of the hip joint. It is prudent not to delay the reduction of a known dislocated hip (**Figure 8**).

Dynamic stress views under general anesthesia have also been used in acetabular fractures. They serve as a clinical measure of dynamic stability and congruence of



**Figure 8.**  
(A) *obturator oblique view* and (B) *iliac oblique view*.

X-ray view	Information regarding
<b>Antero-posterior pelvis</b>	
Iliopectineal line	Anterior column
Ilioischial line	Posterior column
Posterior lip	Posterior column or wall
Anterior lip	Anterior column or wall
Roof	Superior articular surface
Teardrop	Relationship of columns
<b>Obturator oblique</b>	
Pelvic brim	Anterior column
Posterior rim	Posterior column or wall
Obturator ring	Column involvement
Roof	Superior articular surface
<b>Iliac oblique</b>	
Greater and lesser sciatic notch	Posterior column (posterior border of innominate bone)
Quadrilateral surface of ischium	Posterior column (posterior border of innominate bone)
Anterior lip	Anterior column or wall
Iliac wing	Anterior column
Roof	Superior articular surface

**Table 1.**  
*Information obtained from X-ray landmarks on each standard view [17–19].*

the hip thus helps in assessing the need for operative treatment in small and intermediate fractures of the posterior acetabular wall. This stress examination is most applicable to the fractures of posterior wall.

Each fracture pattern in the classification of Letournel and Judet has typical radiographic characteristics. These fracture patterns are described with respect to the disruption or intactness of the radiographic landmarks.

In the operating room, the three standard views can be obtained with fluoroscopy. The restoration of the radiographic landmarks marks the adequacy of fracture reduction (**Table 1**).

#### **4. Computed tomography**

CT plays a pivotal role in the treatment of acetabular fractures [18, 19]. Axial cuts should be taken with thin (3-mm) intervals and corresponding slice thicknesses. To avoid missing a portion of the fracture the entire pelvis is generally included and comparison to the opposite hip is performed routinely. In general, the transverse fracture lines and fractures of the anterior and posterior walls are in the sagittal plane, paralleling the quadrilateral surface when they are viewed on axial CT images.

Some authors have suggested that axial CT images overestimate the extent of comminution of acetabular fractures. An oblique fracture line divides the acetabulum, so the more inferior CT cuts appear to have three fragments when in reality there are only two. By studying the individual fragments on multiple successive cuts, the entire fracture can be appreciated, giving a true mental three-dimensional picture. High-resolution coronal and sagittal reconstructions of the fracture are helpful in the preoperative evaluation of complex fractures by delineating the fracture lines that lie directly in the plane of a given axial CT image.

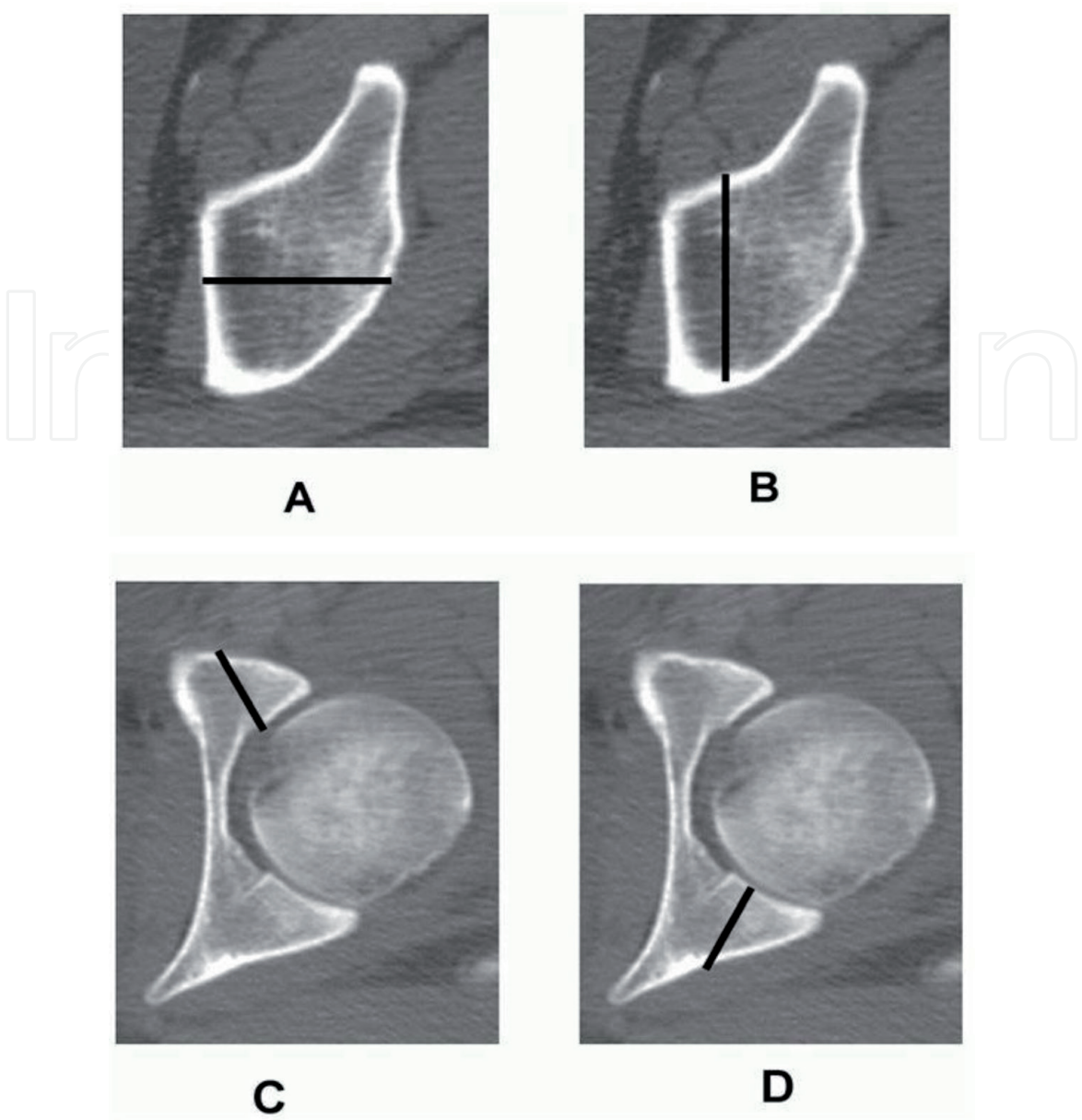
CT scans can give the same information about the acetabular dome as the roof arc measurements on the antero-posterior and oblique radiographs.

Three-dimensional CT reconstructions of a fracture have become sophisticated and can be projected in many different views with the subtraction of the femoral head that show unique features of the various fracture patterns [16] (**Figure 9**).

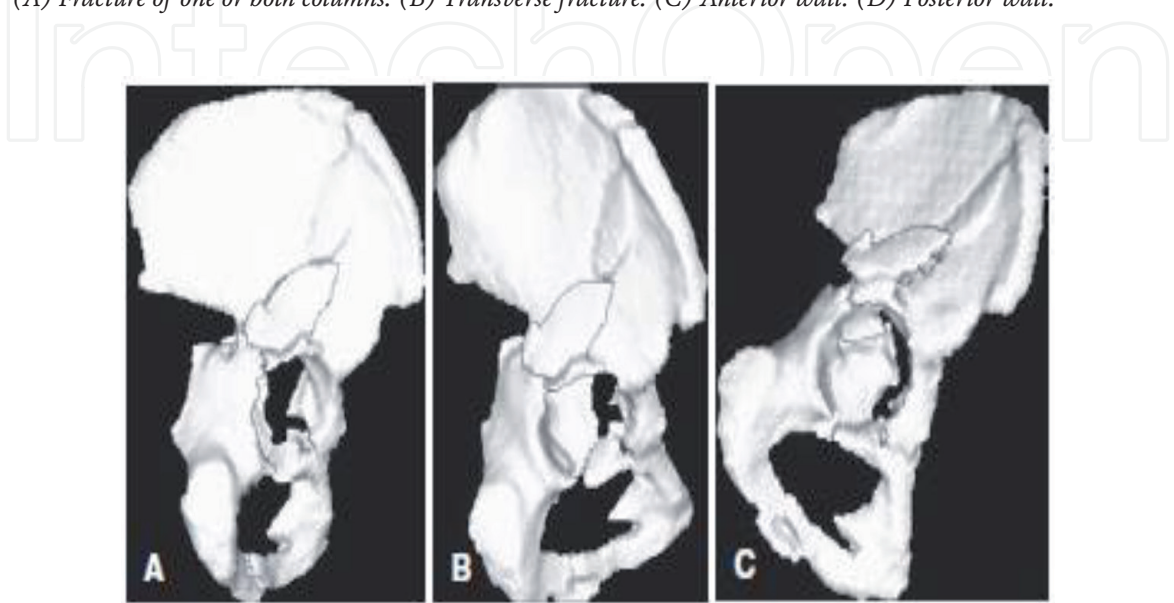
##### **4.1 Role of 3D CT in acetabular fractures**

The late 1970s and early 1980s saw the development of software and hardware that made it possible to produce 3D reformats of complex anatomical structures from sets of transaxial CT images [19]. However, the acceptance of 3D was limited because of poor image quality, lack of user-friendly systems, and limited display flexibility. In past few years, several manufacturers have introduced software that is easier to use and that produces 3D views much faster than the earlier systems. Several investigators now believe that the spatial analysis of a complex acetabular fracture is best made with 3D imaging. Some investigators have stated that 3D CT is a valuable addition to the imaging of acetabular fractures.

The original transaxial slices show the diagnostic details, but 3D imaging integrates the finding into a whole that is more easily assimilated than the sum of its parts. By having an access to a 3D image, the surgeon can decide whether or not to operate and which approach to use. Although 3D images may present less detail to the radiologist than the 2D series, but for an operating surgeon 3D images are very helpful for re orientation during surgical repair. Minor non-displaced fractures are unlikely to require or benefit from 3D reformats [23–26] (**Figure 10**).



**Figure 9.**  
*Orientation of fracture lines on two-dimensional computed tomography as they relate to fracture morphology. (A) Fracture of one or both columns. (B) Transverse fracture. (C) Anterior wall. (D) Posterior wall.*



**Figure 10.**  
*Three-dimensional CT reconstruction of both-column fracture.*

## 5. Classification

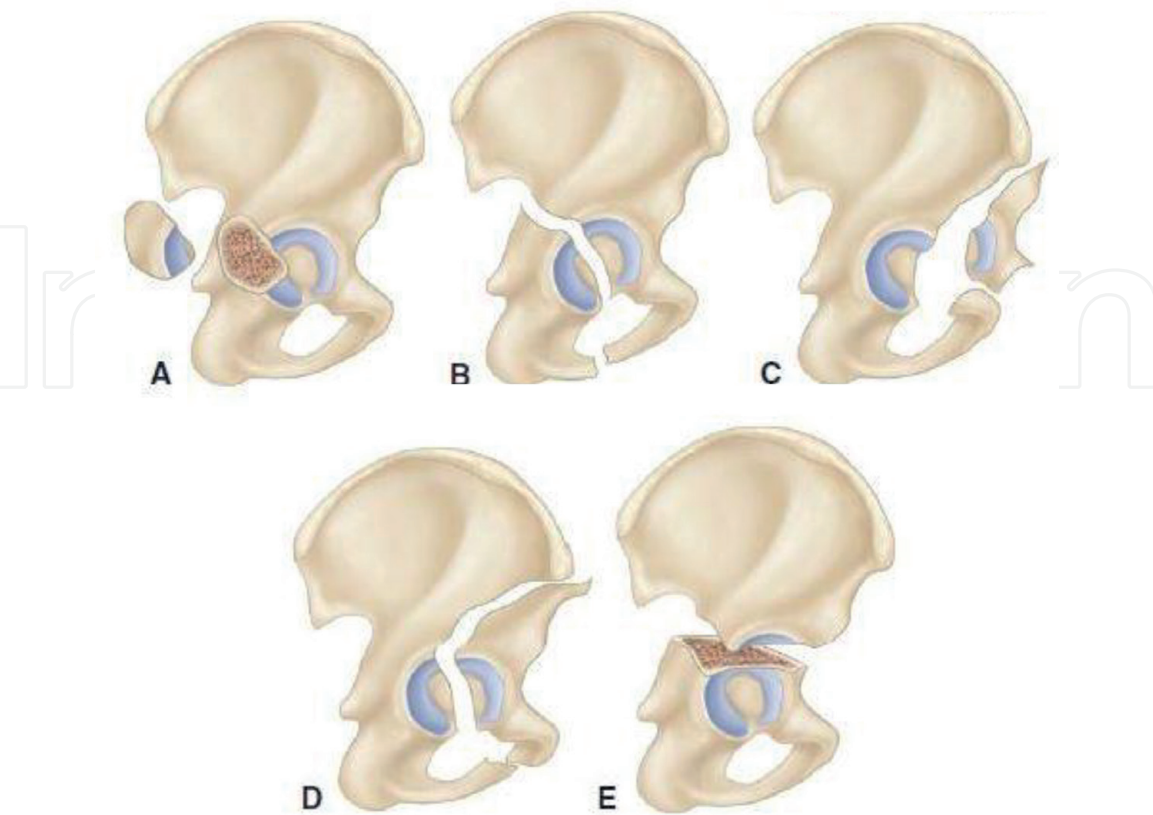
Classification of acetabular fractures is the key element in understanding the injury and is the first stage of surgical planning [17, 18]. Decisions concerning the choice of approach and the alternative fixation techniques available require full appreciation of the fracture anatomy. There are various classifications for acetabular fractures, out of them Letournel and Judet and AO/OTA classification has been discussed in detail here.

### 5.1 Letournel and Judet classification

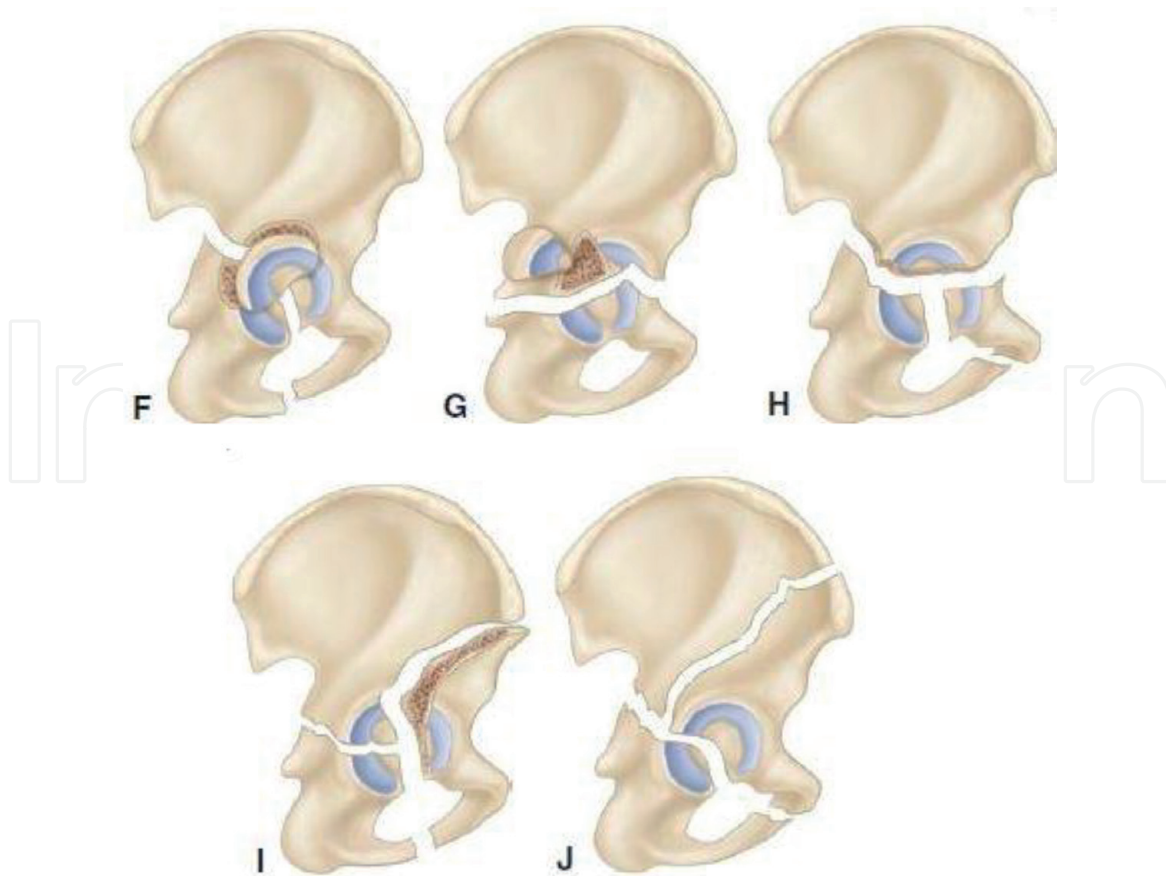
The classification of acetabular fractures that is most widely used is that of Letournel and Judet. This system divides fracture of acetabulum into five simple (elementary) and five complex (associated) patterns. The elementary fracture patterns were defined as those that separated all or parts of a single column of the acetabulum. The associated patterns are either a combination of elementary patterns with an additional fracture line (**Figures 11 and 12**).

Elementary/simple fractures

- Posterior wall
- Posterior column
- Anterior wall
- Anterior column



**Figure 11.**  
*Simple/elementary fractures: (A) posterior wall fracture, (B) posterior column fracture, (C) anterior wall fracture, (D) anterior column fracture, (E) transverse fracture.*



**Figure 12.**

*Associated fractures: (F) Posterior column and posterior wall fracture, (G) Transverse and posterior wall fracture, (H) T-shaped fracture, (I) Anterior column and posterior hemitransverse fracture (J) Complete both column fracture.*

- Transverse

Associated fractures

- Posterior column + wall
- Anterior + posterior hemitransverse
- Transverse + posterior wall
- T-shaped
- Both columns

## 6. Surgical approach for each fracture pattern

One of the most important aspect of the preoperative planning for acetabular fracture surgery is the selection of appropriate surgical approach [23, 24]. The main determinants in the decision-making process are the type of fracture, the elapsed time from injury to operative intervention, and the magnitude and location of maximal fracture displacement. The mainstay surgical approaches to the acetabulum are those described by Letournel and Judet (**Table 2**):

Fracture pattern	Approach
<b>Elementary</b>	
Posterior wall	Kocher-Langenbeck
Posterior column	Kocher-Langenbeck
Anterior wall	Ilioinguinal or iliofemoral
Anterior column	Ilioinguinal or iliofemoral
Transverse	Kocher-Langenbeck or ilioinguinal
<b>Associated</b>	
Posterior column + posterior wall	Kocher-Langenbeck
Anterior column + posterior hemitransverse	Ilioinguinal
Transverse + posterior wall	Extended iliofemoral or Kocher-Langenbeck
T-shaped	Extended iliofemoral or combined
Both columns	Ilioinguinal or extended iliofemoral or combined

**Table 2.**  
*Surgical approaches used for various fracture patterns.*

- The Kocher-Langenbeck
- The ilioinguinal
- The iliofemoral
- The extended iliofemoral

**6.1 Modified Stoppa approach**

General agreement exists for the use of the modified Stoppa approach for all fractures that can be managed with an ilioinguinal approach [24]. This includes anterior wall, anterior column, and associated anterior column and posterior hemi transverse fractures, as well as certain both- column, T-shaped, and transverse fractures. The Stoppa approach is particularly useful for fractures that involve the quadrilateral surface with or without comminution and medial dislocation of the femoral head.

**7. Biomechanics of the acetabulum and applied mechanics of fracture fixation**

**7.1 Normal mechanics of the hip joint**

Of the many joints in the human body, the hip joint has been the one which has attracted the most attention from investigators [26, 27]. The reasons are; first, in normal activity this joint carries the greatest load, load intensity fluctuating between zero and its maximum during each cycle of activity; secondly, probably because of this loading, mechanical failures of the hip joint and of the neighboring bony structure, particularly the upper femoral region, constitute a large proportion of the problems confronting the orthopedic surgeon.

Mechanical forces acting within the normal hip joint are complex and difficult to quantify precisely. During locomotion, large forces occur across the hip joint in which each leg alternately supports the weight of the body. During mid-stance, little acceleration and relatively constant force are applied across the joint, making midstance ideal for a static loading model of investigation. Forces across the joint itself are greatest during midstance and are derived from two primary sources:

- Body weight (BW)
- Abductor moment (Abd)

*Body weight* is centered just anterior to S2 vertebra and exerts a force on the hip joint, which acts to rotate the pelvis about the femoral head toward the center of gravity. Counteracting this force is the *abductor moment*, this act to rotate the pelvis in the opposite direction. During single-leg stance, these two forces cancel each other out and, therefore, the pelvis remains upright.

Because both of these forces have magnitude and direction, they can be expressed as vectors on a free body diagram. The Abd is greater than BW, owing to a shorter moment arm, so that in the steady state.

$$(BW \times a) = (Abd \times b)^2 \quad (1)$$

The joint reactive force is the compressive force experienced at the femoroacetabular articulation, and it is the result of the need to balance the moment arms of the body weight with the pull of the hip abductors at the greater trochanter to maintain a level pelvis (**Figure 13**).

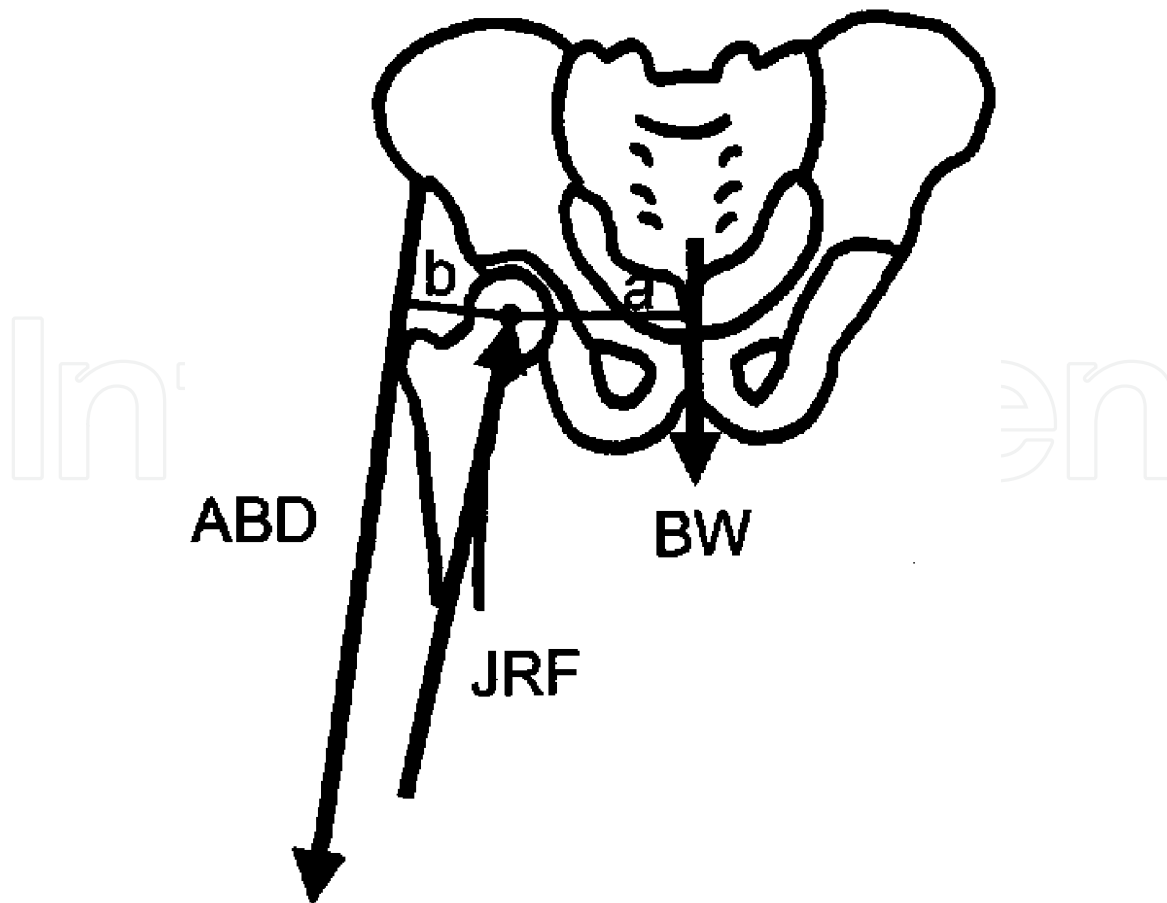
The primary contributions to the joint reactive force are the muscular forces generated to level the pelvis during standing and gait, with a smaller contribution from body weight. The magnitude of this force varies with activities such as the single leg stance phase of gait and it has been found to be as much as 2–4 times the body weight during level walking and stair ascent and slightly higher during stair descent [27, 28].

Smooth gait relies on a well-synchronized series of concentric and eccentric muscular contractions to facilitate a balanced stride. A complete neuromuscular loop exists that maintains the appropriate position between the femoral head and acetabulum with balanced muscular regulation achieved at both the voluntary and involuntary level.

The weight-bearing portion of the hip has been found to vary with position of the femur in relation to the acetabulum and the amount of load placed through the articulation. During normal loading of a nonarthritic joint during activities such as walking, majority of the articular surface participates in weight bearing. This involves the anterior, superior and posterior parts of the femoral head and forms two columns of force that are transmitted within the acetabular margin, joining at the superior aspect of the acetabular fossa. The geometric orientation of the articular cartilage is also optimized for load transfer, because the thickest portions are at the areas of the acetabulum and femoral head most frequently loaded during gait.

## 7.2 Biomechanical consequences of acetabular fracture

A number of studies have focused on the biomechanical consequences of acetabular fracture [28–32]. These studies can be divided into those focusing on.



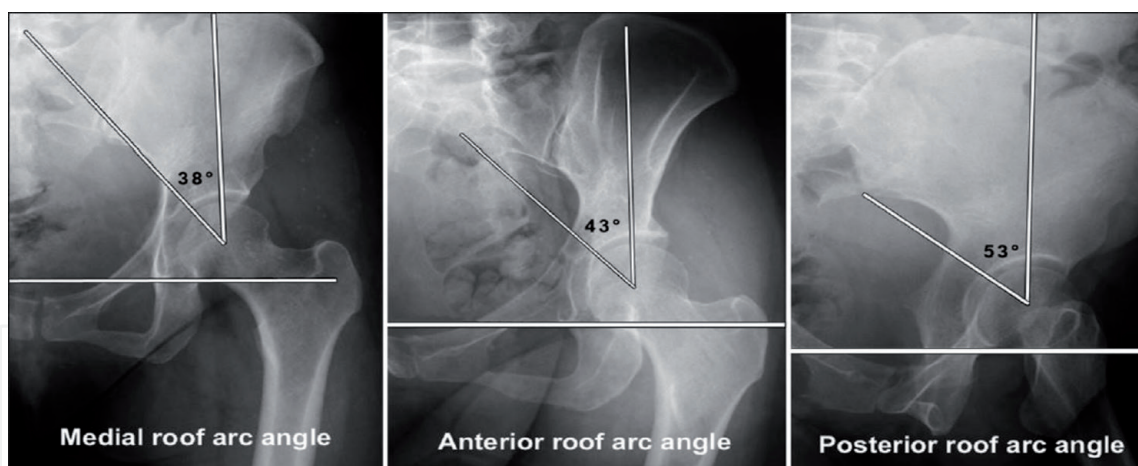
**Figure 13.**

A line drawing of hip joint loading. The joint reaction force vector of the hip is the result of the moments around the hip caused by two opposing surface. The **body weight (BW)** is centered in front of S2 and is distance *a* away from the center of the femoral head. The **force of the abductor muscle (Abd)**, centered from the midiliac wing to the greater trochanter is distance *b* away from the femoral head. During single-leg stance, the product of  $BW \times \text{distance } a$  will equal the force of the *Abd*  $\times$  distance *b*. Because distance *b* is much shorter than *a*, the force of the abductor mechanism is greater.

1. Intra-articular contact area and pressure.
2. Rigidity of fracture fixation.
3. Instability or loss of congruence after fracture.

The studies that focus on contact area and pressures argue that increased joint stress from incongruity or altered loading characteristics eventually will lead to degenerative posttraumatic arthritis through repetitive cartilage damage. The guiding hypothesis is that increased stresses within the cartilage exceed the capacity of the tissue to adapt, initiating a cascade of degenerative changes that ultimately leads to arthritis in the joint. It showed that increased peak pressures, especially in the superior region of the acetabulum, do lead to degenerative arthritis.

Clinically, attempts to define the weight-bearing portion of the acetabulum have used the *roof arc measurement*, which represents the angle formed between a vertical line drawn to the geometric center of the acetabulum and a tangential line drawn from the geometric center to the point at which the fracture line enters the joint on antero-posterior and Judet view radiographs. When measured on standard antero-posterior and 45° oblique radiographs, the roof arc measurement gives an estimation of the amount of articular surface remaining intact (**Figure 14**).



**Figure 14.**  
*Medial, anterior and posterior roof arc angle.*

### 7.2.1 Intra-articular contact characteristics

Several studies have focused on the alteration of contact area and stresses in the joint as a result of the fracture [28–32]. All fracture patterns showed a change from a uniform contact pattern to one of increased contact area and peak pressures in the superior acetabulum.

Letournal introduced the concept of “secondary congruence” in both column fractures of the acetabulum. In this group, the complete separation of all articular acetabular bony fragments can lead to an extra anatomical orientation around the femoral head with the possibility of healing in secondary congruence. In contrast, Levine et al. found an increase of the mean pressure and peak pressure in the acetabular roof area, whereas the contact area and mean pressure between femoral head and acetabular surface was decreased significantly in the anterior articular region and on a lesser degree in the posterior region.

## 8. Significance of surgical anatomy in hip arthroscopy

Surgical anatomy plays a pivotal role in hip arthroscopy as erroneous placement of portals can lead to injury to various important structures as described previously in the chapter. A surgeon should be well aware of various landmarks as well as vital structures around the hip joint while making portals and also while working through these portals.

One of the disastrous complication of hip arthroscopy is injury to sciatic nerve or femoral nerve and vessels. Various evidences suggest that these injuries can be prevented when proper technique in portal placement was used.

Another structure that is quite often injured during hip arthroscopy is lateral femoral cutaneous nerve of thigh (LFCN). LFCN is mostly injured during anterior portal placement. Injury to this nerve leads to loss of sensation on lateral aspect of thigh. The nerve is essentially vulnerable to laceration by a skin incision placed too deeply through the subcutaneous tissue.

Apart from these, if proper surgical anatomy is known, injury to various soft tissues around hip can also be minimized considerably. It is prudent for the surgeon to be aware of various anatomical structures around hip then only a safe and successful surgery can be performed.

## 9. Conclusion

Anatomy has always been a second wife for a surgeon. Its role cannot be neglected whether it is a minor or major surgery. When it comes to advanced surgeries like arthroscopy requiring meticulous techniques, surgical anatomy becomes more important. If a surgeon is well versed with surgical anatomy, many iatrogenic injuries can be avoided considerably.

### Conflict of interest

None.

### Source of funding

Self.

## Author details

Sachin Kumar Sharma\* and Hemant Mathur  
Government Medical College and SSG Hospital Vadodara, Gujarat, India

\*Address all correspondence to: docsachinsharma0@gmail.com

## IntechOpen

© 2020 The Author(s). Licensee IntechOpen. This chapter is distributed under the terms of the Creative Commons Attribution License (<http://creativecommons.org/licenses/by/3.0>), which permits unrestricted use, distribution, and reproduction in any medium, provided the original work is properly cited. 

## References

- [1] Eichenhiltz SN, Stark RM. Central acetabular fractures. *Journal of Bone and Joint Surgery. American Volume*. 1964;**46A**:4
- [2] Beaulé PE, Dorey FJ, Matta JM. Letournal classification of acetabular fractures. *Journal of Bone and Joint Surgery. American Volume*. 2003;**85A**:9
- [3] Stewart MJ. Discussion of prognosis of fractures of acetabulum. *Journal of Bone and Joint Surgery. American Volume*. 1961;**43A**:59
- [4] Laird A, Keating JF. Acetabular fractures: A 16 year prospective epidemiological study. *Journal of Bone and Joint Surgery. British Volume*. 2005;**87**:969-973
- [5] Muller ME et al. *Manual of Internal Fixation*. Berlin Heidelberg: Springer-Verlag; 1992
- [6] Matta J. Fractures of the acetabulum: Accuracy of reduction and clinical results in patients managed operatively within three weeks after the injury. *Journal of Bone and Joint Surgery. American Volume*. 1996;**78A**:1632-1645
- [7] Kleinberg S. Fracture of acetabulum with central luxation of the hip. *Annals of Surgery*. 1923;**78**(6):806-813
- [8] Olson SA. *Diagnosis and Treatment of Acetabular Fractures: Historic Review*. 1st ed. USA: Informa Healthcare; 2007
- [9] Bircher M. Pelvic and acetabular fractures past, present and future. *AO Dialogue*. 2007;**1**(07):36-39
- [10] Rogers LF, Novy SB, Harris NF. Occult central fractures of the acetabulum. *Journal of Bone and Joint Surgery. American Volume*. 1975;**124**:1
- [11] Bray TJ, Esser M, Fulkerson L. Osteotomy of the trochanter in open reduction and internal fixation of acetabular fractures. *Journal of Bone and Joint Surgery*. 1987;**69**(5):711-717
- [12] Murphy D, Kaliszer M, Rice J, McElwain P. Outcome after acetabular fractures: Prognostic factors and their inter relationships. *International Journal of Injury*. 2003;**34**(7):512-517
- [13] Im GI, Chung WS. Fractures of posterior wall of acetabulum: Treatment with cannulated screws. *International Journal of Injury*. 2003;**10**:031
- [14] Berton M, Jessica C, McMicheal. Outcome of posterior wall fractures of acetabulum. *Journal of Bone and Joint Surgery*. 2007;**89-A**:6
- [15] Manson T, Schmidt A. Acetabular fractures in elderly. *Journal of Bone and Joint Surgery*. 2016;**4**(10):e1
- [16] Pesantez R, Ziran BH. *Anatomy of Pelvis: Fractures of Pelvis and Acetabulum*. 1st ed. USA: Informa Healthcare; 2007
- [17] Canale ST. *Campbells Operative Orthopaedics*. 12th ed. Vol. 3. Philadelphia, PA: Elsevier Inc.; pp. 2741-2796
- [18] Buchholz RW, Hechman JD, Court Brown CM. *Rockwood and Green's Fractures in Adults*. 7th ed. Philadelphia, PA: Lippincott Williams and Wilkins Co.; 2012
- [19] Lawrence DA, Men K, Baumgartner M, Hamis AH. Acetabular fractures: Anatomic and clinical considerations. *American Journal of Roentgenology*. 2013;**201**:W425-W436
- [20] Pierannunzii L, Fisher F, Tagliabue L. Acetabular both

column fractures: Essentials of operative management. Injury: International Journal of the Care of the Injured. 2010;1145-1149

for anterior column and posterior hemitransverse acetabular fractures. Acta Orthopaedica et Traumatologica Turcica. 2017;51:248-253

[21] Romanes GJ. Cunninghams' Manual of Practical Anatomy. 15th ed. Vol. 1. Oxford Publications; 1986

[30] Giannoudis PV, Grotz MRW, Papakostidis C, Dinopoulos H. Operative treatment of displaced fractures of the acetabulum (a meta-analysis of 34 studies). Journal of Bone and Joint Surgery. British Volume. 2005;87-B:2-9

[22] Jarrod Durkee N, Jacobson J, Jamadar D, Karunakar MA, Morag Y, Hayes C. Classification of commom acetabular fractures: Radiographic and CT appearances. American Journal of Roentgenology. 2006;187:915-925

[31] Mardanpour K, Rahbar M, Rahbar M, Mardanpour N, Mardanpour S. Functional outcomes of traumatic complex acetabular fractures with open reduction and internal fixation (a study of 200 cases). Open Journal of Orthopedics. 2016;6:363-377

[23] De Boer P, Buckley R, Hoppenfield S. Surgical Exposures in Orthopaedics: The Anatomic Approach. 4th ed. Lippincot Williams and Wilkins Co.; 2011

[32] Rahimi H, Gharahdaghi M, Parsa A, Assadian M. Surgical management of acetabular fractures (a study of 44 cases). Trauma Monthly. 2013;18(1):28-31

[24] Cutrera NJ, Pinkas D, Toro JB. Surgical approaches to the acetabulum and modification in techniques. Journal of American Academy of Orthopedic Surgeons. 2015;23:592-603

[25] Laurence M, Freeman AR, Swanson AV. Section of orthopaedics. Journal of Bone and Joint Surgery. American Volume. 1966;59A

[26] Tile M, Helfet D, Kellam J. Fractures of Pelvis and Acetabulum. 3rd ed. Lippincot Williams and Wilkins Co; 2003

[27] Bowman KF, Fox J, Sekiya JK. A clinically relevant review of hip biomechanics. The Journal of Arthroscopic and Related Surgery. 2010;26(8):1118-1129

[28] Gansslen A, Hildebrand F, Krettek C. Conservative treatment of acetabular both column fractures: Does the concept of secondary congruence work? Acta Chirurgiae Orthopaedicae. 2012;79:411-415

[29] Lei J, Dong P, Li Z. Biomechanical analysis of the fixation systems