

We are IntechOpen, the world's leading publisher of Open Access books Built by scientists, for scientists

6,900

Open access books available

186,000

International authors and editors

200M

Downloads

Our authors are among the

154

Countries delivered to

TOP 1%

most cited scientists

12.2%

Contributors from top 500 universities



WEB OF SCIENCE™

Selection of our books indexed in the Book Citation Index
in Web of Science™ Core Collection (BKCI)

Interested in publishing with us?
Contact book.department@intechopen.com

Numbers displayed above are based on latest data collected.
For more information visit www.intechopen.com



Brace Treatment for Adults with Spinal Deformities

Hans-Rudolf Weiss and Deborah Turnbull

Abstract

The bracing indication for adults with spinal deformities is two-fold: (1) pain and (2) deformity. Although pain is more frequent in the adult population with scoliosis, there is no correlation between the angle of curvature and pain intensity. Pain is reportedly more frequent in patients who were operated. Non-specific pain can successfully be treated with stabilisation exercises; however, some patients may need brace treatment to improve their pain. Today, with the help of a simple clinical test, we can distinguish between different types of lower back pain allowing a differential approach to the symptom. There is some evidence that pain can successfully be reduced by these approaches mainly influencing the sagittal profile. In patients with bigger deformities and in patients aiming at reducing their deformity, pattern-specific scoliosis braces are a successful choice according to published research cases. The different specific brace types/designs along with the differential indication for these brace types will be described in this chapter.

Keywords: adult scoliosis, deformity, pain, brace treatment

1. Introduction

General remarks regarding chronic back pain have been reviewed in a previous study focussing on brace treatment for patients with spinal deformities [1]: within the adult population, certain complaints and diagnoses are increasing such as low back pain, degenerative scoliosis and spinal stenosis. The number of symptomatic patients with spinal stenosis complaints is not known but the main aims of interventions are to improve pain management, functional and lifestyle choices [2]. Spinal stenosis surgery is increasing, and in the 1980s and early 1990s, it is suggested by Ciol et al. [3] that the numbers increased eight-fold. It is controversial to assume that sedentary lifestyles contribute to back pain, but few discussions continue in this topic of research. It is hypothesised that there are negative consequences to this type of lifestyle, initially within muscles, which ultimately lead to compensation in the structure and function of connective tissue [4].

A sedentary choice in lifestyle may initially lead to a negative change in posture, such as a loss of lumbar lordosis. This postural position correlates significantly with a prevalence of lower back pain (LBP) and spinal claudication. In the adult population, lower back pain and spinal claudication can progress to degenerative, de novo scoliosis [5].

Research focusing on younger adolescent female patients [6] demonstrated that non-specific LBP is reported even in this younger age group, especially those reporting a family member with lower back pain.

In 60% of secondary school pupils and 32% of students, lower back pain was a reported symptom. A correlation between lower back pain and displaying a sedentary position ($p < 0.001$ for pupils, and $p < 0.02$ for other students), and smoking ($p < 0.001$ for students and $p < 0.02$ for pupils) has shown to be statistically significant in analysis [7].

Furthermore, a beneficial consequence of an increase in physical activity and leisure time has shown to reduce musculoskeletal morbidity in patients of working age, specifically in those who have sedentary jobs [8].

Postmenopausal women who have sedentary lifestyles may benefit from regular weight-bearing exercise not only to reduce their back complaints but also to slow down the loss of bone mass.

Some studies argue the contrary and do not support the hypothesis that sedentary lifestyle contributes to lower back pain [9–11]. In one study, the lordotic angle seemed to have no influence on the prevalence of low back pain [9]. The presence of lordosis and the angle of lordosis alone may not be the only influential cause, but more specifically, it is the location of lordosis and shape of the posture, specifically the lordosis in the upper lumbar section of the spine that has the most effect upon reported pain levels [12, 13].

‘Chronic low back pain’ is an umbrella term and relates to patients reporting pain in the lumbar or sacral region or even in the sacroiliac pelvic joints. As the pelvis may be involved, the iliolumbar ligaments and even some radicular symptoms may also add to the complexity of the source of pain. With the presence of radicular symptoms, the nerve root affected would determine the origin of the lower back pain [14].

Without the presence of radicular symptoms, chronic lower back pain cannot be caused by a specific nerve root and may have a more complex cause involving L5/S1 or L4/5, and or the pelvis joints or ligaments [14].

Chronic low back pain without radicular symptoms and without any other specific clinical finding (for example, spondylolisthesis) is not classified and attributed in international research as being ‘unspecific’ or ‘non-specific’. For bracing of this group of patients with chronic non-specific low back pain, simple physical tests have been published to predict the brace type the patient might benefit from. Based on the results of physical tests, a simple functional classification of ‘non-specific’ lower back pain has been developed [1].

In patients with scoliosis, besides the common cosmetics issues, pain is also a reported common issue [15]. Although back pain in patients with scoliosis is not related to the size of the curvature (Cobb angle) [16, 17], there is evidence that scoliosis patients experience statistically more back pain in later adulthood than age-matched controls [18–21]. This back pain is not always disabling [19–21] and can be treated conservatively with reasonable success [16, 17, 22, 23]. While low back pain increases after surgery [24], pain in patients with scoliosis without surgery can be reduced with exercises, be it core stabilisation exercises [22, 23] or pattern-specific exercises (for example, Schroth) [16, 17].

In rare cases, the pain cannot be reduced using the functional exercise approach. For these cases, bracing can be successful [1, 12, 13, 25–27].

As outlined above in patients with scoliosis, we distinguish between different kinds of chronic back pain [28]. Most complaints come from the lower back region. Specific chronic low back pain stems from the lumbosacral region and can usually be referred to an injured or inflamed nerve root. This type of pain mainly is caused by a disc prolapse with compression of a nerve root. Specific low back pain needs a

specific treatment in order to reduce the nerve compression and, commonly, surgical decompression in case of significant impairment of the nerve [28].

But as already outlined, non-specific chronic low back pain cannot be referred to a single nerve root. In patients with chronic non-specific low back pain, there may be functional impairments of the sacroiliac joints, lumbar facet joints, overuse of the iliolumbar ligament and spinal stenosis, relative or absolute. Psychological issues also play a role in the development of chronic non-specific low back pain [14, 28]. This also applies to patients with spinal deformities.

Functionally, we may distinguish between postural low back pain (PLBP) and instability low back pain (ILBP) [1] (**Figure 1**). While PLBP mainly is related to loss of lumbar lordosis in later adulthood, ILBP is related to joint laxity or a definite instability like in patients with spondylolisthesis. Combinations of both entities are also possible [1].

In a study from 2009 [26], 130 patients presenting with spinal deformities (ranging from middle aged to older adults of 69 years old) and chronic unspecific low back pain were tested, using brace treatment for their chronic lower back pain. 16 of these patients presented with symptoms of spinal claudication. The sagittal re-alignment test (SRT) was applied (a lumbar hyperextension test) and a ‘sagittal de-lordosation test’ (SDT) to each participant. In addition, three female patients with spondylolisthesis were tested, including one female with symptoms of spinal claudication. 117 of the 130 patients reported a significant pain reduction when the SRT was applied. 13 patients, when applying the SDT also had significant reductions in pain. Three out of 130 patients had no significant change in their pain levels in either test. Pain intensity for all participants was high prior to the physical tests (VRS scale 0–5) and low while performing the physical test. These differences in pain scores were highly significant in analysis. There was an exception in three patients (2.3%): a clear distribution to one of the two classes was possible.

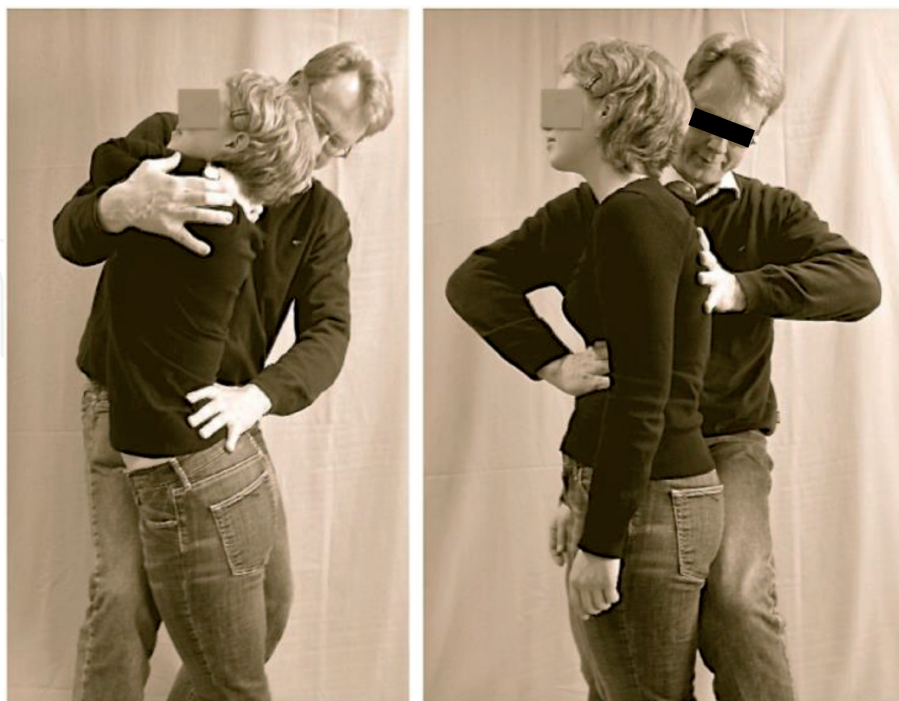

Figure 1.

The sagittal realignment test (SRT) seen on the left and the de-lordosation test (DT) with patient in the standing position. The sagittal realignment test (SRT)—a positive result in this test will present with an immediate reduction in chronic postural LBP (PLBP). The de-lordosation test (DT) pictured on the right—a positive result on this test will present with an immediate reduction in chronic LBP if this is due to instability low back pain (ILBP). Taken from [1] (Creative Commons Attribution Licence).

117 patients were supplied successfully with a sagittal realignment brace and 13 with a sagittal de-lordosing brace. A clear distribution of the patients from this sample to either chronic postural or chronic instability back pain was possible. In 2.3%, a combined chronic low back pain was found. The authors concluded that chronic non-specific low back pain may be classified physically. The functional classification described is necessary to decide which specific conservative approach (lordosation/de-lordosation of the lumbar spine) should be used [1]. However, the topic spinal deformities in conjunction with brace treatment is not well established in the international literature and research. Therefore, a systematic PubMed review has been undertaken in order to find more studies with the aim to establish a scientific basis for treatment suggestions for this group of patients [15].

2. Results from a recent review

A PubMed review was undertaken on the April 28, 2019, using the key words: (1) scoliosis, pain, brace treatment and (2) scoliosis, pain, orthotics [15]. From both searches, the studies were extracted containing patients with the diagnosis of a scoliosis with additional chronic non-specific low back pain who were treated with a brace [15].

142 items have been found for search (1) and 111 for search (2) [15]. Nine items have been identified to fulfil the inclusion criteria from search (1) and six from the search (2). As most of the items were found in both searches, the total number of different items as found in both searches was 10 [1, 12, 26, 27, 29–33]. There were two pilot studies [12, 29] six case reports/case series [13, 27, 30–33], one mid-term study [26] and one study containing a proposal for a simple classification allowing a specific approach for different types of low back pain as already outlined above [1].

3. Discussion

The authors discussed the findings as follows [15]: according to the papers found, there is little overall evidence and no high-quality research studies were found for bracing in relation to pain in this patient group. Only one study had a follow-up of more than 1 year (18 months) [26], allowing some initial conclusions that brace treatment might be effective in the treatment of chronic pain in patients with spinal deformities. In this mid-term study [26], a lumbar brace increasing lordosis was used with a successful outcome, while in a recent pilot investigation, a brace reducing lumbar lordosis was suggested [29]. In the latter study published in 2018, most of these earlier studies were not cited, nor was a differential indication of braces for chronic low back pain attempted or discussed [29].

Considering the facts that (1) in most scoliosis patients, a reduction of lumbar lordosis is evident [12, 25, 26, 34–36] and that (2) loss of lumbar lordosis is correlated to low back pain in adulthood [37, 38], the assumption that reducing lumbar lordosis is an appropriate approach, is not based upon any detailed reasoning or evidence, and even possibly worsen symptoms. Additionally, it has been shown that increasing lumbar lordosis stabilises or may even correct the three-dimensional scoliosis [25, 35]. Therefore, improving lumbar lordosis in this group of patients with scoliosis should be considered as an important issue to address in the initial stages of examination and related treatment. According to the findings within this review [1, 32], only in patients with chronic back pain due to vertebral instabilities, a brace reducing lumbar lordosis is indicated.

The success rate of brace treatment in patients with non-specific chronic low back pain in general does not appear to be significant, and compliance is generally described as moderate or poor [39–41]. A significant pain reduction has not been reported upon in most of the recent literature [41, 42].

In the mid-term follow-up of scoliosis patients treated with a sagittal re-alignment brace [26], there was a high compliance and a reasonable decrease of pain intensity and pain frequency (**Figures 2 and 3**). Patients who were able to feel the brace action and pain reduction before the start of brace treatment using clinical examination tests [1] may have resulted in an increase in compliance and success with treatment. In order to avoid costly brace treatment without any effect, it is suggested by the conclusions of this review, to test the patients for the most beneficial approach (lumbar lordosation/lumbar de-lordosation). When patients recognise that they can benefit from specific brace treatment, by an instant reduction in their pain symptoms, the matter of compliance may be vastly improved.

It seems important to note that true scoliosis is not easily correctable in adulthood, and therefore, specialists should be consulted when assessing these patients to ensure the examination and treatments are appropriate. In patients with an angle of trunk rotation (ATR) exceeding 10°, a pattern-specific brace is indicated [27, 31]. Symmetrical braces applied in patients with a significant rib hump/lumbar prominence will usually twist on the person's trunk according to the asymmetry and torsion effect and therefore will not remain in the correct position, hence the need for individual bespoke fit. There are case reports and a recent report on a cohort treated with a pattern specific Chêneau style brace showing that with specific braces for lower back pain can successfully be reduced [27, 43].

There is a case study of a 37-year-old female patient with late-onset idiopathic scoliosis [27]. The patient had chronic low back pain since the age of 23 and reported daily pain at a level of 5–7 on average on a Visual Analogue Scale of 0–10. She received a short scoliosis-specific Schroth exercise programme and was also fitted with a Gensingen brace (GBW) for part-time wear. At a 16-month follow-up, the patient no longer suffered from daily low back pain (with heavy lifting only)

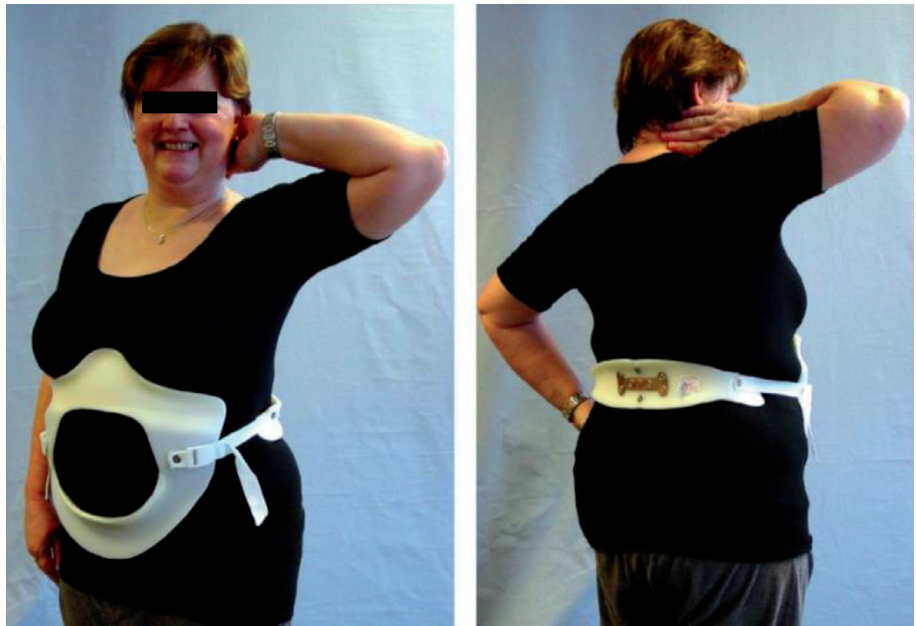

Figure 2.
Patient wearing a sagittal re-alignment brace. When the brace is adjusted to the patient, the main dorsal pressure should restore lordosis at the level of L2. Free space is necessary at the lower ribs while the pressure areas ventrally are located directly caudal of the pectoral region and cranial to the pubis. Taken from [26] (Creative Commons Attribution Licence).

and was fully active. Additionally, her lumbar Cobb angle and angle of trunk rotation improved. The authors concluded that patients with late-onset idiopathic scoliosis may benefit from a pattern-specific conservative treatment approach (physiotherapy and bracing). In this population, surgical intervention should be regarded as the last resort, since there are many long-term unknowns with surgery in patients with scoliosis [44–51] (**Figure 4**).

Widjaja and Varani [43] investigated adolescent idiopathic scoliosis patients with a single lumbar curve pattern who wore a Gensingen Brace (GBW), which is a Chêneau style brace of standardised computer aided design (CAD). They included more mature or adult patients with a Risser sign of IV or V. The in-brace Cobb angle corrections were measured, and patients were monitored for 6 months after brace initiation in order to analyse the effects.

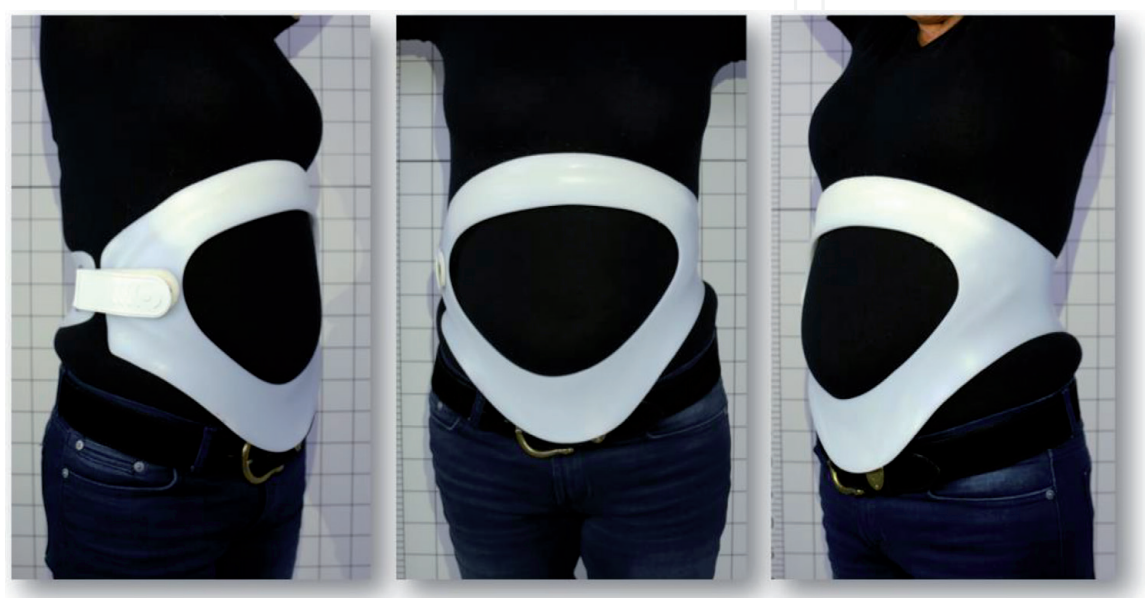


Figure 3.
Design of the sagittal re-alignment brace as applied currently.

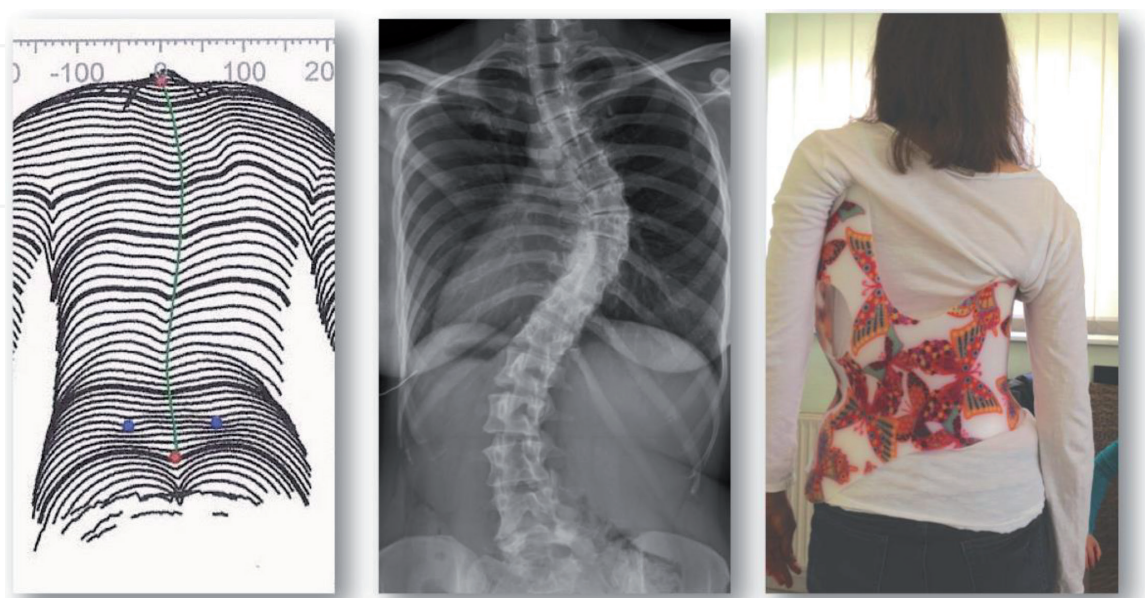


Figure 4.
Left: clinical appearance of the trunk at the start of treatment; middle: X-ray at the start of treatment and on the right: Gensingen brace (GBW) as constructed for the patient. Reproduced with permission of the Society of Physical Therapy Science from [27].

A total of 26 patients have been included. The average age was 17.7 years and the oldest patient from the study was 40 years. The average Cobb angle was 41.5° before treatment (20–72°). 19 patients from this study (73.1%) had chronic low back pain of various degrees before treatment and seven patients (26.9%) were asymptomatic but seeking treatment because of cosmetic reasons.

In-brace correction was 67%. At 6 months follow-up, correction without brace was 23% and the average Cobb angle was 33.2°. About 12 patients (54.5%) had a significant correction of >20%. After 6 months, all previously symptomatic patients reported that they no longer experienced low back pain.

As the GBW is a brace to increase lordosis of the lumbar spine from the results of this latter study [43], we may assume that in scoliosis patients with chronic low back pain, the re-alignment or increase of lumbar lordosis can be regarded as being highly effective with respect to pain reduction.

Although spinal claudication may arise from narrowing of the spinal canal, not all patients with narrowing develop symptoms [13]. The reason why some patients develop symptomatic stenosis and others do not is still unknown. Therefore, the term lumbar spinal stenosis refers to a clinical syndrome of lower extremity pain caused by mechanical compression on the neural elements or their blood supply [13]. A 47-year-old woman with a 55° lumbar scoliosis, 30° upper lumbar kyphosis, and highest pain levels under medication (Durogesic, 25 mg; Ibuprofen, 800 mg; and Mirtazapine, 15 mg) was treated with a sagittal re-alignment brace [13]. This patient is pictured in **Figure 2**. Self-reported walking distance was at around 800 m before the pain was referred to be ‘unbearable’ (since 5 years). Patient-reported walking distance was recorded in the brace 2 days and 10 days after adjustment. Walking distance increased to around 8000 m after 2 days and to around 12,000 after 10 days while pain intensity decreased only one point in the VRS, however now without any medication. The authors concluded: in contrary to current hypotheses about the aetiology of spinal claudication, augmentation of lordosis may lead to a significant improvement of symptoms associated with spinal stenosis and lumbar scoliosis. The brace used in this case was a physio-logic brace™ that increases lumbar lordosis [13].

In another case report, brace treatment for spinal claudication following severe spondylolisthesis has been described [32]: a 14-year-old girl with a 25° thoracic scoliosis (2 years post menarche), grade IV spondylolisthesis and spinal claudication underwent treatment with a spondylogic™ brace reducing lumbar lordosis (**Figure 5**). Walking distance without brace was at around 300 steps before intolerable pain was reported. Self-reported walking distance was recorded in the brace 14 days after adjustment. Walking distance increased to an unlimited number of steps after 14 days, while pain intensity decreased three points in the VRS. However, no correction effect of the orthosis on the degree of slippage was found. Although there is evidence that pain in patients with spondylolisthesis can be reduced using exercises and bracing in mild to moderate symptomatic cases, this case demonstrates that bracing can also improve signs and symptoms of spinal claudication in patients with spondylolisthesis of higher degrees [32].

These cases show that there is not a single brace covering the necessary principles of correction for all patients with scoliosis and chronic low back pain. Soft braces are insufficient in their action on the stiff deformity of adult scoliosis patients and therefore, cannot be regarded as effective tools for the treatment of chronic low back pain in scoliosis patients [15]. Hard braces have shown effectiveness and fulfil all possible treatment requirements [1, 26, 27, 43].

A simple clinical test enables the specialised physician to estimate the appropriate approach of bracing, increasing or decreasing lumbar lordosis [1]. In patients with more significant deformities and chronic low back pain, specific braces are

indicated that allow a stable positioning of the brace on the patient's trunk [27, 43]. However, severely stiff and vast deformities may not be successfully treated by any type of brace (**Figure 6**). Therefore, mobility needs to be tested prior to bracing in order to avoid unnecessary treatment and costs.

In view of these findings, only pattern-specific braces or symmetric braces influencing the sagittal profile can be recommended. In general, however, braces without any visible effect on the deformity continue to be prescribed [52] obviously just immobilising the spine (**Figure 7**). This approach today should be regarded as being outdated.

Patients with thoracic kyphosis in later adulthood may suffer from chronic pain in the thoracic region related to facet joint degeneration and functional impairment of the adjacent ribs. When functional treatment including physiotherapy and spinal manipulation do not reduce the symptoms satisfactorily, brace treatment can also be trialled (**Figure 8**). When passive correction of a thoracic kyphosis leads to




Figure 5. The spondylogic® brace design. This 14-year-old patient has a scoliosis of $<25^\circ$ and a symptomatic (presenting with lower back pain) spondylolisthesis. Immediate in-brace pain relief was reported, and spinal stenosis symptoms also reduced. The patient wore the brace full-time when walking and standing to manage her pain. Further long-term effects from this brace design have not been researched at present. Taken from [1] (Creative Commons Attribution Licence).

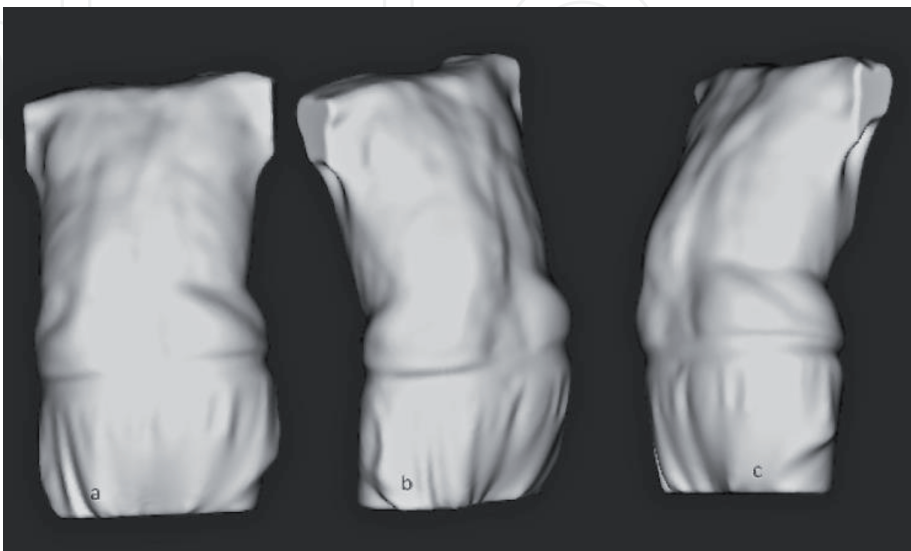


Figure 6. Excessively stiff curves with huge complex deviations cannot be treated by specific bracing. Usually no correction is achievable: (a) view from the rear, (b) view from oblique left and (c) view from oblique right.

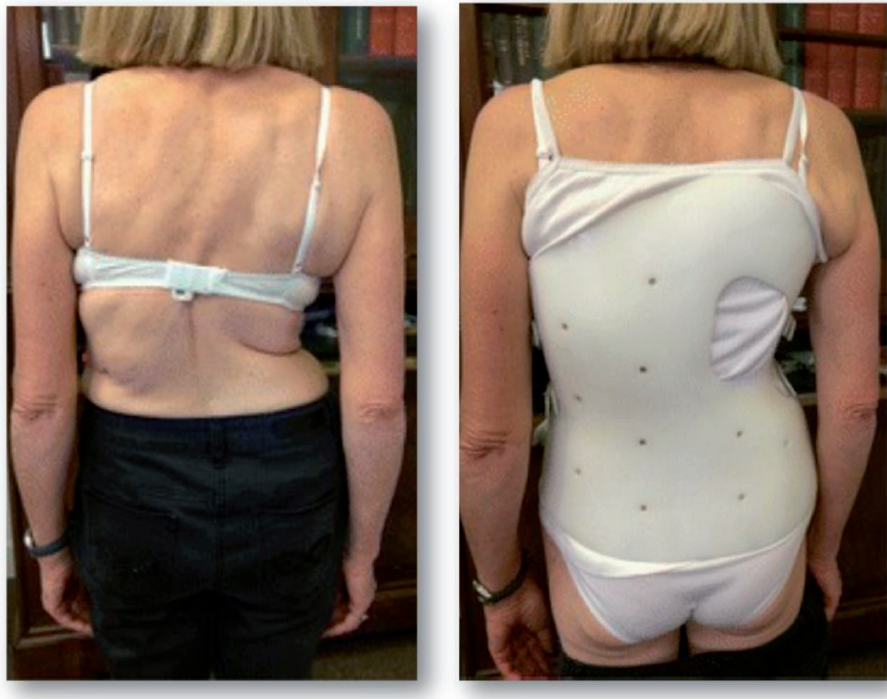

Figure 7.
Brace for an adult with pain. No correction visible, just immobilisation of the spine. This unspecific design could be regarded as outdated. Taken from [52] (Creative Commons Attribution Licence).

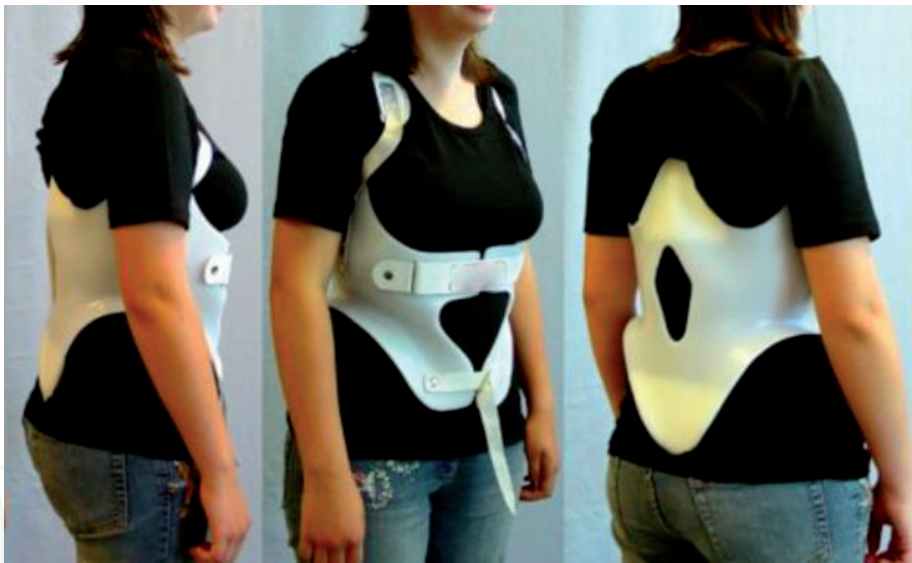

Figure 8.
Patient in a Kyphologic brace™ that may also be used in patients with chronic back pain in the thoracic area. Taken from [53] (Creative Commons Attribution Licence).

significant pain reduction, a brace to reduce thoracic kyphosis may be prescribed. A standardised bracing approach to correct a thoracic kyphosis has been described in literature [53].

Adult patients may experience deformity-related stress and lack of general participation in activities because of their deformity. This fact may be measured and monitored with health-related quality of life questionnaires [54–57].

Freidel et al. investigated women with idiopathic scoliosis with the help of age-appropriate health-related quality of life questionnaires (either the 36-Item Short-Form Health Status Survey, SF-36, or the Berner Questionnaire for Well-Being) [54]. The results from this sample were compared with general population norms.

In univariate and multivariate analyses, it was determined whether age, Cobb angle, and brace use had an impact on health-related quality of life.

Compared with the age-matched general population norm, adolescent patients with idiopathic scoliosis reported to be less happy ($P = 0.001$). They reported more physical complaints ($P < 0.001$) and had lower self-esteem ($P = 0.01$) and higher depression scores ($P = 0.021$). Adult patients reported more psychological ($P < 0.001$) and physical impairment than in the population norm ($P < 0.001$). These results were largely independent of age and Cobb angle.

The authors concluded as follows: the results show that health-related quality of life can be impaired in patients with idiopathic scoliosis. Therefore, the psychosocial situation should be considered in the treatment of these patients [54].

Patients who experienced less body asymmetry were more satisfied with treatment and had a better quality of life [56]. This fact might indicate that quality of life is also related to curve patterns. While combined patterns of curvature (double major) are more compensated and present with less body asymmetry, single curve patterns are more decompensated with significant body asymmetry possibly leading to decreased quality of life.

While there is some evidence that cosmetic improvements can be achieved with pattern specific braces in childhood and adolescence [58–61], there is no literature to be found in PubMed on adult patients with spinal deformities and improved trunk deformity after brace treatment. Nevertheless, there are case reports of adult patients showing a significant improvement of trunk asymmetry and balance (**Figures 9** and **10**). Therefore, high correction bracing should be tried in patients with reduced quality of life because of their trunk deformity. As to the experience of the first author, such improvements cannot be obtained in all adult scoliosis cases.

On the other hand, the cosmetic effects as achieved with the help of spinal fusion surgery are not stable in the mid- or long term [48–50]. Therefore, besides offering psychological support also pattern-specific brace treatment may be tried before a decision for invasive surgery is made.

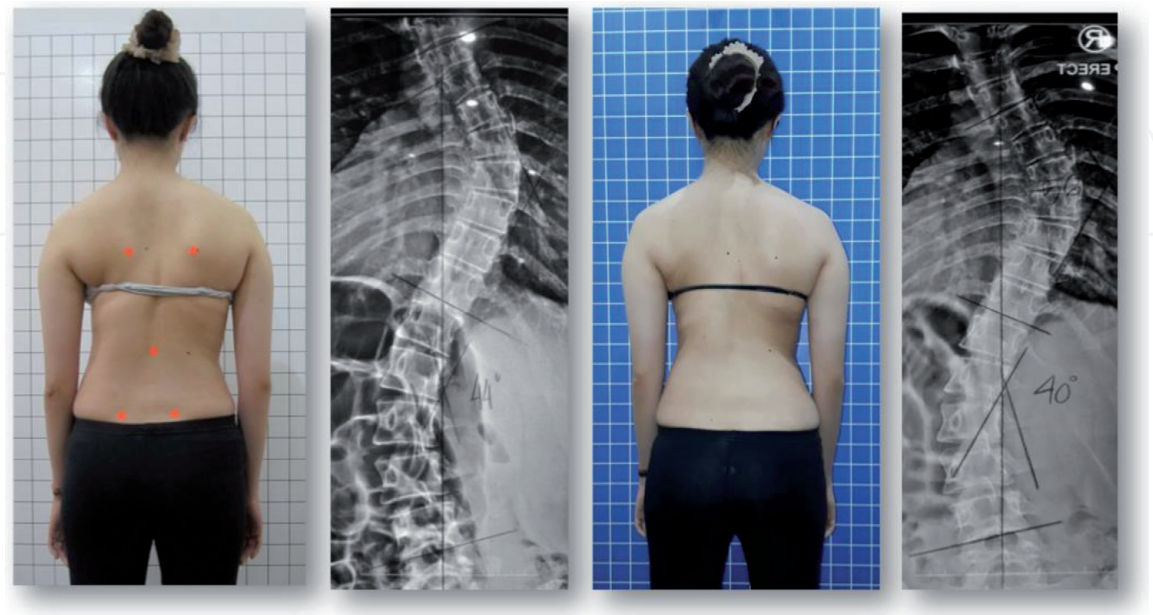


Figure 9. A 23-year-old woman with a Cobb angle of 60° at the start of treatment with a Gensingen brace without significant improvement of Cobb angle, however with a clear cosmetic improvement showing a more balanced posture after 12 months of conservative treatment. With kind permission from Dr. Budi S. Widjaja, Jakarta, Indonesia.

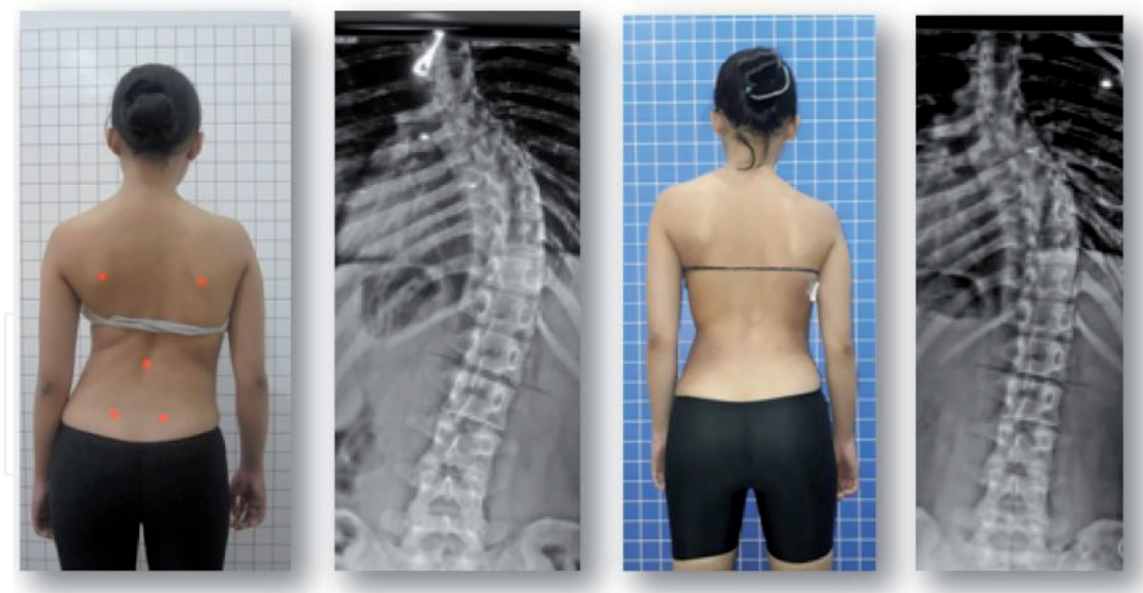


Figure 10.
 An 18-month follow-up of a 20-year-old woman with a Cobb angle of 52° at the start of the treatment with a Gensingen brace and a final Cobb of 36°. A clear cosmetic improvement has been obtained. Courtesy of Dr. Budi S. Widjaja, Jakarta, Indonesia.

It is important to note that brace treatment in later adulthood must be accompanied by a specific daily physical exercise programme. It can be argued that brace wearing does not affect the postural muscles, when in the contrary postural muscle activity is increased while brace wearing [62, 63]. However, the reduction of mobility while wearing the brace may reduce bone mass, especially in postmenopausal women [64–66]. Therefore, regular trabecular loading should be preserved in order to keep bone mass. For patients wearing a brace for some hours per day a Qi Gong, Tai Chi or a Yoga programme involving exercises to mobilise and load the spine in all directions could be beneficial.

4. Conclusions

In adult patients with spinal deformities bracing may be indicated for pain and deformity. Soft braces are not useful for patients with stiff spinal deformities. The appropriate bracing approach can be tested before the brace is prescribed. There is some evidence that pain can successfully be reduced by these approaches mainly influencing the sagittal profile. In patients with bigger deformities and in patients aiming at reducing their deformity, pattern-specific scoliosis braces according to published cases have shown to be successful. There is no high-quality evidence supporting brace treatment for adult patients with spinal deformities; however, the existing evidence is promising.

Acknowledgements

Written informed consent for publication of the patient's information (X-rays, photos, records, etc.) has been obtained from the patients or their parents. HRW provided the first draft and made the literature review. DT contributed to the improvement of the first draft and copyedited the final version. Some parts of the text have been reproduced with permission of the Society of Physical Therapy Science from [15]. More comprehensive information may also be found in [67].

Conflict of interest

HRW is receiving financial support for attending symposia and has received royalties from Koob GmbH & Co KG. The company is held by the spouse of HRW. HRW holds a patent on a sagittal realignment brace (EP 1604624 A1). DT is employed by an orthotic company who make orthotics, including spinal bracing.

Author details

Hans-Rudolf Weiss^{1*} and Deborah Turnbull^{2,3}


1 Schroth Best Practice Academy, Abtweiler, Germany

2 The London Orthotic Consultancy, Kingston upon Thames, UK

3 School of Health and Social Care, University of Teesside, Middlesbrough, UK

*Address all correspondence to: hr.weiss@skoliose-dr-weiss.com

IntechOpen

© 2020 The Author(s). Licensee IntechOpen. This chapter is distributed under the terms of the Creative Commons Attribution License (<http://creativecommons.org/licenses/by/3.0>), which permits unrestricted use, distribution, and reproduction in any medium, provided the original work is properly cited. 

References

- [1] Weiss HR, Werkmann M. Unspecific chronic low back pain—A simple functional classification tested in a case series of patients with spinal deformities. *Scoliosis*. 2009;4:02
- [2] Ploumis A, Transfeldt EE, Denis F. Degenerative lumbar scoliosis associated with spinal stenosis. *The Spine Journal*. 2007;7(4):428-436. DOI: 10.1016/j.spinee.2006.07.015
- [3] Ciol MA, Deyo RA, Howell E, Kreif S. An assessment of surgery for spinal stenosis: Time trends, geographic variations, complications, and reoperations. *Journal of the American Geriatrics Society*. 1996;44:285-290
- [4] Gordon GA. A molecular basis for low back pain in western industrialized cultures. *Medical Hypotheses*. 1990;33(4):251-256. DOI: 10.1016/0306-9877(90)90137-4
- [5] Ploumis A, Liu H, Mehbod A, Transfeldt E. Can radiographic measurement of degenerative lumbar scoliosis predict clinical symptoms? In: *Proceedings of the 5th International Conference on Conservative Management of Spinal Deformities*, Athens, April 2-5, 2008. 2008
- [6] Masiero S, Carraro E, Celia A, Sarto D, Ermani M. Prevalence of nonspecific low back pain in schoolchildren aged between 13 and 15 years. *Acta Paediatrica*. 2008;97(2):212-216. DOI: 10.1111/j.1651-2227.2007.00603.x
- [7] Lebkowski WJ. "Back pain" in teenagers and young adults. *Polski Merkuriusz Lekarski*. 1997;2(8):111-112
- [8] Hildebrandt VH, Bongers PM, Dul J, van Dijk FJ, Kemper HC. The relationship between leisure time, physical activities and musculoskeletal symptoms and disability in worker populations. *International Archives of Occupational and Environmental Health*. 2000;73(8):507-518. DOI: 10.1007/s004200000167
- [9] Nourbakhsh MR, Moussavi SJ, Salavati M. Effects of lifestyle and work-related physical activity on the degree of lumbar lordosis and chronic low back pain in a Middle East population. *Journal of Spinal Disorders*. 2001;14(4):283-292. DOI: 10.1097/00002517-200108000-00002
- [10] Leboeuf-Yde C. Back pain—Individual and genetic factors. *Journal of Electromyography and Kinesiology*. 2004;14(1):129-136. DOI: 10.1016/j.jelekin.2003.09.019
- [11] Yip VY. New low back pain in nurses: Work activities, work stress and sedentary lifestyle. *Journal of Advanced Nursing*. 2004;46(4):430-440. DOI: 10.1111/j.1365-2648.2004.03009.x
- [12] Weiss HR, Dallmayer R, Stephan C. First results of pain treatment in scoliosis patients using a sagittal realignment brace. *Studies in Health Technology and Informatics*. 2006;123:582-585
- [13] Weiss HR, Dallmayer R. Brace treatment of spinal claudication in an adult with lumbar scoliosis—A case report. *Studies in Health Technology and Informatics*. 2006;123:586-589
- [14] Weiss HR. Epidemiologie und Risikofaktoren des chronischen Kreuzschmerzes. *Orthopädische Praxis*. 1999;35(8):469-477
- [15] Weiss HR, Turnbull D. Non-specific chronic low back pain in patients with scoliosis—An overview of the literature on patients undergoing brace treatment. *Journal of Physical Therapy Science*. 2019;31(11):960-964

- [16] Weiss HR. Scoliosis-related pain in adults - treatment influences. *European Journal of Physical and Rehabilitation Medicine*. 1993;**31**:91-94
- [17] Weiss HR, Verres C, Steffan K, Heckel I. Scoliosis and pain—Is there any relationship? In: IAF S, editor. *Research into Spinal Deformities 2*. Amsterdam: IOS Press; 1999. pp. 293-296
- [18] Danielsson AJ, Wiklund I, Pehrsson K, Nachemson AL. Health-related quality of life in patients with adolescent idiopathic scoliosis: A matched follow-up at least 20 years after treatment with brace or surgery. *European Spine Journal*. 2001;**10**(4):278-288
- [19] Weinstein SL, Dolan LA, Spratt KF, Peterson KK, Spoonamore MJ, Ponseti IV. Health and function of patients with untreated idiopathic scoliosis: A 50-year natural history study. *JAMA*. 2003;**289**(5):559-567
- [20] Grauers A, Topalis C, Moller H, Normelli H, Karlsson M, Danielsson A, et al. Prevalence of back problems in 1069 adults with idiopathic scoliosis and 158 adults without scoliosis. *Spine (Phila Pa 1976)*. 2014;**39**(11):886-892
- [21] Weiss HR, Karavidas N, Moramarco M, Moramarco K. Long-term effects of untreated adolescent idiopathic scoliosis: A review of the literature. *Asian Spine Journal*. 2016;**10**(6):1163-1169
- [22] Zapata KA, Wang-Price SS, Sucato DJ, Thompson M, Trudelle-Jackson E, Lovelace-Chandler V. Spinal stabilization exercise effectiveness for low back pain in adolescent idiopathic scoliosis: A randomized trial. *Pediatric Physical Therapy*. 2015;**27**(4):396-402
- [23] Yagci G, Yakut Y. Core stabilization exercises versus scoliosis-specific exercises in moderate idiopathic scoliosis treatment. *Prosthetics and Orthotics International*. 2019;**43**(3):301-308
- [24] Upasani VV, Caltoun C, Petcharaporn M, Bastrom TP, Pawelek JB, Betz RR, et al. Adolescent idiopathic scoliosis patients report increased pain at five years compared with two years after surgical treatment. *Spine (Phila Pa 1976)*. 2008;**33**(10):1107-1112
- [25] Weiss HR. Das “Sagittal Realignment Brace” (physio-logic ® brace) in der Behandlung von erwachsenen Skoliosepatienten mit chronifiziertem Rückenschmerz. *MOT*. 2005;**125**:45-54
- [26] Weiss HR, Werkmann M. Treatment of chronic low back pain in patients with spinal deformities using a sagittal re-alignment brace. *Scoliosis*. 2009;**4**:03
- [27] Weiss HR, Moramarco K, Moramarco M. Scoliosis bracing and exercise for pain management in adults-a case report. *Journal of Physical Therapy Science*. 2016;**28**(8):2404-2407
- [28] Dewitte V, De Pauw R, De Meulemeester K, Peersman W, Danneels L, Bouche K, et al. Clinical classification criteria for nonspecific low back pain: A Delphi-survey of clinical experts. *Musculoskeletal Science & Practice*. 2018 Apr;**34**:66-76
- [29] Zaina F, Poggio M, Donzelli S, Negrini S. Can bracing help adults with chronic back pain and scoliosis? Short-term results from a pilot study. *Prosthetics and Orthotics International*. 2018;**42**(4):410-414
- [30] Polastri M, Romano M. Lumbar scoliosis: Reducing lower back pain and improving function in adulthood. A case report with a 2-year follow-up. *Journal of Bodywork and Movement Therapies*. 2017;**21**(1):81-85

- [31] Gallo D. Case reports: Orthotic treatment of adult scoliosis patients with chronic back pain. *Scoliosis*. 2014;**9**:18
- [32] Weiss HR, Dallmayer R. Brace treatment of spinal claudication in an adolescent with a grade IV spondylosisthesis—A case report. *Studies in Health Technology and Informatics*. 2006;**123**:590-593
- [33] Brubaker ML, Sinaki M. Successful management of iliocostal impingement syndrome: A case series. *Prosthetics and Orthotics International*. 2016;**40**(3):384-387
- [34] Asher MA, Burton DC. Adolescent idiopathic scoliosis: Natural history and long-term treatment effects. *Scoliosis*. 2006;**1**(1):2
- [35] van Loon PJ, Kühbauch BA, Thunnissen FB. Forced lordosis on the thoracolumbar junction can correct coronal plane deformity in adolescents with double major curve pattern idiopathic scoliosis. *Spine*. 2008;**33**(7):797-801
- [36] Burwell RG. Aetiology of idiopathic scoliosis: Current concepts. *Pediatric Rehabilitation*. 2003;**6**(3-4):137-170
- [37] Glassman SD, Bridwell K, Dimar JR, Horton W, Berven SF. The impact of positive sagittal balance in adult spinal deformity. *Spine*. 2005;**30**:2024-2029
- [38] Djurasovic M, Glassman SD. Correlation of radiographic and clinical findings in spinal deformities. *Neurosurgery Clinics of North America*. 2007;**18**(2):223-227
- [39] Jellema P, Bierma-Zeinstra SM, van Poppel MN, Bernsen RM, Koes BW. Feasibility of lumbar supports for home care workers with low back pain. *Occupational Medicine (London)*. 2002;**52**(6):317-323
- [40] van Poppel MN, Koes BW, van der Ploeg T, Smid T, Bouter LM. Lumbar supports and education for the prevention of low back pain in industry: A randomized controlled trial. *JAMA*. 1998;**279**:1789-1794
- [41] Alaranta H, Hurri H. Compliance and subjective relief by corset treatment in chronic low back pain. *Scandinavian Journal of Rehabilitation Medicine*. 1988;**20**:133-136
- [42] Jellema P, van Tulder MW, van Poppel MN, Nachemson AL, Bouter LM. Lumbar supports for prevention and treatment of low back pain: A systematic review within the framework of the Cochrane Back review group. *Spine*. 2001;**26**:377-386
- [43] Widjaja BS, Varani R. Single lumbar curvatures are treated effectively with Gensingen brace (GBW) in late adolescent and adult scoliosis patients. In: *Proceedings of the 1st. International Conference on Scoliosis Management on Behalf of the Turkish Scoliosis Society*, April 12-13. Istanbul, Turkey; 2018. p. 19
- [44] Bettany-Saltikov J, Weiss HR, Chockalingam N, et al. Surgical versus non-surgical interventions in people with adolescent idiopathic scoliosis. *Cochrane Database of Systematic Reviews*. 2015;**4**(4):CD010663
- [45] Cheuk DK, Wong V, Wraige E, Baxter P, Cole A. Surgery for scoliosis in duchenne muscular dystrophy. *Cochrane Database of Systematic Reviews*. 2015;**10**(10):CD005375
- [46] Bettany-Saltikov J, Weiss HR, Chockalingam N, Kandasamy G, Arnell T. A comparison of patient-reported outcome measures following different treatment approaches for adolescents with severe idiopathic scoliosis: A systematic review. *Asian Spine Journal*. 2016;**10**(6):1170-1194
- [47] Ward WT, Friel NA, Kenkre TS, Brooks MM, Londino JA, Roach JW.

SRS-22r scores in non-operated adolescent idiopathic scoliosis patients with curves greater than forty degrees. *Spine (Phila Pa 1976)*. 2017;**42**(16):1233-1240

[48] Hawes M. Impact of spine surgery on signs and symptoms of spinal deformity. *Pediatric Rehabilitation*. 2006;**9**(4):318-339

[49] Weiss HR, Goodall D. Rate of complications in scoliosis surgery—A systematic review of the PubMed literature. *Scoliosis*. 2008;**3**:9

[50] Weiss HR, Moramarco M, Moramarco K. Risks and long-term complications of adolescent idiopathic scoliosis surgery vs. non-surgical and natural history outcomes. *Hard Tissue*. 2013;**2**(3):27

[51] Moramarco K. Least potential harm with treatment for adolescent idiopathic scoliosis patients. *Hard Tissue*. 2013;**2**(5):44. Available from: <http://www.oapublishinglondon.com/article/1011>

[52] de Mauroy JC, Lecante C, Barral F, Pourret S. Bracing in adult with scoliosis: Experience in diagnosis and classification from a 15 year prospective study of 739 patients. *Scoliosis and Spinal Disorders*. 2016;**11**(Suppl 2):29. DOI: 10.1186/s13013-016-0090 y

[53] Weiss HR, Turnbull D, Bohr S. Brace treatment for patients with Scheuermann's disease—A review of the literature and first experiences with a new brace design. *Scoliosis*. 2009;**4**:09

[54] Freidel K, Petermann F, Reichel D, Steiner A, Warschburger P, Weiss HR. Quality of life in women with idiopathic. *Spine (Phila Pa 1976)*. 2002;**27**(4):E87-E91

[55] Weiss HR, Seibel S, Kleban A. Deformity-related stress in a sample of patients with adolescent idiopathic

scoliosis after brace weaning: A cross-sectional investigation. *OA Musculoskeletal Medicine*. 2014;**2**(1):5

[56] Danielsson AJ, Hasserijs R, Ohlin A, Nachemson AL. Body appearance and quality of life in adult patients with adolescent idiopathic scoliosis treated with a brace or under observation alone during adolescence. *Spine (Phila Pa 1976)*. 2012;**37**(9):755-762. DOI: 10.1097/BRS.0b013e318231493c

[57] Diarbakerli E, Grauers A, Danielsson A, Gerdhem P. Health-related quality of life in adulthood in untreated and treated individuals with adolescent or juvenile idiopathic scoliosis. *The Journal of Bone and Joint Surgery. American Volume*. 2018;**100**(10):811-817. DOI: 10.2106/JBJS.17.00822

[58] Rigo M. Radiological and cosmetic improvement 2 years after brace weaning—A case report. *Pediatric Rehabilitation*. 2003;**6**(3-4):195-199

[59] Weiss HR, Moramarco M. Remodelling of trunk and backshape deformities in patients with scoliosis using standardized asymmetric computer-aided design/computer-aided manufacturing braces. *Hard Tissue*. 2013;**2**(2):14

[60] Weiss HR. Bracing can lead to a persistent correction in the treatment of adolescent idiopathic scoliosis: A case report. *Hard Tissue*. 2014;**3**(1):8

[61] Weiss HR, Tournavitis N, Seibel S, Kleban A. A prospective cohort study of AIS patients with 40° and more treated with a Gensingen brace (GBW): Preliminary results. *The Open Orthopaedics Journal*. 2017;**11**:1558-1567

[62] Güth V, Abbink F, Götze HG, Heinrichs W. Kinesiologic and electromyographic studies on the effects of the Milwaukee corset. *Zeitschrift*

für Orthopädie und Ihre Grenzgebiete.
1976;**114**(4):480-483

[63] Güth V, Abbink F, Götze HG, Heinrichs W. Investigation of gait of patients with idiopathic scoliosis and the influence of the Milwaukee brace on gait (author's transl). Zeitschrift für Orthopädie und Ihre Grenzgebiete. 1978;**116**(5):631-640

[64] Schmitt NM, Schmitt J, Doren M. The role of physical activity in the prevention of osteoporosis in postmenopausal women-an update. Maturitas. 2009;**63**:34-38

[65] Yu PA, Hsu WH, Hsu WB, et al. The effects of high impact exercise intervention on bone mineral density, physical fitness, and quality of life in postmenopausal women with osteopenia: A retrospective cohort study. Medicine (Baltimore). 2019;**98**(11):e14898. DOI: 10.1097/MD.00000000000014898

[66] Gonzalo-Encabo P, McNeil J, Boyne DJ, Courneya KS, Friedenreich CM. Dose-response effects of exercise on bone mineral density and content in post-menopausal women. Scandinavian Journal of Medicine & Science in Sports. 2019;**29**(8):1121-1129. DOI: 10.1111/sms.13443

[67] Weiss HR. Pain and deformity. In: Moramarco M, Borysov M, Ng SY, Weiss HR, editors. *Schroth's Textbook of Scoliosis and Other Spinal Deformities*. Newcastle Upon Tyne, UK: Cambridge Scholars Publishing Ltd; 2020. pp. 613-628. ISBN: 978-1527538290