

We are IntechOpen, the world's leading publisher of Open Access books Built by scientists, for scientists

6,900

Open access books available

186,000

International authors and editors

200M

Downloads

Our authors are among the

154

Countries delivered to

TOP 1%

most cited scientists

12.2%

Contributors from top 500 universities



WEB OF SCIENCE™

Selection of our books indexed in the Book Citation Index
in Web of Science™ Core Collection (BKCI)

Interested in publishing with us?
Contact book.department@intechopen.com

Numbers displayed above are based on latest data collected.
For more information visit www.intechopen.com



Normal Pressure Hydrocephalus

Ravish Rajiv Keni, Harsh Deora and Amit Agrawal

Abstract

Normal pressure hydrocephalus (NPH) is characterized by dilated ventricles and a combination of gait impairment, cognition impairment, and loss of urinary control (urgency and incontinence). The only effective treatment for NPH is a CSF shunt; however, only a small percentage of patients ever receive it. The features of gait impairment in patients with NPH are difficult to distinguish from patients of neurodegenerative disorders with motor involvement, such as parkinsonism or dementia with Lewy bodies. CT or MRI imaging is required for the diagnosis of idiopathic normal pressure hydrocephalus. An Evans ratio of more than 0.3 indicates large ventricles, and a ratio of more than 0.33 indicates very large ventricles, but is not specific for idiopathic normal pressure hydrocephalus. The international and Japanese guidelines support shunt surgery as effective treatment of idiopathic normal pressure hydrocephalus, as does the American Academy of Neurology practice guideline. There is a need to provide longitudinal care of patients with idiopathic normal pressure hydrocephalus after shunt surgery as all symptoms respond well to shunt surgery.

Keywords: normal pressure hydrocephalus, shunts surgery

1. Introduction

Normal-pressure hydrocephalus (NPH) is the earliest identified cause of dementia which can be potentially treated [1, 2]. NPH was described by Hakim and Adams in 1965, and the entity was characterized by gait disturbances, impaired cognition, and urinary incontinence that is associated with ventricular enlargement without rise in cerebrospinal fluid (CSF) pressure [3, 4]. NPH may be primary or idiopathic NPH (without known precipitating factors) or secondary (due to trauma, hemorrhage, infection, mass lesions, or delayed aqueductal stenosis) [5–7].

2. Epidemiology

The exact incidence and prevalence of INPH is difficult to determine; however, the incidence of INPH is between 1.8 and 2.2 cases per 1,000,000 individuals [8, 9]. In a door to door survey from two German villages, the 0.41% prevalence of NPH was reported [10]. In patients with dementia, the reported incidence of NPH ranges between 1.6 and 5.4% [11, 12].

3. Pathophysiology

There are two main mechanisms involved in the pathogenesis of NPH [13, 14], that is, increased venous resistance and altered production and absorption of CSF. Studies

have found that in patients with NPH, there is reduction in vascular compliance particularly involving superior sagittal sinus. Hakim and Adam's hypothesized [4] that in NPH reduced CSF absorption leads to raised intracranial pressure and over a period leading to compensatory ventricular enlargement. This new intracranial pressure state directs more CSF flow toward the Virchow-Robin spaces and thus into the brain parenchyma [15]. These metabolic and mechanical changes further leads to periventricular damage and raised myelin basic protein (a possible biomarker) elevated in these patients [16]. This leads to tissue compression, white matter ischemia and parenchymal changes characterized by myelin pallor. These changes further lead to periventricular damage, reduced cellular metabolism, clearance of toxins, and their sequel [15, 17]. Studies have shown that following CSF diversion, there is normalization in global brain stiffness and elasticity on magnetic resonance studies [18].

4. Clinical features

The classical clinical triad of INPH includes gait disturbance, dementia, and urinary incontinence [3–6, 8]. These symptoms are typically insidious in onset, and the patients are in their sixth and eighth decades. These changes occur in presence of ventriculomegaly without much evidence of cortical atrophy on brain imaging [2].

5. Gait disturbances

Gait disturbances are the most common initial symptom (present in 90% of the patients) and initially characterized by unsteadiness, frequent falls, slowness of gait, with difficulty initiating and turning, as the disease advances, these transform into magnetic, slow, broad based, and short steps (with preserved arm swing). These gait disturbances are not usually associated with increase in tone, exaggerated reflexes or weakness and usually there is absence of primary sensorimotor deficits, cerebellar dysfunction, or involuntary movements, involving difficulty integrating sensory information about the position of the body in relation to its environment. The impairment should be symmetric unless coexisting musculoskeletal disorders (e.g., knees, hips, and spine) cause asymmetry.

6. Dementia

INPH patients have subcortical frontal dysexecutive syndrome, manifesting as memory impairment, decreased attention, impaired planning, slowness of thought, and apathy. The cognitive findings of NPH reflect involvement of the prefrontal brain structures, similar to a subcortical dementia, with executive dysfunction (e.g., slow processing, and difficulty with problem solving) and memory deficits with poor retrieval and relatively intact recognition memory. Delirium is not typical in NPH and implies the presence of a concomitant disorder or medication side effect.

7. Urinary incontinence

The urological manifestations include frequency, urgency, and urge incontinence. In a series of 41 patients with possible iNPH, 95% patients had urodynamic evidence of detrusor overactivity [12]. Bladder manifestations in NPH have been attributed to the involvement of sacral fibers of corticospinal pathway. Patients

are usually aware of the urinary urge and are concerned about their incontinence. Incontinence without awareness of urinary urge or that one's clothes are wet is not a feature of NPH. Patients or family should be asked about the use of incontinence pads or undergarments, as occasionally they do not consider the patient to be incontinent if the urine is contained by the pads or undergarments. As bladder symptoms are common in elderly patients, other causes are frequently present in patients with suspected NPH.

8. Imaging

The differential diagnosis of NPH other non-treatable causes of dementias and degenerative disorders is extremely for proper selection of potential candidates for CSF diversion. No brain imaging studies are sufficient to diagnose INPH; however ventricular enlargement with appropriate symptoms is necessary to establish a diagnosis of NPH. Combination of imaging modalities and correlation with clinical findings shall help to make a diagnosis of NPH [2]. Evans' index 0.3 or greater suggests significant ventriculomegaly (**Figures 1** and 2) [19]. Other imaging features include:

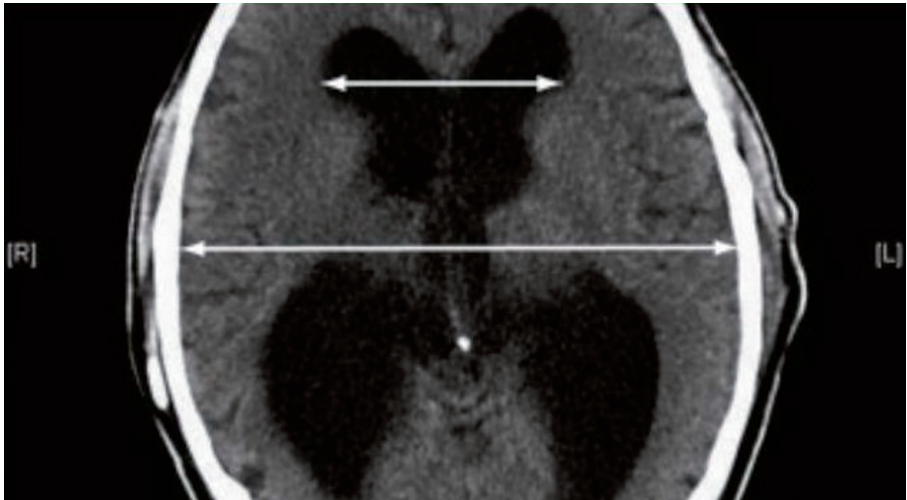


Figure 1.
CT brain of a patient with INPH showing ventriculomegaly without significant cortical atrophy (Evan's index > 0.3).

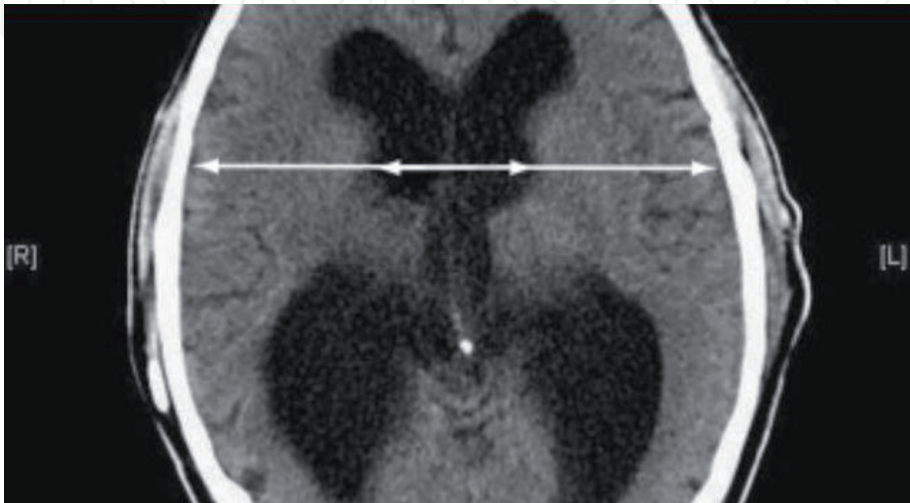


Figure 2.
CT brain of a patient with INPH showing increased bicaudate ratio > 0.25.

- Bicaudate ratio > 0.25
- Enlargement of temporal horn
- Periventricular abnormal signals
- Flow void in aqueduct or fourth ventricle

9. Supportive radiological investigations include

- Radionuclide cisternogram may show delayed clearance.
- Cine MRI can show increased ventricular flow rate
- SPECT-acetazolamide will demonstrate decreased periventricular perfusion which is not reversed with acetazolamide

Distinguishing dilated ventricles due to cerebral atrophy from NPH is difficult [19–22]. Focal atrophy is often indicative of a degenerative dementia, particularly if it is asymmetric (e.g., frontotemporal dementia) or is stereotypical, such as hippocampal atrophy in Alzheimer dementia. In NPH, the Sylvian fissures are disproportionately widened in comparison to the cortical sulci, which are flattened (“high tight” convexity). The appearance of a pulsation artifact in the cerebral aqueduct, or measurements of CSF stroke volume or velocity in the aqueduct using phase – contrast methods cannot be used alone to recommend shunt surgery, but can support the diagnosis of NPH and the need for further testing.

10. Classification of INPH

Based on clinical and radiological features, INPH can be classified into probable, possible, and unlikely categories [19]. Probable criteria include age > 40, symptoms > 3 months, gait disorder, urinary incontinence or dementia, Evan’s index > 0.3, temporal horn enlargement, aqueductal/Fourth ventricle flow void, and callosal angle > 40 [19]. If there is papilloedema, or absence of triad or no ventriculomegaly, the diagnosis of NPH is unlikely [19].

11. Prognostic tests

The tests which are done to ascertain the benefit of surgical intervention in INPH include: lumbar puncture which has a sensitivity of 26%, and specificity of 100%, extended lumbar drainage (sensitivity of 50–80% and specificity of 80%), measurement of CSF outflow resistance measurement (if >18 mm Hg/ml/min than 46% sensitive and 87% specific) and cine phase-contrast MRI (has insufficient evidence).

12. Tap test

In this, 40-50 ml of CSF is removed, and pre- and post-tap with the Gait Scale (walking score + step score + time score) is assessed. The step score is based on the

number of steps required for the patient to walk 10 m. Similarly, pre- and post-tap cognitive function assessed Folstein Mini Mental State Exam and within 2–4 hours after the CSF tap post-tap assessments are conducted. A significant response to the tap test indicates responsiveness to shunt surgery [23]. However, lack of significant response does not exclude shunt responsiveness because the tap test is specific, rather than sensitive. External lumbar drainage can be considered if iNPH is still clinically suspected after a patient has failed to improve after the tap test.

13. External lumbar drainage

In this test, CSF is drained (10 to 15 cc per hour) for 72 hours and patient is assessed before and after the drainage (positive predictive value 90% and negative predictive value 78%). Positive ELD indicates good benefit with shunt. Negative ELD indicates low risk-benefit ratio. Neuropsychological testing before and after external lumbar drainage may also be helpful. Most publications have cited 72 hours of CSF drainage, although some centers drain CSF for shorter periods [19, 20]. This test has the risk of headache, lumbar radiculopathy, and risk of meningitis.

14. CSF infusion testing

Infusion testing for assessment of CSF hydrodynamics is commonly used in Europe to diagnose NPH, but is rarely used in the United States or Canada. In CSF infusion test, Ringer lactate is infused via one spinal needle and a second needle simultaneously records CSF pressure. One of the most consistent findings in NPH research is that patients have an increased resistance to outflow.

15. ICP monitoring

The recordings in NPH reveal wave-form abnormalities similar to those originally described for brain tumor or acute injury, (i.e., B waves and A waves). The presence of unstable ICP (predominantly B waves) in NPH is well known, and the correlation with NPH shunt responsiveness ranges from 50 to 90%. Recently, analysis of the amplitudes of the ICP pulse pressure has been pro-posed as a predictive test in NPH.

16. Practice guidelines

If the CSF pressure is high, the patient should be investigated for other causes of obstructive hydrocephalus. If there is improvement of the patient after a 40 to 50-mL (high-volume) lumbar tap that the patient will likely respond well to shunting. An external ventricular drainage may be used in patients who fail to respond to a high-volume tap. Currently, there is no substantial evidence to support predictive-ness to MRI CSF flow studies [19, 20].

17. Treatment

Treatment includes conservative measures and surgery for patients with favorable risk benefit ratio. Temporizing measures include acetazolamide and high volume tap. As per practice guidelines, surgery is considered for patients

with favorable risk benefit ratio. Age alone is not an exclusionary criterion unless there are other surgical risk factors. Surgical options for the management of INPH include ventriculoperitoneal shunt and endoscopic third ventriculostomy. Literature favors low pressure programmable ventriculo peritoneal shunt as both over and under drainage can be managed in non-invasive manner. Endoscopic third ventriculostomy is indicated in patients with relative aqueduct stenosis and when there is triventricular hydrocephalus. Gangemi et al. reported 72% improvement with 4% complications rate [24].

18. Follow up after shunt surgery

Patients who have had shunt surgery should have periodic follow-up visits. The follow-up of patients with a shunt is similar to the follow-up of patients with parkinsonism or other chronic neurologic disorders. The interval history should cover all three NPH symptoms of gait impairment, incontinence, and dementia. The neurologic examination should include cognitive screening (e.g., MMSE), gait evaluation, and a general neurologic examination. Imaging may be done to rule out over-drainage, such as subdural effusion or hematoma, particularly in the first 6–12 months after shunt surgery until it is determined that the patient's condition and the appearance of the scan are stable. In most instances, a CT scan without contrast suffices. The setting of adjustable shunts should be confirmed during the follow-up visit, provided the neurologist has the device appropriate for the patient's shunt. Depending on the degree of symptomatic recovery and presence or absence of low-pressure signs and symptoms, the shunt setting can be raised or lowered in increments [25]. If there is suspicion regarding patency of the shunt radionuclide, shunt patency test can determine the flow of radionuclide in the peritoneal cavity or the venous system (for ventriculoatrial shunts) [25].

19. Conclusion

NPH common, treatable disorder can be reliably diagnosed with an organized approach by most neurosurgeons and neurologists. Evidence supports the use of shunt surgery to treat patients with NPH, and when patients are properly selected, the benefit-to-risk ratio is favorable. Neurologists have a role in the longitudinal care of patients with NPH who have undergone shunt surgery, particularly in considering the differential diagnosis of any symptoms that may worsen after shunt surgery. Regular follow up and high index of suspicion is paramount.

IntechOpen

Author details

Ravish Rajiv Keni¹, Harsh Deora² and Amit Agrawal^{3*}

1 Department of Neurology, Narayana Medical College and Hospital,
Nellore, Andhra Pradesh, India

2 Department of Neurosurgery, NIMHANS, Bangalore, India

3 Department of Neurosurgery, All India Institute of Medical Sciences, Bhopal,
Madhya Pradesh, India

*Address all correspondence to: dramitagrawal@gmail.com

IntechOpen

© 2020 The Author(s). Licensee IntechOpen. This chapter is distributed under the terms of the Creative Commons Attribution License (<http://creativecommons.org/licenses/by/3.0>), which permits unrestricted use, distribution, and reproduction in any medium, provided the original work is properly cited. 

References

- [1] Conn HO. Normal pressure hydrocephalus: New complications and concepts. *Practical Neurology*. 2007;7(4):252-258
- [2] Kiefer M, Unterberg A. The differential diagnosis and treatment of normal-pressure hydrocephalus. *Deutsches Ärzteblatt International*. 2012;109(1-2):15-25
- [3] Adams RD, Fisher CM, Hakim S, Ojemann RG, Sweet WH. Symptomatic occult hydrocephalus with normal cerebrospinal-fluid pressure. *The New England Journal of Medicine*. 1965;273(3):117-126
- [4] Hakim S, Adams RD. The special clinical problem of symptomatic hydrocephalus with normal cerebrospinal fluid pressure. Observations on cerebrospinal fluid hydrodynamics. *Journal of the Neurological Sciences*. 1965;2(4):307-327
- [5] Beyerl B, Black PM. Posttraumatic hydrocephalus. *Neurosurgery*. 1984;15(2):257-261
- [6] Hebb AO, Cusimano MD. Idiopathic normal pressure hydrocephalus: A systematic review of diagnosis and outcome. *Neurosurgery*. 2001;49(5):1166-1184
- [7] Shprecher D, Schwalb J, Kurlan R. Normal pressure hydrocephalus: Diagnosis and treatment. *Current Neurology and Neuroscience Reports*. 2008;8(5):371-376
- [8] Krauss JK, Halve B. Normal pressure hydrocephalus: Survey on contemporary diagnostic algorithms and therapeutic decision-making in clinical practice. *Acta Neurochirurgica*. 2004;146(4):379-388
- [9] Vanneste J, Augustijn P, Dirven C, Tan WF, Goedhart ZD. Shunting normal-pressure hydrocephalus: Do the benefits outweigh the risks? A multicenter study and literature review. *Neurology*. 1992;42(1):54-59
- [10] Trenkwalder C, Schwarz J, Gebhard J, Ruland D, Trenkwalder P, Hense HW, et al. Starnberg trial on epidemiology of Parkinsonism and hypertension in the elderly. Prevalence of Parkinson's disease and related disorders assessed by a door-to-door survey of inhabitants older than 65 years. *Archives of Neurology*. 1995;52(10):1017-1022
- [11] Beck JC, Benson DF, Scheibel AB, Spar JE, Rubenstein LZ. Dementia in the elderly: The silent epidemic. *Annals of Internal Medicine*. 1982;97(2):231-241
- [12] Clarfield AM. The reversible dementias: Do they reverse? *Annals of Internal Medicine*. 1988;109(6):476-486
- [13] Tarkowski E, Tullberg M, Fredman P, Wikkelso C. Normal pressure hydrocephalus triggers intrathecal production of TNF-alpha. *Neurobiology of Aging*. 2003;24(5):707-714
- [14] Bateman GA. Vascular compliance in normal pressure hydrocephalus. *AJNR. American Journal of Neuroradiology*. 2000;21(9):1574-1585
- [15] Nassar BR, Lippa CF. Idiopathic normal pressure hydrocephalus: A review for general practitioners. *Gerontology and Geriatric Medicine*. 2016;2:2333721416643702
- [16] Pyykko OT, Lumela M, Rummukainen J, Nerg O, Seppala TT, Herukka SK, et al. Cerebrospinal fluid biomarker and brain biopsy findings in idiopathic normal pressure hydrocephalus. *PLoS One*. 2014;9(3):e91974
- [17] Silverberg GD, Mayo M, Saul T, Rubenstein E, McGuire D. Alzheimer's disease, normal-pressure hydrocephalus,

and senescent changes in CSF circulatory physiology: A hypothesis. *The Lancet Neurology*. 2003;2(8):506-511

[18] Freimann FB, Streitberger K-J, Klatt D, Lin K, McLaughlin J, Braun J, et al. Alteration of brain viscoelasticity after shunt treatment in normal pressure hydrocephalus. *Neuroradiology*. 2012;54(3):189-196

[19] Relkin N, Marmarou A, Klinge P, Bergsneider M, Black PM. Diagnosing idiopathic normal-pressure hydrocephalus. *Neurosurgery*. 2005;57(3 Suppl):S4-S16

[20] Marmarou A, Bergsneider M, Klinge P, Relkin N, Black PM. The value of supplemental prognostic tests for the preoperative assessment of idiopathic normal-pressure hydrocephalus. *Neurosurgery*. 2005;57(3 Suppl):S17-S28

[21] Silverberg GD. Normal pressure hydrocephalus (NPH): Ischaemia, CSF stagnation or both. *Brain*. 2004;127 (Pt 5):947-948

[22] Ishikawa M, Hashimoto M, Kuwana N, Mori E, Miyake H, Wachi A, et al. Guidelines for management of idiopathic normal pressure hydrocephalus. *Neurologia Medico-Chirurgica*. 2008;48:S1-S23

[23] Boon AJ, Tans JT, Delwel EJ, Egeler-Peerdeman SM, Hanlo PW, Wurzer HA, et al. Dutch Normal-Pressure Hydrocephalus Study: randomized comparison of low- and medium-pressure shunts. *Journal of Neurosurgery*. 1998;88(3):490-495

[24] Gangemi M, Maiuri F, Buonamassa S, Colella G, de Divitiis E. Endoscopic third ventriculostomy in idiopathic normal pressure hydrocephalus. *Neurosurgery*. 2004;55(1):129-134

[25] Williams MA, Malm J. Diagnosis and treatment of idiopathic normal pressure hydrocephalus. *Continuum*. 2016;22(2 Dementia):579-599