

We are IntechOpen, the world's leading publisher of Open Access books Built by scientists, for scientists

6,900

Open access books available

185,000

International authors and editors

200M

Downloads

Our authors are among the

154

Countries delivered to

TOP 1%

most cited scientists

12.2%

Contributors from top 500 universities



WEB OF SCIENCE™

Selection of our books indexed in the Book Citation Index
in Web of Science™ Core Collection (BKCI)

Interested in publishing with us?
Contact book.department@intechopen.com

Numbers displayed above are based on latest data collected.
For more information visit www.intechopen.com



Diagnosis and Treatment Plan for Gingival Diseases and Conditions

Anahita Punj and Manav Chaturvedi

Abstract

The prevalence of gingival and periodontal disease is manifold and has not been highlighted much due to its asymptomatic and milder symptoms. It is usually given its due importance when the gingival disease progresses to advanced periodontal disease, displays symptoms of dull pain and tooth mobility, and is associated with pus discharge. The starting point of periodontal disease is usually gingival disease which is a reversible condition. It is therefore necessary to diagnose gingival diseases at an early stage to prevent its progression to irreversible periodontal disease. The diagnosis of gingival disease becomes cumbersome due to its similarity in the presentation of signs and symptoms. Gingival diseases can occur due to microbial attack from the plaque biofilm which is usually bacterial in nature. There are other viral, fungal, and immune-mediated mechanisms which can result in gingival diseases. Some systemic conditions also influence the gingiva which allows for diagnosing systemic diseases and treating these conditions appropriately. It is said that oral cavity is the mirror of the body, and in that sense the gingiva is the biggest surface where any changes or manifestations could be observed.

Keywords: gingivitis, gingival disease, diagnosis, treatment

1. Introduction

The gingiva or commonly referred to as gums surround and protect the teeth (**Figure 1**). Gingival diseases by namesake denote to the diseases affecting the gingival tissues. These diseases have burdened the human race since the early civilization, and this is proof enough to gauge the importance of diagnosing gingival diseases and treating them. Gingival disease if left untreated can progress to periodontal tissues and result in periodontal disease which is easier to diagnose probably due to its chronic and severe nature as compared to gingival disease. No wonder periodontal disease has been mentioned in the literature of ancient Egypt and a step toward preventing it by means of oral hygiene practices deserves its mention in the ancient scriptures [1].

2. Gingival disease terminology

The gingival disease terminology and classification has undergone many changes, and the current classification given at the World Workshop in 2017

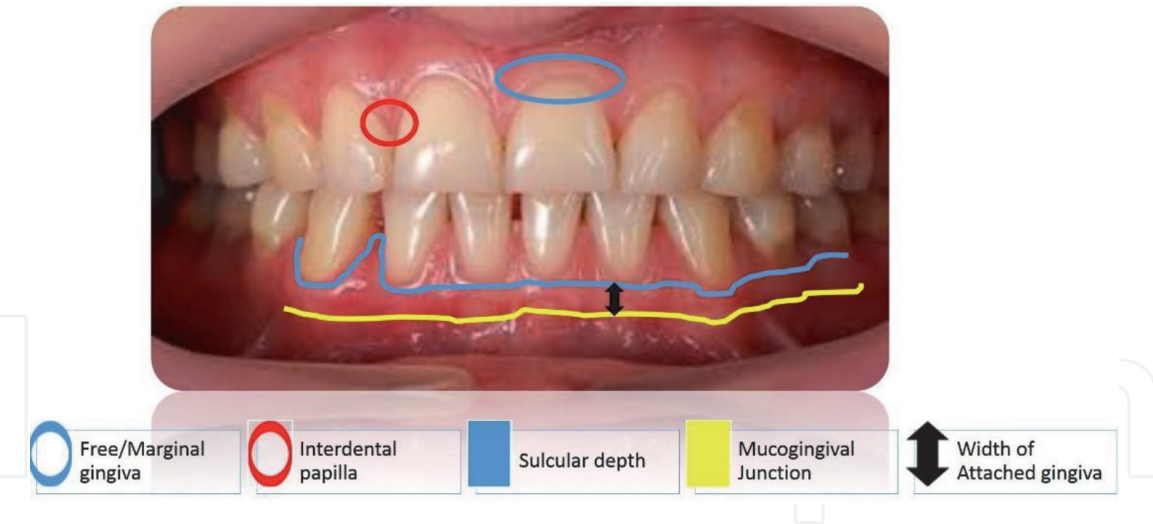


Figure 1. The diagnosis of any disease is based on a proper documentation of case history which requires precise identification of signs and symptoms of disease and also any underlying medical disease/condition which may influence the same. The next step is to correlate clinical, pathological, laboratory and radiological findings. This sequence of steps also holds true for gingival diseases. This chapter attempts to focus on the minute differences in the diagnosis of gingival diseases which becomes cumbersome due to a simple fact that any infection or inflammation usually results in swelling up of the gingiva, bleeding, or formation of ulcers or vesicles. Such symptoms could be due to a single to multiple etiologic agents corresponding to varied diagnoses and treatment regimens [2].

classifies gingival condition in health and disease under three broad categories of health, dental biofilm-induced gingivitis, and non-dental biofilm-induced gingival disease [3] (Table 1).

Periodontal health and gingival health		Dental biofilm-induced gingivitis			Non-dental biofilm-induced gingival disease
Clinical gingival health on an intact periodontium	Clinical gingival health on a reduced periodontium	Associated only with dental biofilm	Mediated by systemic or local risk factors	Drug-influenced gingival enlargement	Genetic/development disorders
	Stable periodontitis	Non-periodontitis			Specific infections and inflammatory and immune conditions
					Reactive processes
					Neoplasms
					Endocrine, nutritional, and metabolic diseases
					Traumatic lesions
					Gingival pigmentation

Table 1. Classification of periodontal health, gingival disease, and condition [3].

2.1 Diagnosis of plaque-induced gingivitis

Gingivitis per se refers to the inflammation of the gingival tissues and is labeled with different diagnostic terms based on the etiology and clinical presentation to aid in formulation of the best-suited treatment. As mentioned above, the broad etiologic factors which result in gingival disease is the dental biofilm, which contain microbes, causing a microbial attack on the gingiva resulting in a dysbiosis amounting to a host response manifested in the form of the inflammatory disease called plaque-induced gingivitis. The plaque microbes have an influence on the gingiva depending upon its quantity and quality of pathogens present. Although the increased plaque burden is almost always associated with gingivitis, there are instances where paucity of plaque can again result in gingivitis due to the effect of modifying factors which make the host response more accentuated and exaggerated as they tend to have a more systemic affect than a local one [2, 4]. These modifying factors include few systemic conditions, factors which increase plaque accumulation and influence of drugs on gingiva. How these factors can affect gingivitis is summarized in **Table 2**.

Factor	Effect on gingiva	Signs and symptoms for diagnosis	Diagnosis	Treatment [5]
Bacterial dental biofilm only	Microbial attack mounts a host response in the form of inflammation	Mild redness with or without broken line of bleeding	Incipient gingivitis	OHI
		Mild changes in color and texture of the gingiva	Mild gingivitis	OHI +/-OP
		Glazing redness, edema, enlargement, bleeding on probing	Moderate gingivitis	OHI + OP
			Overt redness and edema and bleeding on palpation rather on probing	Severe gingivitis
Potential modifying factors of plaque-induced gingivitis				
Systemic conditions				
Sex steroid hormones (estrogen and progesterone) (1) Puberty	Exaggerate the host inflammatory response in the presence of minimal plaque	Bleeding on probing or bleeding with toothbrushing, mild to moderate redness	Diagnostic term not given as not seen frequently in population and if present can be diagnosed as gingivitis associated with puberty	OHI + OP
(2) Menstrual cycle	Exaggerates the host inflammatory response in the presence of minimal plaque	Mild redness, edema based on severity of inflammation seen during the menstrual cycle	Diagnostic term not given as not seen frequently in population and if present can be diagnosed as gingivitis	

Factor	Effect on gingiva	Signs and symptoms for diagnosis	Diagnosis	Treatment [5]
			associated with menstrual cycle	
(3) Pregnancy	The hormones exaggerate the host inflammatory response in the presence of minimal plaque	Deep gingival probing depths, bleeding on probing or bleeding with toothbrushing, and elevated gingival crevicular fluid flow in pregnancy	Pregnancy-associated gingivitis	
(4) Oral contraceptives	The high-dose hormones in the pills exaggerate the host inflammatory response in the presence of minimal plaque; low dose does not have much effect	Mild redness, edema based on severity of inflammation seen after 1 to 3 months of use	Currently the dose of oral contraceptives is low; hence diagnostic terms have been removed	OHI + OP + reduction of high-dose oral contraceptive Low-dose contraceptive does not require any change
Hyperglycemia	High blood glucose levels increase the pathogenic bacteria and also form more AGE which affect collagen turnover and healing	Signs of inflammation of gingivitis + high blood glucose levels	Gingivitis associated with diabetes mellitus	OHI + OP + maintenance of blood glucose levels by diet restriction/ exercise/ medication
Leukemia	Increases number of WBCs which accumulate in the gingival tissues and decreases number of platelets which causes bleeding	Cervical lymphadenopathy, petechiae, ulcers seen in the mucosa, bleeding on slight provocation, swollen, glazed, spongy gingiva, red to deep purple color of gingival lesions	Gingivitis associated with acute/chronic leukemia	Treat leukemia + symptomatic treatment for gingivitis with careful OHI and OP to prevent excessive bleeding
Smoking	Direct smoking can cause vasoconstriction of gingival vasculature	No redness, edema, or swelling present. Color may change to blue and pale pink. No gingival changes and pocket depths increase when lesions progress to periodontitis	No gingivitis	Smoking cessation
Malnutrition	Deficiency of vitamin C affects crosslinking of collagen	Bleeding on probing, mobility, and swollen gums in severe cases with minimal plaque	Scurvy	Vitamin C supplementation + OHI + OP
Oral factors enhancing plaque accumulation				

Factor	Effect on gingiva	Signs and symptoms for diagnosis	Diagnosis	Treatment [5]
Prominent subgingival restoration margins	Roughness and closeness of these restorations to gingival tissue cause accumulation of plaque bacteria and irritation	Localized mild redness, bleeding on probing, slight edema in area of restoration	Gingivitis due to faulty restoration	Correction of restoration + OHI + SRP
Hyposalivation	Decreased saliva causes sticking of bacteria on tooth surfaces	Dental caries, taste changes, halitosis, mucosal and gingival dryness, and gingival inflammation	Gingivitis associated with hyposalivation	OHI + OP+ salivary substitutes
Drug-influenced gingival enlargements				
Phenytoin, sodium valproate	Drugs and plaque cause fibroblasts to increase production of collagen and extracellular connective tissue	Onset after 3 months of drug intake, common in anterior gingiva, gingival size increases which starts from interdental papilla and may extend to the margin and attached gingiva in severe cases. The enlarged areas are firm to soft depending upon the presence of gingival inflammation	Drug-influenced mild gingival enlargement (if only papilla is involved) Drug-influenced mild gingival enlargement (if papilla and margin is involved) Drug-influenced mild gingival enlargement (if papilla, margin, and attached gingiva is involved)	OHI + OP+ drug substitution if required, followed by gingivectomy to correct enlarged gingival tissues
Nifedipine, amlodipine, verapamil, diltiazem, felodipine				
Cyclosporine				
OHI, oral hygiene instruction, OP, oral prophylaxis.				

Table 2.
Diagnosis based on etiology, modifying factors, and clinical features [2, 4].

2.2 Tools used for gingival diagnosis

The crude tools used are a questionnaire/interview to collect important aspects of the patient demographics, medical history, current medications, and habits. The next step involves patient examination starting from extraoral structures to any abnormal intraoral findings to specific examination of the gingiva. The gingival disease is visually examined for clinical signs and symptoms using a mouth mirror under ambient lighting of the dental chair, cotton/gauze to dry the tissues, and sometimes the use of three-way air water syringe to wash way the debris for better inspection. Changes in color, contour, consistency, texture, size, position, etc. are

Advanced diagnostic aid for gingival disease	Mechanism/working	Inference
Periotemp probe	Detects the difference in subgingival temperature which is reflected by red or green light	Red light indicates future periodontal breakdown and increase in periopathogens
New generation of periodontal probes	First-generation	Detects pocket depth using traditional probes
	Second-generation	Pressure-sensitive probe with uniform pressure
	Third-generation	Pressure-sensitive and captures data on computer
	Fourth-generation	Uses 3D technology to detect pocket
	Fifth-generation	Uses 3D technology and ultrasound to detect pocket
Advances in radiography	Use of charged-coupled device, complementary metal oxide semiconductor, and cone beam-computed tomography allow digital recording	These are used to detect bone loss and bone defects in 2D and 3D for periodontal defects rather than gingival diseases
Advances in microbial culturing	High-performance liquid chromatography	Can detect bacterial cell wall components
	Flow cytometry	Can detect various bacteria
	Latex agglutination test	Can detect pathogenic antigen, proteins, and antibody by agglutination reaction
	Direct and indirect immunofluorescence	Can detect pathogenic antigen, proteins, and antibody by agglutination and adding fluorescent dyes
	Enzyme-linked immunosorbent assay	Evalusite can detect <i>P. gingivalis</i> , <i>P. intermedia</i> , and <i>A. actinomycetemcomitans</i>
	Nucleic acid and DNA checkerboard hybridization techniques	Detects microbes based on matching of unknown sample with known hybridization technique of nuclei acid/ DNA
	DNA probe	Omnigene can detect <i>P. gingivalis</i> , <i>P. intermedia</i> , <i>A. actinomycetemcomitans</i> , <i>E. corrodens</i> , <i>C. rectus</i> , <i>F. nucleatum</i>
	Perioscan uses BANA (N-benzoyl-DL arginine naphthylamide) hydrolysis carried out by trypsin-like protease	Detects trypsin-like protease releasing bacteria, such as <i>P. gingivalis</i> , <i>T. denticola</i> , and <i>T. forsythus</i>
	IAI Pado Test 4.5 RNA probe test kit uses oligonucleotide probes complementary to conserve fragments of the 16S rRNA gene that encodes the rRNA	Detects <i>A. actinomycetemcomitans</i> , <i>P. gingivalis</i> , <i>Tannerella forsythia</i> , and <i>T. denticola</i>
Advances in biochemical test kits	MyPerioPath is a DNA test and uses saliva samples	To identify the type and concentration of periodontal bacteria
	Perio-Check	Detects neutral proteases like collagenases in GCF (gingival crevicular fluid)

Advanced diagnostic aid for gingival disease	Mechanism/working	Inference
	Prognos-Stik: detects serine proteinase elastase in GCF	Shows active disease sites
	PocketWatch: detects aspartate aminotransferase in GCF	Differentiates active and non-active sites of disease
	PerioGard: detects aspartate aminotransferase in GCF	Differentiates active and non-active sites of disease
	Perio 2000: detects volatile sulfur compounds	To detect halitosis
	Toxicity prescreening assay (TOPAS)	Detects bacterial toxins and proteins
	Dipstick	Detects (matrix metalloproteinase) MMP-8 in GCF
	Integrated microfluidic platform for oral diagnostics (IMPOD)	Saliva-based detection of MMP-8
	Oral fluid nanosensor test (OFNASET): saliva-based detection of (interleukin) IL-1, IL-8	Used for detection of salivary biomarkers for oral cancer
	Electronic taste chip (ETC)	Detects C-reactive protein which is an important biomarker for inflammation
Genetic tests	Genetic periodontitis susceptibility trait (PST) test	Detects IL-1 polymorphism
	MyPerioID	Saliva-based detection of genetic susceptibility

Table 3.
Diagnostic tools for gingival disease [5, 6].

noted. This is followed by palpation of the gingiva for any spontaneous bleeding, pain, discharge, blanching, consistency (by checking the resiliency of tissues on applying pressure), and pitting edema. The UNC-15 or the Michigan O periodontal probe with William’s marking is used to check for bleeding on probing, subgingival faulty restorative margins, and the presence of deeper than 5-mm pockets which is the critical probing depth to differentiate between gingivitis and periodontitis. Apart from these traditional tools used, advanced diagnostic aids have been introduced to further confirm the presence of gingival disease (**Table 3**) [5, 6].

2.3 Diagnosis of non-plaque-induced gingival diseases

Apart from plaque-induced gingivitis, it is imperative to diagnose and differentiate the non-plaque-induced gingival diseases and conditions to provide appropriate treatment and to avoid overtreatment. The etiology of non-plaque-associated gingival disease is usually related to some genetic defect or systemic disorder. In many instances the oral lesions precede the extraoral findings and can help in diagnosing a disease which could affect the full body. Therefore, while diagnosing these conditions, we need to look for other associated conditions to arrive at a correct diagnosis. **Table 4** attempts to highlight the clinical features to help arrive at a diagnosis [7–11].

C	Cr	Cs	T	S	P	L	Lab & H/P	Add Sym	D	Rx
G	Flat or rounded	Firm and resilient	Loss of stippling	++	Coronal to CEJ	Gingival enlargement	Excisional biopsy shows fibrous connective tissue		Hereditary gingival fibromatosis	Gingivectomy to contour the topography + OHI
P-R/B-Br	Blunted	Soft and friable	Ulcerative	--	Varies from papillary destruction to beyond mucogingival junction	Gingival ulceration	Bacterial culture for various bacteria types such as <i>Treponema</i> , <i>Selenomonas</i> , <i>Fusobacterium</i> , and <i>Prevotella intermedia</i> . H/P Loss of the epithelium in ulcerated areas	Loss of taste, woody sensation in teeth and feeling of extruded teeth accompanied with underlying risk factors such as poor oral hygiene and systemic conditions	Necrotizing periodontal disease	Debridement of local factors + CHX+ amoxicillin and metronidazole
FR/W	No change	Soft and edematous	Ulcerative/white pseudomembranous	+	No change	Erythematous	Bacterial culture for <i>Neisseria gonorrhoeae</i>	Pharyngitis and lymphadenopathy. Other sites: urethra, anus, cervix, oral mucosa	Gonorrhea	Systemic antibiotic therapy
FR	No change	Edematous	Loss of stippling and ulceration with whitish membrane	+	No change	Chancre (rare)	Bacterial culture for <i>Treponema pallidum</i> , followed by serologic reaction tests	Genital and skin lesions	Syphilis	Systemic antibiotic therapy
R-Gy patches	No change	Firm	Nodular/papillary proliferation	+	No change	Nodular/papillary proliferation	Positive delayed hypersensitivity (tuberculin) skin reaction to purified protein derivative (ppd), isolation of mycobacterial antigen from bacterial cultures, and demonstration of acid-fast mycobacteria in clinical specimens. H/P: characteristic multinucleated giant cells	Commonly associated with lung infections. Involves floor of the mouth, extraction sites, and lymph nodes	Tuberculosis	Regimens of multiple antibiotics like isoniazid, rifampicin, pyrazinamide, or ethambutol

C	Cr	Cs	T	S	P	L	Lab & H/P	Add Sym	D	Rx
							and granulomas are diagnostic features			
RP	Rounded	Soft	Erythematous patch				Culture for streptococcal strains. Biopsy	Upper respiratory infections	Streptococcal gingivitis	OHI+ antibiotics
RP	No change	Soft and ulcerative	Small vesicles/ fibrinous coated ulcer	–	Blunted papilla sometimes	Painful ulcers after vesicle rupture		Skin lesions, low-grade fever	Hand, foot and mouth disease	Supportive treatment to correct fever and pain
RP	Flat and rounded	Soft and edematous	Ulcerated, loss of stippling	+	Coronal or apical to CEJ			Lymphadenitis, fever, malaise	Primary herpetic gingivostomatitis	Acyclovir and spirin/ paracetamol, fluids. Dyclonine hydrochloride 0.5% for anesthesia
RP	Flat and rounded	Soft and edematous	Ulcerated	+	Attached gingival and hard palate		Rarely required. If needed fluorescent staining is more sensitive. HSV isolation of a virus in tissue. Culture is the most positive method of identification. Scraping made from the base of the lesion and stained with giemsa. H/P: Wright's or Papanicolaou stain and shows syncytium and ballooning. Degeneration of the nucleus	Fever	Recurrent intraoral herpes simplex	Acyclovir and aspirin/ paracetamol, fluids. Dyclonine hydrochloride 0.5% for anesthesia
BR	No change	Soft	Vesicular	+/-	Diffuse erythema and isolated small vesicles that rupture quickly leaving ulcerations	Lesions on skin and mucosa	Fluorescent-antibody staining of smears using fluorescein-conjugated monoclonal antibodies is more reliable than routine cytology	Fever, malaise, and skin rash	Chicken pox (Varicella)	Acyclovir/valacyclovir for healing and reducing acute pain. Systemic corticosteroids to prevent postherpetic neuralgia, combination of

C	Cr	Cs	T	S	P	L	Lab & H/P	Add Sym	D	Rx
										intralesional steroids and local anesthetics to decrease healing time and prevent postherpetic neuralgia and application of capsaicin
R patches +W halo	Blunt or rounded	Soft and friable	Ulcerated	—	Unilateral vesicles which rupture	Necrosis of periodontium and alveolar bone	Culture	Skin lesion	Shingles (herpes zoster)	Oral acyclovir 800 mg five times a day, famciclovir 500 mg three times a day, or valacyclovir 500 mg three times a day
Pi	No change	Soft	Papules	++	Raised nodular or popular lesions	Mucosal lesions are rare		Discrete papules on skin of face and trunk and in genital areas	<i>Molluscum contagiosum</i> virus	Cryotherapy/laser
G	No change	Firm	Exophytic and verrucous	++		Exophytic papillomatous, verrucous or flat lesions			Squamous cell papilloma, condyloma acuminatum, verruca vulgaris, focal epithelial hyperplasia	Surgical removal, laser ablation, cryotherapy, and topical application of keratinolytic agents. For smaller lesions, topical application of 25% podophyllum resin to reduce the size. Intralesional injection of interferon- α 1,000,000 iu/cm ² once weekly and subcutaneous injections 3,000,000 iu/cm ² twice weekly

C	Cr	Cs	T	S	P	L	Lab & H/P	Add Sym	D	Rx
W-R	No change	Soft and resilient	Scrapable lesion	+/-		Pseudomembrane/ erythematous/plaque-like/ nodular	H/P: culture of infected tissues or exudates on Sabouraud's dextrose agar or other appropriate media	Oral involvement is secondary to serious systemic infection	Candidiasis	Topical antifungal medications, nystatin, and amphotericin b
BR	Rounded	Soft and friable	Chronic vegetating painful ulcer	++		Nodular, papillary, or granulomatous lesions	Biopsy of infected tissue shows small oval yeasts within macrophages and reticuloendothelial cells as well as chronic granulomas, epithelioid cells, giant cells, and occasionally caseation necrosis	Cavitation of the lung and dissemination of the organism to the liver, spleen, adrenal glands, and meninges	Histoplasmosis	Ketoconazole or itraconazole for 6–12 months
RP	Violaceous marginal gingiva in early stage	Soft and friable	Necrosis and covered with pseudomembrane in advanced cases	--		Lesions are necrotic and covered by pseudomembrane		Systemic involvement is present. Late stage involves destruction of alveolar bone and facial muscles	Aspergillosis	Systemic antifungals
R+ W streaks	Normal	Soft	Lichenoid reaction	No change		Lichenoid-like reaction	Patch test by placing aluminum disks with known allergens for 48 hours on hairless skin and wait for any inflammation as a positive test. H/P: chronic inflammatory reaction with lichenoid infiltration of lymphocytes		Contact allergy	Topical corticosteroids

C	Cr	Cs	T	S	P	L	Lab & H/P	Add Sym	D	Rx
R			Velvety texture	+	Seen in anterior maxillary gingiva		Plasma cells in lamina propria		Plasma cell gingivitis	Topical corticosteroids
R-W		Soft and friable	Smooth or disrupted	—		Round lesion with central red area or pale pink surrounded by red periphery	Biopsy an epidermal pattern characterized by lichenoid vasculitis and intraepidermal vesicles and a dermal pattern characterized by lymphocytic vasculitis and subepidermal vesiculation	Skin lesions symmetrically present on distal extremities and moving proximally Hand, face, elbow and knees	Erythema multiforme	Anesthetic mouthwash, corticosteroids in severe cases, and acyclovir if associated with HSV
RP-W	Normal	Soft and friable	Smooth and loss of stippling	No change	Lesions on free and attached gingiva	Desquamative gingivitis with vesiculobullous lesions which rupture	ELISA to detect circulating antibody to desmoglein 1 and 3. Histopathology: suprabasilar acantholysis may be observed	Bullous lesions on skin	Pemphigus vulgaris	Prednisolone usually given in dosages of 1–2 mg/kg/d and later —
R area	Normal	Soft	Smooth and loss of stippling	—	Positive Nikolsky sign: rubbing the gingiva forms bulla	Desquamative lesions with bulla formation	Histopathology: circulating antibodies not always found by indirect immunofluorescence	Scarring in ocular lesions	Pemphigoid	Systemic corticosteroids
R-W streaks	Normal	Soft and resilient	Smooth and ulcerative	No change		Papular, reticular, plaque type or bullous lesions	Hyperkeratosis and saw tooth-shaped rete pegs	Skin lesions	Lichen planus	Topical corticosteroids or intralesional steroids like 0.05% fluocinonide (Lidex) and 0.05% clobetasol (temovate)
R and W striae			Smooth and ulcerative	–/+		Central atrophic area with small white dots surrounded by white striae	Hyperorthokeratosis with keratotic plugs, atrophy of the rete ridges, and liquefactive	Red butterfly-shaped photosensitive, scaly, macules on	Lupus erythematosus	Systemic immunosuppressant and protection from sunlight

C	Cr	Cs	T	S	P	L	Lab & H/P	Add Sym	D	Rx
							degeneration of the basal celllayer	the nose bridge and cheeks		
Pl	Normal	Soft		++		Cobblestone appearance of mucosa and linear ulceration	Histopathology	Intestinal pain, anal fissures, diarrhea, and labial enlargement	Crohn's disease	Steroids and immunosuppressants to decrease progression
RP		Soft and friable	Loss of stippling	++	Gingival recession	Nodules and ulceration. Loosening of teeth	Hyperglobulinemia, an elevated level of serum angiotensin-converting enzyme, evidence of depressed cellular immunity. H/P: noncaseating epithelioid granulomas in more than one organ system	Swelling of salivary glands	Sarcoidosis	Systemic steroids and anti-inflammatory agents
Pi	Normal	Fibrous	Smooth	+		Exophytic smooth masses	H/P: bundles of collagen covered with the epithelium		Fibrous epulis	Excision and curettage
RP	Normal	Fibrous	Smooth	++	Start from interdental papilla	Pedunculated to sessile masses	H/P: cellular fibroblastic tissue containing rounded or lobulated masses of calcified cementum-like tissue		Calcifying fibroblastic granuloma	Excision of lesion
RP				+		Ulcerated, smooth, and pedunculated mass	H/P: discontinuous hyperplastic parakeratinized stratified squamous epithelium and endothelial cells in the connective tissue		Pyogenic granuloma	Excision of lesion

C	Cr	Cs	T	S	P	L	Lab & H/P	Add Sym	D	Rx
Pr-BI-Br		Soft		++		Sessile or pedunculated tumor-like process	H/P: multinucleated giant cell forming granuloma		Peripheral giant cell granuloma	Surgical excision
W		Corrugated or verrucous surface		+		Non-removable white spot	Tissue biopsy. Vital staining with toluidine blue and cytobrush techniques. H/P: dysplastic cells with ++ hyperchromatic nuclei, cellular and nuclear pleomorphism, an ++ nucleocytoplasmic ratio, and generalized loss of cellular polarity and orientation	History of tobacco/ alcohol intake	Leukoplakia	Surgical excision/ cryosurgery and laser ablation
R		Velvety		+		Sharply demarcated from surrounding mucosa	Same as above	May be associated with oral lichen planus	Erythroplakia	Same as above
R- W patches	No change	Soft	Smooth	++	Involve keratinized gingiva	Painless exophytic mass with nonhealing ulceration	Dysplastic changes seen in the epithelium and extending into connective tissue and the presence of keratin pearls	History of tobacco/ alcohol intake	Squamous cell carcinoma	Surgical removal, chemotherapy
RP	No change	Soft and edematous	Smooth	++		Pallor of oral mucosa, pain, petechiae, ecchymosis, gingival bleeding, deep punched out ulcers	Blood investigation. Bone marrow biopsy. Tooth mobility	Dysphagia, facial paralysis, paraesthesia of the face, lips, tongue, and chin, trismus sometimes	Leukemia	Monitoring of the patient for infection during neutropenic periods and early management of infection. Corticosteroids, adrenocorticotropin, or testosterone modulates the sharp reduction in marrow function. Granulocyte colony-

C	Cr	Cs	T	S	P	L	Lab & H/P	Add Sym	D	Rx
P	Rounded	Soft	Smooth	++			Histopathology will show Reed-Sternberg cells	Swollen lymph nodes	Lymphoma	stimulating factor (G-CSF) Radiation and chemotherapy plus doxorubicin, bleomycin, vincristine, and dacarbazine for Hodgkin's lymphoma and cyclophosphamide, vincristine, and prednisone for non-Hodgkin's
W plaques	No change	Soft	Loss of stippling	+	Seen on facial attached gingiva	Leukoplakia-like asymptomatic plaque	H/P: dense fibrous connective tissue		Frictional keratosis	Prevention of deleterious habits
RP	No change	Soft and friable		—	Gingival recession	Superficial and horizontal gingival laceration	Not much significant		Toothbrushing-induced gingival ulceration	Changing the brushing technique
R-W				—		Surface slough or ulceration	Not much significant		Chemical insult due to etching, chlorhexidine, hydrogen peroxide, acetylsalicylic acid, dentifrice, detergent, calcium hydroxide, etc.	Removal of offending irritant
R				—		Erythematous lesion that slough a coagulated surface, vesicles and ulceration may be present	Not of much significance		Burns of mucosa	Supportive care and hydration

C	Cr	Cs	T	S	P	L	Lab & H/P	Add Sym	D	Rx
Br-Bl	No change	No change	No change	=			Pigmented deposits in the epithelium and connective tissue	Addison's disease, Albright syndrome, Peutz-Jeghers syndrome	Gingival pigmentation	Not required
Br	No change	Firm	No change	=	Mandibular facial gingiva		H/P: pigmented macules seen in section		Smoker's melanosis	Smoking cessation for 2 weeks
Bl-Gy-Br-Bl	No change	No change	No change	=		Diffuse pigmentation			Drug-induced pigmentation (antimalarial, minocycline)	Cessation of drug if required
Bl-Gy-Br-Bl	No change	No change	No change	=			H/P: discrete granules in connective tissue		Amalgam tattoo	Removal of amalgam debris and replacement of amalgam if required

C, color; Cr, contour; Cs, consistency; T, texture; S, size; P, position; L, lesion; lab and H/P, laboratory procedures and histopathology; add sym, additional symptoms; D, diagnosis; Rx, treatment; FR, fiery red; G, same as surrounding gingiva; W, white; PR, pink to reddish; B-Br, black to brown; R-Gy, red to gray; RP, reddish pink; BR, bright red; Pi, pink; Pl, pale pink; Pr, purple; Bl, blue; OHI, oral hygiene instruction; CHX, chlorhexidine; +, slightly increased; ++, increased; -, slightly decreased; --, decreased; -/+, may increase or decrease; =, remains the same.

Table 4.
Clinical features for diagnosis and treatment of non-plaque-induced gingival diseases.

3. Treatment of gingival disease

The treatment of gingival disease is based on resolving the etiologic factors and maintaining the systemic status of the individual. In the case of plaque-induced gingivitis, the main treatment plan involves removal of plaque and calculus by scaling and root planning, followed by oral hygiene instruction which includes modified bass method of brushing and the use of chemical plaque control agents like 0.2% or 0.02% chlorhexidine gluconate or essential oil mouthwash. In cases of gingival enlargement, initial therapy is focused on removing plaque and calculus, followed by a review on the gingival condition; only if the condition does not improve the drug substitution may be considered, followed by gingivectomy to remove the enlarged gingival tissue. Plaque-induced gingival disease influenced by modifying factors is controlled by reducing the exposure of the modifying factor in addition to removal of plaque and calculus to maintain oral hygiene. The details of the treatment have been mentioned in **Table 2**. Non-plaque-induced gingival diseases are treated depending on the etiology of the gingival disease. For example, viral lesions are treated by providing antiviral medications in addition to oral hygiene instruction. The details of treatment in brief are mentioned in **Table 4**. Diagnosis is essential for providing the proper treatment plan and updating recent research which might help prevent undue treatment [8].

4. Conclusions

Gingival diseases are an initial starting point of the advanced periodontal disease and in some cases depict the manifestation of an underlying undiagnosed systemic condition. Therefore, the early diagnosis of gingival disease and its treatment are warranted.

Conflict of interest

The authors declare no conflict of interest.

Author details


Anahita Punj^{1*} and Manav Chaturvedi²

¹ Department of Periodontics, Army College of Dental Sciences, Secunderabad, India

² Partha Dental, Hyderabad, India

*Address all correspondence to: anahitapunj@gmail.com

IntechOpen

© 2020 The Author(s). Licensee IntechOpen. This chapter is distributed under the terms of the Creative Commons Attribution License (<http://creativecommons.org/licenses/by/3.0>), which permits unrestricted use, distribution, and reproduction in any medium, provided the original work is properly cited. 

References

- [1] Newman MG, Takei HH, Klokkevold PR, Carranza FA. Newman and Carranza's Clinical Periodontology. 13th ed. Philadelphia: Elsevier Saunders; 2019. pp. 55-79
- [2] Newman MG, Takei HH, Klokkevold PR, Carranza FA. Newman and Carranza's Clinical Periodontology. 13th ed. Philadelphia: Elsevier Saunders; 2019. pp. 248-302
- [3] Caton J, Armitage G, Berglundh T, et al. A new classification scheme for periodontal and periimplant diseases and conditions—Introduction and key changes from the 1999 classification. *Journal of Clinical Periodontology*. 2018; **45**(Suppl 20):S1-S8. DOI: 10.1111/jcpe.12935
- [4] Chapple ILC. Dental plaque-induced gingival conditions. *Journal of Clinical Periodontology*. 2018; **45**(Suppl 20): S17-S27. DOI: 10.1111/jcpe.12937
- [5] Newman MG, Takei HH, Klokkevold PR, Carranza FA. Newman and Carranza's Clinical Periodontology. 13th ed. Philadelphia: Elsevier Saunders; 2019. pp. 378-396
- [6] Mani A, Anarthe R, Marawar PP, Mustilwar RG, Bhosale A. Diagnostic kits: An aid to periodontal diagnosis. *Journal of Dental Research and Review*. 2016; **3**:107-113
- [7] Holmstrup P, Plemons J, Meyle J. Non-plaque-induced gingival diseases. *Journal of Clinical Periodontology*. 2018; **45**(Suppl 20):S28-S43. DOI: 10.1111/jcpe.12938
- [8] Greenberg MS, Glick M. Burket's Oral Medicine Diagnosis & Treatment. 10th ed. Ontario: BC Decker Inc; 2003. pp. 50-118
- [9] Greenberg MS, Glick M. Burket's Oral Medicine Diagnosis & Treatment. 10th ed. Ontario: BC Decker Inc; 2003. pp. 441-490
- [10] Greenberg MS, Glick M. Burket's Oral Medicine Diagnosis & Treatment. 10th ed. Ontario: BC Decker Inc; 2003. pp. 552-555
- [11] Pundir A, Farista S, Afroz SA. Calcifying fibroblastic granuloma—A rare case report. *International Journal of Scientific and Research Publications*. 2013; **3**:1-3