

We are IntechOpen, the world's leading publisher of Open Access books Built by scientists, for scientists

6,900

Open access books available

186,000

International authors and editors

200M

Downloads

Our authors are among the

154

Countries delivered to

TOP 1%

most cited scientists

12.2%

Contributors from top 500 universities



WEB OF SCIENCE™

Selection of our books indexed in the Book Citation Index
in Web of Science™ Core Collection (BKCI)

Interested in publishing with us?
Contact book.department@intechopen.com

Numbers displayed above are based on latest data collected.
For more information visit www.intechopen.com



Posture and Back Shape Measurement Tools: A Narrative Literature Review

Gok Kandasamy, Josette Bettany-Saltikov and Paul van Schaik

Abstract

The clinical assessment of spinal deformities often involves the assessment of posture and back shape together with the associated mobility of the spine, pelvis and rib cage. Currently, there is a wide range of posture and back shape assessment tools available for clinical use. The choice varies from conventional approach to advanced structured light methods. The advanced methods like ultrasound, 3D radiography and inertial sensors are not easily accessible to most clinicians, as they are either expensive, require specialist training or are complex and/or difficult to use. Thus, simple conventional methods like eyeballing, photography and the plumb line are still used within clinical practice today. The primary aim of this article is to give an overview of different tactile and non-tactile measurement systems that have been developed for the measurement of posture and whole-body analysis.

Keywords: posture, back shape, tactile, non-tactile, objective, whole body

1. Background

The term ‘spinal deformity’ indicates the abnormal alignment or shape of the vertebral column and rib cage. Schwab et al. identifies the most common spinal deformities found in the population are scoliosis, lumbar lordoscoliosis, pelvic obliquity and either increased or decreased lumbar lordosis, with a high prevalence rate of 68% [1]. These spinal deformities are often linked to a range of different types of pain, physical dysfunction and psychosocial wellbeing [2–5]. The clinical assessment of these spinal deformities often involves the assessment of posture and back shape together with the associated mobility of the spine, pelvis and rib-cage. Currently, there are a wide range of posture and back shape assessment tools available for clinical use. The choice varies from conventional approaches to advanced structured light methods. The advanced methods like ultrasound [6], 3D radiography [7] and inertial sensors [8] are not easily accessible for most clinicians, as they were either expensive, require specialist training or are complex or difficult to use. Thus, simple conventional methods like “eyeballing” photography [9] and the plumb line [10] are still used within clinical practice.

A comprehensive literature review was undertaken firstly to search and retrieve research papers related to the tools and scientific methods for assessing posture and back shape and secondly to critique which methods were best for assessing posture

and back shape with regard to their cost, safety, reliability, validity, ease of use and duration. The primary research question for the current narrative review was 'what are the different types of tactile and non-tactile measurement systems, for the measurement of posture and whole-body analysis in adults with spinal disorders?'. And the secondary research question is related to the critical evaluation of assessment methods in terms of cost, safety, reliability and validity of the tools.

2. Methods

2.1 Search strategy

A comprehensive literature search was performed in the following databases, PubMed, EMBASE, Scopus, CINAHL, Medline and Science Direct, for articles on posture and back shape from 1980 to 2017. The search keywords were 'posture', 'back shape', 'spinal mobility', 'postural assessment', 'back surface measurement', 'postural alignment', 'posture' and 'reproducibility', 'posture' and 'reliability', 'posture' and 'accuracy', 'posture' and 'validity', 'posture' and 'spinal pain' and 'posture' and 'low back pain'. The author also combined each human body segment with 'posture' as keywords, 'head posture', 'neck posture', 'cervical posture', 'thoracic posture', 'trunk posture', 'lumbar posture', 'shoulder posture', 'arm posture', 'upper limb posture' and 'lower limb posture'. In addition, the author searched for related articles from references cited in the articles identified from the original search. The search was limited to articles only written in English. No wildcards were used in this study.

2.2 Criteria for inclusion and exclusion

All articles that assessed posture and back shape were considered in order to identify all possible methods for the evaluation of posture. Reviews of postural assessment and articles that discussed posture in some manner that could help the discussion were also included. Letters to the editor and conference proceedings were excluded.

3. Data collection and analysis

The titles, keywords and abstracts of all research articles identified during the search were read to confirm whether they satisfied the inclusion criteria. Full text copies of all articles that met the inclusion criteria were obtained for analysis and data extraction. Preference was given to recent reviews on posture and back shape assessment and research papers on new or unusual forms of postural evaluation. Older articles with the same information contained in newer ones were excluded.

4. Results and discussion

The author identified 66 articles representing 15 principal instruments that are currently used to assess posture and back shape (please refer to the PRISMA diagram in **Figure 1**). These included tactile, non-tactile, two-dimensional as well as three-dimensional (3D) methods. Tactile measurement methods are defined as methods used to measure posture or back shape through contact, for example, the flexiruler and goniometry, whereas non-tactile measurement methods measure

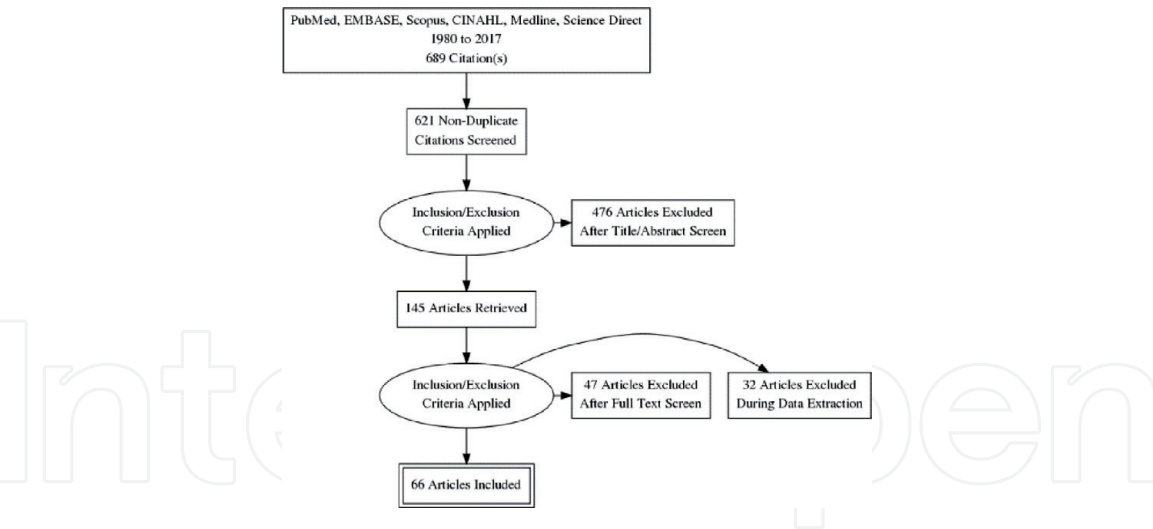


Figure 1.
PRISMA flow diagram of literature search and selection process.

posture and back shape without any direct contact to the skin by the operator. These included, for example, X-rays and photogrammetric methods. The literature primarily documented the reliability and validity of each postural measurement tool in normal individuals including a few patients with spinal deformities. Each method is described and critiqued below.

4.1 Two-dimensional analysis of posture and back shape

4.1.1 Tactile methods of measurement

4.1.1.1 Flexiruler

The flexiruler for the evaluation of posture is common for clinical and research purposes [11, 12]. This objective method of postural measurement requires the manual placement of the flexiruler onto the contours or curvatures of the spine followed by the tracing and calculation of these angles onto paper (see **Figure 2A** and **B**).

Greenfield et al. [13] used a flexiruler to measure the mid-thoracic curvature, while Rheault et al. [14] observed the inter-rater reliability of the flexiruler for measuring cervical lordosis in two different positions (neutral and fully flexed) in 20

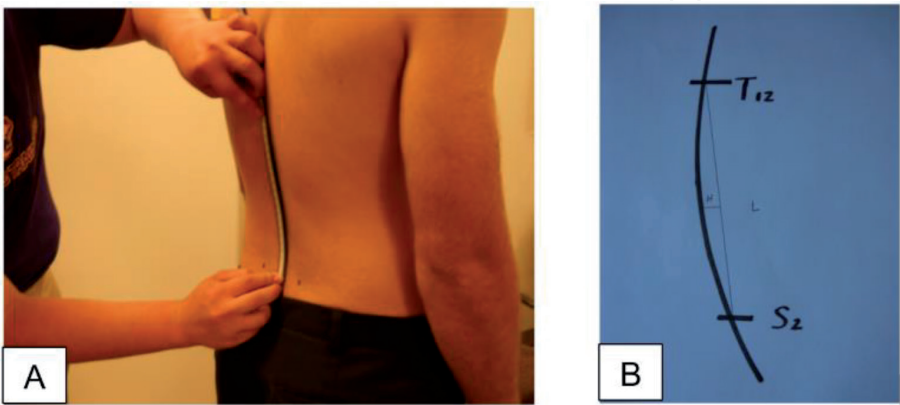


Figure 2.
An example of the flexiruler method (A) data collection and (B) measurement of lumbar lordosis based on the captured data [15].

healthy subjects [13, 14]. In both studies, the flexiruler was placed on the curvature of the spine, with its tip at the most proximal part of the curvature and the other end at the distal end of the spine.

Following the measurement of the spine, the flexiruler was placed on a paper, to trace its curve. Greenfield et al. [13] reported good to moderate Pearson correlation for intrarater ($r = 0.90$) and interrater reliability ($r = 0.70$). Furthermore Rheault et al. [14] reported no significant difference between raters ($t = 1.24$; $p > 0.05$) at the two different positions of the cervical spine. The results of both Greenfield et al. and Rheault et al. studies suggest that the flexible ruler is a reliable measuring tool between raters for measuring sagittal plane curvature.

Concerning validity, many researchers have demonstrated a high correlation between radiographic and surface measurements for measuring the lumbar spine curvature [16, 17]. For example, Hart and Rose [18] compared the angles of the curve taken with a flexible ruler to the angle obtained by the standard roentgenographic technique and found good validity with the Pearson product moment correlation of $+0.87$. Burton further substantiated the result by reporting a correlation of $+0.87$ for the validity of the flexible ruler in comparison to the radiographic method for measuring lumbar lordosis [16]. Even though the above studies demonstrated good validity, the main limitation was that the results were based on a very low sample size ($n = 8$). In addition, the measurement of postural variables through a flexiruler is always two-dimensional. The presentation of spinal curvature is not necessary always two-dimensional. There is a possibility of the deviation of curvature being in more than one plane. In this scenario, the obtained spinal curvature angle might not represent the real degree.

It is important to note that most of the above studies reported their results based on the data collected from young normal healthy participants. Although the use of the flexible ruler is important for this population, there is a possibility that the flexible ruler may be more difficult to use for patients with pain, disease, or postural deformity. Other limitations of this method of postural assessment are the following. Firstly, it is difficult for patients to maintain one position during data collection. Secondly, the literature reports only one measurement plane (sagittal). It is difficult to measure both the frontal and the transverse plane posture variables. Third, this method of postural assessment has a high possibility of manual error during data collection and angle measurement [19].

4.1.1.2 Goniometry

In clinical practice, goniometers are commonly used to measure joint range of motion (ROM) [20]. Icn et al. reported the use of a goniometer for the assessment of a number of posture variables [21]. This method of direct body measurement used a goniometer to quantify posture variables with a value from zero to 360 degrees. The results of their study demonstrated moderate correlation ($r = 0.47$) to measure the tibiotarsal angle, knee flexion/extension angle, quadriceps angle as well as the sub-talar angle in relation to photogrammetry.

Conversely, Harrison et al. reported poor interrater reliability when using manual goniometry for the measurement of sagittal postural angles in the neck inclination angle (craniovertebral angle) and cranial rotation (sagittal head tilt) (see **Figure 3**) [22]. The ICC measures were found to be $r = 0.68$ and $r = 0.34$ for the cervical rotation angle and neck inclination angle, respectively. The authors attributed the poor results to the difficulty in maintaining the arm of the goniometer parallel with the horizontal axis.

Fortin et al. ([9], pp. 381-382) suggest that the main limitation for this type of individual measurement of postural variables is the lengthy evaluation process

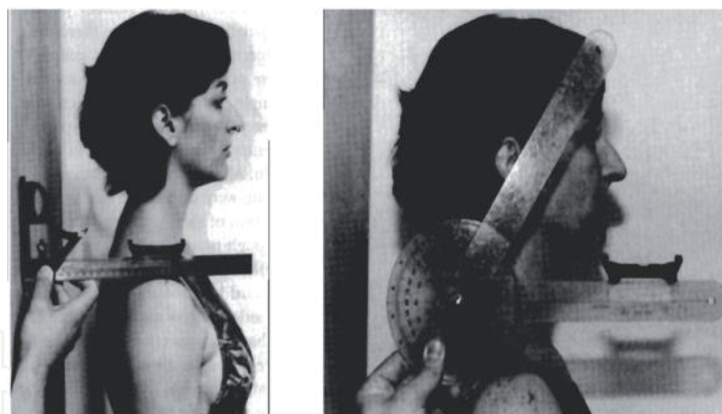


Figure 3.
 Measurement of shoulder and neck inclination angle using goniometer (reproduced from Harrison et al. [22]).

involved for both the therapist and the patient. The author states that ‘this approach may be appropriate for the assessment of one body segment or a variable, but not for the whole body or posture’.

4.1.2 Non-tactile methods of measurement

4.1.2.1 Plumb line method

The two-dimensional evaluation of posture, using a plumb line, is very common, due to its low-cost and simplicity [23]. Kendall et al. postulated guidelines to evaluate posture in accordance with the alignment of the ideal plumb line for the measurement of the sagittal and frontal planes [24]. Kendall et al. state that the ideal alignment of sagittal plane posture is when the plumb line intersects the ear lobe, through the shoulder joint; then through the greater trochanter of the hip, just in front of the knee joint; and finally slightly in front of the lateral malleolus of the ankle before it reaches the floor. Williams and McClay reported that the plumb line method had a good intra-rater reliability for measuring postural variables with an average ICC of 0.80 in both 10 and 90% of body weight bearing scenarios in standing [10]. The standard error of the mean (SEM) reported was between 2 and 5 mm for the lower limb indices and from 5 to 10 mm for patients with a trunk list or lateral shift. List is defined as ‘the lateral displacement, in millimetres, of a surface marking of the spinous processes of T12 from that of S1’ (McKenzie and May [25], p. 214). Furthermore, Hickey et al. evaluated the reliability of using the plumb line to measure resting head posture in a large sample size of 122 healthy volunteers (80 women and 42 men, ages 18–60 years) [26]. In this study, all participants were screened for cranial, cervical and/or upper thoracic dysfunction. The results of this study demonstrated the plumb line method to have high intra-rater reliability with ICCs ranging from 0.83 to 0.84 for the measurement of resting head posture. Although the plumb line method has been reported to have good intra-rater reliability and is a useful and easy to use instrument for measuring posture, its limitations include the difficulty of minimising movement error or postural sway [9, 27]. Additionally, this plumb line method only measures one plane.

4.1.2.2 Radiography

Schwab et al. considers the radiographic method of spinal screening to be the traditional and “gold standard” method for the assessment and screening of

patients with spinal deformities [28]. Furthermore, Schwab et al. suggests that radiography is an essential tool for the accurate diagnoses of spinal abnormalities/deformities and accurately reveals the degree and severity of the problem [29].

In this method, an X-ray image is captured when a beam of X-ray light is passed through the spine and the amount of radiation emerging on the other side is recorded. Since the bones of the spine absorb the radiation and soft tissues allow it to pass through, a clear image of the spine is captured. McVey et al. suggests that the captured radiographic image provides essential information on spinal bone structure, which can be used to analyse individual vertebrae and the overall contour of the spine [30].

In addition to the assessment of spinal curvature, X-rays are also used to record and monitor the progression of spinal deformities and dysfunction [31, 32]. Therefore, in adolescent patients it is performed every few months in order to detect any changes in the progression of the spinal deformity.

The main drawback of the radiographic method of spinal assessment is associated with the increased radiation that has been found to increase the incidence of cancer in later years [33, 34]. Doody et al. in their retrospective cohort study estimated the carcinogenic risk and the patterns in breast cancer mortality among female patients with scoliosis [35]. This study included a large sample size (5,573 female patients with scoliosis, or abnormal curves). The results suggested that due to the high exposure to cumulative x-ray radiation of 10.8 cGy (from childhood to adolescence), breast cancer risk increased by 70%. Similarly, Beir in his review, reported that the exposure to radiation during periods of rapid growth, potentially amplified the deleterious biological effects [36].

Due to its high cost and risk of exposure towards harmful radiation, studies by van Niekerk et al. and Kiliç et al., recommended using alternative non-invasive methods for the assessment and screening of postural variables [37, 38]. In the next section, photogrammetry tools, together with methods to analyse postural variables are discussed. As stated by Furlanetto et al., the simplicity and convenience, has made the photogrammetry method very popular among clinical practitioners [39].

4.1.2.3 Photogrammetric method

In the last two decades, the photogrammetric method of postural evaluation and its applicability has been widely reported in the literature [9, 39]. Low-cost, quantitative evaluation together with its use in reducing the exposure to radiation, makes this method much more feasible for healthcare practitioners to use within their clinical practice. The following research studies have assessed the reliability, and validity of photogrammetry together and its application in different scenarios. Souza et al. and Fortin et al. have proposed a number of diverse photographic methods for evaluating postural variables and conducting postural diagnosis [9, 40]. Several authors [41, 42] have reported the use of photographic methods for the quantification together with the reliability of measuring postural variables. Santos et al. (2009) reported good to excellent inter-rater reliability (interclass correlation coefficient [ICC] values were between 0.84 and 0.99) for the photographic measurement of 33 postural variables in standing in 122 normal healthy children aged 7–10 years [41].

However, Souza et al. in their study on measuring 20 postural variables found mixed results. The ICC values for inter and intra-rater reliabilities for trunk and hip angle were found out to be 0.62 (p value was 0.12) and 0.56 (p value was 0.43) respectively. The level of reliability of these two angles was thus classified

as not acceptable. The ICC values for lower leg postural variables (bilateral hind foot angle) ranged from 0.74 to 0.86 ($p < 0.05$). This level of reliability was classified as good and acceptable. The interrater reliability for the remaining sixteen posture angles reported excellent ICC values (greater than 0.90). Except for the trunk and hip angles, the rest of the sixteen variables yielded non-repeatable intra-rater values. The authors of this study concluded that frontal-view postural variables, such as the alignment of the head, trunk and lower limbs, measured using the photography method were reliable for measuring various postural asymmetries.

Although numerous studies [9, 43, 44] have reported the photogrammetric method of posture analysis, the most common limitation is the inconsistency used in the data collection procedure. For example, the distance between the subject and the placement of the camera varied between studies. The body segment length increases or decreases depending on how close the camera is to the surface of the human body. Additionally, from 2D photographic methods, it is very difficult to study deformities which have a rotational component in the transverse plane [9, 45]. Similarly, in the sagittal plane, there is a possibility that the muscle mass of the erector spinae can obscure the median furrow of the back surface; thereby it is very difficult to study the true spinal curvature [46].

In summary, two-dimensional spinal assessment tools do not provide a complete description of the three-dimensional nature of the back and other spinal deformities. To obtain the detailed three-dimensional description of spinal deformities together with the information of the 3D back surface, various three-dimensional surface and posture measurements tools have been reported in recent years. In the following section, three-dimensional measurement systems (both tactile and non-tactile methods) have been used to assess posture and back shape variables. These are reviewed below.

4.2 Three-dimensional analysis of posture and back shape

In the last decade, three-dimensional analysis of posture and back shape has not only developed significantly, but its use in both the spinal research and clinical environment has also been extended to include both tactile and non-tactile instruments, which will be discussed below.

4.2.1 Tactile tools of measurement of spinal curvature

4.2.1.1 Posturometer-S

The Posturometer-S is a specially designed, electronic, objective, non-invasive body posture measuring device [47] (see **Figure 4**). This tool consists of three coupled systems: 'P' which is a pointer to indicate the position of a measured point (mechanical), an element to compute the position of the pointer in a three-dimensional space (electronic) and an 'informatique' which is used to analyse the results obtained. This system not only enables a practitioner to visualise the curvature of the spine in all three planes but also provides a quantitative description of the postural parameters.

Previous research [47, 48] has demonstrated not only the reliability of the posturometer but also its applicability in the assessment of posture in different age groups. Lichota et al. using the Posturometer-S examined the postures of 46 athletes who were aged between 20 and 24 years [49]. A total of four sports groups were examined, namely, handball ($n = 16$), athletics ($n = 9$), taekwondo ($n = 5$) and

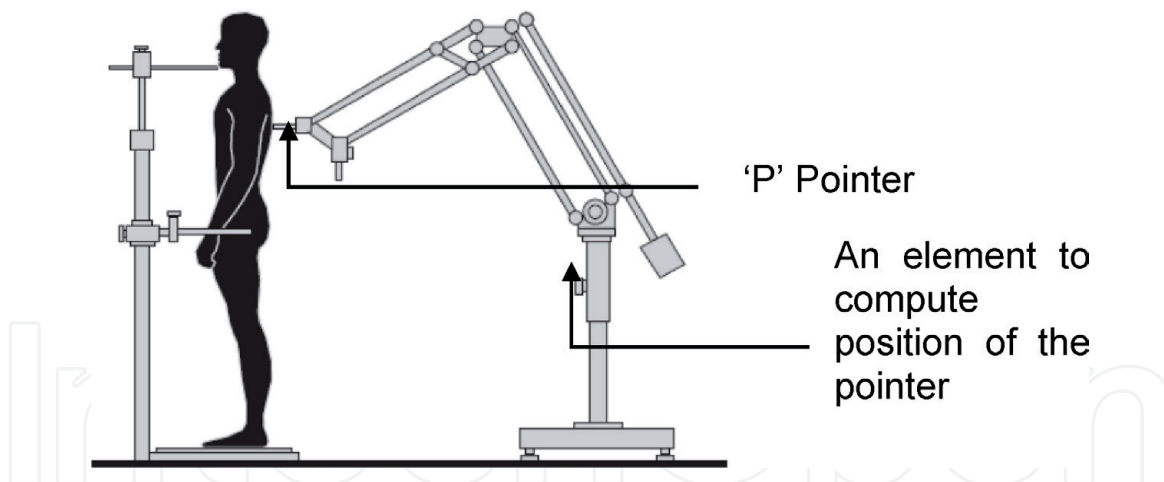


Figure 4.
Schema of Posturometer-S device (source: Stachoń et al. [47]).

volleyball ($n = 13$). In this study, the 'Posturometer-S' was used to describe various angles of the spine, for example, lumbar lordosis, thoracic kyphosis, upper thoracic segment (α angle), the thoracolumbar segment (β angle) and the lumbosacral segment (γ angle). The highest values for α angle, β angle and γ angle were reported in volleyball (15.2°), athletics (12.6°) and taekwondo (14.0°) groups, respectively. The lowest values for the α angle, β angle and γ angle were observed in athletics (12.4°), handball (8.8°) and handball (8.0°) groups, respectively. The authors contended that posture was affected by the specific type of sports training and that the type of sport influenced the type of posture. The main limitation the authors reported in the study was that the Posturometer-S was not user-friendly, consumes more space in the room and requires a thorough understanding of the equipment together with training before it can be used.

4.2.1.2 Ultrasound

Cheung et al. demonstrated the use of a radiation-free three-dimensional ultrasound system for the assessment of spinal curvature in 29 scoliosis patients [6]. Similarly, Kowalski et al. used an ultrasound-based volume projection imaging method to compare the lumbar lordosis and thoracic kyphosis angle in patients with scoliosis as well as normal subjects or other people with spinal disorders [50]. In this volume projection imaging method, the 3D representation of the spinal anatomy was generated using the ultrasound images together with the corresponding 3D spatial information (see **Figure 5**). The structure of the spine anatomy was reconstructed from image data ranging from 16 to 96 MB in size [6]. The results of this feasibility study showed good intra- and interrater reliability with ICCs larger than 0.92 ($p < 0.001$). The results also showed that the spinal curvature obtained by the new method had a good linear correlation with the X-ray Cobb method ($r^2 = 0.8$; $p < 0.001$).

Although these results suggest that the ultrasound volume projection imaging method can be a promising approach for the assessment of spinal deformity, there were still a number of factors that contributed to errors. For example, the ultrasound system and its data were susceptible to the distortion of the electromagnetic field, leading to a system offset/counteract or transient jitter in the spatial and orientation data. Therefore, precaution must be taken especially if the supporting frame is made of metal. The additional limitations of using the ultrasound volume projection imaging method were as follows: (a) heavy to carry around,

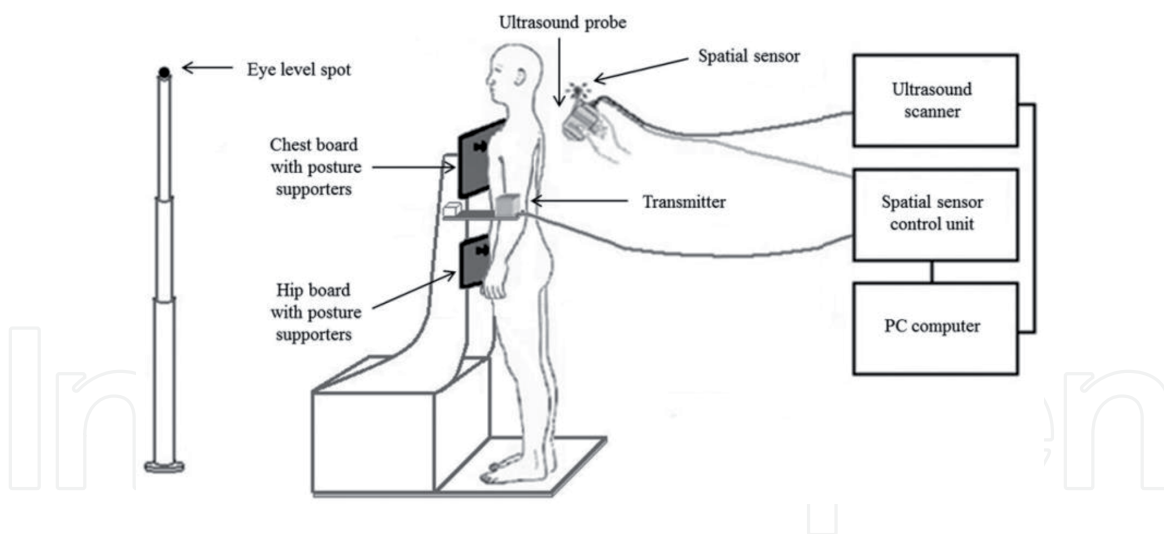


Figure 5.
 Illustration of 3-D ultrasound system for the measurement of spinal deformity [6].

(b) expensive, (c) relatively dependent on the skilled operator [51, 52], (d) only measures the spinal curvature and not the whole back and (d) time-consuming for the assessment of the whole spine. Therefore, this suggests that it is not an appropriate tool for clinical practice.

In summary, the main disadvantage of all tactile posture measurement systems is the error produced due to electromagnetic and patient interference during data acquisition process. This is because it is difficult for patients to maintain a static standing position for a long time.

4.2.2 Non-tactile tools of measurement of spinal curvature

In the following section, non-surface measuring systems, such as 3D radiographic imaging systems and inertial measuring units, will be discussed. This is followed by various surface measurement tools, such as Moiré topography, integrated shape imaging system, laser triangulator system and the Kinect sensor system.

4.2.2.1 Non-surface measuring systems

4.2.2.1.1 3D radiographic imaging

Cheriet et al. demonstrated the use of biplanar X-ray images for the reconstruction of the three-dimensional spine and rib cage [7]. These images are useful in evaluating patients with spinal deformities like scoliosis. In this method, the reconstruction of images is based on a direct linear transformation technique (DLT), which requires the explicit calibration of an object with known 3D coordinates (see **Figure 6**). This method produced accurate 3D reconstruction of six manually identified anatomical landmarks per vertebra (centres of superior and inferior vertebral endplates and the tips of both pedicles). Similarly, the absolute differences between the Cobb angle obtained with the standard DLT and the explicit calibration methods were as low as $0.3 \pm 0.42^\circ$. The absolute differences of the frontal and sagittal balance were $0.15 \pm 0.15^\circ$ and $0.37 \pm 0.25^\circ$, respectively.

Using 3D X-rays for clinical or research purposes has the same motion and radiation issues as the use of 2D X-rays. Additionally, most of these tools are complex to set up, are heavy and only can be applied in laboratory environments.

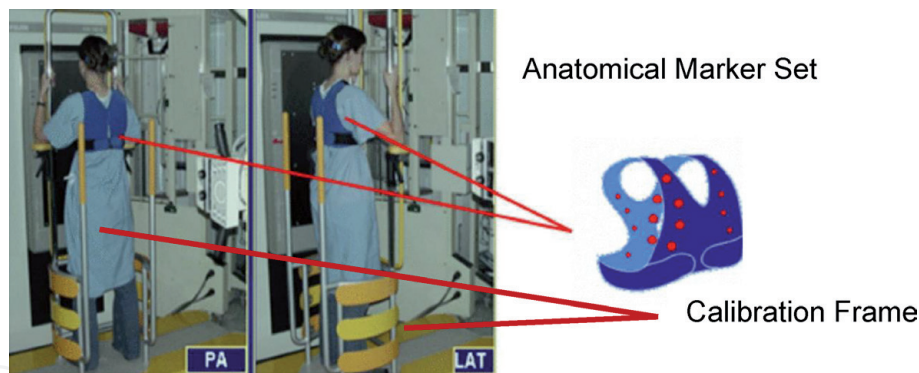


Figure 6. Biplanar X-ray (posterior anterior (PA) and lateral view) acquisition system with calibration apparatus (Cheriet et al. [7]).

4.2.2.2 Inertial sensors

The recent advancement and application of electronic systems and sensors, namely, accelerometers, gyroscopes, flexible angular sensors, electromagnetic tracking systems and sensing fabrics, have enhanced the quality of clinical practice. Godfrey [53] and Fathi [8] all reported the use of sensors in the evaluation of human posture. The following section reviews their clinical applications, together with their problems and limitations.

An inertial measurement unit (IMU) is an electronic device that primarily contains accelerometers, gyroscope and magnetometer sensors. All these sensors are based on measuring and converting the global position of human body segment, momentum/inertia or changes of path length. An accelerometer is a sensor which measures a specific force and acceleration. In this context, an accelerometer is used to determine the orientation of the spinal segment in relation to the Earth's gravitational field. A gyroscope sensor measures the rate of change of angles. Using these sensors, a three-dimensional (3-D) position together with displacement data is calculated by combining inertial sensors orientation data, together with its known distance between the sensors [54, 55].

Kent et al., in their randomised controlled study, used dorsaVi's hardware (which contains two IMU movement sensors) (see **Figure 7**) to measure posture and movement in subacute and chronic low back pain patients ($n = 58$) [56]. The results not only demonstrated that the procedure was suitable for posture measurement but also demonstrated its applicability in providing postural biofeedback. Similarly, Fathi and Curran demonstrated the effective application of wireless IMU sensors to detect the curvature of the spine with 85–95% accuracy in ankylosing spondylitis patients [8].

Other portable, non-invasive sensors used in the assessment of posture are e-textiles. Many studies [57, 58] have reported the use of textile sensors to detect the curvature of the spine. The specially designed fabric contains an inductive sensor, a circuit board and a piezoelectric actuator (a component of a machine responsible for moving and controlling the piezoelectric system) (see **Figure 8**). Any change in posture and spinal movement is calculated by a change in the length or position of the sensors together with the percentage of change in electrical resistance.

Sardini et al. compared the e-textile output data with an optical motion system (Vicon) [58]. The trials performed on four subjects obtained on different days demonstrated that the wireless wearable sensor described in this paper is capable of producing reliable data compared with the data obtained with the optical system.

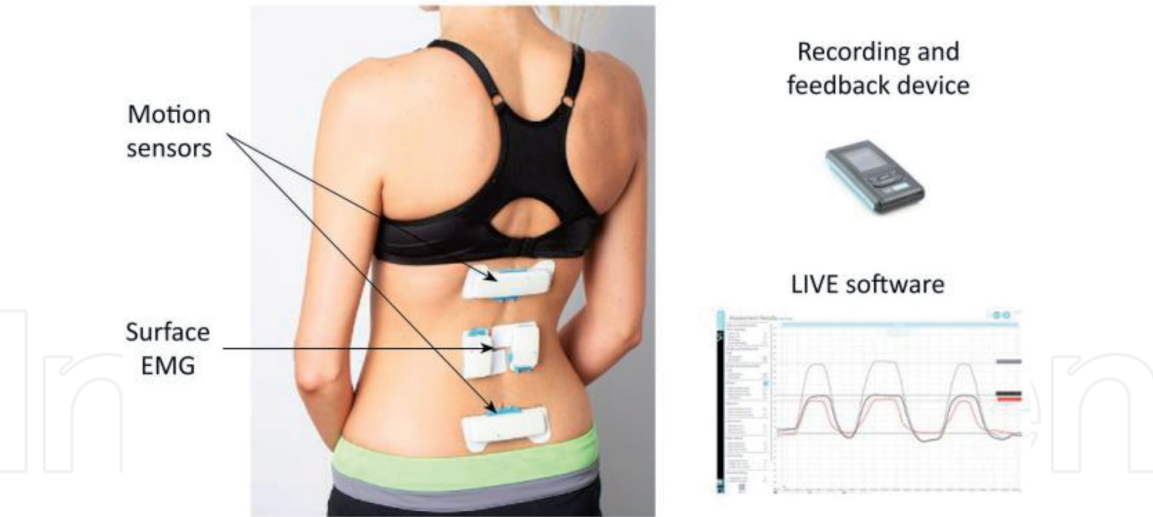


Figure 7.
ViMove wearable motion-sensor system with IMU sensors and surface EMG electrodes (Kent et al. [56]).

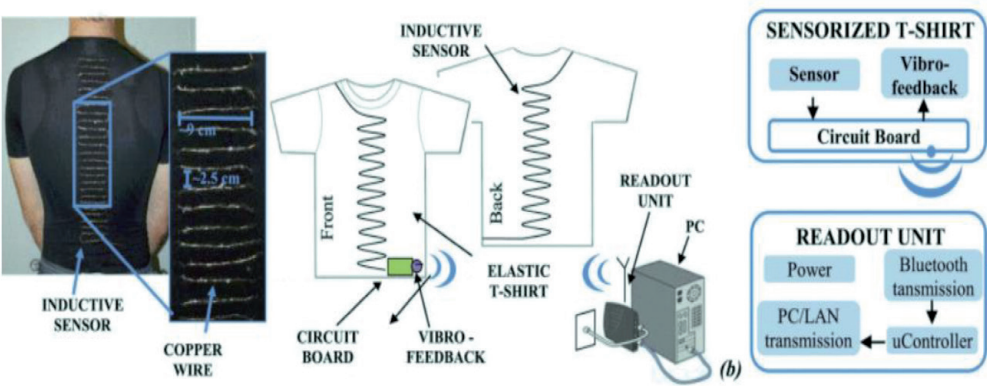


Figure 8.
E-textile with inductive sensors [58].

As the above IMU and e-textile tools were low-cost, portable and easy to use, it might be appropriate to use these for monitoring movement. The reliability of the above tools for measuring spinal curvatures or other back parameters has not yet been reported. The potential limitation of the IMU and e-textile tools is that their interaction with metal in the environment could affect the sensor data extraction due to its capacity to distort electromagnetic waves. In addition, these tools do not provide back surface and whole-body data.

4.2.2.3 Surface measuring systems

Berryman et al. detail that back surface observation and measurement methods have been widely used by both clinicians and researchers for the evaluation of posture and spinal curvature in patients with spinal disorders [59]. The following section aims to review both the qualitative and quantitative studies that describe skin surface measurement tools.

4.2.2.3.1 Moiré topographic methods

Moiré topography and rastereo photography systems are the most valuable and widely used non-radiographic tools in the measurement of posture/back surface. Additionally, these instruments are also used for screening three-dimensional

spinal deformities and furthermore for quantifying the progression of the 3D spinal curvature.

The above topographical systems work on the basis of projecting a structured light onto the back surface. Based on the reflection of the structured light from the subject, Moiré topography images are produced (see **Figure 9**). The contour map image helps to visualise back asymmetry and record the spatial information of the subject's three-dimensional back shape and posture. The quantification of Moiré fringes typically involves the derivation of quantitative angular and/or linear measures by comparing the left and right side back surfaces.

Numerous authors [60, 61] have described the use of the Moiré topography method to evaluate back shape and spinal deformity. The main limitation of the Moiré topography method is that the measurement depends on the absolute order of Moiré fringes.

A Moiré pattern is a low-frequency line image produced from two high-frequency line images or grids. For example, by projecting a high-frequency grid onto an object and viewing the reflection of this projected pattern through another high-frequency grid is called Moiré fringes [62]. The formation of the Moiré fringes depends on a patient's position. A slight change in the patient's position or movement can produce considerable changes in the Moiré topogram. Thus, a direct inspection of Moiré fringes may be misleading. Further Stokes and Moreland states that the data analysis is a complex procedure, requiring much expertise [63]. Additionally, Nissinen et al. also reported that the correlation of Moiré topographs with X-rays is poor and ranges from $r = 0.24$ – 0.45 [64].

4.2.2.3.2 The integrated shape imaging system 1 and 2 (ISIS1 and 2)

The Integrated Shape Imaging System (ISIS) is a widely used optical scanning system for the measurement of human back shape and posture within a clinical environment [65, 66]. The ISIS system consists of an optical scanner (A), which projects a horizontal beam of structured white light onto the patient's back (B). The camera (C), mounted below the projector, captures the position of the light blade on the back from different perspectives (see **Figure 10**). Based on the geometry of the illumination/camera system together with the coordinates of the blade of light, the three-dimensional shape information is derived.

The validation of this system was carried out in the late 1980s and early 1990s [67, 68]. Although the reliability and validity of this tool was good to excellent for clinical use, the original ISIS system was getting old and data acquisition was slow which led to potential movement errors. The system was modified and redesigned

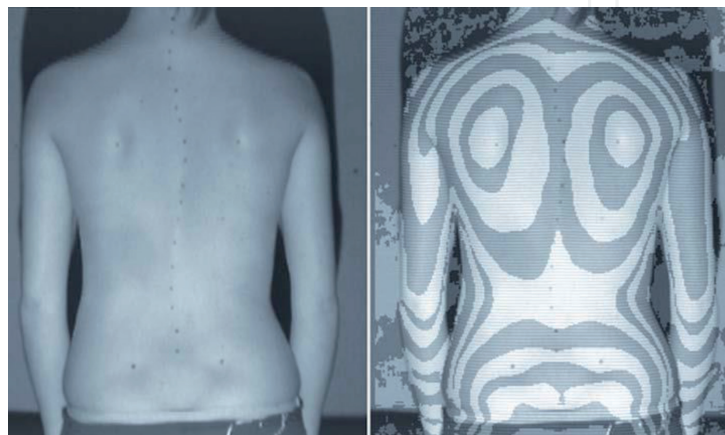

Figure 9.
Example of Moiré topographic images of a subject with scoliosis (reproduced from Kotwicki et al. [60]).

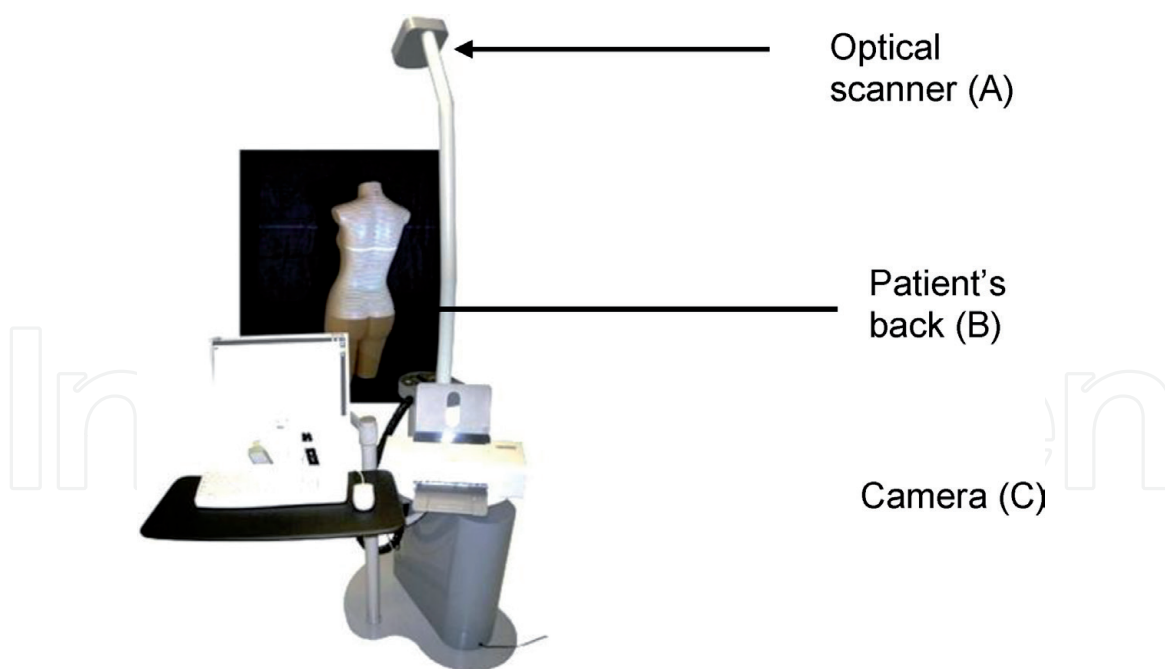


Figure 10.
 Integrated shape imaging system (ISIS2) (reproduced from Porto et al. [73]).

by Berryman et al. with the new addition of a clinical parameters and renamed ISIS2 [59]. This automated non-invasive surface topography system measures three-dimensional shape of the back with improved speed, accuracy, reliability and ease of use [69].

Berryman et al. [59] described the data collection procedure, involving palpation and marking bony landmarks on the subject's back with small coloured stickers. A digital camera is then used to take a photo. The projector then projects a grid of horizontal black lines onto the patient's back. The pixel size is approximately 0.5 mm with fringe frequency of approximately 0.16 fringes/mm. Fourier transform profilometry is used to convert the distortion of the reference grid lines into a three-dimensional surface map of the back.

The data processing with ISIS2 takes only 40 s, compared to 10 min in ISIS. Knott et al. [70] suggest that by reducing the duration of data collection, the error due to natural postural sway of the body decreases, thereby increasing the accuracy (± 1 mm). The results are stored in a database so that the data of the particular patient can be recalled at any given point of time. ISIS2 helps in the screening and monitoring of the development of spinal deformity over time [71, 72].

Zubović et al. [69] carried out a study to validate the ISIS2 system against X-rays. They reviewed 520 ISIS2 scans on 242 scoliosis patients not only for quantifying postural variables but also to assess their validity. The average number of scans per patient was 2.01 with a range of 1–10 scans. The median values and 95% CI were reported for the linear, angular and volumetric asymmetry of scoliosis patients. The results of this study showed no statistically significant differences in their investigations between ISIS measurements and X-ray images.

Similarly, Berryman et al. [59], in their study on measuring three-dimensional back shape in scoliosis patients, also found good correlations ($r = 0.84$) between the Cobb angle and the lateral asymmetry of the ISIS scans.

As seen in **Figure 11**, the ISIS2 system provides additional data to simple radiographic examination, describing the three-dimensional characteristics of the back surface [59, 74]. Previous studies [71, 72] have demonstrated that the ISIS2 produces reliable, valid and accurate data that can monitor the progression of spinal deformities. Berryman et al. [59], Frerich et al. [75], Sadani et al. [76], Brewer et al. [77]

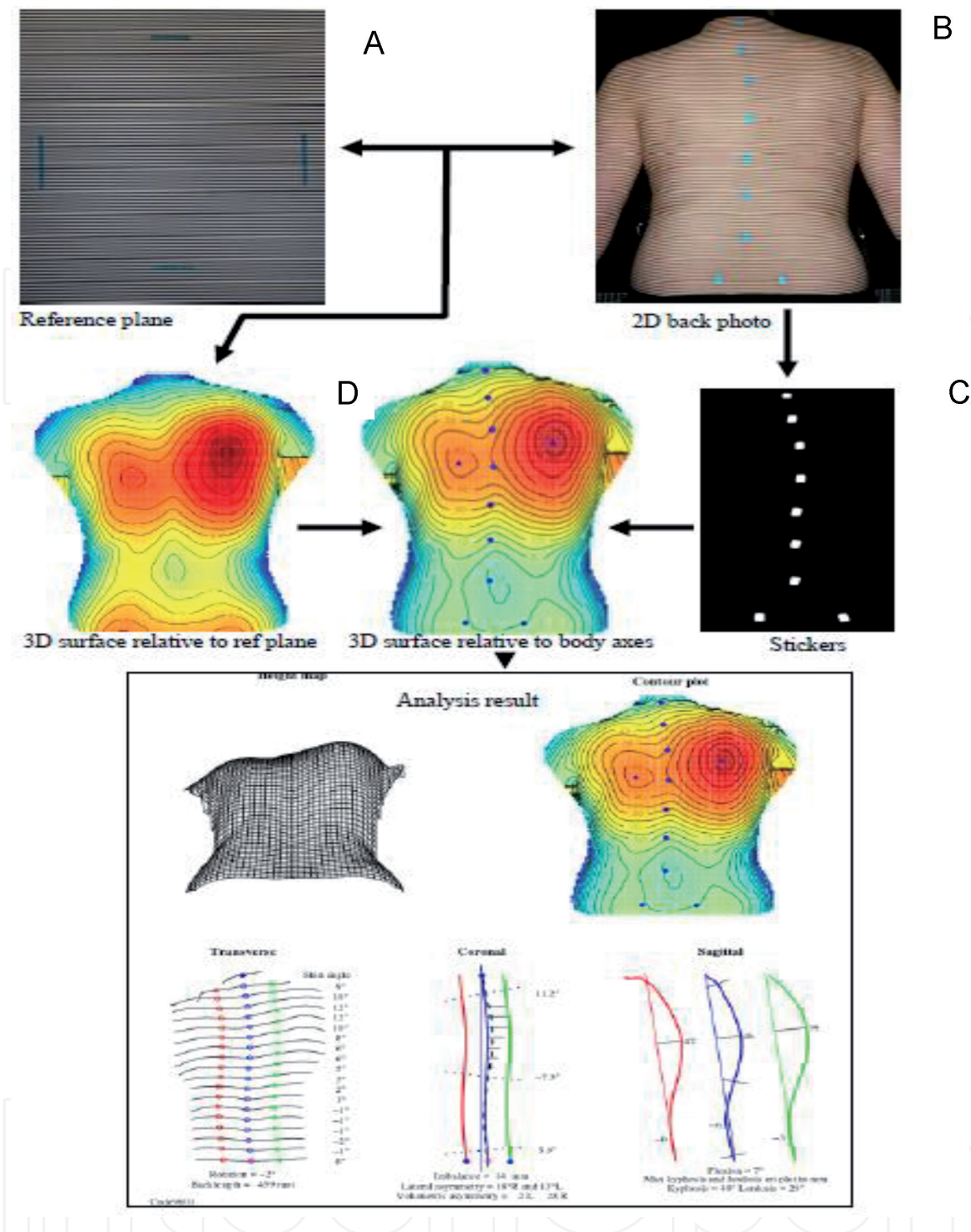


Figure 11. Illustration of data processing and a sample report of ISIS2 method [74]. (A) the reference frame with calibration markers; (B) example of patient image with fringes projected onto the back; (C) representation of symmetry line analysis in frontal and sagittal planes to obtain lateral deviation, kyphosis and lordosis angles; (D) back height map with rib hump, contour plot (representing the shape using contour lines and colour; blue lowest to red highest); and (E) example of ISIS2 report with representation of contour plot and quantification of curve in all planes.

and Knott et al. [33] suggest that the additional advantage of ISIS2 is to reduce the exposure to radiation.

However, Fortin et al. [9] and Bettany-Saltikov et al. [46] identify the ISIS2 system as being very heavy, is not easily moved and requires skilled clinicians to operate it. In addition, Berryman et al. [59] suggests that identifying the bony landmarks for marking spinous process is more difficult for patients who are extremely obese or have heavy musculature. Similarly, the above authors also found it difficult to mark bony landmarks in patients with congenital curves that had little rotation.

The main limitation of the ISIS2 system is that it can only measure back shape and not the whole body. Non-contact optical imaging techniques for the assessment of back shape and posture has also been achieved by using the laser triangulators method.

4.2.2.3.3 *Laser triangulators*

Čelan et al. [78] and Poredoš et al. [79] used the laser triangulation method to evaluate the three-dimensional human spine curvature. The main purpose of these studies was to estimate the spatial bend of the thoracic and lumbar spine curvatures in all three planes. The laser triangulation imaging system used in Poredoš et al.'s study consisted of two basic elements: a greyscale camera (A) and a laser line projector (B) (see **Figure 12**). The spinal path or region of interest (ROI) of the human model is manually marked by the palpation of the subject's bony landmarks. The laser projector illuminates the light onto the subject's back, and the intersection of the laser line with the spinal path or ROI provides the intersection curve, which is then measured using a greyscale camera. The distance between the laser projector and the camera is known. The intersection angle in 3D space is calculated using the triangular method [80].

The laser scanning triangulation method was assessed for both validity and repeatability. Using a point-to-point analysis, the average error (± 1 mm S.D) (distance between markers) for a regular shape (cylinder) was as low as 4.99 ± 1.56 mm, versus 6.91 ± 2.29 mm for an irregular shape (mannequin) [81]. Research by Majid et al. [82] demonstrated the performance of the 3D laser scanning system. In this laboratory-based study, craniofacial measurements of mannequins demonstrated that the photogrammetric/3D laser scanning system had an accuracy of ± 0.7 mm (1 standard deviation [SD]).

The same measurement in human models demonstrated an accuracy of ± 1.2 mm. This decrease in accuracy was due to facial movement during data acquisition.

However, this method also has limitations. The manual spinal path determination is also likely to cause palpation errors. This limits the usage of the system to only experienced healthcare practitioners who have good palpation skills.

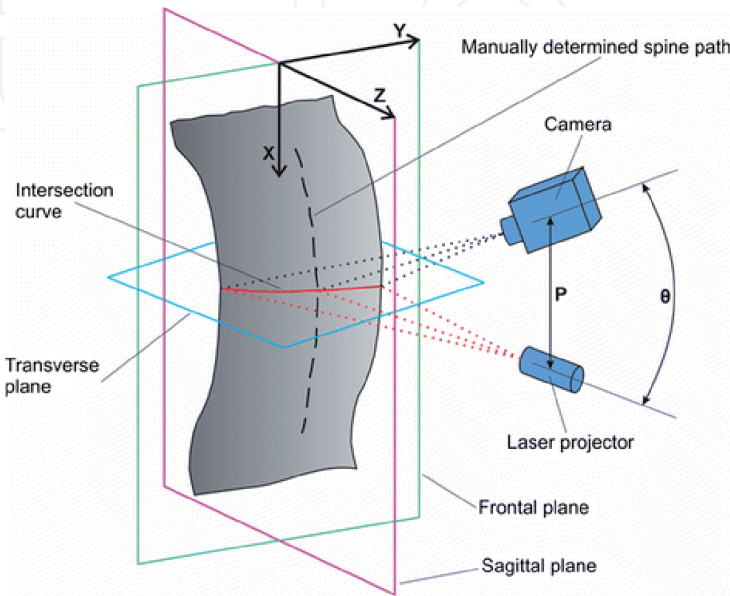


Figure 12.
Illustration of one-laser-plane triangulation method in all planes (reproduced from Poredoš et al. [79]).




Figure 13.
Microsoft Kinect sensor.

Additionally, this tool is capable of only measuring the shape of the human spine and not the complete back or human body.

4.2.2.3.4 Kinect sensors

Microsoft kinetic sensors are currently being used in a range of disciplines from biomechanics to clinical applications [83, 84]. Castro et al. [85] described the use of the Microsoft's Kinect™ to measure back surface and posture. The Kinect sensor consists of two cameras, a colour camera (RGB camera) (A) and a depth (infrared IR) camera (B), and a projector (C) (please see **Figure 13**). These cameras do not require passive markers to determine anatomical landmarks. By measuring the deformations of the projected speckle pattern, a 3D map of the dorsal skin surface is created by using the appropriate software.

The results from previous studies have demonstrated that the depth sensor is valid in measuring 3D back surface in patients with scoliosis and in healthy volunteers [85, 86]. The Microsoft Kinect™ system had comparable intertrial reliability (ICC difference = 0.06 ± 0.05 ; range, 0.00–0.16) and excellent concurrent validity against a benchmark reference, a multiple-camera 3D motional analysis system, with Pearson's r -values >0.90 for the majority of measurements ($r = 0.96 \pm 0.04$; range, 0.84–0.99).

Whilst the Microsoft Kinect™ is inexpensive, portable and offers good repeatable of the 3D map of the back surface, it also has a few limitations. The measurements are limited only to the back surface and not the whole body. Additionally, the Kinect system software is mainly restricted to the Microsoft operating system and is not applicable to any other mobile applications.

5. Conclusion and requirements for a novel system

A number of different techniques for the assessment of posture and back shape within clinical practice and research have been described above. Most are expensive, are difficult to use, need specialised training, are heavy to move or cannot be used for regular clinical use (Fortin et al. [9]). When considering a new system, the following requirements are necessary:

1. A novel tool needs to be simple, portable, low-cost, easy to use and less time-consuming for the purpose of using within clinical practice. This can be

achieved by innovatively using a mobile low-cost scanner, such as the Structure Sensor™ together with freeware software. This has previously been used in the construction and fashion industry [87, 88].

2. The most conventional photographic systems, used in clinical practice at present, do not provide the three-dimensional information of patients' posture and back shape. A novel portable system providing three-dimensional information of patient's posture and back shape would help to better understand the three-dimensional nature of spinal deformities.
3. Most existing systems described in this review provide information on either back shape or spinal posture and not the whole body. A system providing information on the whole body and its relation to spinal posture would yield more information on the relationship between the orientations of the extremities to the trunk.
4. Technological advances in imaging and computerised image-processing led to the development of new 3D image acquisition techniques. There is a demand for bridging the gap between technological advancement and medical practice for the assessment and treatment of spinal disorders [89, 90]. The continuous increase in 3D imaging technology provides opportunities for the development of a novel system that provides reliable and valid results for assessment of whole-body posture and back shape.

Author details


Gok Kandasamy^{1*}, Josette Bettany-Saltikov¹ and Paul van Schaik²

¹ School of Health and Life Sciences, Teesside University, United Kingdom

² School of Social Sciences Humanities and Law, Teesside University, United Kingdom

*Address all correspondence to: g.kandasamy@tees.ac.uk

IntechOpen

© 2020 The Author(s). Licensee IntechOpen. This chapter is distributed under the terms of the Creative Commons Attribution License (<http://creativecommons.org/licenses/by/3.0>), which permits unrestricted use, distribution, and reproduction in any medium, provided the original work is properly cited. 

References

- [1] Schwab F, Dubey A, Gamez L, et al. Adult scoliosis: Prevalence, SF-36, and nutritional parameters in an elderly volunteer population. *Spine (Phila Pa 1976)*. 2005;**30**:1082-1085
- [2] Fällström K, Cochran T, Nachemson A. Long-term effects on personality development in patients with adolescent idiopathic scoliosis. Influence of type of treatment. *Spine (Phila Pa 1976)*. 1986;**11**:756-758
- [3] Burt S, Punnett L. Evaluation of interrater reliability for posture observations in a field study. *Applied Ergonomics*. 1999;**30**:121-135
- [4] Danielsson AJ, Wiklund I, Pehrsson K, et al. Health-related quality of life in patients with adolescent idiopathic scoliosis: A matched follow-up at least 20 years after treatment with brace or surgery. *European Spine Journal*. 2001;**10**:278-288
- [5] Tyson SF, DeSouza LH. A clinical model for the assessment of posture and balance in people with stroke. *Disability and Rehabilitation*. 2003;**25**:120-126
- [6] Cheung C-WJ, Zhou G-Q, Law S-Y, et al. Ultrasound volume projection imaging for assessment of scoliosis. *IEEE Transactions on Medical Imaging*. 2015;**34**:1760-1768
- [7] Cheriet F, Laporte C, Kadoury S, et al. A novel system for the 3-D reconstruction of the human spine and rib cage from biplanar X-ray images. *IEEE Transactions on Biomedical Engineering*. 2007;**54**:1356-1358
- [8] Fathi A, Curran K. Detection of spine curvature using wireless sensors. *Journal of King Saud University*. 2017;**29**:553-560
- [9] Fortin C, Ehrmann Feldman D, Cheriet F, et al. Clinical methods for quantifying body segment posture: A literature review. *Disability and Rehabilitation*. 2011;**33**:367-383
- [10] Williams DS, McClay IS. Measurements used to characterize the foot and the medial longitudinal arch: Reliability and validity. *Physical Therapy*. 2000;**80**:864-871
- [11] Elabd A, Ibrahim A, Elhafez H. Kinesio taping versus postural correction exercises on mechanically triggered neck dysfunction. *International Journal of Therapy and Rehabilitation*. 2017;**24**:155-162
- [12] Raupp EG, Candotti CT, Marchetti BV, et al. The validity and reproducibility of the Flexicurve in the evaluation of cervical spine Lordosis. *Journal of Manipulative and Physiological Therapeutics*. 2017;**40**:501-510
- [13] Greenfield B, Catlin PA, Coats PW, et al. Posture in patients with shoulder overuse injuries and healthy individuals. *The Journal of Orthopaedic and Sports Physical Therapy*. 1995;**21**:287-295
- [14] Rheault W, Ferris S, Foley JA, et al. Intertester reliability of the flexible ruler for the cervical spine. *The Journal of Orthopaedic and Sports Physical Therapy*. 1989;**10**:254-256
- [15] Hecimovich MD, Stomski NJ. Lumbar sagittal plane spinal curvature and junior-level cricket players. *International Journal of Athletic Therapy and Training*. 2016;**21**:47-52
- [16] Burton AK. Suggestion from the field: Measurement of “regional” lumbar sagittal mobility. *The Journal of Orthopaedic and Sports Physical Therapy*. 1987;**9**:166-169
- [17] Bryan JM, Mosner E, Shippee R, et al. Investigation of the validity of postural evaluation skills in assessing

lumbar lordosis using photographs of clothed subjects. *The Journal of Orthopaedic and Sports Physical Therapy*. 1990;12:24-29

[18] Hart DL, Rose SJ. Reliability of a noninvasive method for measuring the lumbar curve. *The Journal of Orthopaedic and Sports Physical Therapy*. 1986;8:180-184

[19] Wu W, Liang J, Du Y, et al. Reliability and reproducibility analysis of the cobb angle and assessing sagittal plane by computer-assisted and manual measurement tools. *BMC Musculoskeletal Disorders*. 2014;15:33

[20] Hogeweg JA, Langereis MJ, Bernards ATM, et al. Goniometry-variability in the clinical practice of a conventional goniometer in healthy subjects. *European Journal of Physical and Rehabilitation Medicine*. 1994;4:2-7

[21] ICN S, BWC Q, et al. Reliability of photogrammetry in relation to goniometry for postural lower limb assessment. *Revista Brasileira de Fisioterapia*. 2007;11:411-417

[22] Harrison DD, Janik TJ, Troyanovich SJ, et al. Comparisons of lordotic cervical spine curvatures to a theoretical ideal model of the static sagittal cervical spine. *Spine (Phila Pa 1976)*. 1996;21:667-675

[23] Perry J, Klopfer E, Norton M, et al. AR gone wild: Two approaches to using augmented reality learning games in zoos. In: *Proceedings of the 8th International Conference on International Conference for the Learning Sciences-Vol. 3*. 2008. pp. 322-329

[24] Kendall FP, McCreary EK, Provance PG, et al. *Muscles; Testing and Function with Posture and Pain*. Williams and Wilkins. Seoul 2005; 52, 61, 159

[25] McKenzie R, May S. *The Lumbar Spine: Mechanical Diagnosis and*

Therapy. New Zealand: Orthopedic Physical Therapy, Spinal Publications; 2003

[26] Hickey ER, Rondeau MJ, Corrente JR, et al. Reliability of the cervical range of motion (CROM) device and plumb-line techniques in measuring resting head posture (RHP). *Journal of Manual and Manipulative Therapy*. 2000;8:10-17

[27] Perry M, Smith A, Straker L, et al. Reliability of sagittal photographic spinal posture assessment in adolescents. *Advances in Physiotherapy*. 2008;10:66-75

[28] Schwab FJ, Patel A, Ungar B, et al. Adult spinal deformity — Postoperative standing imbalance assessing alignment and planning corrective surgery. *Spine (Phila Pa 1976)*. 2010;35:2224-2231

[29] Schwab FJ, Smith VA, Biserni M, et al. Adult scoliosis: A quantitative radiographic and clinical analysis. *Spine (Phila Pa 1976)*. 2002;27:387-392

[30] McVey G, Sandborg M, Dance DR, et al. A study and optimization of lumbar spine X-ray imaging systems. *The British Journal of Radiology*. 2003;76:177-188

[31] O'Neill TW, Felsenberg D, Varlow J, et al. The prevalence of vertebral deformity in European men and women: The European vertebral osteoporosis study. *Journal of Bone and Mineral Research*. 1996;11:1010-1018

[32] Rea JA, Steiger P, Blake GM, et al. Morphometric X-ray absorptiometry: Reference data for vertebral dimensions. *Journal of Bone and Mineral Research*. 1998;13:464-474

[33] Knott P, Pappo E, Cameron M, et al. SOSORT 2012 consensus paper: Reducing x-ray exposure in pediatric patients with scoliosis. *Scoliosis*. 2014;9:1-9

- [34] Zhang Y, Chen Y, Huang H, et al. Diagnostic x-ray exposure increases the risk of thyroid microcarcinoma: A population-based case-control study. *European Journal of Cancer Prevention*. 2015;**24**:439
- [35] Doody MM, Lonstein JE, Stovall M, et al. Breast cancer mortality after diagnostic radiography: Findings from the US scoliosis cohort study. *Spine (Phila Pa 1976)*. 2000;**25**:2052-2063
- [36] Council NR, others. Committee on the biological effects of ionizing radiation. In: *Health Effects of Low Levels Ionizing Radiation (BEIR V)*. National Academics; 1990
- [37] van Niekerk S-M, Louw Q, Vaughan C, et al. Photographic measurement of upper-body sitting posture of high school students: A reliability and validity study. *BMC Musculoskeletal Disorders*. 2008;**9**:113
- [38] Kiliç F, Yaman H, Atay E. Investigation of the effects of intensive one-sided and double-sided training drills on the postures of basketball playing children. *Journal of Physical Therapy Science*. 2009;**21**:23-28
- [39] Furlanetto TS, Sedrez JA, Candotti CT, et al. Photogrammetry as a tool for the postural evaluation of the spine: A systematic review. *World Journal of Orthopedics*. 2016;**7**:136
- [40] Souza JA, Pasinato F, Basso D, et al. Biophotogrammetry: Reliability of measurements obtained with a posture assessment software (SAPO). *Revista Brasileira de Cineantropometria & Desempenho Humano*. 2011;**13**:299-305
- [41] Santos MM, Silva MPC, Sanada LS, et al. Photogrammetric postural analysis on healthy seven to ten-year-old children: Interrater reliability. *Brazilian Journal of Physical Therapy*. 2009;**13**:350-355
- [42] Thigpen CA, Padua DA, Michener LA, et al. Head and shoulder posture affect scapular mechanics and muscle activity in overhead tasks. *Journal of Electromyography and Kinesiology*. 2010;**20**:701-709
- [43] JLP R. Biomechanical assessment of human posture: A literature review. *Journal of Bodywork and Movement Therapies*. 2014;**18**:368-373
- [44] Ruivo RM, Pezarat-Correia P, Carita AI. Cervical and shoulder postural assessment of adolescents between 15 and 17 years old and association with upper quadrant pain. *Brazilian Journal of Physical Therapy*. 2014;**18**:364-371
- [45] Viazzi S, Bahr C, Van Hertem T, et al. Comparison of a three-dimensional and two-dimensional camera system for automated measurement of back posture in dairy cows. *Computers and Electronics in Agriculture*. 2014;**100**:139-147
- [46] Bettany-Saltikov J, Martin D, Wellburn S, et al. Information provided to patients with adolescent idiopathic scoliosis (AIS) at the first point of diagnosis in the hospital clinic: A survey of UK NHS scoliosis consultants. *Scoliosis*. 2012;**7**:O36
- [47] Stachoń A, Burdukiewicz A, Andrzejewska J, et al. The imaging and evaluation of body posture defects in hearing impaired children. *Bio-Algorithms and Med-Systems*. 2012;**8**:221-236
- [48] Mroczkowski A. The effect of aikido exercises on shaping spinal curvatures in the sagittal plane. *Journal of Combat Sports and Martial Arts*. 2013;**2**(2):173-177
- [49] Lichota M, Plandowska M, Mil P. The shape of anterior-posterior curvatures of the spine in athletes practising selected sports. *Polish Journal of Sport and Tourism*. 2011;**18**:112-116
- [50] Kowalski IM, Kotwicki T, Siwik P. Analysis of diagnostic methods in trunk

deformities in the developmental age. Polish Annals of Medicine. 2013;**20**:43-50

[51] Scholten-Peeters GGM, Franken N, Beumer A, et al. The opinion and experiences of Dutch orthopedic surgeons and radiologists about diagnostic musculoskeletal ultrasound imaging in primary care: A survey. *Manual Therapy*. 2014;**19**:109-113

[52] Thoomes-de Graaf M, Scholten-Peeters GGM, Duijn E, et al. Inter-professional agreement of ultrasound-based diagnoses in patients with shoulder pain between physical therapists and radiologists in the Netherlands. *Manual Therapy*. 2014;**19**:478-483

[53] Godfrey A, Conway R, Meagher D, et al. Direct measurement of human movement by accelerometry. *Medical Engineering & Physics*. 2008;**30**:1364-1386

[54] Wong WY, Wong MS. Trunk posture monitoring with inertial sensors. *European Spine Journal*. 2008;**17**:743-753

[55] Voinea G-D, Butnariu S, Mogan G. Measurement and geometric modelling of human spine posture for medical rehabilitation purposes using a wearable monitoring system based on inertial sensors. *Sensors*. 2016;**17**:3

[56] Kent P, Laird R, Haines T. The effect of changing movement and posture using motion-sensor biofeedback, versus guidelines-based care, on the clinical outcomes of people with sub-acute or chronic low back pain-a multicentre, cluster-randomised, placebo-controlled, pilot trial. *BMC Musculoskeletal Disorders*. 2015;**16**:131

[57] Rajdi NNZM, Bakira AA, Saleh SM, et al. Textile-based micro electro mechanical system (MEMS) accelerometer for pelvic tilt

measurement. *Procedia Engineering*. 2012;**41**:532-537

[58] Sardini E, Serpelloni M, Pasqui V. Wireless wearable T-shirt for posture monitoring during rehabilitation exercises. *IEEE Transactions on Instrumentation and Measurement*. 2015;**64**:439-448

[59] Berryman F, Pynsent P, Fairbank J, et al. A new system for measuring three-dimensional back shape in scoliosis. *European Spine Journal*. 2008;**17**:663-672

[60] Kotwicki T, Kinel E, Stryla W, et al. Discrepancy in clinical versus radiological parameters describing deformity due to brace treatment for moderate idiopathic scoliosis. *Scoliosis*. 2007;**2**:18

[61] Rankine L, Liu XC, Tassone C, et al. Reproducibility of newly developed spinal topography measurements for scoliosis. *The Open Orthopaedics Journal*. 2012;**6**:226

[62] Chiang C. Moiré topography. *Applied Optics*. 1975;**14**:177-179

[63] Stokes IAF, Pekalsky JR, Moreland MS. Surface topography and spinal deformity. In: *Proceedings of the 4-th International Symposium*. New York: Gustaw Verlag; 1987

[64] Nissinen M, Heliövaara M, Tallroth K, et al. Trunk asymmetry and scoliosis anthropometric measurements in Prepuberal school children. *Acta Paediatrica*. 1989;**78**:747-753

[65] Turner-Smith AR, Harris JD, Abery JM, et al. Back shape measurement. *Oxford Orthopaedic Engineering Centre*. 1981;**8**:41-49

[66] Turner-Smith AR, Harris JD, Houghton GR, et al. A method for analysis of back shape in scoliosis. *Journal of Biomechanics*. 1988;**21**:497-509

- [67] Legaye J, Lokietek W, Orban C, et al. The ISIS optic scanner: Its use in the evaluation and control of spinal deviations. *Acta Orthopaedica Belgica*. 1992;**58**:66-72
- [68] Berdishevsky H, Lebel VA, Bettany-Saltikov J, et al. Physiotherapy scoliosis-specific exercises - a comprehensive review of seven major schools. *Scoliosis and Spinal Disorders*. 2016;**11**:20
- [69] Zubović A, Davies N, Berryman F, et al. New method of scoliosis deformity assessment: ISIS2 system. *Studies in Health Technology and Informatics*. 2008;**140**:157-160
- [70] Knott P, Smith K, Mack L, et al. A comparison of static vs dynamic surface topography measurements in the evaluation of scoliosis. *Scoliosis*. 2012;**7**:P12
- [71] Talasila SSA, Gorantla M, Thomas V. A study on screening for scoliosis among school children in the age group of 10-14 using a cost effective and an innovative technique. *The International Journal of Community Medicine and Public Health*. 2017;**4**:2118-2123
- [72] Pino-Almero L, M'inguez-Rey MF, Rodr'iguez-Mart'inez D, et al. Clinical application of back surface topography by means of structured light in the screening of idiopathic scoliosis. *Journal of Pediatric Orthopaedics. Part B*. 2017;**26**:64-72
- [73] Porto F, Gurgel JL, Russomano T, et al. Moiré topography: Characteristics and clinical application. *Gait & Posture*. 2010;**32**:422-424
- [74] Anwary AR. Statistical Shape Analysis for the Human Back Statistical Shape Analysis for the Human Back. Openrepository.com, University of Wolverhampton; 2012
- [75] Frerich JM, Hertzler K, Knott P, et al. Comparison of radiographic and surface topography measurements in adolescents with idiopathic scoliosis. *The Open Orthopaedics Journal*. 2012;**6**:261-265
- [76] Sadani S, Jones C, Seal A, et al. A pilot study of scoliosis assessment using radiation free surface topography in children with GMFCS IV and V cerebral palsy. *Child: Care, Health and Development*. 2012;**38**:854-862
- [77] Brewer P, Berryman F, Baker D, et al. Influence of Cobb angle and ISIS2 surface topography volumetric asymmetry on Scoliosis Research Society-22 outcome scores in scoliosis. *Spinal Deformities*. 2013;**1**:452-457
- [78] Čelan D, Papež BJ, Poredoš P, et al. Laser triangulation measurements of scoliotic spine curvatures. *Scoliosis*. 2015;**10**:25
- [79] Poredoš P, Čelan D, Možina J, et al. Determination of the human spine curve based on laser triangulation. *BMC Medical Imaging*. 2015;**15**:2
- [80] Amann M-C, Bosch TM, Lescure M, et al. Laser ranging: A critical review of unusual techniques for distance measurement. *Optical Engineering*. 2001;**40**:10-20
- [81] Chang Y-C, Detchev I, Habib A. A photogrammetric system for 3D reconstruction of a Scoliotic torso [A Master Thesis]. University of Calgary; 2008; 1: 126-137
- [82] Majid Z, Chong AK, Ahmad A, et al. Photogrammetry and 3D laser scanning as spatial data capture techniques for a national craniofacial database. *The Photogrammetric Record*. 2005;**20**:48-68
- [83] Bonanno DR, Zhang CY, Farrugia RC, et al. The effect of different depths of medial heel skive on plantar pressures. *Journal of Foot and Ankle Research*. 2012;**5**:20

[84] Nguyen CV, Izadi S, Lovell D. Modeling kinect sensor noise for improved 3d reconstruction and tracking. In: Second International Conference on 3D Imaging, Modeling, Processing, Visualization and Transmission (3DIMPVT). 2012. pp. 524-530

[85] Castro APG, Pacheco JD, Lourenço C, et al. Evaluation of spinal posture using Microsoft Kinect™: A preliminary case-study with 98 volunteers. Porto Biomedical Journal. 2017;2:18-22

[86] Lachat E, Macher H, Mittet MA, et al. First experiences with kinect V2 sensor for close range 3D modelling. International Archives of the Photogrammetry, Remote Sensing and Spatial Information Sciences - ISPRS Archives. 2015;40:93-100

[87] D'Apuzzo N. 3D body scanning technology for fashion and apparel industry. In: Electronic Imaging. International Society for Optics and Photonics; 2007. pp. 64910O-64910O

[88] Yap YL, Yeong WY. Additive manufacture of fashion and jewellery products: A mini review: This paper provides an insight into the future of 3D printing industries for fashion and jewellery products. Virtual and Physical Prototyping. 2014;9:195-201

[89] Eysenbach G, Köhler C. How do consumers search for and appraise health information on the world wide web? Qualitative study using focus groups, usability tests, and in-depth interviews. The BMJ. 2002;324:573-577

[90] Gammon D, Årsand E, Walseth OA, et al. Parent-child interaction using a mobile and wireless system for blood glucose monitoring. Journal of Medical Internet Research. 2005;7(5):e57