

# We are IntechOpen, the world's leading publisher of Open Access books Built by scientists, for scientists

6,900

Open access books available

186,000

International authors and editors

200M

Downloads

Our authors are among the

154

Countries delivered to

TOP 1%

most cited scientists

12.2%

Contributors from top 500 universities



WEB OF SCIENCE™

Selection of our books indexed in the Book Citation Index  
in Web of Science™ Core Collection (BKCI)

Interested in publishing with us?  
Contact [book.department@intechopen.com](mailto:book.department@intechopen.com)

Numbers displayed above are based on latest data collected.  
For more information visit [www.intechopen.com](http://www.intechopen.com)



# Somatic Nerve Reconstruction and Reinnervation

*Lin Yang and Ping Wang*

## Abstract

Somatic nerves include somatic sensory and somatic motor, both of which are part of the peripheral nervous system. When somatic motor nerve or somatosensory nerve produces injury, then it belongs to peripheral nerve injury. Peripheral nerve injuries are common disease and complex process in clinical surgery. The severe physical dysfunctions such as motor/sensory loss, dyskinesia, and nutritional disorders in the area innervated caused by the peripheral nerve injury and even leave a lifelong disability. Therefore, somatic nerve reconstruction is essential and remains a major challenge for surgeons. Therapeutic methods include neurorrhaphy and nerve transfer or redistribution reconstruction; traditional Chinese medicine-assisted nerve regeneration and repair methods have been increasingly improved, even the functional recovery of peripheral nerve has not made breakthrough progress. All kinds of reconstruction and neural rehabilitation technologies have their own advantages, but they all have some limitations. Although great progress has been made in nerve electrophysiology and microsurgery, the results are still unsatisfactory. This chapter reviews the application of peripheral nerve reconstruction technology and briefly describes the advantages and disadvantages of each method, which will be useful for the selection of clinical treatment.

**Keywords:** somatic nerve, peripheral nerve injury, neural rehabilitation, reinnervation, traditional Chinese medicine

## 1. Introduction

The peripheral nerves are all nerves, except the brain and the spinal cord, and peripheral nerves are composed of nerve fibers. The longer protrusions of the neurons are surrounded by an insulating sheath of myelin and nerve membranes to form nerve fibers. Neurons are classified into motor neurons and sensory neurons according to their function and the direction of nerve conduction. Motor neurons conduct signals from the spinal cord and brain to the effector, and sensory neurons transmit excitability to the central nervous system. The motor and/or sensory nerve fiber bundles form the corresponding motor, sensory, or mixed nerves. Therefore, matching the corresponding bundle branches during nerve repair is of great significance for nerve regeneration. This article discussed the common clinical methods of nerve anastomosis and nerve transplantation and analyzes the characteristics of various neurosurgical reconstruction methods and the effects on somatosensory function recovery. At the same time, this article will list several recognized and effective methods of traditional Chinese medicine neuro rehabilitation, aiming to provide options for somatosensory rehabilitation after peripheral nerve injury.

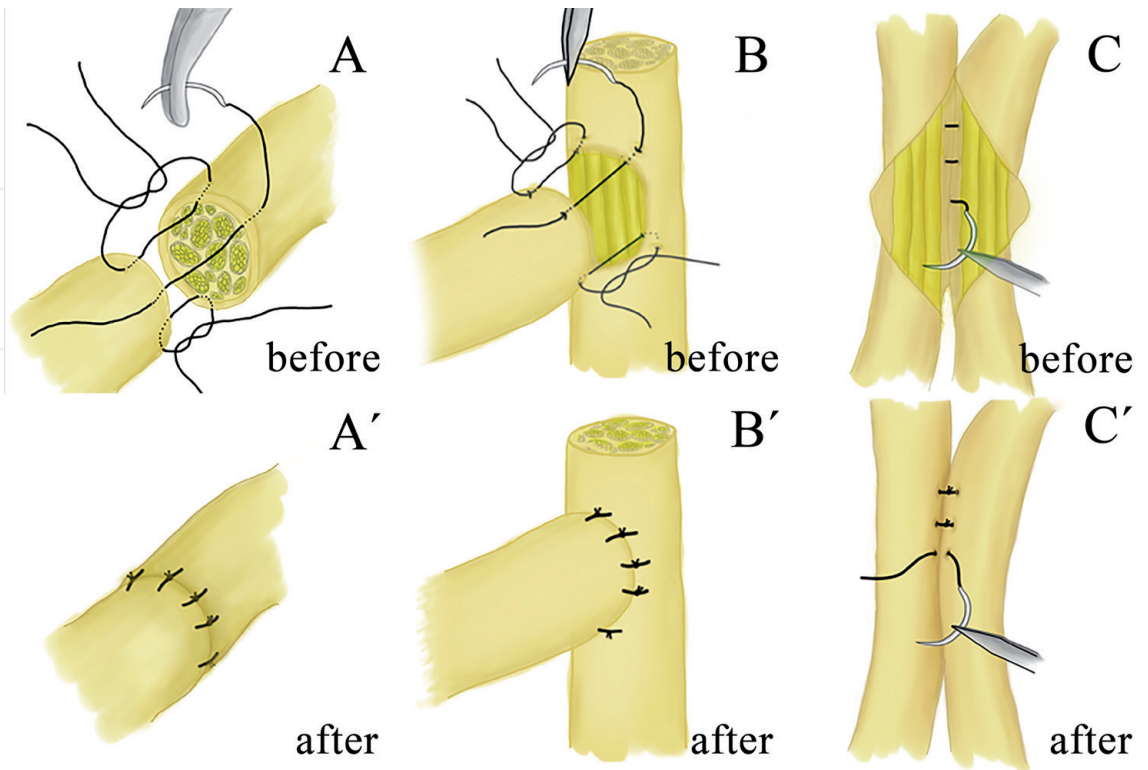
## 2. Nerve transplantation

The concept of nerve transplantation is to repair peripheral nerve injury caused by various injury factors by means of nerve autograft and/or nerve allograft. It is a major alternative technique for nerve neurorrhaphy, applied to the clinical process of nerve neurorrhaphy due to excessive stretching of the nerve leading to partial or permanent ischemia. At present, peripheral nerve transplantation has developed some major types of transplantation such as nerve autograft and nerve allograft. The common transplantation methods used in surgical operations are nerve trunk transplantation, nerve cable transplantation, and nerve bundle transplantation.

### 2.1 Neurorrhaphy

#### 2.1.1 End-to-end (ETE) neurorrhaphy

The peripheral nerve injuries lead to different types and degrees of injuries; for the treatment of peripheral nerves disorders, microsurgery plays a very important role. It is the neurorrhaphy of the broken port to restore the anatomical continuity of the nerve and enable the distal nerve fibers to grow into the corresponding target tissue, so as to restore its sensory and motor functions to the greatest extent. At present, the method commonly used in clinical practice to repair nerves with a defect of a short segment of nerve is direct neurorrhaphy (**Figure 1A**). ETE neurorrhaphy [1] is the current gold standard for clinical repair of nerve injury, with the development of modern microsurgical technology, which has developed from epineurium suture to small gap bridging method and sticky method under the microscope, the nerve technology of conventional silk suture repair has reached a higher level. ETE neurorrhaphy is available, reduces the degree of damage to the nerve itself and surrounding tissues, reduces inflammation and scar formation, and



**Figure 1.**  
The schematic diagram of neurorrhaphy (drawn by Lin).

is conducive to nerve regeneration and maturation. However, ETE neurorrhaphy cannot repair long nerve defects, which is larger than 2 cm.

### *2.1.2 End-to-side (ETS) neurorrhaphy*

ETS neurorrhaphy [2] is to sew (**Figure 1B**) the distal end of the injured nerve to the side adjacent to the normal nerve and to regenerate the nerve through sudden shoots of the collateral axis, thereby restoring the sensory and motor functions of the injured innervation area. This surgical method is simple and requires only anastomosis without tension. The donor nerve can be opened with or without the window of the epineurium. After ETS neurorrhaphy, the function of the donor nerve is not affected. The biggest advantage of this method in repairing nerve damage is that it does not need to consider the distance of the damaged nerve proximal defect, and it does not affect the function of the donor nerve. In 1994, Viterbo et al. [3] first proposed a rat model, which sutured the distal stump of the rat peroneal nerve to the side wall of a healthy tibial nerve on the same side. Experimental studies have found that after ETS neurorrhaphy, injured nerves regenerate, and targeted organ function can be restored. Tarasidis et al. [4] confirmed that sensory nerves can also achieve nerve regeneration through ETS neurorrhaphy. The effect of nerve regeneration depends on many factors, such as contact area and anastomosis angle. Jia et al. increased the contact area of the nerve stump and repaired the nerve with ETS neurorrhaphy, and the nerve fibers regenerated well, increasing the contact area of the nerve stump could obtain more effective nerve regeneration. Yu et al. [5] studied whether sensory nerve induces motor nerve regeneration and suggested that ETS neurorrhaphy of a sensory nerve gives rise to successful motor nerve reinnervation.

Regenerating fibers are produced by normal nerve trunks through collateral sprouting after nerve ETS neurorrhaphy. The level of regenerative nerve function recovery is similar to the effect of ETS neurorrhaphy and has [6] the same effect as nerve transplantation. Defective nerves can achieve self-connection of regenerating fibers by bilateral anastomosis with normal nerves, but this connection plays only a minor role in the recovery of injured nerve function, and the collateral regeneration fibers from the normal neural stem play a major role. At the same time, anastomosis may become a new method for the prevention and treatment of stump neuroma.

Experimental research and preliminary clinical practice [7] prove that nerve ETS neurorrhaphy is a promising method for treating peripheral nerve injury. Especially, it is a suitable choice when repairing a large segment of nerve defect, and ETE neurorrhaphy cannot be applied, but there are few studies in this area, and whether the ETS neurorrhaphy is superior and needs further research.

### *2.1.3 Side-to-side (STS) neurorrhaphy*

As the distal end of the injured nerve and the adjacent healthy nerves are opened and sutured on the opposite side (**Figure 1C**), two nerve channels are established. Transportation reaches the damaged nerve and reaches the target organ to provide nutrition or grow lateral buds, thereby [8] promoting regeneration and repair of the damaged nerve, so as to restore part of the nerve's function. It is obvious that nerve regeneration after ETS and STS neurorrhaphy is not enough to replace the function of the original inner nerve in dominate muscle function.

Peripheral nerve STS neurorrhaphy is one of the effective methods for treating spastic cerebral palsy of the limbs. The spastic muscle group can obtain some normal innervation after operation to change the localization of the cerebral cortex.



Zhou et al. [9] established a model by ligating and fixing the proximal peroneal nerve transection of the right common peroneal nerve in New Zealand rabbits and opening a window of the outer membrane of distal and ipsilateral tibial nerves and anastomosing them with lateral suture, concluding that this method can effectively protect the motor end plate function of the denervated muscles. STS neurorrhaphy [10] is a remedial treatment for damaged nerves that cannot be repaired by conventional methods, such as high injury or incomplete injury such as brachial plexus lower trunk or sciatic nerve injury.

## **2.2 Nerve autograft**

Nerve autograft is a method of suturing and repairing the injured area of the autologous nerve with free autologous nerve. Philipeaux et al. first used the free nerve transplantation to repair hypoglossal nerve defect in 1870, which became the initiation of autologous transplantation. Oberlin et al. [11] reported for the first time that the ipsilateral 1/10 ulnar nerve bundle branch was transposed and anastomosed to the musculocutaneous nerve and biceps brachii muscle branch to repair brachial plexus nerve injury. Since then, the operation has been widely used and continuously improved. Contralateral C7 nerve transposition was first created by Gu et al. [12] for the treatment of brachial plexus root avulsion in 1986, which developed a contralateral C7 vertebral body anterior displacement (in combination with nerve graft) to repair a total brachial plexus avulsion. Nerve autograft throughout hundreds of years' researching has developed into pedicled autologous nerve transfer and free autologous nerve transfer. Pedicled autologous nerve transplant consists of pedicled autologous nerve transfer and pedicled vascular autologous nerve transfer. Free autologous nerve transfer includes traditional autologous nerve transfer, such as cable, trunk, and vascular nerve transfer [13]. Nerve autograft have incomparable advantages over other materials, such as nonantigenicity; orderly arrangement of axons regenerated in vivo; accurate access to target tissues, organs, and blood supply; and low rejection by the body. Autograft have remained as the standard for the nerve grafting material. Therefore, nerve autograft is the golden standard treatment for the majority of clinical diseases in the current peripheral surgery for repairing peripheral nerve defects [14].

However, the limited sources are liable to cause nerve dysfunction. Sensory deficiency and scar formation in donor site, which result in nerve regeneration, were still being pended. Besides, insufficient blood supply and connective tissue hyperplasia have also interfere with its development [15]. Therefore, studies on improving autologous peripheral nerve blood flow, especially microcirculation and blood-nerve barrier restoration, are intended to provide blood flow guarantee for the survival of nerve transplantation segments and are a prerequisite for improving nerve regeneration [16]. Furthermore, increasing Schwann cells and forming Schwann cells with the same number of nerve fibers make nerve fibers to regenerate faster than connective tissue hyperplasia and can achieve better neural regeneration effect [17].

## **2.3 Nerve allograft**

In order to overcome the main shortcomings of nerve allograft in repairing peripheral nerve injury, related scholars have explored a new repairing method—nerve allograft. In 1885, Albert made the first attempt of human nerve allograft. In recent hundred years, it was found that nerve allograft have many advantages, such as no secondary damage on patients, availability of various types of nerve segments, and sufficient sources. It is regarded as one of the new development directions of

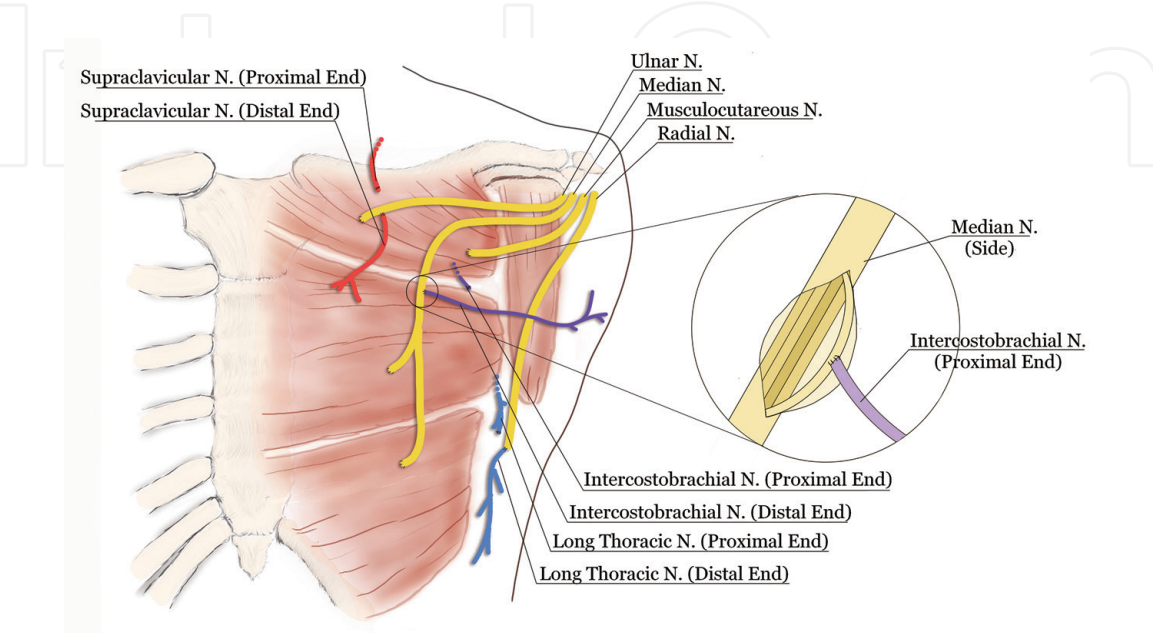
nerve repair and an alternative technical of nerve autograft. But after fresh nerve allograft transplantation by Davis et al. [18], it was found that the area where it was operated on transplantation could not be fully restored. Considering that the transplanted nerves ended with central necrosis and fibrous scarring, Sunderland believed that using fresh nerve allograft was a failure [19]. At present, it is generally accepted in academia that rejection reaction between graft and recipient is the main factor affecting functional repair. Therefore, the key to the success of transplantation is whether immune rejection can be suppressed or not [20]. At present, the main research direction is to explore how to remove the antigenicity of nerve allograft. Radiation-irradiation, cryopreservation, and high temperature preservation are the methods to reduce immunogenicity, but the effect of these pretreated nerve allograft on promoting nerve regeneration is significantly weaker than that of fresh autologous nerve transfer [21]. On these above shortcomings, many domestic and foreign scholars have carried out various animal experiments, but no breakthrough has been made.

## **2.4 Targeted reinnervation (TR)**

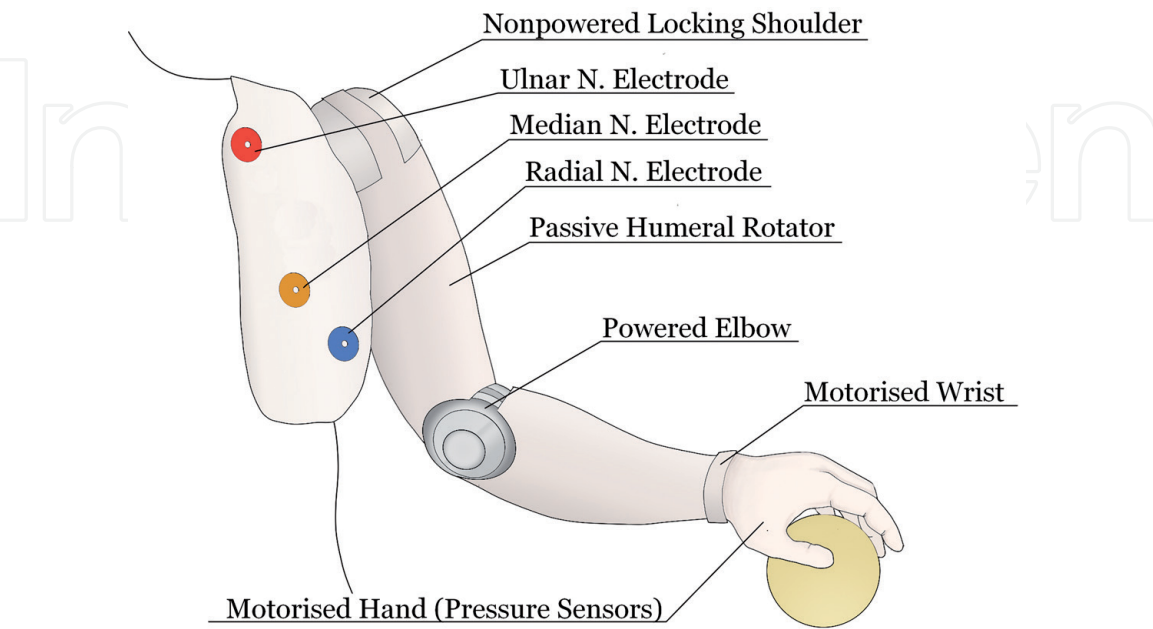
In recent years, scholars have shown great interest in how to enhance the prosthetic somatosensory and motor function of patients with traumatic neurological injuries wearing prostheses [22–25]. Northwestern University and the Chicago Institute of Rehabilitation for the first time proposed the use of TR technology to further improve the flexibility and accuracy of prosthetic sensation and motor function and successfully applied the technology to a male patient with a trans-shoulder fracture with myoelectric prosthesis [26]. Conventional myoelectric prosthetics rely on surface electromyographic amplitude changes for simple displacement of the hands and elbows [27]. Although such artificial limbs break-through the bottleneck of the robotic arm being difficult to move autonomously with personal consciousness, however, once the degree of amputation reaches above the elbow joint, the acquisition of electromyography (EMG) signals is extremely hard [28]. Due to insufficient accuracy and sensitivity, it is difficult to process the complex signals on the EMG of the wrist, thumb, and other parts [29]. TR transplants the amputated patient's nerves to the target muscles to avoid atrophic atrophy of the performing muscles and loss of motor function. By separating the original nerves that dominate the target muscles, it reestablishes the dominant relationship between the remaining important nerves and the target muscles [30]. Muscles are bioamplifiers for stump motion signals, which can convert cortical signals transmitted by newly implanted nerves into myoelectric signals to control prosthetic activity.

TR can reestablish the nerve-muscle innervation relationship. It can more intuitively use myoelectric signals to manipulate limb movements and improve myoelectric prosthetic control. The key to control is that each reinnervated muscle during TR surgery must only generate an EMG signal in response to transplantation to that nerve [31]. In 2009, Kuiken et al. [32] performed TR surgery on a woman with a shoulder joint amputation caused by a car accident. The patient's residual ulnar nerve was connected to the pectoralis major muscle, anastomosis of the median nerve with the pectoralis major at the sternum, and the musculocutaneous nerve was connected to the clavicle head of the pectoralis major muscle. At the same time, the primordial nerves that dominate the above muscles were separated, and the distal end of the long thoracic nerve was anastomosed with the radial nerve end, the distal end of the intercostal arm nerve was anastomosed with the median nerve side, anastomosis of the distal end of clavicle epithelial nerve with the ulnar nerve (see **Figure 2**). Six months after TR, the electrodes widely placed

on the patient’s chest could clearly record all myoelectric signals connected to the nerve. After rehabilitation training, the patient was very skilled in the operation of the prosthetic hands and elbows. When opening, closing, bending, or correcting the elbow, the prosthesis can respond in a timely and accurate manner. Later, after transforming the traditional three-degree-of-freedom myoelectric prosthesis [33] into six free vacation limbs (shoulder flexion, humerus rotation, elbow flexion, wrist rotation, wrist flexion, and hand control), including nonpowered locking shoulder, passive humeral rotator, powered elbow, motorized wrist, and motorized



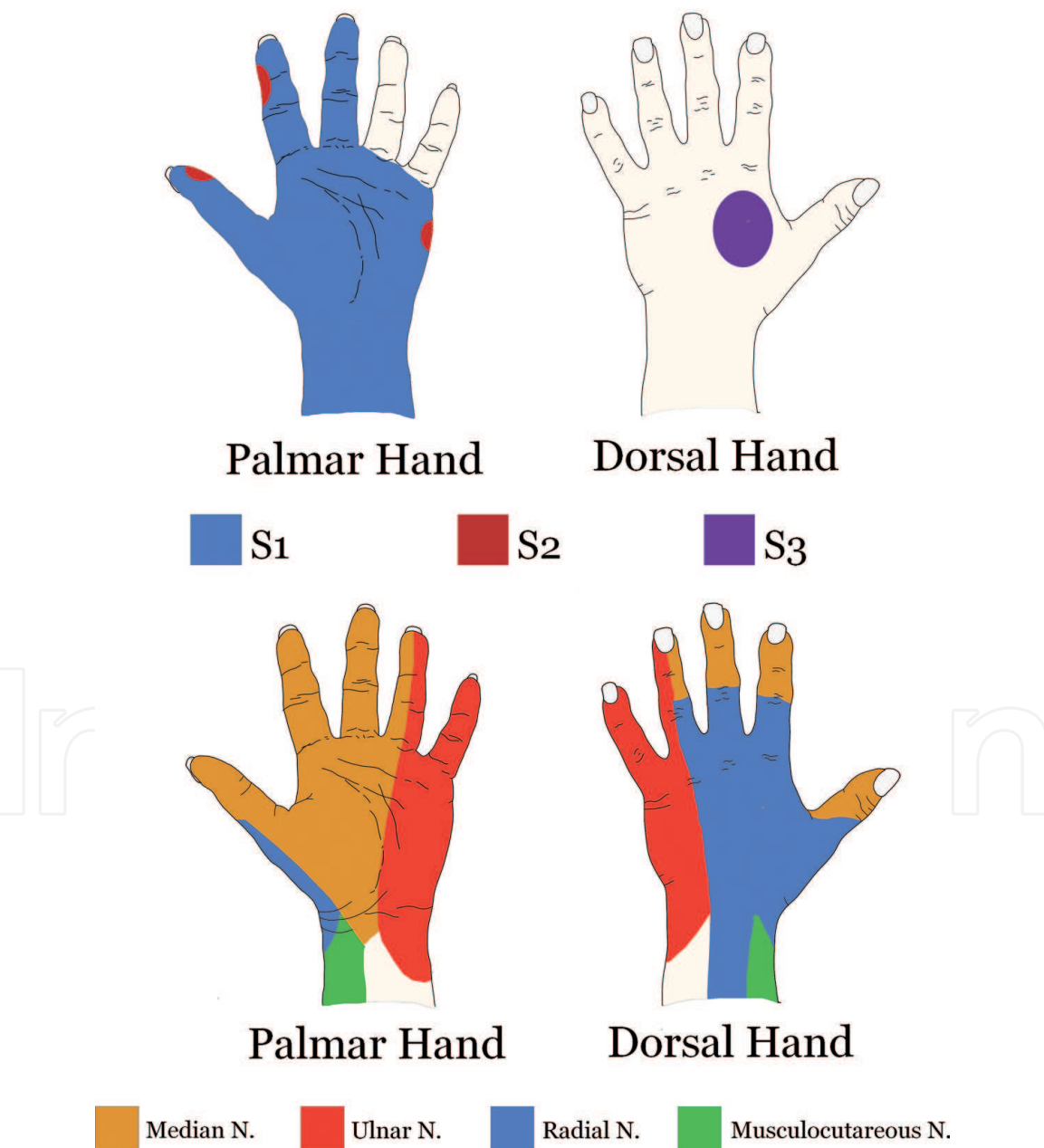
**Figure 2.** Schematics of TR surgery: the patient’s residual ulnar nerve was connected to the pectoralis major muscle, anastomosis of the median nerve with the pectoralis major at the sternum, and the musculocutaneous nerve was connected to the clavicle head of the pectoralis major muscle, the primordial nerves that dominate the above muscles were separated, and the distal end of the long thoracic nerve was anastomosed with the radial nerve end, the distal end of the intercostal arm nerve was anastomosed with the median nerve side, anastomosis of the distal end of clavicle epithelial nerve with the ulnar nerve (drawn by Lin).



**Figure 3.** Six free vacation limbs including nonpowered locking shoulder, passive humeral rotator, powered elbow, motorized wrist, and motorized hand with pressure sensors can lead motor of shoulder flexion, humerus rotation, elbow flexion, wrist rotation, wrist flexion, and hand control (drawn by Lin).

hand with pressure sensors (see **Figure 3**). The patient could perform various movements with high flexibility. After being equipped with pressure sensors at the hand control position, the thumb, index finger, and middle finger could cooperate to complete the basic grasping action.

Amputees wearing prosthetics need not only to have a flexible motor function but also to have a precise sensory function. Somatosensory signal input is an important part of the upper limbs performing motor functions, especially the fingertips are largely dependent on tactile perception of the surrounding environment information [34]. The field of perceptual tactile sensation is very complicated. In 2009 (Sensinger et al.) [35], skin touch tests were performed on three patients undergoing TR surgery. The first subject (S1) undergoes directional transplantation of the musculocutaneous nerve, median nerve, radial nerve, and ulnar nerve to the head of the pectoralis major clavicle and the head of the pectoralis major sternum.



**Figure 4.** Diagrams of skin sensation after TR surgery (referred to Sensinger et al): S1 skin test indicated that the tactile position was located on the back of the hand; S2 skin test showed that the tactile position was located on the outer edge of the index finger, thumb, and palm outer edge; and S3 skin test showed that the tactile position was located on the three fingers on palm and palm side.



Five and a half years of the innervation skin test indicated that the tactile position was located on the back of the hand. For the second subject (S2), the ulnar and musculocutaneous nerves were redirected to the medial and lateral halves of the clavicular head of the pectoralis major. A two-and-a-half year innervation skin test showed the tactile position on the outer edge of the index finger, thumb, and palm outer edge. The third subjects (S3) who underwent TR surgery of the distal radial and median nerves to the lateral head of the triceps brachii and the medial head of the biceps brachii. After 1 year of innervation skin test, the tactile position was located on the three fingers on palm and palm side (see **Figure 4**). Although compared with the normal sensory ability of innervating the hand, TR surgery failed to make the patient's prosthesis completely respond to sensory feedback, but the main sensory nerve pathways were basically established [36], especially the median nerve function recovery was ideal [37].

Nerves are prone to cause symptomatic neuromas during the repair process after traumatic injury. Clinically, neuroma resection or nerve traction is often used to relieve the pain symptoms of neuromas, but nearly 35% of patients do not control their pain symptoms after treatment. TR surgery connects the residual nerve with the target muscle or the corresponding nerve [35, 38]. Although it is difficult to ensure a one-to-one correspondence, compared with autologous nerve transplantation or transplantation, the cost is much smaller. Northwest Hospital counted 100 patients who underwent TR surgery and found that only one patient had symptomatic neuroma after surgery [39]. The data confirmed that TR had certain clinical significance for the prevention and treatment of neuromas.

In addition, due to the limited application of the lower limb electromyography device, the clinical effect of TMR in lower limb amputees is still unclear. At the same time, lower limb metabolic energy costs are higher. There are also complex problems such as sitting posture, asymmetric gait, and slope walking, which needed to carry out in-depth research to evaluate the application value of TMR.

### **3. Traditional Chinese medicine treatment**

There is no such thing as “peripheral nerve injury” in traditional Chinese medicine, but the symptoms after peripheral nerve injury are similar to “tendon injury” and “paralysis syndrome” in the category of traditional Chinese medicine meridian. Chinese medicine believes that the pathogenesis of this type of disease is Qi and blood disorders. Local stasis after peripheral nerve injury can cause Qi stagnation, Qi and blood circulation disorders in the meridians, and insufficient nutrition at the injury site, resulting in local tissue ischemia and abnormal body function. If the trauma severely causes the body to lose blood and Qi instantly, the Qi and blood cannot be delivered to the body, the limbs will become cold, and Qi stagnates blood stasis and then muscle atrophy, resulting in peripheral nerve somatosensory dysfunction [40]. Therefore, in view of the mechanism of Qi and blood dysfunction, Chinese medicine believes that it should be based on imagination and deficiency and based on Qi deficiency and blood stasis as the standard. Rehabilitation treatment methods including acupuncture, massage, fumigation, and heat compress can achieve certain results.

Acupuncture uses acupuncture to penetrate acupuncture points in the human body to achieve the purpose of treatment. For example, acupuncture at Jiquan can help regulate the balance of Qi and blood in the human body and enhance the smoothness of Qi and blood in the body; acupuncture at the Yangming Meridian and Sun Meridian can unblock meridians and reconcile Qi and blood [41]. Modern medical research shows that acupuncture can reduce myelin shedding, prevent axon

disintegration, and protect damaged neurons. He et al. [42] used acupuncture at Baihui (GV20), Fengfu (GV16), Dazhui (GV14), and Shenzhu (GV12) for patients with upper limb nerve injury and acupuncture at Zizhong (GV6), Mingmen (GV4), Yaoyangguan (GV3), and Yaoshu (GV2) for patients with lower limb nerve injury and found that the speed and range of motor nerve transmission were large after treatment, which suggested that acupuncture at various points could effectively enhance nerve excitability and relieve conduction dysfunction; in addition, electroacupuncture could accelerate blood flow in blood vessels, improve blood supply, and thus improve the degree of muscle atrophy. Li et al. [43] found that the content of myelin basic protein MBP in the nerve tissue of the sciatic nerve injury rat model group after acupuncture was significantly higher than that of the control group. The increase of MBP and its antibody expression can promote the release of neurotrophic factor 3, reduce the shedding of myelin sheath, inhibit the apoptosis of nerve cells, and promote the repair of injured sciatic nerve.

Moxibustion ignites the moxa with fire, burns the acupuncture points, penetrates the heat into the skin, and warms the blood. Moxibustion stimulates acupoints on the body surface in this way and regulates the functions of Qi, blood, and internal organs through the conduction of meridians throughout the body. After peripheral nerve injury, the use of moxibustion can significantly reduce the degree of muscle atrophy and help restore muscle regeneration [44]. The early use of moxibustion can alleviate muscle atrophy and restore neuronal function.

The massage technique can relax the muscles, clear the vital energy, loosen the joints, and relieve the pressure, thereby alleviating the local muscle spasm and promoting the blood circulation. In traditional Chinese medicine treatment of peripheral nerve injury, massage can improve the behavior and morphology of peripheral nerve injury. Lu et al. [45] found that the myelin sheath structure of myelinated nerve fibers in rats with sciatic nerve injury treated by massage tends to be complete. The morphology and structure are arranged neatly, and the thickness of myelin sheath and axonal diameter are significantly restored, indicating that massage can effectively promote the recovery of somatosensory function after sciatic nerve injury.

Traditional Chinese medicine fumigation is a treatment method that acts on the body through the permeability of the skin by virtue of the dual effects of medicine and heat. Traditional Chinese medicine fumigation therapy is based on the principle of syndrome differentiation and treatment of traditional Chinese medicine, and according to the needs of disease treatment, certain Chinese medicines are selected to form fumigation prescriptions. The combination of medicinal power and thermal power plays a role. During fumigation, due to the warm and hot stimulation, the medicine gas and heat can reach the disease site directly, which can promote the blood circulation and lymph circulation of the local and the whole body; improve the nutrition of the local tissues; promote the whole body function; dredge the meridians and collaterals; promote the circulation of Qi and blood; eliminate swelling and stasis; relieve the tension and pressure of the local tissues; relieve the tension or rigidity of the skin, muscles, tendons, and ligaments; and make the joints and limbs move flexible to promote early recovery of limb function [46].

After acupuncture, moxibustion, and fumigation act on acupoints and meridians on the body surface, the stem or peripheral nerves are stimulated, and the paralyzed nerves are passively excited and reflexive, which promote nerve fiber repair. Therefore, the clinical development of modern rehabilitation methods combined with traditional Chinese medicine acupuncture and massage is an effective method to relieve pain, improve peripheral nerve somatosensory function, and prevent muscle atrophy after brachial plexus injury. It is hoped that it will be promoted in clinical applications.

## 4. Summary

Nerve injury is a common clinical disease with an incidence of about 1 million cases per year [47]. According to foreign data, the excellent and good rate of repairing peripheral nerve injury is less than half [48], and the disability rate is high. At present, primary doctors are familiar with peripheral nerve injury, but their understanding and practical operation of the theory of peripheral nerve injury still have many shortcomings and even cannot suture the injured nerve with high quality. The situation is very serious. Gu [49] proposed that the key points of successful regeneration of peripheral nerves include the following:

- survival of injured neuron cell bodies;
- budding and extension of proximal axons and growth into distal endometrial basement membrane canals of the same function;
- reconstructing synaptic connections between regenerated axons and corresponding target organs, restoration of target organs of nerve reinnervation;
- synthesis of neurotransmitters and related enzymes of neurons. Specific substances restore nerve conduction, axonal transport, and control of target organs;
- the central nervous system can collect and integrate peripheral nerve signals.

At present, surgeons have limited ability to intervene in the repair and regeneration of peripheral nerve injuries clinically. For instance, they can only intervene including the choice of repair time, repair methods, and rehabilitation retraining. Therefore, they should grasp the “golden time” of 1–3 months after injury, adhere to the concept and technology of microrepair, and pay attention to major basic principles such as normal tissues, tension free, the matching of nerve bundle type and function, base bed, and blood supply.

In summary, with the rapid development of modern medical technology, the continuous research of tissue genetic engineering, and the development of traditional Chinese medicine, the methods and types of peripheral nerve repair after injury are much more in depth. The treatment techniques described in this chapter enrich the treatment methods and therapeutic effects and should be selected according to the specific conditions in clinical practice. However, there are still many problems, such as the promotion of many drugs on nerve regeneration and repair, but the specific mechanism is still unclear, which needs further study [50]. Therefore, great efforts still need to be made to find new repair methods in order to improve the effect of nerve recovery.

## Acknowledgements

The completion of the chapter is attributed to many people's support and encouragement. First and foremost, I want to extend my heartfelt gratitude to supervisor, Professor Guanglin Li, whose patient guidance, valuable suggestions, and constant encouragement make me successfully complete this chapter. He gives me much help and advice during the whole process of my writing, which has made my accomplishments possible.

Also, I would like to express my sincere gratitude to the fund supports of National Natural Science Foundation of China (Grant Nos. U1613222, 81960419, and 81760416) and also to thank the Key Laboratory of Human-Machine-Intelligence Synergic System, Shenzhen Institutes of Advanced Technology, Chinese Academy of Sciences.

Last my thanks would go to my student, Ms. Qianling Zhang who search and collect of references for the completion of this chapter.

### **Author details**


Lin Yang<sup>1</sup> and Ping Wang<sup>2\*</sup>

1 Department of Human Anatomy, Zhuhai Campus of Zunyi Medical University, Zhuhai, China

2 Zhuhai Campus of Zunyi Medical University, Zhuhai, China

\*Address all correspondence to: 582578502@qq.com

### **IntechOpen**

© 2020 The Author(s). Licensee IntechOpen. This chapter is distributed under the terms of the Creative Commons Attribution License (<http://creativecommons.org/licenses/by/3.0>), which permits unrestricted use, distribution, and reproduction in any medium, provided the original work is properly cited. 



## References

- [1] Jaeger MR, Bragasilva J. End-to-end versus end-to-side motor and sensory neurorrhaphy in the repair of the acute muscle denervation. *Annals of Plastic Surgery*. 2014;**67**(4):391. DOI: 10.1097/SAP.0b013e3182126816
- [2] Haninec P, Filip S, et al. Direct repair (nerve grafting), neurotization, and end-to-side neurorrhaphy in the treatment of brachial plexus injury. *Journal of Neurosurgery*. 2007;**106**(3):391-399. DOI: 10.3171/jns.2007.106.3.391
- [3] Viterbo F. Two end-to-side neurorrhaphies and nerve graft with removal of the epineural sheath : Experimental study in rats. *British Journal of Plastic Surgery*. 1994;**47**(2):75-80. DOI: 10.1016/0007-1226(94)90162-7
- [4] Tarasidis G, Watanabe O, Mackinnon SE, et al. End-to-side neurorrhaphy: A long-term study of neural regeneration in a rat model. *Otolaryngology - Head and Neck Surgery*. 1998;**119**(4):341. DOI: 10.1016/s0194-5998(98)70074-9
- [5] Yu Q, Zhang SH, Wang T, et al. End-to-side neurorrhaphy repairs peripheral nerve injury: Sensory nerve induces motor nerve regeneration. *Neural Regeneration Research*. 2017;**012**(010):1703-1707. DOI: 10.4103/1673-5374.217350
- [6] Reichert P, Kiełbowicz Z, Kuryszko J, et al. Gait analysis after neurorrhaphy in the brachial plexus. *Polish Journal of Veterinary Sciences*. 2015. DOI: 10.1515/pjvs-2015-0047
- [7] Stålberg E, Dijk HV, Falck B, et al. Standards for quantification of EMG and neurography. *Clinical Neurophysiology*. 2019. DOI: 10.1016/j.clinph.2019.05.008
- [8] Qiao HY. Comparative Effect of Nerve End-to-Side and Side-to-Side Neurorrhaphy on Prevention and Treatment of Denervated Muscle Atrophy. Shanxi Medical University; 2005
- [9] Zhou Z. Experimental study on the prevention of denervated muscle atrophy by side-to-side neurorrhaphy. *Journal of Fujian Medical University*. 2002;**03**:292. DOI: CNKI:SUN:FJYD.0.2002-03-025
- [10] Rönkkö H, Göransson H, et al. Protective distal side-to-side neurorrhaphy in proximal nerve injury-an experimental study with rats. *Acta Neurochirurgica*. 2019;**161**(4):645-656. DOI: 10.1007/s00701-019-03835-2
- [11] Oberlin C, Béal D, Leechavengvongs S, et al. Nerve transfer to biceps muscle using a part of ulnar nerve for C5–C6 avulsion of the brachial plexus: Anatomical study and report of four cases. *The Journal of Hand Surgery*. 1994;**19**(2):232-237. DOI: 10.1016/0363-5023(94)90011-6
- [12] Gu Y, Zhang G, Chen D, et al. Seventh cervical nerve root transfer from the contralateral healthy side for treatment of brachial plexus root avulsion. *The Journal of Hand Surgery*. 1992;**17**(5):518-521. DOI: 10.1016/S0266-7681(05)80235-9
- [13] Battiston B, Titolo P, Ciclamini D, et al. Peripheral nerve defects: Overviews of practice in Europe. *Hand Clinics*. 2017;**33**(3):545. DOI: 10.1016/j.hcl.2017.04.005
- [14] Gordon T, Borschel GH. The use of the rat as a model for studying peripheral nerve regeneration and sprouting after complete and partial nerve injuries. *Experimental Neurology*. 2016;**287**(3):331-347. DOI: 10.1016/s0140-6736(07)60193-7

- [15] Hood B, Levene HB, Levi AD. Transplantation of autologous Schwann cells for the repair of segmental peripheral nerve defects. *Neurosurgical Focus*. 2009;**26**(2):E4. DOI: 10.3171/FOC.2009.26.2.E4
- [16] Lassner F, Becker M, Berger A, et al. Degeneration and regeneration in nerve autografts and allografts. *Microsurgery*. 1995;**16**(1):4-8. DOI: 10.1002/micr.1920160104
- [17] Arthur-Farraj PJ, Morgan CC, Adamowicz M, et al. Changes in the coding and non-coding transcriptome and DNA methylome that define the Schwann cell repair phenotype after nerve injury. *Cell Reports*. 2017;**20**(11):2719-2734. DOI: 10.1016/j.celrep.2017.08.064
- [18] Mackinnon SE, Doolabh VB, Novak CB, et al. Clinical outcome following nerve allograft transplantation. *Plastic and Reconstructive Surgery*. 2001;**107**(6):1419-1429. DOI: 10.1097/00006534-200105000-00016
- [19] O'Rourke C, AGE D, Murray-Dunning C, et al. An allogeneic 'off the shelf' therapeutic strategy for peripheral nerve tissue engineering using clinical grade human neural stem cells. *Scientific Reports*. 2018;**8**(1):2951. DOI: 10.1038/s41598-018-20927-8
- [20] Gao Y, Wang Y-l, Kong D, et al. Nerve autografts and tissue-engineered materials for the repair of peripheral nerve injuries: A 5-year bibliometric analysis. *Neural Regeneration Research*. 2015;**6**:1003-1008. DOI: 10.4103/1673-5374.158369
- [21] Moore AM, Wagner IJ, Fox IK. Principles of nerve repair in complex wounds of the upper extremity. *Seminars in Plastic Surgery*. 2015;**29**(1):40-47. DOI: 10.1055/s-0035-1544169
- [22] Marasco PD, Kuiken TA. Amputation with median nerve redirection (targeted Reinnervation) reactivates forepaw barrel subfield in rats. *Journal of Neuroscience*. 2010;**30**(47):16008-16014. DOI: 10.1055/s-0035-1544166
- [23] Schiefer M, Tan D, Sidek SM, et al. Sensory feedback by peripheral nerve stimulation improves task performance in individuals with upper limb loss using a myoelectric prosthesis. *Journal of Neural Engineering*. 2016;**13**(1):016001. DOI: 10.1088/1741-2560/13/1/016001
- [24] Souza JM, Cheesborough JE, Ko JH, et al. Targeted muscle reinnervation: A novel approach to postamputation neuroma pain. *Clinical Orthopaedics and Related Research*. 2014;**472**(10):2984-2990. DOI: 10.1523/JNEUROSCI.4044-10.2010
- [25] Lowery MM, Stoykov NS, Taflove A, et al. A multiple-layer finite-element model of the surface EMG signal. *IEEE Transactions on Biomedical Engineering*. 2002;**49**(5):446-454. DOI: 10.1109/10.995683
- [26] Kuiken TA, Marasco PD, Lock BA, et al. Redirection of cutaneous sensation from the hand to the chest skin of human amputees with targeted reinnervation. *Proceedings of the National Academy of Sciences of the United States of America*. 2007;**104**(50):20061-20066. DOI: 10.1073/pnas.0706525104
- [27] Wijk U, Carlsson I. Forearm amputees' views of prosthesis use and sensory feedback. *Journal of Hand Therapy*. 2015;**28**(3):269-278. DOI: 10.1016/j.jht.2015.01.013
- [28] Dumanian GA, Ko JH, O'Shaughnessy KD, et al. Targeted reinnervation for transhumeral amputees: Current surgical technique and update on results. *Plastic and Reconstructive Surgery*.

2009;**124**(3):863-869. DOI: 10.1097/prs.0b013e3181b038c9

[29] Antfolk C, D'Alonzo M, Rosén B, et al. Sensory feedback in upper limb prosthetics. *Expert Review of Medical Devices*. 2013;**10**(1):45-54. DOI: 10.1586/erd.12.68

[30] Cheesborough JE, Smith LH, Kuiken TA, et al. Targeted muscle reinnervation and advanced prosthetic arms. *Seminars in Plastic Surgery*. 2015;**29**(1):62-72. DOI: 10.1097/SLA.0000000000003088

[31] Huang H, Zhou P, Li G, et al. An analysis of EMG electrode configuration for targeted muscle reinnervation based neural machine interface. *IEEE Transactions on Neural Systems and Rehabilitation Engineering*. 2008;**16**(1):37-45. DOI: 10.1055/s-0035-1544166

[32] Kuiken TA, Miller LA, Lipschutz RD, et al. Targeted reinnervation for enhanced prosthetic arm function in a woman with a proximal amputation: a case study. *Lancet (North American Edition)*. 2007;**369**(9559):380. DOI: 10.1016/s0140-6736(07)60193-7

[33] Miller LA, Lipschutz RD, Stubblefield KA, et al. Control of a six degree of freedom prosthetic arm after targeted muscle Reinnervation surgery. *Archives of Physical Medicine and Rehabilitation*. 2008;**89**(11):2065. DOI: 10.1016/j.apmr.2008.05.016

[34] Micera S. Staying in touch: Toward the restoration of sensory feedback in hand prostheses using peripheral neural stimulation. *IEEE Pulse*. 2016;**7**(3):16-19. DOI: 10.1109/MPUL.2016.2539760

[35] Sensinger JW, Schultz AE, Kuiken TA. Examination of force discrimination in human upper limb

amputees with Reinnervated limb sensation following peripheral nerve transfer. *IEEE Transactions on Neural Systems and Rehabilitation Engineering*. 2009;**17**(5):438-444. DOI: 10.1109/TNSRE.2009.2032640

[36] Yao J, Chen A, Kuiken T, et al. Sensory cortical re-mapping following upper-limb amputation and subsequent targeted reinnervation: A case report. *NeuroImage: Clinical*. 2015;**8**:329-336. DOI: 10.1016/j.nicl.2015.01.010

[37] Wall JT, Kaas JH, Sur M, Nelson RJ, Felleman DJ, Merzenich MM. Functional reorganization in somatosensory cortical areas 3b and 1 of adult monkeys after median nerve repair: possible relationships to sensory recovery in humans. *The Journal of Neuroscience*. 1986;**6**(1):218-233. DOI: 10.1523/JNEUROSCI.06-01-00218

[38] Osborn L, Kaliki RR, Soares AB, et al. Neuromimetic event based detection for closed-loop tactile feedback control of upper limb prostheses. *IEEE Transactions on Haptics*. 2016;**9**(2):196-206. DOI: 10.1109/TOH.2016.2564965

[39] Mioton LM, Dumanian GA, Cheesborough J, et al. targeted muscle Reinnervation successfully treats neuroma pain and phantoms in major limb amputees: A randomized clinical trial. *Journal of Neurosurgery*. 2018;**65**(1):86-86. DOI: 10.1093/neuros/nyy303.117

[40] Zhang MX, Zhang Y, Bian YH, et al. Effect of long-term electroacupuncture stimulation on recovery of sensorimotor function after peripheral nerve anastomosis. *Acupuncture in Medicine*. 2018;**36**(3):170-175. DOI: 10.1136/acupmed-2017-011367

[41] Wu J, Lu Y, Hua X, et al. Cortical remodeling after electroacupuncture therapy in peripheral nerve repairing

model. Brain Research. 2018;**1690**:61-73. DOI: 10.1016/j.brainres.2018.04.009

[42] He GH, Ruan JW, Zeng YS, et al. Improvement in acupoint selection for acupuncture of nerves surrounding the injury site: Electro-acupuncture with governor vessel with local meridian acupoints. Neural Regeneration Research. 2015;**10**(1):128-135. DOI: 10.4103/1673-5374.150720

[43] Li XQ, Yu TY, Yu Y, et al. Effects of electroacupuncture on serum myelin basic protein and its antibody in rats with sciatic nerve injury. Journal of Beijing University of Traditional Chinese Medicine. 2015;**38**(12):842-846. DOI: 10.3969/j.issn.1006-2157.2015.12.010

[44] Hu LN, Guo HD, Tian JX, et al. Electroacupuncture and moxibustion promote regeneration of injured sciatic nerve through Schwann cell proliferation and nerve growth factor secretion. Neural Regeneration Research. 2018;**013**(003):477-483. DOI: 10.4103/1673-5374.228731

[45] Lu MQ, Yu TY, Yao BB, et al. Effects of tuina therapy on the neural ultrastructure of sciatic nerve injury model rats. Journal of Nanjing University of Traditional Chinese Medicine. 2015;**31**(4):349-352. DOI: 10.14148/j.issn.1672-0482.2015.0349

[46] Wang XL, Zhu XP, Ji DX, et al. Beneficial effect of traditional Chinese medicine fumigation “bone-healing powder” in postoperative pain and recovery of neurological function of traumatic thoracolumbar spine fractures: A case-control study. Medicine. 2018;**97**(35):e11983. DOI: 10.1097/MD.00000000000011983

[47] Shao SJ. Acupuncture therapy for peripheral nerve injury. Modern Rehabilitation. 2000;(11). DOI: 10.3321/j.issn:1673-8225.2000.11.006

[48] Zhang MX, Liu YY, Liu JW, et al. The clinical research progress of electroacupuncture treatment of peripheral nerve injury. Bright Chinese Medicine. 2016;**31**(08):1196. DOI: CNKI:SUN:GMZY.0.2016-08-074

[49] Liu XJ, Cheng Q, Ding F. Experimental study on the regeneration of mouse sciatic nerve by nerve regeneration extract from *Achyranthes bidentata*. Shizhen Guo Yi Guo Yao. 2009;**20**(01):16-18. DOI: 10.3969/j.issn.1008-0805.2009.01.008

[50] Liu H, Liu YJ, Liu ZH. Study on the neurotrophic effect of *Astragalus membranaceus* extract. Journal of Practical Medicine. 2010;**26**(14):2480-2482. DOI: CNKI:SUN:SYYZ.0.2010-14-007