

We are IntechOpen, the world's leading publisher of Open Access books Built by scientists, for scientists

6,900

Open access books available

185,000

International authors and editors

200M

Downloads

Our authors are among the

154

Countries delivered to

TOP 1%

most cited scientists

12.2%

Contributors from top 500 universities



WEB OF SCIENCE™

Selection of our books indexed in the Book Citation Index
in Web of Science™ Core Collection (BKCI)

Interested in publishing with us?
Contact book.department@intechopen.com

Numbers displayed above are based on latest data collected.
For more information visit www.intechopen.com



Pelvic Organ Prolapse: Examination and Assessment

Priyanka Bhadana

Abstract

Pelvic organ prolapse (POP) is a common, benign condition in women, and patient can present with complaints of vaginal bulge and pressure, voiding and defecatory, and sexual dysfunction, which may adversely affect quality of life. Although POP can occur in younger women, it is commonly seen in aging population with a prevalence of 45–50%. Older terms describing pelvic organ prolapse (e.g., cystocele, urethrocele, rectocele) have been replaced because they do not provide complete information regarding the structures on the other side of the vaginal bulge, especially in women who have had previous pelvic organ prolapse surgery. Therefore, a thorough history and performing a careful physical examination with dignity and care, using some basic tools that aid in the accurate evaluation of anatomical and functional defects, should be conducted. A standardized assessment system has been used to document findings which should explain everything in understandable terms.

Keywords: uterovaginal prolapse, POP-Q

1. Introduction

Pelvic organ prolapse (POP) is the herniation of the pelvic organs to or beyond the vaginal walls. Many women with prolapse experience symptoms that impact daily activities, sexual function, and exercise. The presence of POP can have a detrimental impact on body image and sexuality. Pelvic organ prolapse is an increasingly common condition seen with aging population with a prevalence of 41–50% of women above 40 years. The annual incidence of surgery for POP is within the range of 15–49 cases per 10,000 women years [1]. Pelvic floor defects result from attenuation of the supportive structures or by neuromuscular dysfunction due to obstetric trauma. Pregnancy itself, without vaginal birth, has been cited as a risk factor as well. Genital atrophy and hypoestrogenism also play important contributory roles in the pathogenesis of prolapse. However, the exact mechanisms are not completely understood. Prolapse may potentially result from pelvic tumors, sacral nerve disorders, and diabetic neuropathy [2].

Older terms describing pelvic organ prolapse (e.g., cystocele, urethrocele, rectocele) have been replaced because they do not provide complete information regarding the structures on the other side of the vaginal bulge, especially in women who have had previous pelvic organ prolapse surgery.

Presently, the pelvis is divided into anterior, posterior, and middle or apical compartments. Following hysterectomy, prolapse of the vaginal apex with or without prolapse of the anterior and/or posterior vaginal wall is referred to as vault prolapse [2, 3].

2. Classification of pelvic organ prolapse

Pelvic organ support is maintained by complex interactions between the vagina, levator ani muscle, and pelvic floor connective tissue. A system of three integrated levels of vaginal support has been described by De Lancey [1].

- Level 1: The cardinal uterosacral ligament complex.
- Level 2: Midvaginal supports—pubocervical and rectovaginal fascia.
- Level 3: Urogenital diaphragm and the perineal body.

The prolapse is usually described according to the area of the vagina in which it occurs. Assumptions are often made about which organ is behind the vaginal wall that is prolapsing.

Anatomical classification according to vaginal wall:

- Anterior: cystocele (bladder most common) and urethrocele (urethra).
- Middle: vault of the uterus (after hysterectomy).
- Posterior: rectocele (rectum) and enterocele (small bowel, omentum).

2.1 Shaw's classification

- Anterior wall
 - Upper 2/3 cystocele
 - Lower 1/3 urethrocele
- Posterior wall
 - Upper 1/3 enterocele
 - Middle 1/3 rectocele
 - Lower 1/3 deficient perineum
- Uterine prolapse
 - Grade 0: Normal position
 - Grade 1: Descent into vagina not reaching the introitus

- Grade 2: Descent up to the introitus
- Grade 3: Descent outside the introitus
- Grade 4: Procidentia [2]
- Uterovaginal prolapse usually occurs in nulliparous prolapse due to congenital weakness of cervical ligaments.
- Vaginouterine prolapse usually occurs in cases of prolapse resulting from obstetrical trauma.

3. Pelvic organ prolapse quantification system (POP-Q)

Pelvic organ prolapse quantification system refers to an objective, site-specific system for describing, quantifying, and staging pelvic support in women (**Figure 1**). It provides a standardized tool for documenting, comparing, and communicating clinical findings with proven interobserver and intraobserver reliability. The POP-Q system gained the attention of the specialists all over the world, being approved by the International Continence Society (ICS), the American Urogynecologic Society (AUGS), and the Society of Gynecologic Surgeons for the description of female pelvic organ prolapse. It is the most common system used by gynecologists and urogynecologists, although other systems have been devised (**Figures 2–9**) [4].

The POP-Q may be an easier classification system to use in routine clinical practice. It was developed by the International Urogynecological Association to provide a less cumbersome exam tool [4]. The POP-Q stages (**Table 1**) prolapse

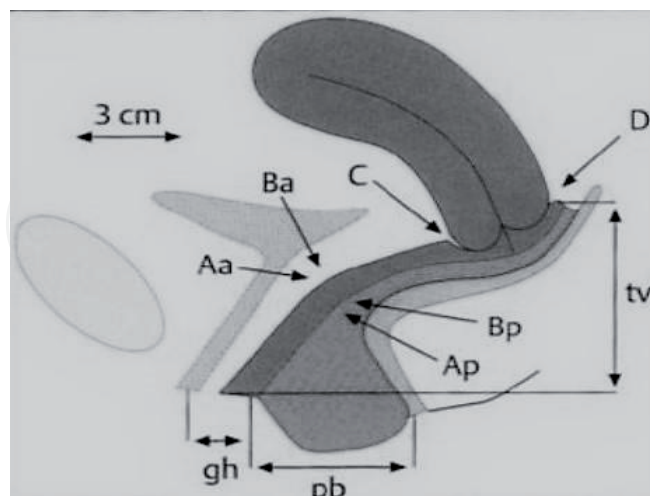


Figure 1.

POP-Q points. Aa, anterior vaginal wall 3 cm proximal to the urethral meatus (–3 cm to +3 cm); Ba, most distal position of the remaining upper anterior vaginal wall (–3 cm to +tvl); C, most distal edge of cervix or vaginal cuff scar; D, posterior fornix (n/a if posthysterectomy); Ap, posterior vaginal wall 3 cm proximal to the hymen (–3 cm to +3 cm); Bp, most distal position of the remaining upper posterior vaginal wall (–3 cm to + tvl); genital hiatus (gh), measured from the middle of external urethral meatus to the posterior midline hymen; perineal body (pb), measured from the posterior margin of gh to the middle of anal opening; total vaginal length (tvl), depth of the vagina when point D or C is reduced to normal position.

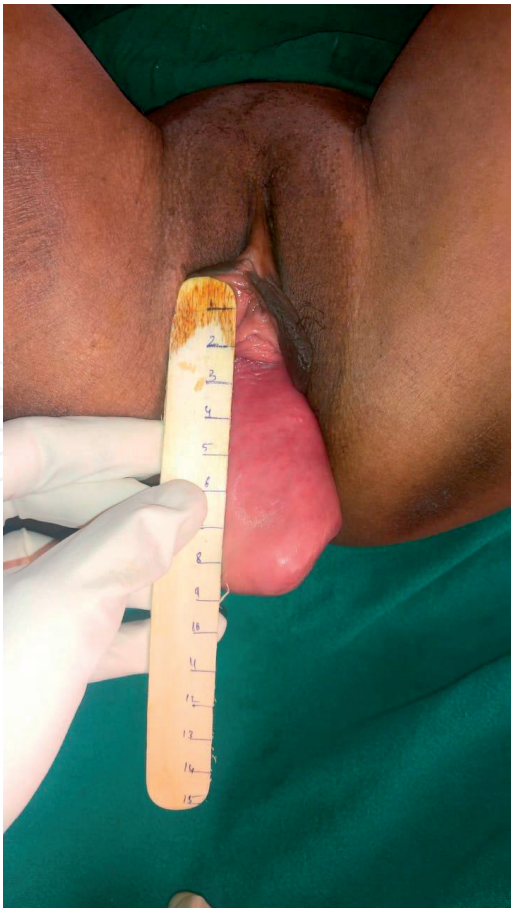

Figure 2.
Point Aa being measured by graded spatula.

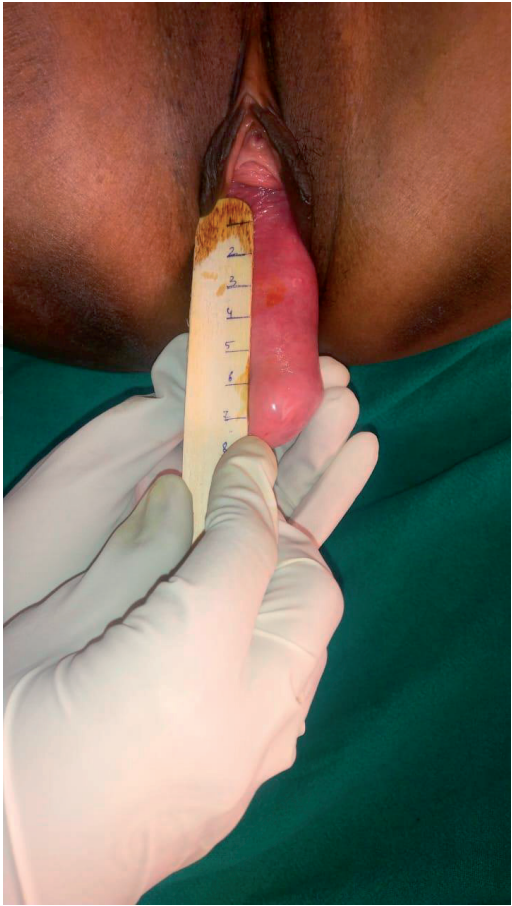


Figure 3.
Point Ba being measured by graded spatula.

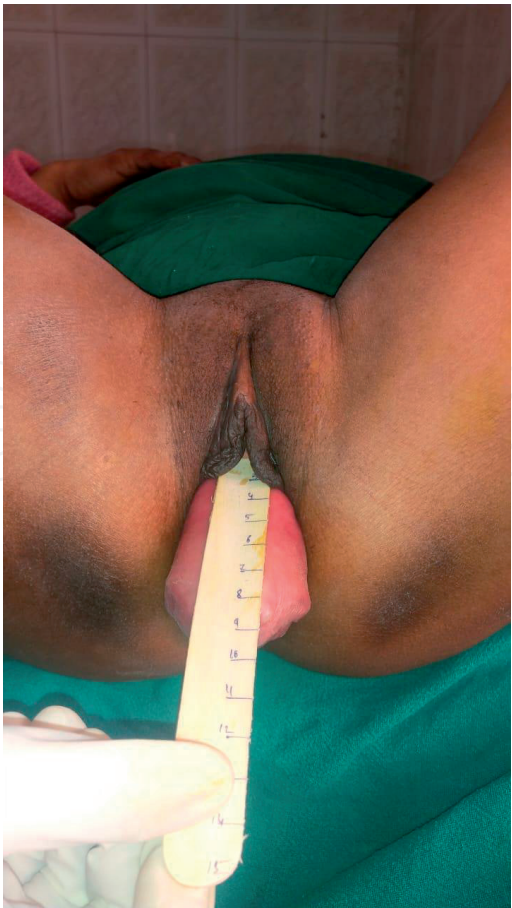

Figure 4.
Point C.

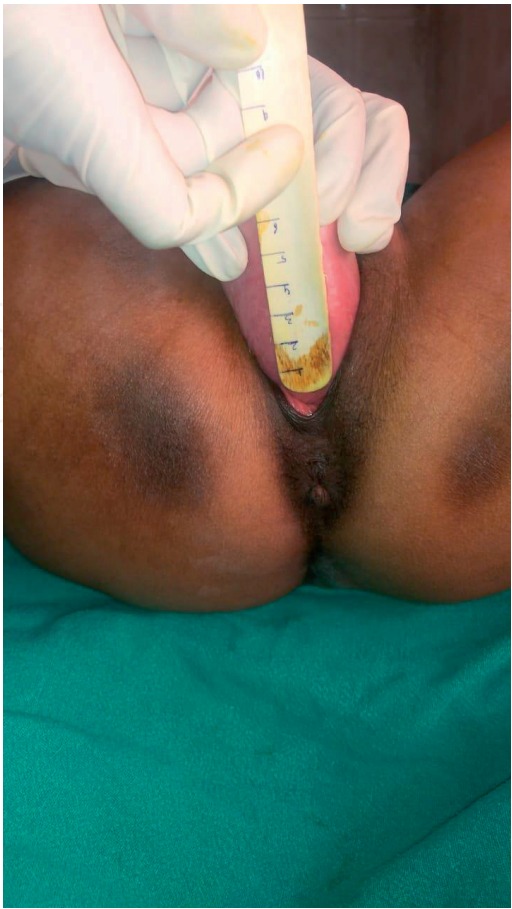

Figure 5.
Point Ap.

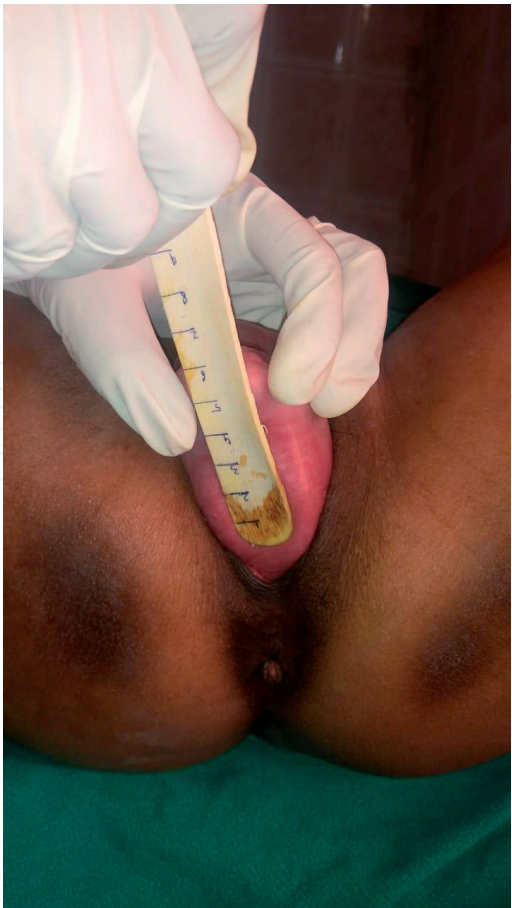

Figure 6.
Point Bp.

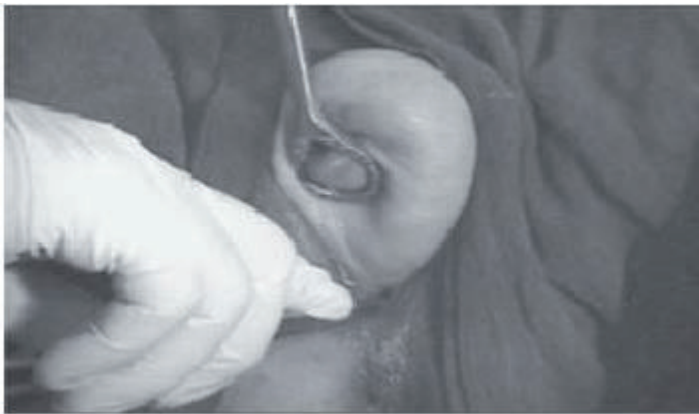

Figure 7.
Point D.

for the anterior and posterior vaginal walls, the apex/cuff of the vagina and the cervix. For women posthysterectomy, there are three stages; for women with an intact uterus, there are four. The exam is carried out similarly to the standard POP-Q exam, with a half speculum placed in the vagina to visualize the vaginal walls and cervix.

A disadvantage of POP-Q is that all points and measures are taken in the mid-line; as a consequence, the POP-Q does not reflect asymmetries and cannot be used to describe, for example, paravaginal defects. One has also to keep in mind that the POP-Q depends on the cooperation of the patient and to the strength of her cough or Valsalva maneuver; it is therefore unreasonable to assume that in an individual patient, the POP-Q will always be identical [4].

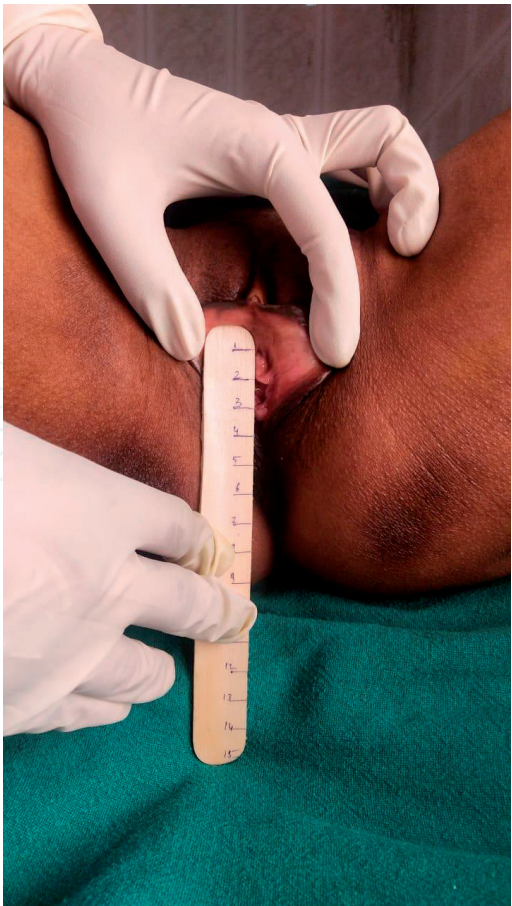

Figure 8.
Genital hiatus (gh).

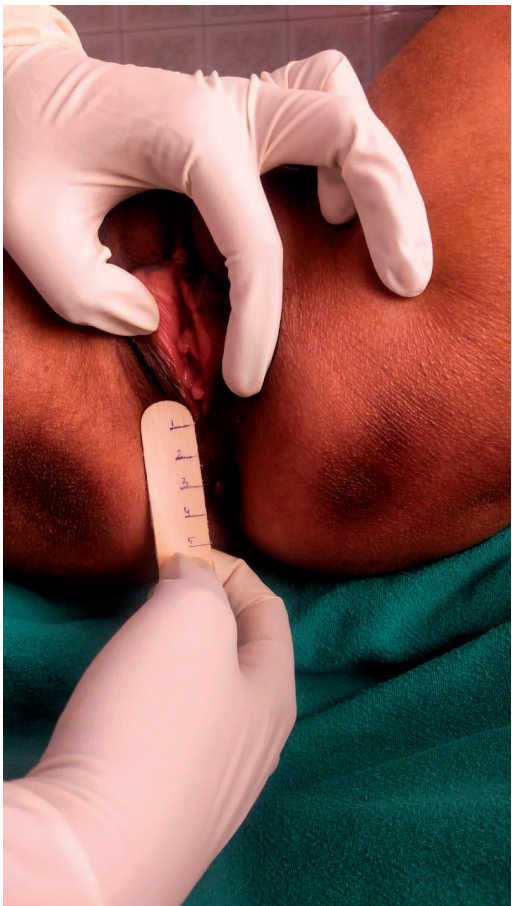


Figure 9.
Perineal body (P_b).

Pelvic organ prolapse quantification system	
Stage	Description
0	No prolapse
I	>1 cm above the hymen
II	≤1 cm proximal or distal to the plane of the hymen
III	>1 cm below the plane of the hymen, but protrudes no farther than 2 cm less than the total vaginal length
IV	Eversion of the lower genital tract is complete
<i>POP-Q staging criteria.</i> <i>Stage 0: Aa, Ap, Ba, Bp = −3 cm and C or D ≤ − (tvL − 2) cm.</i> <i>Stage I: Stage 0 criteria not met and leading edge < −1 cm.</i> <i>Stage II: Leading edge ≥ −1 cm but ≤ +1 cm.</i> <i>Stage III: Leading edge > +1 cm but < + (tvL − 2) cm.</i> <i>Stage IV: Leading edge ≥ + (tvL − 2) cm [3, 4].</i>	

Table 1.
Evaluation/staging of pelvic organ prolapse.

4. History

Most patients with pelvic organ prolapse are asymptomatic. Seeing or feeling a bulge of tissue that protrudes to or past the vaginal opening is the most specific symptom.

4.1 Bulge in the vagina

During a well-woman examination, she should be asked regarding any obvious bulge seen or felt in vagina. The report of a bulge has an 81% positive predictive value and a 76% negative predictive value for pelvic organ prolapse. Patient may complain of an increase in bulging and discomfort with progression of day [1]. Extensive standing, lifting, coughing, and physical exertion may increase patient awareness of discomfort in the pelvis, vagina, abdomen, and low back. Pelvic organ prolapse may progress with increasing body mass index. Weight loss does not reverse the prolapse.

4.2 Vaginal discharge

Vaginal discharge may be present in patients with complete uterine prolapse (i.e., procidentia) who have a decubitus ulcer of the cervix or vagina.

4.3 Urinary symptoms

Patients may have difficulty urinating—stress incontinence affects 40% of patients with pelvic organ prolapse; therefore, they should be asked about frequency, urgency, and sensation of incomplete emptying of the bladder, because they may not volunteer such information. Urinary outlet obstruction may occur because of the pressure on the urethra in anterior vaginal prolapse and sometimes in large posterior vaginal prolapse. Screening is advocated for urinary tract infection, postvoid residual urine volume, and the presence or absence of bladder sensation.

Symptoms may not correlate with the location or severity of the prolapsed compartment.

4.4 Bowel symptoms

Patients with posterior vaginal prolapse sometimes use manual pressure on the perineum or posterior vagina to help with defecation. These maneuvers are called “splinting.”

4.5 Back pain

Though patients of prolapse attribute back and pelvic pain to their prolapse, very little evidence is available to show that this disorder causes pain, so other causes of pain should be ruled out.

4.6 Sexual discomfort

Sexual activity, body image, and quality of life may be affected [3].

5. Examination

5.1 General physical examination

Assessment will include weight, body mass index, and blood pressure, as well as assessment of any varicose veins or hypermobile joints, since these can be markers of a tendency to connective tissue laxity which predisposes to POP and, importantly, to recurrence after surgical repair [2].

5.2 Abdominal examination

On examination of the abdomen, inspect for incisions of previous surgery (which may be associated with intra-abdominal adhesions affecting subsequent surgical approaches), and exclude masses or ascites. The presence of umbilical or other hernia can again indicate underlying connective tissue weakness and may require concomitant surgical correction [2, 3].

5.3 Local examination

On inspection of the vulva, note the presence of any atrophy and whether there is any ulceration of prolapsed tissues that may require local estrogen therapy before surgery. Wide genital hiatus with visible vaginal walls or midline asymmetry on Valsalva shows levator ani damage.

For stress urinary incontinence, the patient needs to be examined with full bladder and asked to cough or strain, and leakage of urine confirms positive stress provocation test.

On examination in lithotomy position, if there is visible vaginal bulge, look for vaginal wall rugosities which predict an intact fascial layer in the midline and a probable lateral defect, or if absent, it suggests a midline defect with only the skin and attenuated connective tissue present.

6. Examination in various positions

6.1 Standing position

In some mild cases of vaginal wall and uterine prolapse, examination of the patient in standing position is the only way to explore it.

6.2 Dorsal position

Mostly for demonstration of uterine prolapse. Either the uterus will be obviously protruded or protrude when the patient is asked to strain.

6.3 Sims' position

In this position, the aim is to demonstrate the different types of vaginal wall prolapse. The patient is asked to lie on her left side at the edge of the table. The left leg is extended, while the right leg is flexed. Afterward, a sterile Sims' speculum is inserted into the vagina gently first to expose the anterior vaginal wall. Then it is pulled backward gradually to expose the posterior vaginal wall. Cystocele and rectocele are usually diagnosed by this examination.

7. Per speculum examination

Examination with a Cusco's bivalve speculum allows assessment of the cervix (including a Pap smear, if appropriate), but not of prolapse. The use of a Sims' speculum is required to carefully assess the anterior and posterior compartments and to assess the supports of the cervix or the vault if there has been a previous hysterectomy. If prolapse is visible at the vaginal introitus or on Valsalva maneuver, a systematic examination should be performed. With the patient in a supine position, a suitable sized vaginal speculum is introduced in the vagina to view the cervix or vaginal cuff, and the extent to which the cervix or the vaginal vault follows the speculum through and out of the vagina is noted, and the speculum is slowly removed while performing Valsalva maneuver.

To examine the anterior vaginal wall, the posterior vaginal wall is retracted with the fixed blade, and the extent of any anterior vaginal prolapse during the Valsalva maneuver is noted and vice versa to examine posterior vaginal wall. Any resulting prolapse is noted.

Decubitus ulcers are inspected and palpated. It is common to require sponge holding forceps to aid in support of the vaginal walls, as this can obscure the view.

8. Per vaginal and rectovaginal examination

Bimanual examination is performed to check the uterine size and mobility, as well as to exclude unsuspected adnexal pathology, such as ovarian tumors. This also allows an assessment of vaginal muscle tone. Rectal examination may distinguish rectocele from enterocele. Make sure you ask the woman to direct your attention to any other findings that she has noted, that you have not discovered, or that she wants to draw your attention to.

Bonney's stress test is performed following reduction of prolapsed. If test is positive, incontinence surgery should be performed at the time of prolapse

surgery. Testing for integrity of anal sphincter should be assessed for resting tone and voluntary squeeze and sensation around the vulva with the bulbocavernous reflex. (Stroking lateral to clitoris contraction of bilateral bulbocavernous muscle is observed.) The anocutaneous reflex (anal wink sign) is triggered by stroking the skin immediately surrounding the anus and observing a reflexive contraction of the external anal sphincter; this reflex should be elicited bilaterally. Absence of these reflexes is not always abnormal, and hyperreflexia or asymmetry may in fact be more suggestive of a neurologic etiology. Crude sensory testing is advocated for evidence of pudendal neuropathy [4, 5].

Grading pelvic floor muscle strength:

1. No discernible contraction.
2. Barely palpable, flickering contraction, not visible on inspection of the perineum.
3. Weak, distinctly palpable contraction, felt as slight pressure on the examining finger.
4. Moderate muscle strength, distinct pressure on the examining finger, palpable upward and forward movement, visible on the perineal surface.
5. Good muscle strength, elevation possible against slight resistance, circular pressure can be felt around the examining finger. During simultaneous examination by the index and middle finger, these are pressed against each other.
6. Very strong muscle strength, contraction possible against vigorous resistance, with suction-type effect on the examining finger. During simultaneous examination by the index and middle finger, these are pressed against each other despite resistance.

Digital examination makes it possible to distinguish between the left and right side of the levator ani. It is capable of quantifying strength, strength endurance, fast contraction, and fast contraction endurance for clinical purposes [2].

9. Quantifying and documenting the findings

A full description of the examination is recorded, including the following:

- Type of examination table, speculum, and retractors
- Patient position
- Bladder and rectal fullness

It is important to note and document any episodes of urinary, fecal, or flatal incontinence that occur during the examination. The findings of the examination should be recorded using a quantitative and reproducible method for recording POP such as the POP-Q, Baden-Walker, or Shaw systems [4, 5].

10. Further evaluation

Further studies depend on the symptoms, stage of prolapse, and treatment plan. If needed for definitive treatment planning, urodynamic studies can help in identifying those patients with lower urinary tract symptoms (urinary incontinence) who are most likely to get benefit from surgery or may require stress incontinence surgery. Patients with defecatory symptoms and/or fecal incontinence may need anal manometry and endoanal ultrasonography [5].

11. Conclusion


Taking a thorough history and performing a careful physical examination of women who are referred help in the assessment of prolapse. Examination should be carried out with dignity and care, using some basic tools that aid in the accurate evaluation of anatomical and functional defects. A standardized assessment system has been used to document findings which should explain everything in understandable terms.

Author details

Priyanka Bhadana
ABVIMS and RML Hospital, New Delhi, India

*Address all correspondence to: docpriyanka89@gmail.com

IntechOpen

© 2020 The Author(s). Licensee IntechOpen. This chapter is distributed under the terms of the Creative Commons Attribution License (<http://creativecommons.org/licenses/by/3.0>), which permits unrestricted use, distribution, and reproduction in any medium, provided the original work is properly cited. 

References

- [1] Shaw R, Luesley D, Monga A, editors. Urogynaecology Section. Gynaecology, 4th ed. London: Churchill Livingstone; 2010
- [2] Bordman R, Telner D, et al. Step-by-step approach to managing pelvic organ prolapse. *Can Fam Physician*. 2007;**53**(3):485-487
- [3] Kuncharapu I, Majeroni BA. Pelvic organ prolapsed Am fam physician. 2010;**81**(9):1111-1117
- [4] Kieren W, Andrew F. Prolapse assessment. *Int urogynecol J*. 2014;**16**(1):35
- [5] ACOG Committee on practice bulletins—gynecology. ACOG practice bulletin no. 85: Pelvic organ prolapse. *Obstetrics and Gynecology*. 2007;**110**(3):717-729