

We are IntechOpen, the world's leading publisher of Open Access books Built by scientists, for scientists

6,900

Open access books available

186,000

International authors and editors

200M

Downloads

Our authors are among the

154

Countries delivered to

TOP 1%

most cited scientists

12.2%

Contributors from top 500 universities



WEB OF SCIENCE™

Selection of our books indexed in the Book Citation Index
in Web of Science™ Core Collection (BKCI)

Interested in publishing with us?
Contact book.department@intechopen.com

Numbers displayed above are based on latest data collected.
For more information visit www.intechopen.com



Intraoperative Radiation Therapy in Gynecological Cancer

Albert Biete, Angeles Rovirosa and Gabriela Oses

Abstract

Gynecological malignancies, mainly cervical uterine cancer, continue to present a high number of pelvic and para-aortic recurrences. Intraoperative radiation therapy (IORT) allows a precise therapeutic boost in the surgical bed in the cases in which removal of the tumor relapse is feasible. At the same time, IORT permits the exclusion of the radiosensitive organs from the irradiation field. While the first published gynecological IORT took place in 1905, the number of patients per year became stable and the published series are retrospective and limited. Recurrences are located in different areas with non-homogeneous prognostic and most of the published manuscripts are retrospective including a mix of primaries, sites and different types and results of salvage surgery. We have revised the present knowledge in this field and the main conclusion is that IORT increases the local control and, in selected cases, probably slightly the survival. Also, the quality of life is probably increased. Randomized trials that allow a breakthrough in the conclusions are highly unlikely to be performed in recurrent gynecological malignancies.

Keywords: gynecological cancer, radiotherapy, intraoperative radiation therapy, uterine cancer, ovarian cancer, endometrial cancer

1. Background

Intraoperative radiation therapy (IORT) is a boosting technique that delivers a single high dose fraction of radiation directly to the resection bed during surgery. The purpose is to selectively irradiate anatomical areas that have been identified as high risk of persistence of subclinical disease or even macroscopic unresectable residual disease. This identification is easily achieved by the direct vision of the area of interest through the surgical field. At the same time, IORT protects or avoids damage to surrounding structures or organs at risk (OAR) because they are radiosensitive. This allows good protection of pelvic organs, such as urinary bladder, ureter, rectum, bowel, etc., and, consequently, decreases the incidence of secondary undesired effects including enteritis, proctitis or cystitis. IORT can be delivered using a dedicated linear accelerator producing electron beams of different energies and penetration degrees, X-ray sources delivering low-energy radiation or high dose-rate brachytherapy sources. All of them can also be conveniently used for IORT procedures in primary or recurrent gynecological tumors. All techniques have different advantages and disadvantages. In the initial period, conventional radiotherapy linear accelerators were used, which meant that the patient had to be moved from the operating room to the radiotherapy room, which

was sometimes far away. Apart from inconveniences to transfer the patient at the time of surgery, there was also a risk of infections and a substantial prolongation of surgery time. As a result, compact mobile electron accelerators were designed that could be installed in a radio-protected operating room to avoid patient transfer (Mobetron and LIAC are the best known). Low kilovoltage X-ray tubes, such as Intrabeam, have a more specific design for intraoperative breast radiotherapy and do not have collimators of sufficient diameter. Another added difficulty is that the irradiation time is too long, about 20–40 minutes as compared to a few minutes in electron accelerators. Also, several dosimetric considerations are favoring the use of accelerated electron beams over 50 kV X-ray beams, the description of which is out of the scope of this chapter.

In the Radiation Oncology literature, the first description of an IORT procedure has been consistently attributed to Beck [1] but Casals et al. [2] from Barcelona documented a case of an IORT treatment in the gynecological area some years before. Comas and Prio [3] reported the case of a 33-year-old woman diagnosed with a cervical squamous cell carcinoma treated by radical surgery and intrapelvic roentgen therapy to the left parametria. The patient survived at least 6 years after the treatment was completed (**Figure 1**). Results were very limited for much of the century, but through the introduction of megavoltage linear accelerators and later specifically designed units as previously explained, studies of IORT delivery procedures began to be published.

IORT has been used in the primary management, as well as in the salvage setting, for many solid tumors of different locations. Conservative treatment of breast cancer has been the most common indication, but many treatments have been done in other sites such as the pancreas, the rectum, the cardio-esophageal junction, etc.

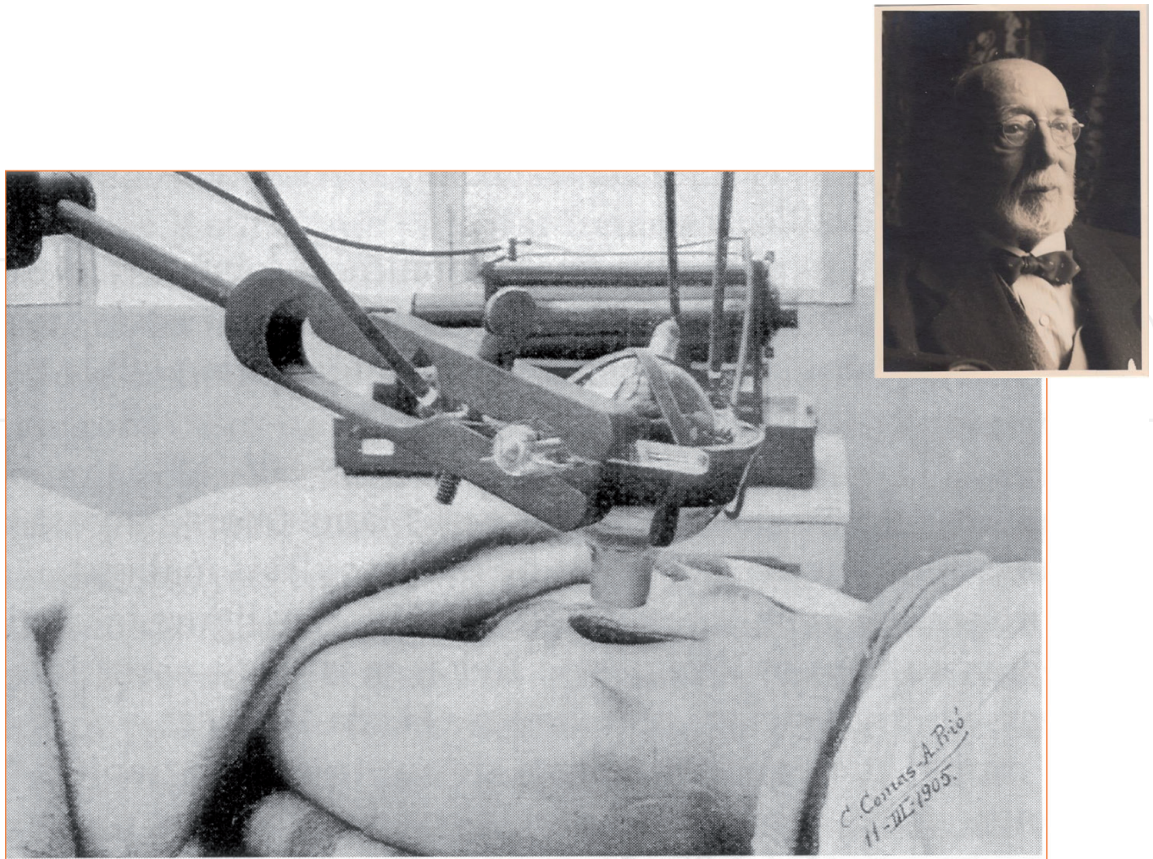


Figure 1. Original picture of the first published IORT treatment. The patient was irradiated to the distant parametrial area and survived at least 7 years. Drs. C. comas and A. Prio signed the image. Barcelona, 1905.

Two reviews on IORT in gynecological tumors have been previously published. The first one, from Backes and Martin [4], comprises all gynecological malignancies, including separate sections focused on uterine primary tumors and recurrent cervical cancer. A total amount of 276 cases of cervical cancer (primary and recurrent) were collected. The main conclusion is that if the surgical margins are positive or close, IORT appears to increase local control of the disease, with an acceptable toxicity profile. The second review, recently published by Krengly et al. [5], focuses on endometrial, cervical, renal, bladder and prostate cancers. A total of 153 patients (primary and recurrent cervical cancer) from 4 studies are analyzed in detail. They conclude as follows: in recurrent cervical cancer from these studies, it emerged that the status of the margins is the most important risk factor for treatment and the association of IORT seems to improve the probability of local control. In contrast, they do not recommend surgery and IORT for primary tumors. They state: “The available data suggests that this aggressive strategy is not advantageous in particular for the risk of severe side effects and that concomitant radio-chemotherapy alone should be considered the best treatment strategy in this patient setting.”

2. Biological and technical considerations

IORT using a linear accelerator of mobile electrons is given by applying a set of collimators of different diameters to the area of interest. The distal end may be perpendicular to the longitudinal or oblique axis, facilitating access to areas in the pelvic wall. The rotation of the accelerator head makes it easier to adapt the collimator to the area to be irradiated. If a risk organ cannot move out of the irradiation field, it can be protected by a metal disc, which is interposed between it and the radiation beam. The available accelerated electron energies are in a range of 4–12 MeV and the available collimator diameters are between 4 and 8 cm. The electron beams deposit their energy to a depth between 1.5 and 4 cm depending on the energy used. The dose refers to the 90% isodoses and from the determined depth falls sharply, which protects the organs located deeper. IORT can also be given employing Ir-192 thread brachytherapy, but it is a more complex procedure and requires more time, and radioprotection, as well as the surface dose/dose ratio at the desired depth, is more unfavorable (**Figure 2**).

The carcinogenic effect depends not only on the nature of the radiation but also on the total dose and the time in which it is given (relative biological efficacy, RBE). The conventional dose per session in external pelvic radiotherapy is 1.8–2 Grays (Gy). In IORT, the doses usually used are 10–20 Gy and it is estimated that the RBE of this single large dose is equivalent up to 2–3 times the dose if delivered as standard external beam radiotherapy. Consequently, IORT can deliver more effective radiotherapy than an external beam, because the antineoplastic efficacy is strongly related to the dose.

Also, there is probably an extra benefit coming from diminishing the release of cell growth-stimulating cytokines. This has been well reported by Belletti et al. [6] in 2008 and later by Zaleska et al. [7] in 2016. It was shown that the growth of cell cultures of breast cancer lines could be stimulated by adding the fluid collected from the operative field to cell cultures. By contrast, if the fluid was collected after irradiation of the surgical site, no such stimulus was elicited. This may help to explain the high effectiveness of IORT in preventing tumor recurrence in the treated area. Also, it has been shown that irradiation blocks the proliferative cascade induced by surgical wound repair. Moreover, Zaleska et al. [7] showed that inhibition patterns vary according to the different histological types of breast cancer, with maximum inhibition in the luminal subtypes.

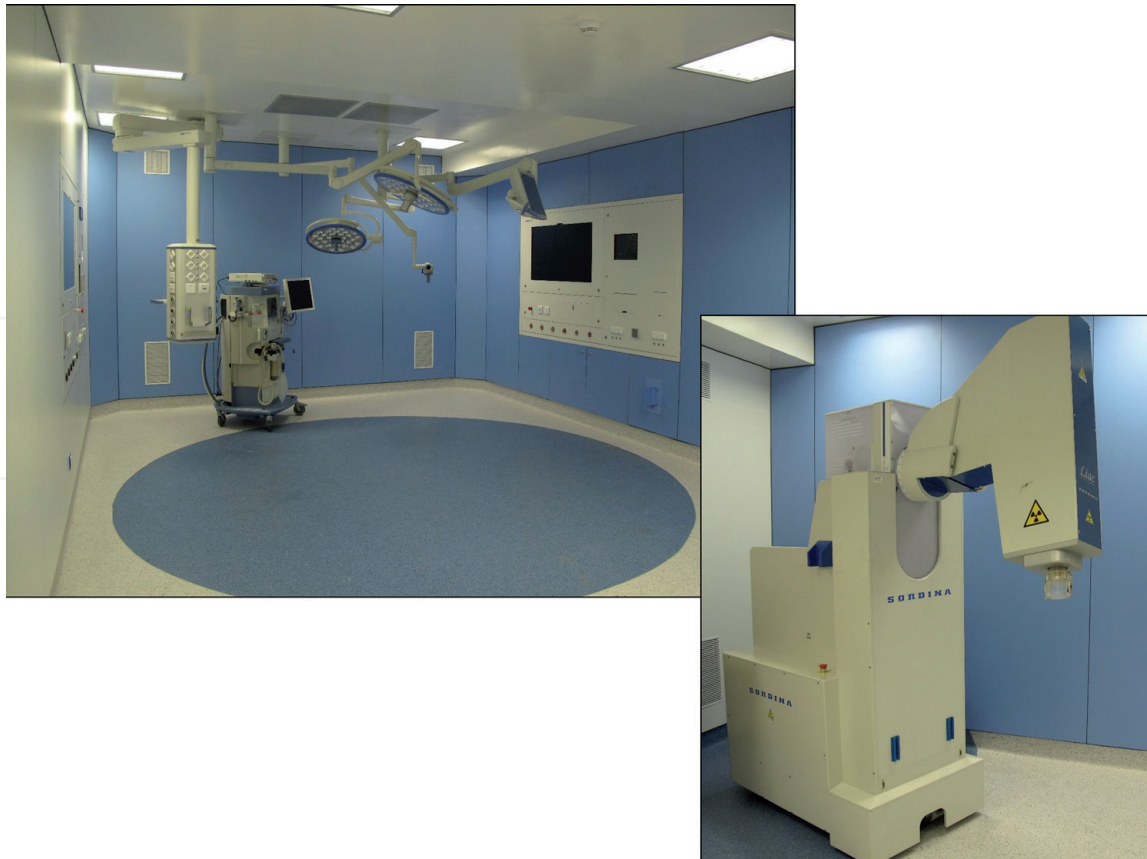

Figure 2.
Operating room designed for IORT and equipped with a mobile electron linear accelerator (LIAC). Hospital clinic. The University of Barcelona.

3. Intraoperative radiotherapy in locally advanced cervical cancer

The elective treatment in advanced cervical cancer is simultaneous radiochemotherapy followed by brachytherapy plus/minus parametrial depending on the extend of the tumor after chemoradiation. Nevertheless, in some cases, brachytherapy could not be performed and then these patients could be treated using SBRT (Stereotaxic radiotherapy) techniques but with lower results in comparison to the elective treatment. Although in 2/3 of the patients the clinical results are satisfactory, there are some cases in which the tumor remains out of control. IORT has been considered a novel approach after the removal of the persistent tumor to boost with irradiation of the surgical bed at risk and mainly performed in FIGO stages IIB.

Martinez-Monge et al. [8] described in 31 patients the results of IORT after surgery in resectable cervical cancer. These patients were treated from 1986 to 1999 with cisplatin plus fluorouracil chemotherapy simultaneously with pelvic irradiation (dose: 45 Gy). After tumor removal, IORT was delivered to the risk areas [mainly pelvic sidewalls with a median dose of 12 Gy (range between 10 and 25 Gy)]. Patients were irradiated using electrons of 9 or 12 MeV and the median field size was 6.4 cm (range between 5 and 12 cm). The 10-year local control obtained in the irradiation field was 92.8% and the pelvic control 78.6%. Attributable to IORT, toxicity was found in 14% of the patients manifested as transient pelvic pain and only one patient had neuropathy. The authors considered IORT as a boosting technique feasible and valuable in advanced resectable cervical tumors.

Giorda et al. [9] reported the results of a phase II trial in 42 patients that underwent surgery (radical hysterectomy) after 6–8 weeks of simultaneous

chemotherapy and pelvic irradiation (50.4 Gy, 1.8 Gy/fraction). After the pathological study, only 5/35 (23%) of the patients achieved a complete response and gross macroscopical disease was present in 10/35 (26%) patients. After tumor removal, IORT was administered in 83% of the patients to parametria (82%), pelvic sidewalls, obturator fossa, iliac vessels, macroscopic residual tumor or macroscopic lymph nodes. IORT median given dose was 11 Gy (range between 10 and 15 Gy), being the median field size diameter 6.3 cm (range from 5.7 to 8.3 cm). At 5 years, the overall survival (OS) was 49% and the disease-free survival (DFS) was 46% with a median time to recurrence of 22 months. In this phase II trial, it was difficult to correlate the detected complications to IORT. Although the authors concluded that IORT was mainly effective in patients with a pathological complete response and in those with residual tumor limited to the cervix, this statement became very difficult to be demonstrated.

In a report from Foley et al. [10], 32 patients were treated with IORT after surgery over a period of 17 years (1994–2011) and 21 (65.6%) of them had a diagnosis of cervical cancer (locally advanced and recurrent cervical cancer). After surgery, 84.4% of the primary cervical cancer patients had microscopically positive margins. Patients were treated using electrons from IORT with a median dose of 13.5 Gy (range 10–22.5 Gy). The higher doses were delivered in the patients with gross tumor persistence. The mean cone size was 6.6 cm with diameters ranging between 4 and 10 cm. The pelvic sidewall was treated in 59.4%, central pelvis in 21.8% and para-aortic areas in 18.8%, respectively. Only one patient developed a grade 3 peripheral neuropathy and no other relevant complications were reported. The authors concluded on the usefulness of IORT after surgery in advanced cases and relapses from cervical cancer and remark the need for clinical trials to better analyze the benefit to add IORT to the surgery.

Gao et al. [11] reported the results of a series of 27 cases presenting a stage II cervical adenocarcinoma collected between 1999 and 2002. The rationale of the study was on the worse prognosis of this raising histological subtype. The patients underwent HDR (high dose rate) brachytherapy (overall dose of 12–14 Gy in 2 applications) and followed 1–2 weeks thereafter by surgery (total hysterectomy and selective lymphadenectomy). IORT given dose was 18–20 Gy using 12 MeV electrons and the diameter of the treatment field size was 10–12 cm with the protection of bowels, sigma, rectum and bladder. The obturator nerve was also partially shielded. Positive or close surgical margins were found in 8 of 27 cases (29.6%). About 4–6 courses of cisplatin and 5-fluorouracil adjuvant chemotherapy were administered 2 weeks after the surgery. The 5-year overall survival and disease-free survival were 77.8 and 70.4%, respectively. With a mean follow-up of 81 months, 2 patients developed local relapse (7.4%), but outside of the treatment field. The main complication was the peripheral neuropathy that appeared in 2 patients (7.4%) at 8 and 17 months, respectively. The authors concluded that IORT was safe and feasible, achieving an optimal local control benefit in stage II patients. The same group published in 2002 [12] a previous study describing the results of delivering IORT as a boosting irradiation technique after tumor resection in stage IIB patients. The 5-year survival was 95% and they conclude that this approach is a new and effective therapy method for this stage, mainly in adenocarcinoma histology.

According to the authors' conclusions, it is very difficult or perhaps near impossible to assess if adding IORT to extensive surgery in cervical cancer stage II has any advantage. Improving the results of standard therapies is not easy because the high control rates obtained. Even with a randomized trial, a large number of cases would be mandatory to have good discrimination and to be sure of a real benefit. We do not think that a study like that will be planned in a short future.

4. IORT in recurrent cervical cancer

Most of the IORT treatments in gynecological tumors have been performed in cervical cancer recurrences. The main locations of them are central pelvis (cervix or vaginal vault if previous radical hysterectomy), pelvic walls, parametria and nodal areas (pelvic or para-aortic). The IORT has been performed on the surgical bed after complete resection or over the remaining unresectable recurrence, mainly because of infiltration or adherence to vascular or other anatomical structures. Facing the optimal efficacy, the goal always will be to achieve a complete resection with surgical margin free (R0) or at least only microscopically invaded (R1). Clinical results became worse if residual gross tumor remains after surgery.

When we made a short review of published clinical data on IORT in cervical cancer recurrences, we found that all studies are retrospective series. The recruitment periods are very long, with a low year rate and large heterogeneity in doses, irradiation fields, energies and duration of follow-up.

One of the historical series was published in 1997 by Garton et al. [13] from the Mayo Clinic. In a large group of 449 patients treated with IORT, 39 patients had gynecological tumors and 22 were cervical relapses. The median dose administered was 17.5 Gy (range 10–25 Gy) and its variation was due to the different degrees of surgical radicality and tumor persistence (R0, R1 or R2). Most of the irradiated locations were lymph nodes followed by the pelvic wall. In a few cases, both sites were treated simultaneously. The 5-year actuarial local control rate on the irradiated area was 81% but decreased to 67% if the whole pelvic and nodal areas were registered. The 5-year DFS was 40.5% mainly due to the appearance of distant metastasis. The authors concluded that the association of surgery, IORT and, if possible, external beam radiotherapy was the right therapeutic approach, but with an uncertain benefit of including IORT.

One of the largest trials on recurrent cervical cancer is the study by Mahe et al. [14]. Due to the short survival registered in these patients, they made a retrospective revision of IORT-treated cases. Between 1985 and 1993, a cohort of 70 patients presenting with pelvic recurrences underwent IORT with or without external radiotherapy. The clinical series were collected from seven French institutions and results were reported in 1996. In most of the patients, the relapse location was on the pelvic sidewall (59/70) and central pelvis in the remaining patients. Lymph node relapses were not reported. Five patients underwent 100 kV X-rays IORT and electrons were used in the rest of the group. The median energy was 12 MeV (range 6–20 MeV) in R0/R1 cases and somewhat higher, 14 MeV (range 7–24 MeV), when macroscopic tumor persisted after surgery. The median IORT doses were similar (18–19 Gy) in both subgroups (R0/R1 vs. R2) but the broad range (10–30 Gy). The cone median diameter was 7.5 cm (range 4–9 cm). The median follow-up was 15 months and the 5-year actuarial local control was 21%, with an OS of only 8%. This study reported one of the lowest local control and survival rates in the literature. Five of seventy patients (7.1%) developed late peripheral neuropathy, presenting with pain and paresthesia. The authors concluded that IORT seems feasible in recurrent cervical cancer but cannot dramatically improve prognosis.

A second paper from the Mayo Clinic was published some years later, in 2013, by Barney et al. [15]. The recruiting period was extended 9 years, with a total of 86 patients treated between 1983 and 2010. Eighty-five percent of patients had locally recurrent tumors and the remaining patients locally advanced primary cervical cancer. The most commonly performed surgery associated with IORT was pelvic exenteration (30%) followed by pelvic side wall resection (26%). In 20% of the patients, IORT was delivered to metastatic para-aortic nodes. During the surgical

procedure, 67% of the cases were found involving the pelvic sidewall but maximal debulking surgery was performed. Surgical margins were free (R0) in 41% of cases, microscopically involved (R1) in 35% and gross residual tumor (R2) in 24%. The patients underwent IORT with an electron beam from a conventional linear accelerator. The median given dose was 15 Gy (range 6–25 Gy) according to the resection margin (R0, R1 or R2). Site and R status were the parameters used to select the appropriate beam energies, and 9 and 12 MeV were the most commonly employed. In the previous study from the same institution [13], the median dose was a little higher (17.5 Gy vs. 15 Gy) and the irradiated volume slightly smaller in the present series. The authors considered that combining IORT and pelvic exenteration, the best results were achieved, improving the probability of local control. After surgery, an R0 or R1 pathological result was obtained only in half of the patients, but the 3-year actuarial local control was 56%. Also, only 43% of patients underwent external beam irradiation after surgery. About IORT-related toxicity, 16/89 (18%) patients experienced peripheral neuropathy, 4/89 (4.5%) ureteral stenosis and also 4.5% bowel perforation or fistula. We must point out that, keeping in mind that both studies from the Mayo Clinic share most of the patients, local control rates are rather different (70% at 5 years vs. 56% at 3 years). The authors concluded that long-term survival is possible with combined modality therapy including IORT for advanced and recurrences of cervical cancer, but distant relapse is common.

A Spanish study by Sole et al. [16] published in 2014 evaluated a series of 31 patients with recurrent cervical cancer. Because all patients had undergone previous external irradiation, the management of relapse was limited to complete or debulking surgical resection and IORT. The mean electron given dose was 12.5 Gy (range 10 to 15 Gy) and the median beam energy 12 MeV from a standard linear accelerator. Circular cones most beveled ranged from 5 to 12 cm in diameter. The 5-year actuarial local control, OS and DFS were 65, 42, and 44%, respectively. Secondary effects directly associated with IORT were not reported. The authors concluded that patients presenting with local or nodal relapse were safely treated and had improved local control by adding IORT to the surgical resection. The largest benefit was detected in the R0 cases.

Tran et al. [17] conducted a study at Stanford University and reported the clinical results of a retrospective series of 36 consecutive patients treated from 1986 to 2005. Cervical recurrent tumors were present in 17 (47%) patients, and all of them had negative margins (R0) on the perioperative pathological examination. IORT was delivered with an orthovoltage X-ray equipment (200–250 kV), using circular cones with diameters from 2.5 to 10 cm and bevels between 0° and 45°. Doses were referred to as the surface of the surgical bed. In some patients, customized lead shielding was designed to protect neighboring radiosensitive organs. The median dose given was 11.5 Gy (range 6–17.5 Gy). The 5-year actuarial local control was 45% and the DSF 46%. These results, which were more favorable than those reported elsewhere, should be interpreted taking into account that IORT was only administered in patients with R0 resections. Another explanation was the lower rate of sidewall pelvic location, 32% vs. 84% in the French study [16]. As previously commented on, recurrences on the pelvic sidewall have the worst prognosis compared with other sites such as the central pelvis or isolated metastatic lymph nodes. A very low reported rate of secondary effects due to IORT may be explained by shielding the organs at risk and limiting the peripheral nerve dose below 12.5 Gy. As a conclusion and remarking the importance of wisely selecting the candidates to IORT, the authors colloquially wrote: “It is a question of fishing in the right hole”.

A few years ago, in 2014, Backes et al. [18] published an article investigating whether the association of pelvic exenteration and IORT in recurrent gynecological cancer could improve survival. A total of 21 patients out of 32 (65.6%) with

recurrence of cervical cancer underwent surgical resection and IORT. The median radiation dose was 17.5 Gy (range 10–20 Gy). The selected electron beam energy ranged from 6 to 12 MeV and the dose depth prescription was, as usual, at 90% isodose curve. In eight patients, the intraoperative radiation was delivered with HDR brachytherapy catheters. It is difficult to understand the results given only 66% (21/32) of patients received IORT and the origin of the primary tumor (cervix, endometrium) was unclear. Probably the reason for that may be explained because the review has been focused to evaluate the efficacy of pelvic exenteration in the whole series. The 5-year actuarial local control rate differs according to the extension of surgery: pelvic exenteration and IORT (64%) vs. laterally extended endopelvic resection (69%). The authors' conclusions remarked that IORT fails to ameliorate local control and survival outcomes. Nevertheless, the cohort treated with pelvic exenteration and IORT had a worse prognosis compared with patients treated only with pelvis lateral wall surgery. It would be reasonable to conclude that if the local control rates are similar in both arms the addition of IORT may contribute to raising the local control in the worst prognosis subgroup.

To our knowledge, the most recent reported study on gynecological malignancies treated with surgery and IORT is the German study of Arians et al. [19] published in 2016. This retrospective series included 36 patients, 18 (50%) of whom presented with cervical cancer recurrence. The recruitment period was 12 years (2002–2014). IORT was performed with a mobile linear accelerator delivering a range of electron beam energies between 6 and 18 MeV. Radiosensitive organs (bowel, ureters and peripheral nerves) were displaced out of the irradiated field or using radiation protection lead shields. The median given dose was 15 Gy (range 10–18 Gy) and the median energy 8 MeV (range 6–15 MeV). The maximum dose permitted to the nerves was always below 10–12 Gy. With a median follow-up of 14 months, the actuarial 5-year OS rate was 6.4% and the DFS 0%. The results of local control were even worse, with a rate of 0% at 2 years. The reported neural toxicity was 11%. Based on these unfavorable results, the authors concluded that surgical resection and IORT in cervical cancer recurrence should be considered a rather palliative procedure, suggesting a careful selection of patients to identify those who may benefit from this combined approach.

Our institutional experience is still limited and has been partially reported [20]. The IORT program started in 2013 with a mobile electron linear accelerator (LIAC) installed in a specifically designed operation room. Treatment objectives are mainly focused on conservative breast cancer but a series of patients with gynecological cancer recurrence have also been included as candidates to receive IORT. At present, 16 patients have been enrolled. Primary tumors included uterine cervix in 11 patients, uterine corpus in 4 and ovarian cancer in 1. The mean age was 53 years (range 40–68). The most common histological type has been squamous cell carcinoma (10/16) followed by different types of adenocarcinoma (5/16) and one carcinosarcoma. Hysterectomy was performed in six cases, resection of local recurrence lesions in five and pelvic exenteration in five. A negative pathological margin (R0) was obtained in 9/16 cases, microscopically involved margins (R1) in 6/16 and macroscopic residual tumor in 1. IORT was administered to the surgical bed using an electron beam with energy ranges from 4 to 12 MeV and a mean diameter field of 5 cm (range 4–6). The median prescribed dose has been 11 Gy (range 8–15 Gy). We consider that beyond 15 Gy the probability of peripheral nerve damage is not acceptable. All the irradiated patients presented with pelvic recurrences (central in eight, the pelvic wall in four and both sites in four) but the involvement of para-aortic nodes was also present in two patients. At follow-up, there were five cancer deaths and two patients were lost. Eight patients are in complete remission without any recurrence in the irradiated area. Only one marginal relapse has appeared.

Taken all these data together, the difficulties of obtaining valid and objective conclusions should be emphasized. The heterogeneity of the data, size, location, and extent of the relapses, the different therapeutic approaches, IORT doses, different surgical procedures, etc. must be taken into account before inadequate conclusions. Probably, adding IORT to the debulking surgery may give an extra benefit in terms of local control, particularly if the resection is R0 or R1. But the influence on survival seems, if any, poor because of the high probability to develop pelvic carcinomatosis or distant metastasis.

5. Endometrial cancer

The experience with IORT in endometrial cancer is still more limited than in cervical cancer. Firstly, the pattern of recurrence is different, with very infrequent isolated relapses in the vaginal fundus fulfilling surgical indication. Most are usually controlled by external radiotherapy and brachytherapy. In other cases, the recurrence is in the form of peritoneal carcinomatosis, which already rules out combined management of surgery and IORT.

When reviewing the literature, it is observed that the majority of revisions do not include cases of endometrial cancer or do not allow their identification because they are mixed with the most numerous of the cervix or even vagina and vulva. For example, Solé et al. [16] in a series of 62 cases recruited over 17 years acknowledge that they have not included the origin of the primary tumor in the analysis criteria. In a subsequent article published 1 year later (2015) [21] dedicated specifically to IORT in oligometastases of gynecological cancer, it is surprising that it refers to more cases of endometrial than of cervical origin (18 vs. 14). With an average follow-up of 55 months, local control was 79% and DFS 44%, which stimulates the addition of IORT to external radiotherapy. In the multivariate analysis, surgery with a positive margin (R1) was the only independent prognostic factor. In a historical series of the Mayo Clinic, published in 1997 by Garton et al. [22] that includes 39 gynecological neoplasms (recurrent or advanced), only 7 are primary endometrial tumors.

In the aforementioned review carried out by Backes et al. [4], 276 cases of cervical cancer with IORT from 8 institutions were collected, but there were only 52 cases of endometrial cancer. This can be explained by the encouraging results of the primary treatment and even of the few isolated vaginal recurrences registered, which through a combination of external radiotherapy and brachytherapy reached control rates between 60% and 70%. Dowdy et al. [23] described a series of 25 patients with recurrence of endometrial cancer treated by external radiotherapy, surgical resection and IORT. The probability of local control was 84% but dropped to 47% if residual tumor persisted. For this reason, they insisted on the need to achieve surgery with negative margins. The two cases with isolated para-aortic relapses achieved control of the disease. Awtrey et al. [24] in 2006, 26 months after that study of Dowdy et al. [23], published a second specific study of IORT and endometrial cancer.

One of the main difficulties to get any valid conclusion about the usefulness of IORT is the great disparity between different studies. Nowadays, endometrial cancer has a good prognosis in most of the treated cases. Recurrences are scarce and 80% of them are located in the vaginal vault. Standard treatment of brachytherapy with or without external radiotherapy obtains satisfactory results. The cases that underwent surgery may benefit from the addition of IORT. The IORT published results in endometrium-isolated relapses are better than in cervical cancer and the toxicity is assumable if doses are under 15 Gy. We must keep in mind that a

significant number of patients will present later on peritoneal carcinomatosis and/or lung metastasis, mainly the grade III tumors. Finally, it is slightly surprising that, in the cases presenting bad prognostic factors, IORT is not used more, because local control in endometrial cancer is mandatory.

6. Ovarian cancer

In most published studies, the cases of IORT in ovarian cancer are marginal and scarce, so that it is difficult to achieve any conclusions. As far as we are aware, there are only four relevant studies on the role of IORT in ovarian cancer.

One of the oldest series is that of Konski et al. [25] in 1990. They performed IORT on nine patients with recurrence of ovarian cancer and compared their evolution with a similar group without IORT. Survival was similar in both groups.

Yap et al. [26] present a series of 24 patients undergoing cytoreductive surgery with which IORT was delivered to the areas at high risk of residual disease. Interestingly, IORT was given by using a 200 kV X-ray beam instead of an electron beam. The average dose was 12 Gy (range 9–14 Gy). At 2 years follow-up, only 5 of the 24 patients were in complete remission, but only 5 showed relapse in the irradiated surgical bed, and the remaining relapse occurred in other areas. Because of the results, they concluded that IORT had some activity but its influence on the prognosis was very limited.

A more extensive series is the experience of Gao et al. [27] with 45 patients enrolled along 11 years (2000–2010) and undergoing cytoreductive surgery. IORT was performed on the pelvis using larger than usual fields (10–12 cm in diameter) and higher than usual doses, 18–20 Gy except in two cases with 10 Gy. They register local faults by 32% but the majority outside the irradiated field (10/14). The DFS was 55% at 5 years. The authors reported a rate of peripheral neuropathy of 11%, with an average time elapsed period of 11 months (range 8–22). They also register 4% of hydronephrosis. It was concluded that IORT was effective in advanced cases or recurrences undergoing surgery, as well as it appears to discreetly increase survival and quality of life. Toxicity attributable to given doses greater than 15 Gy was not mentioned.

Barney et al. [28] from the Mayo Clinic published in 2011 a series of 20 cases treated between 1987 and 2009 because of relapses after surgery and chemotherapy. The IORT zones were pelvis (14/20), para-aortic (6/20) and inguinal fields. The average electron dose was 12.5 Gy (range 10–22.5 Gy). The probability of global-local control at 5 years was 59%, with 76% in the irradiated volume. In all cases of recurrence in the irradiation field, surgeries were R1. Survival at 5 years was 49%, similar to that in the previous study. Neural toxicity was recorded in three cases (15%).

Finally, Albuquerque et al. [29] reported a series of 27 localized extraperitoneal recurrences of ovarian cancer. In 17 cases (63%), surgical results R0 or R1 were obtained. At 5 years, the probability of local control in the irradiated area was 70% and DFS was 33%. It should be noted that in this series 37% of patients had macroscopic disease after surgery. The authors make a comparison with a similar group of relapsed patients treated only with surgery and chemotherapy without finding significant differences in survival, but they concluded “suggesting a role for locoregional therapies in selected patients presenting recurrences in ovarian cancer.”

The role and possible benefit of adding IORT to the surgical resection in ovarian cancers' localized recurrences are still under debate. These kinds of recurrences, tumoral or nodal, are infrequent. Survival is not modified and probably the local control is more related to the quality of life. As we consider ovarian cancer as more

a systemic disease and focus more on systemic therapy, we can assess than IORT would have only a role in the scarce cases presenting an isolated and resectable pelvic recurrence.

7. Miscellaneous

In this section, we would like to comment briefly on three publications as a whole, in which no distinction has been made according to the origin of the gynecological neoplasia. The first one, from Coelho et al. [30], retrospectively analyzed 41 patients with isolated or retroperitoneal recurrences of colorectal, gynecological or retroperitoneal primary tumors. Following salvage surgery, all patients underwent tumor bed IORT with an electron beam or brachytherapy. The median dose of IORT was 12 Gy. A total of 15 gynecological cancers (36%) were included, including tumors of the cervix in 8 cases, uterine corpus in 6 and ovary in 1. Patients were enrolled along 11 years, between 2004 and 2015, with a rate of 1.3 cases per year. The 5-year local control rate was 81%. Surgery R1 was the worst prognostic factor. Peripheral neural toxicity occurred in 7% of the cases.

Haddock et al. [31] reported the results of a retrospective series of 63 patients treated during a period of 12 years (1983–1995). The recruiting rate was 5.25 cases/year. IORT was administered in 8 primary gynecological tumors and 55 relapses. Most of the patients ($n = 40$) had cervical cancer. There were 16 patients with tumors of the endometrium, 5 with vaginal and 2 with ovarian. Most patients had been previously treated with external beam radiotherapy. IORT was given with electrons with a range of energies between 9 and 18 MeV. When macroscopic residual persisted after surgery, the median dose administered was 20 Gy (R2) and 15 Gy in R0-R1 cases. The actuarial 5-year local control was 74% but the probability to survive was 27%. The authors concluded that long-term disease control is obtainable in a significant number of carefully selected patients with locally advanced or recurrent gynecological malignancies with aggressive multimodality treatment, including IORT. Disease control was better when gross total resection was possible. Patients with local or regional relapse after previous external beam radiotherapy appeared to fare as well as those previously non-irradiated.

Finally, Gemignani et al. [32] reported a short series of 17 patients diagnosed with gynecological tumor recurrences. They were treated over a period of 5 years (1993–1998) with an inclusion rate of 3.4 cases per year, quite similar to our recruiting rate. Surprisingly, they are very young, with a median age of only 49 years (range 27 to 72). The origin of neoplasms was the cervix in nine patients, the endometrium in seven and the vagina in one. R0-R1 surgical resections were obtained in 76% of cases and the median IORT dose was 14 Gy. The actuarial 3-year local control reached 67% but if gross tumor remains after surgery the local control decreased to 25%. In R0-R1 cases, the actuarial 3-year control was the highest, with an 85% rate, but the DFS rate was 54%. Peripheral neuropathy occurred in 18% of cases and ureteral stenosis in 12%. The authors concluded the need to obtain R0-R1 surgical resections.

The results of different series obtained in clinical practice with the use of IORT in patients with gynecological cancer are shown in **Table 1**. Most of the experience comes from resected recurrences in various locations, mainly in the central pelvis. Cervical cancer is the most frequent diagnosis followed by endometrium and ovary. The most relevant published experience since 1995 includes 727 patients. The median number of patients per institution is 36, taking into account that the 70 cases described by the French collaborative study [16] came from 7 institutions. The median given dose has been 14.8 Gy but with large differences (range between 27

YEAR	Reference	N	Classification	IORT median dose and range in Grays	5y OS	5y DFS	5y LC
1995	Stelzer et al. [33]	22	Recurrent	22 (14–27)	43%	—	48%
1996	Mahe et al. [14]	70	Recurrent	18 (10–25)	8%(3y)	—	30%
1997	Haddock et al. [31]	63	Mix	15 (8–25)	26%	—	67%
1997	Garton et al. [13]	39	Mix	17 (10–25)	40%	32%	76%
2001	Martinez-Monge et al. [8]	36	Recurrent	15	14%	16%	42%
2001	Martinez-Monge et al. [8]	31	Primary-cervix	12	67%	70%	79%
2001	Gemignani et al. [32]	17	Recurrent	14 (12–15)	54% 3y	54% 3y	83% 3y
2002	Liu and Chen [12]	97	Primary-cervix	19 (18–20)	88%	—	—
2005	Yap et al. [26]	24	Recurrent- ovary	12 (9–14)	22%	—	68%
2006	Dowdy et al. [23]	25	Recurrent	15 (10–25)	71%	—	—
2007	Tran et al. [17]	36	Recurrent	11 (6–17)	—	47%	44%
2011	Giorda et al. [9]	35	Primary-cervix	11 (10–15)	49%	46%	89%
2013	Gao et al. [27]	27	Primary-cervix	19 (18–20)	78%	70%	100%
2013	Barney et al. [15]	73	Recurrent	15 (6–25)	—	31%	61%
2013	Barney et al. [15]	13	Primary-cervix	15 (6–25)	—	—	70%
2014	Foley et al. [10]	21	Recurrent	13.5 (10–22)	69%	30%	59%
2014	Backes and Martin [4]	21	Recurrent	17.5 (10–20)	30%	—	59%
2015	Sole et al. [21]	61	Recurrent	12 (10–15)	42%	44%	65%
2016	Arians et al. [19]	36	Recurrent	15 (10–18)	22%	—	44%
2018	Biete and Osés [20]	16	Recurrent	11 (8–15)	79%	—	86%
2018	Coelho et al. [30]	15	Recurrent	12 (9–15)	56%	—	81%
OS, overall survival; DFS, disease-free survival; LC, local control.							

Table 1.
Selected studies of the use of IORT for gynecologic malignancies.

and 6 Gy). We have divided all groups into two periods: 1995–2007 and 2008–2018. The median dose in the first period has been 15.5 Gy (range 6–27 Gy), whereas the median dose in the second period was 14.1 Gy (range 6–25 Gy). Differences are minor but a tendency to slightly lower doses is detected. The higher doses were administered when gross residual tumor persisted after surgery (R2) assuming that doses over 15 Gy increase the risk of peripheral neural toxicity and may cause ureteral stenosis and pelvic fibrosis if these structures are irradiated. However, in daily clinical practice, it is difficult to determine the precise cause of secondary effects: surgery, radiation or both. Broad differences in local control results are also registered. The probability to be free of the treated recurrence at 5 years switched around 30 and 100%, but most percentages are about 70–80%. No comparisons are allowed due to the high degree of heterogeneity among studies. **Table 2** shows the

Author	Period	Years	N	Rate/year
Coelho et al. [30]	2004–2005	11	15	1.4
Foley et al. [10]	1994–2011	17	32	1.9
Sole et al. [16]	1997–2012	15	35	2.3
Garton et al. [13]	1983–1991	8	39	4.9
Backes and Martin [4]	2000–2012	13	21	1.6
Arians et al. [19]	2002–2014	12	36	3.0
Tran et al. [17]	1986–2005	20	36	1.8
Giorda et al. [9]	2000–2007	8	42	5.2
Gao et al. [11]	1999–2006	7	27	3.8
Barney et al. [15]	1983–2010	27	86	3.2
Mahe et al. [14]	1985–1993	8	70	8.7
Gemignani et al. [32]	1993–1998	6	17	2.8
Garton et al. [22]	1981–1992	11	42	3.8
Martinez-Monge et al. [8]	1985–1992	8	26	3.2
Haddock et al. [31]	1983–1995	13	63	4.8
Dowdy et al. [23]	1986–2002	16	25	1.6
Yap et al. [26]	1994–2002	9	24	2.7
Biete and Oses [20]	2013–2017	5	16	3.2

Table 2.
Recruitment period and year rate of different authors’ published studies.

different recruiting rates from 18 studies, with a median study period of 10.7 years, although there is a large variation between a minimum of 5 years and a maximum of 27 years. The total number of cases included in this table is 626 and the median of cases per institution is 34.7 (range 15–86). The median recruitment rate is low (3.2 cases/year) and ranges between a maximum of 5.2 cases/year and a minimum of 1.4 cases/year. The previously cited French study raises a rate of 8.7 cases/year, but if we consider the 7 different institutions, then the rate lowers to 1.2 cases/year per hospital. Recruitment rates have been stable over the years, and also a strong heterogeneity in the published series persists.

8. Conclusions

The published studies on IORT have many parameters of heterogeneity. Some of them are as follows: recurrence sites of different prognosis such as pelvic sidewalls or central pelvic, margin status on resection (R0, R1 or R2), tumor initial and residual burden, high level of heterogeneity according to the different techniques, energies, fields, doses, etc. Even more, the conclusions of the referred studies are frequently different. It is not easy to demonstrate the efficacy and the benefit of IORT in these retrospective limited series. IORT is a radiation boost in a surgical procedure. In well-designed randomized prospective studies, it is frequently difficult to demonstrate the degree of local control benefit of postoperative radiotherapy. This is particularly difficult in IORT because it is necessarily associated with different degrees of radicality in surgery, from local resection to pelvic exenteration or simply debulking.

However, most of the referred studies agree that adding IORT to surgical resection is the right strategy for raising the local control rate. There are more doubts about the influence on survival and probably there is a little impact. Nevertheless, in cervical cancer, local control has a strong impact on the quality of life. We must keep in mind that half of the mortality in cervical cancer is due to a non-controlled pelvic disease.

By contrast, the therapeutic approach in primary tumors, including surgery and IORT, is strongly debated. It seems there is no clear advantage over the standard well-established approach, including chemoradiotherapy and brachytherapy. But there is some agreement that, if surgery is the therapeutic option, IORT is an effective tool adding extra safety and increasing the local control rate. Nevertheless, IORT is a therapeutical option still not included in the clinical guides.

Finally, we must point out the difficulty and the low probability to design and conduct randomized prospective trials. The experienced low accrual of enough number of patients in a reasonable time and the heterogeneity of recurrences and surgical procedures are hard difficulties to overcome.

9. Concluding remarks

Most of the published studies on IORT on gynecological cancer collected small and non-homogeneous series of patients with the additional difficulty of the long enrolment period. Cervical cancer, as primary or recurrence, is the most analyzed tumor, but many studies include a blend of recurrences from different sites: endometrium, ovary and vagina. At the same time, there is a broad variety of recurrence locations: central pelvis, pelvic walls, retroperitoneal or pelvic nodes are the most common. There is also a great variation of the surgical radicality and margin status: R0, R1 or R2.

Nowadays, knowledge comes from retrospective and heterogeneous series. High survival achieved on the primary treatment, mainly in the cervix and endometrium, results in the onset of a few local recurrences. Then, candidates for IORT are scarce and the recruitment rate becomes low in all the institutions. On the other hand, IORT is not a standard option at the initial treatment. Even taken into account all the difficulties explained before, there is a broad consensus that IORT as a radiation boost after salvage surgery adds an extra benefit to achieve better local control. Also, some authors assess that survival may also be slightly increased. There is no doubt about the benefit of IORT on quality of life. Even in patients presenting with the metastatic disease, local control is a valuable goal and has a substantial impact on the quality of life.

An important challenge for the future is the control of the tumor spreading in the peritoneal cavity, and in this case, the impact of the recurrence local control utilizing surgery and IORT would raise. Probably there will be in the near future little changes in IORT technique delivery excepting smaller units with better mobility and versatility. A significant increase in the treated patients' rate is not expected, quite different from conservative breast cancer treatment.

Finally, the limited side effects of this radiation modality if doses do not exceed 15 Gy must stick out. However, after nearly 30 years, IORT remains a technique of uneasy availability due to the limited number of institutions where it is available.

IntechOpen

Author details

Albert Biete^{1*}, Angeles Rovirosa¹ and Gabriela Oses²

¹ Radiation Oncology Department and Gynecological Oncology Unit, Hospital Clinic, University of Barcelona, Spain

² Radiation Oncology Department and Breast Unit, Hospital Clinic, University of Barcelona, Spain

*Address all correspondence to: abiete@ub.edu

IntechOpen

© 2020 The Author(s). Licensee IntechOpen. This chapter is distributed under the terms of the Creative Commons Attribution License (<http://creativecommons.org/licenses/by/3.0>), which permits unrestricted use, distribution, and reproduction in any medium, provided the original work is properly cited. 

References

- [1] Beck C. On external roentgen treatment of internal structures. *New York Medical Journal*. 1909;**89**: 621-622
- [2] Casas F, Ferrer C, Calvo FA. European historical note of intraoperative radiation therapy (IORT). A case report from 1905. *Radiotherapy and Oncology*. 1997;**43**:323-324
- [3] Comas C, Prio A. Irradiation roentgen preventive intra-abdominal, après l'intervention chirurgicale dans un cas de cancer de l'utérus: Communication au III Congrès International d'Electro-radiologie. Barcelona: Francisco Badia; 1906. p. 1907
- [4] Backes F, Martin D. Intraoperative radiation therapy (IORT) for gynecologic malignancies. *Gynecologic Oncology*. 2015;**138**:449-456
- [5] Krengli M, Pisani C, Deantonio L, Surico D, et al. Intraoperative radiotherapy for gynecological and genitourinary malignancies: Focus on endometrial, cervical, renal, bladder and prostate cancers. *Radiation Oncology*. 2017;**12**:18-27
- [6] Belletti B, Vaidya S, D'Andrea S, Entschladen F, et al. Targeted intraoperative radiotherapy impairs the stimulation of breast cancer cell proliferation and invasion caused by surgical wounding. *Clinical Cancer Research*. 2008;**14**:1325-1331
- [7] Zaleska K, Suchorska WM, Przybyla A, Murawa D. Effect of surgical wound fluids after intraoperative electron radiotherapy on the cancer stem cell phenotype in a panel of human breast cancer cell lines. *Oncology Letters*. 2016;**12**:3707-3714
- [8] Martinez-Monge R, Jurado M, Aristu JJ, Moreno M, et al. Intraoperative electron beam radiotherapy during radical surgery for locally advanced and recurrent cervical cancer. *Gynecologic Oncology*. 2001;**82**:538-543
- [9] Giorda G, Boz G, Gadducci A, Lucia E, et al. Multimodality approach in extra-cervical locally advanced cervical cancer: Chemoradiation, surgery and intra-operative radiation therapy. A phase II trial. *EJSO*. 2011;**37**:442-447
- [10] Foley O, Rauh-Hain JA, Clark R, Goodman A, et al. Intraoperative radiation therapy in the management of gynecologic malignancies. *American Journal of Clinical Oncology*. 2016;**39**:329-334
- [11] Gao Y, Liu Z, Gao F, Chen X. Intraoperative radiotherapy in stage IIB adenocarcinoma of the uterine cervix: A retrospective study. *Oncotargets and Therapy*. 2013;**6**:1695-1700
- [12] Liu Z, Chen X. Preliminary results of intraoperative radiation therapy for cervical carcinoma IIB. *Zhonghua Fu Chan Ke Za Zhi*. 2002;**37**:553-555
- [13] Garton GR, Gunderson L, Webb M, Wilson T, et al. Intraoperative radiation therapy in gynecologic cancer: The Mayo Clinic experience. *Gynecologic Oncology*. 1993;**48**:328-332
- [14] Mahe MA, Gerard JP, Dubois JB, Roussel A, et al. Intraoperative radiation therapy in recurrent carcinoma of the uterine cervix: Report of the French intraoperative group on 70 patients. *International Journal of Radiation Oncology, Biology, Physics*. 1996;**34**:21-26
- [15] Barney B, Petersen I, Dowdy S, Bakkum-Gamez N, et al. Intraoperative electron beam radiotherapy (IOERT) in the management of locally advanced or recurrent cervical cancer. *Radiation Oncology*. 2013;**8**:80-89

- [16] Sole CV, Calvo FA, Lozano MA, Gonzalez-Bayon L, et al. External-beam radiation therapy after surgical resection and intraoperative electron beam radiation therapy for oligorecurrent gynecological cancer. Long-term outcome. *Strahlentherapie und Onkologie*. 2014;**190**:171-180
- [17] Tran P, Su Z, Hara W, Husain M, et al. Long-term survivors using intraoperative radiotherapy for recurrent gynecological malignancies. *International Journal of Radiation Oncology, Biology, Physics*. 2007;**69**(2): 504-511
- [18] Backes F, Billingsley C, Martin D, Tierney B, et al. Does intra-operative radiation at the time of pelvic exenteration improve survival for patients for recurrent previously irradiated cervical, vaginal or vulvar cancer? *Gynecologic Oncology*. 2014;**135**:95-99
- [19] Arians N, Foerster R, Rom J, Uhl M, et al. Outcome of patients with local recurrent gynecological malignancies after resection combined with intraoperative electron radiation therapy (IOERT). *Radiation Oncology*. 2016;**11**:44-54
- [20] Biete A, Oses G. Radiation therapy in uterine cervical cancer: A review. *Reports of Practical Oncology and Radiotherapy*. 2018;**23**:589-594
- [21] Sole CV, Calvo FA, Lizarraga S, Gonzalez-Bayon L, Garcia-Sabrido JL. Intraoperative electron-beam radiation therapy with or without external beam radiotherapy in the management of paraaortic lymph-node oligometastases from gynecological malignancies. *Clinical & Translational Oncology*. 2015;**17**:910-916
- [22] Garton GR, Gunderson LL, Webb MJ, Wilson TO, Cha SS, Podrazz KC. Intraoperative radiation therapy in gynecologic cancer: Update of the experience at a single institution. *International Journal of Radiation Oncology, Biology, Physics*. 1997;**37**:839-843
- [23] Dowdy SC, Mariani A, Clibby VA, Haddock MG, Petersen IA, Sim FH, et al. Radical pelvic resection and intraoperative radiotherapy for recurrent endometrial cancer: Technique and analysis of outcomes. *Gynecologic Oncology*. 2006;**101**:280-286
- [24] Awtrey C, Cadungog M, Leita M, et al. Surgical resection for endometrial carcinoma. *Gynecologic Oncology*. 2006;**102**:480-488
- [25] Konski A, Neisler J, Phibbs B, et al. A pilot study investigating intraoperative electron beam irradiation in the treatment of ovarian malignancies. *Gynecologic Oncology*. 1990;**38**:121-124
- [26] Yap OW, Kapp DS, Teng NN, et al. Intraoperative radiation therapy in recurrent ovarian cancer. *International Journal of Radiation Oncology, Biology, Physics*. 2005;**63**:1114-1121
- [27] Gao Y, Liu Z, Chen X, et al. Intraoperative radiotherapy electron boost in advanced and recurrent ovarian epithelial carcinoma: A retrospective study. *BMC Cancer*. 2011;**11**:439
- [28] Barney BM, Petersen IA, Dowdy SC, et al. Intraoperative electron beam radiotherapy in the management of recurrent ovarian malignancies. *International Journal of Gynecological Cancer*. 2011;**21**:1225-1231
- [29] Albuquerque K, Patel M, Liotta M, et al. Long-term benefit of tumor-volume directed involved field radiation therapy in the management of recurrent ovarian cancer. *International Journal of Gynecological Cancer*. 2016;**26**:4
- [30] Coelho TM, Fogaroli RC, Pellizzon AC, et al. Intraoperative

radiation therapy for the treatment of recurrent retroperitoneal and pelvic tumors: A single-institution analysis. *Radiation Oncology*. 2018;**13**:224-237

[31] Haddock MG, Petersen IA, Webb MJ. IORT for locally advanced malignancies. *Frontiers of Radiation Therapy and Oncology*. 1997;**31**:256-259

[32] Gemignani ML, Alektiar KM, Leitao M, et al. Radical surgical resection and high dose intraoperative radiotherapy in patients with recurrent gynecologic cancers. *International Journal of Radiation Oncology, Biology, Physics*. 2001;**50**:687-694

[33] Stelzer KJ, Kohn WJ, Greer BE, et al. The use of intraoperative radiotherapy in radical salvage surgery for recurrent cervical cancer: Outcome and toxicity. *American Journal of Obstetrics and Gynecology*. 1995;**172**:1881-1886