

We are IntechOpen, the world's leading publisher of Open Access books Built by scientists, for scientists

6,900

Open access books available

185,000

International authors and editors

200M

Downloads

Our authors are among the

154

Countries delivered to

TOP 1%

most cited scientists

12.2%

Contributors from top 500 universities



WEB OF SCIENCE™

Selection of our books indexed in the Book Citation Index
in Web of Science™ Core Collection (BKCI)

Interested in publishing with us?
Contact book.department@intechopen.com

Numbers displayed above are based on latest data collected.
For more information visit www.intechopen.com



Non-Surgical Regional Therapy for Osteoarthritis: An Update and Review of the Literature

Harold Wilson-Morkeh and Charles Mackworth-Young

Abstract

Osteoarthritis (OA) is the most common joint condition worldwide. It can lead to chronic debilitating symptoms that can be definitively managed with surgical techniques at times. More frequently however, either due to age, extent of disease or patient choice, non-surgical approaches are preferred. They include topical therapies such as thermotherapy, ultrasound, laser treatment, non-steroidal anti-inflammatory drugs (NSAIDs) and capsaicin cream. Injections are another technique often implemented. These consist of intra-articular (IA) corticosteroid or hyaluronan injections, trigger point injections and subcutaneous sodium salicylate. Acupuncture and various types of external support are also widely used. This chapter examines the latest evidence and summarises the role of the various regional treatments available for use in the management of OA.

Keywords: osteoarthritis, joint pain, regional therapy, topical therapy

1. Introduction

Osteoarthritis (OA) is the most common chronic joint condition in the world and affects nearly 9 million people in the United Kingdom alone [1]. It manifests clinically as localised joint pain, stiffness and occasionally swelling.

OA can occur as a primary idiopathic phenomenon with no prior causative trauma, although more frequent are cases of secondary OA appearing as a result of pre-existing joint damage [2]. This is often in the context of inflammatory arthropathy or previous injury. Risk factors for primary OA include advancing age, female sex, family history and obesity [1–3]. The disease can be restricted to a single joint or become more widespread, affecting multiple joints. In severe cases, it can progressively lead to significant deformity, loss of function and a reduced quality of life [1, 4].

Treatment has mainly focused on symptomatic relief from pain, physical approaches such as rehabilitation and physiotherapy, disease-modifying treatment (such as hydroxychloroquine) and surgery. Pain relief with systemic drugs has drawbacks. In particular, the use of non-steroidal anti-inflammatory drugs (NSAIDs) has been associated with significant adverse events including gastritis and increased risk of cardiovascular disease. In view of this, there has been increased interest in localised treatments for OA; specifically, therapies that are localised to the affected joint itself. These can be divided into topical treatment, such as anti-inflammatory gels, creams and thermotherapy, and more invasive local treatment including joint aspiration and intra-articular (IA) joint injection with corticosteroid and hyaluronans.

2. Topical treatments

2.1 Thermotherapy

Thermotherapy refers to the application of either heat or cold (cryotherapy) to affected joints in an attempt to improve pain, stiffness and swelling.

Ice massage and the application of ice packs have both been studied in knee osteoarthritis [5–10]. It is likely that most of the observed effects of cryotherapy are related to the induction of local vasoconstriction. This leads to a reduction in blood flow, lower levels of local inflammation and reduced swelling. In one review [7], cryotherapy was found to reduce pain, stiffness and oedema. Regular ice massage, given five times a week, led to clinically significant effects on all three symptoms as well as function, strength and range of movement over a 2-week period [8]. However, these improvements were not replicated with less frequent applications (three times per week) [9]. There are no data to indicate a sustained effect of cold therapy on osteoarthritis as these studies looked only at a limited duration of therapy.

Common methods of superficial heat administration include the use of electrical heating pads, heat packs, towels or wax. Immersion in warm water or wax baths has also been shown to provide some subjective benefit. In some early trials, heat application failed to improve function or symptoms [8, 9]. In recent years, however, various studies have investigated different modalities of local heat therapy [10–13]. These include the application of heat packs [12], ultrasound [11, 13] and diathermy. The application of local heat packs has been found to provide short-lived alleviation of pain [12, 14], and in particular, wet heat (involving liquids) has been found to be better than dry heat [15] for symptomatic improvement.

In one study [12] 18 patients were randomised into two groups that received differing therapy over a course of 12 weeks. One was treated with application of steam generating heat sheets for 6 hours each day, and the other performed a daily quadriceps strengthening exercise regime. At the end of the study, patients in the heat-treated group reported statistically significant improvements in their symptoms and objective “Up and Go” times (a measure of function). The mechanism of heat therapy in osteoarthritis is unclear, although *ex vivo* studies of cartilage [15, 16] have indicated that elevating the temperature of chondrocytes may increase their metabolism and the production of proteoglycans that are major components of cartilage in combination with collagen. This, in part, may be secondary to increased blood flow to the chondrocytes.

On the whole, the available data suggest that thermotherapy may be useful as an adjunct in the treatment of osteoarthritis, although long-term benefits have not been established, and there are no robust clinical trials evaluating its efficacy.

2.2 Local ultrasound therapy

The role of ultrasound (US) in diagnosis of musculoskeletal problems is well established. Its popularity is in large part due to the low cost and non-invasive nature of the modality. In recent years, there has been growing interest in its application for therapeutic purposes [13, 17–19]. In theory, direct treatment with US leads to local heating of the tissue at depths not achieved by applying heat packs. There are two main techniques utilised: continuous US which leads to a rise in temperature of the treated tissues, enhancing fibrous tissue extensibility [20] and promoting capillary permeability [21] and pulsed wave treatment which harnesses nonthermal effects and is beneficial for cartilage health [18].

In vitro and animal studies [17, 18] have suggested that pulsed wave US can increase collagen production and reduce expression of membrane metalloproteinase, suggesting a protective role. However, this has failed to translate to long-term clinical benefit: randomised controlled studies [13, 19] comparing continuous, pulsed and sham US on knee osteoarthritis symptoms have shown no significant difference in pain scores nor function. In general, the safety of US has been established, and anecdotal trends have been observed, but evidence is scarce for any significant therapeutic advantage [13, 19].

2.3 Laser therapy

Laser beam therapy directs intense light to treated tissue. Two types of laser therapy have been trialled in osteoarthritis: low-level and high-intensity. Low-level laser therapy (LLLT) uses red and infrared light wavelengths, whilst high-intensity laser therapy confers higher wavelengths of radiation for deeper tissue penetration. LLLT produces a photochemical rather than thermal response and has been found to reduce pain by modulating the local inflammatory process at a cellular level [22]. This involves the increased production of reactive oxygen species (ROS) and enables transcription of cellular components such as nuclear factor kappa-light-chain-enhancer of activated B cells (NF- κ B) that help modulate cell proliferation and growth (**Figure 1**).

In one rat model of osteoarthritis, laser therapy caused a reduction in neutrophil migration, oxidative stress, altered levels of cyclooxygenase-2 and other pro-inflammatory mediators [24]. Another demonstrated that LLLT stimulates tissue repair and reduces the rate of extracellular matrix degradation [25]. There is also some evidence that LLLT promotes fibroblast proliferation, collagen synthesis and bone regeneration [26–31]. In a rabbit model of osteoarthritis, 6 weeks of treatment with laser therapy not only resulted in less pain but also histological evidence of reduced inflammation and cartilage damage [32].

This suggests that LLLT could have disease-modifying effects as well as symptomatic benefits, although the results of early clinical trials have been mixed thus far [33].

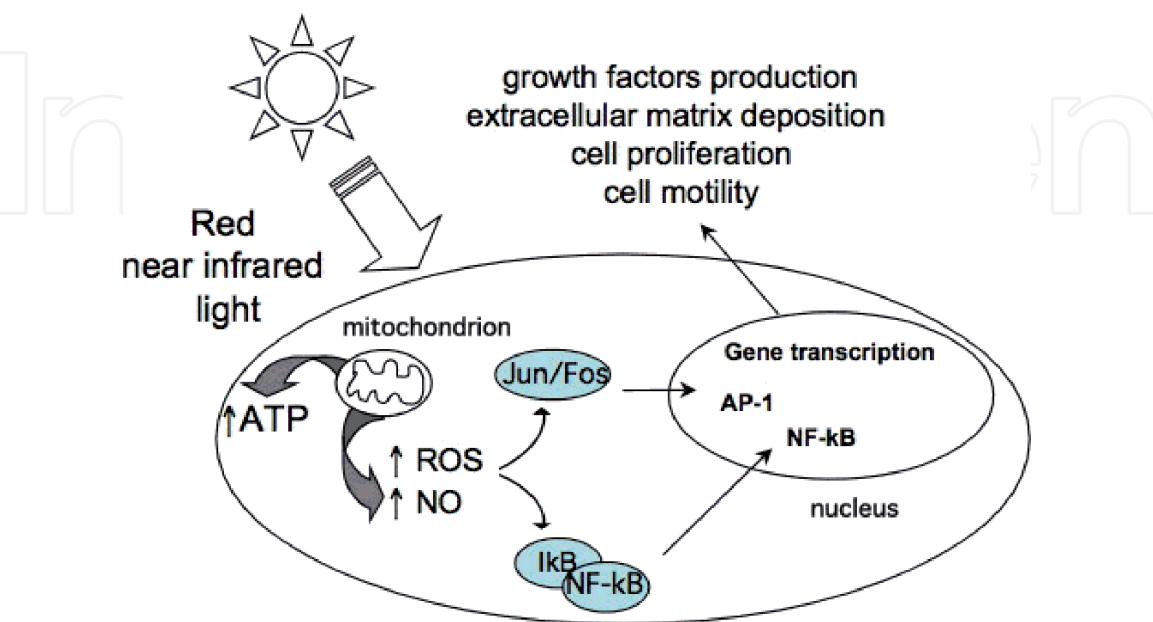


Figure 1. Mechanisms of low-level light therapy (reproduced from Ref. [23]). Abbreviations: ATP, adenosine triphosphate; ROS, reactive oxygen species; NO, nitric oxide; Jun/Fos, Jun and Fos protein subunits; I κ B, inhibitor of kappa B; NF- κ B, nuclear factor kappa-light-chain-enhancer of activated B cells; AP-1, activator protein-1.

Recent studies have tended to be more positive with those treated with laser therapy and exercise faring better than those treated with exercise alone in terms of pain measurements as well as function [34, 35]. These studies suggest that LLLT in combination with standard physiotherapy could provide advantages over standard therapy, and it shows potential as a non-invasive, safe and cost-efficient treatment modality [36]. Once again, however, evidence is lacking regarding long-term effects and whether the cellular effects seen modify disease progression.

2.4 Topical non-steroidal anti-inflammatory drugs

The mechanism of action of non-steroidal anti-inflammatory drugs is well-known. They inhibit the action of cyclooxygenases (COXs) responsible for the synthesis of prostaglandins (PGs), which are recognised mediators of inflammation [37]. Locally this reduces pain, swelling and heat. There is a large body of evidence in animal models of NSAIDs also providing central analgesic actions, with mechanisms involving spinal regulation of COXs and PGs as well as the induction of endogenous opioid peptides and blockade of serotonin release [38].

It is clear to see, therefore, why systemic NSAIDs have long been used in management of osteoarthritis. However, significant side effects including gastritis, renal impairment and increased risk of cardiovascular disease has meant that their long-term use has been limited. This has led to the promotion of topical NSAID use, theoretically providing local analgesic and anti-inflammatory benefits without the undesirable systemic adverse effects.

There are many types of topical NSAID. Preparations containing diclofenac, ibuprofen, piroxicam, ketoprofen or felbinac as the active ingredient all exist. Some include a penetration enhancer such as menthol or dimethyl sulfoxide (DMSO), whilst gels and sprays tend to be more penetrative than cream preparations. Once applied, a topical NSAID is absorbed by the underlying tissue or enters the local blood stream. Studies have shown that the absorption of NSAIDs into the underlying tissue gives rise to therapeutic local concentrations of the drug without significant systemic absorption [39, 40]. An estimated 3–7% of the applied dose is thought to be absorbed systemically [39] with plasma concentrations approximately 5% of those achieved with oral administration [39].

The skin acts as a reservoir from which the drug disseminates to the deeper tissue. Peak concentrations in the skin are achieved 2 hours after application with a further spike approximately 19 hours later, likely secondary to systemic absorption. Further proof of their local action is the absence of analgesic effect at joints distant to the point of application [41].

There have been many studies looking into the efficacy of topical NSAIDs in treating osteoarthritis [42–48]. On the whole, these have found topical NSAIDs to be superior to placebo in the treatment of chronic pain. Most of the initial studies found no benefit beyond 2 weeks of treatment [42–48], but larger randomised controlled trials demonstrated long-term benefit for up to 3 months when compared to placebo [49, 50].

When compared to oral NSAID use, the results have been variable. A meta-analysis in 2006 [48] found that topical NSAIDs were less effective than systemic NSAIDs. Since then, however, there have been several studies showing comparable effectiveness. Two studies comparing oral diclofenac with a topical preparation of the drug [51, 52] found no difference in pain scores or physical function. Furthermore, those in the topical treatment arm had a much lower incidence of severe gastrointestinal side effects, deranged liver function tests and abnormal creatinine clearance [51, 52]. These results were replicated in another study comparing oral and topical treatment with ibuprofen for knee osteoarthritis [50].

On the whole, topical NSAID use is associated with fewer systemic adverse events [42, 46, 51, 52] than oral preparations. The main side effect associated with topical NSAID use is local skin irritation, which has been reported in up to 39.3% of patients [53]. However, these skin reactions occur in equal measure with placebo gel application indicating that they may not be related to the active drug itself [46]. Other studies also suggest that skin reactions may be more common with solutions containing DMSO than diclofenac sodium gel (DSG) [44]. There is some contradictory evidence regarding their safety in older patients as some studies have found the rate of gastrointestinal side effects in the over 50s to be as high as 15% [53].

Overall, the data suggest that topical NSAIDs may be considered as first-line therapy for osteoarthritis as they are efficacious and associated with fewer adverse events. As with oral use, however, there should still be caution about their long-term application in the elderly as these patients are known to be more prone to adverse events.

2.5 Other topical treatments

Topical capsaicin cream has been used to treat a multitude of different painful conditions including osteoarthritis, inflammatory arthritis and neuropathic pain. Derived from chilli peppers, capsaicin is a lipophilic alkaloid that acts as a local irritant. It activates local pain receptors (c-nociceptors) leading to the release of substance P [54]. This in turn causes local irritation in the initial phase of treatment. With repeated use, however, levels of substance P are depleted, leading to desensitisation of the pain fibres and hypoalgesia [55].

In clinical practice, capsaicin is more effective than placebo for the treatment of chronic pain but compares less favourably with other treatments. In a meta-analysis comparing capsaicin with plaster for instance, capsaicin was found to be only marginally effective [56]. Other drawbacks include the need to use the cream four times a day for maximum benefit, as well as the local irritation and burning sensation when the cream is applied (occurring in up to 40% of patients) [57, 58]. These problems cause 10% of patients to discontinue treatment [56]. In view of this, topical capsaicin should be used in conjunction with more traditional treatments.

Other topical treatments include the use of salicylate or nicotine esters, which can be classed as local counterirritants and rubefacients, and lidocaine patches. Rubefacients cause localised vasodilatation and reddening of the skin that result in a local sensation of warmth, which often palliates pain. Irritation of the sensory nerve endings in underlying muscle and tissue is a by-product of their application and thought to modify pain pathways [59], but their main action is regional skin irritation.

The available evidence does not support their use for acute injuries or for chronic conditions such as osteoarthritis, though they are relatively well tolerated in the short term [60]. When compared to topical NSAIDs, counterirritants performed poorly [60]. This has led to numerous recommendations advising the discontinuation of routine rubefacient prescriptions in England, with patients signposted to alternative, more efficacious local treatments [61].

Lidocaine patches are not currently licensed for use in osteoarthritis in the United Kingdom, instead being more commonly utilised in the context of post-herpetic neuralgia. There is some anecdotal evidence for their efficacy in OA, however [62]. Lidocaine forms cations following ionisation with hydrogen ions and reversibly inhibits voltage-gated sodium channels on the internal surface of neuronal surface membranes when bound [63]. This prevents an influx of sodium cations (**Figure 2**) which in turn leads to a failure of nerve depolarisation resulting in the diminished pain signalling that has been observed in some clinical trials.

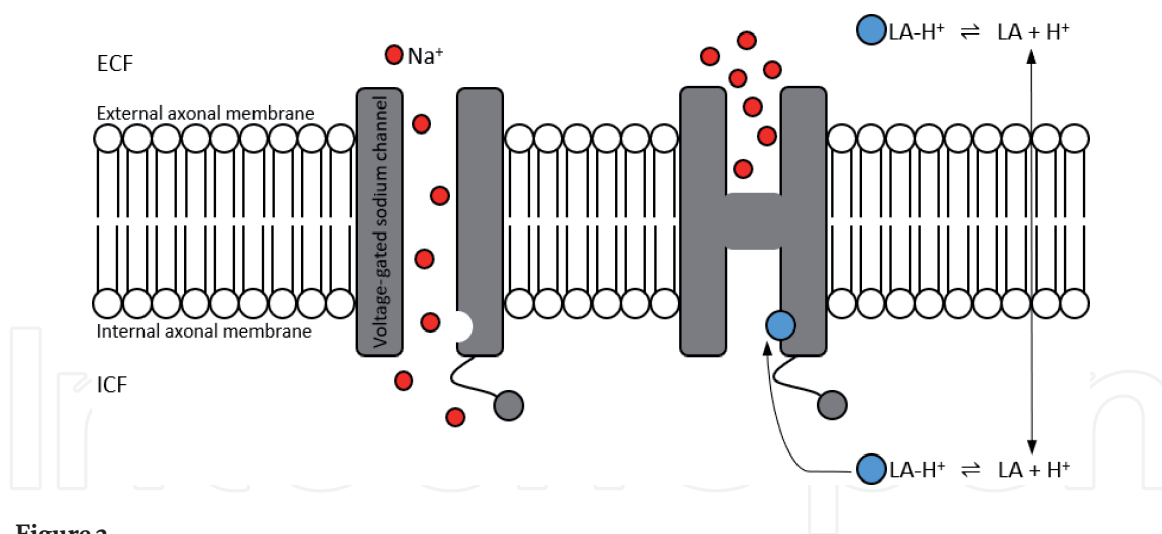


Figure 2.

The effect of lidocaine on a voltage-gated sodium channel. Abbreviations: LA, lidocaine; Na, sodium; H, hydrogen; ECF, extracellular fluid; ICF, intracellular fluid.

One open-label multicentre study investigated the effect of application of lidocaine to the area of maximal OA pain in OA of the knee [62]. A 5% lidocaine patch was applied for 12 hours at the same time each day for a period of 2 weeks with significant improvement in pain and functional scores when this treatment was used as an adjunct to more conventional systemic analgesia. Furthermore, there were minimal adverse effects seen, and the treatment was well tolerated in the patient cohort.

Clearly, randomised control trials are required to support the anecdotal data, as a sustained benefit has yet to be proven. It should also be noted that the symptomatic improvement observed was related to the use of a lidocaine patch as an adjunct to therapy, rather than a lone therapeutic agent in the management of OA. As in the case of capsaicin or rubefacients, lidocaine acts as a painkiller but has no disease-modifying capacity.

3. Local injections

3.1 Intra-articular corticosteroids

Intra-articular corticosteroid injections are frequently used to treat osteoarthritis. They work locally via anti-inflammatory effects, inhibiting the inflammatory cascade predominantly through the glucocorticoid receptor (GR) on both genomic and non-genomic levels (**Figure 3**). The genomic pathway largely comprises GR binding leading to the recruitment of complexes that influence the activity of RNA polymerase II. This affects gene transcription and repression. The GR also directly binds subunits of transcription factors such as NF- κ B and activator protein-1 (AP-1), interfering with their activation and inhibiting the production of pro-inflammatory cytokines.

The non-genomic pathway is set in motion within seconds of GR binding. Various signalling cascades are activated such as those that inhibit phospholipase A2 activation and subsequent arachidonic acid release. These result in a downregulation of cyclic endoperoxides that are key components of the inflammatory response [65].

Local injection avoids many of the systemic problems associated with oral corticosteroid use and allows delivery of high doses to the affected tissue. Response to IA injection, however, does not appear to be dependent on inflammation within the affected joint itself [66]. Additional studies looking at whether inflammation detected on ultrasound predicted clinical response found that those without inflammatory

	GENOMIC	NON-GENOMIC
MEDIATOR	GR (cytosolic)	GR (cytosolic or membrane-bound)
MAIN TARGETS	RNA Polymerase II NF-κB (p65 subunit) AP-1 (Jun subunit)	PI3K AKT MAPKs
LATENCY	Hours	Seconds to minutes
RESPONSE	Activation of gene transcription and repression	Inhibition of phospholipase A2 Phosphorylation of annexin 1 Impaired release of arachidonic acid

Figure 3. Summary of the glucocorticoid signalling pathways (reproduced from Ref. [64]). Abbreviations: GR, glucocorticoid receptor; NF-κB, nuclear factor kappa-light-chain-enhancer of activated B cells; AP-1, activator protein-1; PI3K, phosphoinositide 3-kinase; AKT, RAC-alpha serine/threonine-protein kinase; MAPKs, mitogen-activated protein kinases.

change fared better in response to IA injection than those with evidence of inflammation. Furthermore, the presence of synovial thickening, synovial fluid volume and white cell count did not predict better response to IA injection [66, 67]. In knee OA, joint aspiration prior to IA injection appears to provide greater symptomatic benefit [67]. This is partly due to anatomical confirmation on prior aspiration and concentrated drug delivery due to a lower volume of overall synovial fluid [68].

Commonly, IA injections are diluted with local anaesthetic to provide immediate relief, ensure accurate drug delivery and allow even dispersal of the drug within the joint due to the larger volume [69]. Frequently used corticosteroids in IA injections include hydrocortisone acetate (HCA), methylprednisolone acetate (MPA) and triamcinolone acetonide (TCA). These vary in solubility with the HCA being the most soluble of these three and TCA the least soluble. Less soluble preparations are longer acting and theoretically provide more long-term relief.

This effect is not always observed in clinical practice, however. In one randomised control trial comparing MPA (more soluble and shorter acting) and TCA in knee osteoarthritis, greater improvement in pain scores was found in the TCA group at 3 weeks than in MPA, although there was no difference between the two groups at 8 weeks [70]. There was also no significant difference in functional scores [70].

Further studies have investigated whether IA steroid injections provide symptomatic or functional benefit in knee osteoarthritis [66, 67, 71, 72]. These demonstrated short-term improvement in pain generally up to 4 weeks, though a small proportion of patients reported benefit to 6 weeks. Conversely, no improvement in function was seen when compared to placebo, and follow-up beyond 6 weeks did not reveal longer-lasting benefits. These results were further corroborated in a Cochrane systematic review [73]. This suggests IA steroid injections should be used as a short-term bridging treatment to resolve acute painful flares pending further intervention such as physiotherapy or surgery. Similar trials observing IA injections in the hip echo the results of those studies focusing on the knee: patients gained rapid and short-lived pain relief following injection, but these benefits were not maintained beyond 1 month [74, 75].

Other studies, focused specifically on another joint commonly affected by osteoarthritis, the first carpometacarpal (CMC) joint, uncovered more variable results related to long-term relief. In one study of 40 patients, no benefit was observed between IA steroid injection when compared to placebo [76]. Unsurprisingly, patients less likely to have sustained long-term benefits had more significant radiographic appearances (increased number of osteophytes and advanced joint space narrowing) [77]. In patients with less advanced disease, IA first CMC joint injection could provide symptomatic relief for up to 18 months following injection and splinting [77].

Although IA injections avoid the potentially toxic side effects of systemic steroids, they are not without risks themselves. All patients undergoing IA injection should be consented for the risk of infection, although this is a rare event (incidence reported between 1 in 3000 and 1 in 50,000) [78] and may be clinically difficult to differentiate from an injection-induced crystal arthritis which can occur in 2–6% of patients [67, 71]. In general, septic arthritis following IA injection occurs 3–4 days post procedure. There is a risk of lipoatrophy at the site of injection (estimated 0.6% of patients) [79], although this can be reduced by using shorter-acting preparations. Other serious local adverse events include tendon rupture, muscle wasting and local depigmentation. These risks can be minimised by performing image-guided injections where possible.

Systemic adverse events are rare with local corticosteroid injections, but as there is evidence for systemic absorption, they do still occur [80]. The most common is flushing which occurs in up to 40% of patients [81]. There have been reported incidents of unstable diabetic glycaemic control postinjection but this tends to be minor and usually settles [82]. Studies looking at the endocrine axis in patients who had received IA steroid injections found that serum cortisol dipped 24–48 hours after IA injection and took up to 4 weeks to return to baseline [80]. Major complications, such as steroid-induced osteoporosis, have not been observed, however [82].

Studies in animals have suggested that IA steroids can induce chondrocyte degeneration [83], but prospective clinical trials where patients received regular IA injections have failed to demonstrate an increased rate of cartilage loss [84]. There are also limited data to support a significant increased risk of osteonecrosis in injected joints. Nevertheless, repeated IA injections offer no long-term benefit [73] and should generally be avoided except for rapid pain relief in the short term in the absence of superior alternatives.

3.2 Intra-articular hyaluronic acid/hyaluronan

Hyaluronic acid (HA), also known as hyaluronan, is a large glycosaminoglycan molecule found in synovial and cartilage extracellular matrix (ECM). It is produced by synoviocytes, chondrocytes and fibroblasts and functions as both a lubricant and a means to maintain hydration within the joint [85]. Studies have shown that osteoarthritic joints have decreased hyaluronan content in the synovial fluid [86] and therefore IA injection with a synthetic analogue was a method developed to restore the function in degenerative joints.

Chondroprotection is the most frequent mechanism proposed in favour of the use of IA-HA [87]. This term specifically refers to the reduction of chondrocyte apoptosis as well as an increase in chondrocyte proliferation that occurs when HA binds to CD44 receptors. This results in inhibition of the well-known pro-inflammatory cytokine interleukin (IL)-1 β through induction of mitogen-activated protein kinase phosphatase (MKP)-1 [88].

Synthetic preparations of HA closely mimic endogenous molecules. Later preparations contain cross-linked hyaluronan in order to achieve greater elasticity and viscosity. In theory, this confers greater intra-articular durability of the solution. Preparations with a higher molecular weight also seem to be more beneficial than those with a lower weight [89]. This may be related to the difference in volume required for injection, the number of injections required and the intra-articular durability of the solution.

Multiple studies have been conducted investigating the efficacy of IA injections of hyaluronans in osteoarthritis, mostly affecting the knee, and the evidence to support their use has been mixed. In general, HA appears to be better than placebo in improving pain scores, function and patient global assessment in the context of

knee osteoarthritis [90]. The greatest clinical benefit is achieved at week 5–13 after a course of treatment of several injections. However, one of the drawbacks of the available data is the wide variability in trial design, frequency of injections and molecular weight of the administered synthetic product. Additionally, in hip OA, HA injections were not superior to placebo or corticosteroid injections in reducing pain or improving function [91]. There were similar findings in studies looking at OA of the hand [92].

Though HA is relatively safe, its use is restricted by the relatively high cost of the treatment [87]. It is generally reserved for knee osteoarthritis and, like corticosteroid, is offered either as a holding measure until more definitive treatment can be undertaken (e.g. surgery) or in patients for whom such treatment is inappropriate.

3.3 Subcutaneous and soft tissue injections

Trigger points are localised areas of tenderness and thickening in the soft tissues. They are typically located proximal to an inflamed or painful joint such as the rectus femoris in patients with knee OA and paraspinal regions in the cervical and lumbar spine [93]. They have also been described as interstitial fibrositis, myofasciitis and myofascial trigger points [94–96]. The aetiology and pathogenesis of trigger points are unknown.

Trigger point injections (TPI) have been used as a way of alleviating pain and discomfort associated with these areas of thickening. This can be via direct injection of medication (e.g. local anaesthetic and/or corticosteroid) into the point of tenderness or indirect needling of the soft tissue in that area. The trigger point is identified as the maximal area of tenderness in the muscle and is usually isolated by the thumb and forefinger to prevent movement in the underlying muscle. A small sterile needle is then introduced into the area, and the substance is injected directly within. Alternatively, a dry needle approach (without medication) can be used. If the injection is performed correctly, there is typically an initial acute worsening of pain associated with muscle spasm [97].

A systematic review of TPI in the management of chronic musculoskeletal pain revealed an improvement in symptoms when used exclusively [98]. This was irrespective of the injectant used [98]. The addition of a local anaesthetic, however, has been found to reduce the pain and irritation that is temporarily caused by the procedure [96].

There are limited data on the efficacy of TPI in the treatment of osteoarthritis. One study found that TPI in conjunction with IA corticosteroid was more effective than IA injection alone evidenced in both pain and functional scores [99]. Other studies have looked at TPI as sole treatment for OA, but this does not reflect clinical practice. Overall, TPI is safe and can be used as additional therapy in OA, though consideration should be made on a case-by-case basis.

Medication used in TPI includes local anaesthetic, corticosteroids, anti-inflammatories such as acetylsalicylate and ketorolac, as well as saline and water [96, 100–104]. There have also been several studies looking at the use of subcutaneous salicylate therapy for OA. In one trial 40 patients with OA of the first CMC joint [105] were randomised to receive either sham injection or subcutaneous injection with salicylate into trigger points. Patients were assessed blindly at 3, 7 and 13 weeks. Pain scores were significantly lower in those treated with salicylate than with sham injections [105].

The mechanism of action of subcutaneous salicylate injections is unclear, particularly as the site of injection is not within the affected joint. One theory is that salicylate may alter central sensitisation, and this is supported by the immediate relief patients report following injection. An alternative hypothesis is that the local

effect of salicylate modifies the neurogenic control of inflammation, which may be abnormal in diseases that affect musculoskeletal structures such as OA [106, 107]. Changes in the expression and transport of neurogenic peptides may be induced by the local irritant effect of salicylate [108]. Systemic anti-inflammatory effects are unlikely, since the benefits are generally not observed in distant sites [105].

There is a degree of overlap between TPI and acupuncture in that the injection sites are standard acupuncture locations. Acupuncture involves the insertion of fine filiform needles at or near the tender anatomical site or sometimes at distant acupuncture “points”. In a variation of this, the needles are sometimes stimulated electronically or with heat. Patients typically receive six or more sessions for a complete course of treatment. A systematic review of 393 patients with OA found acupuncture significantly improved pain but not function when compared to sham acupuncture [109–116]. In addition, results were no better than standard treatment with physiotherapy or being on a waiting list to receive acupuncture [109, 112]. There was also no additional benefit seen when using acupuncture as an adjunct to standard therapy with exercise and advice [115]. Moreover, there is little evidence for long-term benefit following acupuncture treatment, as symptomatic improvements tend to last up to 12 weeks only [109, 112]. Acupuncture is relatively safe, however, with minimal risks of serious side effects [113–116].

4. Orthoses

Osteoarthritic joints may be reinforced by various forms of external support known as orthoses. These applied devices modify the structural and functional characteristics of the neuromusculoskeletal system. Benefit can be obtained by adjusting alignment, reducing stress or load, providing shock absorption or simply resting the joint.

Orthoses such as braces, splints and elasticated sleeves are frequently used in OA of the hand and knee. Thumb and wrist splints are employed in hand OA, whilst knee sleeves and unloading braces can be useful adjuncts in knee OA. Medial patellar strapping can be specifically helpful for patellar maltracking [117]. Shoe insoles may be of benefit in OA affecting the ankle and knee and can sometimes alleviate symptoms caused by OA of the hip. Insoles can be differentiated into cushioned or neutral subtypes, which have shock-absorbing properties, and wedged insoles, which offset varus or valgus deformities as well as modulate mechanical stress.

For OA of the knee and ankle, the main purpose of orthoses and insoles is to support a joint that is unstable and to help correct alignment [118]. They can modify load bearing, contribute to pain reduction and improve physical function. There is also some evidence that they can improve proprioception [119] and they may slow disease progression [120]. They are especially useful for mild or moderate uni-compartmental knee OA where there may be varying degrees of instability and malalignment [121, 122].

Unloading knee braces are designed to reduce the load transmitted to the affected compartment by applying an external valgus or varus force. Symptomatic relief is achieved by stabilising the joint, increasing joint opening and reducing local muscle contraction [120]. One study [123] demonstrated that patients with medial compartment knee OA treated with unloading knee braces had better functional and symptomatic outcomes at 6 months. These results were not replicated in other studies [124] although there is evidence they can improve quadriceps strength and gait symmetry [125].

The main disadvantage of these braces is poor tolerability due to the weight and heat of the device. In one study, 41% of patients complained of skin irritation [126],

and up to 20% of patients discontinue use within 6 months [127]. Overall, there is limited evidence that braces or insoles provide an additional beneficial effect for knee OA when compared with medical treatment alone [128].

On the other hand, splinting of the thumb CMC joint has been found to be helpful in improving function and pain [129]. CMC joint OA contributes more to pain and disability than interphalangeal joint OA [130], and thus splinting of the CMC joint is logical. In a systematic review in 2010, CMC splinting was found to improve function and grip strength [129]. Further RCT data has corroborated this finding and demonstrated sustained benefit at 12 months [131]. However, these splints are inevitably somewhat cumbersome to wear and inhibit many day-to-day manual functions.

In general, splinting might be useful for symptomatic relief and may even improve function with prolonged use in appropriately selected patients.

5. Mesenchymal stem cells

The next frontier in local osteoarthritis management is likely to involve the use of mesenchymal stem cells (MSCs). These pluripotent cells have the capacity to differentiate into a variety of cell types, including chondrocytes, making their potential use in osteoarthritis a highly attractive prospect [132].

MSCs can undergo chondrogenesis and have been combined with a number of materials that support this differentiation, including the aforementioned polymer HA [133]. Neocartilage formation, hypertrophy and matrix calcification, as is seen in the terminal differentiation of hypertrophic chondrocytes in the growth plate, have been observed in vitro [134] and in mice [135] resulting in the efficient formation of bone. There are various hypotheses as to how this might occur. They include the inhibition of apoptosis [136] and subsequent immunomodulation [137] both of which are currently being tested in murine models of OA.

Clearly, translation to human studies is required before MSCs become a viable clinical option in the local treatment of OA, but there is understandable optimism that this therapy may herald a long-term solution to slowing the rate of articular cartilaginous degeneration and subchondral bone remodelling.

6. Conclusion

There are numerous local treatments for osteoarthritis. The majority of local therapies are safe and avoid any significant systemic adverse effects. They mostly provide symptomatic relief. In many cases this is of undoubted value to individual patients, particularly during the inflammatory phase of OA. In some cases there may be a useful placebo effect. In general, these therapies should be used as adjuncts to physiotherapy and systemic analgesia which remain the mainstay of conservative OA management. The choice of local therapy in an individual patient should be guided by the severity of disease, local experience and patient preference.

Some of these treatments, for instance, IA injections and orthoses, are well established and have been used in clinical practice for many decades. Other more novel approaches have been developed such as local laser therapy and subcutaneous sodium salicylate injections. However, for all the therapies described in this chapter, there are only limited data to demonstrate long-term benefit. Further studies are required to establish their lasting value. In the meantime these treatments remain valuable as temporary measures for many patients, particularly those with flares of symptoms or who are awaiting more definitive treatment.

IntechOpen

Author details

Harold Wilson-Morkeh¹ and Charles Mackworth-Young^{2*}

1 Department of Rheumatology, Hammersmith Hospital, Imperial College Healthcare NHS Trust, London, United Kingdom

2 Department of Rheumatology, Charing Cross Hospital, Imperial College Healthcare NHS Trust, London, United Kingdom

*Address all correspondence to: c.mackworth-young@imperial.ac.uk

IntechOpen

© 2020 The Author(s). Licensee IntechOpen. This chapter is distributed under the terms of the Creative Commons Attribution License (<http://creativecommons.org/licenses/by/3.0>), which permits unrestricted use, distribution, and reproduction in any medium, provided the original work is properly cited. 

References

- [1] Neogi T. The epidemiology and impact of pain in osteoarthritis. *Osteoarthritis and Cartilage*. 2013;**21**(9):1145-1153
- [2] Haq I, Murphy E, Dacre J. Osteoarthritis. *Postgraduate Medical Journal*. 2003;**79**(933):377-383
- [3] Zhang Y, Jordan JM. Epidemiology of osteoarthritis. *Clinics in Geriatric Medicine*. 2010;**26**(3):355-369
- [4] Zhang Y, Niu J, Kelly-Hayes M, Chaisson CE, Aliabadi P, Felson DT. Prevalence of symptomatic hand osteoarthritis and its impact on functional status among the elderly: The Framingham Study. *American Journal of Epidemiology*. 2002;**156**(11):1021-1027
- [5] Cameron MH. Physical Agents in Rehabilitation. From Research to Practice. Philadelphia: WB Saunders Company; 1999
- [6] Arthritis Foundation. Osteoarthritis. 2017. Available from: <https://www.arthritis.org/about-arthritis/types/osteoarthritis>
- [7] Brosseau L, Yonge KA, Robinson V, Marchand S, Judd M, Wells G, et al. Thermotherapy for treatment of osteoarthritis. *Cochrane Database of Systematic Reviews*. 2003;**4**:CD004522
- [8] Yurtkuran M, Kocagil T. TENS, electroacupuncture and ice massage: Comparison of treatment for osteoarthritis of the knee. *American Journal of Acupuncture*. 1999;**27**(3-4):133-140
- [9] Clarke GR, Willis LA, Stenner L, Nichols PJR. Evaluation of physiotherapy in the treatment of osteoarthrosis of the knee. *Rheumatology and Rehabilitation*. 1974;**13**(4):190-197
- [10] Hecht PJ, Bachmann S, Booth RE Jr, Rothman RH. Effects of thermal therapy on rehabilitation after total knee arthroplasty: A prospective randomized study. *Clinical Orthopaedics and Related Research*. 1983;**178**:198-201
- [11] Boyaci A, Tutoglu A, Boyaci N, Aridici R, Koca I. Comparison of the efficacy of ketoprofen phonophoresis, ultrasound and short-wave diathermy in knee osteoarthritis. *Rheumatology International*. 2013;**33**(11):2811-2818
- [12] Ochiai S, Watanabe A, Oda H, Ikeda H. Effectiveness of thermotherapy using a heat and steam generating sheet for cartilage in Knee osteoarthritis. *Journal of Physical Therapy Science*. 2014;**26**:281-284
- [13] Cakir S, Hepguler S, Ozturk C, Korkmaz M, Iseleten B, Atamaz FC. Efficacy of therapeutic ultrasound for the management of knee osteoarthritis: a randomised controlled and double-blind study. *American Journal of Physical Medicine & Rehabilitation*. 2014;**93**(5):405-412
- [14] Michlovitz S, Hun L, Erasala GN. Continuous low-level heat wrap therapy is effective for treating wrist pain. *Archives of Physical Medicine and Rehabilitation*. 2004;**85**:1409-1416
- [15] Petrofsky JS, Bains G, Raju C. The effect of moisture content of a local heat source on the blood flow response of the skin. *Archives of Dermatological Research*. 2009;**301**:581-585
- [16] Brand HS, De Koning MH, Van Kampen GP. Effect of temperature on the metabolism of proteoglycans in explants of bovine articular cartilage. *Connective Tissue Research*. 1991;**26**:87-100
- [17] Li X, Li J, Cheng K, Lin Q, Wang D, Zhang H, et al. Effect of low-intensity pulsed ultrasound on MMP-13 and MAPKs signaling pathway in rabbit

knee osteoarthritis. *Cell Biochemistry and Biophysics*. 2011;**61**(2):427-434

[18] Naito K, Watari T, Muta T, Furuhashi A, Iwase H, Igarashi M, et al. Low-intensity pulsed ultrasound (LIPUS) increases the articular cartilage type II collagen in a rat osteoarthritis model. *Journal of Orthopaedic Research*. 2010;**28**(3):361-369

[19] Ulus Y, Tander B, Akyol Y, Durmus D, Buyukakincak O, Gul U, et al. Therapeutic ultrasound versus sham ultrasound for the management of patients with knee osteoarthritis: A randomized double-blind controlled clinical study. *International Journal of Rheumatic Diseases*. 2012;**15**(2):197-206

[20] Baker KG, Robertson VJ, Duck FAA. A review of therapeutic ultrasound: Biophysical effects. *Physical Therapy*. 2001;**81**(7):1351-1358

[21] Rutjes AW, Nuesch E, Sterchi R, Jüni P. Therapeutic ultrasound for osteoarthritis of the knee or hip (review). *Cochrane Database of Systematic Reviews*. 2010;**1**:CD003132

[22] Huang YY, Chen AC, Carroll JD, Hamblin MR. Biphasic dose response in low level light therapy. *Dose-Response*. 2009;**7**(4):358-383

[23] Hamblin MR, Demidova TN. Mechanisms of low-level light therapy. *Proceedings of SPIE*. 2006;**6140**: 1-12. Figure 6. Cell signaling pathways induced by LLLT; p. 6

[24] Pallotta RC, Bjordal JM, Frigo L, Leal Junior EC, Teixeira S, Marcos RL, et al. Infrared (810-nm) low-level laser therapy on rat experimental knee inflammation. *Lasers in Medical Science*. 2012;**27**(1):71-78

[25] Lemos GA, Rissi R, de Souza Pires IL, de Oliveira LP, de Aro AA, Pimentel ER, et al. Low-level laser therapy stimulates tissue repair and

reduces the extracellular matrix degradation in rats with induced arthritis in the temporomandibular joint. *Lasers in Medical Science*. 2016;**31**(6):1051-1059

[26] Barushka O, Yaakobi T, Oron U. Effect of low-energy laser (He-Ne) irradiation on the process of bone repair in the rat tibia. *Bone*. 1995;**16**(1):47-55

[27] Grassi FR, Ciccolella F, D'Apolito G, Papa F, Iuso A, Salzo AE, et al. Effect of low-level laser irradiation on osteoblast proliferation and bone formation. *Journal of Biological Regulators and Homeostatic Agents*. 2011;**25**(4):603-614

[28] Saito S, Shimizu N. Stimulatory effects of low-power laser irradiation on bone regeneration in midpalatal suture during expansion in the rat. *American Journal of Orthodontics and Dentofacial Orthopedics*. 1997;**111**(5):525-532

[29] Almeida-Lopes L, Rigau J, Zângaro RA, Guidugli-Neto J, Jaeger MM. Comparison of the low level laser therapy effects on cultured human gingival fibroblasts proliferation using different irradiance and same fluence. *Lasers in Surgery and Medicine*. 2001;**29**(2):179-184

[30] Kreisler M, Christoffers AB, Al-Haj H, Willershausen B, d'Hoedt B. Low level 809-nm diode laser-induced in vitro stimulation of the proliferation of human gingival fibroblasts. *Lasers in Surgery and Medicine*. 2002;**30**(5): 365-369

[31] Medrado AR, Pugliese LS, Reis SR, Andrade ZA. Influence of low level laser therapy on wound healing and its biological action upon myofibroblasts. *Lasers in Surgery and Medicine*. 2003;**32**(3):239-244

[32] Wang P, Liu C, Yang X, Zhou Y, Wei X, Ji Q, et al. Effects of low level laser therapy on joint pain, synovitis, anabolic

and catabolic factors in a progressive osteoarthritis rabbit model. *Lasers in Medical Science*. 2014;**29**(6):1875-1885

[33] Brosseau L, Welch V, Wells G, deBie R, Gam A, Harman K, et al. Low level laser therapy for osteoarthritis and rheumatoid arthritis: A metaanalysis, *The Journal of Rheumatology*. 2000;**27**(8):1961-1969

[34] Al-Rashoud AS, Abboud RJ, Wang W, Wigderowitz C. Efficacy of low-level laser therapy at acupuncture points in knee osteoarthritis: A randomised double blind comparative trial. *Physiotherapy*. 2014;**100**(3):242-248

[35] Soleimnapour H, Gahramani K, Taheri R, Golzari SE, Safari S, Esfanjani RM, et al. The effect of low-level laser therapy on knee osteoarthritis: Prospective, descriptive study. *Lasers in Medical Science*. 2014;**29**(5):1695-1700

[36] Baltzer AWA, Stosch D, Seidel F, Ostapczuk MS. Low level laser therapy: A narrative literature review on the efficacy in the treatment of rheumatic orthopaedic conditions. *Zeitschrift für Rheumatologie*. 2017;**76**(9):806-812

[37] Cashman JN. The mechanisms of action of NSAIDs in analgesia. *Drugs*. 1996;**52**(5):13-23

[38] Vuilleumier PH, Schliessbach J, Curatolo M. Current evidence for central analgesic effects of NSAIDs: An overview of the literature. *Minerva Anestesiologica*. 2018;**84**(7):865-870

[39] Haroutiunian S, Drennan DA, Lipman AG. Topical NSAID therapy for musculoskeletal pain. *Pain Medicine*. 2010;**11**(4):535-549

[40] Anon. Topical Analgesics: A Review of Reviews and a Bit of Perspective. 2005. Available from: www.jr2.ox.ac.uk/Bandolier/Extraforbando/Topextra3.pdf

[41] Sioufi A, Pommier F, Boschet F, Godbillon J, Lavoignat D, Salliere D. Percutaneous absorption of diclofenac in healthy volunteers after single and repeated topical application of diclofenac Emulgel. *Biopharmaceutics & Drug Disposition*. 1994;**15**(6):441-449

[42] Massey T, Derry S, Moore RA, McQuay HJ. Topical NSAIDs for acute pain in adults. *Cochrane Database of Systematic Reviews*. 2010;**6**:CD007402

[43] Brunner M, Dehghanyar P, Seigfried B, Martin W, Menke G, Müller M. Favourable dermal penetration of diclofenac after administration to the skin using a novel spray gel formulation. *British Journal of Clinical Pharmacology*. 2005;**60**(5):573-577

[44] Barthel HR, Haselwood D, Longley S 3rd, Gold MS, Altman RD. Randomized controlled trial of diclofenac sodium gel in knee osteoarthritis. *Seminars in Arthritis and Rheumatism*. 2009;**39**(3):203-212

[45] Moore RA, Tramer MR, Carroll D, Wiffen PJ, McQuay HJ. Quantitative systematic review of topical applied non-steroidal anti-inflammatory drugs. *British Medical Journal*. 1998;**316**(7168):333-338

[46] Mason L, Moore RA, Edwards JE, Derry S, McQuay HJ. Topical NSAIDs for chronic musculoskeletal pain: Systematic review and meta-analysis. *BMC Musculoskeletal Disorders*. 2004;**5**:28

[47] Lin J, Zhang W, Jones A, Doherty M. Efficacy of topical non-steroidal anti-inflammatory drugs in the treatment of osteoarthritis: Meta-analysis of randomised controlled trials. *British Medical Journal*. 2004;**329**(7461):324

[48] Biswal S, Medhi B, Pandhi P. Long-term efficacy of topical nonsteroidal anti-inflammatory drugs in knee osteoarthritis: Meta-analysis of

randomized placebo controlled clinical trials. *The Journal of Rheumatology*. 2006;**33**(9):1841-1844

[49] Roth SH, Shainhouse JZ. Efficacy and safety of a topical diclofenac solution (pennsaid) in the treatment of primary osteoarthritis of the knee: A randomized, double-blind, vehicle-controlled clinical trial. *Archives of Internal Medicine*. 2004;**164**(18):2017-2023

[50] Underwood M, Ashby D, Cross P, Hennessy E, Letley L, Martin J, et al. Advice to use topical or oral ibuprofen for chronic knee pain in older people: Randomised controlled trial and patient preference study. *British Medical Journal*. 2008;**336**(7636):138-142

[51] Tugwell PS, Wells GA, Shainhouse JZ. Equivalence study of a topical diclofenac solution (pennsaid) compared with oral diclofenac in symptomatic treatment of osteoarthritis of the knee: A randomized controlled trial. *The Journal of Rheumatology*. 2004;**31**(10):2002-2012

[52] Simon LS, Grierson LM, Naseer Z, Bookman AA, Zev SJ. Efficacy and safety of topical diclofenac containing dimethyl sulfoxide (DMSO) compared with those of topical placebo. DMSO vehicle and oral diclofenac for knee osteoarthritis. *Pain*. 2009;**143**(3):238-245

[53] Makris UE, Kohler MJ, Fraenkel L. Adverse effects of topical non-steroidal anti-inflammatory drugs in older adults with osteoarthritis: A systematic literature review. *The Journal of Rheumatology*. 2010;**3**(6):1236-1243

[54] Baron R. Capsaicin and nociception: From basic mechanisms to novel drugs. *Lancet*. 2000;**356**(9232):785-787

[55] Nolano M, Simone DA, Wendelschafer-Crabb G, Johnson T, Hazen E, Kennedy WR. Topical capsaicin

in humans: Parallel loss of epidermal nerve fibres and pain sensation. *Pain*. 1999;**81**(1-2):135-145

[56] Mason L, Moore RA, Derry S, Edwards JE, McQuay HJ. Systematic review of topical capsaicin for the treatment of chronic pain. *British Medical Journal*. 2004;**328**(7446):991-994

[57] Zhang W, Moskowitz RW, Nuki G, Abramson S, Altman RD, Arden N, et al. OARSI recommendations for the management of hip and knee osteoarthritis, Part II: OARSI evidence-based, expert consensus guidelines. *Osteoarthritis and Cartilage*. 2008;**16**(2):137-162

[58] Laslett LL, Jones G. Capsaicin for osteoarthritis pain. *Progress in Drug Research*. 2014;**68**:277-291

[59] Morton I, Hall J. *The Royal Society of Medicine: Medicines*. 6th ed. London: Bloomsbury; 2002

[60] Derry S, Matthews PR, Wiffen PJ, Moore RA. Salicylate-containing rubefacients for acute and chronic musculoskeletal pain in adults. *Cochrane Database of Systematic Reviews*. 2014;**11**:CD007403

[61] The PrescQIPP DROP-List. Bulletin 114. Version 2.1. 2015. Available from: www.prescqipp.info

[62] Burch F, Coddington C, Patel N, Sheldon E. Lidocaine 5% patch improves pain, stiffness, and physical function in osteoarthritis pain patients. A prospective, multicenter, open-label effectiveness trial. *Osteoarthritis and Cartilage*. 2004;**12**(3):253-255

[63] Comer AM, Lamb HM. Lidocaine patch 5%. *Drugs*. 2000;**59**(2):245-249

[64] Ramamoorthy S, Cidlowski JA. Corticosteroids—Mechanisms of action in health and disease. *Rheumatic Diseases Clinics of North America*. 2016;**42**(1):15-31

- [65] Croxtall JD, Choudhury Q, Flower RJ. Glucocorticoids act within minutes to inhibit recruitment of signalling factors to activated EGF receptors through a receptor-dependent, transcription-independent mechanism. *British Journal of Pharmacology*. 2000;**130**(2):289-298
- [66] Jones A, Doherty M. Intra-articular corticosteroids are effective in osteoarthritis but there are no clinical predictors of response. *Annals of the Rheumatic Diseases*. 1996;**55**(11):829-832
- [67] Gaffney K, Ledingham J, Perry JD. Intra-articular triamcinolone hexacetonide in knee osteoarthritis: Factors influencing the clinical response. *Annals of the Rheumatic Diseases*. 1995;**54**(5):379-381
- [68] Ayral X. Injections in the treatment of osteoarthritis. *Best Practice & Research. Clinical Rheumatology*. 2001;**15**(4):609-626
- [69] Schumacher HR. Aspiration and injection therapies for joints. *Arthritis and Rheumatism*. 2003;**49**(3):413-420
- [70] Pyne D, Ioannou Y, Mootoo R, Bhanji A. Intra-articular steroids in knee osteoarthritis: A comparative study of triamcinolone hexacetonide and methylprednisolone acetate. *Clinical Rheumatology*. 2004;**23**(2):116-120
- [71] Friedman DM, Moore ME. The efficacy of intra-articular steroids in osteoarthritis: A double-blind study. *The Journal of Rheumatology*. 1980;**7**(6):850-856
- [72] Dieppe PA, Sathapatayavongs B, Jones HE, Bacon PA, Ring EF. Intra-articular steroids in osteoarthritis. *Rheumatology and Rehabilitation*. 1980;**19**(4):212-217
- [73] Jüni P, Hari R, Rutjes AW, Fischer R, Sillelta MG, Reichenbach S, et al. Intra-articular corticosteroid for knee osteoarthritis. *Cochrane Database of Systematic Reviews*. 2015;**10**:CD005328
- [74] Flanagan J, Casale FF, Thomas TL, Desai KB. Intra-articular injection for pain relief in patients awaiting hip replacement. *Annals of The Royal College of Surgeons of England*. 1988;**70**(3):156-157
- [75] Qvistgaard E, Christensen R, Torp-Pedersen S, Bliddal H. Intra-articular treatment of hip osteoarthritis: A randomized trial of hyaluronic acid, corticosteroid, and isotonic saline. *Osteoarthritis and Cartilage*. 2006;**14**(2):163-170
- [76] Meenagh GK, Patton J, Kynes C, Wright GD. A randomised controlled trial of intra-articular corticosteroid injection of the carpometacarpal joint of the thumb in osteoarthritis. *Annals of the Rheumatic Diseases*. 2004;**63**(10):1260-1263
- [77] Day CS, Gelberman R, Patel AA, Vogt MT, Ditsios K, Boyer MI. Basal joint osteoarthritis of the thumb: A prospective trial of steroid injection and splinting. *Journal of Hand Surgery*. 2004;**29**(2):247-251
- [78] Creamer P. Intra-articular corticosteroid treatment in osteoarthritis. *Current Opinion in Rheumatology*. 1999;**11**(5):417-421
- [79] Kumar N, Newman RJ. Complications of intra- and peri-articular steroid injections. *The British Journal of General Practice*. 1999;**49**(443):465-466
- [80] Habib GS. Systemic effects of intra-articular corticosteroids. *Clinical Rheumatology*. 2009;**28**(7):749-756
- [81] Pattrick M, Doherty M. Facial flushing after intra-articular injection of bupivacaine and methylprednisolone. *British Medical Journal*. 1987;**295**(6610):1380

- [82] Slotkoff A, Clauw D, Nashel D. Effect of soft tissue corticosteroid injection on glucose control in diabetics. *Arthritis and Rheumatism*. 1994;**37**(9):S347
- [83] Papachristou G, Anagnostou S, Katsorhis T. The effect of intraarticular hydrocortisone injection on the articular cartilage of rabbits. *Acta Orthopaedica Scandinavica. Supplementum*. 1997;**275**:132-134
- [84] Raynauld JP, Buckland-Wright C, Ward R, Choquette D, Haraoui B, Martel-Pelletier J, et al. Safety and efficacy of long-term intraarticular steroid injections in osteoarthritis of the knee: A randomized, double-blind, placebo-controlled trial. *Arthritis and Rheumatism*. 2003;**48**(2):370-377
- [85] National Institute for Health and Care Excellence. Osteoarthritis: National Clinical Guideline for Care and Management in Adults. London: NICE; 2014. Available from: www.nice.org.uk/CG117
- [86] Fife RS. Osteoarthritis: Epidemiology, pathology and pathogenesis. In: Klippel JH, editor. *Primer on the Rheumatic Diseases*. 11th ed. The Arthritis Foundation: Atlanta; 1997. pp. 216-217
- [87] Altman RD, Manjoo A, Fierlinger A, Niazi F, Nicholls M. The mechanism of action for hyaluronic acid treatment in the osteoarthritic knee: A systematic review. *BMC Musculoskeletal Disorders*. 2015;**16**:321
- [88] Mihara M, Hashizume M, Yoshida H, Suzuki M, Shiina M. IL-6/IL-6 receptor system and its role in physiological and pathological conditions. *Clinical Science*. 2012;**122**(4):143-159
- [89] Wobig M, Bach G, Beks P, Dickhut A, Runzheimer J, Schiewger G, et al. The role of elastoviscosity in the efficacy of viscosupplementation for osteoarthritis of the knee: A comparison of hylan G-F 20 and a lower-molecular-weight hyaluronan. *Clinical Therapeutics*. 1999;**21**(9):1549-1562
- [90] Bellamy N, Campbell J, Robinson V, Gee T, Bourne R, Wells G. Viscosupplementation for the treatment of osteoarthritis of the knee. *Cochrane Database of Systematic Reviews*. 2006;**2**:CD005321
- [91] Qvistgaard E, Christensen R, Torp-Pedersen S, Bliddal H. Intra-articular treatment of hip osteoarthritis: A randomized trial of hyaluronic acid, corticosteroid, and isotonic saline. *Osteoarthritis and Cartilage*. 2006;**14**(2):163-170
- [92] Fuchs S, Mönikes R, Wohlmeiner A, Heyse T. Intra-articular hyaluronic acid compared with corticoid injections for the treatment of rhizarthrosis. *Osteoarthritis and Cartilage*. 2006;**14**(1):82-88
- [93] Fox WW, Freed DLJ. *Understanding Arthritis*. London: Macmillan; 1990
- [94] Steindler A, Luck JV. Differential diagnoses of pain in the low back. *Journal of the American Medical Association*. 1938;**110**:106-113
- [95] Travell JG, Simons DG, editors. *Myofascial Pain and Dysfunction: The Trigger Point Manual*. Baltimore, MD, USA: Williams & Wilkins; 1983. pp. 2-18
- [96] Cailliet R. Chronic pain concept. In: *Soft Tissue Pain and Disability*. Philadelphia, PA, USA: FA Davis; 1977. pp. 25-40
- [97] Kim PS. Role of injection therapy: Review of indications for trigger point injections, regional blocks, facet joint injections, and intra-articular injections. *Current Opinion in Rheumatology*. 2002;**14**(1):52-57
- [98] Scott NA, Guo B, Barton PM, Gerwin RD. Trigger point injections for

chronic non-malignant musculoskeletal pain: A systematic review. *Pain Medicine*. 2009;**10**(1):54-69

[99] Yentür EA, Okcu G, Yegul I. The role of trigger point therapy in knee osteoarthritis. *The Pain Clinic*. 2003;**15**:385-390

[100] Sidel N, Abrams MI. Treatment of chronic arthritis: results of vaccine therapy with saline injections used as controls. *Journal of the American Medical Association*. 1940;**11**:1740-1742

[101] Traut EF, Passarelli EW. Study in the controlled therapy of degenerative arthritis. *Archives of Internal Medicine*. 1956;**98**(2):181-186

[102] Frost FA, Jessen B, Siggaard-Andersen J. A controlled, double-blind comparison of mepivacaine versus saline injection for myofascial pain. *Lancet*. 1980;**1**(8167):499-500

[103] Frost FA. Diclofenac versus lidocaine as injection therapy in myofascial pain. *Scandinavian Journal of Rheumatology*. 1986;**15**:153-156

[104] Byrn C, Olsson I, Falkheden L, Lindh M, Hösterey U, Fogelberg M, et al. Subcutaneous sterile water injections for chronic neck and shoulder pain following whiplash injuries. *Lancet*. 1993;**341**(8843):449-452

[105] Smith AS, Doré CJ, Dennis L, Julius A, Mackworth-Young CG. A randomised controlled trial of subcutaneous sodium salicylate therapy for osteoarthritis of the thumb. *Postgraduate Medical Journal*. 2010;**86**(1016):341-345

[106] Kidd BL, Urban LA. Mechanisms of inflammatory pain. *British Journal of Anaesthesia*. 2001;**87**(1):3-11

[107] Schaible HG, Ebersberger A, Von Banchet GS. Mechanisms of pain

in arthritis. *Annals of the New York Academy of Sciences*. 2002;**966**:343-354

[108] McCarthy GM, McCarty DJ. Effect of topical capsaicin in the therapy of painful osteoarthritis of the hands. *The Journal of Rheumatology*. 1992;**19**:604-607

[109] Witt C, Brinkhaus B, Jena S, Linde K, Streng A, Wagenpfeil S, et al. Acupuncture in patients with osteoarthritis of the knee: A randomised trial. *Lancet*. 2005;**366**(9480):136-143

[110] Molsberger A, Böwing G, Jensen KU, Lorek M. Acupuncture treatment for the relief of gonarthrosis pain—A controlled clinical trial. *Der Schmerz*. 1994;**8**(1):37-42. (German)

[111] Petrou P, Winkler V, Genti G, Balint G. Double blind trial to evaluate the effect of acupuncture treatment on knee osteoarthritis. *The Scandinavian Journal of Acupuncture*. 1988;**3**:112-115

[112] Berman BM, Singh BB, Lao L, Langenberg P, Li H, Hadhazy V, et al. A randomized trial of acupuncture as an adjunctive therapy in osteoarthritis of the knee. *Rheumatology (Oxford, England)*. 1999;**38**(4):346-354

[113] Ezzo J, Hadhazy V, Birch S, Kaplan G, Hochberg M, Berman B. Acupuncture for osteoarthritis of the knee: A systematic review. *Arthritis and Rheumatism*. 2001;**44**(4):819-825

[114] Melchart D, Weidenhammer W, Streng A, Reitmayr S, Hoppe A, Ernst E, et al. Prospective investigation of adverse effects of acupuncture in 97733 patients. *Archives of Internal Medicine*. 2004;**164**(1):104-105

[115] Berman BM, Lao L, Langenberg P, Lee WL, Gilpin AM, Hochberg MC. Effectiveness of acupuncture as adjunctive therapy in osteoarthritis of the knee. *Annals of Internal Medicine*. 2004;**141**(12):901-910

- [116] Ernst E, White A. Acupuncture: Safety first. *British Medical Journal*. 1997;**314**(7091):1362
- [117] Warden SJ, Hinman RS, Watson MA Jr, Avin KG, Bialocerkowski AE, Crossley KM. Patellar taping and bracing for the treatment of chronic knee pain: A systematic review and meta-analysis. *Arthritis and Rheumatism*. 2008;**59**(1):73-83
- [118] Rannou F, Poiraudau S, Beaudreuil J. Role of bracing in the management of knee osteoarthritis. *Current Opinion in Rheumatology*. 2010;**22**(2):218-222
- [119] Birmingham TB, Kramer JF, Kirkley A, Inglis JT, Spaulding SJ, Vandervoort AA. Knee bracing for medial compartment osteoarthritis: Effects on proprioception and postural control. *Rheumatology (Oxford, England)*. 2001;**40**(3):285-289
- [120] Ramsey DK, Briem K, Axe MJ, Snyder-Mackler L. A mechanical theory for the effectiveness of bracing for medial compartment osteoarthritis of the knee. *The Journal of Bone and Joint Surgery. American Volume*. 2007;**89**(11):2398-2407
- [121] Jordan KM, Arden NK, Doherty M, et al. EULAR Recommendations 2003: An evidence-based approach to the management of knee osteoarthritis: Report of a Task Force of the Standing Committee for International Clinical Studies Including Therapeutic Trials (ESCISIT). *Annals of the Rheumatic Diseases*. 2003;**62**(12):1145-1155
- [122] Altman RD, Hochberg MC, Moskowitz RW, Schnitzer TJ. Recommendations for the medical management of osteoarthritis of the hip and knee: 2000 update. American College of Rheumatology Subcommittee on Osteoarthritis Guidelines. *Arthritis & Rheumatology*. 2000;**43**(9):1905-1915
- [123] Kirkley A, Webster-Bogaert S, Litchfield R, Amendola A, MacDonald S, McCalden R, et al. The effect of bracing on varus gonarthrosis. *Journal of Bone and Joint Surgery*. 1999;**81**(4):539-548
- [124] Brouwer RW, van Raaij TM, Verhaar JA, Coene LN, Bierma-Zeinstra SM. Brace treatment for osteoarthritis of the knee: A prospective randomized multicentre trial. *Osteoarthritis and Cartilage*. 2006;**14**(8):777-783
- [125] Beaudreuil J, Bendaya S, Faucher M, Coudeyre E, Ribinik P, Revel M, et al. Clinical practice guidelines for rest orthosis, knee sleeves, and unloading knee braces in knee osteoarthritis. *Joint, Bone, Spine*. 2009;**76**(6):629-636
- [126] Pollo FE, Otis JC, Backus SI, Warren RF, Wickiewicz TL. Reduction of medial compartment loads with valgus bracing of the osteoarthritic knee. *The American Journal of Sports Medicine*. 2002;**30**(3):414-421
- [127] Giori NJ. Load-shifting brace treatment for osteoarthritis of the knee: A minimum 2 1/2-year follow-up study. *Journal of Rehabilitation Research and Development*. 2004;**41**(2):187-194
- [128] Brouwer RW, Jakma TS, Verhagen AP, Verhaar JA, Bierma-Zeinstra SM. Braces and orthoses for treating osteoarthritis of the knee. *Cochrane Database of Systematic Reviews*. 2005;**1**:CD004020
- [129] Valdes K, Marik T. A systematic review of conservative interventions for osteoarthritis of the hand. *Journal of Hand Therapy*. 2010;**23**(4):334-350
- [130] Bijsterbosch J, Visser W, Kroon HM, Stamm T, Meulenbelt I, Huizinga TW, et al. Thumb base involvement in symptomatic hand osteoarthritis is associated with more pain and functional disability. *Annals*

of the Rheumatic Diseases.
2010;**69**(3):585-587

[131] Rannou F, Dimet J, Boutron I, Baron G, Fayad F, Macé Y, et al. Splint for base-of-thumb osteoarthritis: A randomized trial. *Annals of Internal Medicine*. 2009;**150**(10):661-669

[132] Bian L, Hou C, Tous E, Rai R, Mauck RL, Burdick JA. The influence of hyaluronic acid hydrogel crosslinking density and macromolecular diffusivity on human MSC chondrogenesis and hypertrophy. *Biomaterials*. 2013;**34**(2): 413-421

[133] Huang AH, Farrell MJ, Mauck RL. Mechanics and mechanobiology of mesenchymal stem cell-based engineered cartilage. *Journal of Biomechanics*. 2010;**43**(1):128-136

[134] Platas J, Guillén MI, del Caz MD, Gomar F, Mirabet V, Alcaraz MJ. Conditioned media from adipose-tissue-derived mesenchymal stem cells downregulate degradative mediators induced by interleukin-1 β in osteoarthritic chondrocytes. *Mediators of Inflammation*. 2013;**2013**:357014

[135] Jukes JM, Both SK, Leusink A, Sterk LM, van Blitterswijk CA, de Boer J. Endochondral bone tissue engineering using embryonic stem cells. *Proceedings of the National Academy of Sciences of the United States of America*. 2008;**105**(19):6840-6845

[136] Mancuso P, Raman S, Glynn A, Barry F, Murphy JM. Mesenchymal stem cell therapy for osteoarthritis: The critical role of the cell secretome. *Frontiers in Bioengineering and Biotechnology*. 2019;**7**:9

[137] Galleu A, Riffo-Vasquez Y, Trento C, Lomas C, Dolcetti L, Cheung TS, et al. Apoptosis in mesenchymal stroma cells induces in vivo recipient-mediated immunomodulation. *Science Translational Medicine*. 2017;**9**(416):eaam7828