

We are IntechOpen, the world's leading publisher of Open Access books Built by scientists, for scientists

6,900

Open access books available

186,000

International authors and editors

200M

Downloads

Our authors are among the

154

Countries delivered to

TOP 1%

most cited scientists

12.2%

Contributors from top 500 universities



WEB OF SCIENCE™

Selection of our books indexed in the Book Citation Index
in Web of Science™ Core Collection (BKCI)

Interested in publishing with us?
Contact book.department@intechopen.com

Numbers displayed above are based on latest data collected.
For more information visit www.intechopen.com



Caecal Volvulus

Paul K. Okeny

Abstract

Colonic volvulus is the third leading cause of large bowel obstruction. About 35% of these are located in the caecum. Though, relatively, a rare cause of obstruction, the incidence of caecal volvulus is steadily increasing at a rate of about 5% per year. Mortality due to caecal volvulus may be as high as 40% especially in the presence of gangrene and sepsis. Clinical presentation may be acute and fulminant or as a mobile caecum syndrome with intermittent abdominal pain. “Whirl,” “Coffee bean,” and “bird beak” signs seen on computed tomography are pathognomonic. Colectomy is the preferred treatment as it obviates any chance of recurrence. A conservative approach to colectomy such as limited ileocaecal resection and ileostomy formation in critically ill patients or in those with poor physiological reserve may be associated with better postoperative outcomes.

Keywords: caecum, volvulus, obstruction, mobile caecum, management

1. Introduction

There are records of volvulus as far back as 1550 BC and by Hippocrates who first described treatment options such as injection of a large quantity of air or insertion of a 10 digit suppository through the anus [1]. In modern day literature, it was first described by Austrian pathologist Rokitsky in 1837 as an important cause of intestinal strangulation [2]. Colonic volvulus or twisting of the large bowel is the third leading cause of large bowel obstruction world-wide [3]. It mainly occurs in the ‘Volvulus belt’ of Africa, Middle East, India and Russia where it may affect a slightly younger age group compared to the rest of the world [4, 5].

Although the incidence of caecal volvulus as a cause of colonic volvulus appears to be increasing, the commonest sites for colonic volvulus still include sigmoid –60%, caecum –35%, transverse colon –4%, and splenic flexure –1% [1]. This chapter reviews the current management of caecal volvulus.

2. Epidemiology

Caecal volvulus in itself is rare but an associated mortality of nearly 40% warrants prompt diagnosis and treatment [6]. It has an incidence of 2.8–7.1 per million people, is responsible for 1–1.5% of intestinal obstructions, and 25–40% of all colonic volvulus and affects females more than males [7]. The presence of a volvulus belt has already been discussed. In a large epidemiological study done by Halabi et al. [8] over a period covering 9 years in the United States, the incidence of caecal volvulus increased by 5% per year.

3. Aetiology

The aetiology of caecal volvulus can be attributed to an interplay between anatomical and other predisposing factors.

In normal embryological development, the mesentery of the right colon gets fixed on the right posterior abdominal wall (retroperitoneum) during the counter clockwise rotation of the caecum from left to right lower quadrant. Abnormal fixation may lead to an excessively mobile caecum in an anatomical anomaly called “messenterium commune” [9]. In an autopsy examination of 125 cadavers, 11.2% had freely mobile colons with a 36.8% total risk of caecal volvulus [3, 10].

Including previous surgery – adhesions acting as fulcrum for rotation of the mobile caecum [11], other predisposing factors include chronic constipation, distal obstruction, prior colonoscopy, high fibre diet, psychotropic drugs, ileus and late term pregnancy [7, 10, 12–14].

The commonest features in the aetiology of caecal volvulus are therefore caecal displacement, hyperperistalsis/dysmotility and colonic distension. It may also be associated with other congenital malformations such as Cornelia de Lange in children [15] and situs inversus [16].

4. Pathophysiology

Caecal volvulus occurs when the caecum which forms the first part of the large bowel undergoes an axial twist about its mesenteric pedicle leading to a closed loop intestinal obstruction [7, 17]. Also involved in this process are the ascending colon and terminal ileum. This should be differentiated from caecal bascule in which the caecum folds anteriorly along a horizontal plane [7, 18, 19]. See **Figures 1–3**.

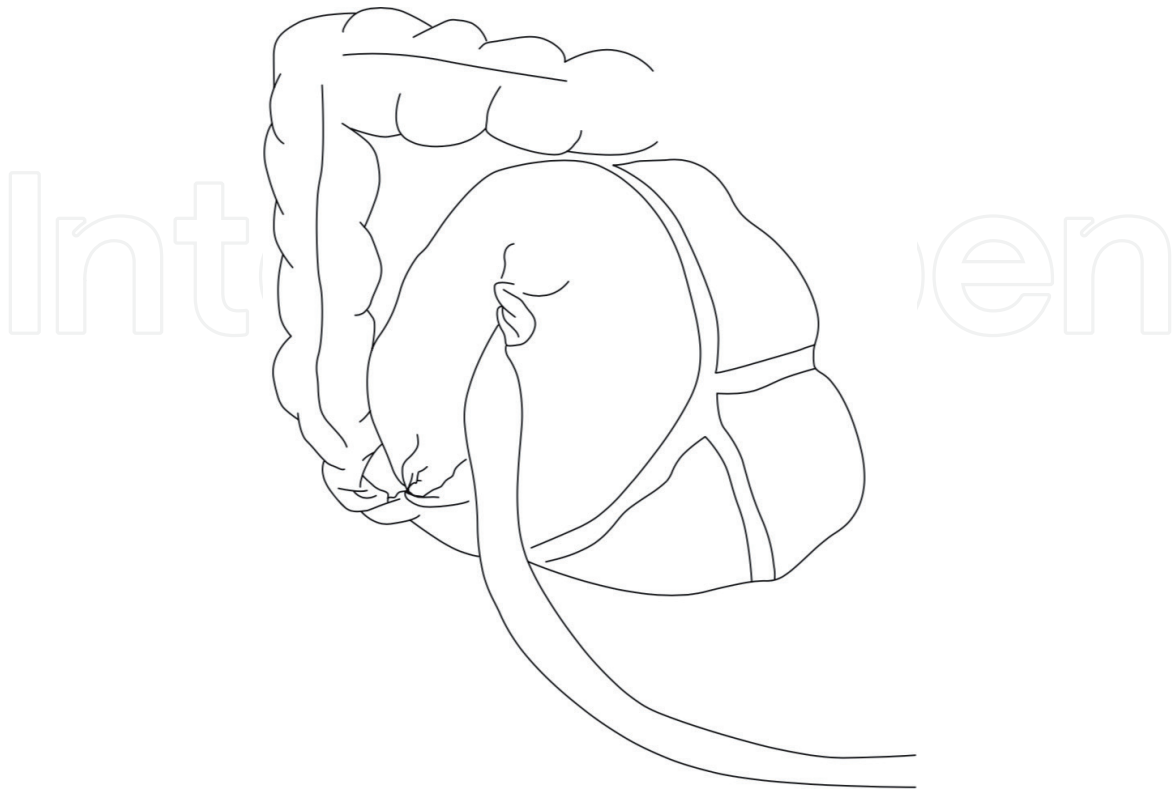


Figure 1.
Caecal volvulus with axial twist causing closed loop obstruction. Adapted from Consorti and Liu [7].

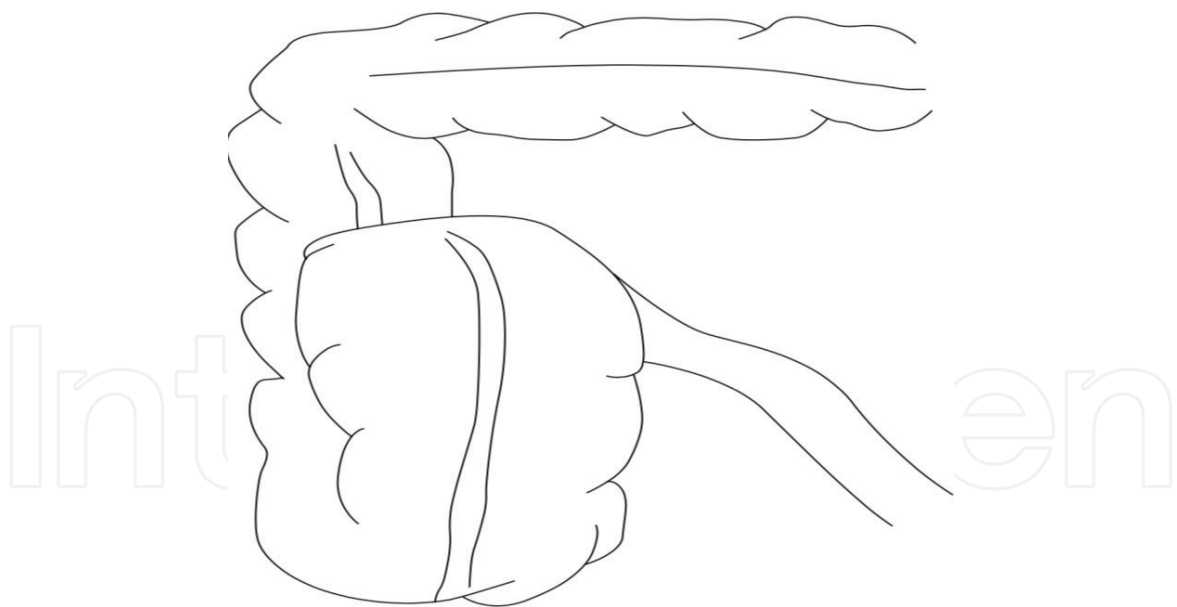


Figure 2.
Caecal bascule. Upward fold along horizontal plane. Adapted from Consorti and Liu [7].

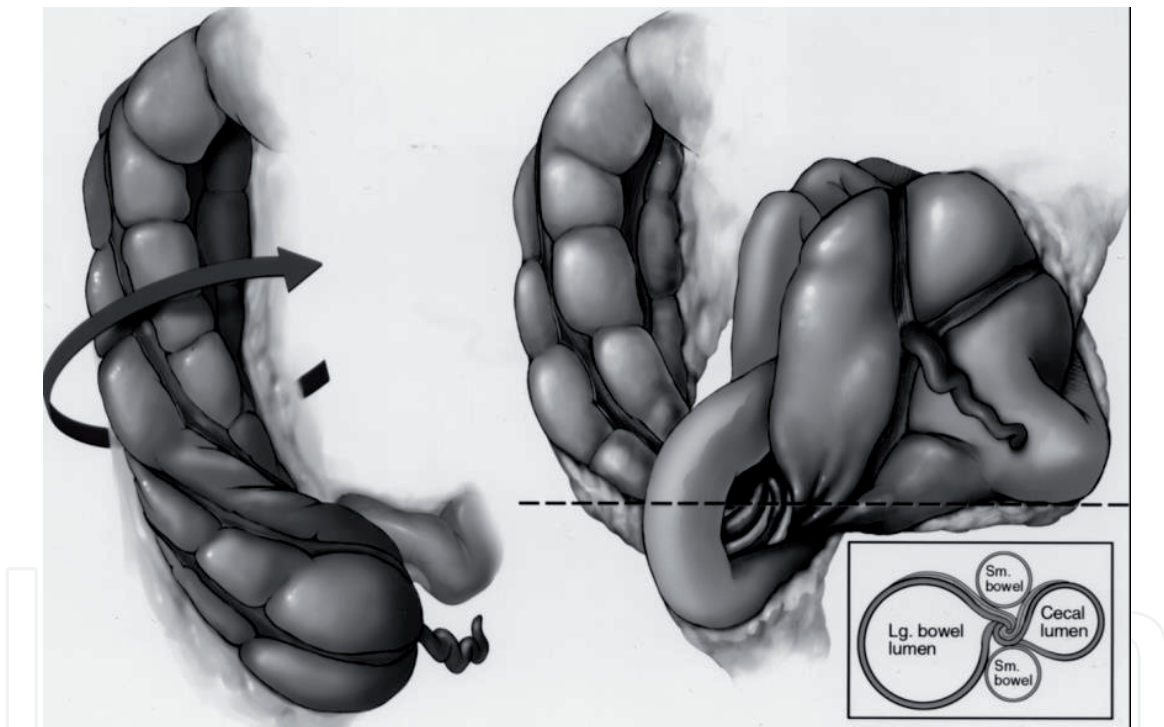


Figure 3.
Pictorial illustration of loop type caecal volvulus with entangled terminal ileum from Moore et al. [22] inset illustrates ‘whirl sign’ at the point of obstruction/torsion as seen in CT images.

Many scholars report three types of caecal volvulus [20–22]:

- Type 1 in which a clockwise axial twist results in the volvulus being located in the right lower quadrant.
- Type 2 in which both the caecum and terminal ileum get involved and ectopically located in the Left upper quadrant in an inverted position. Here, the caecum both twists and inverts and this twist may sometimes be counter clockwise [22]. This type is also referred to as the ‘loop type’ of caecal volvulus. It results in a characteristically empty right iliac fossa [23].

- Type 3 caecal volvulus also known as caecal bascule, is characterised by absence of axial twist.

In all these types, there is potential for intestinal obstruction and strangulation [11, 24] with the risk higher in types 1 and 2 which constitute about 80% of caecal volvulus. Caecal volvulus may sometimes coexist with a synchronous splenic flexure volvulus [25] and/or sigmoid volvulus [26].

Baumann et al. [27] propose a mathematical model based on the physics of a spring to explain the mechanism of occurrence of exercise related caecal volvulus in long distance runners and aggressive walkers. Repetitive vertical stretching of caecum and ascending colon leads to loss of elastic recoil and a lax mesentery which predisposes to volvulus.

5. Clinical presentation

The clinical presentation of caecal volvulus can be divided into separate but interrelated clinical syndromes that is, mobile caecum syndrome, acute obstruction and acute fulminant obstruction [7].

5.1 Mobile caecum syndrome

This may be associated with caecal bascule and occurs due to increased mobility of the caecum. It is characterised by recurrent, intermittent abdominal pain and distension which typically resolves on passage of flatus [18, 28]. Vomiting may occur in only 30% of the patients [18]. It may be associated with some functional colon diseases such as chronic constipation and irritable bowel syndrome.

Gomes et al. [29] propose a laparoscopic grading system for mobile caecum syndrome depending on the degree of mobility of the ileocaecal and appendiceal unit:

- Grade I – The peritoneal attachments are intact and the unit is within the right iliac fossa and does not cross the midline.
- Grade II – The ileocaecal and appendiceal unit can easily be moved across the midline. No fixation hence axial twist about its own axis is possible.
- Grade III – The ileocaecal and appendiceal unit can easily be moved up to the left upper quadrant. No fixation hence axial twist about its own axis is possible.

Caecopexy is advised for Grades II and III.

Due to the quick resolution of symptoms, diagnosis of the mobile cecum syndrome can be difficult. Cesaretti et al. [28] advise performing computed tomography in Trendelenburg position and propose use of virtual colonoscopy to aid diagnosis of mobile caecum syndrome.

Up to 50% of patients with acute obstructive caecal volvulus tend to initially present with features of mobile caecum syndrome [30, 31].

5.2 Acute obstructive pattern

This may be simple – no ischaemia, or fulminant obstruction – bowel ischaemia, sepsis and peritonitis.

These patients present with classical features of acute intestinal obstruction that is, abdominal pain, distension, constipation and vomiting. Being the first part of

large bowel clinical features of caecal volvulus may be indistinguishable from those of acute small bowel obstruction.

In simple obstruction, patients may present with dehydration and electrolyte imbalance due to persistent vomiting. Prolonged obstruction may result in strangulation, gangrene and perforation. At this point patients are toxic, peritonitic, septic and in metabolic acidosis.

The sepsis is associated with translocation of bacteria due to a damaged caecal/colonic mucosal layer. This damage is due to mechanical cut off of arterial blood supply or severe caecal distension >10 cm with intraluminal pressure greatly exceeding mucosal capillary pressure.

Nearly 30% of the acute obstructive pattern occurs in hospitalised patients [32, 33]. This may be attributed to bowel distension and dysmotility. Symptoms in these patients may be masked by the signs and symptoms of concurrent medical illness. High index of suspicion and early diagnostic imaging are therefore paramount [7].

6. Evaluation

Following a thorough history and physical examination, a laboratory workup and appropriate diagnostic imaging should be planned while resuscitation is on-going. The surgeon should be sure to take medication history and ascertain pre-existing comorbidities to ensure they are under control. It is important at this point to pass a urethral catheter and monitor fluid input/output, pass a nasogastric tube if there is excessive distension with vomiting and administer antiemetics and analgesics.

7. Laboratory workup

These are usually non-specific. However, a complete blood count (CBC) with differential, metabolic panel, lactic acid, urea and electrolytes should be done. Fluid and electrolyte imbalance may be found in patients who have had prolonged obstruction with vomiting, bowel ischaemia, peritonitis or systemic sepsis.

8. Radiology

8.1 Plain abdominal radiography (AXR)

In many limited resource settings, this may be the only available radiological investigation. However, the plain AXR is diagnostic in less than 20% of the cases [11, 34] and sometimes the surgeon's only option is to perform an emergency exploratory celiotomy. In cases where AXR is diagnostic or suggestive of caecal volvulus, the typical findings include caecal distension in over 98%, absence of gas in distal colon in 82%, a distended small bowel in 55% that is pushed lateral to the caecum and a single air-fluid level in the right lower quadrant [11]. In contrast to sigmoid volvulus, haustrations are nearly always visible in caecal volvulus. James and Kelly [35] provide an extensive account on how to perform and interpret abdominal radiographs.

8.2 Barium Enema (BE)

This was traditionally used for diagnosis and treatment of colonic volvulus including caecal volvulus [11]. It had the advantage of being 88% accurate and the

possibility of visualising the distal colon for any obstructive causes of volvulus. The “bird beak sign” in the efferent limb is diagnostic [36]. However, it has now been abandoned due to time needed to perform and potential for extravasation of contrast. Currently, a water soluble contrast such as gastrograffin enema may be used [37]. It is absolutely contraindicated in critically ill patients and in suspected perforation or strangulation.

8.3 Computed tomography (CT) scan

Abdominopelvic CT scan is currently the imaging of choice for diagnosis of caecal volvulus. Rosenblatt et al. [38] and later Dane et al. [39] provide an extensive discussion on the utility of CT findings in the diagnosis of caecal volvulus. The CT findings more common in caecal volvulus included severe caecal distension ≥ 10 cm, whirl sign, abnormal caecal position, central appendix – at or close to the midline, split wall, coffee bean sign and distal colonic decompression. In the study conducted by Dane et al., [39] the whirl sign was an independent predictor of caecal volvulus. The “whirl,” “coffee bean” and “bird beak” signs are considered pathognomonic for caecal volvulus although a gas filled appendix is also a common finding especially in the loop type of caecal volvulus [22]. Findings of pneumatosis intestinalis and portal venous gas are suggestive of bowel ischaemia.

8.4 Colonoscopy

In contrast to sigmoid volvulus, the role of colonoscopy in diagnosis and treatment of caecal volvulus is very limited and has a reported success rate of less than 30%. It is associated with delay in definitive operative treatment and high risk for perforation hence not generally recommended [24, 40].

Despite all the above investigations and the high sensitivity and specificity of CT scan for diagnosis of caecal volvulus, diagnosis can sometimes only be made intraoperatively in about 10% of the cases [24, 39, 41].

9. Treatment

Definitive treatment should be sought as soon as the patient has been adequately resuscitated. The surgeon has to decide between non-operative and operative treatment.

9.1 Non-operative treatment

Absolute contraindications to non-operative treatment include pneumoperitoneum, bowel ischaemia, peritonitis or clinically confirmed tenderness over the distended caecum. In very elderly, frail patients with multiple comorbidities and advanced obstruction, the risks of an operation may outweigh the benefits. In such situations, the surgical team may decide to offer palliation. This decision must be reached after consideration of availability of resources for peri and postoperative care and in conjunction with the patient and/or family.

As stated earlier, the role of colonoscopy is generally limited and more than 90% of patients will require surgical treatment. There have been a few reports of successful detorsion of caecal volvulus especially in children albeit with recurrence as early as 6 weeks after colonoscopy [42, 43].

Barium enema is currently not recommended for treatment of caecal volvulus.

9.2 Operative treatment

The surgical approach may be open – midline laparotomy, or laparoscopic depending on availability of resources, surgeon's expertise and patient factors.

A laparoscopic approach is currently considered safe in both the acute and elective setting [28, 37]. In a series of 15 patients with mobile caecum syndrome who underwent laparoscopic caecopexy, Gomes et al. [29] report a very favourable outcome with 84% achieving a modified Visick score [44] of 1 while up to 92% had only a Grade I Clavien-Dindo classification [45].

Most of the time, an emergency laparotomy may be needed especially in fulminant cases even precluding diagnostic imaging. In all cases, an honest discussion needs to be held preoperatively with the patient and their family regarding possible outcomes given available resources. The surgical team will need to be proactive and invite the intensive care team (ICU) for peri and postoperative care planning as some of these patients may require postoperative care in the ICU.

At laparotomy, the decision regarding definitive treatment relies heavily on the operating surgeon and their experience [7]. The factors affecting these decisions are mainly the patient's physiological reserve and state of the bowel. The surgical options are:

- Detorsion and/or caecopexy
- Caecostomy – decompresses caecum and fixes it on to the anterior abdominal wall.
- Resection and primary anastomosis – this may be the traditional right hemicolectomy or a more limited ileocaecal resection with or without colopexy of the right colon.
- Resection and temporary ileostomy or ileostomy with mucus fistula.

There are no randomized controlled trials comparing these treatment options. However, in the presence of gangrene – which occurs about 23 to nearly 100% of the time [24], overly distended and stretched caecum, resection is mandatory. It is advisable not to untwist the gangrenous portion in order not to release toxins into the blood circulation that would lead to worsening of septic shock [46].

Overall mortality with resectional procedures is up to 32% [24]. In patients with poor physiological reserve, a conservative approach such as limited ileocaecal resection or formation of an ileostomy may reduce intraoperative time and result in better postoperative outcome [47]. In synchronous caecal and sigmoid volvulus, a total colectomy with ileostomy may sometimes be necessary [26].

Detorsion alone is associated with a recurrence of up to 75% [24]. A combination of detorsion and caecopexy greatly reduces this recurrence rate to less than 15% with a mortality of about 10% [11]. The technique of caecopexy involves placing two to three knots to attach the lateral taenia coli of the caecum or right colon in colopexy to the right paracolic gutter approximately along the level of the axillary line [29]. This may be achieved by initially raising a peritoneal flap at this level as in the Dixon and Meyer's approach [48]. Sakamoto et al. [49] report a successful case of percutaneous endoscopic colopexy in caecal volvulus.

Caecostomy alone is associated with a mortality of 22% and a recurrence rate of 14–20% [11]. It is advised as a temporary measure or in very high-risk surgical candidates. The technique involves catheter or tube decompression of the caecum

through the anterior abdominal wall. The catheters may regularly get blocked due to the viscid faeces and may require regular flushing. Alternatively, a wider more rigid size 8–9 mm endotracheal tube may be ballooned, sutured in place and attached to an ordinary urinary bag [50]. The approach to caecostomy may be percutaneous – endoscopic or needle [51, 52], or during formal laparotomy.

10. Conclusion

Caecal volvulus is a rare but important cause of intestinal obstruction. It is both organ and life threatening especially if advanced and fulminant. Abdominopelvic CT scan is the preferred imaging and the “whirl sign” is an independent predictor of caecal volvulus. The choice of surgical option hugely depends on the operating surgeon. Current advances favour a multidisciplinary approach and colectomy as the choice of treatment following adequate resuscitation. The surgeon should work closely with the intensive care team as some of these patients may require postoperative mechanical ventilation. Both patient and/or family preferences need to be considered during the course of management.

Conflict of interest

None.

Author details

Paul K. Okeny
School of Postgraduate Studies, Royal College of Surgeons in Ireland,
Dublin, Ireland

*Address all correspondence to: PaulOkeny@rcsi.ie; okenykpaul@yahoo.ca

IntechOpen

© 2020 The Author(s). Licensee IntechOpen. This chapter is distributed under the terms of the Creative Commons Attribution License (<http://creativecommons.org/licenses/by/3.0>), which permits unrestricted use, distribution, and reproduction in any medium, provided the original work is properly cited. 

References

- [1] Ballantyne GH. Review of sigmoid volvulus: History and results of treatment. *Diseases of the Colon and Rectum*. 1982;**25**(5):494-501
- [2] Rokitansky C. Intestinal strangulation. *Archives of General Internal Medicine*. 1837;**14**:202-204
- [3] Ballantyne GH, Brandner MD, Beart RW Jr, Ilstrup DM. Volvulus of the colon. Incidence and mortality. *Annals of Surgery*. 1985;**202**(1):83-92
- [4] Heis HA, Bani-Hani KE, Rabadi DK, Elheis MA, Bani-Hani BK, Mazahreh TS, et al. Sigmoid volvulus in the Middle East. *World Journal of Surgery*. 2008;**32**(3):459-464
- [5] Bruusgaard C. Volvulus of the sigmoid colon and its treatment. *Surgery*. 1947;**22**(3):466-478
- [6] Renzulli P, Maurer CA, Netzer P, Büchler MW. Preoperative colonoscopic derotation is beneficial in acute colonic volvulus. *Digestive Surgery*. 2002;**19**:223-229
- [7] Consorti ET, Liu TH. Diagnosis and treatment of caecal volvulus. *Postgraduate Medical Journal*. 2005;**81**:772-776
- [8] Halabi WJ, Jafari MD, Kang CY, Nguyen VQ, Carmichael JC, Mills S, et al. Colonic volvulus in the United States: Trends, outcomes, and predictors of mortality. *Annals of Surgery*. 2014;**259**(2):293-301
- [9] Moritz AR. Mesenterium commune with intestinal obstruction. *The American Journal of Pathology*. 1932;**8**(6):735-744.1
- [10] Gingold D, Murrell Z. Management of colonic volvulus. *Clinics in Colon and Rectal Surgery*. 2012;**25**(4):236-244
- [11] Rabinovici R, Simansky DA, Kaplan O, Mavor E, Manny J. Cecal volvulus. *Diseases of the Colon and Rectum*. 1990;**33**(9):765-769
- [12] Montes H, Wolf J. Cecal volvulus in pregnancy. *The American Journal of Gastroenterology*. 1999;**94**:2554-2555
- [13] Tejler G, Jiborn H. Volvulus of the cecum. Report of 26 cases and review of the literature. *Diseases of the Colon and Rectum*. 1988;**31**:445-449
- [14] Viney R, Fordan SV, Fisher WE, Ergun G. Cecal volvulus after colonoscopy. *The American Journal of Gastroenterology*. 2002;**97**(12):3211-3212
- [15] Miura da Costa K, Saxena AK. A systematic review of the management and outcomes of cecal and appendiceal volvulus in children. *Acta Paediatrica*. 2018;**107**(12):2054-2058
- [16] Elsharif M, Basu I, Phillips D. A case of triple volvulus. *Annals of the Royal College of Surgeons of England*. 2012;**94**(2):e62-ee4
- [17] Majeski J. Operative therapy for cecal volvulus combining resection with colopexy. *American Journal of Surgery*. 2005;**189**(2):211-213
- [18] Lung BE, Yelika SB, Murthy AS, Gachabayov M, Denoya P. Cecal bascule: A systematic review of the literature. *Techniques in Coloproctology*. 2018;**22**(2):75-80
- [19] Park J-S, Ng K-S, Young CJ. Caecal bascule: A case series and literature review. *ANZ Journal of Surgery*. 2018;**88**(5):E386-E3E9
- [20] Le CK, Qaja E. Caecal Volvulus *Treasure Island: StatPearls*; 2019 [updated 28 February 2019]

- [21] Delabrousse E, Sarliève P, Sailley N, Aubry S, Kastler BA. Cecal volvulus: CT findings and correlation with pathophysiology. *Emergency Radiology*. 2007;**14**(6):411-415
- [22] Moore CJ, Corl FM, Fishman EK. CT of cecal volvulus. *American Journal of Roentgenology*. 2001;**177**(1):95-98
- [23] Zabeirou AA, Belghali H, Souiki T, Ibn Majdoub K, Toughrai I, Mazaz K. Acute cecal volvulus: A diagnostic and therapeutic challenge in emergency: A case report. *Annals of Medicine and Surgery*. 2019;**48**:69-72
- [24] Madiba TE, Thomson SR. The management of cecal volvulus. *Diseases of the Colon and Rectum*. 2002;**45**(2):264-267
- [25] Islam S, Hosein D, Harnarayan P, Naraynsingh V. Synchronic volvulus of splenic flexure and caecum: A very rare cause of large bowel obstruction. *BMJ Case Reports*. 2016;**2016**:bcr2015-213029
- [26] Roy SP, Tay YK, Kozman D. Very rare case of synchronous volvulus of the sigmoid colon and caecum causing large-bowel obstruction. *BML Case Reports*. 2019;**12**(1):bcr-2018-227375
- [27] Bauman BD, Witt JE, Vakayil V, Anwer S, Irwin ED, Kwaan MR, et al. Cecal volvulus in long-distance runners: A proposed mechanism. *The American Journal of Emergency Medicine*. 2019;**37**(3):549-552
- [28] Cesaretti M, Trotta M, Leale I, Minetti GA, Cittadini G, Montecucco F, et al. Surgery to treat symptomatic mobile cecum syndrome is safe and associated with good recovery outcomes. *Case Reports in Gastrointestinal Medicine*. 2018;**2018**:4718406
- [29] Gomes CA, Soares C Jr, Catena F, Di Saverio S, Sartelli M, Gomes CC, et al. Laparoscopic Management of Mobile Cecum. *JSLs*. 2016;**20**(4):e2016.00076
- [30] Rogers RL, Harford FJ. Mobile cecum syndrome. *Diseases of the Colon and Rectum*. 1984;**27**(6):399-402
- [31] Printen KJ. Mobile cecal syndrome in the adult. *The American Surgeon*. 1976;**42**(3):204-205
- [32] Theuer C, Cheadle WG. Volvulus of the colon. *The American Surgeon*. 1991;**57**(3):145-150
- [33] Friedman JD, Odland MD, Bubrick MP. Experience with colonic volvulus. *Diseases of the Colon and Rectum*. 1989;**32**(5):409-416
- [34] Rakinic J. Colonic volvulus. In: Beck DE, Roberts PL, Saclarides TJ, Senagore AJ, Stamos MJ, Wexner SD, editors. *The ASCRS Textbook of Colon and Rectal Surgery*. New York, NY: Springer; 2011. pp. 395-406
- [35] James B, Kelly B. The abdominal radiograph. *The Ulster Medical Journal*. 2013;**82**(3):179-187
- [36] Young WS. Further radiological observations in caecal volvulus. *Clinical Radiology*. 1980;**31**(4):479-483
- [37] Kelly MD, Bunni J, Pullyblank AM. Laparoscopic assisted right hemicolectomy for caecal volvulus. *World Journal of Emergency Surgery*. 2008;**3**(1):4
- [38] Rosenblat JM, Rozenblit AM, Wolf EL, DuBrow RA, Den EI, Levsky JM. Findings of cecal volvulus at CT. *Radiology*. 2010;**256**(1):169-175
- [39] Dane B, Hindman N, Johnson E, Rosenkrantz AB. Utility of CT findings in the diagnosis of cecal volvulus. *American Journal of Roentgenology*. 2017;**209**(4):762-766

- [40] Anderson MJ, Okike N, Spencer RJ. The colonoscope in cecal volvulus: Report of three cases. *Diseases of the Colon and Rectum*. 1978;**21**(1):71-74
- [41] Pulvirenti E, Palmieri L, Toro A, Carlo ID. Is laparotomy the unavoidable step to diagnose caecal volvulus? *Annals of the Royal College of Surgeons of England*. 2010;**92**:e27-e29
- [42] van de Lagemaat M, Blink M, Bakx R, de Meij TG. Cecal volvulus in children: Is there place for colonoscopic decompression? *Journal of Pediatric Gastroenterology and Nutrition*. 2018;**66**(2):e59-e60
- [43] Shahramian I, Bazil A, Ebadati D, Rostami K, Delaramnasab M. Colonoscopic decompression of childhood sigmoid and cecal volvulus. *The Turkish Journal of Gastroenterology*. 2018;**29**(2):221-225
- [44] Rijnhart-De Jong HG, Draaisma WA, Smout AJ, Broeders IA, Gooszen HG. The Visick score: A good measure for the overall effect of antireflux surgery? *Scandinavian Journal of Gastroenterology*. 2008;**43**(7):787-793
- [45] Dindo D, Demartines N, Clavien PA. Classification of surgical complications: A new proposal with evaluation in a cohort of 6336 patients and results of a survey. *Annals of Surgery*. 2004;**240**(2):205-213
- [46] Tuech JJ, Becouarn G, Cattani F, Arnaud JP. Volvulus of the right colon. Plea for right hemicolectomy. Apropos of a series of 23 cases. *J Chir (Paris)*. 1996;**133**(6):267-269
- [47] Kaushal-Deep SM, Anees A, Khan S, Khan MA, Lodhi M. Primary cecal pathologies presenting as acute abdomen and critical appraisal of their current management strategies in emergency settings with review of literature. *International Journal of Critical Illness and Injury Science*. 2018;**8**(2):90-99
- [48] Dixon CF, Meyer AC. Volvulus of the cecum. *The Surgical Clinics of North America*. 1948;**28**(Mayo Clinic Number):953-963
- [49] Sakamoto Y, Hiyoshi Y, Sakata K, Toyama E, Takata N, Yoshinaka I, et al. Case of cecal volvulus successfully treated with endoscopic colopexy. *Asian Journal of Endoscopic Surgery*. 2018;**11**(4):402-404
- [50] Ingoldby CJ, Dawson A, Addison NV. A new technique of caecostomy using endotracheal tubes. *Annals of the Royal College of Surgeons of England*. 1989;**71**(4):211-212
- [51] Koundouris C, Thivaos I, Chrysoulas G, Manisali A, Avitidou E, Sofos G, et al. Percutaneous endoscopic colostomy/caecostomy - A minimally invasive approach to certain colonic disorders: Report of five cases and review of the literature. *Hellenic Journal of Surgery*. 2016;**88**(2):93-96
- [52] Limmer AM, Clement Z. Percutaneous emergency needle Caecostomy for prevention of Caecal perforation. *Case Reports in Surgery*. 2017;**2017**:1090769