

We are IntechOpen, the world's leading publisher of Open Access books Built by scientists, for scientists

6,900

Open access books available

186,000

International authors and editors

200M

Downloads

Our authors are among the

154

Countries delivered to

TOP 1%

most cited scientists

12.2%

Contributors from top 500 universities



WEB OF SCIENCE™

Selection of our books indexed in the Book Citation Index
in Web of Science™ Core Collection (BKCI)

Interested in publishing with us?
Contact book.department@intechopen.com

Numbers displayed above are based on latest data collected.
For more information visit www.intechopen.com



Current Strategies for Prevention and Treatment of Equine Postoperative Ileus: A Multimodal Approach

*Milomir Kovac, Ruslan Aliev, Sergey Pozyabin,
Nevena Drakul and Albert Rizvanov*

Abstract

Equine paralytic (postoperative) ileus generally refers to an acute condition of impaired gastrointestinal motility. Paralytic ileus is most frequently seen following abdominal surgery on the small intestine in horses. Three main mechanisms are involved separately or simultaneously in its causation, namely neurogenic-endocrinic, inflammatory-endotoxic and pharmacological mechanisms. Regardless of the cause, equine paralytic ileus can be fatal, if not properly diagnosed and treated. Over the past 22 years (1997–2019), we have diagnosed and treated more than 180 horses with postoperative ileus using differing methods. Based on our results and experience, and that of others, we have developed a multimodal strategy to reduce the incidence of postoperative ileus. This has resulted in effective treatment of ileus-diagnosed patients in 94% of cases, a significant improvement in survival rates over the last 20 years. In this review, we described pre-, intra-, and postoperative multiple supplementary preventative and treatment procedures that cure this condition. These methods are dependent on individual cases but include the control of endotoxemia and inflammation, as well as using the least traumatic surgical techniques, carrying out the pelvic flexure colotomy, improved anesthesia techniques, treating with continuous postoperative peritoneal lavage, the use of fluid, antibiotic and NSAIDs therapy, according to a scheme the use of different prokinetic agents (including metoclopramide, neostigmine methylsulfate and domperidone), nasogastric decompression, management to minimize the surgical and postoperative stress reaction and judicious timing of postoperative feeding of horses.

Keywords: postoperative ileus, paralytic ileus, horse, prevention, treatment

1. Introduction

Visceral abdominal pain of the horse, defined as equine colic, is one of the most acute life-threatening problems facing equine practitioners [1]. The incidence of equine colic has been reported as between 4 and 10 cases/100 horses/year [2]. Colic in horses can be caused by more than 70 pathological processes in the gastrointestinal tract and manifests itself in many forms [3]. The diseases that

accompany colic in horse are often characterized by ileus. The Greek physician Soranus defined an ileus as “a severe and dangerous twisting of the intestines.” Currently, an ileus can be referred to as a symptom characterized by a complete or partial disturbance passage of contents through the intestinal canal, due to obturation, strangulation, spasm, ischemia, adhesions and impaired motor function (paralytic ileus) [4].

The definition of paralytic ileus is somewhat controversial. Paralytic ileus is mostly defined as a temporary or permanent cessation of propulsive contractions of the gastrointestinal tract, irrespective of pathogenetic mechanisms, with subsequent gut dilation and accumulation of secretions and gas within its lumen [5]. Paralytic ileus in the horse is not a primary disorder but rather an underlying cause and can be classified on the basis of its etiology. More than 95% of all paralytic ileus cases in horses, seen after abdominal surgery, are primarily in the small intestine [6, 7]. Precisely for this reason, the paralytic ileus is often signified as postoperative ileus (POI). Once in a while, equine POI can be classified more precisely according to anatomical localization, for instance POI of the small intestine or POI of the cecum and colon. POI of the small intestine is easy to diagnose, through the presence of gastric reflux (i.a.), and impaired motor function seldom occurs in other parts of the gastrointestinal tract in horses too [8]. In the latter rarer cases, diagnosis is more of a challenge, because the presence of gastric reflux in the postoperative period is relatively uncommon after surgery on the large intestine in horses [9]. However, it must be considered also that the dysmotility in equine POI of small intestine may mask large intestine involvement.

In people following surgery, the return of the small intestine’s action generally begins around 4–8 h postoperatively and generally completes in around 24 h [10]. The colon resumes its function between 48 and 72 h postoperatively [11, 12]. In humans, based on this observation, various additional qualifying terms have been applied to POI, such as physiological POI, prolonged POI and recurrent POI [13]. This classification system can also be applied to horses, but it must be emphasized that the recurrent form of POI is very rare [14].

Regardless of determination or classification, equine paralytic ileus is a common and serious complication of surgery associated with highly increased odds of death. Reported fatality rate in horses with POI also varies widely, from 13 to 86% [15–18]. In one study, horses that developed postoperative ileus were nearly 30 times less likely to survive than horses that did not develop ileus [19]. Additionally, equine POI leads to increased hospitalization time and treatment costs. It is for these reasons that since the first modern attempts to undertake abdominal surgery 50 years ago through to today, prevention and treatment of POI are widely discussed topics in equine medicine [20, 21]. In human medicine, enhanced recovery after surgery (ERAS) programs exist, which include multiple pre-, intra- and postoperative interventions, aiming to reduce the occurrence of POI [22]. Currently, in equine medicine, no universally-accepted approach exists for the management of equine POI.

Over the past 22 years, we have diagnosed and treated more than 180 horses with POI, using, in two veterinary clinics “Hochmoor” (Germany, 1997–2007) and “New Century” in Moskow (Russia, 2007–2019). In the latter times, with multiple pre-, intra- and postoperative procedures, not only was POI prevalence reduced significantly, but also following occurrences of equine POI successful treatment and survival were possible in more than 94% of cases. The purpose of this chapter review is to clarify some of the proposed key mechanisms in the pathophysiology of POI, share our experiences and make proposals for the prevention and treatment of equine POI.

2. Normal physiology of equine gastrointestinal motility

An appreciation of the basic mechanisms that regulate gastrointestinal motility is a key component to understanding paralytic ileus. The musculature of the gastrointestinal tract in horses is made up of smooth muscle cells that are intimately associated, thus allowing them to conduct electrophysiological functions. There are three distinctive electrical potentials in the equine intestine: resting potential, slow-wave and spike potential that trigger contractions. Slow waves are rhythmic pacemaker currents initiated by the interstitial cells of Cajal (ICC). Normal gastrointestinal motility in horses results from very complex interactions among the enteric nervous system (ENS), autonomic and central nervous systems, ICC, gastrointestinal hormones, immune cells, glial cells and local factors that affect smooth-muscle activity [21, 23–25]. Extrinsically, the sympathetic nervous input through noradrenaline has an inhibitory effect on gastrointestinal motility, whereas parasympathetic input increases motility. The ENS is involved in all aspects of gastrointestinal function, not only motility, as well as by enteric processes such as immune responses, detecting nutrients, microvascular circulation, intestinal barrier function, and epithelial secretion of fluids and ions [10]. The neurons of the ENS are collected into two types of ganglia: myenteric (Auerbach's) and submucosal (Meissner's) plexuses. The enteric nervous system influences the gastrointestinal tract either directly through neurotransmitters or indirectly through intermediate cells, such as the ICC, cells of the immune system or endocrine cells [10]. These intestinal neurons communicate through more than 25 different neurotransmitters, including stimulatory neurotransmitters (acetylcholine, neurokinin A, adenosine, substance P, motilin, serotonin and cholecystokinin) and inhibitory neurotransmitters, for instance, vasoactive intestinal peptide (VIP), nitrous oxide (NO), neuropeptide Y, calcitonin gene-related peptide, GABA and neurotensin [26–29]. The endocrine system also indirectly affects regulation of the gastrointestinal tract motility. The hormones related to stress activity (glucocorticoids, cortico-realizing peptide, thyroid hormones and somatotrophic hormone) have the most pronounced inhibitory effect on gastrointestinal tract activity. Additionally, the intestinal cells produce a range of hormones and hormone-like substances, some of which are also neurotransmitters. These substances regulate the motility of the gastrointestinal tract (motilin, enteroglucagon, cholecystokinin, pancreatic polypeptide and peptide YY) and secretory activity (gastrin, secretin, cholecystokinin, pancreatic polypeptide, gastric inhibitory peptide and neurotensin) and also regulate the production of other hormonal substances (somatostatin and gastrin-releasing peptide) [30].

3. Prevalence and risk factors for equine postoperative ileus

The etiology of paralytic ileus in the horse is multifactorial, and various factors contribute either simultaneously or at various times during the development of this entity. In the current literature, the incidence of POI in horses undergoing surgical treatment of all types of colic has been reported to range from 10 to 21% [31–33]. The incidence of POI in horses undergoing surgical treatment for small intestine lesions varies widely from 10 to 73% [1, 15, 16, 18–20, 31, 34–38]. The large variation in the reported rates can be at least partly explained by the criteria used to define postoperative ileus. Other forms of paralytic ileus, those that do not present due to equine surgery, are much less common than in humans. These include forms that result from metabolic derangements, acid-base abnormalities, electrolyte

imbalances (hypokalemia and hypocalcemia), severity stress syndrome, peritonitis, bacterial infection, uremia, hypoalbuminemia, abdominal trauma, burns, botulism, grass sickness, atrophic visceral myopathy and application of drugs and anesthetic agents [6, 7, 26, 32].

According to our investigation, there was no significant age or breed dependence associated with the incidence of postoperative ileus in horses, but stallions more often had POI than geldings [39]. Our observations showed that the horses with a so-called hot temperament (i.e., horses with more excitable demeanors) had increased risks of developing POI than warm- or cold-blooded horses. The preliminary results (unpublished data) also showed that horses with behavioral symptoms of stress and high concentrations of cortisol in their blood in the pre- and postoperative time more often had POI than horses with normal concentrations of cortisol.

According to our observations, if pre- and during surgical intervention the equine jejunum had a high degree of intraluminal distension (more than 8 cm), postoperative ileus was more likely to occur and did so in more than 70% of the cases observed [32]. This is partly confirmed by other authors [15, 18]. A possible reason for this finding is the long onset of colic disease and high degree of endotoxic shock, which leads to enteric nervous system damage and a high degree of intraluminal jejunum distension. It has been demonstrated that decreases in intestinal motility through the distension of equine jejunum are partly due to decreases in motilin receptor synthesis [21].

Horses with small intestinal strangulating obstruction (for instance, by hernia inguinalis, entrapment in foramen omentalis) are at increased risk of developing POI, compared with obstructive ileus (for instance, by ileum or jejunum obstipation) [40, 41]. A basis for higher concentration endotoxins is that horses with entrapment in the foramen omentalis have lower blood pressures during abdominal surgery than horses with ileum obstipation [42]. It has also been shown that horses suffering from pedunculated lipoma obstruction are three times more likely to suffer from POI when compared with horses suffering from other intestinal pathologies [3]. This fact was confirmed in our own observations [4]. Many factors are associated with increased risk of POI in horses with pedunculated lipoma obstruction, for instance age-related decreases in intestinal density of the enteric neurons and glial cells, rapidly developing endotoxic shock and perhaps also high colic pain, which lead to enormous activation of the sympathetic nervous system.

Numerous studies have shown that long duration of colic disease, with evidence of endotoxin shock (high pulse rate and hemoconcentration), the presence of >8 l of reflux at admission, anesthesia for longer than 2.5 h, and the performance of a small intestinal resections pose enormous risks for POI development [15, 31, 43, 44]. Based on our results, the risk of developing POI and other fatal complications were associated with increased duration of surgery [14]. Surgical techniques also affect the incidence of POI in horses. The ability to perform a safe bowel resection and anastomosis techniques also affects the incidence of POI in horses; for instance, the use of jejunocecostomy has been associated more often with the development of POI when compared to horses in which end-to-end jejunostomy is performed [45]. One possible reason for this fact is possibly that the end-end jejunostomy is done more rapidly, and therefore duration of surgery and anesthesia is shorter than by the jejunocecostomy.

Other postoperative complications such as primarily postanesthetic myopathy and peritonitis increased the rapid risk of POI development in horses [46]. Other postoperative complications after colic surgery for example incisional infection, herniation and dehiscence, jugular vein thrombophlebitis, laminitis, adhesions and

diarrhea had no important influence on the development of POI; however, these complications tend to develop later during the postoperative period in horses [39].

4. Pathophysiology of equine postoperative ileus

The pathogenesis of postoperative ileus is complex, with multiple factors contributing either simultaneously or at various times during the development of this entity. The classical view in the pathogenesis of POI involves two phases: an initial neurogenic phase resulting in immediate postoperative impairment of intestinal motility and a subsequent inflammatory phase lasting for several days [24, 30, 37, 47]. On the basis of our observations, we expanded this view into three (or five) main mechanisms, which either independently or in combination are involved in the causation of equine postoperative ileus, namely inflammatory-endotoxic mechanism, neurogen-endocrinic mechanism and pharmacological-anesthetic mechanisms. However, the importance of each contributing mechanism may vary over time, with considerable overlap and possible interactions; therefore, this division is conditional.

4.1 The role of inflammation and endotoxemia

Postoperative inflammation of the small intestine (and nearly imperceptibly of equine large intestine) is an important factor in the pathophysiology of equine POI [9, 48]. It is well known that inflammation is a biological response of the immune system, blood vessels and molecular mediators to a broad range of different stimuli such as pathogens, endotoxins, and physical and chemical irritants. There are a lot of inflammatory agents to take into consideration in POI, for instance, specific intestinal pathology and tissue injury (including obturation, strangulation and adhesion), bacteria, endotoxins, surgical trauma and manipulation [49–53]. The classical intestinal inflammation following paralytic ileus occurs by the duodenitis-proximal jejunitis (DPJ). This syndrome is caused primarily by toxic and infectious agents (e.g., *Salmonella* and *Clostridium perfringens*) [4, 44].

Horses with strangulating lesions of the small intestine have been shown to have various degrees of serosal and neuromuscular inflammation and high numbers of apoptotic cells (including smooth muscle, enteric neurons and glia), possibly due to intestinal ischemia and reperfusion injury [23, 54–57]. According to different studies, equine POI might actually be triggered by a primary disturbance of the smooth muscles' ability to contract, and how the number of smooth muscles or

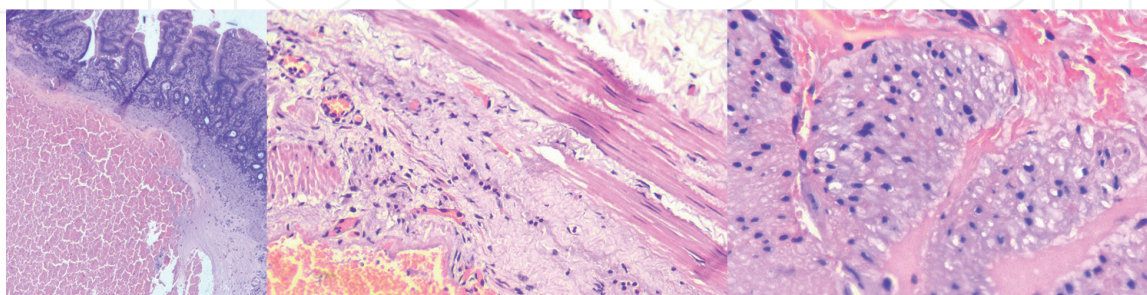


Figure 1.

Histological appearance of the jejunum in a horse affected by postoperative ileus. Note the mucous membrane maintaining its correct structure. In the submucosal layer and on the border with the inner muscle, extensive delaminating hemorrhage and leukocyte reaction were determined. Muscle fibers of the inner muscle layer with pronounced dystrophic changes in the cytoplasm were present. Ganglion cells in the intramuscular layer were not detected; in their place, a loose, weakly basophilic fibrous connective tissue with single mononuclear cells was present. The serosa was moderately edematous. H&E stained, $\times 10$ magnification.

neural receptors has changed through a leukocytic and macrophage inflammatory response, primarily within the intestinal muscularis externa (**Figure 1**) [58–60]. Potentially due to different inhibitory mediators (NO, SP, VIP and NPY), cytokines (TNF, IL-1b, IL-6 and IL-10), monocyte chemotactic protein-1, prostaglandins, histamine, mast cell proteinase-1, tryptase, reactive oxygen intermediates, defensins and adenosine secreted from the muscularis externa during intestinal inflammation and abdominal surgery [49, 61–64]. This local molecular inflammatory response increases prostaglandin E2 levels in the peritoneal cavity that correlates temporally with the development of postoperative ileus [13, 65, 66]. According to our former investigations, in most cases of equine abdominal surgery, during three postoperative days, the concentration of leukocytes is markedly increased (sometimes up to $100 \times 10^9/l$) as are total plasma proteins in the peritoneal cavity [39]. In the horse, postoperative neutrophilic and eosinophilic inflammation of the jejunum has been identified up to 18 h postoperatively [55, 67].

In intestinal inflammation, pathogen-associated molecular patterns or PAMPs have important roles. These molecules can be referred to as small molecular motifs conserved within a class of microbes. Bacterial lipopolysaccharides or endotoxins found on the cell membranes of Gram-negative bacteria are considered to be the prototypical class of PAMPs. The endotoxins are very potent and are widely spread inflammation-inducing substances. One of the basic characteristics of almost all gastrointestinal disorders in horses (primarily by different forms of strangulation ileus) is the development of the endotoxic shock [68]. The mucosal barrier of the equine intestine normally efficiently restricts the transmural movement of endotoxins and bacteria. However, whenever the integrity of the mucosal barrier is lost, as occurs with inflammation or ischemia of the intestinal wall, endotoxins cross into the portal blood and peritoneal cavity [69]. The generally accepted scheme for endotoxin binding is to CD14-bearing receptor cells (monocytes, macrophages, dendritic cells, and possibly vascular endothelial cells), which then associates with the TLR4-MD-2 complex to initiate a downstream signal, causing a proinflammatory response, such as leukocyte recruitment [53]. Macrophage-derived cytokines (such as IL-1b and TNF), as well as arachidonic acid metabolites (i.e., prostacyclin and thromboxane), are responsible for many of the pathophysiologic consequences of endotoxemia and tissue injury in equine colic cases. Endotoxins among other things activate inducible nitric oxide synthase (iNOS) in intestinal macrophages [66]. The resultant increase in NO release stimulates decreased smooth muscle contractility. In healthy ponies, IV infusion of endotoxin also resulted in inhibition of motility in the stomach, cecum, left dorsal colon, and small colon [70]. However, no nasogastric reflux was observed. Although motility in the small intestine was increased, its myoelectric pattern was abnormal. The effects of endotoxins on motility were partially mediated by PGE₂ possibly stimulating alpha-2 adrenergic receptors [28, 51, 71]. A platelet-activating factor (PAF) antagonist suppressed some of the endotoxin-induced inhibition of motility in horses. These findings led to the conclusion that the PAF may also play a role in the development of POI [68].

The degree of endotoxic shock in horses is directly dependent on the forms and time span of gastrointestinal disease [72]. As the concentration of Gram-negative bacteria is highest in the large intestine of horses, the release of endotoxin and development of endotoxic shock are logically expected in pathologies of this part of the gastrointestinal tract, for instance by volvulus or colitis [43]. In the small intestine of horses, different population of Gram-negative bacteria exist, but in lower concentrations than observed in the large intestine. It would therefore be expected that in this case the endotoxins would not play a decisive role in development of POI. In contrast to this theory in one study of colic cases, the highest endotoxin concentrations were found in horses with entrapment in the foramen omentalis,

pedunculated lipoma obstruction and volvulus (torsion) of the large colon [72]. A significant impairment of small intestine transit has been shown in a rat model of colonic manipulation, which occurred even when the small intestine was surgically isolated [73]. These findings led to the conclusion that colonic manipulation induces an inflammatory response in the muscularis of the small intestine that is initiated and maintained by the release of endotoxins from the colon.

One potential trigger for intestinal inflammation not only endotoxins, as well the damage-associated molecular patterns (DAMPs) which realase by extensive surgical intestinal manipulation, luminal distension and resection [6, 7, 48, 52]. DAMPs are host biomolecules that can initiate a noninfectious inflammatory response. DAMPs are mostly cytosolic proteins and materials derived from the extracellular matrix (including hyaluronan fragments, ATP and heparin sulfate) and are generated following tissue injury [6, 7]. An activation of resident muscularis macrophages in the small intestine through DAMPs results in recruitment of intracellular signaling pathways (p38, JNK/SAP) and the release of pro-inflammatory cytokines [6, 7, 37]. Inducible NO synthase (iNOS) and cyclooxygenase-2 (COX-2) upregulation then facilitates the production of NO and prostaglandins, both of which impair the contractile activity of the small intestine [52, 74, 75]. It additionally reduces lymphatic drainage with the occurrence of intestinal edema, which further impairs intestinal motility [76].

4.2 The role of the neurogen-endocrinic factors

The sympathetic division of the autonomic nervous system maintains internal organ homeostasis and initiates the stress response. In addition, sympathetic (adrenergic) hyperactivity results in the reduction of propulsive intestinal motility [8, 77, 78]. In the early component of ileus, the sympathetic neural pathways are activated already in the preoperative period, primarily through intestinal distension or strangulation (i.e., through initial colic pain), but inflammation and surgical manipulation and incision of the intestines and abdomen wall additionally stimulate afferent nerve fibers that subsequently activate peripheral, spinal and/or supraspinal reflex pathways [8, 15, 24, 27]. The sympathetic hyperactivity is amplified through various preoperative stressors (i.e., transport to clinic, unfamiliar surroundings with unknown caretakers, restraint of the horse for examination and rectal investigation) and also in the postoperative period of horse, initially by the recovery from anesthesia, but also in many postoperative diagnostic and management procedures (such as tying in stall, fasting, gastric decompression and blood collection) [24, 79]. There is overwhelming experimental and clinical evidence that different stress paradigms influence gastrointestinal motility [47, 80–82].

Sympathetic hyperactivity in horse primarily depends on the intensity of the nociceptive (pain) receptor stimulus [83]. Numerous nociceptors of sensory intestinal neurons by tissue damage or surgical manipulation send signals to the spinal cord and further to specific hypothalamic and pontine-medullary neurons. Within this pathway, corticotropin-releasing factor (CRF) plays a central role in inhibiting gastric and small intestinal motor function (but not of the colon) via interaction with the CRF-R2 receptors [82, 84–88]. The CRF stimulates neurons in the supra-optic nucleus of the hypothalamus, which send projections to the spinal cord, including the intermediolateral column of the thoracic cord, where sympathetic preganglionic neurons are located [88, 89]. At this point, inhibitory sympathetic efferent neurons are activated. Norepinephrine is released by sympathetic neurons at the enteric ganglia, which inhibit the release of the excitatory neurotransmitter acetylcholine by stimulating $\alpha 2$ -receptors located presynaptically on cholinergic neurons [21]. This causes a depression of smooth muscle contractions in the gastrointestinal tract.

Activation of CRF receptors in the hypothalamus of horses mediates almost the entire repertoire of behavioral, neuroendocrine, autonomic, immunologic and visceral responses characteristic of stress syndrome [77, 90]. CRF release is the first step in activation of the hypothalamic-pituitary-adrenal axis (HPA axis) involved in stress response. The magnitude and duration of the activation in the HPA axis are proportional to the initial tissue damage and surgical injury, but also in other perioperative stress conditions. The pituitary gland responds to CRF by synthesizing a larger precursor molecule, proopiomelanocortin, which is metabolized within the pituitary into ACTH, β -endorphin and N-terminal precursor. Growth hormones and prolactin are also secreted in increased amounts from the pituitary in response to a surgical stimulus. Surgery is one of the most potent activators of ACTH and cortisol secretion; therefore, increased plasma concentrations of both hormones in human can be measured within minutes of the start of surgery [91]. Usually, a feedback mechanism operates so that increased concentrations of circulating cortisol inhibit further secretion of ACTH. This control mechanism appears to be ineffective after surgery resulting in elevated concentrations of both hormones [80]. Cortisol has known complex metabolic effects on the metabolism of carbohydrate, fat and protein. Cortisol impairs inflammation, which is helpful in the short term during conditions such as 'fight-or-flight,' also referred to as hyperarousal, or the acute stress response. In response to surgical trauma, massive levels of catecholamine (adrenaline, noradrenaline and dopamine) and glucagons are also released, while serum insulin concentrations decrease relatively [91]. The overall metabolic effect of the hormonal changes is increased catabolism, which mobilizes substrates to provide energy sources, and a mechanism to retain salt and water and maintain fluid volume and cardiovascular homeostasis [86]. According to our own preliminary research results (unpublished data), the cortisol levels increased from a baseline in the postoperative days after colic surgery, but more remarkably in POI group horses.

It seems that upon inflammation, there are numerous neurotransmitters that are mediated through surgical and postoperative stress, which caused disturbances in the motility of the gastrointestinal tract [92]. In an experimental model in ponies, using jejunal trauma through sympathetic reflexes and inflammation, electrical activity was decreased and the normal synchrony of gastric and duodenal MMCs was disrupted [8]. Intestinal manipulation of the small intestine in rodents impairs intestinal transit, through an inhibitory adrenergic pathway, because its sympathetic blockade is not always successful in reversing the inhibition of gastrointestinal motility induced by abdominal surgical procedures [93, 94]. In addition to sympathetic reflexes, surgical manipulation of the intestines activates inhibitory non-adrenergic, non-cholinergic (NANC) neurons in the gastrointestinal tract, resulting in the release primarily of NO and VIP, the consequences of which result in decreased gastrointestinal motility [93, 95, 96]. Substance P, which is a neurotransmitter involved in pain, has also been hypothesized to have a role in postoperative ileus [85]. In a model of POI in rats, where mechanical trauma to the small intestine and cecum was used, reserpine (which depletes catecholamine stores) and L-nitroarginine (a nitric-oxide synthase inhibitor) completely reversed the inhibition of ingesta transit. This finding supported the involvement of adrenergic and nitrergic neurons in the pathogenesis of POI [93]. As blockade of the calcitonin-receptor-related peptide resulted in a similar effect, this peptide may be one of the neurotransmitters released by these afferent fibers and partly mediate postoperative ileus [97]. Additionally, endogenous opioids are also released after surgery and contribute toward postoperative ileus [92].

Other changes also occur following surgery stress, notably an increase in cytokine production. In human patients after surgery, cytokines IL-1, TNF- α and IL-6 may augment pituitary ACTH secretion and subsequently increase the release of cortisol.

A negative feedback system partially exists; therefore, glucocorticoids inhibit cytokine production and inflammation [98].

Most studies concentrate on central mechanisms whereby a stressful event perceived by the brain triggers neuronal and hormonal reflexes that influence the gastrointestinal motility. According to one study, the intestine produces the same stress peptides that are present in the central nervous system [99]. A local stressor, in this case endotoxins, results in the local generation and action of stress peptides that mediate inflammation without involving the central nervous system. In other words, the peripheral stressors induce local release of CRF possibly from enteric neurons and immune cells [88]. Peripherally derived CRF may act on the enteric nervous system and mast cells to induce inflammation and control motility and secretion [89].

4.3 The role of drugs and anesthetic agents

The pharmacological mechanisms of postoperative ileus are well described in the literature. Xylazine and detomidine are $\alpha 2$ -adrenergic agonists and are commonly used in horses for sedation and pain control. Activation of presynaptic $\alpha 2$ -adrenergic receptors within the enteric nervous system inhibits ACh release from cholinergic neurons, thereby suppressing intestinal contractions in normal ponies, primarily of the distal jejunum, pelvic flexure, cecum, and right ventral colon [100–102]. Although the use of $\alpha 2$ -agonists has been reported to suppress intestinal motility, no direct significant associations have been made between POI and sedation or type of sedative used.

Anesthesia gases do have an effect on intestinal motility, and the longer anesthesia lasts, the greater the actions [85]. Based on our observations during 1997–2000, the incidence of POI was greater than after the year 2000. One of the reasons for this was that the active use of halothane was stopped, and we began to use isoflurane as an anesthetic gas. Other studies have also shown that anesthetic drugs such as halothane and atropine tend to decrease gastric emptying and inhibit intestinal motility, with the greatest effect on the colon and cecum and they can initiate cecal impaction in horses [103–105]. Interestingly, the cecal impaction occurs more commonly after orthopedic procedures [106]. Therefore, general anesthesia herein appears to be a less likely primary cause of cecal and small intestine motility dysfunction [104, 107]. Possibly, persistent pain after orthopedic procedures, resulting in sympathetic overstimulation, is a significant contributing factor.

5. Diagnosis of equine postoperative ileus

Large intestinal dysmotility is commonly recognized following a delay in defecation and also by rectal and/or ultrasonographic examination. There are different criteria for the diagnosis of equine small intestine POI in the literature [15–17, 108, 109]. Based on our previous experience and regardless of the rare cases of exclusion, the main criteria for diagnosis of POI of small intestine are as follows:

1. Postoperative period during 1–7 days after abdominal surgery. Most cases of POI occur within 12–48 h after recovery from anesthesia.
2. Postoperative reflux of ≥ 2 l upon any given intubation, or > 2 l/h on repeated intubation, of gastric contents with pH ≥ 6.0 . Another study defined cases of postoperative ileus as horses with > 20 l during a 24-h period, or > 8 l during any single refluxing event [110]. Merrit and Blikslager [111] suggested the adoption

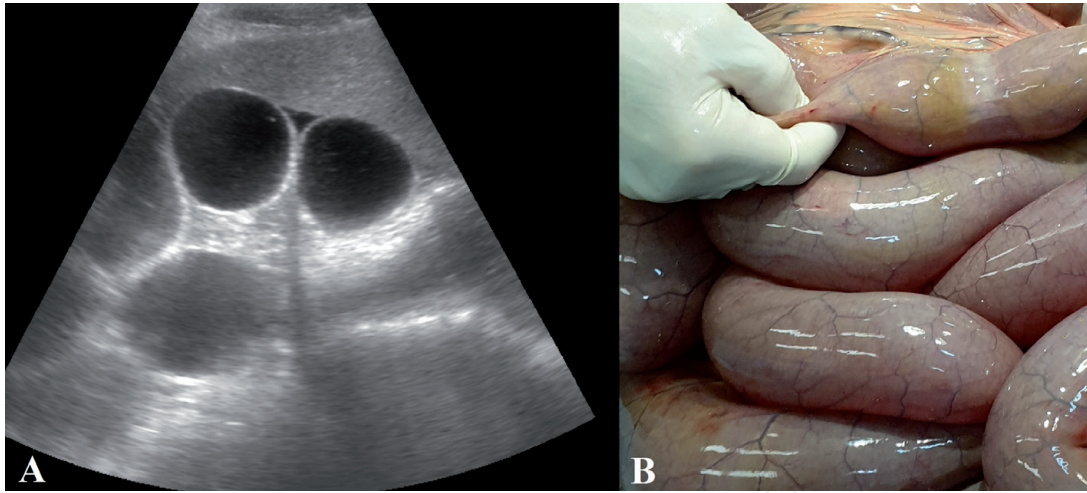


Figure 2.

(A) Transcutaneous ultrasonogram in a horse with POI before surgery in region 3 l with evidence of multiple fluid-distended small intestinal bowel loops [113]. (B) Jejunojejunal distension identified during repeat celiotomy in the same horse.

of a consensus on the classification of clinical criteria for POI, which included ≥ 4 l on any given intubation or > 2 l/h on repeated intubation. In most of our cases of POI, an average of 8–12 l, if intubation is performed every 4–5 h (i.e., approximately 2 l/h of fluid accumulate in the stomach). If more reflux is noticed, other pathologies are possible (e.g., mechanical obstructions and anastomotic leaks).

3. Moderate abdominal discomfort, which intensifies every 4–5 h after the last intubation. The response to nasogastric decompression provides an important clue that the problem is functional (i.e., POI). If a high degree of pain is noticed and continues, other gastrointestinal pathologies are possible.
4. Heart frequency 40–65 beats/min, if intubation is performed every 4–5 h.
5. Hematocrit 0.40–0.50 l/l, if standard infusion therapy is performed. If a high hematocrit is noticed, other gastrointestinal pathologies are possible.
6. Evidence of multiple fluid-distended small intestinal loops on rectal examination.
7. Ultrasonographic evidence of multiple fluid-distended small intestinal bowel loops (≥ 3 cm), edema and lack of motility in different parts of the equine abdomen (**Figure 2**) [112–114].
8. Borborygmi are usually decreased, especially the absence the ileocecal noise dorsally behind the right costal arch [48, 115].

6. Prevention and treatment of equine postoperative ileus

Since the treatment of this condition is very complex, and the complications are often fatal, the prevention strategy of POI is a very important way to improve the survival rate of horses that have undergone abdominal surgery [34, 109]. There are many methods and procedures and prophylactic and therapeutic choices for equine POI, depending on each individual case. The preventive strategies come from better

understanding the pathogenesis of this condition and treatment of POI must first address the underlying cause(s). The prophylactic and treatment strategies of the equine POI we are currently proposing are a multimodal regimen, which can be divided into three phases pre-, intra- and postoperative. The proposed multimodal treatment approach should include limiting factors, which are known to contribute to postoperative ileus. Each phase has the same significance in survival rate of equine POI.

6.1 Preoperative strategies in the prevention of equine POI

The long onset of colic disease producing high degree of endotoxic shock, in accordance with our earlier findings [32], are strongly associated with an increased risk for POI development. In this regard, it is appropriate to again highlight the importance of timely referral and prompt surgical intervention in surgical (strangulation) colic cases for the prevention of POI. Additionally, time from onset of colic to surgery has a decisive role not only in prophylactic but also in terms of a successful treatment by occurrence of equine POI. Failure to refer promptly leads to not only POI but also the occurrence of other perioperative complications by abdominal surgery in the horse. Approximately, every hour of tardiness with surgical interventions in a horse with strangulation ileus (for instance, by small intestine or large colon volvulus) reduces the survival rate from 5 to 10%, due to the rapid development of endotoxic shock [4, 116]. We found a significant correlation between the occurrence and survival of POI with colic duration in horses with inguinal hernia ($r = 0.72$) and epiploic foramen entrapment ($r = 0.78$), and partially (not significant) due to ileum obstruction ($r = 0.41$) [40, 41, 45]. According to our recent study in 33 horses with entrapment in the epiploic foramen, surgery performed within 6 h from onset of colic had a survival rate of 87%, compared with 25% survival with surgery 10 h or more after onset [40].

It is important even before the onset of surgery to prepare, applying medicaments that reduce endotoxin release and alleviate inflammation effect, for instance, the application of NSAIDs (flunixin meglumine), corticosteroids (prednisolone) and antibiotics. Administration of corticosteroid drugs to critically ill surgical colic horses results in a significant reduction of shock symptoms. The use of these drugs should certainly continue in the postoperative period [26]. Antimicrobials should be administered intravenously, ideally within 30–60 min before the first surgical incision. For horses undergoing abdominal surgery in the perioperative period, we introduced the following antibiotics: cobactan[®] 2.5% (cefquinome) (IM 3 mg/kg BW) for 5 d; gentamicin (6.6 mg/kg BW, IV, q24h) and metronidazole (20 mg/kg BW IV, four times daily) for 3 days. Additionally, if time permits, during urgent transport to the equine clinic, horses should have a balanced polyionic intravenous fluid applied in order to reduce hemoconcentration. It is advisable that before abdominal surgery horses should have a hematocrit level of below 0.45 l/l. In cases of metabolic acidosis, 5% sodium bicarbonate solution should also be administered. We used pre- and intraoperative the hypertonic saline (NaCl 8.0%) only in horses with severe endotoxic shock and if in doubt on the presence of intestinal edema [40].

6.2 Intraoperative strategies in the prevention of equine POI

Surgical procedures and anesthesia affect the development of POI in horses (as discussed above). Operative management should be aimed at reducing duration of surgery and anesthesia in addition to other preventative strategies. In this aspect, an important role is played by a high-performing multidisciplinary surgical team with experience and knowledge as this optimizes surgical procedures. During the

abdominal surgery, the least traumatic surgical methods should be selected and performed and these should be carried out as efficiently and therefore quickly as possible. The degree of inhibition of circular muscle contractility is related directly to the magnitude of leukocyte and macrophage infiltration, which in turn depends on the intensity of intestinal manipulation; therefore, every effort should be made to reduce intestinal trauma. One surgical method able to reduce surgery time is the use of the stapled technique for jejunal resections [117]. As already described above, other postoperative complications in horses undergoing abdominal surgeries have an impact in developing POI, notably by postanesthetic myopathy [118, 119]. Therefore, special attention must be paid to optimizing blood pressure during abdominal surgery. For these purposes, anesthesia monitoring should be carried out at all the time, and if a decrease in blood pressure (defined as mean arterial pressure <70 mmHg) is observed, a dobutamine injection should be administered [42, 46]. In cases of severe anesthetic hypoxia ($PO_2 < 70$ mmHg), one ought to have the issue resolved in a timely manner with intermittent positive pressure ventilation (IPPV) with constant positive end-expiratory pressure.

Several methods have recently been developed to decrease the rate of other surgical complications [35, 117]. The methods of minimizing postoperative adhesions are the application of meticulous atraumatic surgical technique, use of a bioresorbable hyaluronate-carboxymethylcellulose membrane [118, 120], administration of heparin [40], omentectomy [121] and performing intraoperative peritoneal lavage [39]. In the case of strangulating obstruction of the small intestine, the bowel to be resected and discarded should be placed over the edge of the surgical field while removing the contents of the small intestine. Performing a pelvic flexure enterotomy may also reduce POI risk [110], which has also been confirmed during our observations [45]. The protective influence of these procedures may be attributable to a reduction in the intraluminal source of endotoxin, but the potential value of evacuating the colon should be weighed against the increased anesthesia time required to perform the surgery, as both factors have been associated with an increased risk of POI [106].

6.3 Postoperative strategies in the prevention and therapy of equine POI

Postoperative strategies in the prevention and treatment of equine POI are numerous and dependent on each individual case [26]. This can be divided into standard supportive postoperative procedures and procedure by risk for the patient. Under standard management, the following should be considered: regular basic clinical measurements (every 4–5 h) including heart and respiration frequency, temperature, auscultation of bowel sound, and of laboratory parameters including hematocrit, total plasma protein and acid-base state of the blood. In the standard postoperative procedures, several checks should be undertaken. We used at least 3 days administration of balanced polyionic intravenous fluid. The amount and length of time of the infusion solution are dependent on blood parameters; on average, we applied 2.5–3 l/h/500 kg BW. Dehydration and electrolyte imbalances are commonly encountered as a result of abdominal disorders and surgery. Even though a horse is stabilized in the perioperative period and the primary problem is corrected, continued replacement of previous and ongoing fluid losses is critical for a successful outcome. If a horse has gastric reflux, the use of the infusion solution should be continued throughout this condition. Given that the introduction of a large number of solutions provokes the development of thrombophlebitis of the jugular veins, it is recommended that a central catheter is installed through the abdominal vein.

In all horses without and with POI after abdominal surgery, NSAIDs should be administered such as flunixin meglumine (1.1 mg/kg BW, IV, q12h initially for

2 days, then 0.55 mg/kg BW, IV, q12h for at least 2 days). Flunixin meglumine controls postoperative pain and improves the cardiovascular manifestations of endotoxemia. Additionally, flunixin meglumine has been shown to significantly attenuate the disruption of gastric, small intestine, and large colon motility elicited by endotoxin infusion [49]. Additional treatments include anti-oxidant medications, which prevent the generation of chemoattractants: DMSO (20 mg/kg BW in 1 l saline IV bolus, q12h) and sodium heparin (20,000 IU, SQ, q12h). In all postoperative horses without gastric reflux, we applied obligatory laxatives (2 l liquid paraffin, p.o.) after abdominal surgery. For the prevention of incisional infection, horses received abdominal bandages during hospitalization. The bandages consisted of sterile absorbent cotton padding next to the incision secured by elastic adhesive tape.

6.4 Postoperative peritoneal lavage

Postoperative peritoneal lavage has been used in an attempt to reduce the rate of postoperative adhesions [119], but this procedure decreases occurrence and increases survival rates of equine POI [39]. Thus, in horses with a high risk of POI and who additionally showed symptoms of peritonitis, we performed retrograde peritoneal lavage through a Foley catheter, which was installed into the abdominal cavity prior to closure of the abdominal incision. For abdomen lavage, we used sterile physiologic saline or Ringer's lactate solution (10–15 l) containing amoxicillin (5 g) and 20,000 units of sodium heparin.

6.5 Prokinetic drugs for the treatment of equine postoperative ileus

The use of prokinetics in horses with POI is only part of the treatment and is not defined as a unique technique toward the survival rate of this disease, only working in combination with other methods [5]. The effectiveness of some prokinetic drugs in horses is associated with the difficulties of conducting a well-designed, randomized clinical trial with homogenous groups of animals [38]. None of the intestinal prokinetic agents have been subject to rigorous clinical efficacy trials [122]. This statement is supported by the fact that the contractile response of intestinal smooth muscle to prokinetic drugs is significantly impaired in many horses with POI. Prokinetic motility drugs are also commonly used following abdominal surgery in humans to prevent ileus, although a Cochrane review examined 39 randomized controlled trials and found most medications to be of little or no benefit [6, 7]. There are numerous prokinetics drugs that can be used by POI in the horse, which have differing mechanisms of action and different efficiency rates [26].

6.5.1 Parasympathomimetic agents (cholinomimetics)

Parasympathomimetic agents (cholinomimetics) are drugs that mimic the effects of the parasympathetic nervous system activity. Directly acting parasympathomimetic agents, bethanechol chloride, improve myoelectric activity in the stomach, jejunum, ileum, and large and small colons of horses, but produce significant cholinergic side effects (increased salivation), and therefore are not used as a standard in equine praxis [71, 101]. In horses with POI, applications are mostly indirectly acting parasympathomimetic agents such as neostigmine methylsulfate. Neostigmine is a cholinesterase inhibitor that prolongs the activity of acetylcholine by retarding its breakdown at the synaptic junction [102, 123]. Neostigmine has been shown to delay gastric emptying and decrease jejunal myoelectric activity, but enhances myoelectric activity in the ileum, cecum, right ventral colon and

pelvic flexure activity in healthy ponies [71, 122]. These results suggest that the drug would not be appropriate for gastric and small intestinal problems but may be beneficial for large intestinal motility dysfunction. However, neostigmine increased the amplitude of rhythmic contractions in both the resting and distended jejunum in anesthetized ponies, and it induced contractile activity in the ileum, supporting its use for motility dysfunction in both the small and large intestine [26, 29, 124]. Based on our clinical impressions, neostigmine if used as monotherapy repeated at 60 min intervals (during 24–48 h) has significant beneficial effects in the treatment of colitis cases, but not in POI of the small intestine [43].

6.5.2 Sodium channel blockers

Sodium channel blockers—lidocaine is currently a prokinetic agent, which is most frequently used for the treatment of POI in equine practice, although scientific evidence on its prokinetic and analgesic effectiveness is limited [33, 124–128]. Lidocaine has antinociceptive, antihyperalgesic, and anti-inflammatory effects [6, 7]. In an investigation within a UK hospital population, lidocaine therapy had no effect on the prevalence of postoperative reflux, total reflux volume or duration of reflux and as well as no effect on postoperative survival in horses undergoing abdominal surgery [129]. According to our observations, lidocaine if used as monotherapy has little positive effect on the treatment of equine POI and is significantly inferior to a combination of prokinetic drugs [32].

6.5.3 Drugs acting as 5-hydroxytryptamine receptors

Drugs acting as 5-hydroxytryptamine receptors include metoclopramide, cisapride, mosapride citrate and tegaserod [36, 130–132]. Metoclopramide hydrochloride (MCP) is a first-generation substituted benzamide whose prokinetic activity is both through dopamine 1 (DA1) and 2 (DA2) receptor antagonism and through 5-HT 4-receptor (5-HT4) agonism and 5-HT3 receptor antagonism [11]. Stimulation of DA2 receptors inhibits the release of acetylcholine, and stimulation of 5-HT4 receptors enhances the release of acetylcholine from the myenteric ganglia. MCP is a drug, which for a long time has often been used in the prevention and treatment of equine POI, but results in published studies have been variable [5, 8, 21, 130]. The prokinetic capacity of metoclopramide appears substantial in the equine stomach, duodenum and jejunum, but not in the large intestine [128, 133].

6.5.4 Motilin agonists

Motilin agonists include erythromycin lactobionate, and a macrolide antibiotic has been shown to significantly increase solid phase gastric and dose-dependent caecal emptying and is thought to exert prokinetic effects via activation of motilin receptors [20, 21, 36]. The prokinetic effects of erythromycin reported in healthy horses were not the same in horses with gastrointestinal disease [110, 122, 128].

6.5.5 Adrenergic antagonists

Adrenergic antagonists include acepromazine maleate, a nonselective α -adrenergic antagonist, and yohimbine, tolazamide, and atipamezole, which are selective α 2-adrenergic antagonists. Their use as prokinetics is based on the assumption that sympathetic hyperactivity contributes to POI, but their beneficial effects are not well understood [6, 7].

6.5.6 Dopamine antagonist

Dopamine antagonist—domperidone is a selective peripheral DA₂ receptor antagonist [26]. In a preliminary experimental model of POI in ponies, domperidone was effective in restoring transit time, electromechanical activity, and coordination of gastric and intestinal cycles [134].

6.5.7 Combination of prokinetic drugs

Combination of prokinetic drugs—based on our research, the best medicinal method for prevention and treatment of equine POI is a combination of three drugs, according to the needs of the individual scheme of each case [5, 14, 32]:

1. Neostigmine methylsulfate (in a dose of 0.004 mg/kg per 2 h, i.e., 2 mg per 500 kg BW, subcutaneously)
2. Metoclopramide (in a dose of 0.01–0.02 mg/kg per 2 h, i.e., 5–10 mg per 500 kg BW, subcutaneously or intravenously)
3. Domperidone (in a dose of 0.16 mg/kg orally, every 8 h)

We found that the prophylactic perioperative use of these drugs in risk horses to reduce the incidence of POI, and by occurrence of ileus significantly improved survival rate [5, 14, 32]. These prokinetic drugs should not be applied at the same time (little benefit), but strictly in turn. Why these drugs benefit only in turn in combination and not at the same time is unknown. Neostigmine methylsulfate and metoclopramide were applied alternatively between each other in 60 min intervals, so that every horse received each of the drugs every second hour (i.e., 1 h neostigmine methylsulfate was administered and in the second hour metoclopramide was given). We used this therapeutic regimen for POI horses continuously for several days until a result was obtained (complete absence of gastric reflux), and usually, this happened within 24–90 h. The withdrawal of these drugs should take place gradually throughout a few days. On average, this occurred 5–6 days after the onset of equine POI. If sharp withdrawal of these prokinetics is undertaken, a relapse of gastric reflux is possible.

6.6 Nasogastric decompression

Nasogastric decompression is a classic supportive treatment that prevents gastric dilation in horses with POI. We performed this procedure in horses that showed gastric reflux, it was applied regularly every 4–6 h, and most horses begin to show clinical signs (colic) associated with excessive fluid accumulation in the stomach. Retaining an indwelling tube for 12–15 h in horses with POI was performed only in cases where animals showed extensive stress syndrome by intubation.

6.7 Judicious timing of feeding

Horses without gastric reflux were allowed access to water within 12–18 h after abdominal surgery and were provided with small amounts of feed at 18–30 h after surgery. Initially, small amounts of grass hay or small amounts of bran mash with 100 ml laxatives were fed every 3–4 h. The quantities were gradually increased daily until the horses were allowed to freely eat hay by choice (usually by 21 days after surgery).

Freeman and coworkers were able to show that of the horses taken to surgery for small intestinal disease, only 10% developed postoperative ileus [17]. According to the authors, one key management factor in prophylactic procedures of POI was early re-feeding, where horses were offered water and small amounts of hay within 18–24 h of the completion of surgery for small intestinal disease. Early feeding following abdominal surgery is a commonly applied prophylactic approach in human medicine, as well. It is hypothesized to promote restoration of gastrointestinal motility via the release of neuropeptides in response to solid feed ingestion. In humans, it is known that chewing gum is a type of sham feeding that promotes intestinal motility through cephalic-vagal stimulation [6, 7, 135].

According to our opinion, the judicious timing of feeding in horses with POI is when no signs of reflux are apparent or when motility is regained. Horses with evidence of gastric reflux are unlikely to tolerate enteral feeding and should receive intravenous nutritional support (i.e., glucose solutions and amino acids). In addition to the intravenous administration of glucose solutions, it is necessary to use insulin subcutaneously at a dose of 0.08 U/kg every 12 h in order to block the lipase enzyme responsible for releasing triglycerides from fat depots. As is well known, if the fasting regime lasts more than 3 days, this may provoke development of a severe form of equine hyperlipidemia, notable in obese horses. Hyperlipidemia is associated with periods of negative energy balance and physiologic stress [136]. For this reason, in horses with POI at 48 h after abdominal surgery, regardless of the presence of gastric reflux, we allowed the horses, after nasogastric decompression, to be fed with a small amount of bran mash with ranitidine oral tablets (H_2 -antihistamine). Additionally, for horses with gastric reflux for which the provision of enteral nutrition is not possible, the provision of a lick (e.g., mineral block) has been suggested as a form of sham feeding, equivalent to gum chewing in humans.

6.8 Stress reduction strategies

Suppression of parasympathetic activity and hyperactivity of the sympathetic nervous system with activation of the hypothalamic-pituitary-adrenal axis (stress syndrome) has a very important role in the development of equine POI (as discussed above). Causes of equine stress syndrome in perioperative period can be varied, primarily pain and inflammation, but also recovery from anesthesia, postoperative diagnostic and management procedures and fasting, as well as different psychological (fear) factors. It is generally considered or hypothesized that a more invasive surgery, with extensive tissue trauma and noxious stimuli, triggers a more significant stress response. After surgery, the horse is placed in an unfamiliar environment with unknown caretakers and probably starved while having additional pain to deal with. Postoperative pain can originate from peritoneal inflammation and abdominal incision. Consequently, it is important on all occasions to consider minimizing sympathetic activity, primarily pain and inflammation control of the horses after abdominal surgery. As is well known, anti-inflammatory drugs lead to lower pain scores and lower plasma cortisol levels [82, 91]. This amount of stress modulates the pain perception and adds further to the perceived pain. This in turn increases appetite, so the horse does not enter a catabolic state in order to produce substrates for healing.

Given all of the stress, it is therefore also extremely important to take care of the horse psychologically. All therapeutic procedures in postoperative period should be performed with minimal stress. Stress-enhancing procedures may include introduction of a nasogastric tube into the stomach, which causes discomfort and the release of catecholamine, and this process is necessarily carried out with the imposition of

a twitch and without sedation. It is believed that a twitch calms the horse by releasing endorphins as pressure is applied, thus reducing stress and pain. Administration of corticosteroid drugs results in the reduction of stress syndrome, but non-pharmacologic mechanisms for reducing the stress response are quite successful, for instance, regular visits from the owner or a familiar caretaker, frequent contact and grooming preferably by the same handler or veterinarian, short periods of hand-walking, treats given from time to time, short periods of grazing (1–2 min around 24–48 h after abdominal surgery) and minimal enteral nutrition. As described above, early re-feeding has been attributed to possible downregulation of the metabolic stress response [35]. Additionally, all other external stress factors for horses (including transport, loud noises, bright light and rudeness of medical staff), as far as possible, should be abolished during the postoperative period in an equine clinic, both in horses with a risk of development and also in horses that already have a POI.

6.9 Repeat celiotomy and postoperative ileus

Relaparotomy (repeat celiotomy) is widely accepted as a treatment option in the management of postoperative colic and ileus [6, 7]. A repeated surgical intervention in the abdominal cavity may correct technical errors that occurred during the first surgery and solve conservatively unsolvable motility disorders as well as pathological conditions that occur in the post-surgical period without a clear relation to the first intervention [1]. Previously, authors considered that intestinal manipulation (massage) and repeated enterotomy likely have beneficial effects to equine POI [103]. However, the potential benefit of limiting the degree of intestinal manipulation in equine surgery must be weighed against the increased risk of other postoperative complications (postanesthetic myopathy, wound infection and hernia). According to our observation, repeat celiotomy did not increase survival rate in horses with POI; for example, surgical cases had a lower survival rate than medically managed cases of POI [32].

Acknowledgements

Albert A. Rizvanov was supported by the Russian Government Program of Competitive Growth of Kazan Federal University and funded by state assignments 20.5175.2017/6.7 and 17.9783.2017/8.9 of the Ministry of Science and Higher Education of Russian Federation.

Conflicts of interest

The authors declare no conflicts of interest.

Dedication

This chapter is dedicated to Prof. Dr. Dr. H.C. Bernhard Huskamp (1932–2018) the founder of the Veterinary clinic Hochmoor in recognition of his extensive contributions to equine colic surgery.

IntechOpen

Author details

Milomir Kovac^{1*}, Ruslan Aliev¹, Sergey Pozyabin¹, Nevena Drakul¹
and Albert Rizvanov²

¹ Veterinary Clinic “New Century”, Moscow State Academy of Veterinary Medicine
and Biotechnology, Moscow, Russia

² Institute of Fundamental Medicine and Biology, Kazan Federal University,
Kazan, Russia

*Address all correspondence to: kovacmilomir@gmail.com

IntechOpen

© 2020 The Author(s). Licensee IntechOpen. This chapter is distributed under the terms
of the Creative Commons Attribution License ([http://creativecommons.org/licenses/
by/3.0](http://creativecommons.org/licenses/by/3.0)), which permits unrestricted use, distribution, and reproduction in any medium,
provided the original work is properly cited. 

References

- [1] Mair TS, Smith LJ, Sherlock CE. Evidence-based gastrointestinal surgery in horses. *Veterinary Clinics of North America: Equine Practice*. 2007;**23**(2):267. DOI: 10.1016/j.cveq.2007.03.005
- [2] Dukti S, White NA. Prognosticating equine colic. *Veterinary Clinics of North America: Equine Practice*. 2009;**25**(2):217. DOI: 10.1016/j.cveq.2009.04.004
- [3] French NP, Smith J, Edwards GB, Proudman CJ. Equine surgical colic: Risk factors for postoperative complications. *Equine Veterinary Journal*. 2002;**34**(5):444-449. DOI: 10.2746/042516402776117791
- [4] Kovac M. *Colic Horse: Cause, Diagnosis, Treatment*. Moscow, Russia: KID; 2010
- [5] Aliev R, Pozabin SV. Treatment method for horses with postoperative paralytic ileus. *Journal Veterinaria I Kormlenie*. 2019;**2**:28-30. DOI: 10.30917/ATT-VK-1814-9588-2019-2-10
- [6] Siciliano S. *Paralytischer Ileus und Reperfusionstörung beim Pferd. Literaturübersicht und retrospektive Fallanalyse*. Berlin: Freie University; 2008
- [7] Traut U, Brugger L, Kunz R, Pauli-Magnus C, Haug K, Bucher HC, et al. Systemic prokinetic pharmacologic treatment for postoperative adynamic ileus following abdominal surgery in adults. *Cochrane Database of Systematic Reviews*. 2009;(4):1-85. DOI: 10.1002/14651858.CD004930.pub3
- [8] Gerring EEL, Hunt JM. Pathophysiology of equine postoperative ileus—Effect of adrenergic-blockade, parasympathetic stimulation and metoclopramide in an experimental-model. *Equine Veterinary Journal*. 1986;**18**(4):249-255. DOI: 10.1111/j.2042-3306.1986.tb03618.x
- [9] Kovac M, Aliev R, Tigina O, Ivanatov E. Equine large colon volvulus. Diagnosis and treatment. *Vet Pharmaceuticals*. 2015;**3**:84-86
- [10] Jain D. Neuromuscular disorders of the GI tract. In: Odze RO, Goldblum JR, editors. *Surgical Pathology of the GI Tract, Liver, Biliary Tract, and Pancreas*. 2nd ed. USA: Elsevier; 2009. pp. 125-143
- [11] Gannon RH. Current strategies for preventing or ameliorating postoperative ileus: A multimodal approach. *American Journal of Health-System Pharmacy*. 2007;**64**:S8-S12. DOI: 10.2146/ajhp070429
- [12] Bauer AJ, Schwarz NT, Moore BA, Turler A, Kalff JC. Ileus in critical illness: Mechanisms and management. *Current Opinion in Critical Care*. 2002;**8**(2):152-157. DOI: 10.1097/00075198-200204000-00011
- [13] Kehlet H, Holte K. Review of postoperative ileus. *American Journal of Surgery*. 2001;**182**(5a):3s-10s. DOI: 10.1016/S0002-9610(01)00781-4
- [14] Kovac M, Aliev R, Elizarova O, Ivanyatov E. Etiology, diagnosis and treatment of equine paralytic ileus. *Vet Pharmaceuticals*. 2015;**4**:26-28
- [15] Blikslager AT, Bowman KF, Levine JF, Bristol DG, Roberts MC. Evaluation of factors associated with postoperative ileus in horses: 31 cases (1990-1992). *Journal of the American Veterinary Medical Association*. 1994;**205**(12):1748-1752
- [16] Freeman DE, Hammock P, Baker GJ, Goetz T, Foreman JH, Schaeffer DJ, et al. Short- and long-term survival and prevalence of postoperative ileus after small intestinal surgery in the horse.

Equine Veterinary Journal. Supplement. 2000;(32):42-51. DOI: 10.1111/j.2042-3306.2000.tb05333.x

[17] Freeman DE. Post operative ileus (POI): Another perspective. Equine Veterinary Journal. 2008;**40**(4):297-298. DOI: 10.2746/042516408X302528

[18] Hunt JM, Edwards GB, Clarke KW. Incidence, diagnosis and treatment of postoperative complications in colic cases. Equine Veterinary Journal. 1986;**18**(4):264-270. DOI: 10.1111/j.2042-3306.1986.tb03623.x

[19] Morton AJ, Blikslager AT. Surgical and postoperative factors influencing short-term survival of horses following small intestinal resection: 92 cases (1994-2001). Equine Veterinary Journal. 2002;**34**(5):450-454. DOI: 10.2746/042516402776117700

[20] Doherty TJ. Postoperative ileus: Pathogenesis and treatment. The Veterinary Clinics of North America. Equine Practice. 2009;**25**(2):351-362. DOI: 10.1016/j.cveq.2009.04.011

[21] Koenig J, Cote N. Equine gastrointestinal motility—Ileus and pharmacological modification. Canadian Veterinary Journal—Revue Veterinaire Canadienne. 2006;**47**(6):551-559

[22] Pedziwiatr M, Mavrikis J, Witowski J, Adamos A, Major P, Nowakowski M, et al. Current status of enhanced recovery after surgery (ERAS) protocol in gastrointestinal surgery. Medical Oncology. 2018;**35**(6):1-8. DOI: 10.1007/s12032-018-1153-0

[23] Fintl C, Hudson NPH, Mayhew G, Edwardst GB, Proudman CJ, Pearson GT. Interstitial cells of Cajal (ICC) in equine colic: An immunohistochemical study of horses with obstructive disorders of the small and large intestines. Equine Veterinary Journal. 2004;**36**(6):474-479. DOI: 10.2746/0425164044877314

[24] Lomax AE, Sharkey KA, Furness JB. The participation of the sympathetic innervation of the gastrointestinal tract in disease states. Neurogastroenterology and Motility. 2010;**22**(1):7-18. DOI: 10.1111/j.1365-2982.2009.01381.x

[25] Antonioli L, Fornai M, Colucci R, Ghisu N, Tuccori M, Del Tacca M, et al. Regulation of enteric functions by adenosine: pathophysiological and pharmacological implications. Pharmacology & Therapeutics. 2008;**120**(3):233-253. DOI: 10.1016/j.pharmthera.2008.08.010

[26] Damen S. A Review on Prokinetics, Splasmolytics and Their Receptors. Belgium: Faculty of Veterinary Medicine, Ghent University; 2016

[27] Rakestraw PC. Intestinal motility and transit. In: White NA, Moore JN, Mair TS, editors. The Equine Acute Abdomen. Jackson, USA: Teton New Media; 2008. pp. 67-91

[28] Schwarz NT, Simmons RL. Minor intraabdominal injury followed by low dose LPS administration act synergistically to induce ileus. Neurogastroenterology and Motility. 2000;**11**(2):288

[29] Wong DM, Davis JL, White NA. Motility of the equine gastrointestinal tract: Physiology and pharmacotherapy. Equine Veterinary Education. 2011;**23**(2):88-100. DOI: 10.1111/j.2042-3292.2010.00173.x

[30] Mcconalogue K, Furness JB. Gastrointestinal neurotransmitters. Baillière's Clinical Endocrinology and Metabolism. 1994;**8**(1):51-76. DOI: 10.1016/S0950-351x(05)80226-5

[31] Cohen ND, Lester GD, Sanchez LC, Merritt AM, Roussel AJ Jr. Evaluation of risk factors associated with development of postoperative ileus in horses. Journal of the American Veterinary Medical Association. 2004;**225**(7):1070-1078. DOI: 10.2460/javma.2004.225.1070

- [32] Kovac M, Huskamp B, Toth J, editors. Prevalence, risk and therapy of postoperative ileus after intestinal surgery in the horse. In: 10th Congress of the World Equine Veterinary Association. Moscow: World Equine Veterinary Association; 2008
- [33] Torfs S, Delesalle C, Dewulf J, Devisscher L, Deprez P. Risk factors for equine postoperative ileus and effectiveness of prophylactic lidocaine. *Journal of Veterinary Internal Medicine*. 2009;**23**(3):606-611. DOI: 10.1111/j.1939-1676.2009.0311.x
- [34] Burke M, Blikslager A. Advances in diagnostics and treatments in horses with acute colic and postoperative ileus. *The Veterinary Clinics of North America. Equine Practice*. 2018;**34**(1):81-96. DOI: 10.1016/j.cveq.2017.11.006
- [35] Freeman DE. Fifty years of colic surgery. *Equine Veterinary Journal*. 2018;**50**(4):423-435. DOI: 10.1111/evj.12817
- [36] Hudson NPH, Pirie RS. Equine post operative ileus: A review of current thinking on pathophysiology and management. *Equine Veterinary Education*. 2015;**27**(1):39-47. DOI: 10.1111/eve.12248
- [37] Lisowski ZM, Pirie RS, Blikslager AT, Lefebvre D, Hume DA, Hudson NPH. An update on equine post-operative ileus: Definitions, pathophysiology and management. *Equine Veterinary Journal*. 2018;**50**(3):292-303. DOI: 10.1111/evj.12801
- [38] Salem SE, Proudman CJ, Archer DC. Prevention of post operative complications following surgical treatment of equine colic: Current evidence. *Equine Veterinary Journal*. 2016;**48**(2):143-151. DOI: 10.1111/evj.12517
- [39] Kovac M, Toth J, Nowak M. Die postoperative Bauchhöhlenlavage bei kolikoperierten Pferden. In: Ein Beitrag zur Minimierung postoperative Komplikation XIX DVG Tagung Pferde Medicine. Hannover, Germany: DVG Tagung Pferde Medicine; 2006. p. 34
- [40] Kovac M, Aliev RU, Ivanatov EY, Novikova SB. Diagnosis and treatment equine small intestinal herniation through the epiploic foramen. *Journal Veterinariya*. 2018;**2**:40-47. Available from: <http://en.journalveterinariya.ru/contents-no12-2018>
- [41] Kovac M, Aliev RIJ, Drakul N. Ileal obstruction in horses. Modern approach to diagnosis and treatment *Vetpharma. Veterinářství*. 2019;**1**:26-31. Available from: <http://vetpharma.org/articles/140/7894/>
- [42] Kovac M, Huskamp NH, Tambur ZA. Arterial hypotension during induction of inhalation anesthesia of horses with hernia foraminis omentalis and ileum constipation. *Veterinarski Glasnik*. 1999;**53**(5-6):249-256
- [43] Kovac M, Huskamp B, Scheidemann W, Toth J, Tambur Z. Survival and evaluation of clinical and laboratory variables as prognostic indicators in horses hospitalized with acute diarrhea: 342 cases (1995-2015). *Acta Veterinaria (Beograd)*. 2017;**67**(3):356-365. DOI: 10.1515/acve-2017-0029
- [44] Underwood C, Southwood LL, McKeown LP, Knight D. Complications and survival associated with surgical compared with medical management of horses with duodenitis-proximal jejunitis. *Equine Veterinary Journal*. 2008;**40**(4):373-378. DOI: 10.2746/042516408X302492
- [45] Kovac M, Aliev R, Ippolitova T. Equine acquired inguinal herniation—diagnosis and treatment in 62 cases. *Veterinarski Glasnik*. 2018;**72**(1):22-34. DOI: 10.2298/VETGL171228006K

- [46] Kovac M, Scheidemann W. Zwischenfälle und Risiken während der Inhalationsnarkose bei Pferden. Untersuchung anhand 2339 operierter Pferde. *Tierärztliche Praxis*. 2002;**30**:46-50
- [47] Osain M. *Gastrointestinal Physiology/Development, Principles and Mechanisms of Regulation*. USA: Springer International Publishing AG, Nature; 2018
- [48] Kovac M, Aliev RIJ, Drakul N. Strangulation of the small intestine in horses. *Veterinářství*. 2019;**3**:56-60. Available from: <http://vetpharma.org/articles/140/8196/>
- [49] Clark ES, Moore JN. The effects of slow infusion of a low dosage of endotoxin in healthy horses. *Equine Veterinary Journal. Supplement*. 1989;**21**(S7):33-37. DOI: 10.1111/j.2042-3306.1989.tb05652.x
- [50] Kalff JC, Carlos TM, Schraut WH, Billiar TR, Simmons RL, Bauer AJ. Surgically induced leukocytic infiltrates within the rat intestinal muscularis mediate postoperative ileus. *Gastroenterology*. 1999;**117**(2):378-387. DOI: 10.1053/gast.1999.0029900378
- [51] Schwarz NT, Kalff JC, Turler A, Engel BM, Watkins SC, Billiar TR, et al. Prostanoid production via COX-2 as a causative mechanism of rodent postoperative ileus. *Gastroenterology*. 2001;**121**(6):1354-1371. DOI: 10.1053/gast.2001.29605
- [52] Schwarz NT, Beer-Stolz D, Simmons RL, Bauer AJ. Pathogenesis of paralytic ileus—Intestinal manipulation opens a transient pathway between the intestinal lumen and the leukocytic infiltrate of the jejunal muscularis. *Annals of Surgery*. 2002;**235**(1):31-40. DOI: 10.1097/00000658-200201000-00005
- [53] Arditi M, Zhou J, Dorio R, Rong GW, Goyert SM, Kim KS. Endotoxin-mediated endothelial cell injury and activation: Role of soluble CD14. *Infection and Immunity*. 1993;**61**(8):3149-3156
- [54] Chen J, Du L, Xiao YT, Cai W. Disruption of interstitial cells of Cajal networks after massive small bowel resection. *World Journal of Gastroenterology*. 2013;**19**(22):3415-3422. DOI: 10.3748/wjg.v19.i22.3415
- [55] Little D, Tomlinson JE, Blikslager AT. Post operative neutrophilic inflammation in equine small intestine after manipulation and ischaemia. *Equine Veterinary Journal*. 2005;**37**(4):329-335. DOI: 10.2746/0425164054529472
- [56] Rowe EL, White NA, Buechner-Maxwell V, Robertson JL, Ward DL. Detection of apoptotic cells in intestines from horses with and without gastrointestinal tract disease. *American Journal of Veterinary Research*. 2003;**64**(8):982-988. DOI: 10.2460/ajvr.2003.64.982
- [57] Bassotti G, Villanacci V, Antonelli E, Morelli A, Salerni B. Enteric glial cells: new players in gastrointestinal motility? *Laboratory Investigation*. 2007;**87**(7):628-632. DOI: 10.1038/labinvest.3700564
- [58] Malone ED, Kannan MS. Effects of intestinal ischemia on in vitro activity of adjacent jejunum in samples obtained from ponies. *American Journal of Veterinary Research*. 2001;**62**(12):1973-1978. DOI: 10.2460/ajvr.2001.62.1973
- [59] Hopster-Iversen C, Hopster K, Staszky C, Rohn K, Freeman D, Rotting AK. Influence of mechanical manipulations on the local inflammatory reaction in the equine colon. *Equine Veterinary Journal*. 2011;**43**:1-7. DOI: 10.1111/j.2042-3306.2011.00378.x
- [60] Kalff JC, Turler A, Schwarz NT, Schraut WH, Lee KKW, Tweardy DJ,

et al. Intra-abdominal activation of a local inflammatory response within the human muscularis externa during laparotomy. *Annals of Surgery*. 2003;**237**(3):301-315. DOI: 10.1097/00000658-200303000-00003

[61] Matthijs G, Peeters TL, Vantrappen G. The role of intracellular calcium stores in motilin induced contractions of the longitudinal muscle of the rabbit duodenum. *Naunyn-Schmiedeberg's Archives of Pharmacology*. 1989;**339**(3):332-339

[62] Collins SM, Hurst SM, Main C, Stanley E, Khan I, Blennerhassett P, et al. Effect of inflammation of enteric nerves. Cytokine-induced changes in neurotransmitter content and release. *Annals of the New York Academy of Sciences*. 1992;**664**:415-424. DOI: 10.1111/j.1749-6632.1992.tb39780.x

[63] Kadowaki M, Nagakura Y, Tokita K, Hanaoka K, Tomoi M. Adenosine A1 receptor blockade reverses experimental postoperative ileus in rat colon. *European Journal of Pharmacology*. 2003;**458**(1-2):197-200. DOI: 10.1016/s0014-2999(02)02766-8

[64] Stoffels B, Schmidt J, Nakao A, Nazir A, Chanthaphavong RS, Bauer AJ. Role of interleukin 10 in murine postoperative ileus. *Gut*. 2009;**58**(5):648-660. DOI: 10.1136/gut.2008.153288

[65] Eskandari MK, Kalff JC, Billiar TR, Lee KKW, Bauer AJ. Lipopolysaccharide activates the muscularis macrophage network and suppresses circular smooth muscle activity. *The American Journal of Physiology-Gastrointestinal and Liver Physiology*. 1997;**273**(3):G727-GG34

[66] Kalff JC, Schraut WH, Billiar TR, Simmons RL, Bauer AJ. Role of inducible nitric oxide synthase in postoperative intestinal smooth muscle dysfunction in rodents. *Gastroenterology*. 2000;**118**(2):316-327. DOI: 10.1016/S0016-5085(00)70214-9

[67] Hopster-Iversen CCS, Hopster K, Staszky C, Rohn K, Freeman DE, Rotting AK. Effects of experimental mechanical manipulations on local inflammation in the jejunum of horses. *American Journal of Veterinary Research*. 2014;**75**(4):385-391. DOI: 10.2460/ajvr.75.4.385

[68] King JN, Gerring EL. Antagonism of endotoxin-induced disruption of equine gastrointestinal motility with the platelet-activating-factor antagonist web-2086. *Journal of Veterinary Pharmacology and Therapeutics*. 1990;**13**(4):333-339. DOI: 10.1111/j.1365-2885.1990.tb00786.x

[69] Morris DD. Endotoxemia in horses. A review of cellular and humoral mediators involved in its pathogenesis. *Journal of Veterinary Internal Medicine*. 1991;**5**(3):167-181. DOI: 10.1111/j.1939-1676.1991.tb00944.x

[70] King JN, Gerring EL. The action of low-dose endotoxin on equine bowel motility. *Equine Veterinary Journal*. 1991;**23**(1):11-17. DOI: 10.1111/j.2042-3306.1991.tb02705.x

[71] Steiner A, Roussel AJ. Drugs coordinating and restoring gastrointestinal motility and their effect on selected hypodynamic gastrointestinal disorders in horses and cattle. *Journal of Veterinary Medicine A*. 1995;**42**(10):613-631. DOI: 10.1111/j.1439-0442.1995.tb00416.x

[72] Vidovic A, Huskamp B. Endotoxämie bei Kolikerkrankungen des Pferdes-Quantitative Bestimmung und klinische Relevanz. *Pferdeheilkunde*. 1999;**15**(4):325-334

[73] Turler A, Moore BA, Pezzone MA, Overhaus M, Kalff JC, Bauer AJ. Colonic postoperative inflammatory ileus in the rat. *Annals of Surgery*. 2002;**236**(1):56-66. DOI: 10.1097/00000658-200207000-00010

- [74] Barbara G, De Giorgio R, Deng Y, Vallance B, Blennerhassett P, Collins SM. Role of immunologic factors and cyclooxygenase 2 in persistent postinfective enteric muscle dysfunction in mice. *Gastroenterology*. 2001;**120**(7):1729-1736. DOI: 10.1053/gast.2001.24847
- [75] Bauer AJ, Boeckxstaens GE. Mechanisms of postoperative ileus. *Neurogastroenterology and Motility*. 2004;**16**(Suppl 2):54-60. DOI: 10.1111/j.1743-3150.2004.00558.x
- [76] Shah SK, Uray KS, Stewart RH, Laine GA, Cox CS. Resuscitation-induced intestinal edema and related dysfunction: State of the science. *Journal of Surgical Research*. 2011;**166**(1):120-130. DOI: 10.1016/j.jss.2009.09.010
- [77] Boeckxstaens GE, de Jonge WJ. Neuroimmune mechanisms in postoperative ileus. *Gut*. 2009;**58**(9):1300-1311. DOI: 10.1136/gut.2008.169250
- [78] Boeckxstaens GE, Hollmann M, Heisterkamp SH, Robberecht P, de Jonge WJ, van Den Wijngaard RM, et al. Evidence for VIP(1)/PACAP receptors in the afferent pathway mediating surgery-induced fundic relaxation in the rat. *British Journal of Pharmacology*. 2000;**131**(4):705-710. DOI: 10.1038/sj.bjp.0703625
- [79] Barquist E, Bonaz B, Martinez V, Rivier J, Zinner MJ, Tache Y. Neuronal pathways involved in abdominal surgery-induced gastric ileus in rats. *The American Journal of Physiology*. 1996;**270**(4 Pt 2):R888-R894. DOI: 10.1152/ajpregu.1996.270.4.R888
- [80] Desborough JP. The stress response to trauma and surgery. *British Journal of Anaesthesia*. 2000;**85**(1):109-117. DOI: 10.1093/bja/85.1.109
- [81] Cao SG, Wu WC, Han Z, Wang MY. Effects of psychological stress on small intestinal motility and expression of cholecystokinin and vasoactive intestinal polypeptide in plasma and small intestine in mice. 2005;**11**(5):737-World J Gastroentero, 740. DOI: 10.3748/wjg.v11.i5.737
- [82] Tache Y, Martinez V, Million M, Wang L. Stress and the gastrointestinal tract III. Stress-related alterations of gut motor function: Role of brain corticotropin-releasing factor receptors. *American Journal of Physiology. Gastrointestinal and Liver Physiology*. 2001;**280**(2):G173-G177. DOI: 10.1152/ajpgi.2001.280.2.G173
- [83] Adams SB. Recognition and management of ileus. *The Veterinary Clinics of North America. Equine Practice*. 1988;**4**(1):91-104. DOI: 10.1016/s0749-0739(17)30652-1
- [84] Bonaz B, Tache Y. Corticotropin-releasing factor and systemic capsaicin-sensitive afferents are involved in abdominal surgery-induced Fos expression in the paraventricular nucleus of the hypothalamus. *Brain Research*. 1997;**748**(1-2):12-20. DOI: 10.1016/s0006-8993(96)01281-4
- [85] Luckey A, Livingston E, Tache Y. Mechanisms and treatment of postoperative ileus. *Archives of Surgery (Chicago, IL)*. 2003;**138**(2):206-214. DOI: 10.1001/archsurg.138.2.206
- [86] Tache Y, Monnikes H, Bonaz B, Rivier J. Role of Crf in stress-related alterations of gastric and colonic motor function. *Annals of the New York Academy of Sciences*. 1993;**697**:233-243. DOI: 10.1111/j.1749-6632.1993.tb49936.x
- [87] Tache Y, Martinez V, Million M, Rivier J. Corticotropin-releasing factor and the brain-gut motor response to stress. *Canadian Journal of Gastroenterology*. 1999;**13**(Suppl A): 18A-25A. DOI: 10.1155/1999/375916
- [88] Chatzaki E, Crowe PD, Wang L, Million M, Tache Y, Grigoriadis DE. CRF

receptor type 1 and 2 expression and anatomical distribution in the rat colon. *Journal of Neurochemistry*. 2004;**90**(2):309-316. DOI: 10.1111/j.1471-4159.2004.02490.x

[89] Chen CY, Million M, Adelson DW, Martinez V, Rivier J, Tache Y. Intracisternal urocortin inhibits vagally stimulated gastric motility in rats: Role of CRF(2). *British Journal of Pharmacology*. 2002;**136**(2):237-247. DOI: 10.1038/sj.bjp.0704713

[90] Le Blanc-Louvry I, Coquerel A, Koning E, Maillot C, Ducrotte P. Operative stress response is reduced after laparoscopic compared to open cholecystectomy—The relationship with postoperative pain and ileus. *Digestive Diseases and Sciences*. 2000;**45**(9):1703-1713. DOI: 10.1023/A:1005598615307

[91] Dubois M, Pickar D, Cohen MR, Roth YF, Macnamara T, Bunney WE Jr. Surgical stress in humans is accompanied by an increase in plasma beta-endorphin immunoreactivity. *Life Sciences*. 1981;**29**(12):1249-1254. DOI: 10.1016/0024-3205(81)90230-7

[92] De Winter BY, Boeckxstaens GE, De Man JG, Moreels TG, Herman AG, Pelckmans PA. Effect of adrenergic and nitrenergic blockade on experimental ileus in rats. *British Journal of Pharmacology*. 1997;**120**(3):464-468. DOI: 10.1038/sj.bjp.0700913

[93] De Winter BY, Robberecht P, Boeckxstaens GE, De Man JG, Moreels TG, Herman AG, et al. Role of VIP1/PACAP receptors in postoperative ileus in rats. *British Journal of Pharmacology*. 1998;**124**(6):1181-1186. DOI: 10.1038/sj.bjp.0701954

[94] de Jonge WJ, van den Wijngaard RM, The FO, ter Beek ML, Bennink RJ, Tytgat GN, et al. Postoperative ileus is maintained by intestinal immune infiltrates

that activate inhibitory neural pathways in mice. *Gastroenterology*. 2003;**125**(4):1137-1147. DOI: 10.1016/s0016-5085(03)01197-1

[95] Malone ED, Brown DR, Trent AM, Turner TA. Influence of adrenergic and cholinergic mediators on the equine jejunum in vitro. *American Journal of Veterinary Research*. 1996;**57**(6):884-890

[96] Boeckxstaens GE, Hirsch DP, Kodde A, Moojen TM, Blackshaw A, Tytgat GN, et al. Activation of an adrenergic and vagally-mediated NANC pathway in surgery-induced fundic relaxation in the rat. *Neurogastroenterology and Motility*. 1999;**11**(6):467-474. DOI: 10.1046/j.1365-2982.1999.00172.x

[97] Zittel TT, Lloyd KC, Rothenhofer I, Wong H, Walsh JH, Raybould HE. Calcitonin gene-related peptide and spinal afferents partly mediate postoperative colonic ileus in the rat. *Surgery*. 1998;**123**(5):518-527. DOI: 10.1067/msy.1998.88090

[98] Jameson P, Desborough JP, Bryant AE, Hall GM. The effect of cortisol suppression on interleukin-6 and white blood cell responses to surgery. *Acta Anaesthesiologica Scandinavica*. 1997;**41**(2):304-308. DOI: 10.1111/j.1399-6576.1997.tb04683.x

[99] la Fleur SE, Wick EC, Idumalla PS, Grady EF, Bhargava A. Role of peripheral corticotropin-releasing factor and urocortin II in intestinal inflammation and motility in terminal ileum. *Proceedings of the National Academy of Sciences of the United States of America*. 2005;**102**(21):7647-7652. DOI: 10.1073/pnas.0408531102

[100] Merritt AM, Burrow JA, Hartless CS. Effect of xylazine, detomidine, and a combination of xylazine and butorphanol on equine duodenal motility. *American*

Journal of Veterinary Research. 1998;**59**(5):619-623

[101] Lester GD, Merritt AM, Neuwirth L, Vetro-Widenhouse T, Steible C, Rice B. Effect of alpha(2)-adrenergic, cholinergic, and nonsteroidal anti-inflammatory drugs on myoelectric activity of ileum, cecum, and right ventral colon and on cecal emptying of radiolabeled markers in clinically normal ponies. American Journal of Veterinary Research. 1998;**59**(3):320-327

[102] Adams SB, Lamar CH, Mast J. Motility of the distal portion of the jejunum and pelvic flexure in ponies: Effects of six drugs. American Journal of Veterinary Research. 1984;**45**(4):795-799

[103] Lester G. Gastrointestinal ileus. In: Smith B, editor. Large Animal Internal Medicine. St. Louis, USA: Mosby; 2002. p. 674-679.

[104] Lester GD, Bolton JR, Cullen LK, Thurgate SM. Effects of general-anaesthesia on myoelectric activity of the intestine in horses. American Journal of Veterinary Research. 1992;**53**(9):1553-1557

[105] Schurizek BA, Willacy LH, Kraglund K, Andreasen F, Juhl B. Effects of general anaesthesia with halothane on antroduodenal motility, pH and gastric emptying rate in man. British Journal of Anaesthesia. 1989;**62**(2):129-137. DOI: 10.1093/bja/62.2.129

[106] Little D, Redding WR, Blikslager AT. Risk factors for reduced postoperative fecal output in horses: 37 cases (1997-1998). Journal of the American Veterinary Medical Association. 2001;**218**(3):414-420. DOI: 10.2460/javma.2001.218.414

[107] Salciccia A, Gougnard A, Grulke S, de Pouyade GD, Libertiaux V, Busoni V, et al. Gastrointestinal effects of general

anaesthesia in horses undergoing non abdominal surgery: Focus on the clinical parameters and ultrasonographic images. Research in Veterinary Science. 2019;**124**:123-128. DOI: 10.1016/j.rvsc.2019.03.011

[108] Lefebvre D, Hudson NPH, Elce YA, Blikslager A, Divers TJ, Handel IG, et al. Clinical features and management of equine post operative ileus (POI): Survey of Diplomates of the American Colleges of Veterinary Internal Medicine (ACVIM), Veterinary Surgeons (ACVS) and Veterinary Emergency and Critical Care (ACVECC). Equine Veterinary Journal. 2016;**48**(6):714-719. DOI: 10.1111/evj.12520

[109] Lefebvre D, Pirie RS, Handel IG, Tremaine WH, Hudson NPH. Clinical features and management of equine post operative ileus: Survey of diplomates of the European Colleges of Equine Internal Medicine (ECEIM) and Veterinary Surgeons (ECVS). Equine Veterinary Journal. 2016;**48**(2):182-187. DOI: 10.1111/evj.12355

[110] Roussel AJ, Cohen ND, Hooper RN, Rakestraw PC. Risk factors associated with development of postoperative ileus in horses. Journal of the American Veterinary Medical Association. 2001;**219**(1):72-78. DOI: 10.2460/javma.2001.219.72

[111] Merritt AM, Blikslager AT. Post operative ileus: To be or not to be? Equine Veterinary Journal. 2008;**40**(4):295-296. DOI: 10.2746/042516408X302537

[112] Mitchell CF, Malone ED, Sage AM, Niksich K. Evaluation of gastrointestinal activity patterns in healthy horses using B mode and Doppler ultrasonography. The Canadian Veterinary Journal. 2005;**46**(2):134-140

[113] Kovac M, Aliev R, Tkacenko A. Improved methodology of abdominal ultrasonography in horses with

gastrointestinal disease. *Veterinářství*. 2018;**5**:31-37. Available from: <http://vetpharma.org/articles/140/7827/>

[114] Freeman SL, England GC. Effect of romifidine on gastrointestinal motility, assessed by transrectal ultrasonography. *Equine Veterinary Journal*. 2001;**33**(6):570-6. DOI: 10.2746/042516401776563436

[115] Durongphongtorn S, McDonell WN, Kerr CL, Neto FJT, Mirakhor KK. Comparison of hemodynamic, clinicopathologic, and gastrointestinal motility effects and recovery characteristics of anesthesia with isoflurane and halothane in horses undergoing arthroscopic surgery. *American Journal of Veterinary Research*. 2006;**67**(1):32-42. DOI: 10.2460/ajvr.67.1.32

[116] Phillips TJ, Walmsley JP. Retrospective analysis of the results of 151 exploratory laparotomies in horses with gastrointestinal-disease. *Equine Veterinary Journal*. 1993;**25**(5):427-431. DOI: 10.1111/j.2042-3306.1993.tb02985.x

[117] Bracamonte JL, Devick I, Thomas KL, Hendrick S. Comparison of hand-sewn and oversewn stapled jejunojejunal anastomoses in horses. *The Canadian Veterinary Journal*. 2018;**59**(1):67-73

[118] Klohnen A. New perspectives in postoperative complications after abdominal surgery. *Veterinary Clinics of North America: Equine Practice*. 2009;**25**(2):341. DOI: 10.1016/j.cveq.2009.05.003

[119] Alonso Jde M, Alves AL, Watanabe MJ, Rodrigues CA, Hussni CA. Peritoneal response to abdominal surgery: The role of equine abdominal adhesions and current prophylactic strategies. *Vet Med Int*. 2014;**2014**:279730. DOI: 10.1155/2014/279730

[120] Lim R, Morrill JM, Lynch RC, Reed KL, Gower AC, Leeman SE, et al. Practical limitations of bioresorbable membranes in the prevention of intra-abdominal adhesions. *Journal of Gastrointestinal Surgery*. 2009;**13**(1):35-42. DOI: 10.1007/s11605-008-0724-3

[121] Kuebelbeck KL, Slone DE, May KA. Effect of omentectomy on adhesion formation in horses. *Veterinary Surgery*. 1998;**27**(2):132-137. DOI: 10.1111/j.1532-950X.1998.tb00109.x

[122] Smith MA, Edwards GB, Dallap BL, Cripps PJ, Proudman CJ. Evaluation of the clinical efficacy of prokinetic drugs in the management of post-operative ileus: Can retrospective data help us? *Veterinary Journal*. 2005;**170**(2):230-236. DOI: 10.1016/j.tvjl.2004.06.006

[123] van der Spoel JI, Oudemans-van Straaten HM, Stoutenbeek CP, Bosman RJ, Zandstra DF. Neostigmine resolves critical illness-related colonic ileus in intensive care patients with multiple organ failure—a prospective, double-blind, placebo-controlled trial. *Intensive Care Medicine*. 2001;**27**(5):822-827. DOI: 10.1007/s001340100926

[124] Van Hoogmoed LM, Nieto JE, Snyder JR, Harmon FA. Survey of prokinetic use in horses with gastrointestinal injury. *Veterinary Surgery*. 2004;**33**(3):279-285. DOI: 10.1111/j.1532-950X.2004.04041.x

[125] Milligan M, Beard W, Kukanich B, Sobering T, Waxman S. The effect of lidocaine on postoperative jejunal motility in normal horses. *Veterinary Surgery*. 2007;**36**(3):214-220. DOI: 10.1111/j.1532-950X.2007.00255.x

[126] Brianceau P, Chevalier H, Karas A, Court MH, Bassage L, Kirker-Head C, et al. Intravenous lidocaine and small-intestinal size, abdominal fluid, and outcome after colic surgery in

horses. *Journal of Veterinary Internal Medicine*. 2002;**16**(6):736-741. DOI: 10.1892/0891-6640(2002)016<0736:ilas sa>2.3.co;2

[127] Freeman DE. Is there still a place for lidocaine in the (postoperative) management of colics? *Veterinary Clinics of North America: Equine Practice*. 2019;**35**(2):275. DOI: 10.1016/j.cveq.2019.03.003

[128] Nieto JE, Rakestraw PC, Snyder JR, Vatisstas NJ. In vitro effects of erythromycin, lidocaine, and metoclopramide on smooth muscle from the pyloric antrum, proximal portion of the duodenum, and middle portion of the jejunum of horses. *American Journal of Veterinary Research*. 2000;**61**(4):413-419. DOI: 10.2460/ajvr.2000.61.413

[129] Salem SE, Proudman CJ, Archer DC. Has intravenous lidocaine improved the outcome in horses following surgical management of small intestinal lesions in a UK hospital population? *BMC Veterinary Research*. 2016;**12**:1-11. DOI: 10.1186/s12917-016-0784-7

[130] Dart AJ, Hodgson DR. Role of prokinetic drugs for treatment of postoperative ileus in the horse. *Australian Veterinary Journal*. 1998;**76**(1):25-31

[131] Gerring EL, King JN. Cisapride in the prophylaxis of equine post operative ileus. *Equine Veterinary Journal. Supplement*. 1989;**21**(S7):52-55. DOI: 10.1111/j.2042-3306.1989.tb05656.x

[132] Sojka JE, Adams SB, Lamar CH, Eller LL. Effect of butorphanol, pentazocine, meperidine, or metoclopramide on intestinal motility in female ponies. *American Journal of Veterinary Research*. 1988;**49**(4):527-529

[133] Doherty TJ, Andrews FM, Abrahams TW, Osborne D, Frazier DL.

Metoclopramide ameliorates the effects of endotoxin on gastric emptying of acetaminophen in horses. *Canadian Journal of Veterinary Research*. 1999;**63**(1):37-40

[134] Nieto JE, Maher O, Stanley SD, Larson R, Snyder JR. In vivo and in vitro evaluation of the effects of domperidone on the gastrointestinal tract of healthy horses. *American Journal of Veterinary Research*. 2013;**74**(8):1103-1110

[135] Holte K, Kehlet H. Postoperative ileus: a preventable event. *British Journal of Surgery*. 2000;**87**(11):1480-1493. DOI: 10.1046/j.1365-2168.2000.01595.x

[136] McKenzie HC. Equine hyperlipidemias. *Veterinary Clinics of North America: Equine Practice*. 2011;**27**(1):59. DOI: 10.1016/j.cveq.2010.12.008