

# We are IntechOpen, the world's leading publisher of Open Access books Built by scientists, for scientists

6,900

Open access books available

185,000

International authors and editors

200M

Downloads

Our authors are among the

154

Countries delivered to

TOP 1%

most cited scientists

12.2%

Contributors from top 500 universities



WEB OF SCIENCE™

Selection of our books indexed in the Book Citation Index  
in Web of Science™ Core Collection (BKCI)

Interested in publishing with us?  
Contact [book.department@intechopen.com](mailto:book.department@intechopen.com)

Numbers displayed above are based on latest data collected.  
For more information visit [www.intechopen.com](http://www.intechopen.com)



---

# Robot-Assisted Partial Nephrectomy: Evolving Techniques

---

Mohammed Kamil Quraishi, Edward Ramez Latif,  
Milan Thomas, Ben Eddy, Elio Mazzone and  
Alexandre Mottrie

Additional information is available at the end of the chapter

---

## Abstract

Robotic-assisted partial nephrectomy is now embraced in urology as a recommended treatment option for small localised renal tumours. There is an increasing trend towards setting up robotic-assisted services in urological centres across the world. Our aim is to review the available published common robotic-assisted partial nephrectomy techniques. We present our institutions' established step-by-step technique for performing robotic-assisted partial nephrectomy, in order to guide aspiring urologists interested in performing robotic-assisted partial nephrectomies. The importance of pre-operative review of imaging in a multi-disciplinary approach is critical. We emphasise certain tips in performing a safer procedure.

**Keywords:** robotic, partial, nephrectomy, technique, procedure

---

## 1. Anatomy

Specific anatomical consideration needs to be given to the hilar and tumour anatomy. In particular this includes reviewing the size, location within the kidney, and the degree of the exophytic nature of the tumour, in robotic-assisted partial nephrectomy. A thorough pre-operative review of the cross-sectional imaging and patient factors needs to be considered in a multi-disciplinary setting. Each hospital uses their own CT protocol, however we perform a pre-contrast and post contrast nephrogenic phase to assess renal mass enhancement. An arterial and delayed excretory phase may also be added for surgical planning. These phases clarify the presence of variant anatomy including feeding vessels to the tumour or accessory renal veins. It also helps demarcate the distance of the tumour from the renal hilum and the

---

collecting system [1]. The anatomical relations play an important role, particularly in hilar dissection, including the presence of the head of the pancreas and part of the duodenum overlying the right renal hilum. The left hilum is in close proximity to the body and tail of the pancreas, with the left colonic flexure bordering the left kidney anteriorly. In nearly 30% of cases more than one renal artery is identified supplying a kidney, often on the right side [2]. The renal arteries run posteriorly from the aorta to the kidneys, due to the orientation of the renal hilum. The arteries split into four anterior and one posterior segmental branches at the renal hilum [3]. The renal arteries sit in the middle at the hilum, with the renal veins anteriorly and the ureters/collecting systems posterior to the artery [4]. Multiple variants in renal artery anatomy have been reported in the literature, thereby highlighting the close attention warranted during the review of preoperative imaging [3, 5].

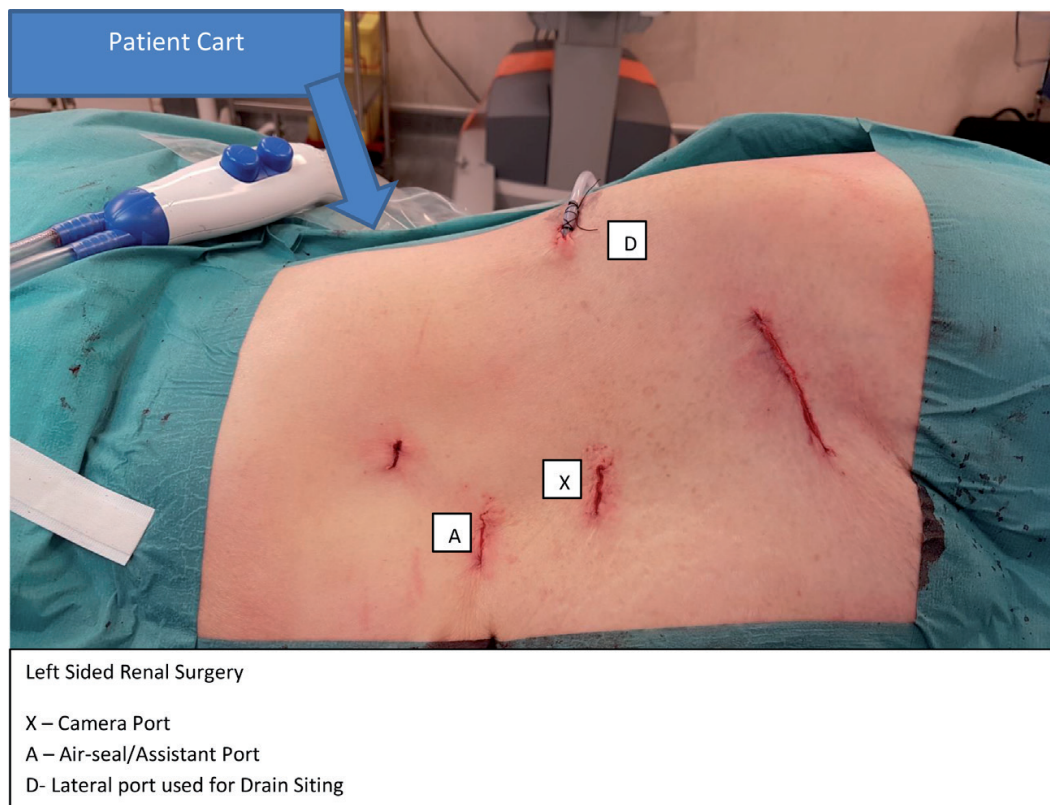
## 2. Introduction

We use a standardised four robotic arm technique using the for renal surgery the Da Vinci Si Surgical system (Intuitive Surgical Inc., Sunnyvale, CA, USA). Suitable training must be achieved to acquire appropriate robotic skills before performing complex renal surgery. We recommend a modular training programme in keeping with European and British board standards [6, 7].

Ensuring that the early stages of the learning curve are supervised with a mentor is essential to reduce errors and aid development of confidence in robotic skills. Evidence on learning curves vary in robotic-assisted partial nephrectomy (RAPN), with a study reporting 44 case requirement by a laparoscopically trained surgeon, to achieve a warm ischaemia time (WIT) of less than 20 min and an operative time of less than 120 min [8]. An alternative report by another centre identified needing to perform 61–90 cases to reach a trifecta of no significant complications, negative surgical margins and WIT of less than 25 min [9]. Needless to say learning curves can be improved with better training techniques, volume and exposure [10]. WIT was found to decrease to 13 from 20 min, following performing 150 RAPN cases compared to the first 10 cases [11]. Robotic trainees under expert supervision were found to have longer operating and warm ischaemia time, but otherwise no worse outcomes than experts performing robotic partial nephrectomies [12]. In addition the patient-side assistant should be appropriately skilled in handling instruments safely and deploying ligature clips. All cases should be subjected to nephrometry scoring (PADUA and RENAL) and a thorough imaging review preoperatively to predict operative complexities and postoperative complications [13–16]. We incorporate the PADUA score due to its standardised use across the national nephrectomy register, collected by the British Association of Urological Surgeons.

## 3. Patient positioning

The authors recommend this operative approach, based on the available disseminated techniques and preference in their experience and training [17–24]. In order to perform a robotic-assisted partial nephrectomy, the patient is positioned in a lateral decubitus/flank position (**Figure 1**) on the operative table to aid bowel mobilisation [24]. The operative table



**Figure 1.** Full flank patient positioning for left RAPN. Note port site marking made prior to knife to skin.

is subsequently broken/flexed. This opens the flank, between the costal margin and the iliac crest. A reported variation may include a slight Trendelenburg position and a flat table [23]. The anterior abdomen lies on the edge of the operative table. The upper arm is flexed at the elbow and kept adjacent to the face [21]. We prefer adhesive tape to secure the patient to the bed, at the level of the iliac crest [23]. Additional adhesive tape used at the level of the mid thoracic cavity should be applied with caution to avoid reduced chest expansion, in the context of ventilation. The back can be stabilised using an additional back support attachment with gel pads. The bottom leg in the lateral position is flexed to 90° at the knee, and is separated from the extended top leg using pillows. All pressure points are padded [23]. A nasogastric tube (NGT) is placed in left sided tumours and a urinary catheter is inserted following anaesthetic induction for all cases, and prior to patient positioning [21]. The NGT is removed in recovery.

### 3.1. Tips and tricks

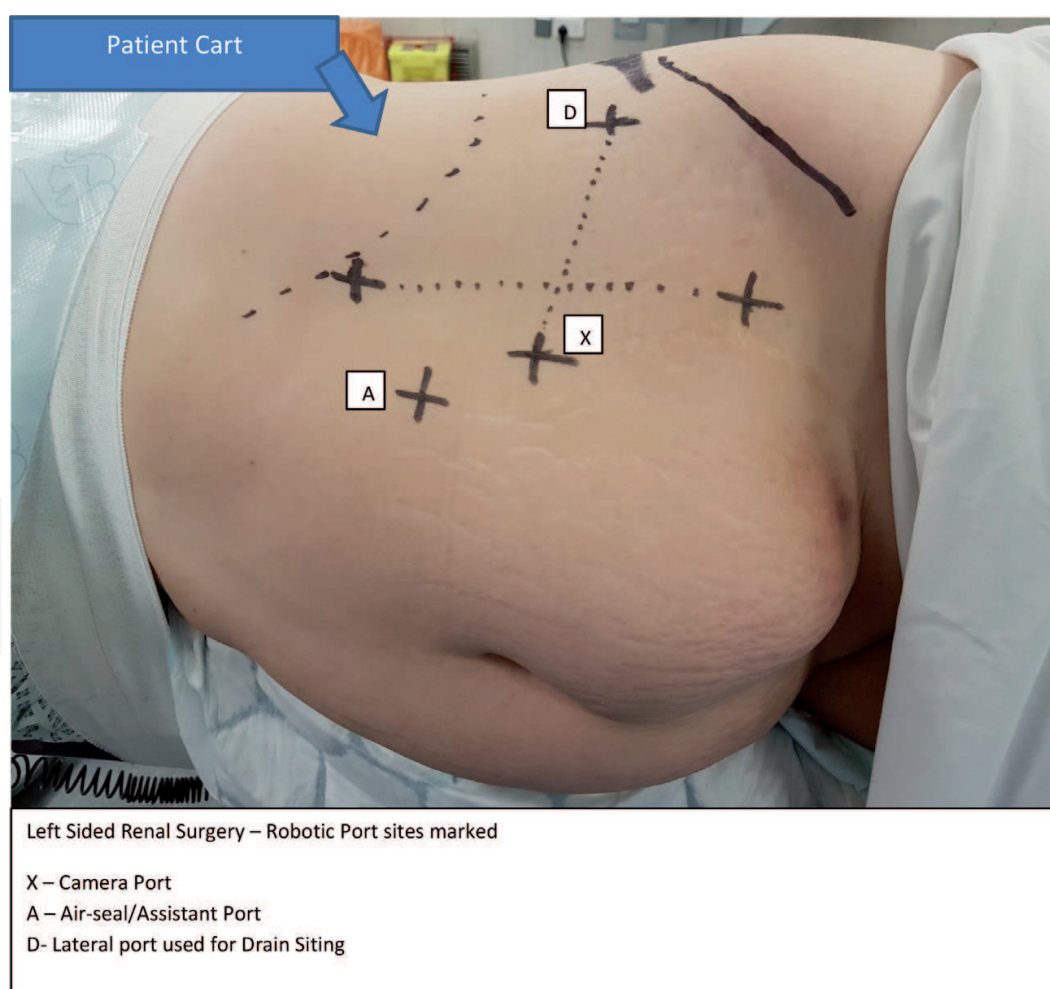
- A consistent surgical team who develop skills progressively with the surgeon, specifically for renal surgery is essential for optimal outcomes. Robotic renal surgery is approached differently from pelvic surgery and cannot instantly be translated.
- It is vital that your anaesthetic staff is experienced with patient positioning and moving for robotic renal surgery.

A uniform anaesthetic team will also lead to better pain control in the post-operative phase and consistently enhanced results particularly during the critical on-clamp (WIT) period of partial nephrectomy.

## 4. Port placement

Precise port placement and patient cart position are important for successful outcomes in robotic renal surgery. Unlike in pelvic surgery, the operative field is wider increasing the potential for robot arms to clash. With some basic principles, success can be replicated case after case. As with radical prostatectomy, the ports must be placed with a minimum 8 cm distance apart. However, with different laterality of renal surgery, an additional consideration is placing arm 3 of the patient cart. In the case of right sided renal tumours, arm 3 should be positioned on the left of the cart stem. The reverse is true for left renal surgery.

We recommend marking the skin to plan port positioning. Formation of a skewed cross or upside-down kite shape should be made with the camera port forming the apex. However the reference point should be the subcostal port, as it offers least flexibility in positioning. The camera port, target organ and patient cart should form a straight line, thereby creating adequate triangulation for safe operating. The contralateral operating port will form a horizontal line to the subcostal port, with the camera port bisecting this line in the middle (**Figure 2**).



**Figure 2.** Port site marking for a right RAPN.



This should give adequate room for the 4th robotic arm port, which will then complete the kite or cross shape, placed laterally roughly in the anterior axillary line. It is possible that arm 1 (when operating on the right kidney) can hold the ProGrasp™ forceps, rather than arm 3. The robot is then manipulated to dock over the patient's upper shoulder at an angle of 45 degrees to the kidney.

#### 4.1. Tips and tricks

- Use of the bariatric ports can be beneficial to achieve greater distance between the robot arms, particularly in smaller patients. This will reduce the potential for robot arm clashing.
- Should the arms clash, then 'burping' the ports away from each other can create additional room and potentially avoid restricted movement of the instruments, which can severely limit surgical progress. The ports placed under traction, tents the abdominal wall externally, increasing intra-abdominal space to work in [25].

## 5. Surgical technique

Evidence from a meta-analysis reveals similar surgical outcomes and complications between transperitoneal and retroperitoneal robot-assisted partial nephrectomies. The retroperitoneal approach may have a specific role in selected cases including posterior tumours and in patients with previous significant transperitoneal surgery. Absence of the need to mobilise bowel and easy access to the hilar vessels, leads to a shorter operative time [26]. However, the choice between retroperitoneal or transperitoneal approach lies based on surgeon's expertise and patient factors [17].

We recommend a trans-peritoneal approach, particularly in the early phase of the learning curve. This will ensure that adjacent structures can be adequately mobilised away from the kidney. In addition, operative space is optimised when within the peritoneum. This will avoid injury to sensitive structures such as the duodenum on the right and the spleen; tail of the pancreas and duodeno-jejunal junction on the left. The authors recommend using a 0° camera lens in the early learning curve period, unless experienced in 30° downward scope lens from laparoscopic surgery [23]. Use of 30° downward lens has a role in the later stages of dissecting posterior tumours [24]. A pneumoperitoneum of 10–12 mmHg is established. In almost all cases the kidney can be adequately mobilised to expose renal masses to perform a partial nephrectomy successfully in the trans-peritoneal approach. However, some surgeons transferring from retroperitoneal laparoscopic surgery may feel suitably experienced in translating skills to perform retroperitoneal robotic surgery. Guides are available on performing retroperitoneal RAPN [27, 28].

A wide array of instruments and preferences exist in performing a RAPN. The authors perform the procedure with the surgeon holding the EndoWrist® Fenestrated Bipolar Forceps and the EndoWrist® Hot Shears™ monopolar curved scissors in the non-dominant and dominant hand robotic ports respectively. Sharp dissection is performed along the white line of Toldt.

Sharp and blunt dissection is used to reflect the large bowel off the anterior surface of Gerota's fascia [24]. Dissection is directed to the inferior border of Gerota's fascia in order to locate the ureter. Release of attachments from adjacent structures including liver or spleen may be performed to characterise the planes clearly. The psoas major muscle is used as a landmark to help identify the ureter, similar to a laparoscopic approach. The ureter is then dissected cranially to identify the renal hilum [23]. Specific care should be taken to control, or avoid injury to the gonadal vessels. The additional robotic arm, holding the ProGrasp™ forceps can now be deployed to retract the kidney laterally, thereby creating space to dissect the hilum safely away from sensitive medial structures (such as the duodenum or inferior vena cava). The Force Bipolar™ is a new instrument which combines the ProGrasp™ grasping qualities with bipolar diathermy and may be incorporated instead for efficiency. In right sided tumours, the hilum can be approached from a cranial to caudal direction, enabling earlier access to the renal artery. The Inferior Vena Cava just below the liver can be easily identified and followed caudally to reach the renal pedicle in right sided tumours.

Hilar dissection requires sensitive movements to adequately expose all renal vessels (one at a time) to allow for application of clamps later in the operation. This enables precise control in case of unexpected haemorrhage. We recommend clamping the main renal artery early in the learning curve, rather than attempting to selectively clamp more distal segmental branches. Near-infrared fluorescence imaging system with indocyanine green is an available technology allowing identification of intraoperative parenchymal perfusion, thereby enabling selective vessel clamping for limiting ischaemia to the tumour alone. It has been shown to improve early functional outcomes, with better preservation of glomerular filtration rate of the resected kidney on renal scan with Tc 99 m-DTPA [29]. Once the main artery is exposed, a short sling can be placed and held in place by a suitable arterial clip (to the rubber sling ends alone), we use a Weck® Hem-o-lok® ligating clip.

At this stage exposure of the renal tumour proceeds by incising Gerota's fascia and 'defatting' the kidney adequately, preferably along the renal capsular plane. This will enable adequate exposure of the renal tumour and mobilise the kidney to achieve a wide surgical field to perform the excision. The drop-in ultrasound probe is introduced and manipulated by the surgeon using the ProGrasp™ forceps to distinguish tumour margins [17]. The tumour is marked superficially on the renal capsule with the Hot Shears™ curved monopolar diathermy scissors, leaving a 5 mm margin for oncological outcomes.

All accessory equipment is introduced through the assistant port, including the arterial clamps. Two absorbable monofilament sutures such as Poliglecaprone, e.g. Monocryl® 3-0 and two absorbable braided sutures such as Polyglactin, e.g. 0-Vicryl®, cut to size are strategically positioned in the abdomen for easy access during renorrhaphy.

At this stage a brief 'time-out' ensures that the surgeon and the surgical team are aware of the ensuing critical element of the operation—sometimes known as 'on-clamp time'. This provides ample opportunity to ensure that there is adequate insufflation gas in the tanks, that additional sutures are readily available and that the anaesthetist is prepared for potential haemorrhage. At this stage it is recommended to re-review the CT images to ensure that the shape of the renal mass can be translated to the operative field. The authors do not recommend

the usage of Mannitol in view of its limited evidence in minimising loss of renal function post operatively in humans [30].

To minimise the dangers associated with, the next step is performed after unanimous readiness of the theatre staff. A Scanlan® Reliance Bulldog Clamp (Scanlan® International, St. Paul, MN, USA) is applied to the renal artery, in selected cases this is followed by another on the renal vein [23]. Satinsky clamp is an option in the rare difficult dissections when bleeding from the renal pedicle impairs ability to clamp the vessels with a bulldog clamp [31]. The clamping marks the triggering of a stopwatch, to measure warm ischaemic time.

The tumour is excised with consideration of surgical margins, with the assistant surgeon ensuring the field is adequately exposed by suctioning away blood. The sliding-clip renorrhaphy principle is applied to close the renal defect, in multiple layers. The deep layer of the renorrhaphy is performed with the poliglecaprone 3–0 suture, with a Weck® Hem-o-lok® ligating clip already attached at one end. A continuous suture runs through the base of the defect closing any open collecting system and small vessels. If arterial bleeds are detected these can be closed individually with additional monofilament sutures to ensure meticulous haemostasis. Once the continuous running poliglecaprone suture is applied, a Hem-o-lok® clip is applied to the needle end. Traction is applied to the needle end to snug the clip down against the renal capsule, bringing the renal defect together. Larger defects will require multiple sutures. We use an early ‘off-clamp’ technique after the deep sliding-clip renorrhaphy is complete, in the order of release of renal vein, followed by the artery, where the vein has been clamped. This reduces the warm ischaemic time. We do not use a bolster. At this stage haemostasis is adequate to complete the superficial sliding-clip renorrhaphy suture with a large polyglactin suture. In this layer, clips are applied at every throw through the renal capsule to further close the defect. A second locking clip can be applied above every previous clip on the sliding suture to prevent slipping. Use of adjuncts to haemostasis is not essential but may provide added security and further minimise blood loss. This may be in the form of Floseal®, Surgicel® or Evicel®. The hilum and excision site are carefully inspected following this step, to ensure haemostasis is achieved. We recommend closing Gerota’s fascia, which may minimise difficulty in future renal surgery from scarring [24]. An intra-abdominal drain is inserted through the lateral port. The specimen is removed using an endocatch pouch, inserted through the assistant’s port.

### 5.1. Tips and tricks

- A ‘time-out’ is taken to assess the tumour excision, the associated renal defect and the plan for renorrhaphy prior to the on-clamp time, will in our experience lead to better planning and a potentially safer procedure.
- Use of intraoperative doppler ultrasound is widely recommended for use in partial nephrectomy.
- Plan your incision on the Gerota’s fascia carefully will help with closure after. Practice often on simulators to ensure that your suturing skills are adequate to perform renorrhaphy under the pressure of limited time, whilst the clamp clock is ticking.



- An apron of Perinephric fat can be placed behind the posterior surface of the kidney, to anteriorly displace the kidney. This improves access to posterior and lateral tumours. If there is inadequate Perinephric fat, tonsil swabs can be placed instead.

This is our summarised technique that is performed in our practice, which can be adopted by departments interested in developing a robotic partial nephrectomy service.

## 6. Indication and guidelines

Both EAU and AUA guidelines advise minimally invasive surgery if possible, however advise caution if perioperative, oncological or functional outcomes are at risk of compromise [32, 33]. In fact, EAU recommend partial nephrectomy over radical in patients with T1 tumours, even if an open approach is warranted. Any approach for PN is valid based on the surgeons skill and preference.

The EAU advise that despite the similar cancer specific survival and recurrence free survival for pT1 tumours in the comparison of partial versus radical nephrectomy; partial nephrectomy is still the ideal treatment in view of minimising impairment to renal function and preventing metabolic and cardiovascular disorders in the long term. Retrospective studies have revealed no difference in long term overall and cancer specific survival between laparoscopic and open partial nephrectomies [34, 35].

Prospective comparison of robotic-assisted versus open partial nephrectomy found significant improvement in estimated blood loss and length of stay in the cohort undergoing RAPN. Early and short term complications, operative time and warm ischaemia time were similar between both approaches [36]. Robotic-assisted surgery was found be superior to laparoscopic PN with regards to conversion to open, conversion to radical nephrectomy, warm ischaemia time and length of stay. This meta-analysis of 23 studies also concluded no difference in short term postoperative complications, operative time, estimated blood loss and positive margins [37].

## 7. Future developments

We describe a few developing technologies which may be of interest to urologists.

Reconstruction and navigation technology appears to have an emerging role in both preoperative and intraoperative planning and operative assistance. A diverse group of 108 urologists of various training experience changed their views to feel an RAPN over a radical nephrectomy was indicated from 47–75% of the 20 complex cases reviewed following a re-review of the CT scan with three dimensional reconstruction of the renal units [38].

Hyperaccuracy three dimensional (HA3D) is an emerging technology allowing three dimensional reconstructions, enabling virtual mapping of the in-vivo structures with the reconstructed model during the partial nephrectomy. A small sample sized study in complex renal tumours (PADUA >10), using this HA3D technology enabled intraoperative management of the pedicle

as preoperatively planned in 90% of the cases [39]. The accuracy of the arterial reconstruction enabled preoperative simulation of vascular ischaemia by selective clamping. This enabled reduction of global ischaemia from 81–24% with the use of the HA3D technology [39].

Near-infrared fluorescence (NIRF) technology using an intravenous contrast medium (e.g. Indocyanine green) enables identification of the segmental vessels perfusing the renal tumour, by switching between white light and fluorescence enhanced views intraoperatively [40]. NIRF RAPN has been found to have a lower loss in renal scan confirmed renal function in the operated unit and a lower reduction in Glomerular Filtration Rate (GFR of 8%) compared to standard RAPN without selective vessel clamping. In three of the 15 NIRF RAPN cases, selective clamping was converted to standard clamping as incomplete ischaemia of the tumour was identified. This demonstrates NIRFs growing benefit over non-NIRF selective clamping.

Urologists participating in a study on 3D (Three Dimensional) printed models of the kidney, favoured its use in preoperative planning, patient counselling and surgical training [41]. The authors report maximal benefit of these models in patients with complex renal vasculature [42].

## 8. Conclusion

Our technique offers a standardised approach to aspiring urologists in performing robotic-assisted partial nephrectomies. We expect urologists to have the appropriate level of training and supervision prior to performing this procedure. We highlight a variety of tips and tricks that have benefitted our team in performing safer and easier surgery. We describe the stance of guidelines of robotic surgery in partial nephrectomies. We highlight emerging technologies which may become incorporated into the future practice of robotic surgery.

## Author details

Mohammed Kamil Quraishi<sup>1\*</sup>, Edward Ramez Latif<sup>1</sup>, Milan Thomas<sup>1</sup>, Ben Eddy<sup>1</sup>, Elio Mazzone<sup>2</sup> and Alexandre Mottrie<sup>2</sup>

\*Address all correspondence to: mkquraishi@doctors.org.uk

<sup>1</sup> Kent and Canterbury Hospital, Canterbury, UK

<sup>2</sup> O.L.V. Hospital, Aalst, Belgium

## References

- [1] Kang SK, Kim D, Chandarana H. Contemporary imaging of the renal mass. *Current Urology Reports*. 2011;**12**:11. DOI: 10.1007/s11934-010-0148-y

- [2] Leung DA, Hagspiel KD, Angle JF, et al. MR angiography of the renal arteries. *Radiologic Clinics of North America*. 2002;**40**:847-865
- [3] Hazirolan T, Öz M, Türkbey B, et al. *Diagnostic and Interventional Radiology*. 2011;**17**: 67-73
- [4] Rocco F, Cozzi G. Renal anatomy, physiology and its clinical relevance to partial nephrectomy. In: Patel V, editor. *Robotic Urologic Surgery*. London: Springer; 2012
- [5] Sampaio FJB, Passos M. Renal arteries: Anatomic study for surgical and radiological practice. *Surgical and Radiologic Anatomy*. 1992;**14**:113-117
- [6] British Association of Urological Surgeons (BAUS) Robotic Surgery Curriculum – Guidelines for Training. Available from: [https://www.baus.org.uk/\\_userfiles/pages/files/Publications/Robotic%20Surgery%20Curriculum.pdf](https://www.baus.org.uk/_userfiles/pages/files/Publications/Robotic%20Surgery%20Curriculum.pdf). [Accessed: Sep 2018]
- [7] Sridhar A, Briggs T, Kelly J, Nathan S. Training in robotic surgery—An overview. *Current Urology Reports*. 2017;**18**:58
- [8] Dias BH, Ali MS, Dubey S, Krishnaswamy SA, Rao AR, Dubey D. Impact of learning curve on the perioperative outcomes following robotic-assisted partial nephrectomy for renal tumours. *Indian Journal of Urology*. 2018;**34**:62-67
- [9] Omidele OO, Davoudzadeh N, Palese M. Trifecta outcomes to assess learning curve of robotic partial nephrectomy. *JSLs*. 2018;**22**: pii e2017.00064
- [10] Peyronnet B, Tondut L, Bernhard JC, et al. Impact of hospital volume and surgeon volume on robot-assisted partial nephrectomy outcomes: A multicentre study. *BJU International*. 2018;**121**(6):916-922. DOI: 10.1111/bju.14175
- [11] Larcher A et al. The learning curve for robot-assisted partial nephrectomy: Impact of surgical experience on perioperative outcomes. *European Urology*. 2018;**75**:253-256. DOI: 10.1016/j.eururo.2018.08.042
- [12] Khene ZE, Peyronnet B, Bosquet E. Does training of fellows affect peri-operative outcomes of robot-assisted partial nephrectomy? *BJU International*. 2017;**120**(4):591-599. DOI: 10.1111/bju.13901
- [13] Garisto et al. Precise clamping of renal artery with endovascular stents during robotic partial nephrectomy: Technical hints to optimize outcomes. *Urology*. 2018;**118**:239-240
- [14] Corradi RB, Vertosick EA, Nguyen DP, et al. Nephrometry scores and perioperative outcomes following robotic partial nephrectomy. *International Brazilian Journal of Urology: Official Journal of the Brazilian Society of Urology*. 2017;**43**(6):1075-1083. DOI: 10.1590/S1677-5538.IBJU.2016.0571
- [15] Kutikov A, Uzzo RG. The R.E.N.A.L. nephrometry score: A comprehensive standardized system for quantitating renal tumor size, location and depth. *The Journal of Urology*. 2009;**182**:844-853

- [16] Ficarra V, Novara G, Secco S, Macchi V, Porzionato A, De Caro R, et al. Preoperative aspects and dimensions used for an anatomical (PADUA) classification of renal tumours in patients who are candidates for nephron-sparing surgery. *European Urology*. 2009;**56**:786-793
- [17] Novara G, Falce SL, Kungulli A, et al. Robot-assisted partial nephrectomy. *International Journal of Surgery*. 2016;**36**:554-559
- [18] Shwartz MJ, Rais-Bahrami S, Kavoussi LR. Laparoscopic and robotic surgery of the kidney. In: Wein AJ, Kavoussi LR, Partin AW, Peters CA, editors. *Campbell-Walsh Urology*. 11th ed. Philadelphia, PA: Elsevier; 2016. chap 61
- [19] Walsh AJ, Kavoussi LR, Partin AW, et al. editors. *Campbell-Walsh Urology*; 11th Edition. 2016
- [20] Benjamin Pradere B, Peyronnet B, Khene Z, et al. Simplified robot-assisted partial nephrectomy: Step-by-step technique and perioperative outcomes. *Journal of Robotic Surgery*. 2018;**13**:245-251. DOI: 10.1007/s11701-018-0845-y
- [21] Kallungal GJS, Swain S, Darwiche F. Robotic partial nephrectomy with the Da Vinci Xi. *Advances in Urology*. 2016;**2016**:9675095. DOI:10.1155/2016/9675095
- [22] Kaouk JH, Khalifeh A, Hillyer S, et al. Robot-assisted laparoscopic partial nephrectomy: step-by-step contemporary technique and surgical outcomes at a single high-volume institution. *European Urology*. 2012;**62**:553-561
- [23] Kaouk JH, Khalifeh A, Hillyer S, et al. Robot-assisted laparoscopic partial nephrectomy: Step-by-step contemporary technique and surgical outcomes at a single high-volume institution. *European Urology*. 2012;**62**:553-561
- [24] Rogers CG, Singh A, Blatt A, et al. Robotic partial nephrectomy for complex renal tumors: Surgical technique. *Urology*. 2008;**53**(3):514-521. DOI: 10.1016/j.eururo.2007.09.047
- [25] Chang C, Steinberg Z, Shah A, Gundeti MS. Patient positioning and port placement for robot-assisted surgery. *Journal of Endourology*. 2014;**28**(6):631-638. DOI: 10.1089/end.2013.0733
- [26] Xia L, Zhang X, Wang X. Transperitoneal versus retroperitoneal robot-assisted partial nephrectomy: A systematic review and meta-analysis. *International Journal of Surgery*. 2016;**30**:109-115
- [27] Porreca A, D'Agostino D, Dente D, et al. Retroperitoneal approach for robot-assisted partial nephrectomy: Technique and early outcomes. *International Braz J Urol*. 2018;**44**:63-68
- [28] Ghani KR, Porter J, Mennon M, et al. Robotic retroperitoneal partial nephrectomy: A step-by-step guide. *BJU International*. 2014;**114**:311-313
- [29] Mattevi D, Luciani LG, Mantovani W, et al. Fluorescence-guided selective arterial clamping during RAPN provides better early functional outcomes based on renal scan

- compared to standard clamping. *Journal of Robotic Surgery*. 2018;**13**:391-396. DOI: 10.1007/s11701-018-0862-x
- [30] Power NE, Maschino AC, Savage C, et al. Intraoperative mannitol use does not improve long-term renal function outcomes after minimally invasive partial nephrectomy. *Urology*. 2012;**79**(4):821-825. DOI: 10.1016/j.urology.2011.11.064
- [31] Abdullah N, Rahbar H, Barod R. Use of the Satinsky clamp for hilar clamping during robotic partial nephrectomy: Indications, technique, and multi-center outcomes. *Journal of Robotic Surgery*. 2017;**11**:47-51. DOI: 10.1007/s11701-016-0611-y
- [32] Ljunberg B, Albiges L, et al. EAU Guidelines on Renal Cell Carcinoma. Renal Cell Carcinoma - Limited Update March 2018. European Association of Urology 2018. Edn. Presented at the EAU Annual Congress Copenhagen 2018. ISBN: 978-94-92671-01-1
- [33] Campbell S, Uzzo RG, et al. Renal Mass and Localized Renal Cancer: AUA Guideline. American Urological Association Education and Research, Inc®; 2017
- [34] Lane BR et al. 7-year oncological outcomes after laparoscopic and open partial nephrectomy. *The Journal of Urology*. 2010;**183**:473
- [35] Marszalek M et al. Laparoscopic and open partial nephrectomy: A matched-pair comparison of 200 patients. *European Urology*. 2009;**55**:1171
- [36] Masson-Lecomte A et al. A prospective comparison of the pathologic and surgical outcomes obtained after elective treatment of renal cell carcinoma by open or robot-assisted partial nephrectomy. *Urologic Oncology*. 2013;**31**:924
- [37] Choi JE et al. Comparison of perioperative outcomes between robotic and laparoscopic partial nephrectomy: A systematic review and meta-analysis. *European Urology*. 2015;**67**:891
- [38] Bertolo R, Autorino R, Fiori C, et al. Expanding the indications of robotic partial nephrectomy for highly complex Renal tumors: Urologists' perception of the impact of Hyperaccuracy three-dimensional reconstruction. *Journal of Laparoendoscopic & Advanced Surgical Techniques. Part A*. 2019;**29**(2):233-239. DOI: 10.1089/lap.2018.0486
- [39] Porpiglia F, Fiori C, Checcucci E, Amparore D, Bertolo R. Hyperaccuracy three-dimensional reconstruction is able to maximize the efficacy of selective clamping during robot-assisted partial nephrectomy for complex renal masses. *European Urology*. 2018;**74**(5):651-660
- [40] Mattevi D, Luciani LG, Mantovani W, et al. Fluorescence-guided selective arterial clamping during RAPN provides better early functional outcomes based on renal scan compared to standard clamping. *Journal of Robotic Surgery*. 2018;**13**:391-396. DOI: 10.1007/s11701-018-0862-x
- [41] Porpiglia F, Fiori C, Checcucci E, Amparore D, Bertolo R. The hyper-accuracy 3D reconstruction is able to maximize the efficacy of selective clamping during robot-assisted



partial nephrectomy for complex renal masses. *European Urology*. 2018;**74**:651-660.  
DOI: 10.1016/j.eururo.2017.12.027

- [42] Wake N, Bjurlin MA, Rostami P, Chandarana H, Hua WC. Three-dimensional printing and augmented reality: Enhanced precision for robotic assisted partial nephrectomy. *Urology*. 2018;**116**:227-228

IntechOpen

IntechOpen

