

# We are IntechOpen, the world's leading publisher of Open Access books Built by scientists, for scientists

6,900

Open access books available

185,000

International authors and editors

200M

Downloads

Our authors are among the

154

Countries delivered to

TOP 1%

most cited scientists

12.2%

Contributors from top 500 universities



WEB OF SCIENCE™

Selection of our books indexed in the Book Citation Index  
in Web of Science™ Core Collection (BKCI)

Interested in publishing with us?  
Contact [book.department@intechopen.com](mailto:book.department@intechopen.com)

Numbers displayed above are based on latest data collected.  
For more information visit [www.intechopen.com](http://www.intechopen.com)



# Femoroacetabular Impingement: Anatomy and Pathogenesis

*Nefiss Mouadh, Ben Maatoug Aymen, Teborbi Anis, Tekaya Asma, Ezzaouia Khelil and Bouzidi Ramzi*

## Abstract

Femoroacetabular impingement (FAI) is an often unrecognized hip disorder in young adults that can lead to early hip osteoarthritis and a decrease in sports performance. The diagnosis and treatment of this entity have rapidly evolved in recent years. Hip arthroscopy finds its place in the treatment of this conflict, and its indications are more and more frequent. The technical challenge of this operation involves a relatively long learning curve and a good knowledge of the hip anatomy in order to minimize the risk of complications and iatrogenic lesions. In addition to intra-articular structures of the hip joint, the anatomical structures that may be affected by the main and accessory arthroscopic approach are primarily the lateral femorocutaneous nerve, the lateral circumflex femoral artery, the medial circumflex femoral artery, and the circumflex superior iliac artery. A little further, 3–5 cm from the main portals, we must pay attention to the femoral nerve, the sciatic nerve, the superior gluteal nerve, the profunda femoris artery, the superficial femoral artery, and the common femoral artery. The pathogenesis of femoroacetabular impingement is not fully understood. The multifactorial origin is still relevant today. We have divided factors incriminated in the genesis of FAI into three groups.

**Keywords:** femoroacetabular, impingement, anatomy, pathogenesis, arthroscopy

## 1. Introduction

Femoroacetabular impingement (FAI) is a common cause of early hip osteoarthritis. Often underdiagnosed, this entity deserves a particular interest in orthopedic surgeons.

In some cases of FAI, the underlying structural abnormality is secondary to residual childhood hip disorders, such as Legg-Calvé-Perthes disease, slipped capital femoral epiphysis, and others. In other cases, there is no obvious history of previous hip pathology, and the impingement is referred to as primary FAI [1]. The exact description of this morphological anomaly and how it causes early hip osteoarthritis has been studied by Ganz in 2001 [2]. However, Smith Petersen and Stulberg have talked about this pathology several years before [3, 4].

Diagnosis has become easier and easier with new imaging techniques, but clinical suspicion remains essential before any exploration.

Arthroscopy is the most common surgical procedure for FAI involving acetabuloplasty, labral repair/debridement, and/or femoroplasty [5].

Nakano [6], in a systematic review published in 2017, reported a complication rate of 3.3% after hip arthroscopy, and potential complications include neurovascular injuries, chondral and labral injuries, muscle pain, and avascular necrosis of femoral head and even femoral neck fracture [6–8].

This chapter reviews the bony, muscular, and neurovascular anatomies of the hip joint with specific attention to structures of greatest relevance to FAI and hip arthroscopy.

## 2. Methods

This chapter is a descriptive study of FAI anatomy and pathogenesis.

Anatomy figures were drawn by us to explain some anatomical relationships as well as the pathogenesis of FAI. Other figures are photographs and radiographs of patients followed and treated at our university hospital.

Concerning the literature research, the data sources used in our manuscript were PubMed, MEDLINE, and ScienceDirect.

The search terms used were femoroacetabular impingement OR FAI, anatomy, pathogenesis, and hip arthroscopy.

All study types were included, including case reports and review articles. Studies referenced in the selected papers were retrieved individually.

## 3. Anatomy of FAI

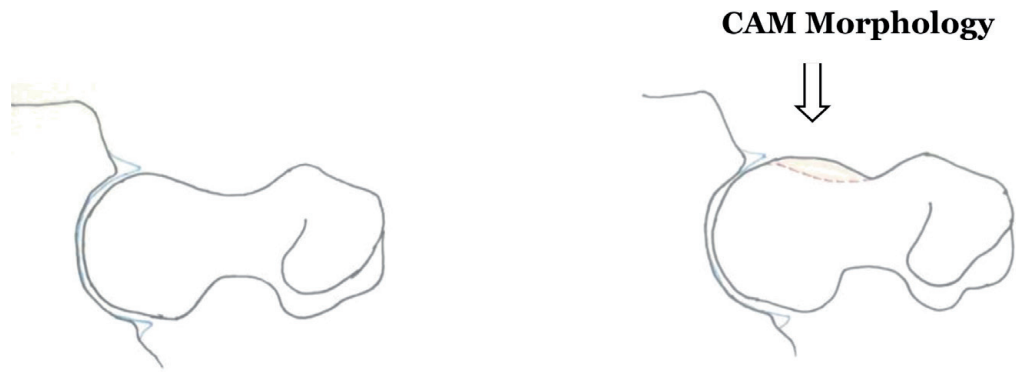The morphology of the proximal femur and acetabulum can vary significantly, which can have an important clinical relevance and impact on hip joint biomechanics. The detailed anatomy of the hip is well described in the manuals of anatomy. In FAI, two types of hip morphology have been described, namely, the cam type and the pincer type. These two types may exist separately or be associated within the same patient.

Thus, the isolated presence of either cam or pincer morphology is insufficient for a diagnosis of FAI syndrome. It is important to note that these morphologies are thought to be fairly common (around 30% of the general population) including in people without hip symptoms [9, 10].

### 3.1 Cam morphology

It describes a flattening or convexity of the femoral head neck junction [6] (Figures 1, 2).

This morphology is more common in men [10].



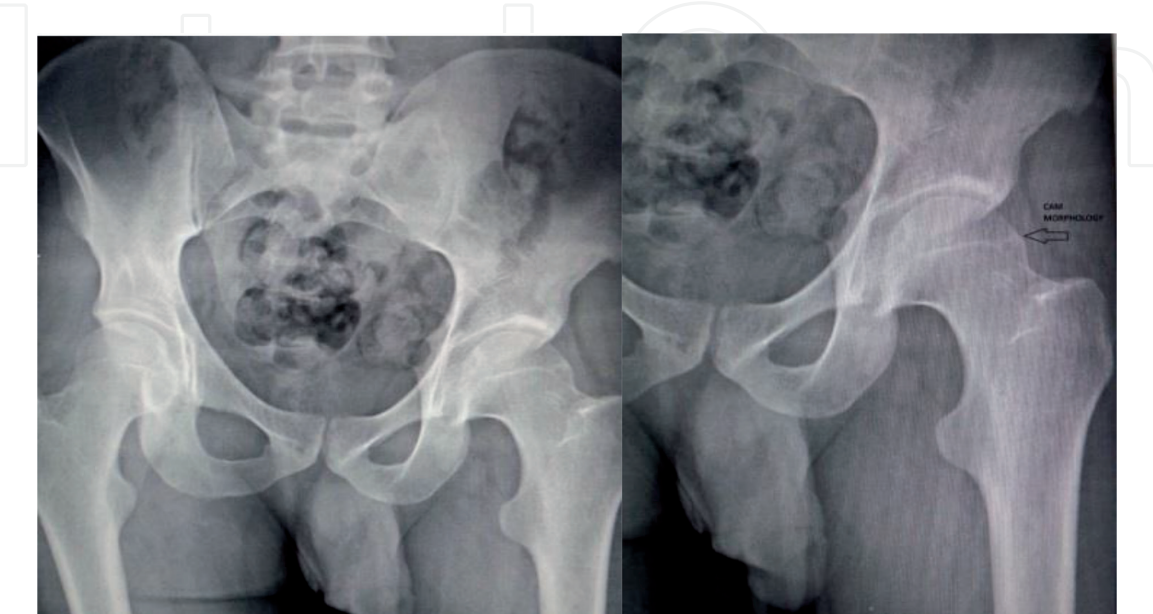**Figure 1.**  
*Normal aspect of femoral head-neck junction versus cam morphology.*

3.2 Pincer morphology

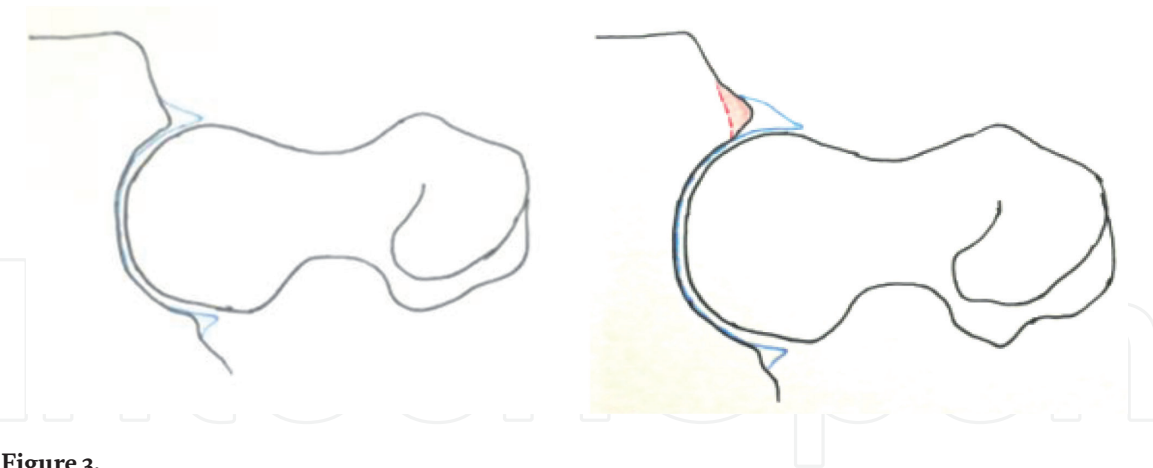
It describes the overcoverage of the femoral head by the acetabulum in which the acetabular rim is extended beyond the typical amount, either in one focal area or more generally across the acetabular rim [6] (**Figure 3**).

This morphology is more common in women [10].

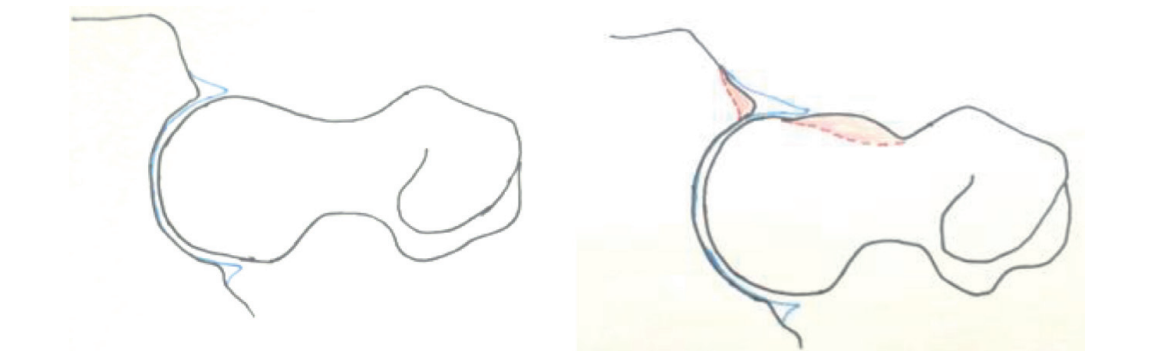
These two types (CAM and Pincer Morphology) may exist separately or be associated within the same patient (**Figure 4**).



**Figure 2.**  
*CAM morphology in a young man with a childhood hip disease.*



**Figure 3.**  
*Normal aspect of femoroacetabular junction versus Pincer morphology.*



**Figure 4.**  
*Mixed morphology with both aspects of CAM and Pincer morphology.*

Recently, several studies have shown that the prominence of the anterior-inferior iliac spine (AIIS) could also contribute to a conflict with the cervico-cephalic junction even if the hip anatomy is normal. This subspine impingement can simulate FAI and thus represents a differential diagnosis [11, 12].

### 3.3 Arthroscopic approach for FAI and anatomy of the hip

#### 3.3.1 Superficial landmarks of the hip

Given the proximity of vasculo-nervous elements, identification of a so-called safe zone is essential in such a minimally invasive surgery requiring a good knowledge of hip region anatomy (**Figure 5**).

The identification of certain structures will depend on the degree of obesity of the patient.

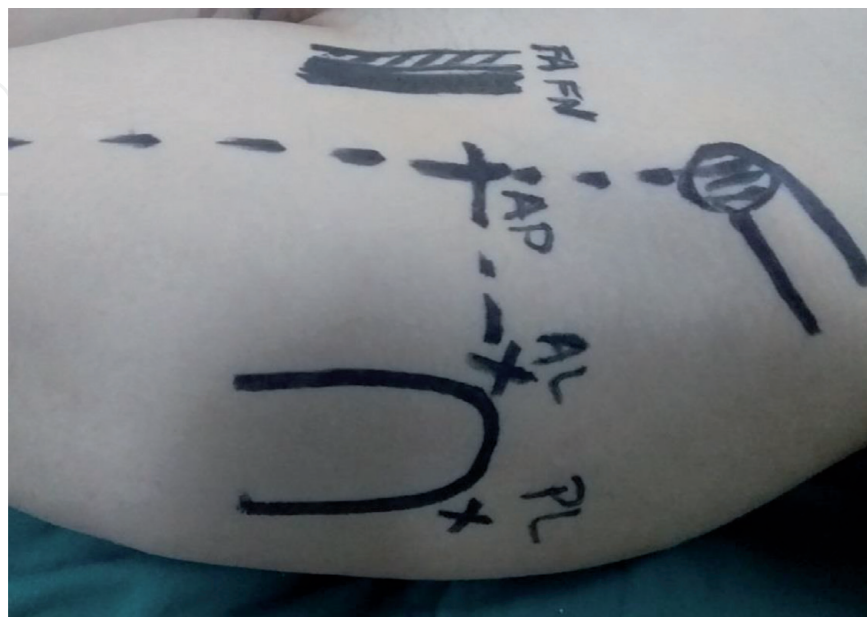
The superficial landmarks conventionally used in hip arthroscopy for an FAI are the following.

##### 3.3.1.1 The anterior-superior iliac spine (ASIS)

The hip being in neutral rotation, a vertical line joining the anterior-superficial iliac spine and the middle of the base of the patella forms the medial limit of the “safe zone.” Beyond this line there is a higher risk of femoral nerve and femoral vessel injuries [13].

##### 3.3.1.2 Great trochanter (GT)

Identification of the tip of the GT and its anterior and posterior edges is essential and easily felt. The anterolateral portal (AL) and the posterolateral portal (PL) are located 1 cm proximal and anterior or posterior to the tip of the GT, respectively. The



**Figure 5.** Landmarks and main portal used in hip arthroscopy: PL, posterolateral portal; AL, anterolateral portal; AP, anterior portal; FA, common femoral artery; FN, femoral nerve.



anterior portal (AP) is located at the intersection of a transverse line passing through the AL and PL portals and a sagittal line drawn distally from the ASIS [13, 14].

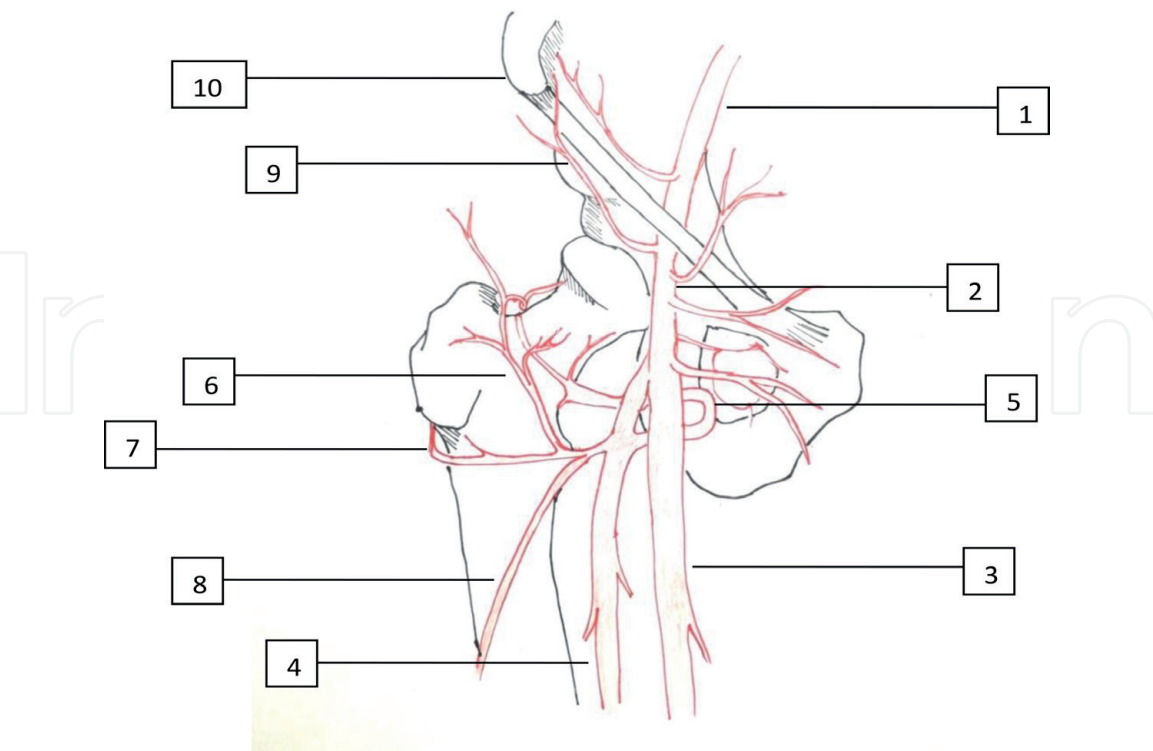
*3.3.1.3 Muscles*

The muscles crossed during hip arthroscopy for a FAI are [14, 15]:

- The AP crosses the sartorius and then the rectus femoris. A more recent interpretation of AP is described as 1 cm laterally compared to the first marker, and it crosses tensor fascia latae before intersecting the interval between the gluteus minimus and rectus femoris.
- The AL portal crosses superficially the gluteal fascia at its junction with tensor fascia latae before deepening through the fibers of the gluteus medius muscle.
- The PL portal crosses the gluteal fascia and the gluteus medius; medially to the GT, it passes anterosuperiorly to the piriformis tendon before entering the lateral capsule in its posterior aspect.

*3.3.2 Neurovascular structures*

The vascular structures that need attention in hip surgery in general and in hip arthroscopy in particular are essentially the common femoral artery (CFA) and its two terminal branches, the profunda femoris artery (PFA) and the superficial femoral artery, (SFA) as well as three lateral branches, which are the circumflex superficial iliac artery (CSIA), the lateral circumflex femoral artery (LCFA), and the medial circumflex femoral artery (MCFA) (**Figure 6**).



**Figure 6.**  
*Vessels to be considered in hip arthroscopy. (1) External iliac artery (EIA); (2) common femoral artery (CFA); (3) profunda femoris artery (PFA); (4) superior femoral artery (SFA); (5) medial circumflex femoral artery (MCFA); (6) lateral circumflex femoral artery (LCFA), ascending branch; (7) LCFA, transverse branch; (8) LCFA, descending branch; (9) circumflex superior iliac artery (CSIA); (10) anterior superior iliac spine (ASIS).*

### 3.3.2.1 The common femoral artery

It continues the external iliac artery (EIA) and lies anterior and medial to the hip capsule. Only the iliopsoas lies between the vessel and capsule at this point, and it is continued by the superficial femoral artery. The femoral vein lies medial to the artery.

### 3.3.2.2 The circumflex superior iliac artery

A collateral branch of the CFA originates from its proximal part at the level of the Scarpa triangle and goes out toward the ASIS.

### 3.3.2.3 The profunda femoris artery

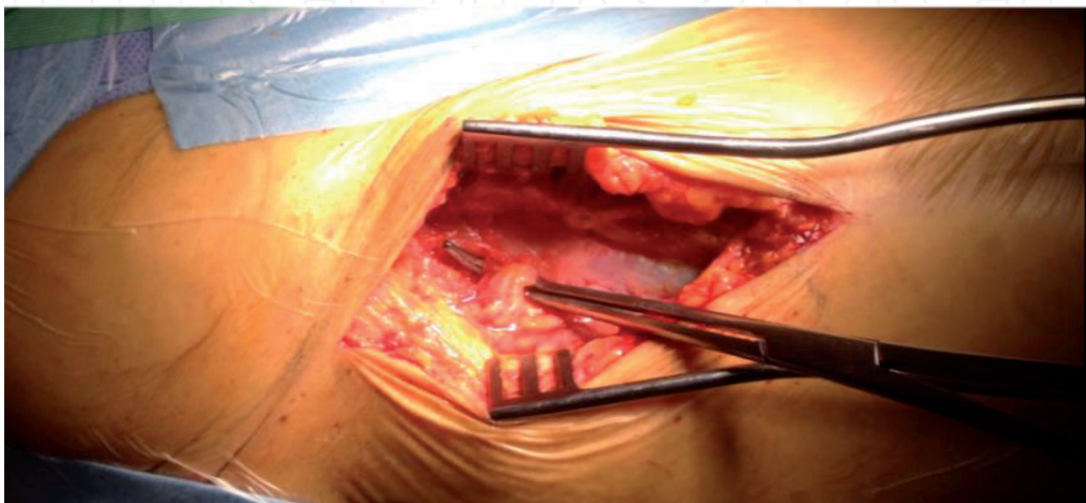
It lies medial to the SFA and continues the CFA 3 to 4 cm below the femoral triangle. It gives at the level of the hip the following collaterals.

### 3.3.2.4 The lateral circumflex femoral artery (LCFA)

It is a collateral branch of the PFA that originates from its proximal part (2–3 cm). It lies behind the sartorius and the rectus femoris and is divided into three branches:

- An ascending branch that vascularizes the GT and participates in the irrigation of the head and neck of the femur
- A transverse branch that passes through the large external muscle to anastomize with the MCFA
- A descendant branch that sometimes originates directly from the deep femoral artery and runs along the medial part of the vast outer back of the anterior right

The ascending branch of LCFA averaged 3.7 cm from the anterior portal. A terminal branch of this vessel was present in three specimens 0.3 cm from this portal [15] (**Figure 7**).



**Figure 7.**  
*Position and trajectory of the lateral circumflex femoral artery.*

3.3.2.5 The medial circumflex femoral artery (MCFA)

It is a collateral branch of the PFA that originates 1–2 cm from its proximal part, journeys medially, and then wraps itself around the femoral diaphysis to give an ascending branch and a transverse branch that anastomoses with their counterparts of the LCFA.

Nerve structures that are at risk in hip arthroscopy are the femoral (FN), the sciatic nerve (SN), the lateral femorocutaneous nerve (LFCN), and the superior gluteal nerve (SGN).

3.3.2.6 The lateral femorocutaneous nerve (LFCN)

It emerges from underneath the inguinal ligament just medial to the ASIS and courses down along the surface of the sartorius muscle.

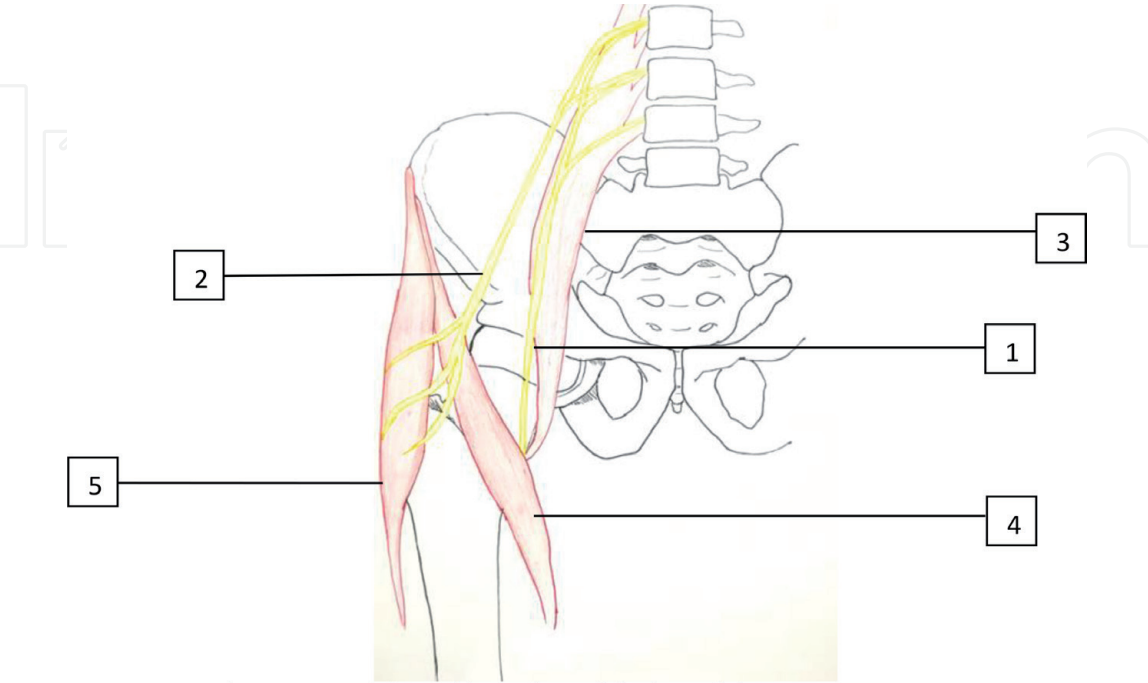
The proximal path of the nerve is relatively constant, but its branching is rather irregular, giving 0–5 branches when becoming more superficial; the most lateral of them are potentially on the course of AP (**Figures 8, 9**).

Byrd [14] in an anatomic study of portal placement and relationship to the extra-articular structures in hip arthroscopy found that the LFCN had divided into three or more branches at the level of the AP and that this portal averaged only 0.3 cm from one of these branches.

Larson and Clohisy [16, 17] in a prospective multicenter trial including 1505 hip arthroscopies and in systematic review found that the most common complication was postoperative LFCN disturbance (16.5%), which persisted beyond 6 months in only 1.6%.

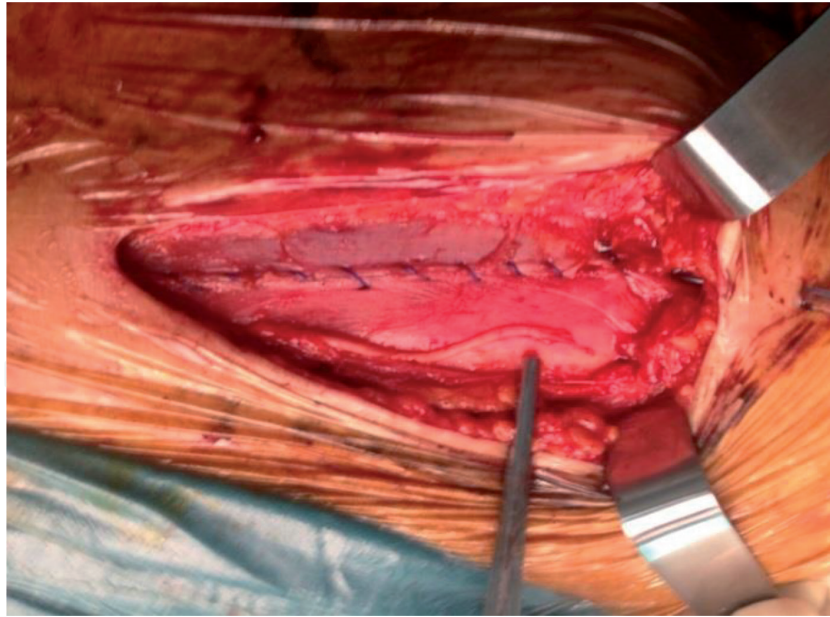
3.3.2.7 The femoral nerve

The femoral nerve is the most lateral structure within the femoral triangle. It lies on the Psoas muscle belly at the approximate midpoint between the anterior superior iliac spine and pubic tubercle.



**Figure 8.**  
Origin and branches of the lateral femorocutaneous nerve. (1) Femoral nerve; (2) lateral femorocutaneous nerve with its branch; (3) psoas muscle; (4) sartorius muscle; (5) tensor fascia latae muscle.





**Figure 9.**  
*A branch of the lateral femorocutaneous nerve accidentally cut in an anterior hip approach.*

The average minimum distance from the anterior portal to the femoral nerve was 3.2 cm [15].

#### 3.3.2.8 *The sciatic nerve*

The sciatic nerve averaged 2.9 cm from the poster lateral portal. From this study, these portal placements appear to be safe [15].

#### 3.3.2.9 *The superior gluteal nerve*

It averaged 4.4 cm superior to the anterolateral and posterolateral portals [15].

Relations of these structures with arthroscopic portals have to be assessed and topographic knowledge of the delicate anatomy surrounding the hip fully understood [14].

## 4. Pathogenesis

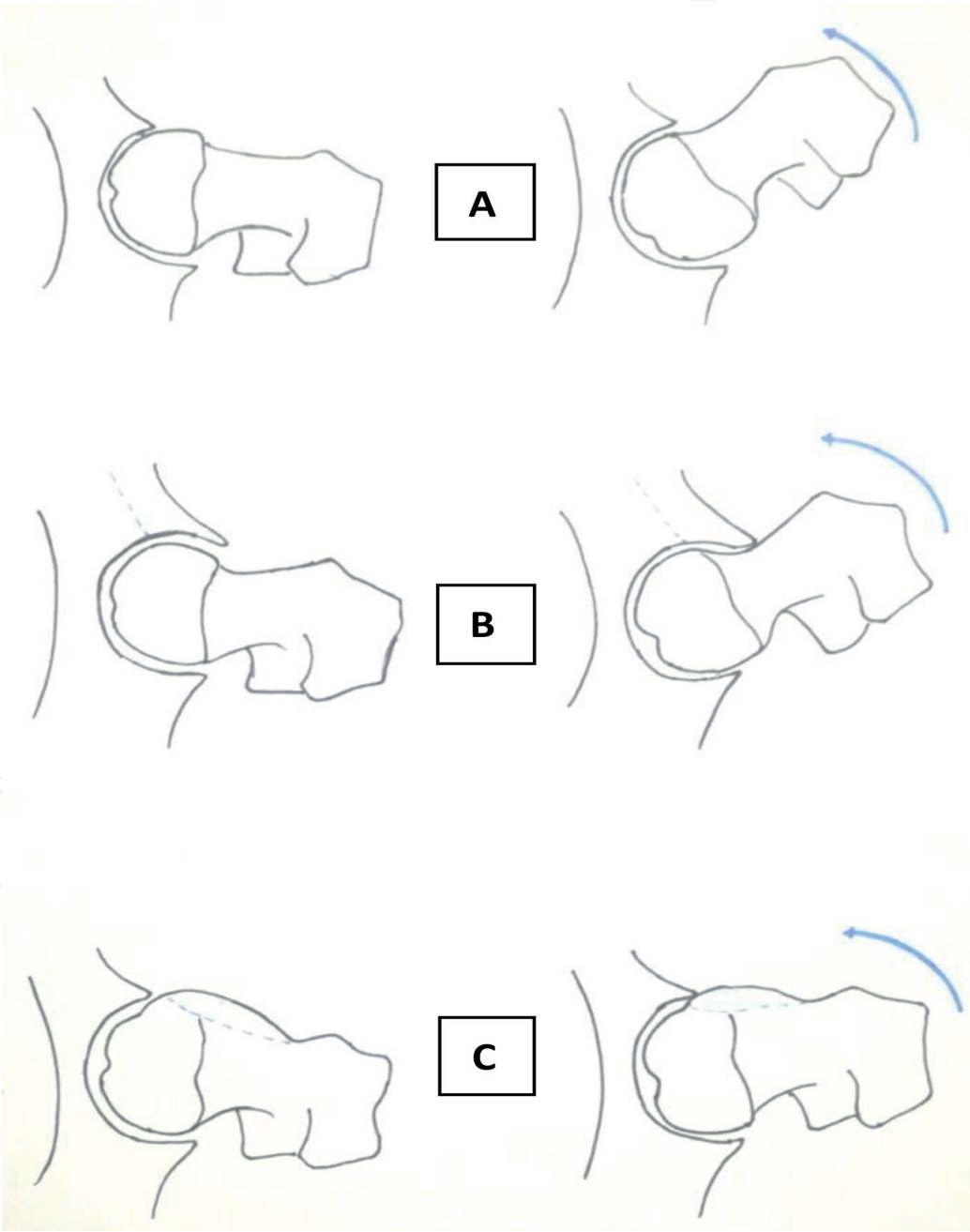
The presence of a conflict between the acetabulum and the femoral head-neck junction was noted by several surgeons as being the cause of early hip osteoarthritis (**Figure 10**); however, it was Ganz [1] who was the first to describe details of FAI pathogenesis. He defined it as a condition of abnormal contact between femoral head-neck junction and the acetabulum due to abnormal morphological features and/or as a result of subjecting the hip to the excessive and supraphysiologic range of motion.

This repetitive contact causes a microtraumatic effect and subsequently irreversible chondral damage to the acetabular as well as femoral surfaces [18].

Based on a systematic review performed by Chaudhry and Ayeni, the etiology of FAI syndrome is likely multifactorial [4].

The main factors incriminated in the genesis of FAI belong to three groups:

- Factors related to the level and type of physical activity of the patient; indeed the FAI is particularly common among young athletes requiring extreme and repetitive movement of the hip in flexion and internal rotation such as hockey and basketball.
- Morphological abnormalities such as acetabular retroversion and coxa profunda or changes in hip morphology due to the history of childhood hip disease which may have altered the shape of the femoral head-neck junction such as slipped capital femoral epiphysis (SCFE) or Legg-Calvé -Perthes disease [4].
- Iatrogenic factors such as excessive correction of hip dysplasia or following an osteosynthesis of a neck or head fracture.



**Figure 10.**  
*Pathogenesis of femoroacetabular impingement. (A) Normal morphology; (B) mechanism of impingement in pincer morphology; (C) mechanism of impingement in cam morphology.*

Given that cam and pincer morphologies can be present in asymptomatic individuals, Casartelli [19] propose that other factors out with the bony structures may be involved with FAI syndrome. Weakness of deep hip muscles could not only compromise hip stability but also lead to overload of secondary movers of the hip, thus causing an anterior glide of the femoral head into the acetabulum and increased joint loading.

5. Discussion

The hip region is an area where several noble elements pass including the femoral neurovascular bundle anteriorly, the LFCN anterolaterally, and the sciatic nerve and gluteal vessels posteriorly. Direct neurovascular injury is rare, except the LFNC; however, their proximity to portals and the effect of traction have to be considered by the surgeon especially during the learning curve.

In fact, during hip arthroscopy, a perineal post is used for countertraction and traction and is needed to provide space for instrument introduction which can lead to soft tissue injuries, and this is the most commonly reported complication of hip arthroscopy [20].

Risks and recommendation during hip arthroscopy and portals placement are detailed in **Table 1**.

	Risks	Recommendations [20]
Traction	1. Femoral and sciatic nerve neurapraxia 2. Pudendal nerve injury	1. Continuous traction should not exceed 2 hours The force of traction should be limited to <22.7 kg 2. Well-padded and wide enough perineal post
Anterior portal	1. Direct injury of the LFCN 2. Vascular injury (rare) 3. Iatrogenic labral and chondral injuries	1. Use lateralized anterior portal, and the skin incision should not extend into the subcutaneous fat 2. Optimal landmarks spotting and portal placement 3. Adequate traction ( $\geq 10$ mm) Avoid repetitive exchange of instruments
Anterolateral portal	Iatrogenic labral and chondral injuries	Optimal portal placement
Posterior portal	Inferior gluteal artery and sciatic nerve injury (rare)	Optimal portal placement Avoid internal rotation of the hip while positioning this portal

**Table 1.**  
*Risks incurred during traction and portal placement.*

6. Conclusion

FAI is explained by morphological abnormalities reaching the femoral head-neck junction or the acetabulum. Hip arthroscopy is widely used nowadays for its management.

To avoid complications of this technique, a good knowledge of hip anatomy is necessary as well as the risks incurred during its practice.

Traction and portal placement are the cause of most complications.

The lateral femorocutaneous nerve is the noble structure and the most exposed to injuries through the anterior portal. With the exception of it, direct major neurovascular injury is very rare; however, care is needed especially during the learning curve.

IntechOpen

IntechOpen

### **Author details**

Nefiss Mouadh\*, Ben Maatoug Aymen, Teborbi Anis, Tekaya Asma, Ezzaouia Khelil and Bouzidi Ramzi

Orthopedic Surgery Department, Faculty of Medicine, Mongi Slim Hospital, Tunis El Manar University, La Marsa, Tunisia

\*Address all correspondence to: [mouadhnefiss2@gmail.com](mailto:mouadhnefiss2@gmail.com)

### **IntechOpen**

© 2020 The Author(s). Licensee IntechOpen. This chapter is distributed under the terms of the Creative Commons Attribution License (<http://creativecommons.org/licenses/by/3.0>), which permits unrestricted use, distribution, and reproduction in any medium, provided the original work is properly cited. 



## References

- [1] Leunig M, Azegami S, Kamath AF, Ganz R. Femoro-acetabular impingement: Definition, etiology, pathophysiology. In: Nho S, Leunig M, Larson C, Bedi A, Kelly B, editors. *Hip Arthroscopy and Hip Joint Preservation Surgery*. New York, NY: Springer; 2015
- [2] Ganz R, Parvizi J, Beck M, Leunig M, Notzli H, Siebenrock KA. Femoroacetabular impingement: A cause for osteoarthritis of the hip. *Clinical Orthopaedics and Related Research*. 2003;**417**:112-120
- [3] Stulberg SD, Cordell LD, Harris WH, Ramsey PL, MacEwen GD. Unrecognised childhood hip disease: A major cause of idiopathic osteoarthritis of the hip. In: *Third Open Scientific Meeting of The Hip Society*. St. Louis: CV Mosby Co.; 1975. pp. 212-228
- [4] Chaudhry H, Ayeni OR. The etiology of femoroacetabular impingement: What we know and what we don't. *Sports Health*. 2014;**6**(2):157-161
- [5] Mansell NS, Rhon DI, Marchant BG, Slevin JM, Meyer JL. Two-year outcomes after arthroscopic surgery compared to physical therapy for femoroacetabular impingement: A protocol for a randomized clinical trial. *BMC Musculoskeletal Disorders*. 2016;**17**:60
- [6] Nakano N, Lisenda L, Jones TL, Loveday DT, Khanduja V. Complications following arthroscopic surgery of the hip: A systematic review of 36 761 cases. *Bone & Joint Journal*. 2017;**99-B**(12):1577-1583
- [7] Malviya A, Raza A, Jameson S, James P, Reed MR, Partington PF. Complications and survival analyses of hip arthroscopies performed in the national health service in England: A review of 6,395 cases. *Arthroscopy*. 2015;**31**(5):836-842
- [8] Harris JD, McCormick FM, Abrams GD, Gupta AK, Ellis TJ, Bach BR Jr, et al. Complications and reoperations during and after hip arthroscopy: A systematic review of 92 studies and more than 6,000 patients. *Arthroscopy*. 2013;**29**(3):589-595
- [9] Griffin DR, Dickenson EJ, O'Donnell J, Agricola R, Awan T, Beck M, et al. The Warwick Agreement on femoroacetabular impingement syndrome (FAI syndrome): An international consensus statement. *British Journal of Sports Medicine*. 2016;**50**(19):1169-1176
- [10] Raveendran R, Stiller JL, Alvarez C, Renner JB, Schwartz TA, Arden NK, et al. Population-based prevalence of multiple radiographically-defined hip morphologies: The Johnston County osteoarthritis project. *Osteoarthritis and Cartilage*. 2018;**26**(1):54-61
- [11] Hetsroni I, Larson CM, Dela Torre K, Zbeda RM, Magennis E, Kelly BT. Anterior inferior iliac spine deformity as an extra-articular source for hip impingement: A series of 10 patients treated with arthroscopic decompression. *Arthroscopy: Journal of Arthroscopic and Related Surgery*. 2012;**28**(11):1644-1653
- [12] Pan HL, Kawanabe K, Akiyama H, Goto K, Onishi E, Nakamura T. Operative treatment of hip impingement caused by hypertrophy of the anterior inferior iliac spine. *The Journal of Bone and Joint Surgery. British Volume*. 2008;**90-B**(5):677-679
- [13] Aprato A, Giachino M, Masse A. Arthroscopic approach and anatomy of the hip. *Muscle, Ligaments and Tendons Journal*. 2016;**6**(3):309-316. DOI: 10.11138/mltj/2016.6.3.309
- [14] Byrd JW, Pappas JN, Pedley MJ. Hip arthroscopy: An anatomic study of

portal placement and relationship to the extra-articular structures. *Arthroscopy*. 1995;**11**(4):418-423

[15] Robertson WJ, Kelly BT. The safe zone for hip arthroscopy: A cadaveric assessment of central, peripheral, and lateral compartment portal placement. *Arthroscopy*. 2008;**24**(9):1019-1026

[16] Larson C, Clohisy J, Beaulé P, et al. Complications after hip arthroscopy: A prospective, multicenter study using a validated grading classification. *Arthroscopy*. 2013;**29**(12 Suppl):e204

[17] Clohisy JC, St John LC, Schutz AL. Surgical treatment of femoroacetabular impingement: A systematic review of the literature. *Clinical Orthopaedics and Related Research*. 2010;**468**(2):555-564

[18] Cakic J, Patricios J. Femoroacetabular impingement: Prevention or intervention? The sports physician's quandary. *British Journal of Sports Medicine*. 2014;**48**:1073-1074

[19] Casartelli NC, Maffiuletti NA, Bizzini M, et al. The management of symptomatic femoroacetabular impingement: What is the rationale for non-surgical treatment? *British Journal of Sports Medicine*. 2016;**50**:511-512

[20] Papavasiliou AV, Bardakos NV. Complications of arthroscopic surgery of the hip. *Bone & Joint Research*. 2012;**1**:131-144