

# We are IntechOpen, the world's leading publisher of Open Access books Built by scientists, for scientists

6,900

Open access books available

185,000

International authors and editors

200M

Downloads

Our authors are among the

154

Countries delivered to

TOP 1%

most cited scientists

12.2%

Contributors from top 500 universities



WEB OF SCIENCE™

Selection of our books indexed in the Book Citation Index  
in Web of Science™ Core Collection (BKCI)

Interested in publishing with us?  
Contact [book.department@intechopen.com](mailto:book.department@intechopen.com)

Numbers displayed above are based on latest data collected.  
For more information visit [www.intechopen.com](http://www.intechopen.com)



# The Realm of Oncological Lung Surgery: From Past to Present and Future Perspectives

*Alexander Maat, Amir Hossein Sadeghi, Ad Bogers  
and Edris Mahtab*

## Abstract

In this chapter, a historical overview as well as an overview of state of the art of the surgical techniques for the treatment of lung cancer is outlined. The chapter focuses on the introduction of open surgery, video-assisted thoracic surgery (VATS), uniportal VATS (UVATS), and robotic-assisted thoracic surgery (RATS) techniques for lung resections. A short introduction on upcoming techniques and modalities is given. The currently available tools as three-dimensional (3D) computed tomography (CT), virtual reality, and endo-bronchial surgery will be discussed. Based on the current development, this chapter attempts to delineate the horizon of oncological lung surgery. The information is generated not only from the available literature, but also from the experiences of surgeons and other physicians as well as co-workers involved in lung cancer treatment around the world. This chapter can be seen as a general introduction to several aspects of oncological lung surgery.

**Keywords:** lung cancer, lung surgery, VATS, UVATS, RATS, thoracotomy, virtual reality, endo-bronchial surgery

## 1. Introduction

For centuries, the inside of the chest cavity was a no-go area for complex surgical interventions. The problems of an open pneumothorax were already known by the ancient Greek Celsus around the year 30 AD noted: “as soon as the knife really penetrates to the chest, by cutting through the transverse septum, a sort of membrane which divides the upper from the lower parts, the man loses his life at once” [1].

At that time, drainage of an empyema as described by Hippocrates (approx. 460–375 BC) was the only feasible operation [2]. The first report of a successful lung resection is attributed to Roland of Parma in 1499 who resected the herniating part of a lung, days after a penetrating chest trauma [3]. In 1846, general anesthesia with ether had been introduced by William Morton in Boston, an extremely important step in the history of surgery.

During the mid-nineteenth century, when tuberculosis reached its highest incidence, it was recognized that a state of rigidity of the mediastinum permitted an open pneumothorax. Estlander of Helsingfors was one of the first to describe wide thoracoplasty in order to “rest” a lung affected by tuberculosis (“decostalisation of the chest” in 1879) [4].

During the late nineteenth century, many experiments were carried out, mainly in animals, aimed at performing lobectomy and pneumonectomy. Usually these experiments were done in stages, the first procedure aiming at creating a state of fixation of the mediastinum. The world still was not ready yet for primary lung resections.

Further in this chapter, a historical overview and an overview of modern surgical techniques for the treatment of lung cancer are outlined. The focus is on the introduction of open surgery as well as the minimally invasive surgery. In addition, a short introduction to upcoming techniques and modalities is given.

## **2. The evolution of thoracic surgery: a journey through time**

### **2.1 The first giant steps: aseptic approach, X-ray, and positive pressure ventilation**

During the late nineteenth century, Joseph Lister, based on Louis Pasteur's theory of micro-organisms, introduced the concept of asepsis in 1867. Surgeon's hands, instruments, and surgical wounds were sterilized with 5% carbolic acid (phenol) solution and a mist of phenol was sprayed into the surgical field [5]. This policy led to an extreme reduction of post-operative mortality and for this reason, Lister is regarded as the father of modern surgery. Caroline Hampton, chief nurse and later on the wife of William Halsted, one of the founding fathers of the John's Hopkins Hospital, developed severe dermatitis due to frequent exposure to phenol and mercuric chloride. This provoked Halsted to ask the Goodyear Company to develop rubber gloves to protect the hands of the surgical team. These became available at the end of 1890 and were soon used throughout the world [6].

The aftermath of the nineteenth century saw the discovery of X-ray by William Konrad Rontgen in 1895. For the first time in mankind, it became possible to identify large tumors in the chest when not shaded by the heart and other mediastinal structures. At the turn of the twentieth century, the major barrier to enable one stage intrathoracic surgery was that of the open pneumothorax. This is remarkable since the anatomist Vesalius in 1543 had extensively studied respiration and already studied tracheotomy and positive pressure ventilation. His ideas would be dormant for about 3.5 centuries [7]. Based on this concept that there should be a pressure difference between the intra-alveolar pressure and the atmospheric pressure, Sauerbruch, still an assistant of von Mikulicz, developed the negative pressure chamber [8]—a genius idea, but quite unpractical. Only two of these operation theaters were built worldwide, one in Germany and the other one in the German Hospital (today the Lenox-Hill hospital) in New York where the surgeon Willy Meyer, emigrated to the USA from Germany in 1884, added a small positive pressure chamber over the patients head in 1909, this was called the super chamber but it was never clinically used [9]. Willy Meyer would become one of the founding fathers of the American Association for Thoracic Surgery (AATS) in 1918.

In the same year, 1909, and also in New York, Meltzer and his son-in-law Auer launched their concept of positive pressure ventilation, using a flexible silk woven tracheal catheter and a continuous stream of air mixed with ether [10]. Their concept was the birth of modern anesthesia. Recognizing that this was an enormous step forward, Meltzer was invited to become the first president of the AATS. In a speech delivered at the founding meeting of the AATS, Willy Meyers stated: "The thorax was the last fortress to be attacked and it has been laid open safely to the surgeon's knife" [9].

## 2.2 Smoking induced global lung cancer epidemic

Lung cancer was a very rare disease in the beginning of the twentieth century. In 1919, Alton Ochsner, as a medical student was invited with his whole class to witness an autopsy of a patient who died of lung cancer. The pathologist announced that no one in that class would ever again see another such case [11]. It took 17 years before Ochsner, who had become a surgeon, saw his second case, followed by 8 other cases in the 6 following months. All of these patients were male and had served as soldiers in World War I and in the line of duty they had taken up the habit of smoking, provoked by mass advertisements promoting smoking. Ochsner was amongst the first surgeons to correlate smoking to the development of lung cancer [12]. With the lung cancer epidemic which started after World War I, the number of patients with potentially resectable lung cancer increased significantly. Two major surgical items had to be settled; should a lung resection for cancer be a lobectomy or a pneumonectomy and what is the best surgical technique? Is it mass hilar ligation or anatomical dissection? The first report on lobectomy for lung cancer was that of Edward Churchill (Boston) in 1932 [13]. One year later, Evarts Graham, while intending to perform a lobectomy, was forced to perform a pneumonectomy because the tumor was very centrally located in the hilum at the origin of the left upper lobe (bronchoplastic procedures such as sleeve resection had not been developed yet) [14]. For a considerably long period, pneumonectomy was regarded as the golden standard for all lung cancer patients. Lobectomy by many was considered inferior and compared with lumpectomy without resection of loco-regional lymph nodes in breast cancer [15]. Only in 1962, a large case series between pneumonectomy and lobectomy were compared showing that lobectomy was equivalent to pneumonectomy as a cancer operation but with a lower rate of complications and mortality [16].

## 2.3 Fundamental steps in the development of state-of-the-art lung surgery

With respect to surgical technique, there was no consensus on hilar control; mass ligation or anatomical dissection and step-by-step control of the hilar structures. Cadaveric studies performed by Blades and Kent in the early 1940s pushed the world toward the latter, later supported by several publications of Boyes on the intrahilar anatomy of the lung segments [10, 17].

With this knowledge, Clement Thomas Price (London, 1947) introduced the concept of parenchyma sparing operations, having done the first anatomical segmentectomy in a lung cancer patient [18]. The first sleeve resection for bronchogenic carcinoma was performed in 1952 [19]. Consequently, it was around the mid-1950s the four main operations in lung cancer as we know today were in the armamentarium of the thoracic surgeon: pneumonectomy, lobectomy, sleeve lobectomy, and segmentectomy.

A major step forward was the introduction of double lumen endo-tracheal tube by Carlens in 1949 [20]. With this selective single lung ventilation concept, modern lung surgery is greatly facilitated, particularly, the endoscopic and robotic techniques used nowadays (discussed later in this chapter).

Diagnostic techniques were still very primitive in that era compared with today's standards. Besides standard chest X-ray, there was rigid bronchoscopy, bronchography, planography, and cytology. The concept of staging had to be developed yet. Exploratory thoracotomy in "operable patients" was performed with a very low threshold, not to lose time. Some authors reported up to 50% inoperability [21]. In the Amsterdam University Hospital between 1955 and 1960 in a series of 100

exploratory thoracotomies in patients who were found to be inoperable, 54% of patients had complications and 9 of the 100 patients died due to post-operative complications [22]. In 63% of the cases, mediastinal ingrowth or large irresectable nodes were found. In 23%, there was ingrowth in heart and/or major vessels, 12% ingrowth into the thoracic wall, 1% in growth in the diaphragm, and 1% pleural carcinomatosis. By far, mediastinal involvement was the leading cause of inoperability. In 1959, Carlens had published his experience with 100 mediastinoscopies [20]. The morbidity of this technique was 2.5% and the mortality was less than 0.5%, way better than exploratory thoracotomy. The Amsterdam team embraced mediastinoscopy and combined this in a series of operable patients with bronchoscopy and on indication diagnostic pneumothorax. Due to the mediastinoscopy findings, the resection rate in Amsterdam rose from 60 to 94% with 12% false positive mediastinoscopies [20]. Years later, in 1984, Griffith Pearson published a landmark paper showing that when positive mediastinal nodes were found, any subsequent lung resection would not cure a patient [23].

The world was waiting for methods to better identify loco-regional progression and distant metastases. Hounsfield, by combining tomography images with the calculating power of a computer, constructed the first computed tomography (CT) scanner, first for brain scans only, but in 1975 he and his team built the first whole body scanner. The computed tomography (CT) scanner was soon to be followed by the magnetic resonance imaging (MRI) scanner in 1977, while the next big step was the combination of positron emission tomography (PET) and CT scanners in 1991. The use of mediastinoscopy has declined after the introduction of ultrasound-guided examinations of the mediastinum and the hilum (endo-esophageal ultrasound (EUS) and endo-bronchial ultrasound bronchoscopy (EBUS)), but is still used on a regular base when the latter techniques fall short.

## 2.4 The rise of minimally invasive lung surgery

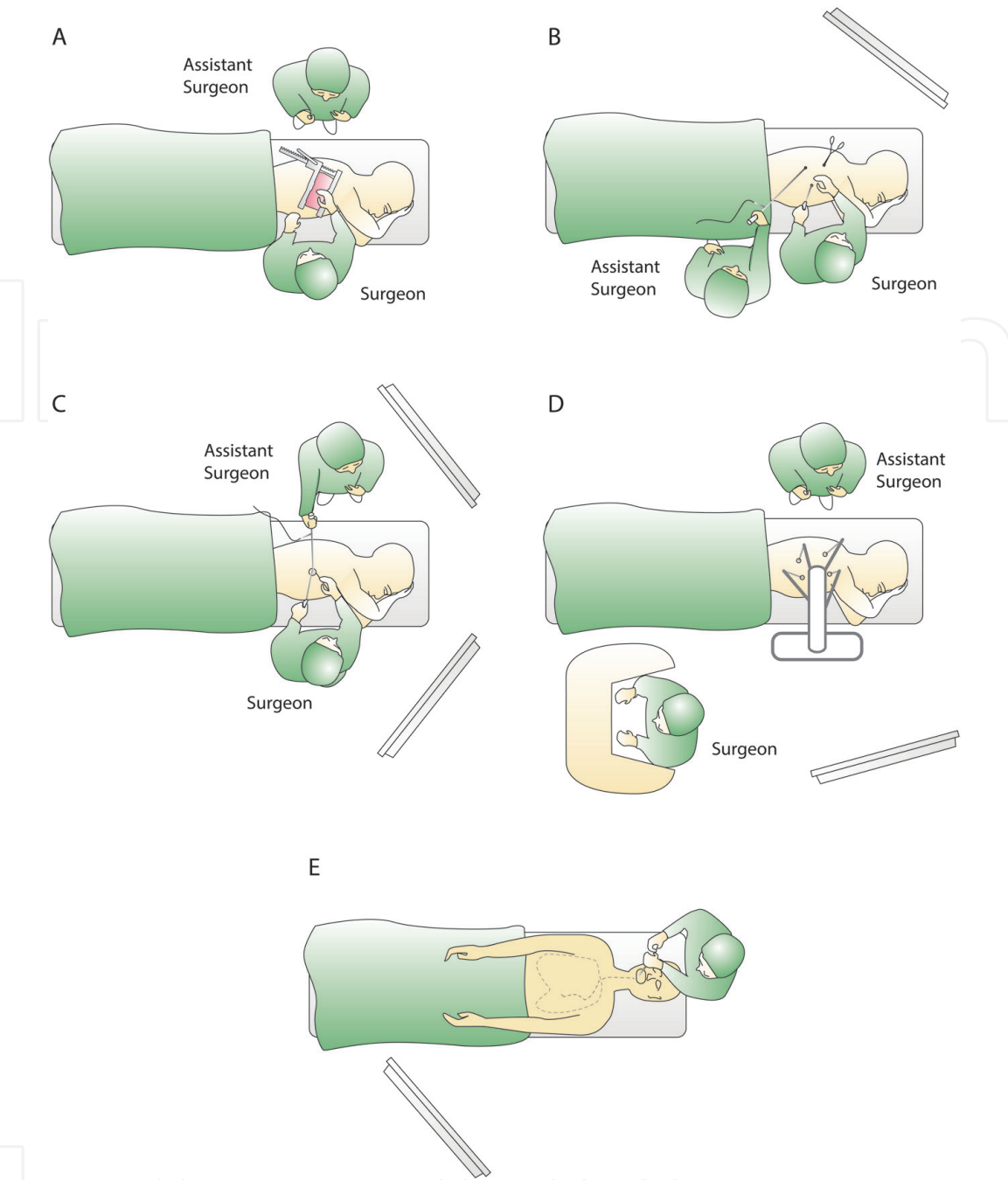
For decades, postero-lateral thoracotomy has been the preferred entrance for most lung resections (**Figure 1A**). However, the price of an excellent exposure to the lung hilum came with high percentages of long standing post-operative pain, discomfort, and functional loss.

The Swedish internist Jacobaeus is often positioned as the founding father of thoracoscopy but in fact, it was the British surgeon Francis Richard Cruse who already had published this technique in 1865 [24].

The first thoracoscopic resections were not immediately embraced by the surgical community. Ralph Lewis was the first one to publish a series of 100 lobectomies done thoracoscopically [25]. Lacking experience, tailor-made instruments, and specific endo-staplers, these resections were performed using a mass stapling technique. In Los Angeles, Robert McKenna worked out a standardized approach for video-assisted thoracic surgery (VATS) lobectomy (**Figure 1B**), working through the hilum from anterior to posterior; in 2006, he published a series of 1100 cases [26].

This provoked surgeons around the world to adapt this technique and today in many hospitals, it is the preferred approach for the majority of cases. In 2019, Eric Lim published the results of the VIOLET trial, a prospective randomized trial between VATS and thoracotomy in lung cancer patients. VATS showing to be superior with respect to major adverse events, less pain on post-operative day 2 and shorter median hospital stay with an equal oncological outcome (number of lymph nodes harvested and upstaged and R-0 resections) [27].

Studies on chronic pain (pain for which patients visit a doctor 3 months post-operative), however, did not show a major difference in pain between thoracotomy



**Figure 1.** Overview of the surgical approaches for treatment of lung cancer. (A) Postero-lateral thoracotomy, (B) 3 ports, video-assisted thoracic surgery (VATS), (C) uniportal video-assisted thoracic surgery (UVATS), (D) robotic-assisted thoracic surgery (RATS), and (E) endo-bronchial surgery.

patients and VATS patients 3–6 months post-operatively [28]. Chronic pain after VATS is often contributed to the insult of multiple intercostal nerves by trocars and instruments. It has to be seen whether the explanation is that simple, however, it moved surgeons to search for even less invasive methods, eventually leading to the concept of uniportal VATS (UVATS), first proposed by Rocco in 2004 [29] (Figure 1C).

There is still no proof that an UVATS approach leads to less pain, discomfort, and loss of functionality compared with multiple port VATS. With the idea of intercostal nerve damage in mind, surgeons have also explored other VATS-assisted intrathoracic pathways like subxiphoid and cervical approaches [30, 31]. Others are exploring a hybrid approach, combining 5 mm intercostal ports with a subxiphoid approach [32].

Almost parallel with the introduction and evolution of VATS, the world saw the introduction of robotic-assisted thoracic surgery (RATS), first published by Franca Melfi and her team [33] (**Figure 1D**).

Up till now, no significant differences have been shown in complications and outcome between VATS, UVATS, and RATS [34]. The major reason that the introduction of RATS lagged behind in many institutions is a financial reason; it is not cost-efficient. In the meantime, VATS has evolutionized to three-dimensional VATS (3D VATS) and robotic-like instruments have become available for laparoscopic and VATS procedures.

#### *2.4.1 Sub-lobar resection: the rise of segmentectomy*

During the last decade, there is a growing interest in lung parenchyma-sparing resections. This need is more highlighted by the results of the two largest population based national screening studies (NLST, 2011 and NELSON, 2018) showing that discovery and resection of early stage lung cancer through screening programs lead to significantly better survival of patients [35, 36]. The NLST study showed a reduction of 20% in lung cancer mortality for annual screening over 3 years with low-dose CT with a greater benefit for screening in women. The NELSON study showed for screening with low-dose CT, a 26% reduction of lung cancer mortality in high-risk men and up to 61% reduction of lung cancer mortality in high-risk women over a 10-year period. Nowadays, there is a trend toward sub-lobar resection as segmentectomy, making the oncological lung surgery even more challenging. Moreover, this makes the role of peri-operative diagnostic tools as fluorescent indocyanine green (ICG) [37], 3D-CT modalities, and (navigational) bronchoscopy interventions (next section, **Figure 1E**) indispensable. Because of its anatomical complexity, many surgeons hesitate to perform segmentectomy. For this reason, in 2012, Hiroaki Nomori and Morihito Okada published the book “Illustrated Anatomical Segmentectomy for Lung Cancer” which is an essential book for surgeons starting a segmentectomy program at their centers. In 2019, segmentectomy is mostly performed in countries of Eastern Asia, such as Japan, followed by few centers in the USA and Western Europe.

### **3. Advances in thoracic imaging facilitating minimally invasive lung surgery: a brief outlook into the future**

Over the past few decades, imaging modalities such as CT, PET-CT, and standard chest X-ray imaging have played a key role in the non-invasive diagnostic work-up of thoracic disease. In addition, these imaging modalities are an essential part of the preoperative planning process of thoracic surgical procedures. Even though there is a broad range of clinical indications for various thoracic imaging modalities and the information provided by all different modalities is different, the purpose of this section is not to undertake a comprehensive evaluation of the characteristics of these imaging modalities. Specifically, this section will focus on innovative preoperative and intraoperative imaging modalities as a surgical planning and navigation tools and provide a brief overview of new developments in medical imaging, especially in the context of (oncologic) pulmonary resections.

#### **3.1 Three-dimensional computed tomography (3D-CT)**

In the setting of oncologic thoracic surgery, a standard chest CT scan can be used to evaluate the extensiveness of disease in terms of pleural, mediastinal, chest

wall, or vascular involvement. In addition, the CT scan is used to study the surgical anatomy of the pulmonary artery (and its major branches), pulmonary vein, and bronchial structures when a resection of the lung parenchyma is planned. Due to the establishment and development of more modern multislice CT scanners, it has become easier to detect smaller peripheral tumors. While this has enabled more diagnostic accuracy, it has resulted in an increased clinical use of sublobar anatomic resections. Specifically, in the setting of anatomic segmental pulmonary resections, which are technically and anatomically more demanding and complex, there is a need for more accurate imaging modalities that enables better preoperative knowledge of the surgical anatomy (such as bronchial and vascular anatomy in sublobar/segmental levels). Recently, an increasing number of scientific reports have been published on the use of preoperative three-dimensional (3D)-CT reconstruction as a surgical planning tool before anatomic resection of pulmonary segments or lobes [38–42]. According to some of these studies, the preoperative use of 3D-CT reconstructed images is feasible and safe and, in some cases, associated with shorter operative time due to better preoperative understanding of surgical anatomy [38, 42]. In order to obtain 3D-CT image reconstructions, different methods are described and various (free open-source) software packets are available [42–44]. However, there are also limitations regarding the utility of software to reconstruct 3D images of CT scans. For example, the identification and separation of the pulmonary artery and vein may be a challenging and time-consuming process. Moreover, in some cases, a contrast-enhanced CT scan is required to create 3D-simulations, which increases the risks of radiation exposure. In addition, the reconstruction commonly requires technical support and the assistance of radiology and information and communication technology (ICT) experts.

Oizumi et al. reported a study on the use of 3D reconstruction of multidetector CT (MDCT) images in order to plan and guide pulmonary segmentectomy preoperatively and during surgery [38]. It was noted that after the introduction of 3D-CT reconstruction, the number of (fairly) difficult classified segmentectomies that have been performed increased significantly, suggesting that preoperative 3D-CT simulation contributes fairly to the efficacy of surgical planning of complex segmentectomies. In addition, in a retrospective analysis of patients undergoing thoroscopic segmentectomy reported by Xue et al., the authors found that when preoperative 3D-CT reconstruction was used to make operation plans, in 19% of the cases, the operation plan was changed due to the results of 3D simulation [42]. The original surgical plan of these cases was changed due to the expectation of an inadequate resection margin distance, based on pre-operative simulation results. This indicates that preoperative 3D simulation not only contributes to technical feasibility and efficacy of surgery, but also to the decision-making process from an oncological point of view.

Even though an increasing number of studies on the use of 3D-CT simulation are being published, the majority of them do not report on the differences in parameters of clinical outcome (such as perioperative blood loss, post-operative stay, and conversion rates to thoracotomy) but focus more on technical aspects and feasibility of 3D-simulation and surgery. However, the majority of reports do recognize the following advantages of preoperative 3D-simulation in the context of (sub-)lobar pulmonary resection: (1) classification and identification of anatomical (vascular and bronchial) abnormalities; (2) identification of unsuitable surgical cases for segmentectomy; (3) training of less experienced thoracic surgeons and surgical residents; (4) preoperative estimation of proper surgical resection margin; (5) a step-wise preoperative surgical planning; and (6) intraoperative navigation for identification of anatomical structures [38, 40–42].

3D-CT-mediated preoperative surgical planning and intraoperative guidance of (oncological) pulmonary surgery could contribute significantly to the development

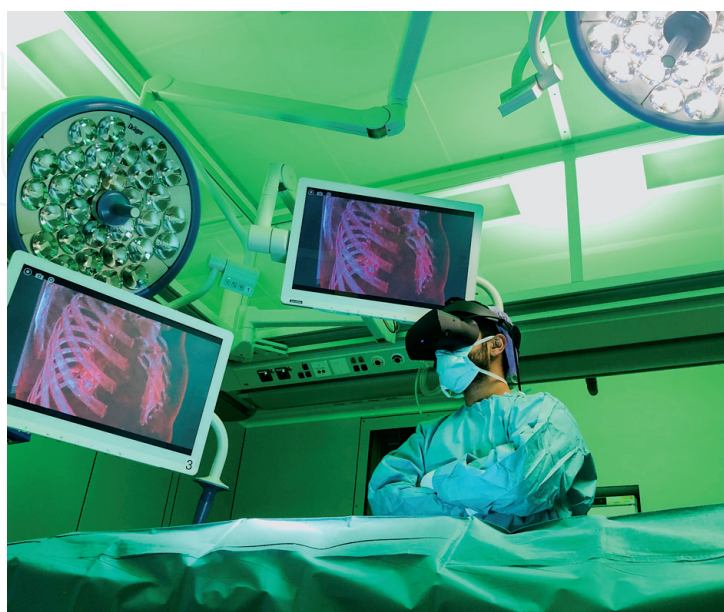of more accurate and safer (sublobar) anatomic resections. In the near future, this technology will become more common in thoracic surgery. However, in order to reach that stage, some (mostly technical) limitations need to be overcome.

### 3.2 Virtual reality, augmented reality, and mixed reality

Virtual reality (VR) is a technology that enables users to interact with a computer-generated virtual 3D interface (**Figure 2**). More interestingly, in augmented reality (AR), the user is able to overlay aspects of the VR world within the real physical world. Finally, mixed reality (MR) allows users to create a hybrid physical and virtual world and offers the possibility to interact and analyze objects in the physical world by virtual projections [45, 46].

Recently, surgical intraoperative navigation as well as preoperative surgical simulation based on VR, MR, and AR have been developed and successfully used in various surgical fields including neurosurgery, liver surgery, kidney surgery, and orthopedic surgery [47–51]. In contrast to 2D interfaces (e.g. conventional CT scans), VR, MR, and AR enable not only visualization of anatomical structures but also allow interactive manipulation of the digital information (e.g. anatomic structures) provided by (wearable) computer-integrated devices (such as the Microsoft HoloLens or the Google Glass). It has been suggested that these new interfaces might have the potential to benefit both the surgeon and the patient. For surgeons, this benefit comes by the way of improved preoperative surgical planning, better and more accurate intraoperative imaging guidance, and a better preoperative awareness of anatomical abnormalities. Patients will potentially benefit from shorter operative time, shorter length of hospital stay, and improved outcomes. Additionally, AR, VR, and MR offer the possibility to simulate surgical situations as well as facilitating training for surgeons and residents. In the field of thoracic surgery, some of these modalities have been used over the past few years in order to train surgical residents and surgeons to master the techniques necessary for minimally invasive lung surgery [52].

However, only very few reports are available on the use of AR, VR, or MR for surgical planning or intraoperative navigation for lung surgery [53–55]. Frajhof



**Figure 2.**  
*An example of virtual reality application during minimally invasive lung cancer surgery in the operating theater.*

et al. recently published a study on the use of AR, VR, and MR technology in the preoperative planning of a technically demanding VATS left upper lobectomy [53]. In another study from Rouzé et al., augmented reality was used as a navigation tool in combination with cone beam CT (CBCT) to guide intraoperative localization of pulmonary nodules for wedge resection through VATS. The investigators firstly localized the lesions by CBCT intraoperatively. Subsequently, a 3D reconstruction of the nodule was created by using software. After this, an augmented fluoroscopic 3D image of the pulmonary nodule was projected on a screen in front of the operating table. By this, the surgeon was able to localize the lesion intraoperatively and perform a wedge resection safely [54].

Interestingly, also some reports are available on the use of VR 3D reconstruction of the airways, known as virtual bronchoscopy, specifically used as a diagnostic aid tool in the assessment of airway masses and stenosis [56, 57]. Virtual bronchoscopy contributes fairly to the diagnostic process since it enables diagnostic maneuvers, such as assessing bronchial anatomy distally from stenoses, which are not possible with standard flexible bronchoscopy. Moreover, virtual bronchoscopy is a noninvasive method and does not bear any additional risks (e.g. radiation exposure or iatrogenic airway damage) for patients. Despite these advantages, virtual bronchoscopy is not expected to completely replace flexible bronchoscopy due to some limitations. For example, tumor boundaries can be misjudged by intrabronchial secretions that might lead to a false-positive result. Moreover, it has shown not to be sensitive and effective enough for detecting small mucosal abnormalities (e.g. erythema and erosion), dynamic stenoses (caused by, for example, the respiratory cycle or vocal cords), and in differentiating mucus plugs from a mass. Finally, virtual bronchoscopy has the limitation that it does not enable biopsies.

#### **4. Advances in the armamentarium of (the endo-bronchial) lung cancer surgery**

In the past two decades, there has been an increase in the development of innovative technologies to facilitate more accurate, efficient, and safe (minimally invasive) thoracic interventions. Specifically, there have been some reports on the progress of innovative therapeutic modalities that approach lung cancer through other minimally invasive methods than direct surgery. Examples of these therapeutic options are thermal ablation, including radiofrequency ablation (RFA), microwave ablation (MWA), and cryoablation of malignant lung lesions. This section will touch on some of these developments and review some outcomes of thermal ablation therapy.

##### **4.1 Thermal ablation therapy**

###### *4.1.1 Radiofrequency ablation (RFA)*

Amongst various thermal ablation therapies, RFA is a well-studied method, especially in the treatment of liver cancer [58, 59]. Due to favorable outcomes in the treatment of liver cancer, specifically hepatocellular carcinoma, the application of this technology to malignant lesions in other organs, including the lungs, has been growing. RFA involves the insertion of a probe inside the affected target tissue. The electrode on the probe generates frictional heat that creates coagulation necrosis of the surrounding (tumor) lung parenchyma. In pulmonary surgery, the use of RFA has been reported in the treatment of various malignant lesions including

inoperable lung cancer [60–62], primary or metastatic pulmonary tumors of less than 3.5 cm in size [63], and stage I-4 non-small cellular lung cancer (NSCLC) not eligible for surgery [64–67]. Results from retrospective studies on RFA of primary malignant lung lesions have suggested reasonable overall 1-year survival rates ranging from 78 to 94% in patients with early stage lung cancer [66, 68–70]. A 5-year survival rates have been reported to be significantly lower and in the range of 25–58% [66, 71, 72]. Important prognostic factors in RFA therapy of lung cancer, in terms of survival, are the additional use of targeted systemic therapies, lesions less than 3 cm (diameter), a Charlson comorbidity index (an index of associated comorbidities) >5, and lower stage disease [66, 73].

A major drawback of RFA therapy compared with surgical resection is the poor results of local progression control [74]. This limitation might be explained by the fact that in RFA therapy no systematic lymph node dissection is carried out and, additionally, no good method exists to check for local adequate treatment margins. With regard to complications, pneumothorax is one of the most common complications associated with RFA. However, it is most often (>80%) treated conservatively without the need for chest tube drainage [75]. In addition, pleural effusion might develop after RFA, however, similar to pneumothorax, does not often (<5%) require intervention [75]. In summary, RFA therapy seems an effective and relatively safe intervention for treating lung cancer, however, a careful patient selection is necessary. Moreover, more future long-term and large randomized controlled trials are necessary to compare the clinical outcomes between RFA, surgical resection, and other modalities of thermal ablation therapy.

#### 4.1.2 Microwave ablation (MWA)

MWA involves hyperthermia-mediated ablation of tissue by causing friction between water molecules in the target tissue. By creating a dipole excitation, hyperthermia is generated and coagulation necrosis results in the lesion and surrounding tissue [76, 77]. The placement of the probes is commonly guided by CT/CT-fluoroscopy. MWA has been successfully used to create larger ablation zones than RFA. Compared with RFA, MWA technology is thought to be more effective in creating larger zones of coagulation necrosis due to the elimination of heat loss through heat sink (the loss of heat through blood flow inside the target tissue) [76].

Studies and long-term data after MWA as a thermal ablation modality are limited when compared with RFA. In a recent review, Yuan and colleagues reported a meta-analysis of clinical outcomes after RFA and MWA for primary and metastatic pulmonary malignancies [75]. The authors identified 11 studies based on MWA compared with 42 studies based on RFA therapy, all with a retrospective study design. In this meta-analysis, it was demonstrated that RFA seems to be superior to MWA with regard to overall survival (up to 5 years) for both primary and metastatic pulmonary malignancies. However, the authors note that the results of lung metastasis should be interpreted carefully, since small groups of patients were included in the analysis based on only a few retrospective studies. With regard to local tumor progression free survival, RFA and MWA showed similar results. In addition, similar to RFA, MWA is a relatively safe intervention which is not associated with high complication rates. Yuan et al. reported comparable rates of pneumothorax and pleural effusion after ablation by MWA and RFA [75]. Concerning prognostic factors negatively affecting survival and local tumor progression control, more advanced disease stage, tumors >3 cm (diameter), and emphysematous lungs have been identified [78].

#### 4.1.3 Cryoablation

An opposite method of hyperthermia induced ablation, termed cryoablation, creates protein denaturation, ischemia, cell rupture, and necrosis through local hypothermia (temperatures  $< -40^{\circ}\text{C}$ ) [79]. In this technique, compressed argon gas is used to create freezing temperatures that induce local injury to the tissue. Subsequently, helium is used to thaw the tissue. Comparable to MWA, in cryoablation, multiple probes can be used to increase the ablation area in the tissue and placement under the guidance of CT/CT-fluoroscopy. Although cryosurgery is a relatively old ablative technique, use of cryoablation in the context of lung cancer and long-term studies are limited. Besides percutaneous cryoablation, other methods of cryoablative strategies are endo-bronchial (for obstructive intrabronchial tumors) (**Figure 1E**) and intrathoracic (during surgery). Specific indications for each modality have been reviewed by Niu and colleagues and are beyond the scope of this chapter [80].

Since thermal ablation therapies are commonly reserved for patients not eligible for curative surgery, tumor recurrence after radiotherapy or patients who refuse surgery, even though they have resectable lesions, cryoablation is often offered as a therapy to palliate symptoms or to increase survival in advanced disease stage. Consequently, a number of reports have been published on the use of cryoablation for the treatment of medically inoperable NSCLC, advanced stages of NSCLC, and for pulmonary metastasis [80–84]. Niu et al. reported on a series of 840 patients with NSCLC who received percutaneous cryoablative therapy for various stages of NSCLC ranging from IIa to IV. The reported overall survival was 68, 52, 34, 26, and 17% for 1-, 2-, 3-, 4-, and 5-year, respectively. Local and peripheral recurrence rates were 28.3 and 47.2%, respectively, after a median follow-up of 34 months (range 4–63 months). For patients with less advanced NSCLC, better outcome is reported in terms of overall survival. In 2012, Yamauchi et al. demonstrated a 2-year overall survival of 88% in medically inoperable patients with stage I NSCLC who were treated with percutaneous cryoablation [84]. In addition, Moore and colleagues published a study in which an overall survival rate of 67.8% was reported in patients with stage I NSCLC after 5 years [82].

Regarding cryoablation therapy in metastatic lung lesions, studies have also proven the efficacy and safety of percutaneous cryoablation. For example, Yamauchi et al. reported a 3-year progression free survival rate of 59% for patients with metastatic colorectal carcinoma treated with cryoablation [85]. Factors associated with local tumor progression or poor prognosis have been studied by multivariate analyses. Interestingly, most of these factors (e.g. tumor size  $<3$  cm and stage of disease) are comparable to the factors in other modalities of thermal ablation [78, 80]. Regarding the safety profile of cryoablation compared with other modalities of thermal ablation, comparable rates of pneumothorax and pleural effusion are reported in the literature [77, 80]. However, incidental reports of transient recurrent laryngeal nerve neuropraxia have also been documented [86].

## 5. Conclusions

Until the late nineteenth century, the inside of the chest cavity was a no-go area for complex surgical interventions. The world still was not ready yet for primary lung resections. To make the lung surgery possible, several giant steps were undertaken: the introduction of aseptic concept by Joseph Lister in 1867, the discovery of X-ray by William Konrad Rontgen in 1895, and the introduction of positive pressure ventilation

by Meltzer and Auer in 1909. With the lung cancer epidemic after World War I, the number of patients with potentially resectable lung cancer increased significantly. Surgeons around the world were debating on the preferable resection (lobectomy vs. pneumonectomy) and the best surgical technique: mass hilar ligation versus anatomical dissection. While the first report on lobectomy for lung cancer in 1932, it took almost 30 years to report that lobectomy was the preferred resection for lung cancer surgery. In the same period, the anatomical dissection technique gained wider application. This all together with the discovery of double lumen endo-tracheal tube by Carlens in 1949 paved the way for modern lung resection techniques. The introduction of diagnostic tools as CT, MRI, PET-CT, and later EUS and EBUS facilitated even better tumor localization and mediastinal evaluation decreasing the surgical mortality.

The next major challenge was decreasing the morbidity of thoracotomy: high percentages of long standing post-operative pain, discomfort, and functional loss. The solution led to the development of modern minimally invasive lung surgery. In 2006, Robert McKenna published a standardized approach for VATS lobectomy in a series of 1100 cases leading to global adaptation of VATS for lung surgery. While VATS showing to be superior with respect to major adverse events, less pain on post-operative day 2 and shorter median hospital stay with an equal oncological outcome, studies on chronic pain, however, did not show a major difference in pain between thoracotomy and VATS. This moved surgeons to search for even less invasive methods, eventually leading to the concept of uniportal VATS, first proposed by Rocco in 2004, subxiphoid and cervical approaches, and hybrid approach combining 5 mm intercostal ports with a subxiphoid approach. At the same time, the world witnessed the introduction of RATS by Franca Melfi and her team, however, because of the financial reasons, the introduction of RATS in many centers lagged behind. In the meantime, VATS has evolutionized to 3D-VATS and robotic like instruments have become available for laparoscopic and VATS procedures. Whether all these approaches will lead to reduction of chronic pain is yet to be determined.

The results of major screening programs have shifted the trend of lung resection toward sub-lobar resection as segmentectomy, making the lung surgery even more challenging. Moreover, this makes the role of peri-operative imaging tools as fluorescent indocyanine green (ICG), 3D-CT modalities, and (navigational) bronchoscopy interventions indispensable.

The upcoming VR, AR, and MR enable a more naturalistic 3D presentation of human anatomy in a digital interface. As a diagnostic tool, it can provide physicians with a more realistic view of the patient's anatomy and might enable diagnostic assessment, preoperative surgical planning, and intraoperative guidance. In addition, it can provide training and learning platform for students, residents, and surgeons. It has already proven its added value for a broad range of surgical procedures; however, AR/VR/MR has not been used widely in thoracic surgery yet. Considering the speed of development of this technology in other areas, it is expected that it will make its way into the world of thoracic surgery in the near future. In this perspective, hybrid operating theaters including 3D-CT and (robotic-assisted) navigational bronchoscopy tools are already on their way. To address this, however, it is essential that thoracic surgeons have an active and open attitude toward the introduction of innovative (digital) applications.

With respect to endo-bronchial interventions, thermal ablation therapy seems to provide an efficacious and safe alternative for surgical therapy of lung cancer and lung cancer metastasis. However, patient's selection should be carried out with caution and should be personalized for each patient based on type of cancer (e.g. NSCLC), comorbidities, tumor size, and disease stage. Specifically, thermal ablation therapy could offer a palliative or even a life-prolonging treatment option for non-surgical candidates. Hopefully future long-term and larger prospective

(randomized controlled) trials will answer the remaining questions. For example, it will be necessary to study the impact of combining thermal ablation therapy with other conventional (e.g. systemic or radiotherapy) therapies for the treatment of lung cancer. In addition, more data are warranted on the determination of the best therapy for incomplete ablations and/or local recurrence of disease. More interestingly, biomarkers or novel imaging techniques to follow-up on ablative therapies are also required, especially since the radiological follow-up of recently ablated lung tissue is very challenging. More data and confirmation of these data are therefore necessary and need to be generated by future multicenter trials.

To conclude, this chapter provides a historical overview and a summary of state-of-the-art surgical techniques in the treatment of lung cancer today. The journey of lung surgery was and is a very challenging one, with major hurdles to overcome. It departed from a “no-go” era, leaving behind the golden standard of pneumonectomy and thoracotomy, to arrive in the current era of minimally invasive and robotic-assisted surgery. The journey continues toward the horizon of non-intubated operations, sub-lobar resections, virtual reality imaging modalities, navigational bronchoscopy interventions, and hybrid procedures. We are heading toward the era of incisionless, natural orifice surgery: an almost science fiction vision, yet nothing is more real.

### Acknowledgements

The contribution of Egied Simons (Simons Productions, Mathenesserdijk 236A, 3026 GL, Rotterdam, The Netherlands) and Chris Hordijk (Medical VR, van Eeghenstraat 98, 1071JL, Amsterdam, The Netherlands) in generating the figures is highly appreciated. We would like to thank Dr. F. Incekara (Departments of Neurosurgery and Radiology, Erasmus Medical Center, Rotterdam, The Netherlands) for his helpful advice.

### Abbreviations

VATS	video-assisted thoracic surgery
UVATS	uniportal video-assisted thoracic surgery
RATS	robotic-assisted thoracic surgery
3D	three-dimensional
CT	computed tomography scanner
AATS	American Association for Thoracic Surgery
MRI	magnetic resonance imaging scanner
PET	positron emission tomography
EUS	endo-esophageal ultrasound
EBUS	endo-bronchial ultrasound bronchoscopy
ICG	indocyanine green
ICT	information and communication technology
MDCT	multidetector computed tomography
VR	virtual reality
AR	augmented reality
MR	mixed reality
CBCT	cone beam computed tomography
RFA	radiofrequency ablation
MWA	microwave ablation
NSCLC	non-small cellular lung cancer

IntechOpen

IntechOpen

### **Author details**

Alexander Maat, Amir Hossein Sadeghi, Ad Bogers and Edris Mahtab\*  
Department of Cardio-thoracic Surgery, Erasmus Medical Centre, Erasmus  
University, Rotterdam, The Netherlands

\*Address all correspondence to: e.mahtab@erasmusmc.nl

### **IntechOpen**

© 2019 The Author(s). Licensee IntechOpen. This chapter is distributed under the terms of the Creative Commons Attribution License (<http://creativecommons.org/licenses/by/3.0>), which permits unrestricted use, distribution, and reproduction in any medium, provided the original work is properly cited. 

## References

- [1] Celsus A. *De Medicina*, with an English Translation by W. G. Spencer. 3 Vols. Cambridge: Harvard University Press; 1935-38
- [2] Christopoulou-Aletra H, Papavramidou N. "Empyemas" of the thoracic cavity in the Hippocratic corpus. *The Annals of Thoracic Surgery*. 2008;**85**(3):1132-1134
- [3] Walcott-Sapp S. The History of Pulmonary Lobectomy: Two Phases of Innovation. CTSNet. 2016. Available from: <https://www.ctsnet.org/article/history-pulmonary-lobectomy-two-phases-innovation>
- [4] Estlander JA. Résection des côtes dans l'empyème chronique. *Revista medico-chirurgica a Societati de Medici si Naturalisti din Iasi (Paris)*. 1879;**3**:157-170
- [5] Lister J. On the antiseptic principle in the practice of surgery. *The Lancet*. 1867;**90**(2299):353-356
- [6] Barton M. The History of Surgical Gloves. 2018. Available from: <https://www.pastmedicalhistory.co.uk/the-history-of-surgical-gloves/>
- [7] Hage JJ, Brinkman RJ. Andreas Vesalius' understanding of pulmonary ventilation. *Respiratory Physiology & Neurobiology*. 2016;**231**:37-44
- [8] Sauerbruch F. Intrathoracic operations. *Lancet*. 1904;**7**:1308
- [9] Meltzer A. Dr. Samuel James Meltzer and intratracheal anesthesia. 1990;**2**(1):54-58
- [10] Meltzer SJ. Continuous respiration without respiratory movements. *The Journal of Experimental Medicine*. 1909;**11**(4):622-625
- [11] Blum A. Alton ochsner, MD, 1896-1981 anti-smoking pioneer. *The Ochsner Journal*. 1999;**1**:102-105
- [12] Ochsner A, Blalock J, Sucre A. Carcinoma of the stomach. *The American Surgeon*. 1955;**21**:1-16
- [13] Churchill ED. The surgical treatment of carcinoma of the lung. *The Journal of Thoracic Surgery*. 1933;**2**:254-261
- [14] Graham EA, Singer JJ. Successful removal of an entire lung for carcinoma of the bronchus. *JAMA*. 1984;**251**(2):257-260
- [15] Ochsner A, DeBakey M. Primary pulmonary malignancy: Treatment by total pneumonectomy; analysis of 79 collected cases and presentation of 7 personal cases. *The Ochsner Journal*. 1999;**1**(3):109-125
- [16] Shimkin MB, Connelly RR, Marcus SC, Cutler SJ. Pneumonectomy and lobectomy in bronchogenic carcinoma. A comparison of end results of the Overholt and Ochsner clinics. *The Journal of Thoracic and Cardiovascular Surgery*. 1962;**44**:503-519
- [17] Kent EM, Blades B. The anatomic approach to pulmonary resection. *Annals of Surgery*. 1942;**116**(5):782-794
- [18] Thomas CP. Conservative resection of the bronchial tree. *Journal of the Royal College of Surgeons of Edinburgh*. 1956;**1**(3):169-186
- [19] Johnston JB, Jones PH. The treatment of bronchial carcinoma by lobectomy and sleeve resection of the main bronchus. *Thorax*. 1959;**14**(48):48-54
- [20] Carlens E. Mediastinoscopy: A method for inspection and tissue biopsy in the superior mediastinum. *Diseases of the Chest*. 1959;**36**:343-352
- [21] Kirklin JW, McDonald JR, Clagett OT, Moersch HJ, Gage RP.

Bronchogenic carcinoma: Cell type and other factors relating to prognosis. *Surgery, Gynecology & Obstetrics*. 1955;**100**(4):429-438

[22] Reynders H. Radicale' of 'conservatieve' pneumonectomie? *Nederlands Tijdschrift voor Geneeskunde*. 1962;**2257**

[23] Pearson FG, DeLarue NC, Ilves R, Todd TR, Cooper JD. Significance of positive superior mediastinal nodes identified at mediastinoscopy in patients with resectable cancer of the lung. *The Journal of Thoracic and Cardiovascular Surgery*. 1982;**83**(1):1-11

[24] Hokschi B, Birken-Bertsch H, Müller JM. Thoracoscopy before Jacobaeus. *The Annals of Thoracic Surgery*. 2002;**74**(4):1288-1290

[25] Lewis RJ, Caccavale RJ, Sisler GE. Imaged thorascopic surgery: A new thoracic technique for resection of mediastinal cysts. *The Annals of Thoracic Surgery*. 1992;**53**:38-20

[26] McKenna RJ Jr. Lobectomy by video-assisted thoracic surgery with mediastinal node sampling for lung cancer. *The Journal of Thoracic and Cardiovascular Surgery*. 1994;**107**(3):879-882

[27] Lim E. In hospital clinical efficacy, safety and oncologic outcomes from VIOLET: A UK multi-centre RCT of VATS versus open lobectomy for lung cancer. In: *World Conference on Lung Cancer*. London: Royal Brompton Hospital; 2019

[28] Bayman EO, Parekh KR, Keech J, Selte A, Brennan TJ. A prospective study of chronic pain after thoracic surgery. *Anesthesiology*. 2017;**126**(5):938-951

[29] Rocco G, Martin-Ucar A, Passera E. Uniportal VATS wedge pulmonary resections. *The Annals of Thoracic Surgery*. 2004;**77**(2):726-728

[30] Liu CC, Shih CS, Liu YH, Cheng CT, Melis E, Liu ZY. Subxiphoid single-port video-assisted thorascopic surgery. *Journal of Visceral Surgery*. 2016;**2**:112

[31] Zieliński M, Rami-Porta R. *The Transcervical Approach in Thoracic Surgery*. Berlin Heidelberg: Springer-Verlag; 2014. 221 p

[32] ElSaegh MMM, Ismail NA, Mydin MI, Nardini M, Dunning J. Subxiphoid uniportal lobectomy. *Journal of Visceral Surgery*. 2017;**3**:24

[33] Melfi F. Early experience with robotic technology for thorascopic surgery. *European Journal of Cardio-Thoracic Surgery*. 2002;**21**(5):864-868

[34] Subramanian MP, Colditz GA. Time trends of perioperative outcomes in early-stage non-small cell lung cancer resection patients (statistical commentary). *Annals of Thoracic Surgery*. 2019. Available online 19 October 2019. <https://doi.org/10.1016/j.athoracsur.2019.09.031>. In Press

[35] Aberle J, Reining F, Dannheim V, Flitsch J, Klinge A, Mann O. Metformin after bariatric surgery—An acid problem. *Experimental and Clinical Endocrinology & Diabetes*. 2012;**120**(3):152-153

[36] De Koning H, Van Der Aalst C, Ten Haaf K, Oudkerk M. PL02.05 effects of volume CT lung cancer screening: Mortality results of the NELSON randomised-controlled population based trial. *Journal of Thoracic Oncology*. 2018;**13**(10):S185

[37] Seguin-Givelet A, Grigoriu M, Brian E, Gossot D. Planning and marking for thorascopic anatomical segmentectomies. *Journal of Thoracic Disease*. 2019;**10**:1187-1194

[38] Oizumi H, Kanauchi N, Kato H, Endoh M, Suzuki J, Fukaya K, et al. Anatomic thorascopic pulmonary

segmentectomy under 3-dimensional multidetector computed tomography simulation: A report of 52 consecutive cases. *The Journal of Thoracic and Cardiovascular Surgery*. 2011;**141**(3):678-682

[39] Saji H, Inoue T, Kato Y, Shimada Y, Hagiwara M, Kudo Y, et al. Virtual segmentectomy based on high-quality three-dimensional lung modelling from computed tomography images. *Interactive Cardiovascular and Thoracic Surgery*. 2013;**17**(2):227-232

[40] Shimizu K, Nakazawa S, Nagashima T, Kuwano H, Mogi A. 3D-CT anatomy for VATS segmentectomy. *Journal of Visceral Surgery*. 2017;**3**:88

[41] Wu WB, Xu XF, Wen W, Xu J, Zhu Q, Pan XL, et al. Three-dimensional computed tomography bronchography and angiography in the preoperative evaluation of thoracoscopic segmentectomy and subsegmentectomy. *Journal of Thoracic Disease*. 2016;**8**(Suppl 9):S710-S7S5

[42] Xue L, Fan H, Shi W, Ge D, Zhang Y, Wang Q, et al. Preoperative 3-dimensional computed tomography lung simulation before video-assisted thoracoscopic anatomic segmentectomy for ground glass opacity in lung. *Journal of Thoracic Disease*. 2018;**10**(12):6598-6605

[43] Chen-Yoshikawa TF, Date H. Update on three-dimensional image reconstruction for preoperative simulation in thoracic surgery. *Journal of Thoracic Disease*. 2016;**8**(Suppl 3):S295-S301

[44] Iwano S, Yokoi K, Taniguchi T, Kawaguchi K, Fukui T, Naganawa S. Planning of segmentectomy using three-dimensional computed tomography angiography with a virtual safety margin: Technique and

initial experience. *Lung Cancer*. 2013;**81**(3):410-415

[45] Chinnock C. Virtual reality in surgery and medicine. *Hospital Technology Series*. 1994;**13**(18):1-48

[46] Shuhaiber JH. Augmented reality in surgery. *Archives of Surgery*. 2004;**139**(2):170-174

[47] Chytas D, Malahias MA, Nikolaou VS. Augmented reality in orthopedics: Current state and future directions. *Frontiers in Surgery*. 2019;**6**:38

[48] Guha D, Alotaibi NM, Nguyen N, Gupta S, McFaul C, Yang VXD. Augmented reality in neurosurgery: A review of current concepts and emerging applications. *The Canadian Journal of Neurological Sciences*. 2017;**44**(3):235-245

[49] Incekara F, Smits M, Dirven C, Vincent A. Clinical feasibility of a wearable mixed-reality device in neurosurgery. *World Neurosurgery*. 2018;**118**:e422-e427

[50] Shirk JD, Thiel DD, Wallen EM, Linehan JM, White WM, Badani KK, et al. Effect of 3-dimensional virtual reality models for surgical planning of robotic-assisted partial nephrectomy on surgical outcomes: A randomized clinical trial. *JAMA Network Open*. 2019;**2**(9):e1911598

[51] Tang R, Ma LF, Rong ZX, Li MD, Zeng JP, Wang XD, et al. Augmented reality technology for preoperative planning and intraoperative navigation during hepatobiliary surgery: A review of current methods. *Hepatobiliary & Pancreatic Diseases International*. 2018;**17**(2):101-112

[52] Jensen K, Bjerrum F, Hansen HJ, Petersen RH, Pedersen JH, Konge L. A new possibility in thoracoscopic virtual reality simulation training:

Development and testing of a novel virtual reality simulator for video-assisted thoracoscopic surgery lobectomy. *Interactive Cardiovascular and Thoracic Surgery*. 2015;**21**(4):420-426

[53] Frajhof L, Borges J, Hoffmann E, Lopes J, Haddad R. Virtual reality, mixed reality and augmented reality in surgical planning for video or robotically assisted thoracoscopic anatomic resections for treatment of lung cancer. *Journal of Visualized Surgery*. 2018;**4**:143

[54] Rouze S, de Latour B, Flecher E, Guihaire J, Castro M, Corre R, et al. Small pulmonary nodule localization with cone beam computed tomography during video-assisted thoracic surgery: A feasibility study. *Interactive Cardiovascular and Thoracic Surgery*. 2016;**22**(6):705-711

[55] Tan W, Ge W, Hang Y, Wu S, Liu S, Liu M. Computer assisted system for precise lung surgery based on medical image computing and mixed reality. *Health Information Science and Systems*. 2018;**6**(1):10

[56] Finkelstein SES, M R, Nguyen DM, Stewart JH, Tretler JA, Schrupp DS. Virtual bronchoscopy for evaluation of malignant tumors of the thorax. *The Journal of Thoracic and Cardiovascular Surgery*. 2001;**123**(5):967-972

[57] Rapp-Bernhardt U, Welte T, Doebling W, Kropf S, Bernhardt TM. Diagnostic potential of virtual bronchoscopy: Advantages in comparison with axial CT slices, MPR and mIP? *European Radiology*. 2000;**10**(6):981-988

[58] Rossi S, Di Stasi M, Buscarini E, Cavanna L, Quaretti P, Squassante E, et al. Percutaneous radiofrequency interstitial thermal ablation in the treatment of small hepatocellular

carcinoma. *The Cancer Journal from Scientific American*. 1995;**1**(1):73-81

[59] Shiina S, Teratani T, Obi S, Hamamura K, Koike Y, Omata M. Nonsurgical treatment of hepatocellular carcinoma: From percutaneous ethanol injection therapy and percutaneous microwave coagulation therapy to radiofrequency ablation. *Oncology*. 2002;**62**(Suppl 1):64-68

[60] Dupuy DE, DiPetrillo T, Gandhi S, Ready N, Ng T, Donat W, et al. Radiofrequency ablation followed by conventional radiotherapy for medically inoperable stage I non-small cell lung cancer. *Chest*. 2006;**129**(3):738-745

[61] Okuma T, Matsuoka T, Yamamoto A, Oyama Y, Hamamoto S, Toyoshima M, et al. Determinants of local progression after computed tomography-guided percutaneous radiofrequency ablation for unresectable lung tumors: 9-year experience in a single institution. *Cardiovascular and Interventional Radiology*. 2010;**33**(4):787-793

[62] Powell JW, Dexter E, Scalzetti EM, Bogart JA. Treatment advances for medically inoperable non-small-cell lung cancer: Emphasis on prospective trials. *The Lancet Oncology*. 2009;**10**(9):885-894

[63] Gillams A. Ablation of lung tumours. *Cancer Imaging*. 2012;**12**:361-362

[64] Hiraki T, Gobara H, Iishi T, Sano Y, Iguchi T, Fujiwara H, et al. Percutaneous radiofrequency ablation for clinical stage I non-small cell lung cancer: Results in 20 nonsurgical candidates. *The Journal of Thoracic and Cardiovascular Surgery*. 2007;**134**(5):1306-1312

[65] Pennathur A, Luketich JD, Abbas G, Chen M, Fernando HC, Gooding WE, et al. Radiofrequency ablation for the

treatment of stage I non-small cell lung cancer in high-risk patients. *The Journal of Thoracic and Cardiovascular Surgery*. 2007;**134**(4):857-864

[66] Simon CJ, Dupuy DE, DiPetrillo TA, Safran HP, Grieco CA, Ng T, et al. Pulmonary radiofrequency ablation: Long-term safety and efficacy in 153 patients. *Radiology*. 2007;**243**(1):268-275

[67] Thanos L, Mylona S, Pomoni M, Athanassiadi K, Theakos N, Zoganas L, et al. Percutaneous radiofrequency thermal ablation of primary and metastatic lung tumors. *European Journal of Cardio-Thoracic Surgery*. 2006;**30**(5):797-800

[68] Dupuy DE, Fernando HC, Hillman S, Ng T, Tan AD, Sharma A, et al. Radiofrequency ablation of stage IA non-small cell lung cancer in medically inoperable patients: Results from the American College of Surgeons Oncology Group Z4033 (Alliance) trial. *Cancer*. 2015;**121**(19):3491-3498

[69] Hiraki T, Gobara H, Mimura H, Matsui Y, Toyooka S, Kanazawa S. Percutaneous radiofrequency ablation of clinical stage I non-small cell lung cancer. *The Journal of Thoracic and Cardiovascular Surgery*. 2011;**142**(1):24-30

[70] Liu B, Liu L, Hu M, Qian K, Li Y. Percutaneous radiofrequency ablation for medically inoperable patients with clinical stage I non-small cell lung cancer. *Thoracic Cancer*. 2015;**6**(3):327-333

[71] Ambrogi MC, Fanucchi O, Cioni R, Dini P, De Liperi A, Cappelli C, et al. Long-term results of radiofrequency ablation treatment of stage I non-small cell lung cancer: A prospective intention-to-treat study. *Journal of Thoracic Oncology*. 2011;**6**(12):2044-2051

[72] Palussiere J, Marcet B, Descat E, Deschamps F, Rao P, Ravaud A, et al.

Lung tumors treated with percutaneous radiofrequency ablation: Computed tomography imaging follow-up. *Cardiovascular and Interventional Radiology*. 2011;**34**(5):989-997

[73] Simon TG, Beland MD, Machan JT, DiPetrillo T, Dupuy DE. Charlson comorbidity index predicts patient outcome, in cases of inoperable non-small cell lung cancer treated with radiofrequency ablation. *European Journal of Radiology*. 2012;**81**(12):4167-4172

[74] Li G, Xue M, Chen W, Yi S. Efficacy and safety of radiofrequency ablation for lung cancers: A systematic review and meta-analysis. *European Journal of Radiology*. 2018;**100**:92-98

[75] Yuan Z, Wang Y, Zhang J, Zheng J, Li WA. Meta-analysis of clinical outcomes after radiofrequency ablation and microwave ablation for lung cancer and pulmonary metastases. *Journal of the American College of Radiology*. 2019;**16**(3)

[76] Dupuy DE, Zagoria RJ, Akerley W, Mayo-Smith WW, Kavanagh PV, Safran H. Percutaneous radiofrequency ablation of malignancies in the lung. *AJR. American Journal of Roentgenology*. 2000;**174**(1):57-59

[77] Robert Sheu Y, Hong K. Percutaneous lung tumor ablation. *Techniques in Vascular and Interventional Radiology*. 2013;**16**(4):239-252

[78] Mouli SK, Kurilova I, Sofocleous CT, Lewandowski RJ. The role of percutaneous image-guided thermal ablation for the treatment of pulmonary malignancies. *AJR. American Journal of Roentgenology*. 2017;**209**(4):740-751

[79] Gage AA, Baust J. Mechanisms of tissue injury in cryosurgery. *Cryobiology*. 1998;**37**(3):171-186

[80] Niu L, Xu K, Mu F. Cryosurgery for lung cancer. *Journal of Thoracic Disease*. 2012;**4**(4):408-419

[81] McDevitt JL, Mouli SK, Nemcek AA, Lewandowski RJ, Salem R, Sato KT. Percutaneous cryoablation for the treatment of primary and metastatic lung tumors: Identification of risk factors for recurrence and major complications. *Journal of Vascular and Interventional Radiology*. 2016;**27**(9):1371-1379

[82] Moore W, Talati R, Bhattacharji P, Bilfinger T. Five-year survival after cryoablation of stage I non-small cell lung cancer in medically inoperable patients. *Journal of Vascular and Interventional Radiology*. 2015;**26**(3):312-319

[83] Uhlig J, Case MD, Blasberg JD, Boffa DJ, Chiang A, Gettinger SN, et al. Comparison of survival rates after a combination of local treatment and systemic therapy vs systemic therapy alone for treatment of stage IV non-small cell lung cancer. *JAMA Network Open*. 2019;**2**(8):e199702

[84] Yamauchi Y, Izumi Y, Hashimoto K, Yashiro H, Inoue M, Nakatsuka S, et al. Percutaneous cryoablation for the treatment of medically inoperable stage I non-small cell lung cancer. *PLoS One*. 2012;**7**(3):e33223

[85] Yamauchi Y, Izumi Y, Kawamura M, Nakatsuka S, Yashiro H, Tsukada N, et al. Percutaneous cryoablation of pulmonary metastases from colorectal cancer. *PLoS One*. 2011;**6**(11):e27086

[86] Maiwand MO, Asimakopoulos G. Cryosurgery for lung cancer: Clinical results and technical aspects. *Technology in Cancer Research & Treatment*. 2004;**3**(2):143-150