

We are IntechOpen, the world's leading publisher of Open Access books Built by scientists, for scientists

6,900

Open access books available

185,000

International authors and editors

200M

Downloads

Our authors are among the

154

Countries delivered to

TOP 1%

most cited scientists

12.2%

Contributors from top 500 universities



WEB OF SCIENCE™

Selection of our books indexed in the Book Citation Index
in Web of Science™ Core Collection (BKCI)

Interested in publishing with us?
Contact book.department@intechopen.com

Numbers displayed above are based on latest data collected.
For more information visit www.intechopen.com



Stump Overgrowth after Limb Amputation in Children

Rami Jahmani and Dror Paley

Abstract

Stump overgrowth is the most common complication after limb amputation in children. Its morbidity is relatively high, that required frequent revisions of the stump and prosthesis. The incidence of stump overgrowth varies in the literature; depending on different factors. The exact pathogenesis is unclear, many hypotheses have been suggested. The treatment is a challenge; simple excision of the bone is associated with recurrence and further shorting of the stump. Many options of treatment have been used. This paper is an up-to date literature review that includes the definition, incidence, pathogenesis, clinical presentation, radiographic diagnosis, and treatment options of stump overgrowth in children.

Keywords: limb amputation, stump overgrowth, complication of amputation, stump capping procedures, heterotopic ossification

1. Introduction

Overgrowth is the most common complication after stump amputation in children, and it leads to significant morbidity and multiple revisions of both the stump and prosthesis [1–3]. Overgrowth is characterized by the formation of bone spikes at the end of the amputated stump. At some point, the bone end becomes covered with a bursa, and skin adheres to the underlying bone. Finally, the skin perforates, and bone and soft tissue infections develop, **Figure 1**.

2. Incidence

Stump overgrowth is the most common complication following limb amputation in children, and the incidence varies from 4 to 50% [2–8]. Age, location, reason for amputation, and level of amputation are known factors that affect the prevalence of stump overgrowth. Among them age and location are the most influencing factors. Osseous overgrowth is not observed in children older than 12 years or in cases of disarticulation amputations. Younger patients have a higher incidence of stump overgrowth [1, 7, 9]. The most frequent locations are the humerus, followed by the fibula and the tibia, whereas stump overgrowth is rare in the radius and ulna [7, 10]. Traumatic amputations carry a higher risk of overgrowth than elective surgical amputations, as stump overgrowth is very rare in congenital agenesis but common in amniotic band syndrome [1–3, 5, 11, 12].

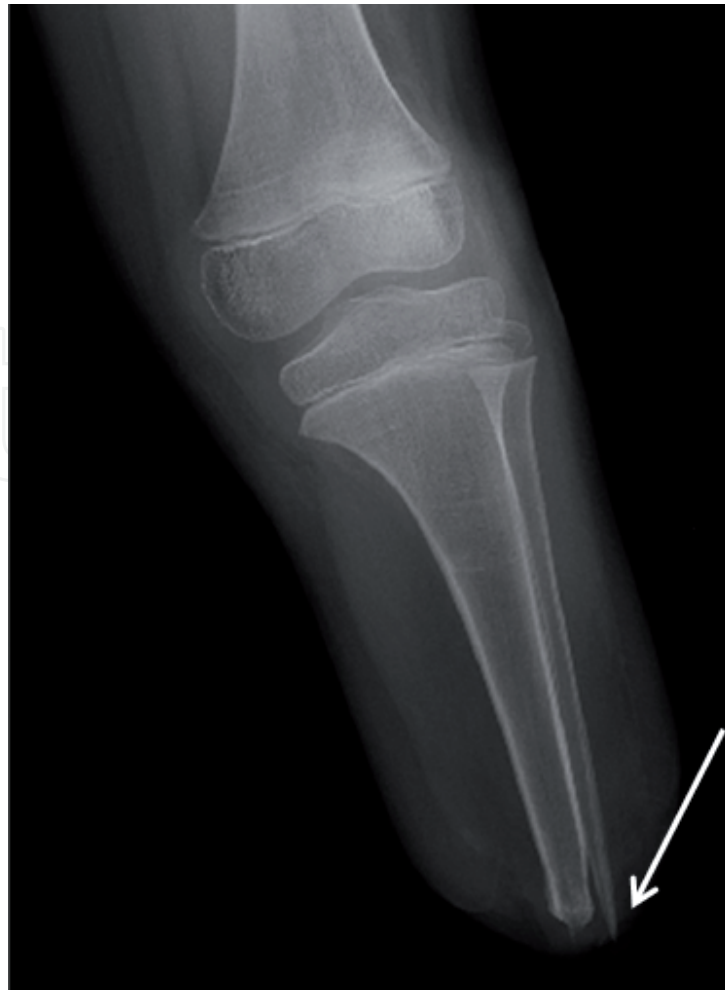

Figure 1.
X-ray of distal tibia and fibula overgrowth, arrow is indicating the sharp end of overgrown spike.

Aitke postulated that bone overgrowth in congenital cases is due to intrauterine amputation (amniotic band syndrome) rather than true agenesis, considering that bone overgrowth does not occur in congenital agenesis; however, this assumption has not been proven [7]. An increased prevalence of overgrowth has been reported in patients who had previously undergone surgery for overgrowth [3, 11, 12]. Last, metaphyseal level amputations carry a higher risk of overgrowth than diaphyseal level amputations [1, 5].

3. Pathogenesis

Many hypotheses have been proposed to explain the phenomenon of bone overgrowth. Because overgrowth occurs in children, it has been suggested that overgrowth occurs as a result of disproportional growth between the remaining proximal physis and the contracted distal soft tissue and skin [13–15]. Pellicore et al. observed bone growth stimulation following amputation and concluded that stump overgrowth occurs because soft tissues cannot keep up with the rapid growth of the bone [16]; however, attempts to treat overgrowth by proximal epiphysiodesis and leaving long redundant soft tissue have failed [12, 17–19]. The incidence of the overgrowth phenomenon in cases of surgical and post-trauma amputations was higher [1–3, 5] compared with that of disarticulation amputation and congenital agenesis, [7, 20] which suggests that stump overgrowth might be a result of bone and soft tissue trauma rather than continuous growth of the proximal physis. This would mean that overgrowth is a local

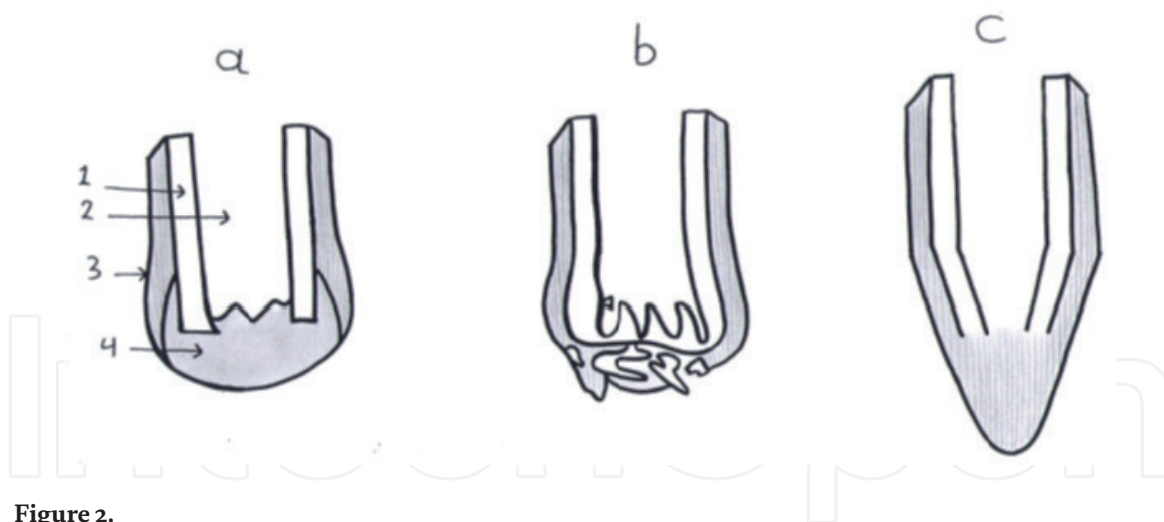


Figure 2.

Pathogenesis of stump overgrowth: (a) initial stage, hematoma formation and periosteal elevation. (b) Organization of collagen fibers of scar and periosteum as continuous mass. (c) Pulling the collagen fibers more distal by wound contracture and spike formation. 1 – Cotrex, 2 – Medullary canal, 3 – Periosteum, 4 – Hematoma.

process of bone formation and wound healing that occur in the distal stump. Studying the histology of stump overgrowth in rabbits, Hellstadius concluded that the medullary canal is the source of overgrowth [21]. Aitken implanted a radiographic marker in the bony stump and confirmed that overgrowth occurs distal to the marker, proving that overgrowth does not represent an epiphyseal contribution but rather a local phenomenon of bone healing [7, 8]. This explains why overgrowth does not occur in cases of disarticulation where there is intact articular cartilage rather than transected bone. If stump overgrowth is a local phenomenon, it is unclear why it is not observed following adult amputation. Speer, by conducting an experimental histological study on the immature skeleton of rabbits, described the pathogenesis of stump overgrowth and explained why it does not occur in the mature skeleton [22]. His study indicates that an amputation stump responds via wound healing and intramembranous bone formation. In the immature skeleton, the elastic characteristic of the periosteum allows it to pull away from the end of the amputee stump and leads to local bone formation, **Figure 2**.

4. Diagnosis and clinical picture

Patients with stump overgrowth present with pain, intolerance to the prosthesis, soft tissue irritation, pressure ulcers, skin perforation, and infection. The sharp edge of the bony spike can be palpated subcutaneously. The diagnosis is confirmed radiographically, with characteristic distal tapering of the bone to a narrow tip, with the absence of a medullary canal (the so-called licked candy sign), **Figure 1**. Orthopaedists should differentiate between stump overgrowth and bone spurs, which develop as a response to periosteal stimulation at the periphery of transected bone edges. Such bone spurs rarely necessitate stump revision. The cause of pain might also be an adventitious bursa, which is common in soft tissues overlying an area of the stump.

5. Treatment

5.1 Conservative treatment

The initial management of stump overgrowth includes prosthetic modifications and lifestyle adjustments. Before wearing the prosthesis, soft tissues should be pulled

distally to prevent “mushrooming” of the soft tissue proximally into the socket. In many cases, the cause of pain is attributed to bone spurs and adventitious bursae, which can be treated with aspiration, steroid injections, and stump wrapping.

The skin traction method, first described by Marquardt in the late 1960s, has been reported to be successful in selected cases [10, 23]. This method has become the standard in very young children with very short stumps, in whom further shortening may preclude the use of prosthetics. The method involves a lengthy treatment and requires a cooperative parent. Older children can be taught to apply traction by themselves. The early period at the beginning of the treatment, before the skin becomes adherent to the underlying bursa, is important. The method is less successful for amputations below the knee due to the presence of the interosseous membrane and related tissue that hold the soft tissue firmly to the bone. Traction should be applied 23 hours a day, with 1 hour off for cleaning, and should be continued until skeletal maturity. A skin adhesive, such as Hollister medical skin adhesive, is applied to the distal stump. Cotton or nylon stockinettes are placed on the limb over the adhesive and pressed onto the skin firmly. After the adhesive dries, the loose end of the fabric is split into medial and lateral “tails.” The tails are cut to the skin margin where the stockinette is adherent to the skin and are used to counter-pull through a D-ring attached to the outside of the socket after being looped around a rod built into the prosthesis. Night traction is achieved by attaching the tail of the stockinette to a weight with appropriate weight over a pulley on the side of the bed.¹

5.2 Surgical treatment

The surgical treatment of stump overgrowth has always been a challenge. Simple excision of the overgrown bone is associated with high recurrence; Davids et al. [11] reported a rate of revision as high as 87% after simple bone excision, multiple revisions (more than one revision) have been reported in 18% of cases, and one case with six revisions has been reported [5, 12]. Repeated surgical excision, while it is temporarily effective, leads to progressive shortening of the stump. A lack of understanding of the pathogenesis has led to a wide variety of treatment recommendations. Disproportional growth between bone and soft tissue has been considered a reason for overgrowth in the immature skeleton. Attempts to treat the condition by proximal epiphyseodesis and leaving a redundant soft tissue envelope have failed to stop overgrowth [12, 17–19]. The recent hypothesis, which considers overgrowth a local appositional overgrowth as a result of the healing process [6–8, 21], has directed surgical treatment for reducing the intensity of the bone healing process. Attempts to stop local bone formation by sclerosing the end of the stump by periosteal excision and cauterization have failed to treat the condition, and histological studies of the excised-periosteum distal stump have shown viable bony tissue [3]. To interrupt the interaction between the endosteum and surrounding outside soft and bony tissues, capping of the medullary canal has been suggested. The first capping procedure was performed by Swanson in 1969 with the use of silicon rubber [24, 25]. Marquardt, in 1974, has been credited as being the first to propose the application of a biological cap to prevent bone overgrowth in children. He described his procedure of using an epiphysis taken from the amputated limb as a cap to prevent overgrowth of a distal tibia amputation [26]. The goal was to convert a diaphyseal amputation into a stump resembling a disarticulation type, **Figure 3**. Many animal and human studies have been conducted to study the result of capping procedures using different materials, including 1 – biological caps: cancellous, cortical, and cartilaginous caps from the amputated distal stump and iliac crest; and

¹ The technique is further described in [23].

2 – synthetic caps: rubber, polyethylene, titanium, and Teflon caps [1, 3, 4, 11, 24, 26–32] (**Table 1**). Animal studies on rabbits, with transplantation of the metatarsal epiphyses and fixation to the end of the amputated bone, have shown epiphyseal capping to be a very successful procedure to prevent overgrowth [31]. Many further publications have shown capping of the stump with an osteochondral cap to be the most effective treatment, with a revision rate of 0–10% [4, 29, 32, 33]. A controlled study compared osteochondral capping of the stump with simple resection and found a revision rate of 10% and, subsequently, of 86% [11, 28]. The distal epiphysis of the amputated stump, distal tibia, distal ulna, head of the metatarsal bone, and calcaneus serve as donors for the osteochondral cap for primary amputation (amputation where a distal stump is available). Finding a donor for the osteochondral cap is a challenge in secondary amputation (revision cases and cases where the distal part is absent), and the proximal fibula of the ipsilateral knee can be used in these situations [4, 29, 31, 33]. To avoid donor site morbidity (knee instability), Paley D used the apophysis of the iliac crest as a cap in a case series of patients [34]. Bernd et al. [27] studied the relationship between the revision rate in cartilaginous stump plasty and different factors and found no relationship with sex, reason for amputation, origin of the graft or method of fixation (screw vs. wires). However, revision was related to age and site; there were no revisions in patients below the age of 10 years old, and there were more revisions in the humerus; the high revision rate in the humerus was attributed to a loose interference fit between the humeral shaft and cartilaginous cap [32].

To avoid donor site morbidity and to substitute biological caps when unavailable, synthetic cap usage has been attractive for orthopedist. Silicon rubber, polyethylene and titanium caps have shown poor results [3, 11, 24]. Although capping

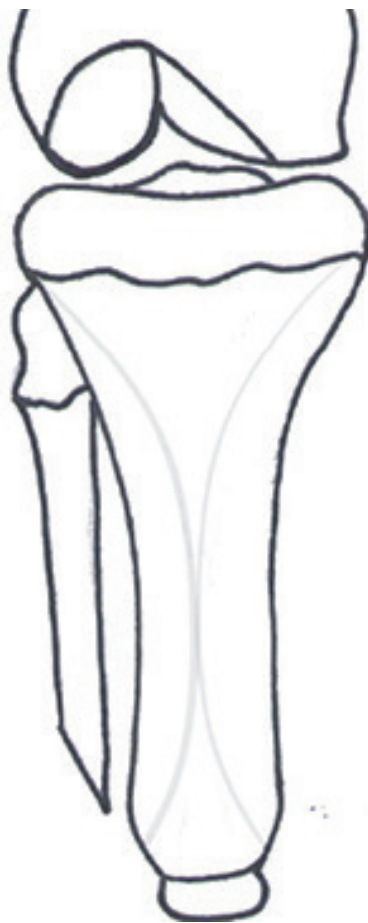


Figure 3.
Tibia stump plugged by cartilaginous cap.

N	Year	Author	Revision rate	Type of cap	Note
1	1978	Wang et al.	Zero	Epiphyseal cap from amputated limb of rabbits	Animal study
2	1991	Bernd et al.	12%	Bone graft	
3	1992	Benevenia et al.	10%	Epiphyseal cap form amputated segment	
4	1992	Hugh et al.	Zero	Ipsilateral fibula	
5	1995	Davids et al.	70%	Polyethellene	Failure mainly due to infection, prosthesis loosening, difficult soft tissue coverage
6	1995	Davids et al.	27%	Bone graft	
7	2004	Davids et al.	29%	Teflon	
8	2015	Fedorak et al.	10%	Ipsilateral fibula transplanted to tibias	
9	2017	Fedorak et al.	30%	Ipsilateral fibula transplanted to humerii	High failure rate in humerii treated by osteochondral transplantation
10	2017	Fedorak et al.	69%	Bone graft	
11	2019	Paley and Jahmani	50%	Apophysis of the ileac crest	A case series

Table 1.
Result of capping procedure by different authors using different capping materials.

with synthetic material is successful for reducing the intensity of bony growth, the revision rate is high because of failure of fixation, infection, implant fracture, and difficulty covering with soft tissue. The synthetic cap must be biologically inert and durable. Teflon caps show better results than other synthetic materials, with a 29% revision rate. This result is comparable to capping of the stump with bone grafts; the cause of failure is mainly due to infection and painful bursa rather than overgrowth [3].

Conclusion of treatment: conservative treatment (prosthesis and lifestyle modification) is the initial treatment, and the skin traction method can be used in selected cases, especially in very young patients and cases of short stumps. When performing amputations, prophylactic transplantation of an osteochondral graft to plug the stump is recommended when a graft is available. In revision cases and cases in which the osteochondral graft is unavailable, the head of the fibula and Teflon caps can be used to plug the stump.

Acknowledgements

The authors are thankful to Maha Almaani for drawing the figures.

IntechOpen

Author details

Rami Jahmani^{1*} and Dror Paley²

¹ Department of Special Surgery/Orthopaedic Division, Faculty of Medicine,
Jordan University of Science and Technology, Irbid, Jordan

² Paley Orthopedic and Spine Institute, St. Mary's Hospital, West Palm Beach,
Florida, USA

*Address all correspondence to: dr.Jahmany@yahoo.com

IntechOpen

© 2019 The Author(s). Licensee IntechOpen. This chapter is distributed under the terms of the Creative Commons Attribution License (<http://creativecommons.org/licenses/by/3.0>), which permits unrestricted use, distribution, and reproduction in any medium, provided the original work is properly cited. 

References

- [1] Michels F, De Smet L. Osseous overgrowth in congenital amputations of the upper limb: Report of 3 cases treated with autologous stump plasty. *Acta Orthopaedica Belgica*. 2001;**67**(5):452-455
- [2] Vocke AK, Schmid A. Osseous overgrowth after post-traumatic amputation of the lower extremity in childhood. *Archives of Orthopaedic and Trauma Surgery*. 2000;**120**(7-8):452-454
- [3] Tenholder M, Davids JR, Gruber HE, Blackhurst DW. Surgical management of juvenile amputation overgrowth with a synthetic cap. *Journal of Pediatric Orthopedics*. 2004;**24**(2):218-226
- [4] Fedorak GT, Watts HG, Cuomo AV, Ballesteros JP, Grant HJ, Bowen RE, et al. Osteocartilaginous transfer of the proximal part of the fibula for osseous overgrowth in children with congenital or acquired tibial amputation: Surgical technique and results. *Journal of Bone and Joint Surgery*. 2015;**1**, **97**(7):574-581
- [5] O'Neal M, Bahner R, Geney T, Ogden J. Osseous overgrowth after amputation in adolescents and children. *Journal of Pediatric Orthopedics*. 1996;**16-A**:78-84
- [6] Abraham E, Pellicore RJ, Hamilton RC, Hallman BW, Ghosh L. Stump overgrowth in juvenile amputees. *Journal of Pediatric Orthopedics*. 1986;**6**:66-71
- [7] Aitken G. Surgical amputation in children. *Journal of Bone and Joint Surgery*. 1963;**45**:1735-1741
- [8] Aitken G. Overgrowth of the amputation stump. *Inter Clinic Information Bulletin*. 1962;**1**:1
- [9] Abraham E. Operative treatment of bone overgrowth in children who have an acquired or congenital amputation (letter). *Journal of Bone and Joint Surgery*. 1996;**78**:1287-1288
- [10] Atkins D, Meier R. *Comprehensive Management of the Upper-Limb Amputee*. 3rd ed. New York: Springer-verlag; 1989
- [11] Davids JR, Meyer LC, Blackhurst DW. Operative treatment of bone overgrowth in children who have an acquired or congenital amputation. *Journal of Bone and Joint Surgery*. 1995;**77**:1490-1497
- [12] Pfeil J, Marquardt E, Holtz T, Niethard FU, Schneider E, Carstens C. The stump capping procedure to prevent or treat terminal osseous overgrowth. *Prosthetics and Orthotics International*. 1991;**15**(2):96-99
- [13] Beekman F. Amputations during childhood. *The Surgical Clinics of North America*. 1938;**18**:425
- [14] Frantz A, Aitken G. Management of the juvenile amputee. *Clinical Orthopaedics*. 1959;**14**:30
- [15] Kurtz A, Hand R. Bone growth following amputation in childhood. *American Journal of Surgery*. 1939;**43**:773
- [16] Pellicore RJ, Sciora J, Lambert CN, Hamilton RC. Incidence of bone overgrowth in the juvenile amputee population. *Inter Clinic Information Bulletin*. 1974;**13**:1-10
- [17] Saal F. Epiphysiodesis combined with amputation. *Journal of Bone and Joint Surgery*. 1939;**21**:442
- [18] Aitken GT. The child with an acquired amputation. *Inter Clinic Information Bulletin*. 1968;**7**:1-15
- [19] Drvaric DM, Kruger LM. Modified Ertl osteomyoplasty for terminal

overgrowth in childhood limb deficiencies. *Journal of Pediatric Orthopedics*. 2001;21:392-394

[20] Firth GB, Masquijo JJ, Kontio K. Transtibial Ertl amputation for children and adolescents: A case series and literature review. *Journal of Children's Orthopaedics*. 2011;5(5):357-362. DOI: 10.1007/s11832-011-0364-0

[21] Hellstadius A. An investigation, by experiments on animals, of the role played by the epiphysial cartilage in longitudinal growth. *Acta Chirurgica Scandinavica*. 1947;95:156

[22] Speer DP. The pathogenesis of amputation stump overgrowth. *Clinical Orthopaedics and Related Research*. 1981;(159):294-307

[23] Friedmann LW, Friedmann L. The conservative treatment of the bony overgrowth problem in the juvenile amputee. *Inter Clinic Information Bulletin*. 1985;20(2):17-23

[24] Swanson AB. Bone overgrowth in the juvenile amputee and its control by the use of silicone rubber implants. *Inter Clinic Information Bulletin*. 1969;8:9-18

[25] Swanson AB. Silicone-rubber implants to control the overgrowth phenomenon in the juvenile amputee. *Inter Clinic Information Bulletin*. 1972;11:5-8

[26] Marquardt E. Plastische Operationen bei drohender Knochendurchspießung am kindlichen Oberarmstumpf. *Zeitschrift für Orthopädie*. 1976;114:711-714

[27] Bernd L, Blasius K, Lukoschek M, Lücke R. The autologous stump plasty. Treatment for bony overgrowth in juvenile amputees. *Journal of Bone and Joint Surgery*. 1991;73:203-206

[28] Davids JR. Terminal bony overgrowth of the residual limb:

Current management strategies. In: Herring JA, Birch JG, editors. *The Child with a Limb Deficiency*. Rosemont, IL: The American Academy of Orthopaedic Surgeons; 1998. pp. 269-280

[29] Benevenia J, Makley JT, Leeson MC, Benevenia K. Primary epiphyseal transplants and bone overgrowth in childhood amputations. *Journal of Pediatric Orthopedics*. 1992;12:746-750

[30] Meyer LC, Sauer BW. The use of porous high-density polyethylene caps in the prevention of appositional bone growth in the juvenile amputee: A preliminary report. *Inter Clinic Information Bulletin*. 1975;14:1

[31] Wang G-J, Baugher WH, Stamp WG. Epiphyseal transplant in amputations. Effects on overgrowth in a rabbit Model. *Clinical Orthopaedics and Related Research*. 1978;(130):285-288

[32] Fedorak GT, Cuomo AV, Watts HG, Scaduto AA. Management of terminal osseous overgrowth of the humerus with simple resection and osteo-cartilaginous grafts. *Journal of Pediatric Orthopedics*. 2017;37(3):e216-ee22

[33] Hugh GW, Yoshio S. Marquardt stump capping for overgrowth. *Journal of the Association of Children's Prosthetic & Orthotic Clinics*. 1992;27:6

[34] Jahmani R, Robbins C, Paley D. Iliac crest apophysis transfer to treat stump overgrowth after limb amputation in children: Case series and literature review. *International Orthopaedics*. 2019. DOI: 10.1007/s00264-019-04289-y. [Epub ahead of print]