

# We are IntechOpen, the world's leading publisher of Open Access books Built by scientists, for scientists

6,900

Open access books available

186,000

International authors and editors

200M

Downloads

Our authors are among the

154

Countries delivered to

TOP 1%

most cited scientists

12.2%

Contributors from top 500 universities



WEB OF SCIENCE™

Selection of our books indexed in the Book Citation Index  
in Web of Science™ Core Collection (BKCI)

Interested in publishing with us?  
Contact [book.department@intechopen.com](mailto:book.department@intechopen.com)

Numbers displayed above are based on latest data collected.  
For more information visit [www.intechopen.com](http://www.intechopen.com)



# Transcatheter Cardiac Surgery

*Antonio Giovanni Cammardella, Federico Ranocchi,  
Antonio Lio, Amedeo Pergolini, Francesco Nicolò,  
Marina Comisso, Vitaliano Buffa and Francesco Musumeci*

## Abstract

The introduction of transcatheter aortic valve implantation (TAVI) have changed the management of patients affected by severe aortic stenosis. Nowadays, TAVI procedure represents the treatment of choice in patients with severe AS inoperable or at high risk. MDCT is the technique of choice in preoperative planning: it provides information regarding aortic valve and vascular access. Particular attention should be paid on bicuspid valve morphology. The choice of valve is, basically, based on confidence and experience of the operator and center.

**Keywords:** transcatheter aortic valve implantation, aortic stenosis, patient selection, imaging, access site

## 1. Introduction

The introduction of transcatheter aortic valve implantation (TAVI) has changed the management of patients affected by severe aortic stenosis.

The calculated incidence rate of severe AS is 4.4%/year in patients  $\geq 65$  years [1]. The prevalence of the disease was estimated of about 13% in general population aged  $\geq 75$  years [2].

Approximately 40% of symptomatic severe AS patients do not undergo SAVR [1].

Nowadays, TAVI procedure represents the treatment of choice in patients with severe AS inoperable or at high risk. The improvement in early and midterm results has extended the indication for TAVI also to elderly patients at intermediate and low risk for surgery. This is the result of a continuous improvement in patients' selection and procedural assessment which is supported by the progress in imaging technology which is central for better diagnostic planning and more precise technical procedure.

## 2. Selection of patients

Actually, the main surgical risk score used in clinical practice and in randomized trial is the STS score: a STS score  $> 8\%$  identifies patient at high risk; a STS score between 4 and 8% corresponds to an intermediate-risk profile; a STS lower than 4% encloses patients at low surgical risk [3].

The last 2017 ESC/EACTS guidelines for the management of valvular disease recommend that in patients who are at increased surgical risk, the decision between SAVR and TAVI should be made by the Heart Team, according to the individual

patient characteristics, with TAVI being favored in elderly patients suitable for transfemoral access (class of recommendation Ib) [4].

AHA/ACC guidelines, also, underline the importance of a multidisciplinary Heart Team in the evaluation of a patient affected by severe AS [5].

However, it seems to be clear that the only evaluation based on surgical preoperative risk score (STS or Euroscore II) is not enough. In fact, specific risk factors for TAVI, such as frailty, chest radiation, porcelain aorta, and vessel tortuosity are not included [6]. Thus, it is difficult to create an appropriate risk score for TAVI due to heterogeneity of patient characteristics.

In conclusion, the role of the Heart Team to include a cardiac surgeon, a cardiologist with interest in heart valve disease and an interventional cardiologist, other specialist such as anesthesiologists and geriatricians, and, if necessary, other clinicians for a complete patient assessment is fundamental [6].

### 3. Imaging assessment

The use of multidetector computed tomography (MDCT) is a daily practice in the preoperative planning of TAVI. MDCT improves the precision in prosthesis sizing and reduce peripheral vascular complications [3].

MDCT provides information about aortic annulus, LVOT calcifications, valve morphology, coronary ostial height, sinus of Valsalva, sino-tubular junction, ascending aorta, and optimal projection curve.

Moreover, through MDCT it is possible to have an analysis of coronary arteries status: if it detects significant coronary stenosis, a coronary angiography should be performed.

MDCT has a key role in vascular access assessment: by routine use of CT scan in preprocedural planning, the rate of vascular complication has dropped to 4–5%.

#### 3.1 Aortic annulus

The aortic annulus is defined as the luminal contour within a virtual plane aligned with the most basal attachment points of the three aortic valve cusps [7]. Usually, the annulus can be measured into the systole, corresponding to 30–40% of the R-R interval: in this way the under-sizing of the prostheses can be avoided [3].

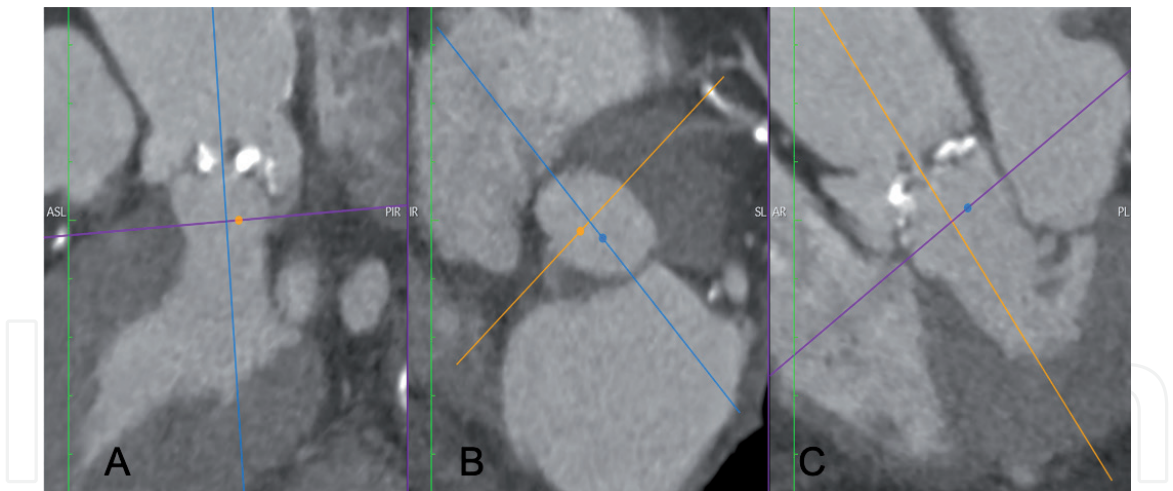
The measurement of the aortic annulus can be obtained manually or semiautomatically. It is clear that the support of software facilitates the work, but it requires a supervision by an expert operator.

In the manual procedure, once the central axis is aligned with the long axis of the aortic root, turning counterclockwise, the lower insertions of the single cusps are identified (**Figure 1**).

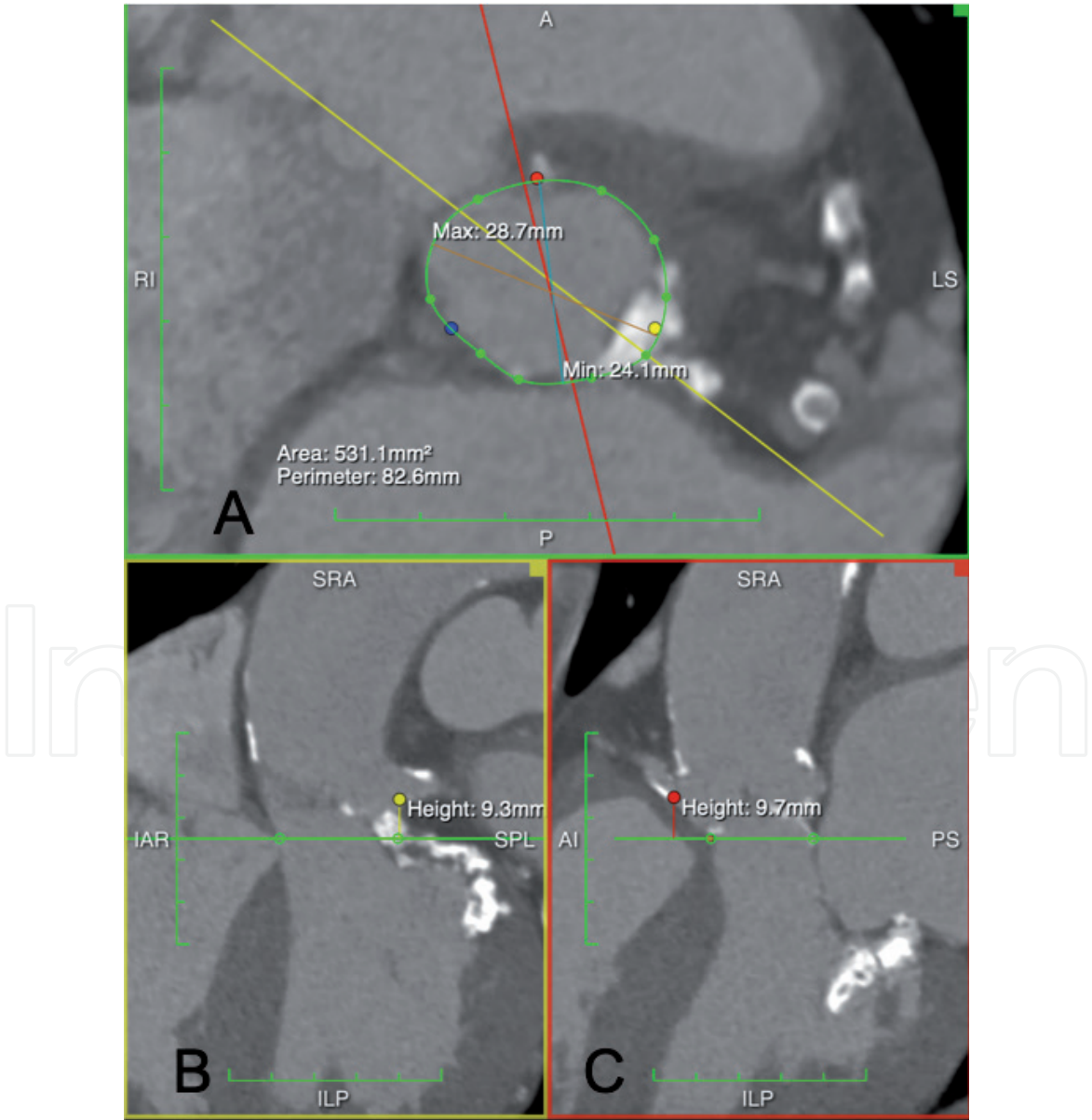
Once aortic annulus is obtained, the measurements of minimal and maximal diameter, perimeter, and area can be calculated (**Figure 2**).

Next, we can proceed to measure coronaries' height, inter-commissural distances, sino-tubular junction, and ascending aorta diameters (**Figure 2**).

It is very important to identify LVOT calcifications, their distribution, and their protrusions. The amount of calcium in LVOT is correlated with AV blocks and annular rupture, representing one of the factors keeping in mind the choice of the type of prostheses (balloon-expandable or self-expanding).



**Figure 1.**  
*Aortic annulus (virtual basal ring) in sagittal view (A), axial (B), and coronal (C).*



**Figure 2.**  
*(A) aortic annulus. (B) Left main height. (C) Right coronary height.*



### 3.2 Bicuspid aortic valve

The incidence of bicuspid aortic valve (BAV) is up to 2–3% in the general population, but probably echocardiography underestimates the real percentage [8]. In the USA, Transcatheter Valve Therapy registry, 2% of the patients had BAVs [9].

According to the number of cusps, the presence of raphe, and the orientation, bicuspid aortic valve was classified into three types (0, 1, 2) and in subcategories [10]. A novel non-numerical classification seems to be useful in TAVI procedure. This classification identifies three BAV morphologies: tri-commissural (one commissure completely fused between two cusps), bi-commissural raphe type (two cusps fused by a fibrous or calcified ridge of various height), and bi-commissural non-raphe type (two cusps completely fused; there are only two commissures and no raphe or third commissure) [11].

For a long time, BAV was considered a risk condition in TAVI procedures. The association between BAV and some risk factors for TAVI is clear: calcified raphe, asymmetrical annulus, the risk of annulus rupture, coronary obstruction, and paravalvular leaks (PVL). Moreover, it is relevant to underline that BAV is associated more frequently with aortopathy (ascending aorta aneurism and coarctation). Thus, it is important to investigate these conditions prior to TAVI, because they should be a contraindication to implantation [6].

In addition, the height and location of coronary ostia in BAV could be very different than in tricuspid valves, and a specific assessment is fundamental to avoid coronary occlusion. About that, in those cases in which there is an uncertain sizing, a pre-dilatation angiography with one or more undersized balloon could be useful.

In BAV, the implantation is associated with lower success rate and higher rate of PVL, but similar outcomes, especially with new generations of prostheses [9, 12]. No significant differences were observed comparing the results of balloon-expandable to that of self-expanding valves [12].

### 3.3 Coronary disease

Observational data suggest that coronary artery disease (CAD) co-exists in up to 60% of patients candidate for TAVI [13]. Recent multicenter trials also report these percentages [14, 15].

Currently, the decision to perform PCI is discussed in Heart Team, considering the location and the complexity of PCI, as the latest ESC guidelines suggest.

Actually, severe lesions (>70%) involving proximal segments of coronary arteries should be treated prior to TAVI [4].

After all, it should be kept in mind that the use of FFR and iFR is theoretically influenced by the presence of a low aortic pressure due to severe aortic stenosis.

When a revascularization is required in TAVI candidates, it can be performed before TAVI, in a single procedure or after TAVI. Recent evidences showed no clinical advantages in terms of cardiovascular mortality, stroke, myocardial infarction, and acute kidney injury, when PCI is performed before or concomitant to TAVI procedure [16].

On the other hand, performing PCI after TAVI can be challenging because of the presence of valve struts and the relative difficulty to access coronary ostia. For this, the decision should be individualized on each case.

### 3.4 Vascular access

The choice of the most appropriate vascular access represents a key role in TAVI procedure. It is fundamental to evaluate the thoracoabdominal aorta, carotid arteries, and iliofemoral vessels.

Different vascular sites can be chosen: transfemoral (TF), transapical (TA), transaortic (TAo), trans-subclavian (TS), trans-carotid (Tc), and others [3, 17].

Different studies and registries have shown that a non-transfemoral TAVI accesses may be necessary up to 10–15% of patients. This is due, mainly, to obstructive peripheral vascular disease, severe vessel tortuosity, aortic aneurysm or atheroma, and previous peripheral grafts [18].

### *3.4.1 Transfemoral TAVI*

The transfemoral access represents the preferred route in TAVI patients: because of its minimal invasiveness and large feasibility, TF access is recommended as first choice [18]. Analysis of iliofemoral vessel size, calcification, and tortuosity is necessary to establish if TF access can be used or not [19].

Multidetector CT provides all these aspects with a greater predictive value for vascular complications than invasive angiography [20].

The combination of a very small iliofemoral artery diameter and the presence of moderate or severe calcifications is associated with a high rate of vascular complications.

The minimum iliofemoral vessel diameter required is 5 mm for current self-expanding valves and 5.5 mm for balloon-expandable prostheses (ideally 6.5 mm for a 18F delivery system) [18].

Iliofofemoral tortuosity does not predict vascular complications, but it can determine vascular elongation. In the case of severe tortuosity, the use of a stiff wire can be helpful, but particular attention should be paid to the distance between the access site and the aortic annulus [21].

For TF procedures, both percutaneous and cutdown access can be used: when the site of access is adequately large and without significant calcifications, percutaneous access is the first choice. In this case, the access is usually closed with various percutaneous devices available in commerce [11]. In the percutaneous approach, the anatomy of femoral artery should be always accurately studied, paying attention to the level of femoral bifurcation [19].

When the risk of percutaneous access is too high, it is preferable to opt for a cutdown approach, avoiding vascular complications in the site of puncture.

Several retrospective studies and one randomized trial have analyzed the differences in outcomes between a percutaneous approach and a surgical cutdown access. None of the available studies could demonstrate a superiority of a percutaneous approach, and the benefit of this choice remains controversial [22–24].

A step-by-step approach is mandatory in order to minimize the risk of complications.

General anesthesia is optional for transfemoral TAVI, but less used rather than the initial TAVI era.

The first step is to identify the femoral puncture site, ideally 1 cm above the femoral bifurcation. Usually, on the basis of CT scan, the best femoral access (right or left) is chosen. Two sheaths (6 Fr) are placed in the contralateral femoral artery and vein, so that a pigtail arterial catheter and a right ventricular pacemaker lead are placed [25].

To proceed more safely, in the case of percutaneous access, the puncture could be done under ultrasound view or fluoroscopy (preferably after a selective angiography from the contralateral site). A standard 0.035 inch wire is retrogradely introduced in the iliac-femoral axis, and a 8 Fr vascular introducer sheath is placed in order to predilate the artery before the placement of a preclosure suture devices. At this point, a 8 Fr sheath is reintroduced over a standard 0.035 guidewire, an Amplatz catheter is placed in descending aorta, and the previous guidewire is changed with a 260 cm stiff wire.

The native aortic valve is crossed by a straight tip guidewire with the support of an Amplatz catheter (AL1–AL2). Once the aortic valve is crossed, the catheter is replaced by a stiff wire with a pigtail curve, paying attention to the risk of ventricular perforation [26].

At this point, a balloon aortic valvuloplasty (BAV) could be performed. BAV is particularly useful in some settings: in very severe and calcified aortic valves, in the case of borderline transcatheter aortic valve sizes, in bicuspid aortic valves, and in the presence of very low coronary ostia to observe the movement of the aortic valvular leaflets.

Then, the transcatheter aortic bioprosthesis is advanced up to the aortic valve, being careful during aortic arch crossing.

The balloon-expandable prostheses need rapid ventricular pacing (180–200 bpm) during the deployment while for self-expanding valves are not mandatory.

It is important to find an optimal implantation plane. Usually, it is calculated before the procedure on the basis of CT scan and verified by angiography, in order to have a single plane with all three cusps aligned.

Once the valve has been implanted, it is necessary to evaluate, by angiography and echocardiography, the position of prosthesis (not too high or too low), the possible presence of perivalvular regurgitation, and the trans-prosthesis gradients.

To have an easier vascular access closure, in some centers, a crossover with a secure wire from the contralateral femoral artery is performed: in this way, a rapid balloon occlusion and/or a delivery of a covered stent could be performed. A final angiography should be performed to check the result.

#### 3.4.2 Transapical TAVI

The transapical (TA) approach, first described by Ye and colleagues in 2006 [27], is historically considered the alternative to transfemoral access. Usually, it is performed when the peripheral axis is impractical. The presence of large apical thrombus represents the major contraindication to this procedure.

The apex can be localized by fluoroscopy, TTE, or TEE. The more appropriate site of puncture is on the LV apex, which is, usually, more anterior and proximal than anatomic cardiac apex [3].

For ventricular pacing, both intracavitary (via femoral vein) and epicardial ventricular leads could be positioned.

The apex is exposed via an anterolateral left anterior mini-thoracotomy in the fifth or sixth intercostal space, under general anesthesia. After placing two purse-string sutures at the puncture site, ventricular puncture is done, and a standard 0.035 inch guidewire is advanced across the degenerated aortic valve, paying attention to avoid mitral valve apparatus. After, with a support of a Judkins catheter, a long stiff wire (260 cm) is placed into the abdominal aorta. The delivery sheath is introduced into the ventricular cavity, and the balloon-expandable valve is opened during rapid ventricular pacing. The final result is checked by TOE and aortic ascending angiography.

The balloon-expandable valves (Edwards Sapien) are the most used in transapical access; anyway, self-expanding bioprostheses (Symetics or Jena-Valve) could be implanted having CE mark. In the latter case, there is no need for rapid ventricular pacing.

Possible complications of the TA approach are bleeding at the site of the apical puncture, myocardial tears, apical scarring, aneurysm formation, or chronic pain [28].

### 3.4.3 Alternative routes

For transaortic access, an upper partial sternotomy or a right mini-thoracotomy at the second or the third intercostal space can be performed. Felt-reinforced purse-string suture is placed in the ascending aorta 4–5 cm above the aortic valve. Once the aortic valve is crossed retrogradely with a guidewire, the procedure is similar to transapical approach [3]. There are few contraindications to transaortic access: chest deformities, porcelain aorta, very short ascending aorta, and previous CABG with patent grafts [18].

The left subclavian artery can be used as an alternative access; the proximal third of the axillary artery represents the ideal site. In the evaluation of the axillary access, the same principles for the TF approach should be kept in mind. Particular attention should be paid at the level of the emergency of left subclavian artery, because of high rate of localization of atherosclerotic calcific plaques. Most of the times, the surgical approach is preferred in case of choice of the trans-axillary access [18]. Most of the time, in the trans-axillary access, self-expanding prostheses are preferred over balloon-expandable.

Rarely, if all types of approaches are not adequate, the **trans-carotid** access could be a valid alternative.

## 4. Valve choice

Currently, the types of valves most implanted are balloon-expandable and self-expanding valves.

Basically, the choice of valve depends on anatomical considerations and available valve sizes. Attention should be paid to annulus dimension and its geometry, bicuspid/tricuspid valve, amount and distribution of calcifications in LVOT and proximal aorta, sino-tubular and ascending aorta dimensions, and coronary height [11].

Usually, in the case of extensive calcifications with an increased risk of rupture, in extreme oval-shape annulus or in the presence of iliofemoral diameter between 5.0 and 5.5 mm, a self-expanding valve is preferred [29–31].

Instead, when we are in the presence of dilated ascending aorta (> 43 mm), very angulated aorta (particularly for transfemoral approach), or in the presence of an elevated preoperative risk of postprocedural pacemaker implant, the choice can fall on the balloon-expandable valves.

Anyway, most of the time the choice depends on operator experience and confidence [3].

## 5. Conclusions

The use of TAVI in patients affected by aortic stenosis is spreading more and more, treating intermediate- and low-risk patients.

The selection of patients seems to be a crucial point, pointing out the role of the Heart Team.

MDCT is the technique of choice in preoperative planning: it provides information regarding aortic valve and vascular access. Particular attention should be paid on bicuspid valve morphology.

The choice of valve is, basically, based on confidence and experience of the operator and the center.



IntechOpen

### Author details

Antonio Giovanni Cammardella<sup>1\*</sup>, Federico Ranocchi<sup>1</sup>, Antonio Lio<sup>1</sup>,  
Amedeo Pergolini<sup>1</sup>, Francesco Nicolò<sup>1</sup>, Marina Comisso<sup>1</sup>, Vitaliano Buffa<sup>2</sup>  
and Francesco Musumeci<sup>1</sup>

1 Department of Cardiac Surgery and Heart Transplantation, San Camillo Forlanini Hospital, Rome, Italy

2 Cardio-Vascular Radiology Unit, San Camillo Forlanini Hospital, Rome, Italy

\*Address all correspondence to: agcammardella@gmail.com

### IntechOpen

© 2019 The Author(s). Licensee IntechOpen. This chapter is distributed under the terms of the Creative Commons Attribution License (<http://creativecommons.org/licenses/by/3.0>), which permits unrestricted use, distribution, and reproduction in any medium, provided the original work is properly cited. 

## References

- [1] Durko AP, Osnabrugge RL, Van Mieghem NM, Milojevic M, Mylotte D, Nkomo VT, et al. Annual number of candidates for transcatheter aortic valve implantation per country: Current estimates and future projections. *European Heart Journal*. 2018;**39**(28):2635-2642
- [2] De Sciscio P, Brubert J, De Sciscio M, Serrani M, Stasiak J, Moggridge GD. Quantifying the shift toward transcatheter aortic valve replacement in low-risk patients: A meta-analysis. *Circulation. Cardiovascular Quality and Outcomes*. 2017;**10**(6):e003287
- [3] Otto CM, Kumbhani DJ, Alexander KP, Calhoon JH, Desai MY, Kaul S, et al. ACC expert consensus decision pathway for transcatheter aortic valve replacement in the management of adults with aortic stenosis: A report of the American College of Cardiology task force on clinical expert consensus documents. *The Journal of the American College of Cardiology*. 2017;**69**(10):1313-1346
- [4] Baumgartner H, Falk V, Bax JJ, De Bonis M, Hamm C, Holm PJ, et al. ESC/EACTS guidelines for the management of valvular heart disease. *The European Heart Journal*. 2017;**38**(36):2739-2791
- [5] Nishimura RA, Otto CM, Bonow RO, Carabello BA, Erwin JP 3rd, Fleisher LA, et al. 2017 AHA/ACC focused update of the 2014 AHA/ACC guideline for the management of patients with valvular heart disease: A report of the American College of Cardiology/American Heart Association task force on clinical practice guidelines. *Circulation*. 2017;**135**(25):e1159-e1e95
- [6] Bax JJ, Delgado V, Bapat V, Baumgartner H, Collet JP, Erbel R, et al. Open issues in transcatheter aortic valve implantation. Part 1: Patient selection and treatment strategy for transcatheter aortic valve implantation. *European Heart Journal*. 2014;**35**(38):2627-2638
- [7] Blanke P et al. Computed tomography imaging in the context of transcatheter aortic valve implantation (TAVI)/Transcatheter aortic valve replacement (TAVR): An expert consensus document of the Society of Cardiovascular Computed Tomography. *JACC: Cardiovascular Imaging*. 2019;**12**(1):1-24
- [8] Roberts WC, Janning KG, Ko JM, Filardo G, Matter GJ. Frequency of congenitally bicuspid aortic valves in patients  $\geq 80$  years of age undergoing aortic valve replacement for aortic stenosis (with or without aortic regurgitation) and implications for transcatheter aortic valve implantation. *The American Journal of Cardiology*. 2012;**109**(11):1632-1636
- [9] Mack MJ, Brennan JM, Brindis R, Carroll J, Edwards F, Grover F, et al. Outcomes following transcatheter aortic valve replacement in the United States. *Journal of the American Medical Association*. 2013;**310**(19):2069-2077
- [10] Sievers HH, Schmidtke C. A classification system for the bicuspid aortic valve from 304 surgical specimens. *The Journal of Thoracic and Cardiovascular Surgery*. 2007;**133**(5):1226-1233
- [11] Jilaihawi H, Chen M, Webb J, Himbert D, Ruiz CE, Rodes-Cabau J, et al. A bicuspid aortic valve imaging classification for the TAVR era. *JACC: Cardiovascular Imaging*. 2016;**9**(10):1145-1158
- [12] Yoon S-H, Bleiziffer S, De Backer O, et al. Outcomes in transcatheter aortic valve replacement for bicuspid versus tricuspid aortic valve stenosis. *Journal*

of the American College of Cardiology. 2017;**69**(21):2579-2589

[13] Abdel-Wahab M, Zahn R, Horack M, Gerckens U, Schuler G, Sievert H, et al. Transcatheter aortic valve implantation in patients with and without concomitant coronary artery disease: Comparison of characteristics and early outcome in the German multicenter TAVI registry. *Clinical Research in Cardiology*. 2012;**101**(12):973-981

[14] Leon MB, Smith CR, Mack MJ, Makkar RR, Svensson LG, Kodali SK, et al. Transcatheter or surgical aortic-valve replacement in intermediate-risk patients. *The New England Journal of Medicine*. 2016;**374**(17):1609-1620

[15] Reardon MJ, Van Mieghem NM, Popma JJ, Kleiman NS, Sondergaard L, Mumtaz M, et al. Surgical or transcatheter aortic-valve replacement in intermediate-risk patients. *The New England Journal of Medicine*. 2017;**376**(14):1321-1331

[16] Kotronias RA, Kwok CS, George S, Capodanno D, Ludman PF, Townend JN, et al. Transcatheter aortic valve implantation with or without percutaneous coronary artery revascularization strategy: A systematic review and meta-analysis. *Journal of the American Heart Association*. 2017;**6**(6)

[17] Bax JJ, Delgado V, Bapat V, Baumgartner H, Collet JP, Erbel R, et al. Open issues in transcatheter aortic valve implantation. Part 2: Procedural issues and outcomes after transcatheter aortic valve implantation. *European Heart Journal*. 2014;**35**(38):2639-2654

[18] Biasco L, Ferrari E, Pedrazzini G, Faletra F, Moccetti T, Petracca F, et al. Access sites for TAVI: Patient selection criteria, technical aspects, and outcomes. *Frontiers in Cardiovascular Medicine*. 2018;**5**:88

[19] Blanke P, Weir-McCall JR, Achenbach S, Delgado V, Hausleiter J, Jilaihawi H, et al. Computed tomography imaging in the context of transcatheter aortic valve implantation (TAVI)/transcatheter aortic valve replacement (TAVR): An expert consensus document of the society of cardiovascular computed tomography. *JACC Cardiovasc Imaging*. 2019;**12**(1):1-24

[20] Okuyama K, Jilaihawi H, Kashif M, Takahashi N, Chakravarty T, Pokhrel H, et al. Transfemoral access assessment for transcatheter aortic valve replacement: Evidence-based application of computed tomography over invasive angiography. *Circulation. Cardiovascular Imaging*. 2015;**8**(1)

[21] Toggweiler S, Gurvitch R, Leipsic J, Wood DA, Willson AB, Binder RK, et al. Percutaneous aortic valve replacement: Vascular outcomes with a fully percutaneous procedure. *Journal of the American College of Cardiology*. 2012;**59**(2):113-118

[22] Genereux P, Webb JG, Svensson LG, Kodali SK, Satler LF, Fearon WF, et al. Vascular complications after transcatheter aortic valve replacement: Insights from the PARTNER (placement of AoRTic TraNscathetER valve) trial. *Journal of the American College of Cardiology*. 2012;**60**(12):1043-1052

[23] Kadakia MB, Herrmann HC, Desai ND, Fox Z, Ogbara J, Anwaruddin S, et al. Factors associated with vascular complications in patients undergoing balloon-expandable transfemoral transcatheter aortic valve replacement via open versus percutaneous approaches. *Circulation. Cardiovascular Interventions*. 2014;**7**(4):570-576

[24] Bernardi FL, Gomes WF, de Brito FS Jr, Mangione JA, Sarmiento-Leite R, Siqueira D, et al. Surgical cutdown

versus percutaneous access in transfemoral transcatheter aortic valve implantation: Insights from the Brazilian TAVI registry. *Catheterization and Cardiovascular Interventions*. 2015;**86**(3):501-505

[25] Cribier A, Litzler PY, Eltchaninoff H, Godin M, Tron C, Bauer F, et al. Technique of transcatheter aortic valve implantation with the Edwards-Sapien heart valve using the transfemoral approach. *Herz*. 2009;**34**(5):347-356

[26] Stortecky S, Buellesfeld L, Wenaweser P, Windecker S. Transcatheter aortic valve implantation: The procedure. *Heart*. 2012;**98**(Suppl 4):iv44-iv51

[27] Ye J, Cheung A, Lichtenstein SV, Carere RG, Thompson CR, Pasupati S, et al. Transapical aortic valve implantation in humans. *The Journal of Thoracic and Cardiovascular Surgery*. 2006;**131**(5):1194-1196

[28] Pascual I, Carro A, Avanzas P, Hernandez-Vaquero D, Diaz R, Rozado J, et al. Vascular approaches for transcatheter aortic valve implantation. *Journal of Thoracic Disease*. 2017;**9**(Suppl 6):S478-SS87

[29] Koehler T, Buege M, Schleiting H, Seyfarth M, Tiroch K, Vorpahl M. Changes of the eSheath outer dimensions used for transfemoral transcatheter aortic valve replacement. *BioMed Research International*. 2015;**2015**:572681

[30] Kasel AM, Cassese S, Bleiziffer S, Amaki M, Hahn RT, Kastrati A, et al. Standardized imaging for aortic annular sizing: Implications for transcatheter valve selection. *JACC: Cardiovascular Imaging*. 2013;**6**(2):249-262

[31] Hansson NC, Norgaard BL, Barbanti M, Nielsen NE, Yang TH,

Tamburino C, et al. The impact of calcium volume and distribution in aortic root injury related to balloon-expandable transcatheter aortic valve replacement. *Journal of Cardiovascular Computed Tomography*. 2015;**9**(5):382-392