

We are IntechOpen, the world's leading publisher of Open Access books Built by scientists, for scientists

6,900

Open access books available

186,000

International authors and editors

200M

Downloads

Our authors are among the

154

Countries delivered to

TOP 1%

most cited scientists

12.2%

Contributors from top 500 universities



WEB OF SCIENCE™

Selection of our books indexed in the Book Citation Index
in Web of Science™ Core Collection (BKCI)

Interested in publishing with us?
Contact book.department@intechopen.com

Numbers displayed above are based on latest data collected.
For more information visit www.intechopen.com



The Impact of Nailfold Capillaroscopy in the Approach of Microcirculation

*Vera Bernardino, Ana Rodrigues, Ana Lladó,
Melissa Fernandes and António Panarra*

Abstract

Nailfold capillaroscopy (NFC) is a simple, validated, and noninvasive method to assess the microcirculation, through direct visualization of the capillaries. Main patterns are classified, according to Cutolo et al., as scleroderma, further divided into early, active, or late patterns, or nonscleroderma. NFC findings include dilated loops, tortuosities, meandering or bushy capillaries, hemorrhage, or architectural distortion. NFC use has been indicated for the evaluation of Raynaud's phenomenon (RP), once it permits the distinction between primary and secondary RP. NFC results accounts for diagnostic criteria of systemic sclerosis, but they can also be useful in staging other connective tissue autoimmune diseases, like systemic lupus erythematosus, inflammatory myositis, or vasculitis. The CSURI index uses NFC for prediction of digital ulcer relapse. Recent evidence revealed NFC can also be applied in systemic disorders with vascular involvement.

Keywords: nailfold capillaroscopy, microcirculation, Raynaud's phenomenon, connective tissue autoimmune disorders, vasculitides

1. Introduction

Nailfold capillaroscopy (NFC) is a noninvasive, simple, and highly sensitive technique used in the study of microcirculation, as it permits direct visualization of nailfold capillaries [1, 2]. The understanding of NFC results from years of research in Raynaud's phenomenon (RP) in rheumatic diseases. In fact, this method is a paramount tool to differentiate between primary and secondary RP and, associated with autoantibodies, contributes for an early detection of systemic autoimmune connective tissue disorders (AICTD), as microcirculation abnormalities can arise as first manifestations of these diseases [3–5]. Its importance has reached a global recognition and validation as it became a classification criterion for systemic sclerosis, pointing 2 out of a minimum of 9 points to perform the diagnosis [6].

Ensuing studies have been disclosing the relationship between NFC abnormalities and some clinical syndromes or diseases, as digital ulcers, myositis, pulmonary hypertension, heart failure severity, diabetes mellitus, and arterial hypertension, among others [7–13]. Capillaroscopy can also be useful in monitoring the microvascular impact of certain drugs, as systemic vasodilators [2]. A role of NCF as a prognostic tool has been established with the Capillaroscopic Skin Ulcer Risk Index

(CSURI), to predict the appearance of new scleroderma ulcers and/or persistence of nonhealing lesions, within 3 months from NFC exam [14]. It has a good sensitivity, specificity, and positive predictive value, even in different devices. Its reliability has been successively demonstrated by European League Against Rheumatism (EULAR) study groups [15–17].

Indications for NFC do not resume to RP or other vascular acrosyndromes approach. It should be performed to any patient with microcirculation involvement from a systemic disease that includes AICTD, like systemic sclerosis, idiopathic inflammatory myositis, mixed connective tissue disease, and systemic lupus erythematosus, among others, but also other systemic diseases associated to microangiopathy, like vasculitides, diabetes, and arterial hypertension. As it also plays an important role in diagnosis, prognosis, and treatment monitoring of some diseases, capillaroscopy can be considered to act as a promising microcirculation biomarker [18].

2. Capillaroscopy procedures

NFC is commonly performed in nailfold cuticles, as the capillary loops become more parallel to the skin surface in this area and can be observed in their full length in the last row [2]. Usually, eight fingers are examined: the 2nd, 3rd, 4th, and 5th [1, 19]. The thumbs are excluded because, in these fingers, capillaries are poorly observed and microtrauma is more frequent due to thumb's opponency. At least four images should be taken from each finger, in order to maximize nailfold area visualization (**Figure 1**). Less than eight nailfold reduces the sensitivity to detect capillary changes [20]. So, in a regular exam, at least 32 pictures are taken from each hand when using a videocapillaroscope.

The patient should stay at least 20 minutes in a climatized room (20–22°C), to reduce RP attacks, and a clinical examination should be performed in his or her hands, in order to avoid traumatic injuries and to detect sclerodactyly, edema, pitting scars, active arthritis, skin lesions, onychophagia, or other possible changes [19, 21]. As several physiological and external factors can affect NFC image quality, patients are asked to avoid cutting cuticle or even the nails in the previous week, prevent nail varnish removal, and avoid smoking or drinking caffeine-containing beverages in the preceding hours [7]. To improve the amount of light reaching the nails and then ameliorate image quality, an immersing oil is used between the skin and the lens.

Different devices can be used for microcirculation visualization:

- Ophthalmoscopes and traditional microscopes: they consist in low cost options and are widely available, which can be used with minimal training; the disadvantages include not only low magnifications (10–20×), but also it is hard handling and it has a poor reproducibility.
- Dermatoscopes: they have an intermediate cost; they are portable devices and easily available and have acceptable resolution and sensitivity for NFC abnormalities; however, they also have magnification restraint (20–40×) and can only detect gross NFC changes, and images are not reproducible.
- Stereomicroscopes: they also have an intermediate cost, they are easy to use, their magnification lens vary from 10–200×, but they are time-consuming and difficult to use in patients with joint contractures and they need an additional camera and fiber optic light source to capture the images, and a specialized training is even required.

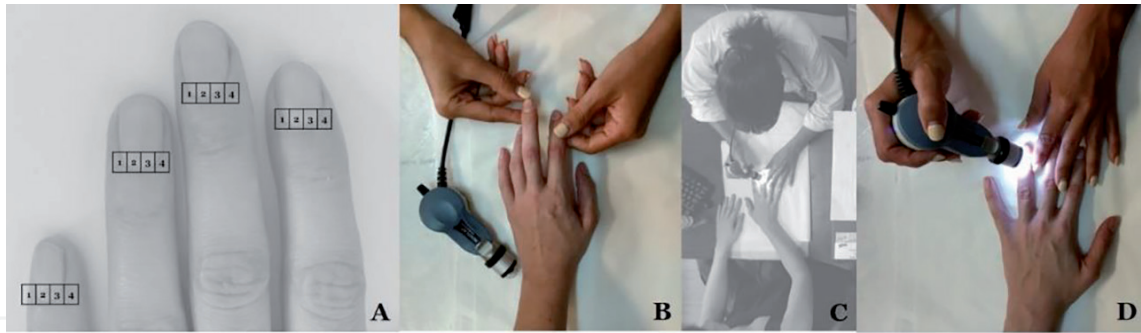


Figure 1.
 Nailfold capillaroscopy should be performed in 2nd, 3rd, 4th, and 5th fingers, dividing each nailfold cuticle into 4 areas and taking images from each of them. (A) Clinical examination of the fingers should be performed before the exam begins. (B) Performing videocapillaroscopy using Videocap biomicroscope, version 3.0. (C, D).

- Videocapillaroscope (**Figure 1**): it has an excellent image quality and reproducibility and variable magnification from 200–600×. It has a portable system enabling its use in patients with severe joint contractures, and it carries specific software for capturing and analyzing the images, yet it is the most expensive option and requires specialized training [7].

NFC procedure includes the assessment of morphologic and some functional parameters: skin transparency, capillary density and orientation, venous plexus visualization, presence of neoangiogenesis or microhemorrhages, capillary loop diameter, length and morphology, and characteristics of blood flow [1, 21]. The number of capillaries has been validated as the most important criterion for the patient follow-up [22].

3. Nailfold capillaroscopy assessment and classification

NFC studies lead to the detection of microvascular abnormalities. Some of them, rarer, have a clear pathological significance and can disclose early an AICTD—they are called the “major abnormalities” [1]. Among those are giant capillaries, capillary architecture disorganization, microhemorrhages, neoangiogenesis, and capillary loss. Other abnormalities, more frequent, have an uncertain pathological meaning and represent an overlap between the scope of normality and microangiopathy—they are called the “minor abnormalities.” Those are principally tortuosity, abnormal shapes, or visibility of the subpapillary venous plexus.

Capillaroscopic parameters are usually evaluated through qualitative, semiquantitative, and quantitative analysis. The qualitative assessment implies pattern recognition and describes the global microvascular array and architecture, shape and distribution of the capillaries, and abnormalities of single loops. It readily allows a distinction between a normal capillaroscopy exam and an abnormal one [20]. The semiquantitative analysis is focused on major NFC changes. The quantitative evaluation estimates capillary density, avascular areas, diameter of enlarged capillaries, and the frequency of each abnormality. The quantification of capillaries includes the number of loops in the distal row in a 1 mm² section of the nailfold (**Figure 2**).

Normal capillaries are hairpin shaped and present a homogeneous distribution, in a “comb-like” structure [1] (**Figure 3**). Capillary density varies from 9 to 14 capillaries per millimeter in adults and at least 6 in children [1, 7, 23]. Abnormal shapes include the following:

- **Tortuous capillaries:** arterial and venous limbs are curled but do not cross [23] (**Figure 4A**).

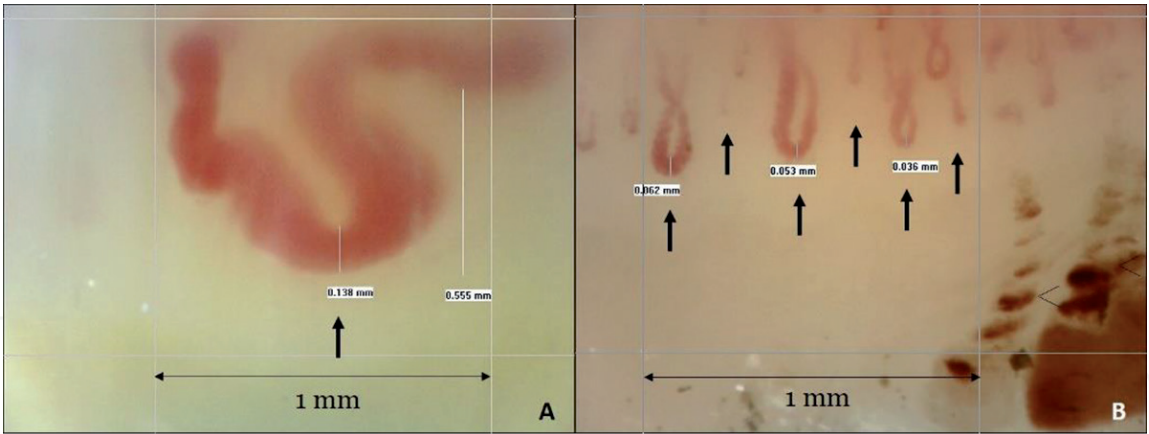


Figure 2. Capillary density. Panel A: 1 capillary/mm²; panel B: 6 capillaries/mm². (arrows) images were taken using Videocap biomicroscope, version 3.0, magnification ×200. Courtesy of Nailfold Capillaroscopy Clinic of Hospital Curry Cabral.

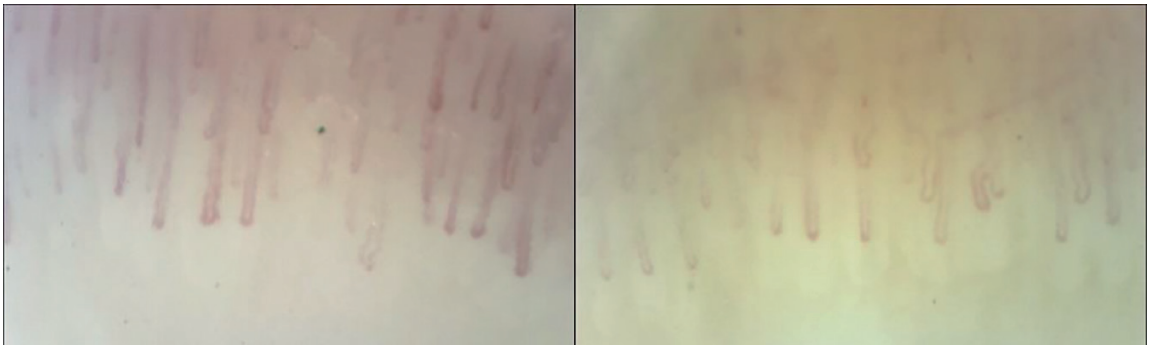

Figure 3. Examples of images of nailfold capillaroscopy captured in healthy subjects and considered as normal. Images were taken using Videocap biomicroscope, version 3.0, magnification ×200. Courtesy of Nailfold Capillaroscopy Clinic of Hospital Curry Cabral.

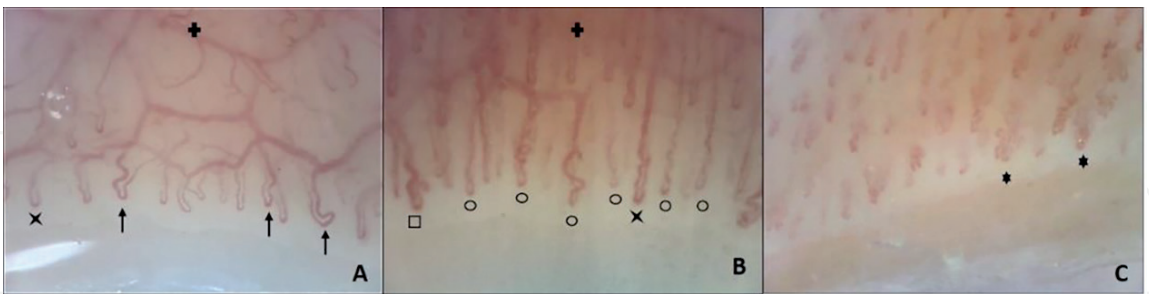


Figure 4. Examples of capillaroscopy abnormalities: Tortuosity (arrow), crossing (X), meandering (black circle), bushy capillaries (six-pointed star), subpapillary plexus visibility (plus sign), and dilated loop (black square). Images were taken using Videocap biomicroscope, version 3.0, magnification ×200. Courtesy of Nailfold Capillaroscopy Clinic of Hospital Curry Cabral.

- Crossing capillaries: arterial and venous limbs cross at one point [23] (**Figure 4B**).
- **Meandering loops:** the limbs cross upon themselves or with each other several times [23] (**Figure 4A**).
- Bushy capillaries: the limb branches present themselves in small and multiple buds [7] (**Figure 4C**).

- **Ramified capillaries:** there are abnormal connections between arterial and venous limbs or different capillaries [7] (**Figure 5**).
- **Neoangiogenesis:** neoformations can be heterogeneous and may comprise shape heterogeneity, four or more capillaries within a single dermal papilla, elongated loops, branching, and interconnected capillaries [1] (**Figure 5**).
- **Bizarre loops:** capillaries with an atypical morphology, distinct from other described categories [23].
- **Dilated or enlarged loops:** there is not a universally accepted definition for loop enlargement, but it is usually considered if the limbs are enlarged about four times the normal width or if the width diameter is $>20\text{ }\mu\text{m}$. Nevertheless, a recent study from Cutolo et al suggests that dilations below $30\text{ }\mu\text{m}$ may be considered nonspecific [23] (**Figure 6**).
- **Megacapillary or giant capillary:** capillaries with homogeneously enlarged loops with a branch diameter above $50\text{ }\mu\text{m}$ [1, 23] (**Figure 6**).
- **Elongated capillaries:** capillary loops longer than $300\text{ }\mu\text{m}$ [7] (**Figure 7**).

Other capillaroscopic parameters include the following:

- **Hemorrhages:** microbleeding appears as dark masses adjacent to distal row, due to hemosiderin deposits. They result from disruption of the capillary wall, either spontaneous or traumatic [1, 7] (**Figure 8**).
- **Avascular areas:** lack of two or more successive capillaries. Loss of capillaries is associated with tissue hypoxia and subsequent digital ulcers and ischemia [7, 23] (**Figure 2**).
- **Subpapillary venous plexus visibility:** observation of large and linked arrangement of vessels with a greater caliber than the capillaries. Enlargement and congestion of venules and capillaries related to persistent opening of arteriovenous anastomoses, thus enabling a greater visibility [1] (**Figure 4**).
- **Capillary blood flow:** with powerful magnifications, when the blood flow is slow, it is possible to see the packs of red blood cells moving as a capillary sludge [1] (**Figure 9**).
- **Capillary array and architecture disarrangement:** when shapes, length, and diameter vary in continuous loops, it leads to a complete distortion of a normal capillary pattern [1] (**Figure 10**).

Major NFC patterns divide into scleroderma and nonscleroderma pattern. Scleroderma pattern was first described by Maricq et al, through a combination of widening of the capillary loop, loss of capillaries, and disorganization of the nailfold capillary bed [1]. This pattern is frequently seen in scleroderma spectrum disorders, like systemic sclerosis, dermatomyositis, and mixed connective tissue disease and in RP without a clear diagnosis. Later, Cutolo et al further classified the scleroderma pattern into “early,” “active,” and “late” stages. “Early” scleroderma pattern presents with few giant capillaries and hemorrhages, relatively well-preserved capillary

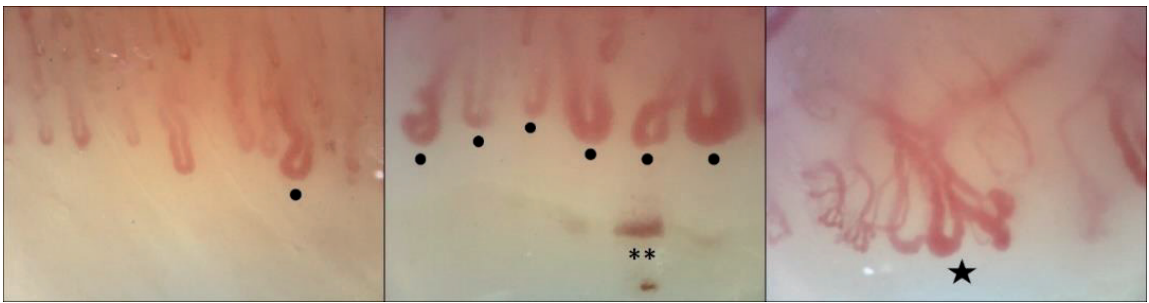


Figure 5. Images from three different phases of scleroderma pattern, belonging to three different patients: Early, active, and late (from left to right). Capillary density decreases from early to late pattern. Capillaroscopic findings include giant capillaries (black spot), hemorrhages (**), and neoangiogenesis (star). Images were taken using Videocap biomicroscope, version 3.0, magnification $\times 200$. Courtesy of Nailfold Capillaroscopy Clinic of Hospital Curry Cabral.

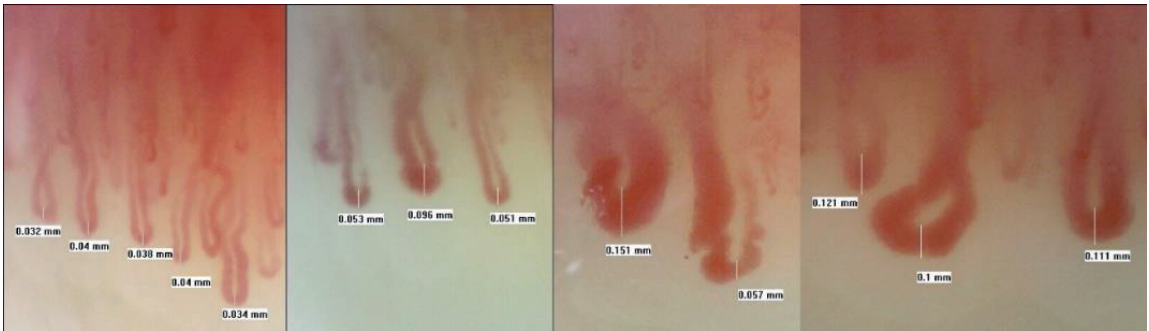


Figure 6. Capillary limb dilatation: Dilated (diameter $\geq 30 \mu\text{m}$) and giant (diameter $\geq 50 \mu\text{m}$) capillaries. Images were taken using Videocap biomicroscope, version 3.0, magnification $\times 200$. Courtesy of Nailfold Capillaroscopy Clinic of Hospital Curry Cabral.

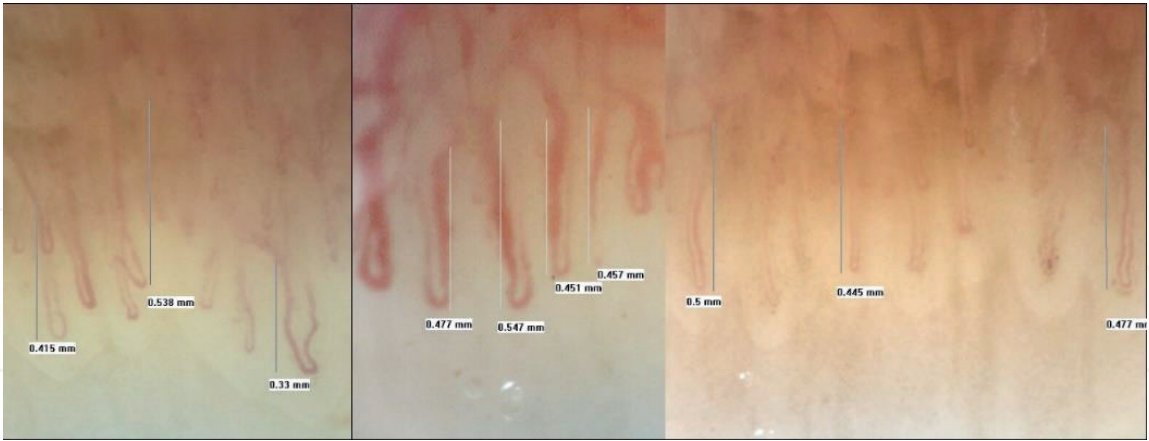


Figure 7. Elongated capillaries (capillary loops $\geq 300 \mu\text{m}$). Images were taken using Videocap biomicroscope, version 3.0, magnification $\times 200$. Courtesy of Nailfold Capillaroscopy Clinic of Hospital Curry Cabral.

distribution, and no loss of capillaries. “Active” scleroderma pattern reveals frequent giant capillaries and hemorrhages, moderate loss of capillaries, mild disorganization of capillary bed, and absent or mild ramified capillaries (i.e., neoangiogenesis). “Late” scleroderma pattern shows an irregular enlargement of the capillaries, few or absent giant capillaries and hemorrhages, severe loss of capillaries with avascular areas (the *plages désertes*), and ramified or bushy capillaries (**Figure 5**).

In healthy subjects, anatomic variations occur, and capillary abnormalities can be found. The estimated prevalence of these changes are meandering loops in 25%,

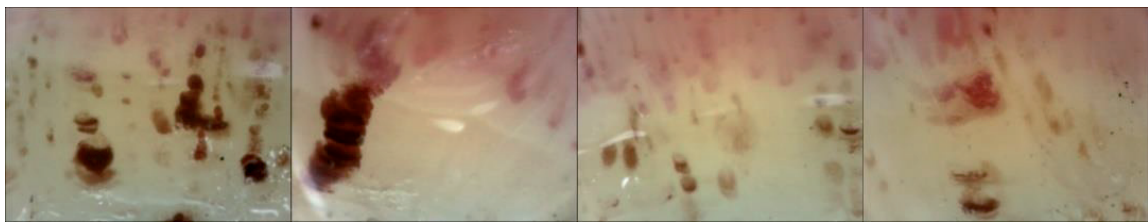


Figure 8.
Examples of nailfold hemorrhages in patients with different diseases. Images were taken using Videocap biomicroscope, version 3.0, magnification $\times 200$. Courtesy of Nailfold Capillaroscopy Clinic of Hospital Curry Cabral.

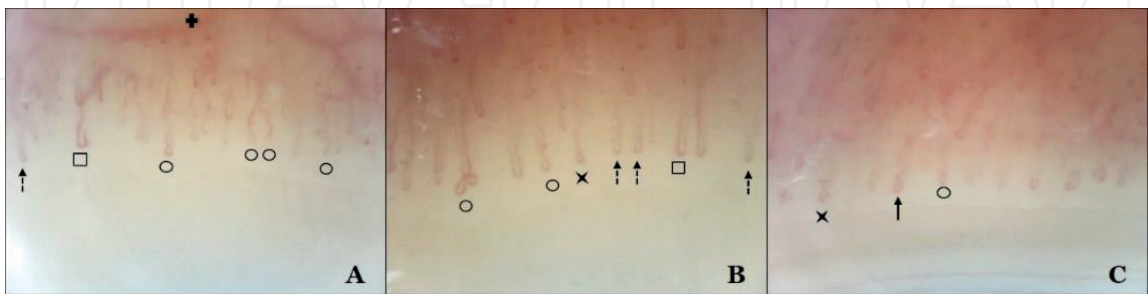

Figure 9.
Images from a single patient with Sjögren syndrome, presenting dilated loops (black square), meandering (black circle), crossing (X), reduced capillary flow with sludge (dashed arrow), and ingurgitated venous plexus (plus sign). (A: 5th finger of the right hand; B: 2nd finger of the left hand; C: 4th finger of the right hand.) images were taken using Videocap biomicroscope, version 3.0, magnification $\times 200$. Courtesy of Nailfold Capillaroscopy Clinic of Hospital Curry Cabral.

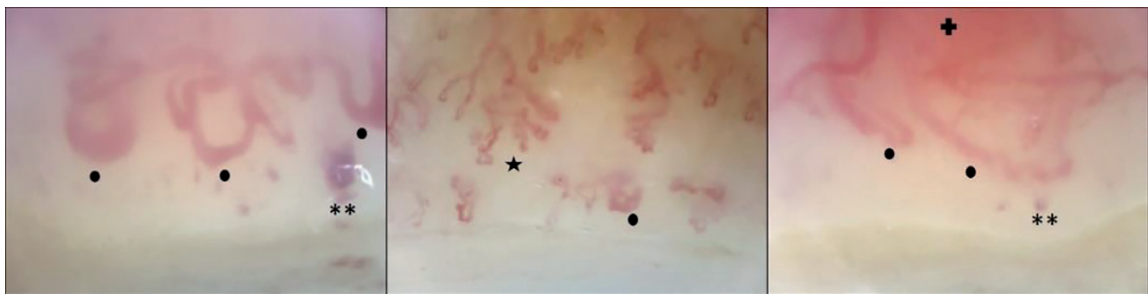


Figure 10.
*Dermatomyositis-images from 3 different patients, revealing reduced capillary density, with a complete distortion of the vascular array, neoangiogenesis (star), giant capillaries (black dot), and hemorrhages (**). Venous plexus is also ingurgitated (plus sign). Images were taken using Videocap biomicroscope, version 3.0, magnification $\times 200$. Courtesy of Nailfold Capillaroscopy Clinic of Hospital Curry Cabral.*

dilated capillaries in 12%, bushy loops in 7%, bizarre loops in 2%, and giant capillaries in 0.3% of the healthy population [23].

4. Nailfold capillaroscopy in autoimmune connective tissue diseases

AICTD complex pathogenesis usually includes microvascular changes, with occurrence of progressive structural and functional damage of the capillaries. Therefore, NFC became an important diagnostic and prognostic tool to use while managing these disorders.

4.1 Systemic sclerosis (SSc)

Systemic sclerosis has probably been the most studied disease with NFC. It is a severe AICTD in which the main pathological events are endothelial dysfunction,

fibrosis, and inflammation, which usually results in skin and vascular changes [24]. These include an important damage of microvascular network, with enlarged and giant capillaries, capillary loss with disarrangement of capillaries' architecture, and neoangiogenesis. As mentioned above, the scleroderma patterns are divided into three different patterns: "early," revealing only few enlarged capillaries, few hemorrhages, and preserved capillary density; "active," showing frequent giant capillaries and hemorrhages, mild capillary loss, and disorganization of the microvascular network; and "late," where irregular and giant capillaries can be found, as with few hemorrhages, neoangiogenesis, and avascular areas [25] (**Figure 5**).

A large multinational study based on EULAR Scleroderma Trials and Research (EUSTAR) registry disclosed a scleroderma pattern in more than 86% of SSc patients [24]. Subjects without this pattern did not have organ involvement and RP and some had negative autoantibodies. These results suggest that although these patients were classified as having an SSc, they did not have an overt disease and, then, nonspecific NFC changes may precede an evolving scleroderma pattern. In patients with overt disease, capillaroscopic findings mirror somehow internal organ involvement evolution. Following disease progression, dynamic transition of microvascular abnormalities through different NFC patterns can be found in up to 50% of SSc patients [18, 26]. On the other hand, capillaroscopy patterns can improve after up to 4 years of combined treatment, revealing a progressive significant recovery in structure and function of microcirculation, associated to ameliorated outcomes, independently of disease severity [27–29].

Capillaroscopy abnormalities became one of the diagnostic criteria for SSc in the 2013 classification [6]. NFC should not only be used for a diagnostic purpose but also for monitoring the disease process and determining its prognosis, because, as explained above, its dynamic changes occur, and its severity directly relates to the extent of organ involvement [8].

4.2 Systemic lupus erythematosus (SLE)

A systematic review was recently performed by a EULAR study group, in order to establish capillaroscopic parameters in SLE patients and its correlations with clinical and laboratory characteristics [30]. According to this study, SLE patients present more tortuous and abnormal capillaries than healthy controls, as well as more hemorrhages (**Figure 11**). An NFC score was created by these authors to set the microangiopathy severity, SLE patients being those who had the higher scores. "Nonspecific patterns" and "scleroderma-like patterns" were also described. A correlation between NFC abnormalities and clinical and laboratory parameters was established, since a relationship between NFC score and SLE activity was disclosed. Further, it is an important note to highlight that, once SLE is a heterogeneous disease, with altered vascular involvement, probably capillaroscopic changes will only be seen in the active phase of the disease [31]. Also, as the microvasculopathy profile in SLE is quite different from the SSc's, which is typically obliterative, changes as neoangiogenesis are less common in SLE patients [32, 33].

4.3 Inflammatory idiopathic myositis

In inflammatory idiopathic myopathies (IIM), it is frequent to find tortuosities, capillary loss, enlarged and giant capillaries, microhemorrhages, and neoangiogenesis, as well as a disorganization of the vascular network and avascular areas [1, 34]. In dermatomyositis (DM), patients present more severe NFC findings, compared with those with polymyositis (PM). Ramified and bushy capillaries represent a hallmark of microvascular damage in DM (**Figure 10**). In these patients,

capillaroscopic abnormalities seem to be related with disease duration: in the first 6 months of disease duration, capillary density is usually reduced and giant capillaries are frequent; after that period, scleroderma pattern becomes more common. In PM patients, NFC findings do not significantly differ from healthy controls. It has also been demonstrated that there is a potential relationship between capillary changes and organ involvement, especially in patients with lung disease [35].

A recent multicenter study in antisynthetase syndrome revealed that NFC changes are usually independent from the presence of RP [27]. In these patients, the scleroderma pattern is associated to positivity for anti-Jo1 antibodies and a longer disease duration. An interesting finding was that significant correlation was established between ILD and ramified capillaries, but not with SSc-like pattern.

Together, these studies suggest that NFC can become an important indicator of interstitial lung disease in patients with IIM, disclosing early this potential life-threatening manifestation.

4.4 Mixed connective tissue disease (MCTD)

In MCTD, different abnormalities can be found: minor changes, hemorrhages, dilated and giant capillaries, reduced density, and neoangiogenesis [19] (**Figure 12**). The patients can present with a scleroderma-like pattern, but less severe when compared to systemic sclerosis. The dilated loops are usually more dystrophic, and the dilated loops are long. The neoangiogenesis features are normally present in patients who progress to SSc. The avascular areas are more frequent in patients with pulmonary involvement or under immunosuppressants [36].

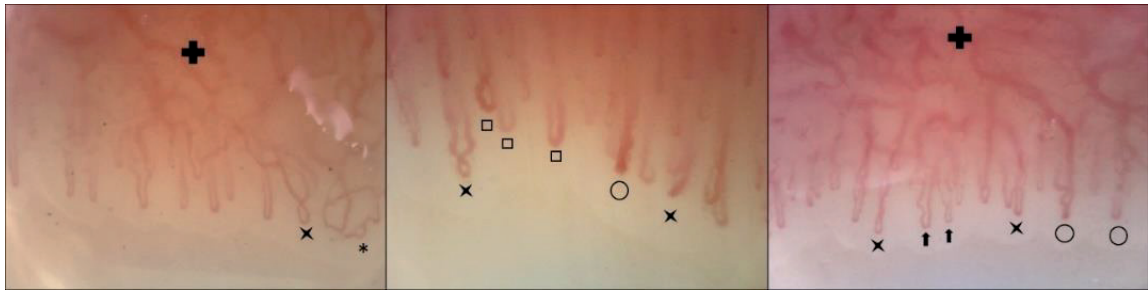


Figure 11.
Systemic lupus erythematosus. Images from three different patients, revealing crossing capillaries (x), dilated loops (square), meandering capillaries (black circle), tortuosities (arrow), ingurgitated venous plexus (plus sign), and loop aneurysm (). Images were taken using Videocap biomicroscope, version 3.0, magnification ×200. Courtesy of Nailfold Capillaroscopy Clinic of Hospital Curry Cabral.*

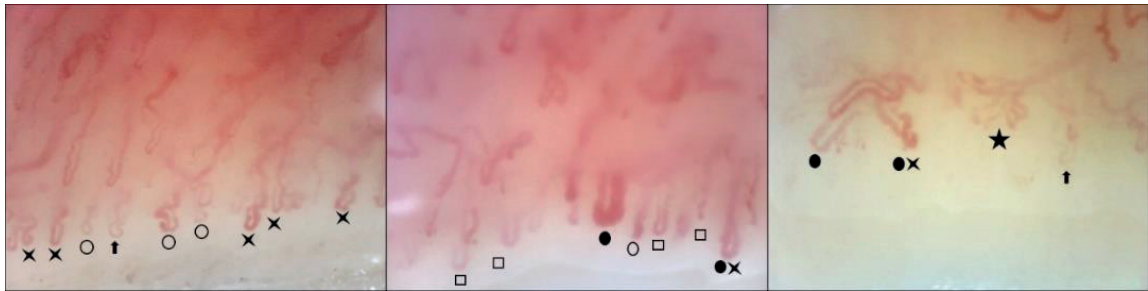


Figure 12.
Images from 3 different patients with mixed connective tissue disease. Capillaroscopic findings include crossing (x), meandering (black circle), tortuosity (arrow), dilated loops (black square), giant capillaries (black dot), neoangiogenesis (black star), and clear avascular areas on the right image. Images were taken using Videocap biomicroscope, version 3.0, magnification ×200. Courtesy of Nailfold Capillaroscopy Clinic of Hospital Curry Cabral.

4.5 Sjögren syndrome

In patients with Sjögren syndrome (SSj), NFC can be normal in up to 59% of cases, if RP is absent [19]. The more frequent findings in this disease are tortuosities, crossings, and ingurgitated venous plexus (**Figure 9**). In patients carrying positive anticontromere antibody, dilated loops and giant capillaries can also be found. No correlations were stated between NFC changes and laboratory parameters.

4.6 Rheumatoid arthritis

The different abnormalities found in rheumatoid arthritis patients confirm the coexistence of microangiopathy in this disease [37]. In patients without rheumatoid vasculitis, it is frequent to find thin, long, and tortuous capillaries, with ingurgitated anarchic venous plexus and microhemorrhages [19]. These changes have no correlation with disease activity. Dilated or giant capillaries are rare and justify a closer follow-up.

4.7 Psoriasis

NFC in psoriasis usually reveals a reduced capillary density, with avascular areas, and morphologically abnormal capillaries [38]. No correlation was found between capillary density and disease duration or the extent of skin involvement, but avascular areas are more frequent in patients whose nails are also affected. If the exam is performed over the psoriasis plaques, dilated and long loops can be seen, with interstitial edema and fast blood flow [19].

5. Nailfold capillaroscopy in noninfectious vasculitides

Vasculitides evolve by inflammation of vessels, which include capillaries. NFC can, then, provide valuable information on the approach of patients with vasculitis. Although scarce research has been made in this field, a recent systematic review, following Chapel-Hill nomenclature, puts in evidence that NFC is more useful in small than in large vessel vasculitides [39, 40]. However, as large vessel vasculitides also involve microcirculation, the presence of NFC changes in these disorders cannot be excluded. Besides, NFC can also give important information about organ involvement and disease activity [41, 42].

The microangiopathy in vasculitides reveals several and heterogeneous NFC changes, but generally nonspecific, when compared to scleroderma pattern. Increased tortuosity; microhemorrhages; enlarged, bushy, and bizarre capillaries; and architectonic disarrangement are the most frequent findings [39]. In some cases, however, the described NFC abnormalities include capillary dilation and reduced density, which are usually associated with scleroderma spectrum diseases. Whether a deep capillary damage is due to primary vasculitis or if there is a possible overlap of cases with scleroderma-related disorders is yet to be clarified.

5.1 Large vessel vasculitis

A recent study revealed that in Takayasu arteritis (TA) capillaries are affected due to hypoperfusion [43]. NFC abnormalities found were reduced capillary length and venous limb diameter and tortuosity, but, in hands with subclavian involvement, these changes were more severe. Capillary diameter was then considered as an example of subclavian artery stenosis alteration due to disease progression.

We found no data about nailfold capillaroscopy in giant cell arteritis.

5.2 Medium vessel vasculitis

In polyarteritis nodosa, NFC can be normal in the absence of Raynaud's phenomenon [19]. Yet, in its presence, changes include reduced capillary density, microhemorrhages, and edema. When digital ischemia is present, important edema, capillary flow sludge, and multiple hemorrhages can be seen (**Figure 13**).

Only one study about Kawasaki disease and NFC was found and it involved 64 pediatric patients [44]. Microcirculation abnormalities found included reduced density, dilation of arterial and venous limb diameters, higher intercapillary distance, and abnormal loops. The latter two were related to disease activity, as they improved from postacute to convalescent phase. Blood velocity was associated with increased coronary artery diameter.

5.3 Small vessel vasculitis

- Antineutrophil cytoplasmic antibody (ANCA)-associated vasculitis

Microcirculation abnormalities of granulomatosis with polyangiitis, formerly Wegener's granulomatosis, were described in one study involving 12 patients [45]. The main NFC changes detected were avascular areas; crossed and bushy capillaries; and microhemorrhages. No relationship was established with disease activity or its clinical aspects.

No valuable information was found about NFC in microscopic polyangiitis and eosinophilic granulomatosis with polyangiitis-former Churg-Strauss vasculitis.

- Immune complex small vessel vasculitis

NFC changes in cryoglobulinemic vasculitis were disclosed in one study with 29 patients, of which 28 had hepatitis C infection [41]. Microcirculation abnormalities detected were tortuosity, altered orientation, shortened capillaries, and neoangiogenesis (**Figure 14**). No relation was found with disease activity, but glomerulonephritis was associated with a higher score of NFC alterations.

IgA vasculitis (IAV), formerly called Henoch-Schönlein purpura, rarely affects adults and studies about NFC changes have been performed in small samples of patients in pediatric age [46–48]. The NFC changes in IAV are conflicting, including density reduction, increased capillary length, loop dilatation, persistent edema,

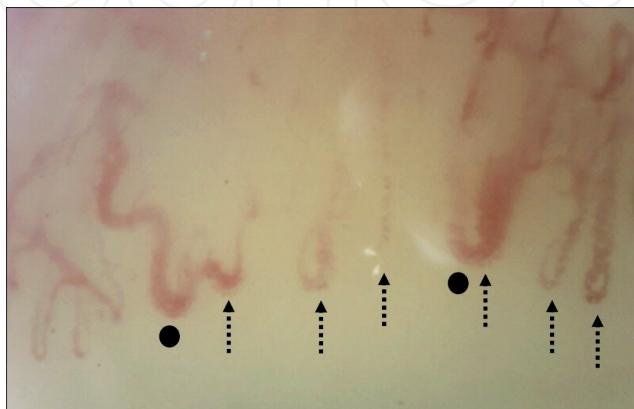


Figure 13. Polyarteritis nodosa. This patient presents with capillary slow flow sludge (dashed arrow), reduced capillary density, but also enlarged capillaries (black dot) (4th finger of the left hand). Images were taken using Videocap biomicroscope, version 3.0, magnification $\times 200$. Courtesy of Nailfold Capillaroscopy Clinic of Hospital Curry Cabral.

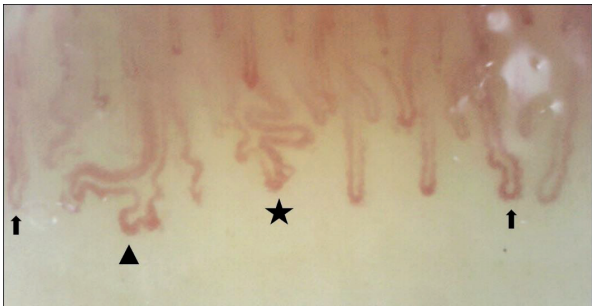

Figure 14. Cryoglobulinemic vasculitis. The image reveals tortuosity (arrow), bifurcation with altered orientation (triangle), and neoangiogenesis (star) (2nd finger of the right hand). Images were taken using Videocap biomicroscope, version 3.0, magnification $\times 200$. Courtesy of Nailfold Capillaroscopy Clinic of Hospital Curry Cabral.

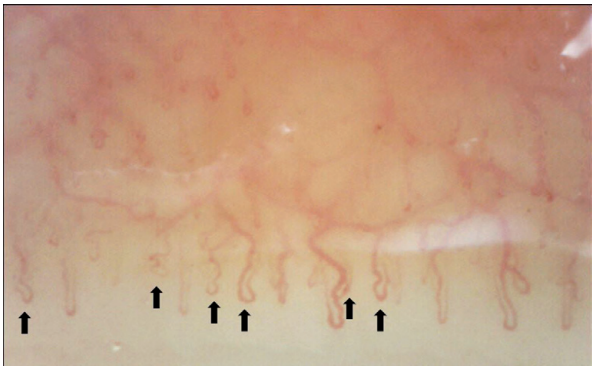


Figure 15. Tortuosity (arrow) in a patient with Behçet disease (4th finger of the left hand). Images were taken using Videocap biomicroscope, version 3.0, magnification $\times 200$. Courtesy of Nailfold Capillaroscopy Clinic of Hospital Curry Cabral.

tortuosity, and branching capillaries. No statistically significant correlation was found between NFC abnormalities and organ involvement, but Zampetti et al. described normalization of the edema after 6-month follow-up.

There was no available data about NFC in anti-glomerular basement membrane disease and hypocomplementemic urticarial vasculitis-former anti-C1q vasculitis.

5.4 Variable vessel vasculitis

Behçet disease (BD) relationship with NFC alterations have been described in some studies, but they all used different technical characteristics for visualization of microcirculation [42, 49–51]. The main NFC abnormalities include enlarged capillaries, microhemorrhages, reduced density, and tortuosity (**Figure 15**). None of them were related with disease activity. Still, some NFC alterations were described as being related with clinical aspects of BD: NFC severity corresponded to longer disease duration and positive pathergy test; enlarged capillaries were associated with younger age at disease onset, high blood pressure, and superficial phlebitis.

We did not find any information about capillaroscopy in Cogan syndrome.

5.5 Vasculitis associated with systemic disease

In rheumatoid vasculitis, some studies correlated with capillary damage and levels of soluble intracellular adhesion molecule-1 (sICAM-1), which is highly expressed during inflammation [52–54]. They found abnormalities in the great majority of

patients, mainly morphologic changes, and although there was no direct relation with disease activity, severe NFC alterations were associated with disease duration, cutaneous vasculitis, joint erosions, systemic vasculitis, and sICAM-1 levels. In a recent study involving 62 patients, scleroderma-like NFC changes were found in 20% of patients with rheumatoid vasculitis and they were interpreted as varying degree of microvascular inhomogeneity, not being necessarily related to overlap syndromes [55, 56].

No specific information was found about NFC in lupus vasculitis or sarcoid vasculitis.

6. Nailfold capillaroscopy in systemic disorders with vascular involvement

6.1 Antiphospholipid syndrome (APS)

Since APS does not derive from connective tissue, we consider more appropriated to approach it in a separated part of this chapter. Capillaroscopy has been studied in APS and attempts were made to include it as a diagnostic tool [57]. NFC findings include microhemorrhages and dilated loops. Long loops and slow flow sludge capillaries are suggestive of a primary APS, while hemorrhages are typical of secondary APS [19] (**Figure 16**). A specific pattern of microhemorrhage, symmetrically disposed, has been called the “comb-like” hemorrhage and is highly associated to APS [1]. Further, positivity for anticardiolipin antibody has been related to higher prevalence of hemorrhages [58]. In spite of this, and even if microhemorrhages significantly correlate with the diagnosis of APS and its clinical manifestations, NFC findings are not sufficient to establish APS diagnosis for its lack of sensitivity and specificity.

6.2 Diabetes mellitus (DM)

In DM, NFC changes are apparently associated to the level of glycemic control and the existence of chronic microvascular complications [9]. However, there is an elevated prevalence of comorbidities concurring for microangiopathy, especially in type 2 diabetes, including arterial hypertension, dyslipidemia, and obesity. Still, a “diabetic capillaropathy” was described, which includes tortuosity, capillaries with bizarre shapes, loop dilations, and avascular areas [9, 59]. No differences were found between type 1 and 2 DM, but microvascular complications detected with NFC were correlated with diabetic peripheral neuropathy [60]. It has also been demonstrated that even in prediabetic patients, microangiopathy can already be

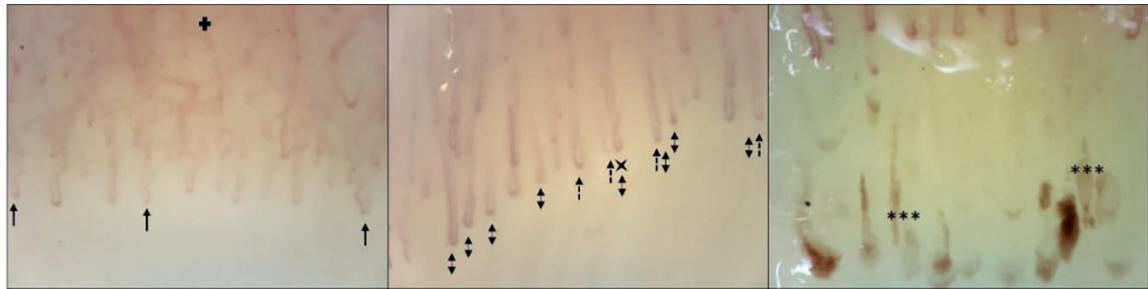


Figure 16. Antiphospholipid syndrome in three different patients, revealing tortuosity (arrow), ingurgitated venous plexus (plus sign), long capillaries (two-way arrow), slow flow sludge (dashed arrow), and “comb-like” hemorrhages (***). Images were taken using Videocap biomicroscope, version 3.0, magnification $\times 200$. Courtesy of Nailfold Capillaroscopy Clinic of Hospital Curry Cabral.

detected. So, it is reasonable to suggest that capillaroscopy could be included in the screening of DM-related complications, since it can easily detect microvascular damage at a peripheric level.

6.3 Arterial hypertension

The available data on NFC in arterial hypertension is scanty, but microangiopathy has been demonstrated in different studies. Decreased capillary density has been described as being related with the mean diastolic pressure and the blood hyperviscosity [61]. These abnormalities are even more severe in the hypertensive elderly population, once capillary loops become longer and narrower. A slow flow capillary sludge is usually found in individuals with a hypertensive systolic pressure. Capillary density is reversible, as it has been proved in different ethnic groups that a reduction in ingested salt would result in augmented capillary density [62]. A different study revealed a significant narrowing of arterial loops in patients with either arterial hypertension or prehypertension stage, regardless of their age [11].

7. Conclusion

Capillaroscopy is a paramount tool in the microcirculation study. Its reliability in the early diagnosis of some AICTD disorders has already been well stated, but it has also proved its great value in treatment monitoring and predicting systemic complications, especially in scleroderma spectrum disorders. In this way, it should be considered as a potential biomarker for microangiopathy.

Until now, scarce data are available about the impact of capillaroscopy on vasculitides approach. However, some studies have shown an active involvement of capillaries in these disorders, apart from the size of the vessels typically involved, which offers a large field and opportunity for further investigation. Large-scale standardized studies are, thus, required to clarify the role of capillaroscopy in vasculitis.

Conflict of interest

The authors declare no conflict of interest.

Author details

Vera Bernardino*, Ana Rodrigues, Ana Lladó, Melissa Fernandes and António Panarra

Internal Medicine 7.2 Department, Nailfold Capillaroscopy Clinic, Hospital Curry Cabral – Centro Hospitalar Universitário Lisboa Central, Lisbon, Portugal

*Address all correspondence to: verarodriguesb@gmail.com

IntechOpen

© 2019 The Author(s). Licensee IntechOpen. This chapter is distributed under the terms of the Creative Commons Attribution License (<http://creativecommons.org/licenses/by/3.0>), which permits unrestricted use, distribution, and reproduction in any medium, provided the original work is properly cited. 

References

- [1] Cutolo M. Atlas of Capillaroscopy in Rheumatic Diseases. Milano: Elsevier; 2012
- [2] Tavakol ME, Fatemi A, Karbalaie A, et al. Nailfold Capillaroscopy in rheumatic diseases: Which parameters should be evaluated? *Journal of Biomedicine and Biotechnology*. 2015;**2015**:974530
- [3] Koenig M, Joyal F, Fritzler MJ, et al. Autoantibodies and microvascular damage are independent predictive factors for the progression of Raynaud's phenomenon to systemic sclerosis: A twenty-year prospective study of 586 patients, with validation of proposed criteria for early systemic sclerosis. *Arthritis and Rheumatism*. 2008;**58**(12):3902-3912
- [4] Cutolo M, Pizzorni C, Tuccio M, et al. Nailfold videocapillaroscopy patterns and serum autoantibodies in systemic sclerosis. *Rheumatology*. 2004;**43**(6):719-726
- [5] Ingegnoli F, Borachi P, Gualtierotti R, et al. Improving outcome prediction of systemic sclerosis from isolated Raynaud's phenomenon: Role of autoantibodies and nailfold capillaroscopy. *Rheumatology*. 2010;**49**(4):797-805
- [6] Van den Hoogen F, Khanna D, Fransen J, et al. 2013 classification criteria for systemic sclerosis: An American college of rheumatology/ European league against rheumatism collaborative initiative. *Arthritis and Rheumatism*. 2013;**65**(11):2737-2747
- [7] Karbalaie A, Emrani Z, Fatemi A, et al. Practical issues in assessing nailfold capillaroscopic images: A summary. *Clinical Rheumatology*. 2019;**38**:2343-2354. DOI: 10.1007/s10067-019-04644-9
- [8] Soulaïdopoulos S, Triantafyllidou E, Garyfallos A, et al. The role of Nailfold capillaroscopy in the assessment of internal organ involvement in systemic sclerosis: A critical review. *Autoimmunity Reviews*. 2017;**16**:787-795
- [9] Lisco G, Cicco G, Cignarelli A, et al. Computerized video-capillaroscopy alterations related to diabetes mellitus and its complications. *Advances in Experimental Medicine and Biology*. 2018;**1072**:363-368
- [10] Emrani Z, Karbalaie A, Fatemi A, et al. Capillary density: An important parameter in nailfold capillaroscopy. *Microvascular Research*. 2017;**109**:7-18
- [11] Gurfinkel Y, Sasonko ML, Priezzhev AV. Digital capillaroscopy as important tool for early diagnostics of arterial hypertension. *Proceedings of SPIE*. 2015;**9448**:944804
- [12] Shirshin EA, Gurfinkel YI, Matskeplishvili ST, et al. In vivo optical imaging of the viable epidermis around the nailfold capillaries for the assessment of heart failure severity in humans. *Journal of Biophotonics*. 2018;**11**(9):e201800066
- [13] Ghizzoni C, Sebastiani M, Manfredi A, et al. Prevalence and evolution of scleroderma pattern in nailfold videocapillaroscopy in systemic sclerosis patients: Clinical and prognostic implications. *Microvascular Research*. 2015;**99**:92-95
- [14] Sebastiani M, Manfredi M, Lo Monaco A, et al. Capillaroscopic skin ulcers risk index (CSURI) calculated with different videocapillaroscopy devices: How its predictive value change. *Clinical and Experimental Rheumatology*. 2013;**31**(2;76):115-117
- [15] Cutolo M, Melsens K, Herrick A, et al. Reliability of simple capillaroscopic definitions in describing capillary morphology in rheumatic

diseases. *Rheumatology*. 2018;**57**(4):757-759

Springer Nature Switzerland AG 2019, M. Matucci-Cerinic, CP Denton

[16] Smith V, Beeckman S, Herrick A, et al. An EULAR study group pilot study on reliability of simple capillaroscopic definitions to describe capillary morphology in rheumatic diseases. *Rheumatology*. 2016;**55**(5):883-890

[24] Ingegnoli F, Ardoino I, Boracchi P. Nailfold capillaroscopy in systemic sclerosis: Data from the EULAR scleroderma trials and research (EUSTAR) database. *Microvascular Research*. 2013;**89**:122-128

[17] Cutolo M, Smith V. State of art on nailfold capillaroscopy: A reliable diagnostic tool and putative biomarker in rheumatology? *Rheumatology*. 2013;**52**(11):1933-1940

[25] Cutolo M, Sulli A, Smith V. Assessing microvascular changes in systemic sclerosis diagnosis and management. *Nature Reviews Rheumatology*. 2010;**6**:578-587

[18] Smith V, Decuman S, Sulli A, et al. Do worsening scleroderma capillaroscopic patterns predict future severe organ involvement? A pilot study. *Annals of the Rheumatic Diseases*. 2012;**71**:1636-1639

[26] Sulli A, Pizzorni C, Smith V, et al. Timing of transition between capillaroscopic patterns in systemic sclerosis. *Arthritis and Rheumatism*. 2012;**64**(3):821-825

[19] Jammal M, Kettaneh A, Cabane J, et al. Capillaroscopie périunguée: une évaluation simple et fiable de toute pathologie de la microcirculation. *La Revue de Médecine Interne*. 2015;**36**:603-612

[27] Cutolo M, Zampogna G, Vremis L, et al. Longterm effects of endothelin receptor antagonism on microvascular damage evaluated by nailfold capillaroscopic analysis in systemic sclerosis. *The Journal of Rheumatology*. 2013;**40**:40-45

[20] Cutolo M, Sulli A, Smith V, et al. How to perform and interpret capillaroscopy. *Best Practice & Research. Clinical Rheumatology*. 2013;**27**(2):237-248

[28] Cutolo M, Ruaro B, Pizzorni C, et al. Longterm treatment with endothelin receptor antagonist bosentan and iloprost improves fingertip blood perfusion in systemic sclerosis. *The Journal of Rheumatology*. 2014;**41**:881-886

[21] FAggioli P, Tamburello A, Sciascera A, et al. Nailfold videocapillaroscopy in internal medicine. *Italian Journal of Medicine*. 2015;**9**:234-242

[29] Trombetta AC, Pizzorni C, Ruaro B, et al. Effects of longterm treatment with bosentan and iloprost on nailfold absolute capillary number, fingertip blood perfusion, and clinical status in systemic sclerosis. *The Journal of Rheumatology*. 2016;**43**:2033-2041

[22] Cutolo M, Herrick AL, Distler O, et al. Nailfold videocapillaroscopic features and other clinical risk factors for digital ulcers in systemic sclerosis: A multicenter, prospective cohort study. *Arthritis & Rheumatology*. 2016;**68**(10):2527-2539

[30] Cutolo M, Melsens K, Wijnant S, et al. Nailfold capillaroscopy in systemic lupus erythematosus: A systematic review and critical appraisal. *Autoimmunity Reviews*. 2018;**17**:344-352

[23] Cutolo M, Sulli A and Smith V. Capillary microscopy. In *Atlas of Ulcers in Systemic Sclerosis*,

- [31] Soltesz P, Kerekes G, Der H, et al. Comparative assessment of vascular function in autoimmune rheumatic diseases: Considerations of prevention and treatment. *Autoimmunity Reviews*. 2011;**10**:416-425
- [32] Murdaca G, Colombo BM, Cagnati P, et al. Endothelial dysfunction in rheumatic autoimmune diseases. *Atherosclerosis*. 2012;**224**:309-317
- [33] Chora I, Guiducci S, Manetti M, et al. Vascular biomarkers and correlation with peripheral vasculopathy in systemic sclerosis. *Autoimmunity Reviews*. 2015;**14**:314-322
- [34] Manfredi A, Sebastiani M, Cassone G, et al. Nailfold Capillaroscopy changes in dermatomyositis and polymyositis. *Clinical Rheumatology*. 2015;**34**:279-284
- [35] Selva-O'Callaghan A, Fonollosa-Pla V, TRallero-Araguás E, et al. Nailfold capillary microscopy in adults with inflammatory myopathy. *Seminars in Arthritis and Rheumatism*. 2010;**39**(5):398-404
- [36] de Holanda A, Bonfá E, Fuller R, et al. Capillaroscopy is a dynamic process in mixed connective tissue disease. *Lupus*. 2007;**16**:254-258
- [37] Vayssairat M, Priollet P. *Atlas pratique de capillaroscopie*. 1ere éd ed. Paris: Les éditions de la revue de Médecine; 1983
- [38] Ribeiro C, Holler A, Skaer T, et al. Periungual capillaroscopy in psoriasis. *Anais Brasileiros de Dermatologia*. 2012;**87**(4):550-553
- [39] Bertolazzi C, Gallegos-Nava S, Villarreal-Treviño A, et al. The current role of capillaroscopy in vasculitides. *Clinical Rheumatology*. 2019;**38**(9):2299-2307. DOI: 10.1007/s10067-018-4399-1
- [40] Jenette JC, Falk RJ, Bacon PA, et al. 2012 revised international Chapel Hill consensus conference nomenclature of vasculitides. *Arthritis & Rheumatology*. 2013;**65**:1-11
- [41] Rossi D, Mansouri M, Baldovino S, et al. Nailfold videocapillaroscopy in mixed cryoglobulinaemia. *Nephrology, Dialysis, Transplantation*. 2004;**19**:2245-2249
- [42] Movasat A, Shahram F, Carreira PE, et al. Nailfold capillaroscopy in Behçet's disease, analysis of 128 patients. *Clinical Rheumatology*. 2009;**28**:603-605
- [43] Javinani A, Pournazari M, JAmshidi A, et al. Nailfold videocapillaroscopy changes in Takayasu arteritis and their association with disease activity and subclavian artery involvement. *Microvascular Research*. 2019;**122**:1-5
- [44] Huang MY, Huang JJ, Huang TY. Deterioration of cutaneous microcirculation status of Kawasaki disease. *Clinical Rheumatology*. 2012;**31**:847-852
- [45] Anders HJ, Haedecke C, Sigl T, et al. Avascular areas on nailfold capillary microscopy of patients with Wegener's granulomatosis. *Clinical Rheumatology*. 2000;**19**:86-88
- [46] Greenberg LW. Nailfold capillary abnormalities in Henoch-Schönlein purpura. *The Journal of Pediatrics*. 1983;**103**:665-666
- [47] Martino F, Agolini D, Tsalikova E. Nailfold capillaroscopy in Henoch-Schönlein purpura: A follow-up study of 31 cases. *The Journal of Pediatrics*. 2002;**141**:145
- [48] Zampetti A, Rigante D, Bersani G, et al. Longitudinal study of microvascular involvement by nailfold capillaroscopy in children with

Henoch-Schönlein purpura. *Clinical Rheumatology*. 2009;**28**:1101-1105

[49] Vaiopoulos G, Pangratis N, Samarkos M. Nailfold capillary abnormalities in Behçet's disease. *The Journal of Rheumatology*. 1995;**22**:1108-1111

[50] Aytekin S, Yuksel EP, Aydin F, et al. Nailfold capillaroscopy in Behçet disease, performed using videodermoscopy. *Clinical and Experimental Dermatology*. 2014;**39**:443-447

[51] Alan S, Balkarli A, Tuna S. The nailfold capillaroscopy findings of Behçet's syndrome. *Dermatologica Sinica*. 2016;**34**:74-77

[52] Kuryliszyn-Moskal A, Bernacka K, Klimiuk PA. Circulation intercellular adhesion molecule 1 in rheumatoid arthritis – Relationship to systemic vasculitis and microvascular injury in nailfold capillary microscopy. *Clinical Rheumatology*. 1996;**15**:367-373

[53] Kuryliszyn-Moskal A. Cytokines and soluble CD4 and CD8 molecules in rheumatoid arthritis: Relationship to systematic vasculitis and microvascular capillaroscopic abnormalities. *Clinical Rheumatology*. 1998;**17**:489-495

[54] Witkowska AM, Kuryliszyn-Moskal A, Borawska MH, et al. A study on soluble intercellular adhesion molecule-1 and selenium in patients with rheumatoid arthritis complicated by vasculitis. *Clinical Rheumatology*. 2003;**22**:414-419

[55] Lambova S, Müller-Ladner U. Capillaroscopic features of microangiopathy in rheumatoid arthritis patients with peripheral vascular syndrome. *Clinical Rheumatology*. 2019;**38**(9):2339-2341. DOI: 10.1007/s10067-019-04561-x

[56] Rajaei A, Dehghan P, Amiri A. Nailfold capillaroscopy in 430

patients with rheumatoid arthritis. *Caspian Journal of Internal Medicine*. 2017;**8**(4):269-274

[57] Pyrpasopoulou A, Triantafyllou A, Anyfanti P, et al. Capillaroscopy as a screening test for clinical antiphospholipid syndrome. *European Journal of Internal Medicine*. 2011;**22**:e158-e159

[58] Sulli A, Pizzoni C, Cutolo M, et al. Nailfold capillaroscopy abnormalities in patients with antiphospholipid antibodies. *The Journal of Rheumatology*. 2000;**27**:1574-1576

[59] Maldonado G, Guerrero R, Paredes C, et al. Nailfold capillaroscopy in diabetes mellitus. *Microvascular Research*. 2017;**112**:41-46

[60] Hsu PC, Liao PY, Chang HH, et al. Nailfold capillary abnormalities are associated with type 2 diabetes progression and correlated with peripheral neuropathy. *Medicine*. 2016;**95**(52):e5714

[61] Gasser P, Bühler FR. Nailfold microcirculation in normotensive and essential hypertensive subjects, as assessed by video-microscopy. *Journal of Hypertension*. 1992;**10**:83-86

[62] He FJ, Marciniak M, Markandu ND, et al. Effect of modest salt reduction on skin capillary rarefaction in white, black and Asian individuals with mild hypertension. *Hypertension*. 2010;**56**:253-259