

We are IntechOpen, the world's leading publisher of Open Access books Built by scientists, for scientists

6,900

Open access books available

185,000

International authors and editors

200M

Downloads

Our authors are among the

154

Countries delivered to

TOP 1%

most cited scientists

12.2%

Contributors from top 500 universities



WEB OF SCIENCE™

Selection of our books indexed in the Book Citation Index
in Web of Science™ Core Collection (BKCI)

Interested in publishing with us?
Contact book.department@intechopen.com

Numbers displayed above are based on latest data collected.
For more information visit www.intechopen.com



Chronic Pain Associated with Lateral Epicondylitis: Treatment with Radiofrequency

*Vicente Vanaclocha, Nieves Saiz-Sapena,
José María Ortiz-Criado and Leyre Vanaclocha*

Abstract

Lateral epicondylitis is a painful condition that impairs the quality of life and the working capacities of many middle-aged people. Conservative treatments offer an opportunity for improvement in the majority of cases. Surgical alternatives can be considered in those patients with persisting pain. Open, arthroscopic and percutaneous extensor tendon procedures offer similar results with 10–20% failure rates. Radiofrequency microtenotomies have been introduced with comparable results to traditional surgical procedures. Although both thermal and pulsed radiofrequency techniques have been applied, there is more experience with the thermal. In the past, thermal radiofrequency has been applied through a 3–5 cm skin incision, but now some researchers have reported its percutaneous application with radiofrequency cannulas. The results are similar to former techniques but with significantly reduced surgical aggressiveness that correlates with less postoperative discomfort and a faster recovery.

Keywords: lateral epicondylitis, radiofrequency, pulsed radiofrequency, radiofrequency microtenotomy, tennis elbow, elbow joint

1. Introduction

Lateral epicondylitis relates to pain in the humeral insertion of the hand extensor tendons, loss of hand grip strength and aggravation of the pain on grasping objects like turning the doorknob or handshaking [1, 2]. The name lateral epicondylitis is a misnomer in itself as it is not an inflammatory process but rather a tendinosis of the humeral insertion of the hand extensor muscles, usually the extensor carpi radialis brevis [3]. Despite its popular name—tennis elbow—only 5–10% of those suffering from it play tennis [4]. This condition arises from repetitive gripping with wrist extension, radial deviation and/or forearm supination [3, 5, 6], and its incidence is 1–3 per 1000 inhabitants/year [7–10]. Lateral epicondylitis can be diagnosed clinically, as direct pressure to the lateral epicondyle reproduces the pain [11], and confirmed with the Thomsen test, in which resisted wrist extension with the elbow in an extended position aggravates the pain [12, 13]. It affects people aged 40–50 years with similar distribution between men and women [7] and can lead to work absenteeism and permanent work incapacities [2, 14].

In about 80% of cases of lateral epicondylitis, symptoms improve over a year [15, 16] often after the offending activity is stopped [17], but in the remaining 20%, it becomes a chronic condition [18].

Physical therapy is a first-line treatment [11, 18–21], which can be supplemented with wrist orthoses [20].

Local steroid injections in the painful areas are commonly used in the treatment of lateral epicondylitis [16, 22] despite being associated with iatrogenic soft tissue calcification [23] and long-term poor outcomes in some cases [24–26].

Botulinum toxin injections weaken temporarily the hand extensor muscles facilitating the healing of the extensor tendon injury [27–29] but can induce weakness in wrist and finger extension, impairing hand grip [28].

Newer treatment modalities include injection in the lateral epicondyle of platelet-rich plasma [30–34], autologous whole blood [35, 36] and stem cell therapy [37, 38]. These are as effective as some more invasive techniques and thus are becoming increasingly popular [31].

Surgical treatment is indicated when all conservative treatments have failed, which occurs in 5–10% of the patients [39–42]. Open surgical resection of the extensor carpi radialis brevis tendon was traditionally the gold standard [43, 44], but recently it is being reevaluated [45]. Some surgeons recommend more extensive procedures with simultaneous posterior interosseous nerve decompression and intra-articular pathology resolution [46], and others prefer collateral ligament repair [47]. To reduce the surgical aggressiveness, several arthroscopic extensor tendon release techniques have been introduced [48–50] finding that they render equivalent clinical results to the open surgical resection of the same anatomical structures [51, 52]. Further refinements are performing the extensor tendon release with an 18-gauge needle [53] or with ultrasound equipment [54]. On comparing open, arthroscopic and percutaneous procedures, no significant differences in clinical outcomes were observed [55], all of them rendering 10–20% of cases with persistent pain and functional incapacity [56–59].

Moreover, lateral epicondyle innervation is provided by sensory branches coming mostly from the radial nerve [60, 61]. Open surgical removal of those branches was attempted [62–64], but it is an aggressive technique and yielded poor clinical results. Other nearby nerves also contribute to the lateral epicondyle pain perception such as the musculocutaneous, the median and the ulnar nerves [60, 65, 66]. Considering that the removal of the sensory branches from all of them was not feasible, other alternatives have been tried.

One of these alternatives is radiofrequency. Radiofrequency—both thermal and pulsed—is a well-established technique for chronic pain treatment [67, 68], but its application to recalcitrant cases of lateral epicondylitis is a relatively new procedure [69, 70]. The rationale was that the pulse radiofrequency modulates the nerve function and alters the pain transmission [71], while the thermal radiofrequency destroys the sensory nerve terminals and induces collagen fibre reorganization [72].

1.1 Lateral epicondylitis radiofrequency treatment: historical background

In 2005, Tasto et al. [70] were the first to report radiofrequency microtenotomy in the treatment of chronic lateral epicondyle pain that persisted after 6 months of conservative treatment. The procedure was performed with a Topaz Microdebrider device (ArthroCare, Sunnyvale, CA) through a 3 cm skin incision. In 13 patients and with a 24-month follow-up, they reported pain amelioration but did not quantify it. No complications were reported. It was Meknas et al. [69] in 2008 using the same equipment and 3 cm skin incision who compared the radiofrequency microtenotomy with the open surgical extensor tendon release and repair. At 18 months, both groups

had similar pain relief rates, but hand grip strength improved only in the radiofrequency group. No side effects were reported. Further studies with more patients and longer follow-ups (7 [13] and 9 [73] years) confirmed these results [74, 75]. The reduced surgical aggressiveness correlated with a shorter operating time [13], lower rates of post-operative discomfort [76] and faster recoveries [75]. The percentage of patients with residual pain was 10% [75], similar to the reported for the open and arthroscopic procedures [57].

The next step was taken by Lin et al. [77] in 2011, where they investigated the applications of percutaneous radiofrequency. With a Radionics RFG-3C Generator (Radionics Inc., Burlington, Massachusetts, USA), special cannulas and under ultrasound guidance, they applied the radiofrequency with no skin incision in 34 patients that had been symptomatic for lateral epicondylitis for over 6 months and had exhausted all conservative treatment options. With an average follow-up of 14.3 months (range 12–21 months), Lin et al. [77] found an improvement of 78% in pain and 20.6–27.0 kg in hand grip strength. No complications were reported.

Subsequently, Weber and Kabelka [78] in 2012 reported the administration of radiofrequency directly on the skin to the lateral epicondyle without needles. The procedure—known as monopolar capacitive-coupled radiofrequency (mcRF)—was applied with the Alpha Orthopaedics' AT2 System (Hayward, CA, USA). This equipment provides a maximum local temperature increase of 50°C [79], damaging selectively the unmyelinated fibres, while the myelinated axons are mostly spared [80]. This study involved 39 patients with an average 14-month follow-up, reporting an 81% successful outcome and an 89% patient satisfaction with no adverse effects.

Another possibility is pulsed radiofrequency, which can be applied without an irreversible neural damage [81] and has been used in many areas of chronic pain management. Oh et al. [82] in 2016 reported its use on elbow pain, aiming at the radial nerve as it crosses the elbow joint. The procedure was performed with a radiofrequency 22G cannula with a 5 mm active tip (SL-S505-2, Neuro-Them, Wilmington, DE, USA). Only two patients were treated this way but showed significant pain relief for 12 months. No long-term results were reported but no statistically significant data can be extracted from two isolated cases.

2. Indications for radiofrequency lateral epicondyle treatment

Patients must have confirmed lateral epicondyle chronic pain that has not been controlled after at least 6 months of conservative treatment [39, 43].

Exclusion criteria: elbow instability, rheumatic arthritis, cervical radiculopathy, severe cervical osteoarthritis and higher-grade extensor tendon damage [69, 74].

3. Surgical techniques for radiofrequency lateral epicondyle treatment

The techniques reported to apply the radiofrequency in the treatment of lateral epicondylitis are the radiofrequency-based microtenotomy, the monopolar capacitive-coupled radiofrequency, the monopolar thermal radiofrequency and the bipolar thermal radiofrequency. To these, we could add the pulsed radiofrequency, but as its use has only been described in two patients and there are no long-term results, we will not describe it.

The technique for radiofrequency-based microtenotomy as performed by several groups [13, 69, 70, 73–75] will be described first. Under general anaesthesia and in the supine position, a tourniquet is applied to the affected arm. The humeral insertion of the extensor tendons is exposed through a 3–5 cm skin incision.

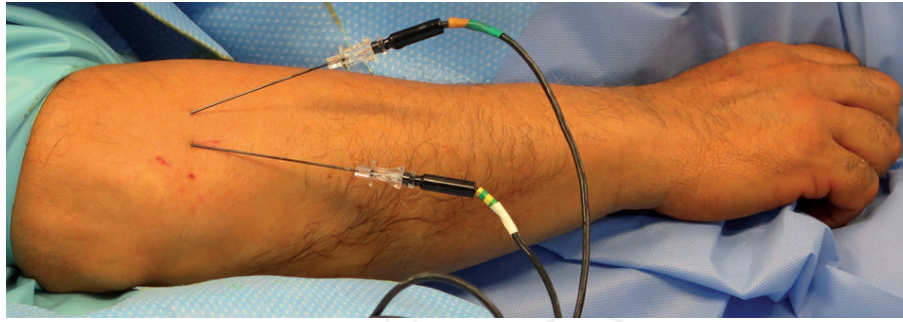


Figure 1.
Bipolar radiofrequency treatment of lateral epicondyle chronic pain.

The tendons from the extensor carpi radialis brevis, the extensor carpi radialis longus and the extensor digitorum communis are identified. The radiofrequency-based microtenotomy is performed with the Topaz Microdebrider electrode. The electrode is inserted 3–5 mm deep inside the extensor carpi radialis brevis tendon at 5 mm intervals in a grid-like pattern. Usually 3–6 lesions are required [13]. Once the procedure is over, the wound is closed by layers. After the procedure, patients are discouraged from heavy work for 6 weeks.

The monopolar capacitive-coupled radiofrequency is performed with the Alpha Orthopaedics' AT2 System and applied directly to the skin without any anaesthetic agent [78, 83]. The painful points are marked and a grid depicted on the skin to guide the treatment's application. A grounding pad is placed on the forearm volar side. The energy pulses are delivered applying the equipment hand piece directly on the skin and concentrated on the most painful points. Patients are advised not to apply ice or NSAIDs over the treated area and to return the next morning to normal daily activities with no restrictions at all [78].

Another alternative is thermal radiofrequency, applied with a Radionics RFG-3C Generator (Radionics Inc., Burlington, Massachusetts, USA) [77]. The procedure is guided and controlled with ultrasound imaging. With the patient in the supine position, the painful lateral epicondyle areas are identified by manual palpation and marked with a pen. After local anaesthetic agent is injected, a 22-gauge cannula is inserted through the skin with a 30–45° angle and advanced to the painful spots parallel to the extensor carpi radialis brevis tendon. To confirm the painful spots, sensory stimulation is applied at 50 Hz frequency and 0.5 V. Muscle stimulation is also performed to rule out proximity of any motor nerve or that the active electrode tip lies inside muscular tissue. Another 0.3 mL of local anaesthetic is injected through the lesioning cannula and the radiofrequency applied to achieve a temperature of 80° for 120 s. For optimal results, the lesion should be performed at the extensor muscle humeral insertion [77]. Patients are allowed to regain normal working activities by 6 weeks after the procedure.

To improve the results, we do a variation of this procedure. The thermal radiofrequency is applied not monopolar but bipolar. This increases the size of the lesion and covers the painful areas better. To do it, two radiofrequency cannulas are used (22 gauge, 100 mm length, 5 mm active tip, Halyard, Alpharetta, GA, USA) and the energy provided by a generator (Coolief Cooled Radiofrequency Pain Management Generator, Halyard Alpharetta, GA, USA) (**Figure 1**).

4. Conclusions

Lateral epicondylitis is a painful condition that often resolves spontaneously. The recalcitrant cases in which the pain persists can be treated with a vast array of

options. Physiotherapy and local steroid injections are commonly used. Further conservative treatment modalities include local injection of botulinum toxin, platelet-enriched plasma, autologous blood or stem cells. The traditional open surgery has been subsided by other less invasive procedures like arthroscopic or percutaneous tenotomies. Radiofrequency, particularly thermal, has been proven as an adequate alternative to the surgical procedures and after failure of conservative treatments. Although in the past the radiofrequency was applied through a 3–5 cm skin incision, it is now possible to apply it through a cannula, minimising the surgical aggressiveness, reducing the patients' discomfort and speeding up the recovery.

Author details

Vicente Vanaclocha^{1*}, Nieves Saiz-Sapena², José María Ortiz-Criado³
and Leyre Vanaclocha⁴

1 Hospital General Universitario Valencia, Spain, and University of Valencia, Medical School, Valencia, Spain

2 Department Anaesthesiology and Pain Management, Hospital 9 de Octubre, Valencia, Spain

3 Universidad Católica San Vicente Mártir, Valencia, Spain

4 Medical School, University College London, London, United Kingdom

*Address all correspondence to: vvanaclo@hotmail.com

IntechOpen

© 2019 The Author(s). Licensee IntechOpen. This chapter is distributed under the terms of the Creative Commons Attribution License (<http://creativecommons.org/licenses/by/3.0>), which permits unrestricted use, distribution, and reproduction in any medium, provided the original work is properly cited. 

References

- [1] Rompe JD, Overend TJ, MacDermid JC. Validation of the patient-rated tennis elbow evaluation questionnaire. *Journal of Hand Therapy: Official Journal of the American Society of Hand Therapists*. 2007;**20**:3-10; quiz 11
- [2] Taylor SA, Hannafin JA. Evaluation and management of elbow tendinopathy. *Sports Health*. 2012;**4**:384-393
- [3] De Smedt T, de Jong A, Van Leemput W, Lieven D, Van Glabbeek F. Lateral epicondylitis in tennis: Update on aetiology, biomechanics and treatment. *British Journal of Sports Medicine*. 2007;**41**:816-819
- [4] Cohen M, da Rocha Motta Filho G. Lateral epicondylitis of the elbow. *Revista Brasileira de Ortopedia*. 2012;**47**:414-420
- [5] Buchanan BK, Varacallo M. Tennis elbow (lateral epicondylitis). In: StatPearls. Treasure Island (FL): StatPearls Publishing; 2018. Available from: <http://www.ncbi.nlm.nih.gov/books/NBK431092/>
- [6] Titchener AG, Fakis A, Tambe AA, Smith C, Hubbard RB, Clark DI. Risk factors in lateral epicondylitis (tennis elbow): A case-control study. *The Journal of Hand Surgery, European Volume*. 2013;**38**:159-164
- [7] Degen RM, Conti MS, Camp CL, Altchek DW, Dines JS, Werner BC. Epidemiology and disease burden of lateral epicondylitis in the USA: Analysis of 85,318 patients. *HSS Journal: The Musculoskeletal Journal of Hospital for Special Surgery*. 2018;**14**:9-14
- [8] Hamilton PG. The prevalence of humeral epicondylitis: A survey in general practice. *The Journal of the Royal College of General Practitioners*. 1986;**36**:464-465
- [9] Shiri R, Viikari-Juntura E, Varonen H, Heliövaara M. Prevalence and determinants of lateral and medial epicondylitis: A population study. *American Journal of Epidemiology*. 2006;**164**:1065-1074
- [10] Wolf JM, Mountcastle S, Burks R, Sturdivant RX, Owens BD. Epidemiology of lateral and medial epicondylitis in a military population. *Military Medicine*. 2010;**175**:336-339
- [11] Rothschild B. Mechanical solution for a mechanical problem: Tennis elbow. *World Journal of Orthopedics*. 2013;**4**:103-106
- [12] Geldschläger S. Osteopathic versus orthopedic treatments for chronic epicondylopathia humeri radialis: A randomized controlled trial. *Forschende Komplementärmedizin und klassische Naturheilkunde = Research in Complementary and Natural Classical Medicine*. 2004;**11**:93-97
- [13] Meknas K, Al Hassoni TN, Odden-Miland Å, Castillejo M, Kartus J. Medium-term results after treatment of recalcitrant lateral epicondylitis: A prospective, randomized study comparing open release and radiofrequency microtenotomy. *Orthopaedic Journal of Sports Medicine*. 2013;**1**:2325967113505433
- [14] Kurppa K, Viikari-Juntura E, Kuosma E, Huuskonen M, Kivi P. Incidence of tenosynovitis or peritendinitis and epicondylitis in a meat-processing factory. *Scandinavian Journal of Work, Environment & Health*. 1991;**17**:32-37
- [15] Haahr JP, Andersen JH. Prognostic factors in lateral epicondylitis: A randomized trial with one-year follow-up in 266 new cases treated with minimal occupational intervention or the usual approach in general practice.

Rheumatology (Oxford, England). 2003;**42**:1216-1225

[16] Hay EM, Paterson SM, Lewis M, Hosie G, Croft P. Pragmatic randomised controlled trial of local corticosteroid injection and naproxen for treatment of lateral epicondylitis of elbow in primary care. *BMJ*. 1999;**319**:964-968

[17] Zeisig E. Natural course in tennis elbow—Lateral epicondylitis after all? *Knee Surgery, Sports Traumatology, Arthroscopy: Official Journal of the ESSKA*. 2012;**20**:2549-2552

[18] Altintas B, Greiner S. Lateral epicondylitis: Conservative-operative. *Orthopade*. 2016;**45**:870-877

[19] Cullinane FL, Boocock MG, Trevelyan FC. Is eccentric exercise an effective treatment for lateral epicondylitis? A systematic review. *Clinical Rehabilitation*. 2014;**28**:3-19

[20] Nowotny J, El-Zayat B, Goronzy J, Biewener A, Bausenhardt F, Greiner S, et al. Prospective randomized controlled trial in the treatment of lateral epicondylitis with a new dynamic wrist orthosis. *European Journal of Medical Research*. 2018;**23**:43

[21] Weber C, Thai V, Neuheuser K, Groover K, Christ O. Efficacy of physical therapy for the treatment of lateral epicondylitis: A meta-analysis. *BMC Musculoskeletal Disorders*. 2015;**16**:223

[22] Okçu G, Erkan S, Sentürk M, Ozalp RT, Yercan HS. Evaluation of injection techniques in the treatment of lateral epicondylitis: A prospective randomized clinical trial. *Acta Orthopaedica et Traumatologica Turcica*. 2012;**46**:26-29

[23] Park HB, Kam M, Gwark J-Y. Association of steroid injection with soft-tissue calcification in lateral epicondylitis. *Journal of Shoulder and Elbow Surgery*. 2019;**28**:304-309

[24] Orchard J. Corticosteroid injection for lateral epicondylalgia is helpful in the short term, but harmful in the longer term; data for non-corticosteroid injections and other tendinopathies are limited. *Evidence-Based Medicine*. 2011;**16**:116-117

[25] Sims M, Langley T, Lewis S, Richardson S, Szatkowski L, McNeill A, et al. Effectiveness of tobacco control television advertisements with different types of emotional content on tobacco use in England, 2004-2010. *Tobacco Control*. 2016;**25**:21-26

[26] Struijs PA, Kerkhoffs GMMJ, Assendelft WJJ, Van Dijk CN. Conservative treatment of lateral epicondylitis: Brace versus physical therapy or a combination of both—A randomized clinical trial. *The American Journal of Sports Medicine*. 2004;**32**:462-469

[27] Cogné M, Creuzé A, Petit H, Delleci C, Dehail P, de Seze M. Number of botulinum toxin injections needed to stop requests for treatment for chronic lateral epicondylar tendinopathy. A 1-year follow-up study. *Annals of Physical and Rehabilitation Medicine*. Sep 2019;**62**(5):336-341. DOI: 10.1016/j.rehab.2018.12.003

[28] Galván Ruiz A, Vergara Díaz G, Rendón Fernández B, Echevarría Ruiz De Vargas C. Effects of ultrasound-guided administration of botulinum toxin (incobotulinumtoxinA) in patients with lateral epicondylitis. *Toxins*. 2019;**11**:46

[29] Galvin R, Callaghan C, Chan W-S, Dimitrov BD, Fahey T. Injection of botulinum toxin for treatment of chronic lateral epicondylitis: Systematic review and meta-analysis. *Seminars in Arthritis and Rheumatism*. 2011;**40**:585-587

[30] Arirachakaran A, Sukthuyat A, Sisayanarane T, Laoratanavoraphong S,

- Kanchanatawan W, Kongtharvonskul J. Platelet-rich plasma versus autologous blood versus steroid injection in lateral epicondylitis: Systematic review and network meta-analysis. *Journal of Orthopaedics and Traumatology : Official Journal of the Italian Society of Orthopaedics and Traumatology*. 2016;**17**:101-112
- [31] Boden AL, Scott MT, Dalwadi PP, Mautner K, Mason RA, Gottschalk MB. Platelet-rich plasma versus Tenex in the treatment of medial and lateral epicondylitis. *Journal of Shoulder and Elbow Surgery*. 2019;**28**:112-119
- [32] Calandruccio JH, Steiner MM. Autologous blood and platelet-rich plasma injections for treatment of lateral epicondylitis. *The Orthopedic Clinics of North America*. 2017;**48**:351-357
- [33] Chaudhury S, de La Lama M, Adler RS, Gulotta LV, Skonieczki B, Chang A, et al. Platelet-rich plasma for the treatment of lateral epicondylitis: Sonographic assessment of tendon morphology and vascularity (pilot study). *Skeletal Radiology*. 2013;**42**:91-97
- [34] Mi B, Liu G, Zhou W, Lv H, Liu Y, Wu Q, et al. Platelet rich plasma versus steroid on lateral epicondylitis: Meta-analysis of randomized clinical trials. *The Physician and Sportsmedicine*. 2017;**45**:97-104
- [35] Amin QM, Ahmed I, Aziz A. Autologous blood injection in the treatment of lateral epicondylitis. *JPMMA. Journal of the Pakistan Medical Association*. 2014;**64**:S38-S43
- [36] Bostan B, Balta O, Aşçı M, Aytekin K, Eser E. Autologous blood injection works for recalcitrant lateral epicondylitis. *Balkan Medical Journal*. 2016;**33**:216-220
- [37] Imam MA, Holton J, Horriat S, Negida AS, Grubhofer F, Gupta R, et al. A systematic review of the concept and clinical applications of bone marrow aspirate concentrate in tendon pathology. *SICOT-J*. 2017;**3**:58
- [38] Lee SY, Kim W, Lim C, Chung SG. Treatment of lateral epicondylitis by using allogeneic adipose-derived mesenchymal stem cells: A pilot study. *Stem Cells (Dayton, Ohio)*. 2015;**33**:2995-3005
- [39] Baker CL, Murphy KP, Gottlob CA, Curd DT. Arthroscopic classification and treatment of lateral epicondylitis: Two-year clinical results. *Journal of Shoulder and Elbow Surgery*. 2000;**9**:475-482
- [40] Boyd HB, McLeod AC. Tennis elbow. *The Journal of Bone and Joint Surgery. American Volume*. 1973;**55**:1183-1187
- [41] Goldberg EJ, Abraham E, Siegel I. The surgical treatment of chronic lateral humeral epicondylitis by common extensor release. *Clinical Orthopaedics and Related Research*. Aug 1988;**233**:208-212
- [42] Posch JN, Goldberg VM, Larrey R. Extensor fasciotomy for tennis elbow: A long-term follow-up study. *Clinical Orthopaedics and Related Research*. Sep 1978;**135**:179-182
- [43] Müller A, Spies CK, Unglaub F, Bruckner T, Pötzl W. Chronic lateral epicondylitis: The Nirschl procedure. *Operative Orthopädie und Traumatologie*. 2015;**27**:525-535
- [44] Nirschl R, Pettrone F. Tennis elbow. The surgical treatment of lateral epicondylitis. *Journal of Bone and Joint Surgery*. 1979;**61**:832-839
- [45] Bateman M, Littlewood C, Rawson B, Tambe AA. Surgery for tennis elbow: A systematic review. *Shoulder Elb*. 2019;**11**:35-44

- [46] Wahegaonkar A, Sanghavi S, Bansode A, Mane S. A novel technique for the surgical management of chronic lateral epicondylitis. *Techniques in Hand & Upper Extremity Surgery*. Jun 2019;**23**(2):65-69. DOI: 10.1097/BTH.0000000000000227
- [47] Shim JW, Yoo SH, Park MJ. Surgical management of lateral epicondylitis combined with ligament insufficiency. *Journal of Shoulder and Elbow Surgery*. 2018;**27**:1907-1912
- [48] Gowda A, Kennedy G, Gallacher S, Garver J, Blaine T. The three-portal technique in arthroscopic lateral epicondylitis release. *Orthopedic Reviews*. 2016;**8**:6081
- [49] Grewal H, Grewal BS, Patel R. Nonsurgical interventions for low back pain. *Primary Care*. 2012;**39**:517-523
- [50] Savoie FH, O'Brien MJ. Arthroscopic tennis elbow release. *Instructional Course Lectures*. 2015;**64**:225-230
- [51] Clark T, McRae S, Leiter J, Zhang Y, Dubberley J, MacDonald P. Arthroscopic versus open lateral release for the treatment of lateral epicondylitis: A prospective randomized controlled trial. *Arthroscopy: The Journal of Arthroscopic & Related Surgery: Official Publication of the Arthroscopy Association of North America and the International Arthroscopy Association*. 2018;**34**:3177-3184
- [52] Kim DS, Chung HJ, Yi C-H, Kim S-H. Comparison of the clinical outcomes of open surgery versus arthroscopic surgery for chronic refractory lateral epicondylitis of the elbow. *Orthopedics*. 2018;**41**:237-247
- [53] Panthi S, Khatri K, Kharel K, Byanjankar S, Shrestha R, Sharma JR, et al. Outcome of percutaneous release of tennis elbow: A non-randomized controlled trial study. *Cureus*. 2017;**9**:e952
- [54] Battista CT, Dorweiler MA, Fisher ML, Morrey BF, Noyes MP. Ultrasonic percutaneous tenotomy of common extensor tendons for recalcitrant lateral epicondylitis. *Techniques in Hand & Upper Extremity Surgery*. 2018;**22**:15-18
- [55] Szabo SJ, Savoie FH, Field LD, Ramsey JR, Hosemann CD. Tendinosis of the extensor carpi radialis brevis: An evaluation of three methods of operative treatment. *Journal of Shoulder and Elbow Surgery*. 2006;**15**:721-727
- [56] Coleman B, Quinlan JF, Matheson JA. Surgical treatment for lateral epicondylitis: A long-term follow-up of results. *Journal of Shoulder and Elbow Surgery*. 2010;**19**:363-367
- [57] Peart RE, Strickler SS, Schweitzer KM. Lateral epicondylitis: A comparative study of open and arthroscopic lateral release. *American Journal of Orthopedics (Belle Mead, NJ)*. 2004;**33**:565-567
- [58] Sochol KM, London DA, Rothenberg ES, Hausman MR. Arthroscopic treatment of lateral elbow pain mimicking lateral epicondylitis: Long-term follow-up of a unique surgical protocol. *Techniques in Hand & Upper Extremity Surgery*. Mar 2019;**23**(1):27-30. DOI: 10.1097/BTH.0000000000000217
- [59] Valera-Garrido F, Minaya-Muñoz F, Medina-Mirapeix F. Ultrasound-guided percutaneous needle electrolysis in chronic lateral epicondylitis: Short-term and long-term results. *Acupuncture in Medicine: Journal of the British Medical Acupuncture Society*. 2014;**32**:446-454
- [60] Nourbakhsh A, Hirschfeld AG, Schlatterer DR, Kane SM, Lourie GM. Innervation of the elbow

joint: A cadaveric study. *Journal of Hand Surgery*. 2016;**41**:85-90

[61] Wilhelm A. Innervation of the radial upper arm epicondyle area and its clinical significance. *Zeitschrift für Anatomie und Entwicklungsgeschichte*. 1962;**123**:115-120

[62] Dellon AL. Partial joint denervation I: Wrist, shoulder, and elbow. *Plastic and Reconstructive Surgery*. 2009;**123**:197-207

[63] Rose NE, Forman SK, Dellon AL. Denervation of the lateral humeral epicondyle for treatment of chronic lateral epicondylitis. *Journal of Hand Surgery*. 2013;**38**:344-349

[64] Wilhelm A. Tennis elbow: Treatment of resistant cases by denervation. *Journal of Hand Surgery (Edinburgh, Scotland)*. 1996;**21**:523-533

[65] Bekler H, Riansuwan K, Vroemen JC, Vroeman JC, McKean J, Wolfe VM, et al. Innervation of the elbow joint and surgical perspectives of denervation: A cadaveric anatomic study. *Journal of Hand Surgery*. 2008;**33**:740-745

[66] De Kesel R, Van Glabbeek F, Mugenzi D, De Vos J, Vermeulen K, Van Renterghem D, et al. Innervation of the elbow joint: Is total denervation possible? A cadaveric anatomic study. *Clinical Anatomy (New York, N.Y.)*. 2012;**25**:746-754

[67] Lord SM, Bogduk N. Radiofrequency procedures in chronic pain. *Best Practice & Research. Clinical Anaesthesiology*. 2002;**16**:597-617

[68] Takahashi N, Tasto JP, Ritter M, Ochiai N, Ohtori S, Moriya H, et al. Pain relief through an antinociceptive effect after radiofrequency application. *The American Journal of Sports Medicine*. 2007;**35**:805-810

[69] Meknas K, Odden-Miland A, Mercer JB, Castillejo M, Johansen O. Radiofrequency microtenotomy: A promising method for treatment of recalcitrant lateral epicondylitis. *The American Journal of Sports Medicine*. 2008;**36**:1960-1965

[70] Tasto JP, Cummings J, Medlock V, Hardesty R, Amiel D. Microtenotomy using a radiofrequency probe to treat lateral epicondylitis. *Arthroscopy: The Journal of Arthroscopic & Related Surgery: Official Publication of the Arthroscopy Association of North America and the International Arthroscopy Association*. 2005;**21**:851-860

[71] Vallejo R, Tilley DM, Williams J, Labak S, Aliaga L, Benyamin RM. Pulsed radiofrequency modulates pain regulatory gene expression along the nociceptive pathway. *Pain Physician*. 2013;**16**:E601-E613

[72] Akamatsu FE, Saleh SO, Hojaij F, Martinez CAR, Andrade M, Teodoro WR, et al. Radiofrequency preserves histoarchitecture and enhances collagen synthesis in experimental tendon injury. *Histology and Histopathology*. 2016;**31**:515-522

[73] Tasto JP, Richmond JM, Cummings JR, Hardesty R, Amiel D. Radiofrequency microtenotomy for elbow epicondylitis: Midterm results. *American Journal of Orthopedics (Belle Mead, NJ)*. 2016;**45**:29-33

[74] Hamlin K, Munro C, Barker SL, McKenna S, Kumar K. Open release versus radiofrequency microtenotomy in the treatment of lateral epicondylitis: A prospective randomized controlled trial. *Shoulder & Elbow*. 2018;**10**:45-51

[75] Lee J-H, Park I, Hyun H-S, Shin S-J. A comparison of radiofrequency-based microtenotomy and arthroscopic release of the extensor carpi radialis

brevis tendon in recalcitrant lateral epicondylitis: A prospective randomized controlled study. *Arthroscopy: The Journal of Arthroscopic & Related Surgery: Official Publication of the Arthroscopy Association of North America and the International Arthroscopy Association.* 2018;**34**:1439-1446

[76] Pierce TP, Issa K, Gilbert BT, Hanly B, Festa A, McInerney VK, et al. A systematic review of tennis elbow surgery: Open versus arthroscopic versus percutaneous release of the common extensor origin. *Arthroscopy: The Journal of Arthroscopic & Related Surgery: Official Publication of the Arthroscopy Association of North America and the International Arthroscopy Association.* 2017;**33**:1260-1268.e2

[77] Lin C-L, Lee J-S, Su W-R, Kuo L-C, Tai T-W, Jou I-M. Clinical and ultrasonographic results of ultrasonographically guided percutaneous radiofrequency lesioning in the treatment of recalcitrant lateral epicondylitis. *The American Journal of Sports Medicine.* 2011;**39**:2429-2435

[78] Weber T, Kabelka B. Noninvasive monopolar capacitive-coupled radiofrequency for the treatment of pain associated with lateral elbow tendinopathies: 1-year follow-up. *PM & R: The Journal of Injury, Function, and Rehabilitation.* 2012;**4**:176-181

[79] Whipple T, Villegas D. Thermal and electric energy fields by noninvasive monopolar capacitive-coupled radiofrequency: Temperatures achieved and histological outcomes in tendons and ligaments. *PM & R: The Journal of Injury, Function, and Rehabilitation.* 2010;**2**:599-606

[80] Erdine S, Bilir A, Cosman ER, Cosman ER. Ultrastructural changes in axons following exposure to pulsed radiofrequency fields. *Pain Practice: The*

Official Journal of World Institute of Pain. 2009;**9**:407-417

[81] Vatansever D, Tekin I, Tuglu I, Erbuyun K, Ok G. A comparison of the neuroablative effects of conventional and pulsed radiofrequency techniques. *The Clinical Journal of Pain.* 2008;**24**:717-724

[82] Oh DS, Kang TH, Kim HJ. Pulsed radiofrequency on radial nerve under ultrasound guidance for treatment of intractable lateral epicondylitis. *Journal of Anesthesia.* 2016;**30**:498-502

[83] Whipple TL. From mini-invasive to non-invasive treatment using monopolar radiofrequency: The next orthopaedic frontier. *Orthopedic Clinics of North America.* 2009;**40**:531-535