

We are IntechOpen, the world's leading publisher of Open Access books Built by scientists, for scientists

6,900

Open access books available

185,000

International authors and editors

200M

Downloads

Our authors are among the

154

Countries delivered to

TOP 1%

most cited scientists

12.2%

Contributors from top 500 universities



WEB OF SCIENCE™

Selection of our books indexed in the Book Citation Index
in Web of Science™ Core Collection (BKCI)

Interested in publishing with us?
Contact book.department@intechopen.com

Numbers displayed above are based on latest data collected.
For more information visit www.intechopen.com



Cerebral Arteriovenous Malformations (cAVMs): What Is New?

*Adel E. Ahmed Ganaw, Abdulgafoor M. Tharayil,
Moad Ehfeda, Mohamed Hassan Alfared, Qazi Zeeshan,
Sohel M.G. Ahmed, Ali Ayyad, Ibrahim Naemi,
Hossam Algallie, Nissar Shaikh and Nabil Shallik*

Abstract

Cerebral arteriovenous malformations (cAVMs) are rare congenital anomalies of cerebral blood vessels that result from maldevelopment of the capillary bed, permitting direct communication between cerebral arteries and veins. It usually occurs in the supratentorial area of the brain; however, it can occur anywhere in the brain and spinal cord. Most of the patients with cAVMs present with a variety of complaints such as seizures, intracerebral hemorrhage, headache, and progressive focal neurological deficit. Imaging such as CT, MRI, and angiography plays a vital role in diagnosis, grading, risk assessment, and posttherapeutic follow-up. The multidisciplinary team use three therapeutic modalities in the treatment of cAVMs. This chapter reviews the clinical presentations, diagnosis, classification, and treatment of cAVMs.

Keywords: cerebral angiography, endovascular embolisation, focal neurological deficit, headache, intracerebral hemorrhage, microsurgery, radiosurgery, seizures

1. Introduction

Arteriovenous malformations (AVMs) are rare congenital anomalies of cerebral blood vessels with critical clinical implications. These anomalies may occur anywhere in the central nervous system (brain and spinal cord). It is a neurosurgical emergency that is characterized by abnormal vascular web, consisting of a tangle of dysplastic vessels (nidus) fed by arteries and drained by veins without intervening capillaries, generating a high flow, low resistance shunt between cerebral arteries and veins (**Figure 1**). They are a significant form of vascular malformation, with dilated arteries congregating from different directions and distended veins twisting from turbulence of shunted blood flow. This gives the pathology its radiological characteristic (early venous drainage) on formal catheter-based cerebral angiography. Although cAVMs are considered as a congenital cerebrovascular disease, patients may present with intracerebral hemorrhage, convulsions, chronic headache, and

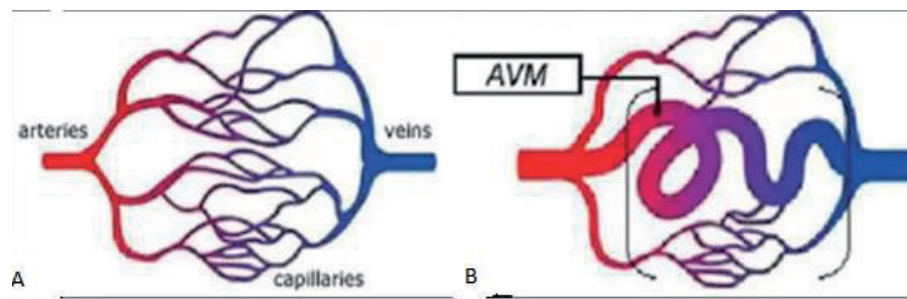


Figure 1.

(A) Normal vasculature, arteries, and veins communicate at capillary bed. (B) cAVM direct communication between high-flow arterial vessels and low-resistance venous capacitance vessels. And an arteriovenous malformation. Steal phenomenon (blood flow through low resistance shunt (low resistance) and stealing blood flow from adjacent brain) [1].

progressive neurological deficit. Some of them remain asymptomatic and are noticed only incidentally on cerebral imaging for other indications. AVMs are associated with a lifelong risk of intracerebral hemorrhage (ICH); therefore, these lesions necessitate appropriate assessment, workup, and considerations for treatment based upon many factors such as age, size, and location of the lesions [2–5].

2. Epidemiology

The prevalence of cAVMs is very low, and a collection of population-based studies from the literature estimates the incidence of cerebral AVMs at 0.69–1.32 per 100,000. However, they are considered as an important cause of intracerebral hemorrhage in a young age group. Bleeding rate is almost 1% per year in previously unruptured arteriovenous malformations. cAVMs cause approximately 2–4% of all hemorrhagic strokes [2, 4, 6, 7].

They are a congenital disease that is developed from indistinguishable causes in developing a fetus. While numerous mechanisms of cAVM formation have been suggested, the heterogeneity and lack of inheritance of these pathologies make their exact cause to remain idiopathic. They are associated with a few syndromes, such as hereditary hemorrhagic telangiectasia, Wyburn-Mason syndrome, von Hippel-Lindau disease, and Sturge-Weber syndrome [2].

Cerebral AVMs generally occur as a single lesion, and multiple lesions are observed only in 9% of the patients. cAVMs are equally distributed between sexes [8, 9].

Patients may present at any age, although they most commonly present in the second through fourth decades of life [6, 7].

3. Clinical manifestation

cAVM patients may present with a variety of clinical symptoms such as hemorrhage, seizure, headaches, or focal neurologic deficits. The clinical presentations of cAVMs depend on the patient's age, size, location, and vascular features of the cAVMs. Some patients are asymptomatic at presentation and cAVMs are accidentally discovered when images are performed for potentially unrelated reasons.

3.1 Hemorrhage

Hemorrhage is the most common initial presentation of cAVMs. Studies reported that hemorrhage is the initial presentation in 50% of patients with cAVMs. The risk of hemorrhagic stroke in cAVM patients is about 2–5% per year. It is fatal

in 5–25% of all cAVM patients. Children more frequently present with intracerebral hemorrhage than do adults. Hypertension, previous intracerebral hemorrhage (ICH), AVMs with feeding artery aneurysm, AVMs with multiple arterial feeders, deep-seated cAVMs, and cAVMs with limited venous drainage are associated with increased risk of hemorrhagic stroke. Hemorrhage begins in the lesion itself and then accumulates, increases in size, and produces a mass effect. Therefore, hemispherical lesions generate less severe syndromes in comparison with primary hemorrhage that originates from functioning parts of the brain. Hemorrhages in polar regions such as frontal, temporal, and occipital regions may cause only minor headache, while those in deeper structures affect vital regions packed into tiny spaces and produce severe neurological manifestations. Hence, patients with ICH may present with a wide span of presentations such as sudden severe headache, drop in the level of consciousness, progressive neurological deficits, hemiparesis, aphasia, cranial nerve palsy, visual field deficits, and coma [2, 9–11].

The type of the hemorrhage and clinical presentations depend on the location of cAVMs. Superficial lesions cause subarachnoid hemorrhage with low risk of cerebral vasospasm and the bleeding confined in local sulci, whereas lesions with deep drainage may vent blood in the ventricular system, causing hemohydrocephalus. Lesions embedded in the brain parenchyma cause parenchymatous hemorrhage. **Figure 2** [11, 13].

3.2 Seizure

Seizures are the second most common presentation of cAVMs; it occurs in 20–29% of patients with cAVMs at initial diagnosis. One study showed that the 5-year risk of first seizure was 8% (95% CI 0–20). The risk of the seizures rose to 23% in the presence of ICH and focal neurological deficit. The seizures are frequently observed in male patients with cortical lesions, especially in the frontal and temporal lobe. Large lesions (nidus greater than 3 cm in diameter) and superficial venous drainage are associated with increase in seizure frequency. Posterior fossa, coexisting aneurysms, and deep locations were associated with the absence of seizures. AVM may cause focal or generalized seizures or both. The exact pathophysiology of the seizures is not completely understood. However, increased venous back pressure secondary to venous outflow obstruction may be involved. cAVM-related seizures may occur secondary to ICH, from the hemosiderin deposition, or secondary to venous hypertension, and ischemia following steal. Seizure control rate ranges between 49 and 85% according to approach (surgery, radiosurgery, or embolisation), and the highest seizure freedom has been achieved in patients with approved complete angiographic obliteration after radiosurgery [2, 9, 14].

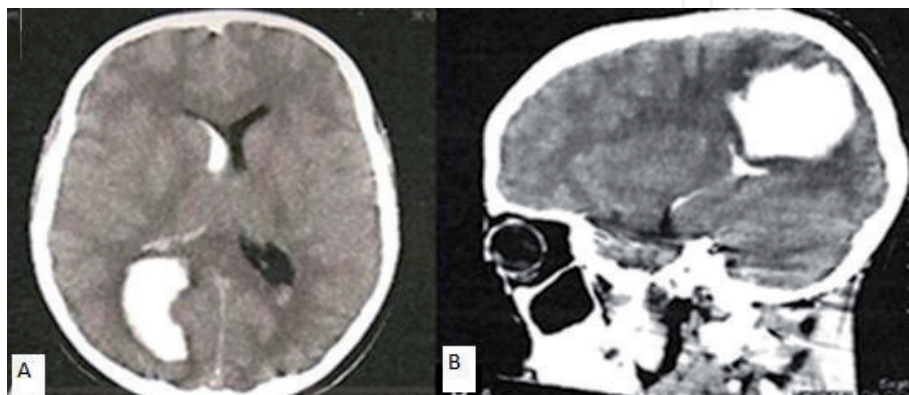


Figure 2.
(A) Axial and (B) sagittal plain CT brain of 13-year-old patient presented with severe headache; the scan demonstrates right parieto-occipital intra-axial hemorrhage with intra-ventricular extension. Urgent craniotomy was done due to deterioration of the neurological status confirming underlying AVM [12].

3.3 Headache

Approximately 0.2% of cAVM patients present with headache and normal neurologic examination. The headache associated with cAVMs is incidental, without any specifications. Headache is the presenting symptom in nearly 15% of cAVM patients without evidence of rupture. Headache can be characterized as similar to migraines with lateralization to one side [11, 13]. The attack occurrence, auras, duration, and pulsatile quality are all shared. Treatment of headache in AVM patients has not been studied so far. No specific medication has been exclusively useful in headache management. Expert opinions do not recommend using any vasoconstrictors in these patients as it may lead to rupture and ICH. However, there are limited data to support this recommendation [9].

3.4 Neurological deficit

Neurological deficit is a relatively rare presentation of cAVMs. Patients may present with transient, progressive, permanent, or progressive focal neurological deficits not secondary to ICH or seizures. Vascular steal syndrome is assumed to be the main reason of neurologic deficit. Moreover, recurrent ICH, local mass effect, or hydrocephalus may cause neurological deficits [2, 9].

4. Diagnosis of cAVMs

Diagnosis of cAVMs must include a detailed assessment of the nidus and the adjacent structures. Plain CT is the initial diagnostic tool for cAVM patients who present with one of previously mentioned clinical manifestations, while CT angiography or digital subtraction angiography are used to locate the exact site of rupture in patients with ICH. Magnetic resonance imaging (MRI) is the recommended investigation for patients with nonhemorrhagic manifestations. Digital subtraction angiography is the investigation of choice for the characterization of the feeding arteries, nidus angioarchitecture, and draining veins and is mandatory for precise AVM grading and management planning [2, 4].

4.1 Computerized tomography (CT) and related techniques

CT scan is the first radiological investigation that is performed in patients who present with convulsions, focal neurological deficit, or clinical signs of ICH. Plain head CT is useful for confirming ICH or assessing abnormal suspicious dilated dural veins, abnormal faint hyperdense cerebral mass, and focal cerebral calcification, which are alert signs for the radiologist for the possibility of underlying cAVMs; however, negative CT scan cannot be excluding the presence of cAVMs. Compression of the nidus by hematoma impedes CT diagnosis of cAVM in patients with acute ICH. Therefore, CT angiography should be done promptly to diagnose the underlying cAVMs. CT angiogram with intravenous iodinated contrast media with images acquired by bolus tracking technique is very helpful for maximum cerebral as well as cAVM arterial opacification. The CT head angiogram is used for confirming the diagnosis, assessing the cAVM size, site, number, and origin of feeding arteries and draining vein as well as the presence of associated aneurysm and site of bleeding. The high spatial resolution of CTA allows the generation of multiplanar reformations, maximum intensity projections, and volumetric reconstructions for analysis (**Figures 3–5**) [4, 16, 18].

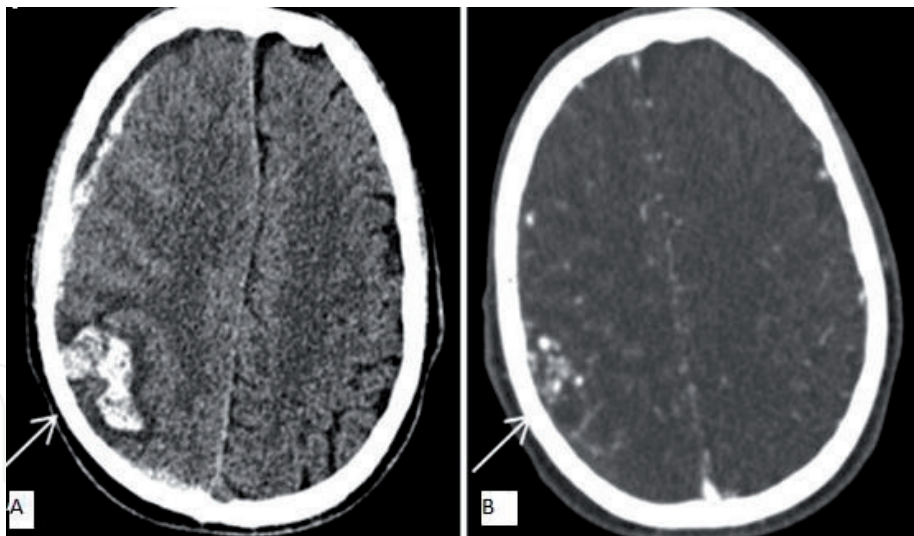


Figure 3.
Plain CT head (A) and CT head angiogram (B) of young adult patient demonstrate right parietal parenchyma brain hemorrhage (the arrow on A image) and multiple serpiginous tortuous vascular malformation AVM (the arrow on the B image) [15].

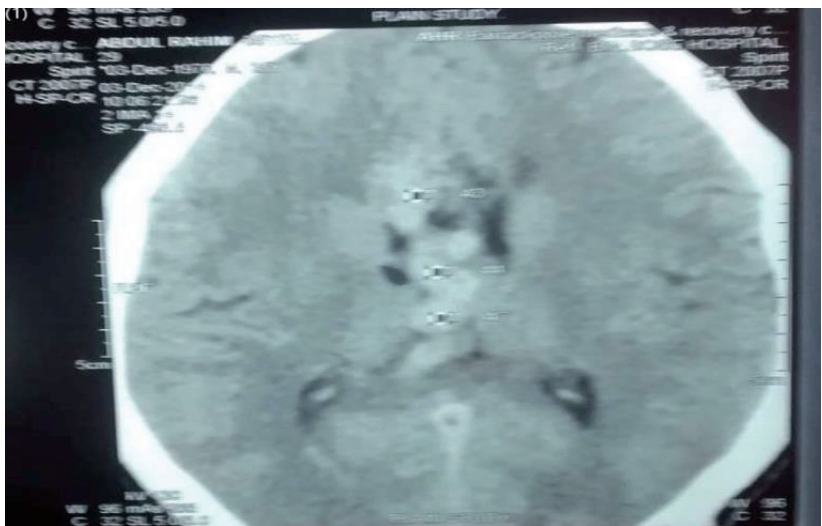


Figure 4.
Plain CT shows hyperdense tortuous structure at lateral ventricular region representing AVM [16].

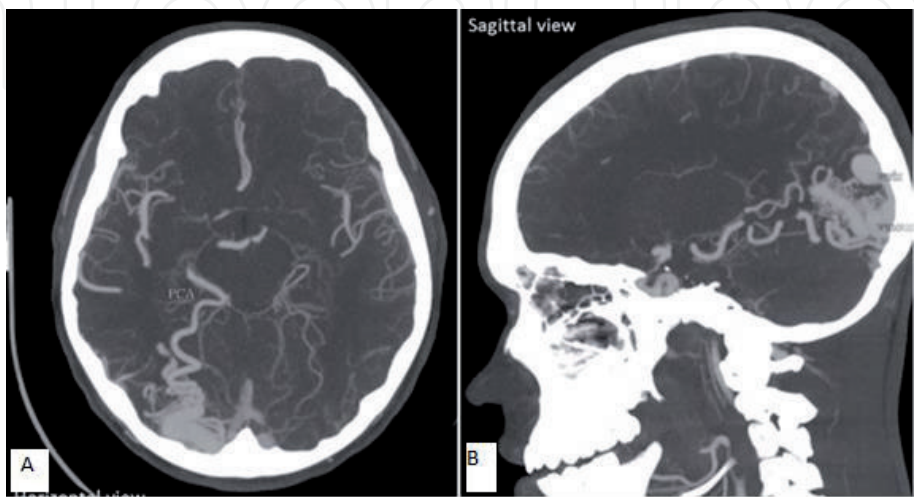


Figure 5.
CT head angiogram MIP (maximum intensity projection) axial and sagittal view (A and B respectively) demonstrates right occipital lobe AVM supplied mainly by right posterior cerebral artery and drained to straight and right transverse dural sinuses [17].

In recent decades, the radiological equipment has showed visible development making us more aware of the pathophysiology of many diseases by using perfusion CT and MRI scan for cAVMs to provide information regarding the blood flow abnormality within and around such vascular anomalies by assessing cerebral blood flow (CBF), cerebral blood volume (CBV), and the mean transient time (MTT). Through these, we can demonstrate three different forms of extra-nidal parenchymal perfusion abnormalities:

1. Functional steal is characterized by redistribution of the blood flow from surrounding brain tissue through the arteriovenous malformation that leads to disturbance of normal cerebral perfusion. Patients with this phenomenon usually present with convulsions. CT scan shows decrease in CBV, CBF, and MTT as a result of sump effect from the artery supplying the arteriovenous malformation **Figures 6 and 7**.

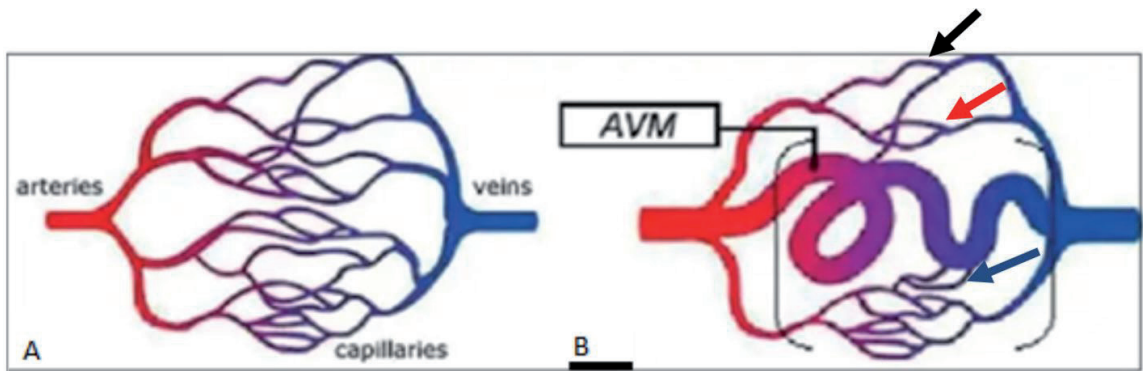


Figure 6. Normal and Perfusion abnormalities diagram in cAVMs. (A) Illustrate normal brain tissue blood flow. (B) Illustrate the abnormal brain tissue blood flow within and adjacent to the AVM. The Black arrow represent functional steal region in which the blood shunted away to the nearby AVM. The red arrow representing ischemic steal region due to indirect collateral of the near the AVMs. The blue arrow is a brain region drained by high pressure veins of AVM leading to venous congestion [15].

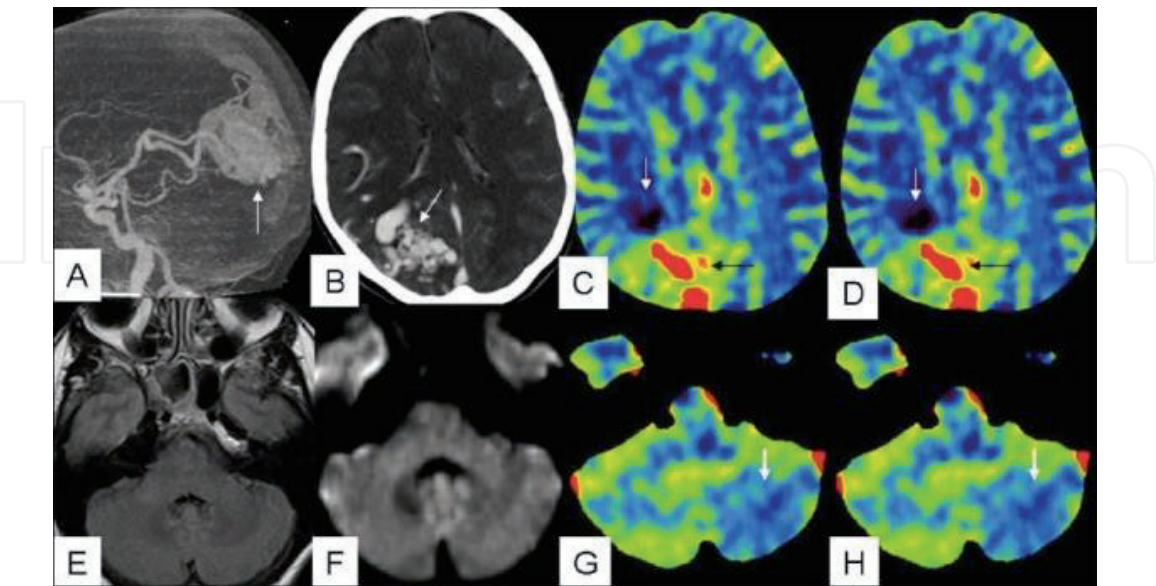


Figure 7. Illustrate the effect of steal phenomenon in Brain's AVM on adjacent brain tissue (A) and (B) CT angiograms demonstrate right side occipital AVM (arrows). Selected images from brain CT perfusion (C and D) shows high CBF (black arrows in C) and CBV (black arrows in D) in the nidus and low CBF (white arrows in C) and CBV (white arrows in D) in the perinidal area, suggestive of perinidal ischemia. There is no evidence of cerebellar ischemia on the FLAIR (E) and diffusion (F) images. CBF (arrows in G) and CBV (arrows in H) are low in the contralateral cerebellar hemisphere, suggestive of cerebellar diaschisis [19].

2. Ischemic steal is characterized by a reduction in CBF and CBV with increased MTT in the brain parenchyma secondary to indirect collateral flow to the shunt from nearby arteries. These patients usually present with a focal neurological deficit.
3. Venous congestion is characterized by increased CBV and MTT in remote parts of the brain as a result of the high-pressure flow in the draining veins of the AVM. These patients may present with progressive neurological deficits [4, 15, 16, 18].

4.2 Magnetic resonance imaging (MRI) of the brain and related techniques

MRI of the brain is very sensitive for the exact determination of the cAVM nidus location and an associated draining vein; it also has exclusive sensitivity in determining remote bleeding due to these lesions. On noncontrast brain MRI, the cAVM nidus is seen as signal void on T2-weighted images with dilated feeding arteries and draining veins, and susceptibility-weighted imaging can detect the presence of hemosiderin component of chronic bleeding as low signal intensity. The ischemic and brain steal area can appear as hyperintense T2 weighted and FLAIR. MRA also could be used to add crucial information regarding the feeding arteries, draining veins, and the presence of associated aneurysm, which appear Could be gained from CT perfusion (CTP). The same pathophysiological information that could be gained from CTP can also be done by MRI perfusion using noncontrast ALS (arterial spine labeling) technique or with the usage of contrast media **Figures 8 and 9** [2, 4].

MRI of the brain is especially valuable in follow-up patients after treatment. After radiosurgery, MRI is essential to follow up regression of the nidal volume. While the MR angiography is very useful to characterize the venous drainage and other vascular features, the adjacent tissue that is exposed to the radiation field can be precisely observed for posttherapy edema or radiation necrosis [4, 16].

4.3 Digital subtraction angiography (DSA)

Digital subtraction angiography is the gold standard for assessment of nature and number of the feeding arteries, presence of flow-related aneurysms, quality of venous drainage, associated varices, and stenosis.

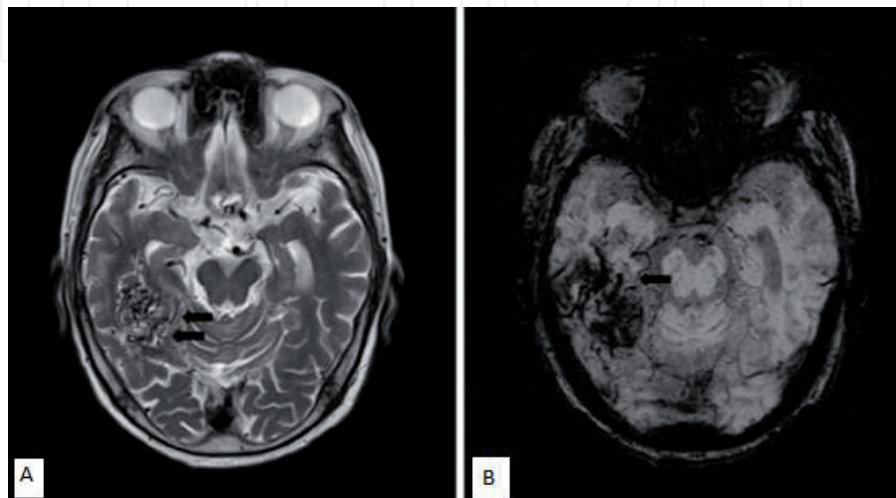


Figure 8.
MRI brain of an adult patient T2-weighted image A and SWI (susceptibility weighted image). B demonstrates right temporal T2WI and DWI serpiginous hypointensity representing AVM [20].

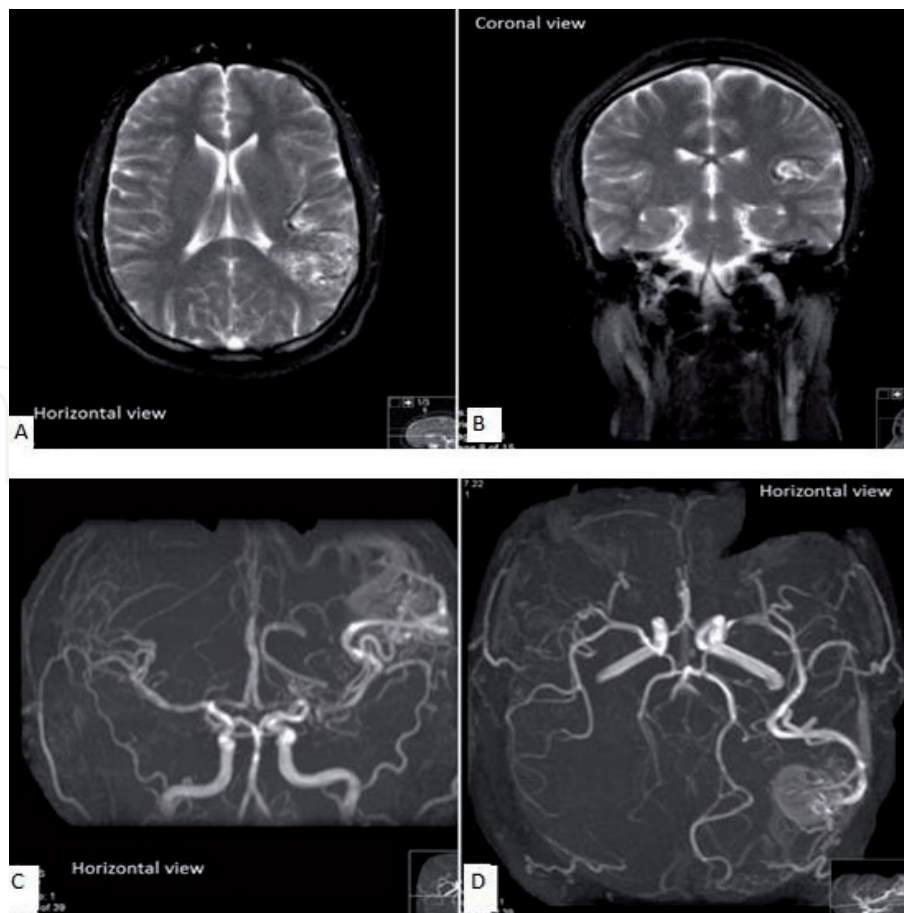


Figure 9.

MRI T2-weighted image A&B and MRA brain C&D images the brain demonstrate T2 weighted signal void serpiginous structure at left inferior parietal lobe; on MRA, images show the nidus fed by arterial feeder from left middle cerebral artery and drained to superficial cortical veins to left transverse sinus [16].

Two types of feeding arteries that can be identified by DSA are as follows:

1. Direct arterial feeders: they end in the AVM; it is either large cortical arteries or small perforator coursing through white matter or ventricles.
2. Indirect arterial feeders: they supply the AVM through small branches that arise from the involved but also pass to healthy brain tissue distal to AVM.

Flow-related aneurysms in the feeding arteries usually result from amplified shear stress and considered as an indicator of vascular friability and hemorrhage risk. These aneurysms may resolve following curative treatment of the AVM. Intranidal aneurysms are usually small, less than 3 mm, and pseudoaneurysms and can be successfully treated with embolisation.

The AVM nidus may have both fistulous and glomerular compartments; the fistulous compartments form high-flow shunt that can be treated with endovascular therapy, while the glomerular compartments form an intervening network of pathological vessels and are very difficult to treat with embolisation.

Assessment of the venous part of AVM is critical and should include the anatomy of drainage (superficial, deep, or mixed) and characteristics of the venous outflow (focal stenosis, venous pouches, and sinus stenosis or occlusion). Drainage into the deep venous system is associated with a high risk of bleeding and indicates deep location that may make surgical intervention difficult [2, 4].

5. Grading of cAVMs

Before starting the management of cAVMs, all management risks should be considered, starting from those associated with diagnosis, surgical intervention, radiotherapy, to interventional radiology. Treating physicians should also consider both early and late complications such as hemorrhage and convulsions. There are many grading systems that may help physicians to assess the risk of these complications, take appropriate intervention for each patient, predict prognosis, and standardize patient's evaluation for scientific study purposes [21–23].

5.1 Spetzler-Martin (S-M) grading

In 1986, Spetzler and Martin introduced the most commonly used grading scale for cAVMs; it uses three anatomical features of AVM (nidus size, nidus location relative to the eloquent brain (**Figure 10**), and pattern of venous drainage) to generate five cAVM grades (**Table 1**).

To determine S-M grade of cAVMs, size of the nidus, venous drainage, and eloquence of adjacent brain tissue are determined in angiography, brain CT scan, and/or MRI of the brain. A numerical value is assigned for each category, as described in **Table 1**. The grade is derived from adding the points awarded for each category; for example, for grade I, the lesion would be small (less than 3 cm/1 point), in noneloquent region (0 point), and have only superficial drainage (0 point) (**Figure 11**); therefore, excision of such lesion would be complete, minimally invasive, and associated with low surgical complications. Whereas for grade V, the lesion would be large (more than 6 cm/3 points), sited within or immediately close to eloquent brain

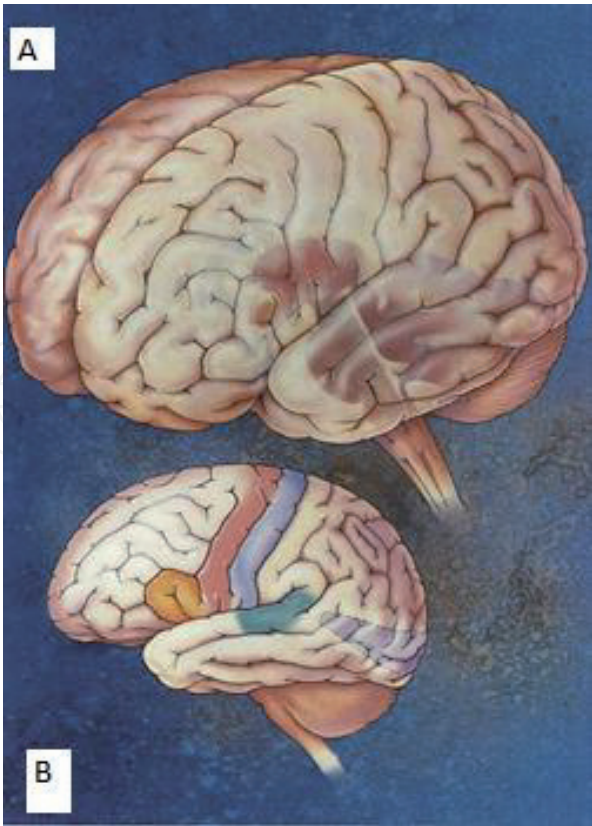


Figure 10.
The anatomic areas considered neurologically eloquent. (A) Deep eloquent area (hypothalamus, thalamus, brain stem, and cerebellar peduncle). (B) Eloquent area in cerebral cortex (sensory-motor, primary visual, and language area) [19].

Size of cAVM	Point
0-3 cm	1
3.1-6 cm	2
>6 cm	3
Location of cAVM (eloquence area)	
No	0
Yes	1
Venous drainage	
Superficial	0
Deep	1

Table 1.
Spetzler-Martin (S-M) grading scale is used to make decisions about treatment risks.

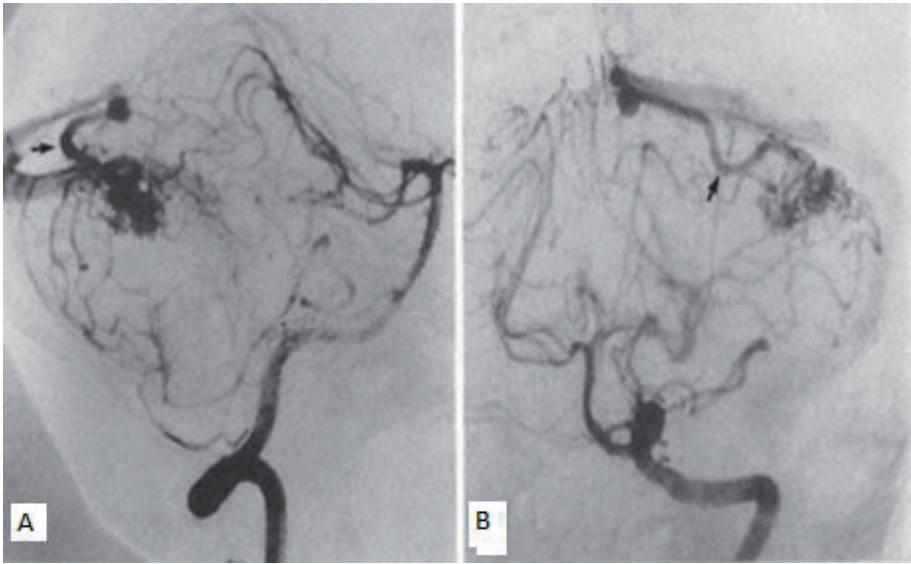


Figure 11.
Grade I AVM; (A) Vertebral angiograms. (B) Anteroposterior view cerebellar AVM less than 3 cm (1 point), superficial on cerebellar cortex (0 point), superficial drainage (through superficial cerebellar hemisphere veins—arrows: 0 point) [19].

(1 point), and venous drainage would drain into deep venous system (**Figure 12**), so excision of such lesion is extremely difficult and associated with significant risk of bleeding and surgical morbidity and mortality. Moreover, obliteration of large cAVMs leads to sudden increase in perfusion, which leads to vasogenic edema or hemorrhage (normal perfusion pressure break through phenomenon). There are certain lesions that should not be considered for surgery such as large AVM that invades eloquent critical area or diffuse nidus that involves crucial structure such as hypothalamus or brain stem (**Figure 13**), so the surgical resection of such lesions would necessarily be associated with significant neurological deficit or death. These AVMs are graded under separate category (grade VI) and considered as inoperable AVM [22, 23].

The S-M grading scale was introduced to predict the outcome of surgical resection but can also be used to predict the radiosurgical outcome. Lower grades (grades I and II) are associated with a good result and less postoperative neurological deficit in comparison with grades IV and V [21–23].

Multiple retrospective studies showed that rates of poor outcome were highly correlated with S-M grade. Precisely, rates of poor outcome were calculated as follows: S-M grade I = 4% (95% CI, 2–7), S-M grade II = 10% (95% CI, 7–13), S-M

grade III = 18% (95% CI, 15–22), S-M grade IV = 31% (95% CI, 25–37), and S-M grade V = 37% (95% CI, 26–49). These results prove that microsurgical resection is suitable for low-grade cAVMs (S-M grades I and II), whereas surgical resection of high-grade cAVMs (S-M grades IV and V) is associated with a high risk of poor patient outcome. Lawton and Davies et al. subcategorized grade III into three groups based on a specific combination of the same anatomical features (size, location, and venous drainage) to improve prediction of treatment outcome:

Group 1: Patients with S-M grade III cAVMs (a combination of small size, eloquent location, and deep venous drainage) have surgical outcomes similar to those of S-M grades I and II.

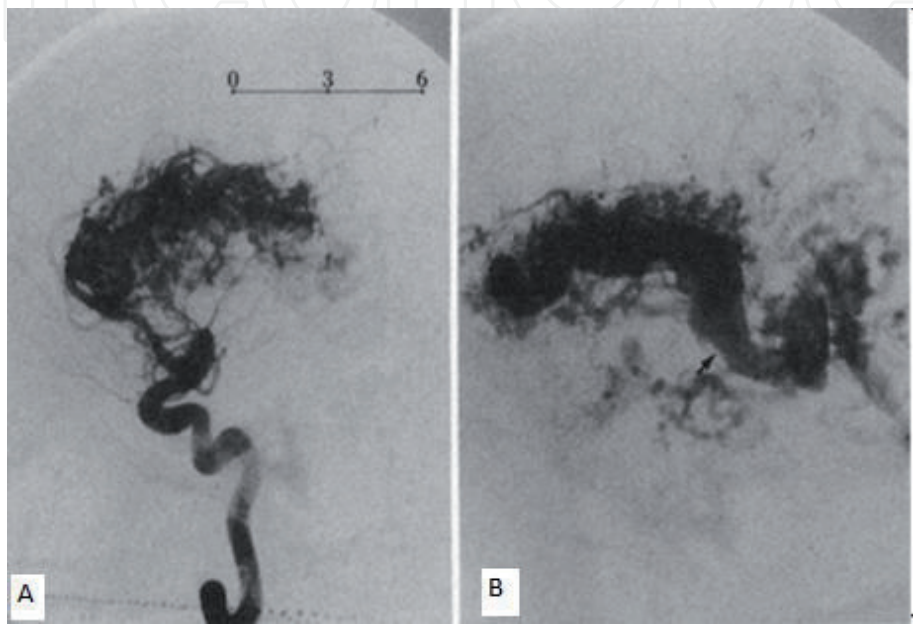


Figure 12.
Grade VAVM; (A) Carotid angiogram, arterial phase. (B) Venous phase, AVM greater than 6 cm (3 points), situated in corpus callosum with a deep thalamic component (eloquent: 1 point), draining into a hugely dilated internal cerebral vein (deep drainage–arrow 1 point) [19].

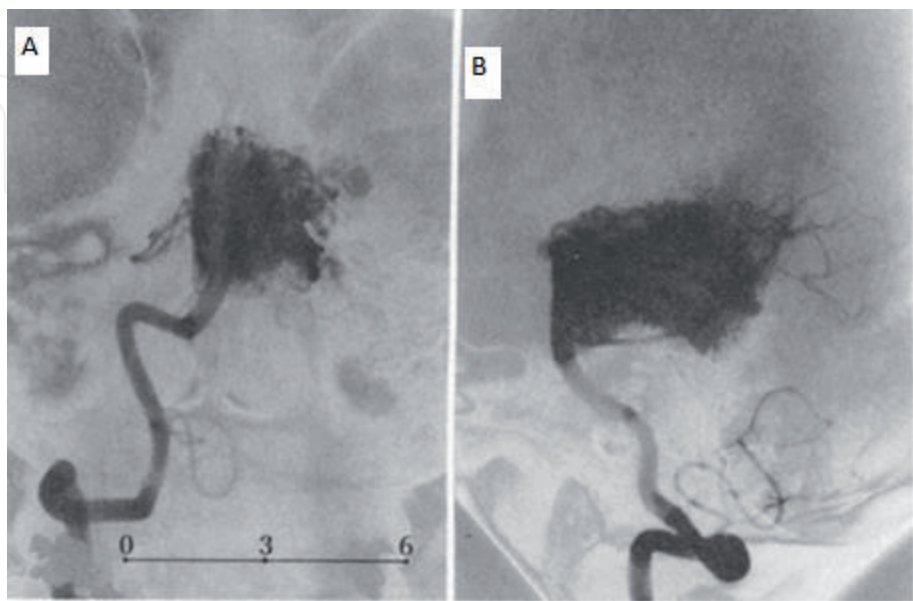


Figure 13.
Grade IV AVM (inoperable AVM), (A) Vertebral angiogram, anteroposterior view. (B) Lateral view, arterial phase this lesion fed by multiple vessels from rostral basilar artery, surrounding and invading the mesencephalon [19].

Size of cAVM	Point	Patient's age
0-3 cm	1	<20
3.1-6 cm	2	20-40
>6 cm	3	>40
Location of cAVM (eloquence area)		Compactness
No	0	Yes
Yes	1	No
Venous drainage		Bleeding
Superficial	0	Yes
Deep	1	No

Table 2.
Supplementary Spetzler-Martin or Lawton-Young cAVM grading scale.

Group 2: Patients with S-M grade III cAVMs (a combination of medium size, noneloquent location, and deep venous drainage) have a poor surgical outcome similar to that of S-M grades IV and V.

Group 3: Patients with S-M grade III cAVMs (a combination of medium size, eloquent location, and superficial venous drainage) have a poor surgical outcome similar to that of S-M grades IV and V [23].

Supplementary grading scale to traditional S-M grading scale was proposed in 2010 to enhance its predictive power for predicted outcomes after surgical resection of cAVMs. This supplemental scoring system added three factors that affect patient's outcome (age, hemorrhagic presentation, and nidus configuration) (**Table 2**). The supplementary grading scale named Lawton-Young supplementary grading scale has been authorized in a separate cohort of 1009 patients [21, 23].

6. Treatment of cAVMs

Complete resection or obliteration of the nidus and AV shunt is considered as the treatment of choice of cAVMs. Incomplete nidal resection does not decrease hemorrhage risk. However, There are few reports of partial resection may improve neurological symptoms in patients who have neurological symptoms related to hemodynamic. There are three complementary therapeutic techniques that have been developed to achieve these goals (microsurgery ± embolization, stereotactic radiosurgery, and embolisation). The treatment plans of cAVMs should be carefully taken by a multidisciplinary team of knowledgeable and skilled physicians. They should take the size, location, and vascular features of the AVM in consideration. Moreover, risks of significant complications such as short- and long-term hemorrhage risk, feasibility, associated aneurysm, patient's age, risks of intervention, availability of interventional radiologist, and size and compactness of the nidus should be assessed. The short- and long-term hemorrhage risk is associated with a history of ruptured cAVM, patient age, AVM location, size, and vascular morphological features [23–25].

Children and young adults have a long life expectancy, and the risk of intracerebral hemorrhage (ICH) is gradually increasing over the years. Therefore, curative therapy and complete obliteration are recommended whenever possible, while conservative treatment may be considered for elderly patients. The cumulative risk of hemorrhage can be calculated by the formula: lifetime risk of hemorrhage = 1 – (1 – P) × N (N is the expected years of life remaining, and P is the annual probability of hemorrhage). Another more straightforward formula is as follows: lifetime risk of hemorrhage = 105-patient's age in years.

6.1 Microsurgery

Craniotomy and surgical resection of cAVMs were first introduced in the 1920s, where the outcomes were inferior. The development of angiography played an essential role in understanding vascular anatomy and hemodynamics of AVM lesions. The introduction of microsurgery and bipolar diathermy has resulted in significant improvement of morbidity and mortality in comparison to the early known surgical resections. Microsurgical excision of cAVMs is considered as the most efficient approach as it offers the best chance of immediate cure and eliminates morbidity and mortality associated with its potential rupture. Before taking patients to the operating theater for surgical resection, preoperative angiogram and MRI should be done for intraoperative stereotactic localization of the lesion. Moreover, endovascular embolisation has frequently been considered to improve surgical safety and to possibly magnify the pool of cAVMs amenable to safe surgical resection. The main goals of endovascular embolisation are elimination of arterial feeders (particularly those that would be challenging to access in early stages of surgical intervention), decrease of nidus volume that would warrant safer surgical resection, and management of high-risk angiographic characters such as feeding artery and intranidal aneurysms.

Essential steps in the resection process of AVM are wide dural opening, identification of AVM lesion, elimination of superficial feeding arteries, circumferential resection of the nidus with control of deep arterial pedicle, and transection of draining veins. When all arterial feeders to the nidus have been determined and coagulated, the direct venous drainage can be blocked and the nidus resected. Intraoperative vascular imaging, such as DSA, is beneficial to confirm complete nidus resection at the time of surgery. Furthermore, indocyanine green videoangiography with either fluorescein or indocyanine can be very useful to intraoperatively map the angioarchitecture of the lesions, including distinguishing arterial feeders from arterialized draining veins.

The surgeons should vigilantly inspect the resection bed microscopically to make sure that hemostasis has been achieved, during which the blood pressure is maintained at 15–20 mm Hg above the baseline. Oxidized cellulose (Surgicel) can be used to line the nidus bed, and the patient's goal blood pressure should be maintained within the normal range for the first 24 hours after surgical resection.

Although the microscopic complete nidus resection has long-term durability and leads to abrupt elimination of hemorrhage risks, it is an invasive intervention and associated with neurological risks [23, 25].

6.2 Stereotactic radiosurgery (SRS)

Radiosurgery is typically reserved for the obliteration of compact cAVMs (less than 3 cm) in patients who are poor surgical candidates either radiographically (Spetzler-Martin grades >III) or due to existing medical comorbidities. SRS promotes endothelial cell proliferation, gradual, concentric vessel wall thickening, and ultimately luminal closure. Numerous studies about efficiency and safety of radiosurgery indicated that radiosurgery seems to be suitable for small-to-moderate volume lesions (less than 12 cm³ in volume or less than 3 cm in maximum diameter). Furthermore, radiosurgery is best suited for injuries situated in deep or eloquent regions of the brain. The primary goal of SRS is the obliteration of cAVMs. With obliteration, the risk of hemorrhage from cAVM nidus is eliminated. Complete obliteration of cAVM nidus after SRS is associated with fading of cAVM-associated epilepsy as well as improvement of nidus-associated neurological signs and symptoms.

Study	Number	Year	Design	Follow-up	Obliteration rate%	Annual hemorrhage rate before obliteration %	Permanent radiation injury %
Ding et al	444	2013	Retrospective	86 Month (mean)	62	1.6	2
Starke et al	2236	2016	Multicenter registry	7 year (median)	64.7	1.1	2.7
Pollock	174	2013	Retrospective	64 month (mean)	78.9	Not reported	4

Table 3.
Radio-surgical outcomes for unruptured cAVMs [23].

Most series with long-term follow-up show obliteration in 70–80% of cAVMs and it is achieved within 2–3 years after starting stereotactic radiosurgery (**Table 3**) [17, 20]. The time between starting radiosurgery and complete obliteration is named the latency period; it varies from 1 to 3 years. During this latency period, the risk of hemorrhage ranges between 1 and 3% per year. The outcome of radiosurgery has been affected by many factors such as age, nidus volume, preceding embolisation, and previous hemorrhage. Therefore, all these factors should be considered before deciding to proceed with radiosurgery.

Though preceding endovascular embolisation may shrink large nidus to a suitable target volume for SRS as well as eradicate high-risk characters associated with cAVM such as perinidal or intranidal aneurysms, it may lead to difficulties in precisely targeting residual nidus and reducing successful obliteration rates after SRS.

Radiosurgery is not entirely safe; during latency period, symptomatic changes secondary to radiation occur in 10 percent of the patients. However, permanent neurological changes are reported only in 2–3% of patients.

The main risk factors for symptomatic changes secondary to radiations are the location of AVM, target volume, and dose to surrounding healthy tissue (margin dose). The symptomatic changes secondary to radiation effect can be reduced with corticosteroids and bevacizumab.

Delayed cyst formation and radiation-induced neoplasia are uncommon although may occur after 10 years from radiosurgery [23, 26, 27].

6.3 Embolisation

Endovascular embolisation plays a crucial role in multidisciplinary approach to treat cAVMs. Embolisation may be considered in the following scenarios:

6.3.1 Preoperative embolization

The primary goal of preoperative embolisation is to facilitate surgical resection of cAVMs and reduce complication rates of microsurgery. It is instrumental in the reduction of intraoperative bleeding and postoperative complications such as healthy perfusion pressure breakthrough. The healthy brain tissue surrounding cAVMs exposes to chronic low perfusion pressure. When the lesion is wholly or partially resected, these areas are suddenly subject to normal perfusion pressure, and their autoregulation ability may be impaired. Therefore, a sudden increase in perfusion pressure may lead to brain edema, delayed hemorrhage, and seizures. Large cAVMs should go through staged embolisation to gradually

reduce flow to the AVM before resection. Moreover, preoperative embolisation may be useful in the elimination of feeding artery pedicles that may be deep and not accessible [23, 28, 29].

6.3.2 Curative embolisation

The role of endovascular embolisation as a stand-alone treatment in AVM has been reported in small case series. The introduction of detachable-tip microcatheters plays a vital role in improvement of curative embolisation rates as it facilitates extended Onyx infusion. Small lesions with few arterial feeders are most suitable for complete curative embolisation. However, most of these lesions are graded as S-M grades I and II, for which microsurgery is considered as the best therapeutic approach. Therefore, the relative risk of curative embolisation must be weighed cautiously against this traditional therapeutic approach. The durability of embolic materials and the length of follow-up are needed to establish a complete cure. AVM recurrence after successful complete angiographic elimination has been reported in various case reports [23, 30, 31].

6.3.3 Before radiosurgery

Embolisation before radiosurgery is commonly used when cAVM nidus is greater than 3 cm in diameter to reduce the size of the nidus. However, embolisation may lower rates of successful obliteration, most likely due to the artifact effect of the radiopaque embolic interfere with targeting the lesion [23, 32].

6.3.4 Targeted embolization

Targeted embolisation is used to treat high-risk angiographic features such as nidal and perinidal aneurysms and arteriovenous fistulas that may lead to rupture of AVM [33].

6.3.5 Palliative embolization

Infrequently, cAVMs may cause focal neurological deficits as a result of vascular steal or local venous hypertension. In these situations, decreased venous hypertension and steal by embolisation of select, high-flow feeders may improve focal neurological deficit and quality of life. However, there is no substantial evidence to support this approach and further studies are needed [23, 34, 35].

6.3.6 Complications of embolization

Stroke and ICH are the most common complications of endovascular embolisation. The ischemic stroke is most likely secondary to thromboembolic complications of catheterization and nontarget embolization, while ICH may occur secondary to vascular injury or AVM rupture. Arterial feeders' injury and perforation occur when a microcatheter or wire is introduced through tiny tortuous pial arteries. Accidental closure of draining veins before elimination of the nidus during embolization may cause nidal rupture and ICH [23, 35, 36].

7. Conclusion

Cerebral arteriovenous malformations (cAVMs) are rare congenital disease. However, they are considered as a significant cause of hemorrhagic stroke in

children and young adults. They account for 33% of intracerebral hemorrhage in young patients. Although it is congenital disease, patients with cAVMs mostly present in their second and fourth decades of life. Intracerebral hemorrhage is the most common presentation of AVM patients. Imaging such as CT, MRI, and angiography is advantageous in diagnosis, grading, risk assessment, and posttherapeutic follow-up. cAVMs are graded by many grading systems. However, Spetzler-Martin grading and supplementary Spetzler-Martin grading scales are the most important grading scales as they can be used to assess risk of postoperative complications and therapeutic outcomes. Therefore, they are beneficial in deciding best therapeutic approach for each patient. There are three therapeutic modalities for management of cAVMs. The multidisciplinary team approach is the best for management of cAVM patients. The surgical excision of cAVM gives definitive therapy in cAVM patients. Radiosurgery is a curative approach in selected cAVM patients, and embolisation is rarely used as a sole therapy. It is usually used as adjunctive therapy to microsurgery and SRS.

Author details

Adel E. Ahmed Ganaw^{1*}, Abdulgafoor M. Tharayil¹, Moad Ehfeda¹, Mohamed Hassan Alfared², Qazi Zeeshan¹, Sohel M.G. Ahmed¹, Ali Ayyad³, Ibrahim Naemi¹, Hossam Algallie¹, Nissar Shaikh¹ and Nabil Shallik¹

¹ Anesthesiology, Intensive Care and Perioperative Medicine, Hamad General Hospital, Hamad Medical Corporation, Qatar

² Radiology Department, Hamad General Hospital, Hamad Medical Corporation, Qatar

³ Neurosurgery Department, Hamad General Hospital, Hamad Medical Corporation, Qatar

*Address all correspondence to: aganaw@hamad.qa

IntechOpen

© 2019 The Author(s). Licensee IntechOpen. This chapter is distributed under the terms of the Creative Commons Attribution License (<http://creativecommons.org/licenses/by/3.0>), which permits unrestricted use, distribution, and reproduction in any medium, provided the original work is properly cited. 

References

- [1] Pandhare MN, Jyoti DB, Suresh RB. Acquired arteriovenous malformation of lip occurring as occupational hazard: A case report with review of literature. *Journal of Oral and Maxillofacial Pathology*. 2018;22(2):287
- [2] Osbun JW. Arteriovenous and cavernous malformations. In: *Handbook of Clinical Neurology*. Vol. 143. 3rd series. B.V USA: Elsevier; 2017. DOI: 10.1016/B978-0-444-63640-9.00003-5
- [3] Ondra SL, Troupp H, George ED. The natural history of symptomatic arteriovenous malformations of the brain: A 24-year follow-up assessment. *Journal of Neurosurgery*. 1990;73(3):387-391
- [4] Lawton MT. Brain arteriovenous malformations. *Nature Reviews Disease Primers*. 2015;28:15008. DOI: 10.1038/nrdp.2015.8
- [5] Berman MF, Sciacca RR, Pile-Spellman J. The epidemiology of brain arteriovenous malformations. *Neurosurgery*. 2000;47:389-397
- [6] Hofmeister C. Demographic, morphological, and clinical characteristics of 1289 patients with brain arteriovenous malformation. *Stroke*. 2000;31:1307-1310
- [7] Kim H. Untreated brain arteriovenous malformation: Patient-level meta-analysis of hemorrhage predictors. *Neurology*. 2014;83:590-597
- [8] Willinsky RA, Lasjaunias P, Terbrugge K, Burrows P. Multiple cerebral arteriovenous malformations (AVMs). Review of our experience from 203 patients with cerebral vascular lesions. *Neuroradiology*. 1990;32:207
- [9] Mohr JP, Kejda-Scharler J, Pile-Spellman J. Diagnosis and treatment of arteriovenous malformations. *Current Neurology and Neuroscience Reports*. 2013;13(2):324
- [10] Hetts SW, Cooke DL, Nelson J. Influence of patient age on angioarchitecture of brain arteriovenous malformations. *AJNR. American Journal of Neuroradiology*. 2014;35(7):1376-1380
- [11] Stapf C, Mast H, Sciacca RR. Predictors of hem-orrhage in patients with untreated brain arteriovenous mal-formation. *Neurology*. 2006;66(9):1350-1355
- [12] Manzato LB, Vanzin JR, Frighetto L, Filho PM, Pedrolo E, et al. Multiple cerebral arteriovenous malformation: Report of two cases and treatment strategy. *Journal of Neurology and Neurophysiology*. 2017;3(1):1-4. DOI: 10.16966/2379-7150.138
- [13] Choi JH, Mast H, Sciacca RR. Clinical outcome after first and recurrent hemorrhage in patients with untreated brain arterio-venous malformation. *Stroke*. 2006;37:1243-1247
- [14] Ding D, Starke RM, Quigg M. Cerebral arteriovenous malformations and epilepsy, part 1: Predictors of seizure presentation. *World Neurosurgery*. 2015;84(3):645-652
- [15] July J, Wahjoepramono EJ. editors. Gamma knife surgery for AVM. *Neurovascular Surgery*. 2019:275-283. DOI: 10.1007/978-981-10-8950-3-32
- [16] Rajesh RU, George T, Manickam A. Cerebral arterio venous malformation. *International Journal of Clinical & Medical Images*. 2015;2(9):1-2. DOI: 10.4172/2376-0249.1000369
- [17] Zahouani T, Lopez S, Standish-Parkin L, et al. High grade incidental arteriovenous malformation. *Annals*

of Clinical and Laboratory Research. 2017;**5**:1

[18] Kim DJ, Krings T. Whole-brain perfusion CT patterns of brain arteriovenous malformations: A pilot study in 18 patients. *AJNR. American Journal of Neuroradiology*. 2011;**32**:2061-2066

[19] Shiva Shankar JJ, Lum C. Whole brain perfusion on a 320-slice CT scanner. *Indian Journal of Radiology and Imaging*. 2011;**21**:209-214

[20] Roh K, Kang H, Kim I. Clinical application of neuroimaging with susceptibility weighted imaging: Review article. *Journal of the Korean Society of Magnetic Resonance in Medicine*. 2014;**18**(4):290-302

[21] Poncea FA, Spetzler RF. Arteriovenous malformations: Classification to cure. *Clinical Neurosurgery*. 2011;**58**:10-12

[22] Spetzler RF, Martin NA. Proposed grading system for arteriovenous malformation. *Journal of Neurosurgery*. 1986;**65**:476-483

[23] Derdeyn CP et al. Management of brain arteriovenous malformations. A scientific statement for healthcare professionals from the American Heart Association/American Stroke Association. *Stroke*. 2017;200-224. DOI: 10.1161/STR. 000000000 0000134

[24] Solomon RA, Connolly ES. Arteriovenous malformations of the brain. Review article. *The New England Journal of Medicine*. 2017;**376**:19

[25] Barr JC, Ogilvy CS. Selection of treatment modalities or observation of arteriovenous malformations. *Neurosurgery Clinics of North America*. 2012;**23**:63

[26] Pan HC, Sheehan J. Late cyst formation following gamma

knife surgery of arteriovenous malformation. *Journal of Neurosurgery*. 2005;**103**(suppl):124-127

[27] Starke RM, Yen CP, Chen CJ, Ding D, Mohila CA, Jensen ME, et al. An updated assessment of the risk of radiation-induced neoplasia after radiosurgery of arteriovenous malformations. *World Neurosurgery*. 2014;**82**:395-401. DOI: 10.1016/j.wneu.2013.210.02.008

[28] Gutiérrez-González R, Gil A, Serna C, López-Ibor L, Boto GR. Normal per-fusion pressure breakthrough phenomenon: What still remains unknown. *British Journal of Neurosurgery*. 2012;**26**:403-405. DOI: 10.3109/02688697.2011.633637

[29] Spetzler RF, Wilson CB, Weinstein P, Mehdorn M, Townsend J, Telles D. Normal perfusion pressure breakthrough theory. *Clinical Neurosurgery*. 1978;**25**:651-672

[30] Moon K, Levitt MR, Almefty RO, Nakaji P, Albuquerque FC, Zabramski JM, et al. Safety and efficacy of surgical resection of unruptured low-grade arteriovenous malformations from the modern decade. *Neurosurgery*. 2015;**77**:948-952. DOI: 10.1227/NEU.0000000000000968

[31] Bauer AM, Bain MD, Rasmussen PA. Onyx resorbtion with AVM re-canalization after complete AVM obliteration. *Interventional Neuroradiology*. 2015;**21**:351-356. DOI: 10.1177/1591019915581985

[32] Kano H, Kondziolka D, Flickinger JC, Park KJ, Iyer A, Yang HC, et al. Stereotactic radiosurgery for arteriovenous malformations after embolization: A case-control study. *Journal of Neurosurgery*. 2012;**117**:265-275. DOI: 10.3171/2012.4.JNS111935

[33] Brown RD, Wiebers DO, Forbes GS. Unruptured intracranial

aneu-rysms and arteriovenous malformations: Frequency of intracranial hem-orrhage and relationship of lesions. *Journal of Neurosurgery*. 1990;**73**:859-863. DOI: 10.3171/jns.1990.73.6.0859

[34] Batjer HH, Devous MD, Seibert GB, Purdy PD, Ajmani AK, Delarosa M, et al. Intracranial arteriovenous malformation: Relationships between clinical and radiographic factors and ipsilateral steal severity. *Neurosurgery*. 1988;**23**:322-328

[35] Kusske JA, Kelly WA. Embolization and reduction of the “steal” syndrome in cerebral arteriovenous malformations. *Journal of Neurosurgery*. 1974;**40**:313-321. DOI: 10.3171/jns.1974.40.3.0313

[36] Asadi H, Kok HK, Looby S, Brennan P, O’Hare A, Thornton J. Outcomes and complications after endovascular treatment of brain arteriovenous malformations: A prognostication attempt using artificial intelligence. *World Neurosurgery*. 2016;**96**:562-569.e1. DOI: 10.1016/j.wneu.2016.09.086