

We are IntechOpen, the world's leading publisher of Open Access books Built by scientists, for scientists

6,900

Open access books available

186,000

International authors and editors

200M

Downloads

Our authors are among the

154

Countries delivered to

TOP 1%

most cited scientists

12.2%

Contributors from top 500 universities



WEB OF SCIENCE™

Selection of our books indexed in the Book Citation Index
in Web of Science™ Core Collection (BKCI)

Interested in publishing with us?
Contact book.department@intechopen.com

Numbers displayed above are based on latest data collected.
For more information visit www.intechopen.com



Challenge of Xenotransplantation in Pediatric Heart Transplantation

Norihide Fukushima, Motohiro Kawauchi, Francois Bouchart, Sandra Nehlsen-Cannarella and Leonard L. Bailey

Abstract

Although surgical techniques have progressively improved in the field of congenital heart disease (CHD), even such as hypoplastic left heart syndrome, pediatric heart transplantation is the most effective surgical option for complex CHD and cardiomyopathy with severe heart failure. However, even now, donor heart availability has been poor in children. Although technologies for ventricular assist device (VAD) have been progressing even in children, VAD cannot grow as the pediatric recipient grows. Therefore, pediatric cardiac xenotransplantation has a great possibility to save and grow children with end-stage heart failure. In this chapter, I would like to introduce the first pediatric baboon-to-human heart transplantation and its basic animal experiments done by Bailey's group and the following attempts for pediatric cardiac orthotopic xenotransplantation (rhesus monkey-to-baboon and pig-to-primate combination).

Keywords: concordant and discordant xenogeneic orthotopic heart transplantation, pediatric heart transplantation, clinical trial, antibody absorption, primates, pig, goat, lamb

1. Introduction

Clinical heart transplantation (HTx) was the unambiguous goal of the laboratory research at Stanford University in the mid-1960s [1]. They were making tremendous progress in their understanding of the host immune response, and how to control that response with drugs of that era, while at the same time avoiding lethal infection. Then, unexpectedly, on December 3, 1967, Christiaan Barnard et al. performed the first clinical HTx in Cape Town, South Africa [2]. Their recipient survived only 18 days, dying of pneumonia. Nevertheless, it stirred worldwide enthusiasm for HTx, and, more importantly, it opened the door for the Stanford group to develop the procedure in human.

But with regard to infants, Adrian Kantrowitz at New York attempted HTx in a newborn from an anencephalic baby just 3 days after Barnard's first HTx [3]. The recipient died 6 and a half hour after the procedure, and Kantrowitz never pursued clinical HTx. In the 1970s, there have been great progresses in medical and intensive management and surgical technology for neonates and infants with complex congenital heart. However, almost all neonates and infants with too complexed congenital anomaly, especially hypoplastic left heart syndrome (HLHS), could not survive surgery. Theoretically, these neonates, with naïve immune systems and

uniformly lethal heart disease, should be excellent candidates for HTx that included aortic arch reconstruction. But around for a decade since the first HTx, clinical HTx was limited to only a handful of progressive institutions, and none was spearheading research in neonatal HTx except a little Leonard L Bailey's group at Loma Linda University.

His laboratory was using neonatal goats as recipients, and, initially, goats as donors. In 1981, the Sandoz Laboratory, a pharmaceutical house in Basel, Switzerland, agreed to provide them with an investigational agent called cyclosporine-A (CsA). With CsA immunosuppression alone, they observed remarkable survival, maturation, and reproductive capacity among goats that were orthotopically transplanted as newborns with allografts [4]. Even recipients of cross-species grafts from lamb to goat experienced unprecedented survival [5].

2. Lamb to goat orthotopic concordant xenoHTx

Fourteen newborn (less than 7 days old) goats underwent orthotopic HTx with a size-matched lamb's heart [5]. Ten goats survived longer than 24 hours after HTx. Recipient animals received CsA 48 and 24 hours before HTx and daily after HTx on a gradually reducing daily protocol. Recipients were also given pulse doses of methylprednisolone (100 mg/kg) and azathioprine (3 mg/kg) once a week, the dosage schedule being gradually reduced. Azathioprine was discontinued on postoperative day 60. Survival among the 10 recipients was 24, 32, 44, 47, 60, 60, 78, 90, 120, and 165 days. Average survival was 72 days. Serial left ventricular ejection fractions measured by radionuclide left ventriculography from 1 to 4 months postoperatively in four recipients averaged 50, 58, 45, and 45%. There were no significant infections. Most animals showed mild-to-moderate subacute and chronic graft rejection at autopsy. One host showed no gross or microscopic graft rejection at autopsy on postoperative day 47. Tumor was not observed. These data suggest that long-term survival may be feasible for newborn recipients of cardiac xenografts with CsA therapy and limited supplemental immunosuppression.

3. Attempt of a baboon-to-human orthotopic concordant xenoHTx

Neonatal and small infant heart donors were not available in the early 1980s; hence, the Bailey's group focused on the possibility of using immature baboons as donors for neonates with HLHS. They purchased a panel of infant baboons and studied them extensively for infectious diseases. They performed HLA-typing, two-way mixed lymphocyte cultures, and ex vivo perfusion studies to assess their compatibility with human neonates. They thought it might be possible to actually select a "best" baboon donor for any individual baby with HLHS. They began an arduous 14-month process of obtaining Institutional Review Board (IRB) approval for experimental clinical trials of baboon-to-human baby concordant xenoHTx. Sandra Nehlsen-Cannarella, a transplant immunologist and Medawar protégé, was one of external reviewers, helped their works, and finally joined their team after the IRB was approved in October 1984 [6].

Then, in late July of 1984, Dr. Magdi Yacoub and his team at the National Heart Hospital in London transplanted an 11-day-old newborn with HLHS [7], but the recipient had a complex postoperative course and died of respiratory failure on postoperative day 4. Later that same year, in October, the Bailey's group were confronted with the potential to activate our IRB-approved protocol. A neonate

with HLHS named “Baby Fae” was transplanted on October 26, 1984, with the heart of a highly selected infant baboon [8, 9]. She lived for only 20 days, and despite careful observations and analysis, the cause(s) of her death remains somewhat of an enigma. She did heighten awareness, however, and her transplant led directly to the first successful neonatal HTx, again as treatment for HLHS, in November of 1985. That infant is now a 34-year-old man working in Las Vegas. Baby Fae’s legacy is found among the hundreds of neonates and small infants who are living today because of primary or secondary HTx in the world. However, donor shortage had been still severe, and continuous experimental efforts to achieve clinical infant xenoHTx had been performed in the Bailey’s group.

4. The immunological effects of concordant xenograft bridging to cardiac allografting in baboon

Human neonatal xenoHTx evolved around the idea of xenograft bridging to cardiac allografting. The important question relating to this approach was whether the bridged recipient would develop an antibody response to the initial xenograft that would be cross-reactive with the allograft donor. This question was initially explored by Alonso de Begona [10] using a heterotopic HTx model from African green monkey to juvenile baboons treated with CsA (Table 1). These 5 grafts are rejected over a period of 5–65 days. Lymphocytotoxic xenoantibody was identified in recipient blood samples. The rejected xenografts were removed, and the recipient circulating xenoantibody titers were observed to peak over 24–48 hours. Using cardiopulmonary bypass primed without blood, the immature baboon recipients then underwent orthotopic allogeneic HTx and were treated with varying degrees using a cyclosporine (CSA) protocol. All survived the secondary allogeneic HTx without any evidence of hyperacute, antibody-mediated rejection. The recipients survived 10, 58, 65, 198, and 164 days. Despite a high titer of circulating xenoantibody in each of the host baboons, orthotopic allogeneic engraftment was possible in all five recipients. Each was immunosuppressed with gradations of CSA-based therapy. Survival to 5 and 6 months of the last two consecutive animals (which were ultimately euthanized) was not unlike that expected for

Cardiac heterotopic xenograft (African green monkey)				Cardiac orthotopic allograft (common olive baboon)			
	Therapy ^a	Rescue therapy	Survival (days)		Therapy ^a	Rescue therapy	Allograft rejection
1	A	None	11	A	None	10	Severe
2	A	None	5	A	B	58	Moderated to severe
3	A	None	6	A	B	65	Moderated to severe
4	A + B	B + C	13	A	B + C	198 ^b	None
5	A + B + C	None	65	A + B	None	164 ^b	None

^aImmunosuppression. (A) cyclosporine + azathioprine + solumedrol; (B) goat anti-human T cell IgG; (C) monoclonal antibody.
^bElectively euthanized.

Table 1.
Survival of xenografts and allografts and host therapy employed in a xenograft bridge to allograft model using an immature baboon recipient.

allotransplanted hosts. Xenoantibody did not appear to alter acute or chronic survival of baboon recipients managed with a clinically applicable regimen of immune regulation. The two chronic survivors had well-functioning allografts that were free of significant rejection injury. These findings have subsequently been confirmed and elaborated on by Michler et al. [11].

5. Rhesus monkey to baboon orthotopic concordant xenoHTx

Orthotopic concordant xenotransplantation in a juvenile primate model was examined [12, 13]. Eighteen donor rhesus monkeys weighing 2.4–3.8 kg (mean 2.9 kg) were matched with juvenile baboons, aged 9–19 months (mean 12.7 months) and weighing 3.2–4.8 kg (mean 3.9 kg), using ABH blood type and mixed lymphocyte culture. In order to examine plasma level of tacrolimus (Tac) in infant baboons and establish immunosuppressive regimen before starting orthotopic xenoHTx experiments [14], seven of these baboons already received two courses of 4-week immunosuppressive therapy prior to HTx. All baboons underwent splenectomy at the time of HTx.

Twelve animals were divided into three groups; five baboons received no immunosuppressive therapy (Group-C). Five baboons were pretreated (Group-P) and the other seven (Group-NP) was not pretreated. Twelve baboons received sheep antilymphocyte globulin (ALG; IV 15 mg/kg) induction for 3 days before the operation and 5 days after xenoHTx and oral tacrolimus (Tac; 18 mg/kg) and intravenous methotrexate (MTX; 0.1–5 mg IV twice weekly) daily after xenoHTx. The baboons in Group-P received two courses of 4-week immunosuppressive therapy prior to xenoHTx; the first course consisted with Tac (18 mg/kg p.o. daily) alone and the second one consisted with Tac (12 mg/kg p.o. daily) and methotrexate (MTX; 25 mg IV weekly). Pretreated baboons had drug-free intervals for 37 days between two courses and for 83–110 days between the second course and xenoHTx. Intravenous methotrexate, methylprednisolone, ALG, and their combination were used as rescue therapy (**Table 2**).

Baboons in group-C had a mean survival of 8 days; all died as a result of classic severe cellular rejection. Baboons in Group-NP had a mean survival of 51.3 days (25–75 days), and those in Group-P had a mean survival of 198 days (35–502 days). Two in Group-NP died during rescue therapy for rejection, and three in Group-NP and two in Group-P died of cytomegalovirus (CMV) infection. One in Group-NP died of massive micro-pulmonary embolism. The remaining two in Group-P died of *Klebsiella pneumoniae* and renal failure aggravated by ganciclovir, respectively.

The longest surviving baboon, named Max, had been a healthy, active, growing baboon with normal cardiac function assessed by echocardiography and left ventriculography and coronary arteries normal in size and distribution assessed by coronary arteriograms at 1 year after xenoHTx. After these examinations, we tried to convert him to oral medications, and his level of immunosuppression fluctuated widely, which led to a late, powerful rejection response. This xenograft rejection was reversed successfully using corticosteroids and ALG. The additional bolus immunosuppression, however, permitted the development of generalized CMV disease and eventually bacterial sepsis from which Max (**Figure 1**) ultimately died. The animal's autopsied xenograft was almost free of cellular rejection but with mild coronary graft atherosclerosis [15].

Management of CMV infection in this splenectomized series of baboon recipients proved to be at least as difficult as controlling the immune response toward their cardiac xenografts. However, Tac coupled with low-dose maintenance

methotrexate and splenectomy has produced prolonged host survival in this xenotransplantation model. Results suggest that concordant xenotransplantation would be a suitable biologic bridge to allotransplantation.

Survival (days)	Histological findings of autopsied xenograft	Rescue therapy (onset day after transplant)	Cause of death
Group-C ^a			
1 6	Moderate cellular rejection	None	Rejection
2 7	Moderate cellular rejection	None	Rejection
3 8	Severe cellular rejection	None	Rejection
4 8	Severe cellular rejection	None	Rejection
5 9	Severe cellular rejection	None	Rejection
6 10	Severe cellular rejection	None	Rejection
Group-NP ^a			
1 25	CMV infection, no rejection	ALG (21)	Systemic CMV infection
2 32	CMV infection, no rejection	None	CMV infection (graft)
3 43	Cellular infiltration to coronary arteries	None	CMV infection (lung, kidney)
4 53	Mild cellular rejection	ALG (68)	CMV infection (lung)
5 57	Mild cellular rejection	ALG + MP (13), Up ^b Tac + ALG + MP (38)	During rejection treatment
6 74	Mild cellular rejection Mild graft atherosclerosis	Up ^b MTX (25)	Pulmonary embolism
7 75	Mild cellular rejection	ALG + MP (29, 62)	During rejection treatment
Group P ^a			
1 35	Mild cellular rejection	None	<i>Klebsiella pneumonia</i>
2 96	No rejection	ALG + MP (71)	Renal failure
3 123	Patchy fibrosis in septum and inferior wall	None	CMV infection (lung, kidney)
4 234	Toxoplasmosis	ALG (94d)	Toxoplasmosis
5 502	Mild cellular rejection Mild graft atherosclerosis	Up ^b Tac and MTX (68, 238), ATGAM+MP (392), MP (482)	Liver failure and CMV infection

ALG, sheep antilymphocyte globulin; CMV, cytomegalovirus; MP, methyl prednisolone; Tac, tacrolimus; MTX, methotrexate; ATGAM, equine anti-thymocyte globulin.

^aGroup-C: controls. Group-NP: intravenous sheep antilymphocyte globulin (ALG) induction at -3 and + 5 days perioperatively, daily oral tacrolimus (Tac), and twice weekly intravenous methotrexate (MTX) after transplantation. Group-P: two courses of 4-week immunosuppressive therapy (1st course, oral Tac alone; 2nd course, oral Tac and intravenous MTX) prior to transplantation and the same immunosuppressive therapy after transplantation as for Group-NP.

Groups NP and P subjects had splenectomy at the time of heart transplantation.

^bincrease dose.

Table 2.
Results of orthotopic cardiac xenotransplantation between immature baboon recipients and rhesus monkey donors.



Figure 1.
Max, an immature baboon recipient of an orthotopic cardiac xenotransplant acquired from a donor rhesus monkey.

6. Toward discordant xenoHTx

Although the high degree of evolutionary relatedness between human beings and primates both suggests that xenotransplantation of primate organs and tissue might be successful, particular concerns are raised by the use of primates, such as baboons. The characteristics, for example, of intelligence and complex social interactions of these closely related higher primates appear to be so like those of human beings that use members of those species as sources for xenotransplantation which might well be seen as ethically unacceptable [16]. The potential risk of extinction, even to a species like the baboon that is not currently endangered, must be taken seriously. The possible transmission of disease from higher primates to human beings and the welfare of the animals should be concerned. From these concerns, it is currently agreed that the use of primates would be ethically unacceptable.

Given the ethical concerns raised by the use of primates for xenotransplantation, attention has turned to developing the pig as an alternative source of organs and tissue, because the use of pigs for xenotransplantation raises fewer ethical concerns. Attention has focused in particular on pigs, since their organs are comparable in size to human ones, and they breed rapidly and could thus be used to supply transplant material on a large scale. The use of pigs as a domestic animal that is farmed and eaten is long established, and many would have fewer concerns about their use for xenotransplantation than the use of primates. If pigs are used for xenotransplantation, they are likely to have been genetically modified so the human immune response to the pig organs and tissue is reduced [16].

When a pig organ is transplanted into a human or nonhuman primate, an immediate immune response occurs with hyperacute rejection (HAR). This has been defined as destruction of the graft in less than 24 hours; however, it usually occurs

within the first hour. This is due to the binding of the preformed anti-pig antibodies (Ab) to the endothelial cells of the graft. Ab deposits initiate a complement-mediated response with endothelial injury, resulting in thrombosis, interstitial hemorrhage, and edema, with subsequent graft dysfunction [17]. Later, it was determined that Ab bind to the carbohydrate epitope, galactose- α 1,3-galactose (Gal), expressed in the pig vascular endothelium. This oligosaccharide is present in other mammals, except humans and primates. These Ab are produced in response to viruses and microorganisms that express Gal and colonize the gastrointestinal tract of primates [18].

7. Pig-to-baboon orthotopic discordant xenoHTx

The feasibility of transplanting across discordant xenogeneic barriers in an orthotopic newborn pig-to-juvenile baboon model was first explored in the Bailey’s

Treatment		Survival (hours)	Pathology of autopsied xenograft	Cause of death
Lung perfusion	Exsanguination			
Group-C ^a				
1 ^b None	None	4.5	HAR	Rejection
2 None	None	18	HAR	Rejection
Group-D ^a				
1 ^c Donor lung	None	6.5	HAR	Rejection
2 Donor lung	None	10	HAR	Rejection
3 ^d Donor lung	None	375	Mild DXR and GCAS	CMV infection
Group-LD ^a				
1 Large pig lung	None	99	Pneumonia	Pneumonia
2 Large pig lung	None	111	DXR	Rejection
Group-D + E ^a				
1 Donor lung	Blood replacement	117.5	DXR	Brain death
2 ^c Donor lung	RBC/serum replacement	100	DXR	Rejection
3 Donor lung	RBC/serum replacement	111	DXR	Rejection
4 Donor lung	RBC/serum replacement	123	DXR	Rejection
5 Donor lung	RBC/serum replacement	174.5	DXR, CR	Rejection

^aGroup-C, controls; Group-D, donor lung perfusion; Group-LD, perfusion with another large pig lungs; Group-D + E, donor lung perfusion, exsanguination, and replacement with whole blood pretreated or packed red blood cell (RBC) and serum pretreated.

^bNo immunosuppression therapy.

^cKidney perfusion in case of suspected antibody-mediated rejection.

^dThymic injection with donor myocardium (left atrium).

All subjects had pretransplant splenectomy. CMV, cytomegalovirus; RBC, red blood cell; HAR, hyperacute rejection; DXR, delayed xenograft rejection; CR, cellular rejection.

Table 3.
Results of orthotopic cardiac xenotransplantation between juvenile baboon recipients and piglet donors.

laboratories during the early 1990s. Because HAR was at that time the single most important factor in limiting discordant xenoHTx, early strategies were directed toward eliminating or reducing baboon preformed xeno Ab to pig sugar antigens [19, 20].

All recipient baboon underwent splenectomy 2 weeks before HTx. Donor hearts were obtained from 12 newborn piglets of either sex age 2–7 days and weighing 1.8–3.1 kg (mean 2.3 ± 0.1 kg) and transplanted orthotopically with deep hypothermia and circulatory arrest in recipient juvenile baboon age 252–459 days (mean 362 ± 19 days) and weighing 2.4–3.5 kg (mean 2.9 ± 0.1 kg). All animals received an infusion of nafamostat mesylate (FUT-175) at a dose of 2 mg/kg/h for 2 h at the time of reperfusion. The recipient baboon received 15 mg/kg CsA orally or 5 mg/kg intravenously and 5 mg/kg 15-deoxyspergualin (DSG) intramuscularly, from the day before HTx until death.

In two baboons, no antibody adsorption (AbA) using pig lungs was performed for control (Group-C). In 10 baboons, the blood in the bypass circuit was perfused into a pig lung to absorb baboon anti-pig antibody during circulatory arrest at the time of HTx. In three baboons (Group-D), the donor lung was perfused, and in two baboons (Group-LD), a lung larger than the donor pig (weighing 5–7 kg) was perfused. In five baboons (Group-D + E), the donor lung was perfused, and exsanguination was also performed at the beginning of cardiopulmonary bypass (CPB), and the baboon blood was replaced with pretreated whole blood (N = 1) or packed red blood cell (RBC) and 50 ml of pretreated plasma (N = 4). The pretreated blood (N = 1) and serum (N = 4) were made by perfusing with other large pig lung (weighing 15 and 20 kg) before xenoHTx. Two baboons underwent pig kidney perfusion using an extracorporeal shunt from the right femoral artery to vein, 5 and 6 days after xenoHTx, because antibody-mediated rejection was suspected.

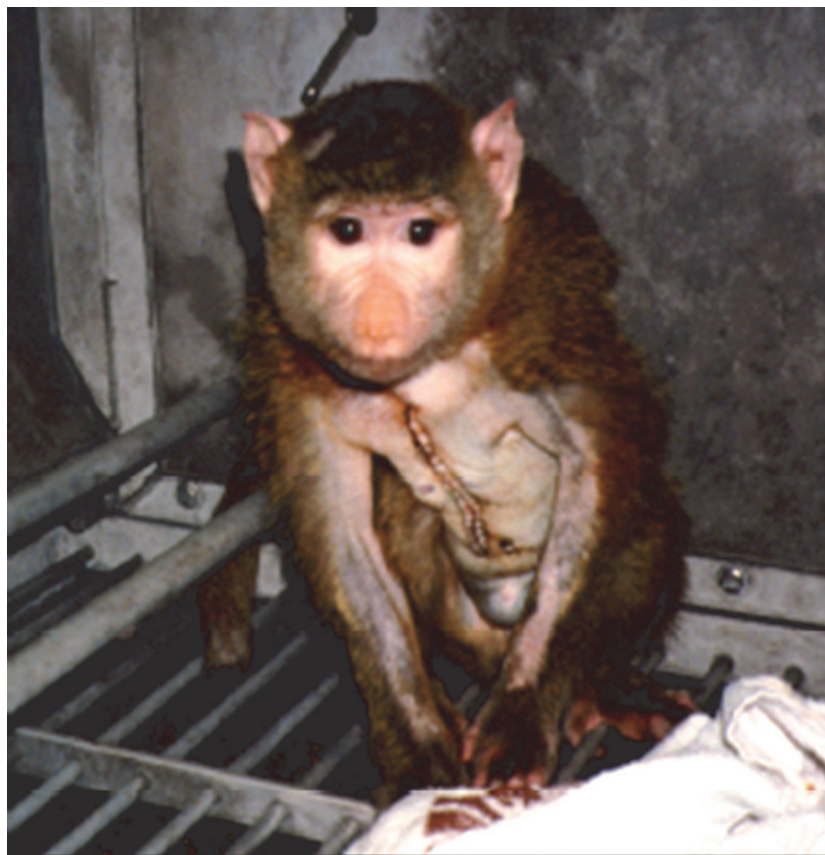

Figure 2.
An immature baboon recipient of an orthotopic cardiac xenotransplant acquired from a donor pig, which survived 6 days after xenotransplant.

The two control animals survived 4.5 and 18 hours, and the pathological changes of the grafts were compatible with HAR. The other animals survived 125 ± 33 h (10–375 hours). The longest surviving baboon who survived 375 hours was in Group-D, but other two in Group-D died of HAR. All baboons in Group-LD and Group-D + E survived more than 4 days after XenoHTx. One in Group-D died of CMV infection and one in Group-LD died of pneumonia. One in Group-LD and four in Group-D + E died of acute cellular rejection. In summary, examination and echocardiography revealed no evidence of hyperacute rejection in baboons surviving more than 1 day. The longest survivor (375 hours) died of CMV infection with microscopic evidence of mild delayed HAR and graft coronary atherosclerosis. A variable amount of delayed xenograft rejection (DXR) was observed histologically, among the other recipient baboons (**Table 3** and **Figure 2**) [20].

Another baboon which underwent large pig lung perfusion and is given Tac + MTX without splenectomy survived 16 days, and the autopsied graft showed mild DXR and moderate GCAS [20].

8. The role of anti-pig antibody in pig-to-baboon xenoHTx rejection

To investigate the role of anti-pig Ab in discordant xenograft rejection, these 12 baboons were divided into 2 groups: Group-S (n = 4) died within 24 hr. of HTx and Group-L (n = 8) survived more than 24 hr. [19]. Mean survival period was 9.8 ± 3.0 h in Group-S and 151 ± 33 h in Group-L. Baboon anti-pig Ab was measured before CPB, before circulatory arrest, during AbA, at the end of CPB, and daily after HTx. Anti-RBC Ab was measured by the titration method at temperatures of 4 degrees C and 37 degrees C (RAb-4 and RAb-37). Anti-endothelial cell Ab (EAb) and anti-white blood cell Ab (WAb) titers were measured with enzyme-linked immunosorbent assay (ELISA). RAb titration $\geq 1/4$ and EAb and WAb $\geq 1/256$ were determined to be seropositive. Seropositive rate of RAb-37 at the end of CPB (endCPB) in Group-L was significantly higher than that in Group-S (8/8 vs. 1/4; $P < 0.05$). The seronegative rates of RBC-4 and EAb (endCPB) in Group-L were higher than those in Group-S (7/8 vs. 1/4 and 6/8 vs. 1/4, respectively), but not significantly. There was no difference in seronegative rate of WAb (endCPB) between both groups. More than fourfold decrease in RAb-4 and RAb-37 by AbA with a pig lung was observed in 5 and 7 of 8 baboons, while EAb and WAb did not change by AbA. In all of Group-L, RAb-4 reverted to seropositive within 3 days after HTx. In four of Group-L, RAb-37 became S(+), 1 or 2 days before death by rejection. EAb became seropositive in all of Group-S, but five of them survived more than 5 days after seroconversion. It was concluded that a pig lung absorbed RAb-4 and RAb-37 may play a role in DXR.

After I came back to Japan, the role of RAb-37 on pig-to-baboon xenoHTx was investigated using sequential heterotopic HTx [21]. Fifteen pig hearts were obtained from pigs weighing 6.4–91 kg. Eleven hearts from pigs larger than the recipient were used for perfusion, and four hearts from a pig of the same size as the recipient for heterotopic transplant donor heart. Four female baboons weighing 5.9–8.1 kg received Tac (12 mg/kg) and CAM (50 mg/kg) p.o. daily 2 weeks before and after xenoHTx. After perfusion with two or three large pig hearts, a pig heart was heterotopically transplanted in the right neck of recipient baboon. As the second and third recipient baboons died of hypotension during the third pig heart perfusion and could not undergo heterotopic xenoHTx, the last baboon underwent two pig heart perfusion and subsequent heterotopic xenoHTx. All first perfused hearts and two second perfused hearts were hyperacutely rejected within 30 minutes of perfusion, but the other two second and all third

	RAb-4	RAb-37	EAb-IgM	EAb-IgG
Adult	582 ± 579	296 ± 291	288 ± 189	853 ± 264
Cord blood	144 ± 181 [*]	69/96 [*]	21 ± 8.3 ^{**}	683 ± 264
Infant <38 days old	80 ± 58 [*]	30 ± 19 [*]		
Infant >= 38 days old	689 ± 678 ^{***}	239 ± 149 ^{***}		

RAb-4 and RAb-37: human anti-pig red blood cell antibody titer at temperature of 4°C and 37°C, respectively.
EAb-IgM and EAb-IgG: human anti-pig endothelial cell antibody (immunoglobulin M and G) titers, respectively.
^{*}*p* < 0.01 vs. adult.
^{**}*p* < 0.05 vs. adult.
^{***}*p* < 0.01 vs. cord blood or infant younger than 38 days old.

Table 4.
Human anti-pig antibody against red blood cell and endothelial cell.

Treatment			Survival after releasing AXC (minutes)	Off CPB and chest closure	Extubation	Pathology of autopsied xenograft
Donor pig	DAF pig organ perfusion					
Group-C ^a						
1 ^b	F1 pig	None	21	No	No	Severe HAR
2	F1 pig	None	132	Yes	No	Severe HAR
Group-DAF ^a						
1 ^c	DAF ^b transgenic pig	None	104	Yes	No	Mild HAR
2	DAF ^b transgenic pig	None	135	Yes	Yes	Mild HAR
3	DAF ^c transgenic pig	None	126	Yes	Yes	Mild HAR
Group-DAF+P ^a						
1	DAF ^b transgenic pig	Heart	211	Yes	No	Moderate HAR
2	DAF ^b transgenic pig	Heart	310	Yes	No	Moderate HAR
3 ^d	DAF ^b transgenic pig	Lung	305	Yes	Yes	Mild HAR
Group-GnT-III ^a						
1	GnT-III transgenic pig	None	73	Yes	No	Mild to moderate HAR
2 ^c	GnT-III transgenic pig	None	257	Yes	Yes	Mild to moderate HAR
3	GnT-III transgenic pig	None	493	Yes	Yes	Mild to moderate HAR

DAF, decay-accelerating factor; GnT-III, beta-D mannoside beta-1,4-N-acetylglucosaminyltransferase III; AXC, aortic cross-clamping; CPB, cardiopulmonary bypass; HAR, hyperacute rejection; DXR, delayed xenograft rejection.

^aGroup-C, controls; Group-DAF, transplanted DAF transgenic pig heart; Group-DAF + P, transplanted DAF transgenic pig heart and perfused with another pig heart; Group-GnT-III, transplanted GnT-III transgenic pig heart.

^bHetero DAF transgenic pig.

^cHomo DAF transgenic pig.

Table 5.
Results of orthotopic cardiac xenotransplantation between rhesus monkey recipients and transgenic pig donors.

perfused hearts were not rejected within 2 hours after perfusion. The first and last transplanted pig hearts stopped beating 6 days and 18 hours after xenoHTx. Histological examination showed no rejection findings in the myocardium of the graft taken at 1 hour after xenoHTx, but the explanted grafts after cardiac arrest showed massive necrosis with ischemic change which suggested some kinds of DXR. RAb-37 prior to perfusion in all baboons was 1: 256 or 1:512, but that at 1 hour after XenoHTx was less than 1:4 which was considered to be negative. These findings suggested that RAb-37 may play an important role in DXR in pig-to-baboon combination.

We also investigated the differences between newborn and adult natural heterophile anti-pig red blood cell IgM xenoantibodies as correlates of xenograft survival [22] (**Table 4**). Newborns and younger infants have significantly lower titers of anti-pig RAb-4 and RAb-37 and anti-pig EAb-IgM than adult.

After coming back to Japan, Kawauchi M also investigated ontogeny of RAb-37 and HAR in 15 macaque monkeys [23]. Ten hearts from newborn Gottingen miniature swine (6–12 days old) were heterotopically transplanted into 10 infant macaque monkeys (52, 59, 75, 101, 108, 114, 129, 151, 181, and 192 days old) without immunosuppressive therapy. RAb-37 prior to xenoHTx were gradually increased according to the age of the monkeys. All six donor hearts in the recipients younger than 4 months survived 6 hours, and then the animals were killed while the donor hearts were beating. Donor hearts in four infant recipients ages 129, 151, 181, and 192 days were hyperacutely rejected at 19, 22, 29, and 9 minutes. The pig hearts in the recipients younger than 4 months showed no findings of HAR.

These two findings may suggest that newborn and younger infants may be more suitable recipient of discordant xenoHTx.

9. Transgenic pig-to-rhesus monkey orthotopic discordant xenoHTx

As Miyagawa et al. demonstrated the effect of the human beta-D mannoside beta-1,4-N-acetylglucosaminyltransferase III (GnT-III) gene in downregulating the xenoantigen of pig heart grafts, using a pig to cynomolgus monkey transplantation model suggests that this approach may be useful in clinical xenotransplantation in the future [24]. Moreover, they showed the possibility that both the decay-accelerating factor (DAF) and GnT-III double transgenic pig skin xenografts could be used in place of human skin allografts in the cases of severe burns [25].

Then, after coming back to Japan, the author and Japanese colleagues underwent orthotopic discordant xenoHTx using DAF and GnT-III transgenic pig heart xenografts (unpublished data). Donor hearts were obtained from two F1 pigs, six DAF transgenic pigs (five hetero DAF and one homo DAF), and three GNT-III transgenic pigs and transplanted orthotopically in adult rhesus monkey with deep hypothermia and circulatory arrest. All animals received no immunosuppressive drugs.

In two baboons, a F1 pig heart was transplanted for control (Group-C). In three baboons, the blood in the bypass circuit was perfused into a hetero DAF pig heart or lung to absorb baboon anti-pig antibody during circulatory arrest at the time of xenoHTx (Group-DAF + P).

In the one control animal, the graft stopped beating 21 minutes after aortic unclamping before weaning from cardiopulmonary bypass (CPB). All other 10 rhesus monkeys could wean from CPB and undergo chest closure, but only one in Group-DAF, one in Group-DAF + P, and two in Group-GNT-III could be removed from a ventilator. Two grafts in Group-C and two perfused pig hearts showed severe HAR. Other grafts showed various degree of HAR. These data suggested that

transgene of DAF or GNT-III might not be enough to suppress HAR in adult rhesus monkey which had high titers of anti-pig xenoantibodies.

10. Recent concerns about xenotransplantation in children

Xenotransplantation has been proposed as a method of reducing the especially acute shortage of organs for babies and children. Early clinical trials of xenotransplantation will be a form of therapeutic research. Therapeutic research must offer some prospect of genuine benefit for the patient, but it involves greater uncertainties than treatment, and therefore greater caution must be exercised. Many working parties concerning xenotransplantation, such as the British Pediatric Association and the Medical Research Council, have advised that therapeutic research should not involve children if it could equally well be performed with adults. It would be difficult to justify the involvement of children in major and risky xenotransplantation trials before some of the uncertainties have been eliminated in trials involving adults. Therefore, the FDA and WHO also recommend that the first xenotransplantation trials involve adults rather than children.

Then, although the authors tried to continue animal experiment to start clinical pediatric xenoHTx in the mid-2000s, we resigned.

11. Current status of pediatric heart transplantation in the world and Japan

After the Bailey’s first xenoHTx, hundreds of neonates and small infants with end-stage heart failure are living today because of primary or secondary HTx in the world. The number of pediatric HTx has been increasing (Figure 3), and their survival has been acceptable in every recipient age (Figure 4).

When the author came back to Japan in 1994, there was no Transplant Act in Japan. In 1988, the Japan Medical Association professed that it would accept brain death as human death. In 1990, the Provisional Commission for the Study on

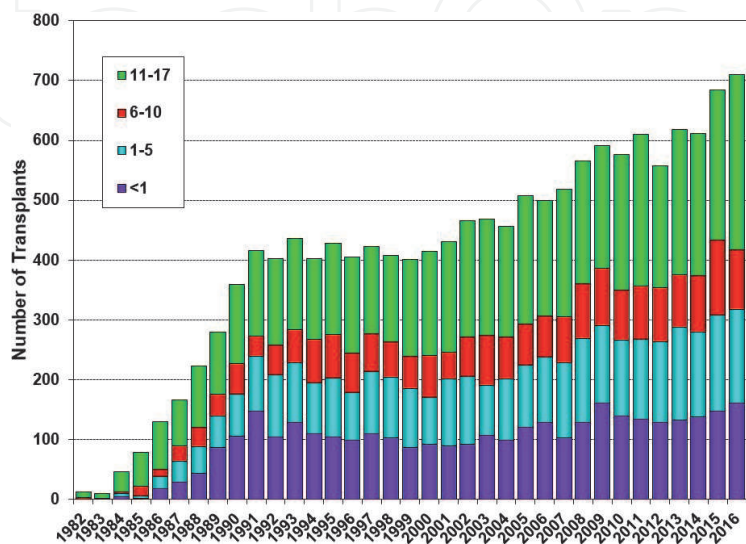


Figure 3. Pediatric heart transplants. Recipient age (in years) distribution by year of transplant.

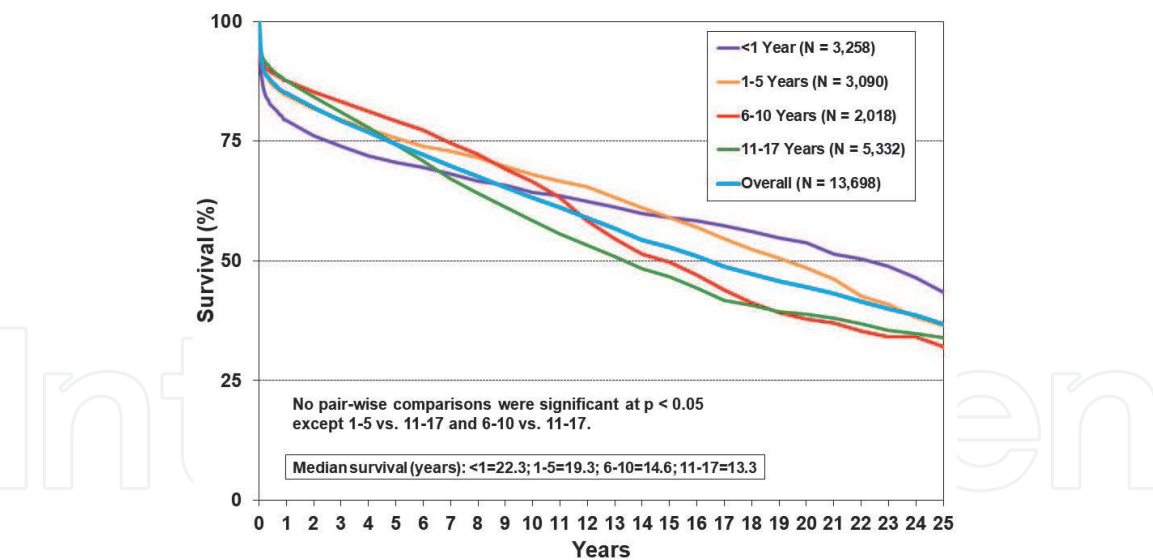


Figure 4.
Pediatric heart transplants. Kaplan–Meier survival (transplants: January 1982–June 2016).

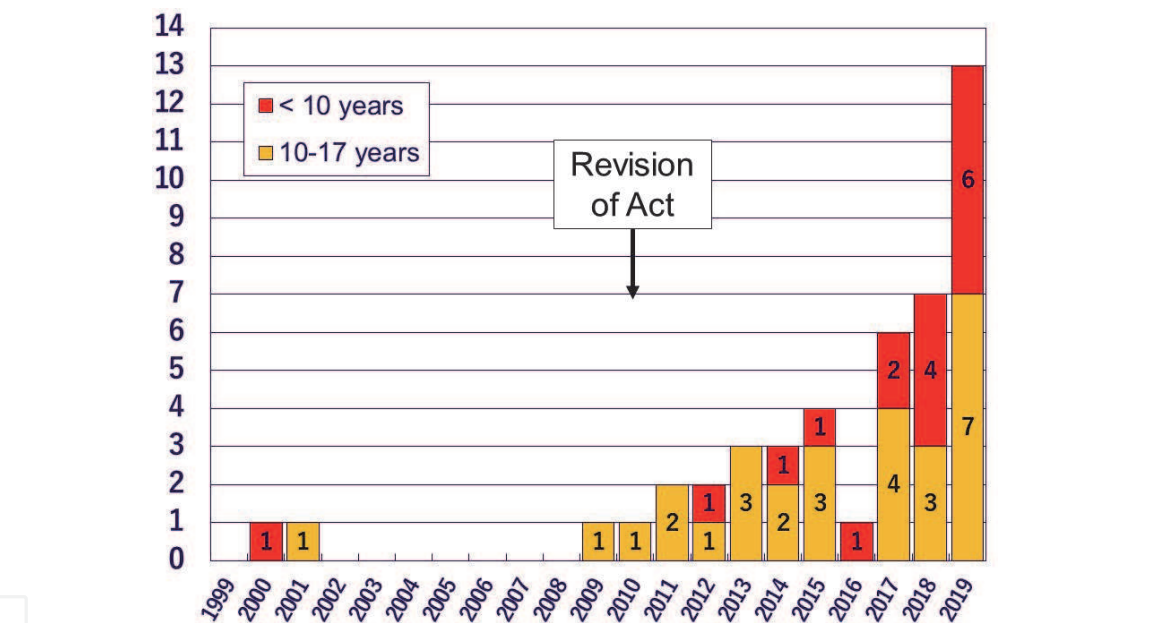


Figure 5.
Pediatric heart transplant in Japan.

Brain Death and Organ Transplantation was set up in 1990. The draft of the Organ Transplantation Law was proposed in 1994. Finally, on October 16, 1997, the Organ Transplant Act took effect, which enabled brain dead organ donation only if the person expressed in writing prior to death his/her intent to agree to donate his/her organs. In addition, the Act states that “only persons 15 years and above can express to donate.” Then, heart transplants to small children become impossible.

So, we started to send children with end-stage heart failure to Dr. Bailey as other pediatricians did (**Figure 5**) and continued to perform xenoHTx experiments. But as mentioned above, we finished experiments due to the FDA and WHO recommendation against pediatric xenotransplantation. Since 2003, the author and members of Japanese Associations of Transplant patients made many efforts to revise the Act, and finally the Act was revised in 2010. After then, the

number of pediatric HTx has increased and finally exceeded that of HTx abroad (Figures 5 and 6).

Unexpectedly, Dr. Bailey (Figure 7) died of cancer in May 2019.

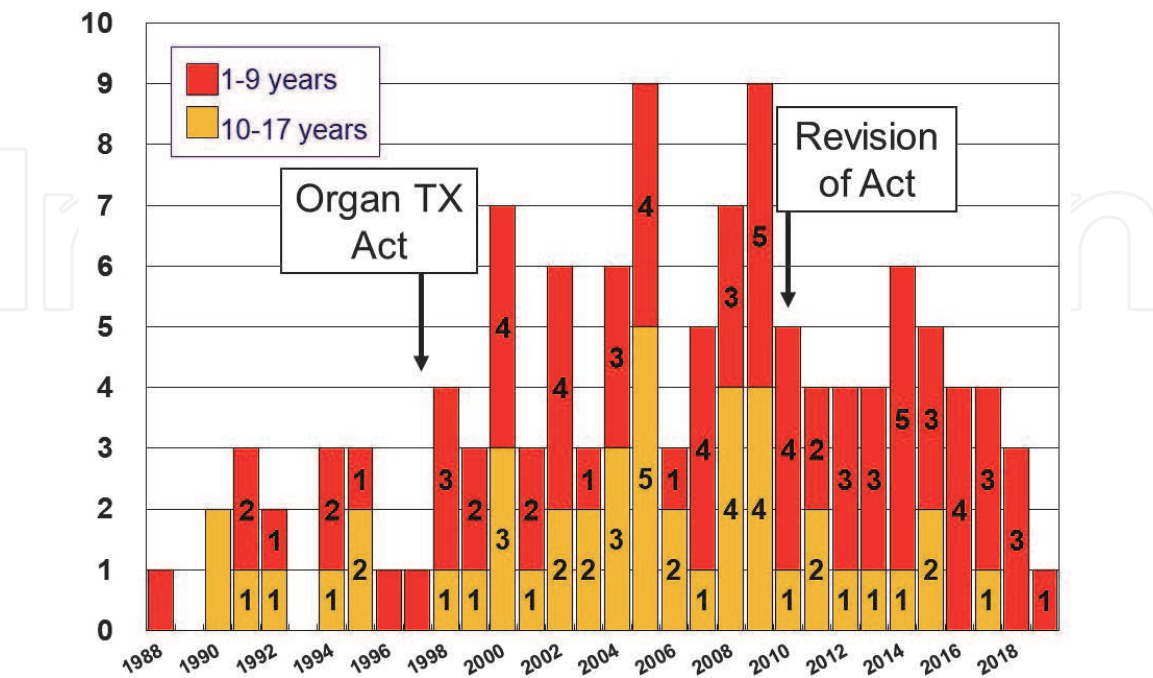


Figure 6.
Pediatric heart transplantation abroad from Japan.

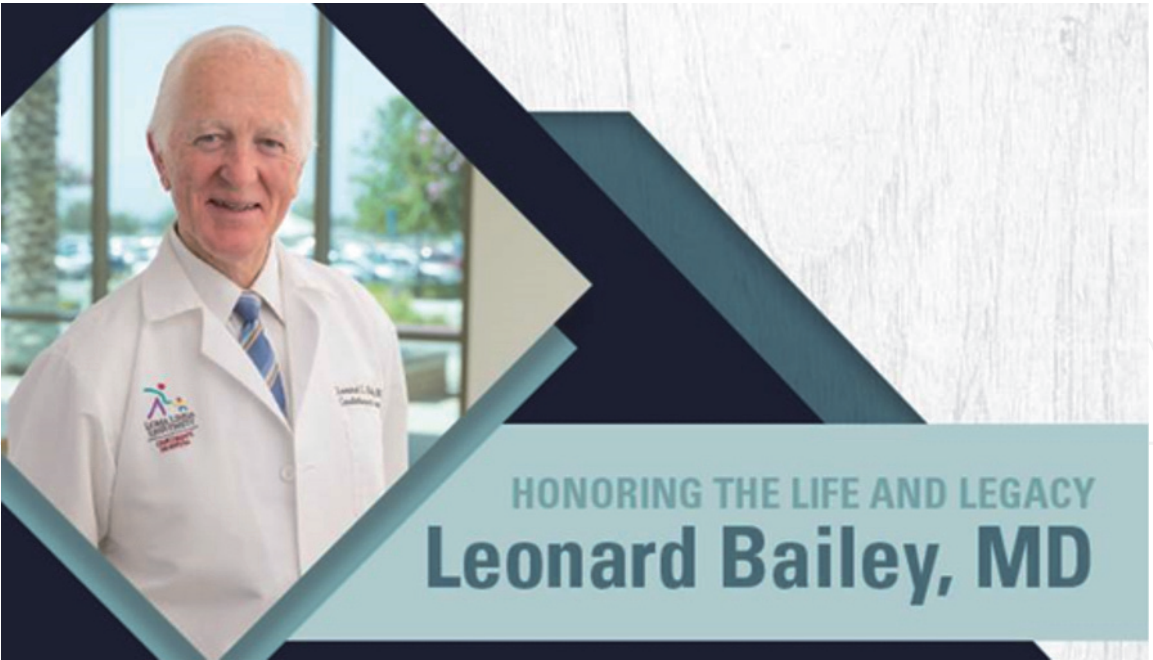


Figure 7.
The panel of Professor Leonard Bailey’s memorial service.

IntechOpen

Author details

Norihide Fukushima^{1*}, Motohiro Kawauchi², Francois Bouchart³,
Sandra Nehlsen-Cannarella⁴ and Leonard L. Bailey⁵

1 Department of Transplant Medicine, National Cerebral and Cardiovascular Center, Suita, Japan

2 Department of Cardiovascular Rehabilitation, Itabashi Rehabilitation Hospital, Tokyo, Japan


3 Department of Thoracic and Cardiovascular Surgery, Rouen University Hospital Charles Nicolle, Rouen, France

4 Immunogenetics/HLA Laboratory, Department of Pathology, Detroit Medical Center, Wayne State University Laboratories, Detroit, Michigan, United States

5 Department of Cardiovascular and Thoracic Surgery, Loma Linda University School of Medicine, Loma Linda, California, United States

*Address all correspondence to: nori@ncvc.go.jp

IntechOpen

© 2019 The Author(s). Licensee IntechOpen. This chapter is distributed under the terms of the Creative Commons Attribution License (<http://creativecommons.org/licenses/by/3.0>), which permits unrestricted use, distribution, and reproduction in any medium, provided the original work is properly cited. 

References

- [1] Lower RR, Stoffer RC, Shumway NE. Homovital transplantation of the heart. *The Journal of Thoracic and Cardiovascular Surgery*. 1961;**41**: 196-204
- [2] Barnard CN. The operation. A human cardiac transplant: An interim report of a successful operation performed at Groote Schuur hospital, Cape Town. *South African Medical Journal*. 1967;**41**: 1271-1274
- [3] Kantrowitz A, Haller JD, Joos H, et al. Transplantation of the heart in an infant and an adult. *The American Journal of Cardiology*. 1968;**22**:782-790
- [4] Bailey LL, Li Z, Lacour-Gayet F, et al. Orthotopic cardiac transplantation in the cyclosporine-treated neonate. *Transplantation Proceedings*. 1983;**15** (Suppl 1):2956-2959
- [5] Bailey LL, Jang J, Johnson W, et al. Orthotopic cardiac xenografting in the newborn goat. *The Journal of Thoracic and Cardiovascular Surgery*. 1985;**89**: 242-247
- [6] Bailey LL, Nehlsen-Cannarella S. Observations on cardiac xenotransplantation. *Transplantation Proceedings*. 1986;**18**:88-92
- [7] Youngest transplant patient dies in Britain after 28 days. *New York Times*. 1984
- [8] Bailey LL, Nehlsen-Cannarella SL, Concepcion W, Jolley WB. Baboon-to-human cardiac xenotransplantation in a neonate. *Journal of the American Medical Association*. 1985;**254**: 3321-3329
- [9] Nehlsen-Cannarella SL, Chang L. Immunology and organ transplantation in the neonate and young infant. *Critical Care Nursing Clinics of North America*. 1992;**4**:179
- [10] Alonso de Begona J, Gundry S, Kawauchi M, Bailey LL, et al. Assessment of baboon lymphocyte subsets and activity in cardiac xenobridging to allotransplantation. *Transplantation Proceedings*. 1992;**24**: 453-454
- [11] Michler RE, O'Hair DP, Xu H, Shah AS, Itescu S. Newborn baboon immunity: Lessons in cross-species transplantation. *Society of Thoracic Surgeons*. 1995;**60**:S581
- [12] Kawauchi M, Gundry SR, Alonso de Begona J, Razzouk AJ, et al. Prolonged survival of orthotopically transplanted heart xenograft in infant baboons. *The Journal of Thoracic and Cardiovascular Surgery*. 1993;**106**:779-786
- [13] Fukushima N, Fagoaga O, Kawauchi M, et al. Lymphocyte subset markers as predictors of survival after concordant cardiac xenotransplantation. *Transplantation Proceedings*. 1994;**26**: 1212-1213
- [14] Kawauchi M, Gundry SR, Alonso de Bogona J, Beierle F, Bailey LL. Plasma level of FK 506 in newborn goats and infant baboons. *Transplantation Proceedings*. 1991;**23**:2755-2756
- [15] Fukushima N, Kawauchi M, Bouchart F, Gundry SR, Zuppan CW, Ruiz CE, et al. Graft atherosclerosis in concordant cardiac transplantation. *Transplantation Proceedings*. 1994;**26**: 1059-1060
- [16] Toi te Taiao. The cultural, ethical and spiritual aspects of animal-to-human transplantation. A report on xenotransplantation. Bioethics Council. August 2005. Available at: www.bioethics.org.nz
- [17] Rose AG, Cooper DK. Venular thrombosis is the key event in the pathogenesis of antibody-mediated

cardiac rejection. *Xenotransplantation*. 2000;7:31-41

[18] Cooper DKC, Ekser B, Tector AJ. Immunobiological barriers to xenotransplantation. *International Journal of Surgery*. 2015;23(Pt B): 211-216

[19] Fukushima N, Bouchart F, Gundry SR, Nehlsen-Cannarella S, Gusewitch G, Chang L, et al. The role of anti-pig antibody in pig-to-baboon cardiac xenotransplant rejection. *Transplantation*. 1994;57: 923-928

[20] Fukushima N, Gundry SR, Matsumiya G, Bouchart F, Zuppan C, Bailey LL. Histological findings in heart grafts after orthotopic pig to baboon cardiac transplantation. *Transplantation Proceedings*. 1996;28:788-790

[21] Fukushima N, Shirakura R, Chang J, Yamaguchi T, Kobayashi Y, Yoshitatsu M, et al. Prolonged survival of pig cardiac xenografts in baboons by sequential cardiac transplantation. *Transplantation Proceedings*. 1998;30: 3815-3817

[22] Fukushima N, Fagoaga O, Bouchart F, Grinde S, Gusewitch G, Thorpe R, et al. Comparison of newborn versus adult natural heterophile anti-pig red blood cell IgM xenoantibodies as correlates of xenograft survival. *Transplantation Proceedings*. 1994;26: 1395-1396

[23] Kawauchi M, Nakajima J, Endoh M, Oka T, Takamoto S. Ontogeny of antipig xenoantibody and hyperacute rejection. *Transplantation*. 2000;70(4):686-688

[24] Miyagawa S, Murakami H, Takahagi Y, et al. Remodeling of the major pig xenoantigen by N-acetylglucosaminyltransferase III in transgenic pig. *The Journal of Biological Chemistry*. 2001;276(42): 39310-39319

[25] Fujita T, Miyagawa S, Ezoe K, et al. Skin graft of double transgenic pigs of N-acetylglucosaminyltransferase III (GnT-III) and DAF (CD55) genes survived in cynomolgus monkey for 31 days. *Transplant Immunology*. 2004; 13(4):259-264