

We are IntechOpen, the world's leading publisher of Open Access books Built by scientists, for scientists

6,900

Open access books available

185,000

International authors and editors

200M

Downloads

Our authors are among the

154

Countries delivered to

TOP 1%

most cited scientists

12.2%

Contributors from top 500 universities



WEB OF SCIENCE™

Selection of our books indexed in the Book Citation Index
in Web of Science™ Core Collection (BKCI)

Interested in publishing with us?
Contact book.department@intechopen.com

Numbers displayed above are based on latest data collected.
For more information visit www.intechopen.com



Role of Cranioplasty in Management of Chiari Malformation

Asifur Rahman

Abstract

Chiari malformations (CM) are a set of enigmatic congenital anomalies, owing to their complex pathology, varied presentations and management dilemma. Because of the daunting nature of this disease, a universal definitive treatment protocol is yet to be established. Diverse surgical procedures are in practice with various philosophies, aiming to resolve different sections of the pathologies of this disorder, either singly or in combination. However, outcomes are quite variable. Though not a well-recognized and commonly practiced paradigm of managing CM, different techniques of cranioplasty for CM has been described by many authors with variable rates of success. Cranioplasty for Chiari has been found to be helpful in different circumstances with the objective to address different predicaments. Initially, it has been exercised as one of the modalities to manage some particular situations, mostly in cases to solve complications following surgery. Now in some centers, different types of methods of cranioplasty are practiced routinely to treat particular set of Chiari patients with specifically set criteria and some have shown success in those certain scenarios. In this chapter, different methods of cranioplasty for Chiari malformation by different authors, strategies behind the techniques and their results are described in brief. “Stealth cranioplasty”, a technique devised by our team is also portrayed.

Keywords: Chiari malformation, posterior fossa volume, posterior fossa decompression, cranioplasty

1. Introduction

Hans Chiari analytically described his eponymous subset of patients of Chiari malformation (CM) first in 1891. In his subsequent article on CM in 1896, he elaborated the entity and added a new type to his previously described three types. He only described his findings and gave two theories to relate the findings to probable pathogenesis. He thought that the herniation is a result of congenital hydrocephalus, which is a chronic one with early onset that displaces the neural structures through the foramen magnum (FM) into the spinal canal [1]. But that is actually not the case always. The other possibility that he thought of was inadequate bone growth and insufficient enlargement of skull triggering raised intracranial pressure (ICP) leading to force down the hindbrain. Later, with advancements of technologies and further research, Chiari's latter hypothesis appears to be impressively a precise one [1–4]. Some other scientists around that period of Chiari, like Cleland

in 1883 and Mennicke in 1891 described about hindbrain herniation and also advocated that the pathology lies in the defective bone around the foramen magnum, which supports the theory of the pathogenesis originating from the small posterior cranial fossa (PCF) [5, 6]. Though, these earlier studies were based on observations of autopsy findings, these theories still are very much contemporary, as verified by the findings of the modern technologies of recent times. However, Chiari or other researchers of his time did not think of solving the problem.

For this puzzling condition, surgery was not contemplated till 1930, when Cornelis Joachimus Van Houweninge Graftdijk, first attempted surgery for CM on a patient with myelomeningocele and ventriculogram-proven hindbrain herniation. He tried to restore better flow of cerebrospinal fluid (CSF) around the craniovertebral junction (CVJ) by widening the space through which the redundant cerebellar tissue had herniated [7]. Since then, attempts to solve the problem of CM by surgery are being practiced and many procedures have been devised and various modifications have been made.

From the very beginning of surgical endeavors, disputes regarding management of CM are a continuing issue of debate because of its intricate and perplexing character. The pathophysiology of syringomyelia (SM) that often exist with CM, seems to be identical and gives the opportunity to solve both with a common procedure, as both CM and SM share the common pathology [8]. The commonest surgical practice for Chiari malformation type 1 (CM1), the commonest of the Chiari malformations, and SM is a simple posterior fossa decompression with the removal of part of posterior arch of C1 combined with variations in the next steps. Reconstruction of the posterior fossa (PF) by cranioplasty is not a routine procedure following posterior fossa decompression (PFD) for the CM1. Many authors described posterior fossa reconstruction with cranioplasty following PFD in many ways with different philosophies. In this chapter, we will discuss the different procedures of cranioplasties performed in surgery for CM1 along with the concepts behind those with elaboration of our thoughts while we do cranioplasty in our technique.

2. Common surgical approaches for Chiari malformation

Development of CM results from developmental anomaly of the occipital bone, rendering the posterior fossa small and shallow, which, along with other factors, leads to herniation of the normal neural elements through the foramen magnum. To reach a unanimous management protocol for CM is challenging owing to the nature of the disorder, its diverse clinical presentations and inexplicable image findings. Depending on presentation in milder forms of symptoms, some authors have advocated conservative management. Nonetheless, surgical intervention remains the gold standard for most of the symptomatic CMs, both in reduction of tonsillar herniation and reestablishment of CSF dynamics around the CVJ; and ultimately in overall outcome. Surgical procedures are many for CM, but no definite single procedure is accepted universally. Keeping the basic techniques identical, many forms and variations are adopted in the procedures and are practiced in different combinations. For many years after Van Houweninge Graftdijk first attempted to treat CM surgically, surgery carried a grave prognosis. At present, with better understanding of the pathology and advances in technology, most patients with CM1 can be benefited by surgical procedures.

The common practice in all surgical approaches is a suboccipital craniectomy with removal of posterior arch of C1. However, there are disagreements and wide range of variations regarding the extent of bone removal and different additional measures taken along with. For management of CM1, dura can be addressed in different ways like leaving the dura intact with removal of the constricting bands only [9], scoring of

the dura [10, 11], resection of the outer layer of the dura [12–14], opening the dura and keeping it remain open [15–17], and performing duraplasty with different materials, both natural and artificial [13, 18–24]. The arachnoid manipulation equally differs from leaving it intact by doing an arachnoid preserving durotomy or arachnoid preserving duraplasty [9, 25–27], to opening and resecting it to remove adhesions [8, 19, 23, 28–30]. Dealing the cerebellar tonsils also vary like not touching them [27, 31], separating them by dissection [28, 32], shrinking by bipolar coagulation [13, 19, 23, 33, 34] or carrying out a subpial resection [8, 19, 35, 36]. Recently, minimal invasive endoscopy assisted decompression at the foramen magnum for CM have also been reported [37, 38].

3. An overview of cranioplasties for Chiari malformation

Cranioplasty is not an uncommon procedure in neurosurgery for different conditions. In CM1 surgery, cranioplasty is not a generally prescribed regular technique and thus is not practiced frequently. Most of the times, this is done to manage complications related to routine surgeries for CM1 and sometimes for other types of CM. Whatever the reason is, those who do cranioplasty during CM1 surgery have their own philosophies and the techniques have evolved around the basic pathology of development of CM1 or the complications following regular surgery. Various operative methods for CM and SM have been reported and their efficacy either singly or in combinations in management of CM is still debatable. Most of the authors who practice cranioplasty for the treatment of CM have the theory in their minds that the basic pathology lays in the erroneous architecture of the posterior fossa. Most believe that the posterior fossa is less roomy than the volume of normal neural structures which attributes to herniation of the tonsils through the foramen magnum as well as resulting in disequilibrium of the CSF flow and dynamics between the cranial and the spinal CSF compartments. In some instances, cranioplasty is done routinely in selected cases of CM1. A chronology of cranioplasty procedures for CM with philosophies behind those are portrayed here.

3.1 “Expansive suboccipital cranioplasty” by Tokuno et al.

The very first portrayal of cranioplasty designed for surgery of Chiari malformation found in English literature is by Tokuno et al. in 1987, when they described their technique for treating patients of CM with SM [39]. Till then, the commonest and most popular operative technique of surgery for Chiari was based on the theories of Gardner and William. Tokuno et al. operated on 38 patients over 10 years between 1976 and 1986. A total of 31 out of 38 patients of their series had syringomyelia. In the last 2 years of their study, they carried out an “expansive suboccipital cranioplasty” on their last 17 patients, in addition to Gardner’s operation. With the goal of expanding the posterior fossa, they did cranioplasty with autologous suboccipital bone and an iliac bone graft, creating a larger suboccipital bone flap measuring about $5 \times 3 \times 0.5$ cm in size. They followed up all the 38 patients for 1–10 years post-operatively. The addition of “expansive suboccipital cranioplasty” to Gardner’s operation resulted in substantially better result in comparison to Gardner’s operation alone, with 82% and 67% of good recovery, respectively. Following expansive suboccipital cranioplasty, symptoms of the patients also seemed to improve more rapidly, though a very few patients had transient worsening. By their new operative method, they wanted to obtain a full decompression of the posterior fossa to maintain normal CSF flow around the foramen magnum.

As there was no regular use of MRI for screening or diagnosing CM or SM at that time, they could not measure the volume of the posterior fossa in all of their patients.

However, based on radiological and intra-operative observations of 32% of their patients having narrow posterior fossa, they came to a conclusion that there is disproportion between the suboccipital cavity and the infratentorial content. They also had the premonition that, even if the suboccipital space seems to be normal, the infratentorial component might be relatively too large for that. They devised their procedure with the intention to remodel the neural structures back to a normal physiology by enlarging the posterior fossa through “expansive suboccipital cranioplasty”.

3.2 “Expansive suboccipital cranioplasty” by Sakamoto et al.

In 1999, after 12 years of the first report of cranioplasty for Chiari by Tokuno et al., Sakamoto et al. from the same university hospital of Osaka City reported a procedure of cranioplasty for surgery of CM1 associated with SM with some modifications of the procedure of their predecessors. They also termed their technique “expansive suboccipital cranioplasty” (ESC) [40]. Relatively high incidence of postoperative complications and deterioration following the most practiced Gardner’s operation, instigated them to devise their technique. During the period between 1985 and 1996, they divided their patients into 2 groups with 20 patients in each group. One group consisted of the patients who underwent ESC together with opening of the foramen of Magendie and plugging of the obex (ESC + PO) from 1985 to 1990 and the other consisted of another 20 patients who underwent ESC but without any intra-arachnoidal procedures between 1991 and 1996.

Their technique of ESC comprised of a large suboccipital osteoplastic craniotomy extending from the FM inferiorly to the margin of the transverse sinus superiorly and 5 cm from the midline laterally on each side along with an osteoplastic laminotomy of the atlas. The FM was enlarged and arachnoid preserving dural opening was carried out ensuring absence of any arachnoid adhesion at the major cistern by intra-operative ultrasound. Duraplasty was done with pericranium. For enlargement of the posterior fossa, the harvested occipital bone flap was fashioned to be expanded by joining the preserved part of the atlas and graft harvested from the outer layer of the cranium at the external protuberance or from the iliac bone. The newly crafted bone flap was then restored and fixed over the craniotomy gap to cover the major cistern. Dural tacking with the bone flap was done to widen the CSF space around the major cistern.

Post-operative MRI revealed enlargement of the major cistern and the whole subarachnoid space of the posterior fossa and reduction of the syrinx size and length in all 40 patients irrespective of clinical improvement. All the 20 patients who underwent ESC, had neurological improvement after surgery without recurrence, while 17 patients improved neurologically and 3 remained unchanged in the ESC + PO group. Based on the theory of a small posterior fossa that may trigger CM and SM, they developed the ESC, targeting to enlarge the small posterior fossa and to obtain a sufficient flow of CSF. They postulated that intra-arachnoid procedures are not necessary to facilitate restoration of CSF flow as by expanding the posterior cranial fossa, the CSF spaces are enlarged and the craniospinal pressure dissociation is also reduced. They also had the impression that the major cistern can be effectively kept open by tacking the dura to the overlying bone flap. They furthermore postulated that ESC can prevent cerebellar slump despite a large craniotomy by avoiding adhesion of the caudal surface of the cerebellum to the dura.

3.3 “Partial suboccipital cranioplasty” by Holly and Batzdorf

Cerebellar ptosis (CP) is not an uncommon occurrence that usually results from too large a craniectomy for CM, which often can potentially refute the desired

outcome of the surgery. In 2001, Holly and Batzdorf reported partial suboccipital cranioplasty with or without intradural exploration for cerebellar ptosis following suboccipital craniectomy for CM [41].

Aiming to treat CP following PFD for CM1 effectively, they developed their technique and implemented that on four of the seven symptomatic CP patients. These patients presented with symptoms from 9 months to 17 years following initial surgery. Of the four patients, two patients underwent re-exploration with reduction of the tonsils, pericranial duraplasty and partial suboccipital cranioplasty with hydroxyapatite (HA) in one and with methylmethacrylate (MMA) in the other. Rest of the two patients underwent extradural exploration of the suboccipital craniectomy and partial suboccipital cranioplasty with MMA. All the four patients, who had partial suboccipital cranioplasty with or without intradural exploration produced rewarding results. With their crescent-shaped partial suboccipital cranioplasty the previous 4×4 cm suboccipital craniectomies were transformed into approximately 2×2 cm ones. To secure the prosthesis, they grooved the contiguous bone edges with high speed drill and injected MMA into the grooves.

Most of these patients of cerebellar sag present with headache and neurological deficits due to persistent obstruction of CSF flow around the CVJ leading to disturbance in CSF flow dynamics. Usually, too large a craniectomy leads to CP, and from that they philosophized that decompression of the posterior fossa extensively is unnecessary to treat a pathology that is primarily around the level of the foramen magnum. They felt that the initial craniectomies were nearly twice as large as necessary and lessened the opening to approximately 2×2 cm in all. They basically had the aim to make the posterior fossa as roomy as possible to reestablish the CSF flow dynamics around the FM back to normal without hampering the support for the cerebellum and suggested that enough bone should be left to support the greatest diameter of the cerebellum as a bony supportive shelf. The use of MMA or HA for the cranioplasty was chosen as prosthesis as because these materials can be fixed in place without any additional hardware. Partial suboccipital cranioplasty was successful in treating the headache by supporting the cerebellum and alleviating stretching the dura mater with reversal of the CSF flow obstruction.

3.4 “Supratentorial cranial enlargement” by Di Rocco and Velardi

Chiari malformation is generally a congenital anomaly, but CM can be an acquired event as well. Some literatures in recent time have highlighted the role of the cranio-spinal pressure differential across the foramen magnum in pathogenesis of Acquired Chiari type-1 malformation (ACM1). In 2003, Di Rocco and Velardi drew attention to a different dimension in development of acquired ACM1 in patients that had surgery for raised ICP resulting from causes other than congenital HCP and they treated these patients in their technique [42]. They described two cases of symptomatic ACM1 following lumbo-peritoneal shunt and cystoventriculo-peritoneal shunt for pseudotumor cerebri and suprasellar arachnoid cyst, respectively, in two adolescents. They hypothesized that secondary cranioccephalic disproportion plays a substantial role in the genesis of ACM1 in patients having extrathecal CSF shunts.

Both of their patients remained asymptomatic following the initial shunting procedures. However, both became symptomatic after a long interval and MRI revealed ACM1 in both the patients. Di Rocco and Velardi did surgery upon them in their devised technique successfully.

They devised a method of supratentorial cranial decompression by expansive cranioplasty with autologous bone. In their procedure, two parietal bone flaps were made on each side of the sagittal suture. The bone flaps were then raised to augment

the supratentorial cranial volume. For sustained elevated position of the bone flaps in order to maintain the enlarged cranial dimension, two small blocks of bone harvested from the posterior parietal margin of the bone flaps were placed between the bone flap and the margin of the craniotomy adjacent to the medial border. Cosmetic aspect of the expanding craniotomy to maintain precise contour of the calvarial surface was meticulously taken care of.

There were marked improvements of the symptoms of both the patients. Headache and papilledema in the first patient and diplopia, papilledema, retinal hemorrhage, headache, mild right hemiparesis and mild dysmetria of the left upper limb in the second patient—all subsided. Post-operative MRI showed significant regression of tonsillar caudal descent in both the patients.

Pathogenesis of ACM1 is most likely multifactorial and its development following extrathecal shunts can be explained by the “craniospinal pressure gradient” theory and the “cephalocranial disproportion” theory. They theorized from their observations that placement of the extrathecal shunt in children leads to cessation of cranial growth as well as results in progressive thickening of the cranial vault by inner apposition of bone, which spans for years. Further observation of upward displacement of the upper cerebellar vermis to lodge upward into the quadrigeminal cistern along with the caudal herniation of the cerebellar tonsils, firmly establishes the fact of overcrowding of the neural structures within the posterior cranial fossa. When cephalocranial disproportion is the main factor responsible for ACM1 in these cases, it was logical for them to go for the cranial expansion as a whole to create more supratentorial intracranial space by autologous bone cranioplasty to dismiss the cephalocranial disproportion, which yielded satisfactory result. This alleviated the need for manipulation of the shunts as well.

3.5 “One-stage posterior decompression and fusion” by Nishikwawa et al.

In 2004, Nishikwawa et al. came with their method of one stage expansive cranioplasty with autologous bone and rigid occipitocervical fixation for CM1 associated with various degrees of other anomalies in two patients [43]. Their patients presented with various symptoms like occipitalgia, chest pain and numbness from face to both hands. Radiologically, there were occipitalization of the atlas, mild form of AAD, ventral compression of the cervicomedullary junction by the basilar invagination, Chiari malformation and syringomyelia. Additionally, the second patient had possible slump of the cerebellum following foramen magnum decompression with small craniectomy and splitting the dura elsewhere 12 years previously.

A large suboccipital osteoplastic craniotomy in the first case and extension of the previous suboccipital craniectomy in the second case was performed. Ultrasonographic confirmation of pulsation of the tonsils was done to ensure adequate decompression. Safety of the screw insertion was verified from preoperative and peroperative simulation by computerized navigation system for two cervical transarticular screws through the lateral mass of the axis into the lateral mass of the occipitalized atlas in patient 1 and into the pedicle of the axis in patient 2. Guide holes along the diploic space on the margin of the craniotomy in the 1st patient and oblique burr hole at the margin of the craniotomy on each side in the 2nd patient were made. Rigid occipitoaxial fixation was accomplished by connecting the diploic screws to the pedicle or transarticular screws with a rod on each side. The autologous bone flap was secured with titanium wires. Finally, dural tacking sutures connecting the dura to the overlying bone were done.

Both the patients had remarkable recovery of their symptoms with notable expansion of the posterior fossa with an enlarged CSF space in MRI and good fusion

of the grafted bones in 3D CT scan. They innovated the technique of simultaneous occipitocervical fusion in addition to their regularly practiced method of posterior fossa decompression and expansive cranioplasty for implantation of screw in the occipital diploic space for stabilization and fusion of occipitocervical instability in Chiari patients with syrinx, basilar invagination and AAD. They opined that diploic screws can be used safely for occipital fixation irrespective of the size of the suboccipital craniectomy and in cases of mobile and partially or completely reducible atlantoaxial dislocation. However, a synchronized stabilization in the optimally reduced position is mandatory for successful fusion.

3.6 “Simple technique for expansive suboccipital cranioplasty” by Takayasu et al.

Takayasu et al. made posterior fossa reconstruction simpler and easier by autologous cranioplasty for CM with SM and described this procedure on 14 patients in 2001 and on 16 patients in 2004 [44, 45]. The basic idea of this method was also to expand the volume of the PCF, thus they too call it expansive suboccipital cranioplasty like their preceding Japanese colleagues. They performed their procedures on patients of syringomyelia associated with Chiari I malformation since 1992. Different symptoms and signs in their patients included sensory disturbances, motor weakness, brainstem and/or cerebellar signs and intractable pain.

In their simpler procedure, they first did an en bloc upper suboccipital craniotomy, keeping the foramen magnum margin intact. Under the microscope with the help of air drill, Kerrison punches and rongeurs, the posterior bony margin of the FM is removed. The C1 posterior arch is removed to the maximum along with the upper part of the C2 lamina if the tonsils extended beyond C2. Arachnoid preserving duraplasty with fascia lata was done. The thick internal crista of the occipital bone flap is removed and the flap is shaped to fit the lower portion of the craniectomy gap to cover the FM. Expansive cranioplasty is accomplished by fixing the tailored bone flap with titanium miniplates. In some cases, the flap was replaced inside-out to buy more space and to have a better fit. Tacking of the dural graft with the bone graft and packing of bone chips into the upper craniectomy defect, reinforced with fibrin glue, was done to complete the cranioplasty.

All the patients improved clinically significantly within a few weeks of surgery, except 2. Both had persistent dysesthetic pain, one of whom improved within several months. In follow-up of more than 1 year most of the patients showed marked improvement in terms of ascent of tonsils and resolution of size of syringes.

They did the cranioplasty with the intension to prevent complications like pseudomeningocele and CSF leakage by providing support for the dural closure. Furthermore, posterior fossa reconstruction has the potential to prevent relapse of symptoms from restenosis of the cisterna magna, cerebellar ptosis and wound depression. Their method is simpler than the others as this only needs repositioning of the bone flap on the bony defect.

3.7 “Cranioplasty using hydroxyapatite implants” by Itoh et al.

Itoh et al. described a procedure of cranioplasty with a curved plate of Hydroxyapatite for Treatment of Syringomyelia associated with Chiari I Malformation, in 2001 [46]. They applied their method on eight patients diagnosed on basis of clinical examinations and neuroradiological findings of MRI and 3D-CT over a period of 19 months. All patients had varying degrees of sensory discomfort of the extremities with the mean duration of symptoms for 40 months. The most frequent complaint was unilateral dysesthesia in the upper extremity. MRI revealed

tonsillar herniation and syrinx of various degrees and extents. Phase-contrast cine-MRI displayed absence of CSF flow in the retrotonsillar subarachnoid space and to-and-fro drift within the syrinx.

In their technique, they first did foramen magnum decompression by a suboccipital craniectomy as in other procedures along with C1 laminectomy in seven cases and did C1 and C2 upper dome laminectomies in one case. In three cases, they did duraplasty with Gore-Tex membrane and resected the outer layer of the dura in five cases. Cranioplasty to cover the craniectomy gap as well as to expand the posterior fossa was performed using HA implants in all cases. They did tenting of the dura or the duraplasty with the implants in all cases.

In a mean follow-up period of 13.3-months, five patients improved and three patients remained unchanged. Postoperative syrinx resolution was seen in seven patients on MRI. HA cranioplasty had to be removed in one patient because of development of an epidural abscess, but this patient had no further neurological deterioration. Six months after surgery, 3D-CT revealed the HA implant to be integrated with the adjacent occipital bone. They used HA, as a substitute for autologous bone grafts, for expansive cranioplasty to enlarge small posterior fossa to establish better CSF flow at the major cistern. The use of HA was to reduce the chance of absorption of the autologous bone in the long run if used for cranioplasty. Moreover, it is technically easy to use the HA implants. The idea of tenting the dura with the cranioplasty was to inhibit the retention of CSF at epidural space following surgery.

3.8 “Simple and safe method of cranial reconstruction” by Sheikh et al.

In 2006, Sheikh et al. described a simple method of cranioplasty that they applied for posterior fossa reconstruction for many procedures including Chiari malformation [47]. They depicted their easy modified procedure of cranioplasty utilizing patient's own bone dust, tissue glue and gel foam sheets. Ten patients underwent posterior fossa reconstruction between the period of 2000 and 2004 for different pathologies including CM.

After exposure of the suboccipital bone, craniectomy is done by doing multiple burr holes and connecting them with a high-speed drill. Produced bone dust is meticulously collected, preserved and kept wet in a container with small amount of antibiotic treated saline. Following craniectomy and water tight dural closure, a layer of tissue glue is applied over the dura. Two sheets of gel foam are fashioned to fit the craniectomy defect. The bone dust is dried to make dough and is spread between the 2 layers of the gel foam sheets and is held together with tissue glue. The bone dust sandwich is placed over the craniectomy defect separated from the overlying muscle layer by another sheet of gel foam to complete the cranioplasty.

Post-operative plain and 3D CT scan in follow-up of 11–36 months showed excellent reconstruction of the posterior fossa bony contour with the cranioplasty. Two patients needed redo surgery after 6 weeks of cranioplasty which revealed interesting findings. In both the patients, the cranioplasty was totally separated from the suboccipital musculature and the dura. No other complication was noted.

They devised this quick and safe reconstruction technique to prevent the persistent post craniectomy headache due to dural stretching from musculo-fibrous adhesion with the dura as well as to give a better cosmetic result by preventing depression at the craniectomy site. Their procedure of making a bone dust sandwich was better than putting the bone dust directly on the craniectomy gap as the dust is not dispersed. The gel foam used for the cranioplasty also hold some blood which help in ingrowth of osteoblasts to form new bone. This simple and easy procedure had a satisfactory and effective result both clinically and radiologically.

3.9 “Posterior cranial fossa box expansion” by Heller et al.

Heller et al. portrayed a new method of “posterior cranial fossa box expansion” for MRI confirmed symptomatic cerebellar ptosis following cranial vault decompression for Chiari I malformations in 2007 [48]. They operated on seven patients, who had undergone posterior fossa decompression for CM and developed symptomatic cerebellar ptosis for 12 ± 1 months from the initial surgery at other institutions. Their patients presented with headache, upper extremity numbness, paresthesia, respiratory disturbance and walking difficulty from cerebellar ptosis.

Through the previous incision, the previous suboccipital craniectomy was delineated. In the next steps of the procedure, a split thickness square calvarial bone graft, approximately 2–3 cm larger than the width of foramen magnum is harvested from the occipital bone, just below the lambdoid suture. With the help of reciprocating saw and bone cutter, the bone graft is fashioned for the box reconstruction by trisecting the approximately 1 cm wide upper and lower margins into equal 3 segments which leaves six split-thickness pieces and one large rectangular graft. The smaller grafts are stacked into three stacks of two grafts each and fixed with screw at the upper and the two lateral margins of the foramen magnum in an inverted “U” manner. The rectangular bone graft is placed and fixed with the three legs of the bone graft stacks to create a concave dome of bone over the foramen magnum. The box cranioplasty is then completed to cover the cerebellum, separating the surrounding soft tissues and reducing the foramen magnum defect significantly.

All their patients were symptom free in a follow-up period of more than 12 months and resolution of cerebellar ptosis in all seven patients and collapse of syrinx in five of the seven patients were confirmed by MRI.

They felt that the cerebellar ptosis is a combination of lack of mechanical support from PFD and pressure-dissociation of CSF causing a sucking effect. As they acknowledged the need of cerebellar support, with their procedure they reduced previous craniectomy gap around the foramen magnum to 2×3 cm from over 4×4 cm. As a whole their box reconstruction cranioplasty resulted in expansion of the posterior cranial fossa with support to prevent cerebellar ptosis and preservation of pressure dissociation equilibrium around the cisterna magna with the added benefit of maintenance of separation between the neck musculature and soft tissues from the neural tissue. They infer that posterior fossa box reconstruction can resolve symptomatology of cerebellar sag without any intradural manipulation.

3.10 “Partial suboccipital cranioplasty” by Di et al.

Di et al. described cranioplasty related to surgery for CM in 2008 [49]. They reported about critical complication of respiratory arrest in 2 patients following partial cranioplasty for cerebellar ptosis subsequent to PFD for CM. One patient developed symptoms like recurrent and intractable headache and gait disturbance for 1 year following surgery for CM 2 years previously, while the other had developed mild headache, dizziness, difficulty in swallowing, gait imbalance, progressive numbness in the face and upper extremities and occasional urinary incontinence for 4 years following PFD 7 years back. Both the patients had severe cerebellar ptosis on MRI.

Both the patients underwent a partial suboccipital cranioplasty. Per-operatively large suboccipital craniectomy gaps were identified in both where the cerebellar hemispheres protruded out of the previous craniectomy gap. Only duraplasty was done in one while tonsillar cautery and duraplasty was done in the other. Partial suboccipital cranioplasty with titanium mesh and MMA in one and only with MMA in other was accomplished to reduce the previous craniectomy gap to approximately 2×2 cm in size.

Both the patients suffered from similar episodes of apnea and subsequent respiratory arrest, 15 h and 72 h post-operatively, respectively. No bleeding, infarct and blockage of the CSF pathway was seen in the post-operative MRI or CT scan. Chest radiographs were also normal. Both were reintubated and monitored in an intensive care unit. One of them was extubated within 24 h and was discharged home 1 week after, while, extubation failed twice in the other and recovery to a near independent state was achieved after a prolonged mechanical ventilation, with tracheostomy.

Among various post-operative complications, cerebellar ptosis, which usually results from a large craniectomy, has a potentially severe consequence, and its incidence is possibly underestimated. Partial suboccipital cranioplasty has been used to treat the cerebellar ptosis to minimize the large craniectomy gap and to support the cerebellum. The respiratory arrest in these patients is thought to be from stretching on the vulnerable and damaged brainstem by the elevation of the cerebellum during the cerebellar shelving process. There might have been some compromised vasculature too, which surely could play a role.

3.11 “Autologous cranioplasty” by Chou et al.

In 2009, Chou et al. published a technical note on a cranioplasty technique that they devised for treatment for CM [50]. They believed that adherence between muscle and dura, together with the development of occipital neuromas, are the factors of common postoperative complaint of headache. They made some modifications to the conventional craniectomy with the aim to expansion of the posterior fossa. They performed suboccipital craniotomy in their technique on six patients with CM1.

They performed a rectangular craniotomy extending from just below the nuchal line down to the foramen magnum. Following duraplasty, with the help of a Leibinger plate attached to the inner table, the craniotomy flap was fixed to the outer table of the skull with 2 mm screws to elevate the bone flap and to expand the posterior fossa volume as well.

They followed-up the patients for 7 months on average. Post-operative headaches in all the patients improved within 3–4 weeks and there had been no complication. Patients with syringomyelia had complete resolution of syringes. Improvement was seen in overall quality of life of the patients. Three-dimensional analysis of posterior fossa volume revealed effective increase in posterior fossa volume on average, from pre-operative 168 cc to post-operative 192 cc.

Small and shallow posterior fossa is recognized to be the prime factor in development of CM. The authors felt the need of the posterior fossa to be expanded. Consequently, they devised their technique of decompression and expansion of the posterior fossa. With their procedure they also eliminated the possibility of fibrous adhesion between nuchal musculature and the exposed dura to reduce the chance of post-operative headache and neckache during motion from dural stretching. Cranioplasty with autologous bone has the added advantage of reducing local tissue reaction and edema by artificial grafts.

3.12 “Cranioplasty” by Furtado et al.

Furtado et al. reported the management of rare entity of Chiari 3 malformation (CM3) by cranioplasty among other measures in 2009 [51]. Their patient, a 15 months old girl was presented with titubation and occipito-cervical encephalocele since birth. She also had downbeat nystigmus. MRI revealed an occipito-cervical encephalocele containing cerebellum, brainstem and both the occipital poles,

in a shallow posterior fossa. 3D CT scan showed a big gap in the occipital bone with mal-development of the C1 and C2 posterior arches.

On surgery, after excising the gliotic cerebellum and the occipital lobes, a meticulous watertight dural closure was accomplished. The large bony gap in the occipital bone was covered with a 5 × 5 cm methylmethacrylate cranioplasty that was fixed with the margin of the occipital bone with steel wire. The remaining occipital lobe, transverse sinus and the upper part of the cerebellum were well contained within the cranioplasty. Wound was covered with an occipital rotation skin flap.

Recovery was uneventful and the baby was discharged home after 5 days. Her lower cranial nerves were intact and there was no HCP. Follow-up CT scan at 3 year showed no bone growth along the cranioplasty margin and she had retarded physical and mental development.

They introduced a variant of cranioplasty procedure to cover and support the transverse sinus and the occipital lobe in a case of CM3. They did cranioplasty with the goal to prevent further herniation of the remaining cerebellar tissue by reducing the gap down to half. Though the functional outcome of CM3 is grave most of the times, surgery is recommended.

3.13 “Expansile suboccipital cranioplasty” by Oro et al.

Oro et al. in 2011 reported the largest series of expansile cranioplasty for CM1 [52]. They described their technique that they applied on 241 patients of fresh Chiari malformation or on recurrent CM patients.

In 2004, they developed a preformed crescent shaped titanium plate to treat CM1 patients by expansile suboccipital cranioplasty. Their titanium plate was designed to cover a craniectomy defect measuring 3 cm wide. Larger crescent plates that can cover 4 cm craniectomies also exist and plates to cover wider decompressions for post-surgical patients can also be customized. Besides, they developed a triangular plate for smaller triangular-shaped craniectomies. After the desired craniectomy, once the suitable plate is selected, it is manually bent into a curved arch and fixed to cover the upper two-thirds to three-fourths of the craniectomy with five to six small screws. No plate dislodgements have been detected in follow-up MRI. The use of the plate is straightforward and they are redesigning the plate to provide more coverage.

The goals of surgery are to achieve dorsal and dorsolateral decompression with restoration of normal CSF dynamics at the CVJ and reduction of the surgical risks.

The expected extent of craniectomy, which varies from 2.7 to 3 cm and the size of the duraplasty, approximately 1.5–2 cm less than the base length, are planned from the T2 sagittal MRI of the CVJ. Planning for inclusion of a C1 laminectomy, and on rare occasions a partial C2 laminectomy, depends on the extent of tonsillar herniation, and the degree of tonsillar and brainstem compression.

They designed their cranioplasty with the goal to provide a rigid surface for attachment of the suboccipital muscles to prevent formation of scar to dura. This process can also prevent “soft spot” headache and reduce the possibility of injury to the area.

3.14 “Cranioplasty with titanium plate” by Rekate and Bristol

In 2012, Rekate and Bristol described their method of cranioplasty following foramen magnum decompression for CM1 [53]. They only described their procedure, but did not provide any patient data. They applied their technique both in adults and in children.

In their method, the rim of the foramen magnum is removed to a distance of 1.5–2.0 cm. The posterior arch of C1 and the laminae and spinous process of C2, when felt necessary, are removed along with the ligamentum flavum. Dura is opened in a linear fashion starting from the spinal dura and then extending upwards upto the bone margin. The fourth ventricle is entered into, to see and lyse the veil, which the authors claim to be typically present and advocates that the veil must be opened to visualize the porcelain white floor of the fourth ventricle. Duraplasty is performed with pericranium, which is sewn in place with absorbable or nonabsorbable suture. Cranioplasty is done with a titanium plate that has been developed only to extend over the craniectomy gap around the foramen magnum and fixed with screws on both sides. The preformed plate allows for custom fitting depending on the patient's anatomy and the extent of the bony opening. A tenting is taken from the center of the graft to the titanium plate.

They set their goals of surgery to remove the compression from the brainstem and reestablish normal CSF dynamics at the CVJ. The dura was opened and the arachnoid around the tonsils was dissected to see the floor of the fourth ventricle with the theory in mind that this maneuver does not add morbidity to the procedure. The aim of dural closure with a patch graft is to create a larger CSF space around the CVJ. The cranioplasty is done mainly to prevent the scarring of the graft to the underlying tonsils.

3.15 “Expansile suboccipital cranioplasty with titanium mesh-assisted dural tenting” by Assina

Assina et al. in 2014 described their process of titanium mesh-assisted dural tenting and expansile suboccipital cranioplasty for preventing cerebellar ptosis following posterior fossa decompression for CM1 [54]. Cerebellar ptosis and dural prolapse or collapse of the cisterna magna are well-recognized complications following PFD. Almost one-third of the operated patients come back with recurrence in their lifetime, often from ptosis and dural prolapse.

They developed their method to prevent cerebellar ptosis and dural prolapse by the technique of titanium mesh-assisted dural tenting and expansile suboccipital cranioplasty. They performed surgery by this procedure on four patients of CM1, three of whom had associated syrinx. All presented with suboccipital headache.

Their craniectomy was extended to the posterior aspect of the occipital condyles laterally. A partial laminectomy of the C2 was done sometimes when the tonsils were extended down to C2. Arachnoid preserving dural opening was performed in a “Y”-shaped fashion superiorly and upside down “T” fashion inferiorly to have a larger dural opening. After watertight duraplasty, a titanium mesh cranioplasty, covering the superior aspect of the craniectomy was done and 2-3 dural tentings were tied with the cranioplasty.

All the patients had uneventful post-operative course without any complication in mean follow-up period of 19 months. In follow-up MRI at 1 year no cerebellar ptosis, collapse or restenosis of cisterna magna, obstruction of CSF pathway requiring re-do surgery was evident. All the patients had improvement of their symptoms and radiographic resolution of syrinx. By this expansile titanium mesh cranioplasty, in addition to expanding the volume of the posterior fossa, they also had the aim to prevent the cerebellar sag by the support of the cranioplast and dural prolapse and the collapse of the cisterna magna by the dural tenting with the cranioplasty. The titanium mesh also has the extra preventive accomplishment against re-stenosis at the CVJ by creating a barrier between the musculature and the dura.

3.16 “Modified pi-technique of reduction cranioplasty” by Choi et al.

Choi et al. in 2014 described reduction cranioplasty in an infant of congenital HCP, occipital encephalocele with CM1 [55]. Though it was not a conventional posterior fossa decompression surgery the presence of CM1 carries the merit to be mentioned here.

They reported a baby of occipital encephalocele diagnosed antenatally by USG. MRI at the age of 1 day revealed severe hydrocephalus, occipital encephalocele and herniation of the lower brainstem and cerebellum into the cervical defect. The baby underwent multiple surgeries from the age of day 1, like repair of the encephalocele, VP shunt, foramen magnum decompression, ETV and EVD for multiple times. Despite all these measures, macrocephaly persisted and anterior fontanelle was open and bulged at 32 months postnatally.

The cranial vault was reshaped by modified pi-procedure of reduction cranioplasty. The gap at the anterior fontanelle was covered with two paired sagittal-parietal bone flaps and the coronal bone flap was advanced to the midline to cover the bone defect. To allow the brain to expand laterally, multiple barrel stave osteotomy was done at the level of the squamosal suture bilaterally.

Postoperatively, the skull defect at the non-fused fontanelle was closed. The skull vault circumference decreased from 58 to 53 cm and correction of macrocephaly was seen. There were no postoperative complications. However, they did not mention about the post-operative status of the CM1. Early in infancy, the patient had considerable developmental delays in early infancy. Nevertheless, slow neurological improvement was witnessed during the overall course of development of the baby.

The Chiari malformations are a complex of hindbrain deformities associated hydrocephalus in a minority of patients that need to be managed during the initial stages, which can be cumbersome. Different CSF diversion procedures, even with multiple attempts can lead to craniocerebral disproportion due to discrepancy between the volume of the brain and the volume of the cranium. They recommended that patients of CM1 with other congenital anomalies and HCP can be satisfactorily managed by reduction cranioplasty utilizing the modified pi-technique.

3.17 “Posterior fossa reconstruction using titanium plate” by Udani et al.

In 2014, Udani et al. described their technique of partial posterior fossa cranioplasty using perforated titanium plate for treating cerebellar ptosis and dural ectasia following posterior fossa decompression [56].

They described 12 patients, who previously had undergone PFD for CM1. The interval ranged from 2 to 12 years between the initial surgery and the cranioplasty. First surgery consisted of different combinations of procedures like durapasty, tonsillar shrinkage or syrinx shunting in addition to PFD. Patients presented with headache, neck and back pain, gait ataxia, limb weakness, sensory changes and nystagmus. Imaging revealed persistent tonsillar descent. Four patients had bulging dural ectasia and eight patients had ptosis. Three of the patients had recurrent syrinx.

Five patients, including the three with syrinx, had a 1- to 2-week trial of suboccipital counter pressure with a soft foam rubber pad against the decompression site that was held in place with an elastic bandage, prior to partial titanium cranioplasty and had symptomatic improvement with this trial. Prior craniectomy defects were defined in all the patients pre-operatively. A suboccipital perforated titanium plate was shaped to make it slightly convex in the midline and flat on the sides to merge with the bone. It was placed along the inferior edge of the craniectomy to support the dura over the cerebellar hemispheres but not extending down to the foramen

magnum and was fixed with the bone using four 4-mm mini screws. Seven patients had intradural exploration with duraplasty with a composite dural graft.

In the mean follow-up period of 18 months, symptoms of four patients with dural ectasia improved significantly. Syring improved in two of the three patients. Overall, 10 out of 12 patients responded favorably to the partial titanium cranioplasty.

The cerebellar ptosis, which may develop as a delayed and potentially serious complication, has the potential to reestablish contact with the brainstem, recreating partial obstruction of CSF flow. This in turn may re-establish conditions for filling of a syrinx cavity which is usually a consequence of large craniectomies. They theorized that larger craniectomies are not necessary to accomplish tonsillar decompression.

3.18 “Hemicranioplasty for osteopetrosis and CM1” by Alsahlawi et al.

Alsahlawi et al. reported a case of autosomal-dominant type of osteopetrosis with concomitant CM1, who had headache and severe visual deterioration, all attributing to increased ICP [57]. Osteopetrosis, a disease of abnormal bone density and volume, resulting from imbalance between osteoblastic formation and osteoclastic resorption, usually presents to a neurosurgeon with features of raised ICP. However, association of osteopetrosis and Chiari malformation is rare.

Their patient presented with gradual deteriorating vision, generalized pain in back, limbs and face, and occasional dizziness and tinnitus. Bone mineral density was high and CT scan revealed generalized diffuse thickening of the skull vault and secondary narrowing of the skull base foramina and internal acoustic meatus. MRI demonstrated crowding at the foramen magnum with bilateral cerebellar tonsillar herniation. There was also severe bilateral compression of the cerebral hemispheres with effacement of the ventricles and the subarachnoid spaces. Medical treatment and left sided optic nerve fenestration failed to resolve the symptoms, rather the patient continued to deteriorate and elective hemicranioplasty was performed after 6 weeks of fenestration.

A right sided fronto-parietal craniotomy flap, measuring 14 × 12 cm, was made with the help of 6 burr holes connected by making grooves with drill first and then with craniotome to cover the thickness of the bone. The inner table of the craniotomy flap was thinned out with saw and drill to reduce the thickness from 30 to 8 mm. The brain under pressure was relieved by duraplasty. Cranioplasty was done with the thinned bone with help of mesh and micro plates. Their plan was to do bilateral decompression, but brain was found to be relaxed after performing the procedure on right side.

Immediately after surgery, the patient noticed significant relief of headache. At 6-month follow-up, headache had resolved completely and vision improved markedly. Postop CT scan showed relief of the brain compression evidenced by enlargement of the ventricles and the subarachnoid spaces. Marked improvement of the cerebellar tonsillar herniation was also observed.

Presently, there exists no medical cure for osteopetrosis. Neurosurgical management evolve around symptom relief mainly. Because of severe headache and progressive visual loss, the authors decided to be aggressive in approach. In absence of osteoclastic activity, thickening of the bones led to raised ICP as well as smaller posterior fossa which ultimately resulted in herniation of the tonsils and following decompressive hemicranioplasty, both the raised ICP and tonsillar herniation were markedly relieved.

3.19 “Expansive suboccipital cranioplasty” by Korshunov

Korshunov et al. described their method of expansive suboccipital cranioplasty for CM1 in 2017 [58]. Their patient presented with intensive disabling persistent

headache and cervico-occipital pain. The patient also had two attacks of generalized tonic seizures with loss of consciousness. Neurological examination revealed horizontal nystagmus. MRI revealed wedge-shaped tonsillar herniation down to 17 mm below the foramen magnum. There was no HCP or syrinx.

The thickened and deformed margin of the foramen magnum was widely dissected following a posterior fossa midline osteoplastic craniotomy. Posterior arch of the atlas was also resected. Arachnoid preserving duraplasty was performed with collagen matrix patch graft. The thickness of the free bone flap was reduced by grinding and the margin of the foramen magnum on the bone flap was also widened. The upper edge of the bone flap was fixed at the upper margin of the craniectomy defect by silk sutures. The lower part of the flap was pulled outwards and fixed with two resorbable mini-plates to create new space in the lower portion of the PCF.

Immediate postop CT scan revealed satisfactory cranioplasty. At 3 months follow-up, the patient was totally free of headache, cervico-occipital pain and seizure and MRI revealed resolution of tonsillar herniation and reformation of the occipital cistern.

Posterior decompression of the craniovertebral junction is the most common treatment for CM1. In addition to the conventional procedure, the authors tried to expand the posterior fossa with the aim to normalize CSF circulation at the CVJ with some modification. The whole procedure renders a better dural closure with less chance of complications, less chance of compression from inside and outside because of the bony barrier and better chance of reformation of the occipital cistern.

3.20 “Upside down-inside out cranioplasty” by Tjokorda and Tjokorda

Tjokorda and Tjokorda described a method of a less invasive suboccipital decompression-cranioplasty in 2018 [59]. They analyzed retrospectively, 10 patients from 2010 to 2016, on whom they performed their formulated method of upside down-inside out (UDIO) cranioplasty.

Seven patients in their 4th decade or older and three patients in their 3rd decade or younger had Chiari malformation type I with or without syringomyelia.

With the help of pneumatic perforator and drill, a reverse triangular-shaped craniotomy was done in one piece. Laminectomy of C1 and duraplasty was performed, ensuring normal cerebrospinal fluid flow and dural pulsation. The triangular bone flap harvested from the suboccipital craniotomy was replaced upside down-inside out and was fixed with titanium mini plate and screws.

All patients had improvement of their sensory and motor functions immediately following surgery. Post-operative Japanese Orthopedic Association scoring system (JOA score) scores compared to pre-operative scores were improved in all the patients. Only one patient needed a syringo-subarachnoid shunt for syrinx. No acute or late surgical complications were encountered in a follow-up period of at least 12 months.

The philosophy behind putting the bone upside down and inside out was to place the bone graft above the external table of its origin with periosteum inside to increase the posterior fossa volume, prevent re-stenosis and dural scarring. Other benefits of UDIO were thought to be protecting the cerebellum from adhesion or sagging, and this was believed to prevent adhesion, preventing formation of the pseudomeningocele, facilitating the reconstruction of the posterior neck muscles and preventing CSF leak by reducing the suction effect.

3.21 “Cranial vault remodeling” by Valentini et al.

In 2019, Valentini et al. described cranial vault remodeling of five children in a special subset of CM1 with untreated sagittal stenosis (USS) [60]. Association of

CM1 with craniosynostosis is not uncommon and coexistent low cranial volume, especially the small posterior fossa with venous engorgement and hydrocephalus has the potential to contribute in developing symptomatic CM1 in infants.

From a series of 636 CM1 children, from 1998 to 2018, 48 cases of untreated sagittal synostosis associated with CM1 were analyzed. Of the 48 children, 27 children were operated for different signs and symptoms like headache, intellectual disability, behavioral disorders, visual loss, sleep apneas, raised ICP, papilledema, syringomyelia and scoliosis. Different modalities of surgical procedures were performed and 5 of the children underwent cranial vault remodeling. Three of them had only cranial vault remodeling, while craniovertebral decompression (CVD) was also performed on 1 before and on 1 after the remodeling.

They did a complete cranial vault remodeling, by means of a personal free flaps technique, adopting the osteo-distraction techniques used for complex craniosynostosis. The flaps were extended on the sagittal area also to favor vertical and wide enlargement.

All the patients had improved symptomatically. In postop MRI they had restoration of normal posterior fossa CSF flow with tonsillar ascent or stabilization, and shrinkage or control of the syrinx diameter.

This procedure was aimed to increase the skull volume, both supra and infratentorial, to reduce the struggle for space between cerebrum and cerebellum. The pathogenesis of CM1 in sagittal stenosis (SS) has been explained by the downward compensatory cranial growth. USS causes a constraint to the posterior cranial vault vertical expansion, resulting in a posterior fossa smaller than normal. The reduced supratentorial volume contributes to downward cerebellar migration directly or through the increase of ICP, and probably also related to the venous hypertension due to superior sagittal sinus constriction in the bony groove. They suggested that the double causal factor in SS, the competition for volume between cerebrum and cerebellum; and the small posterior fossa, both need a surgical intervention by cranial vault remodeling and by CVD respectively. The observations suggest, SS carries the risk to develop a symptomatic CM1, when left untreated, is not amenable by CVD alone.

3.22 “Stealth cranioplasty” by Rahman et al.: our technique and thoughts

In 2017, we described a novel technique of reconstruction of posterior fossa by cranioplasty with the use of pre-shaped titanium mesh for CM1, which we call “Stealth cranioplasty” [27]. In the procedure, we set our goal to address all possible symptoms with maintenance of the surgical modifications continually as well as to prevent complications and recurrence.

We performed surgery in our method on 11 adult patients of CM1 with SM, who presented between 2012 and early 2017. Neurological symptoms of the patients included sensory disturbance, neckache, limb weakness and suboccipital headache for a duration of 6–84 months. MRI of all the patients demonstrated cerebellar tonsillar descent more than 5 mm from the foramen magnum and syringes of different diameters, extending from 3 to more than 10 levels.

A midline posterior fossa craniectomy measuring about 3×2.5 cm and laminectomy of the C1 posterior arch about 1 cm on both sides from the midline is done (**Figure 1A**). An arachnoid preserving midline linear durotomy (**Figure 1B**) followed by duraplasty with a patch of investing layer of the deep cervical fascia is performed (**Figure 1C**). Six tacking sutures are taken from the cut margins of the dura; 2 on both sides and 1 each from the upper and lower tips of the opening (**Figure 1B and C**).

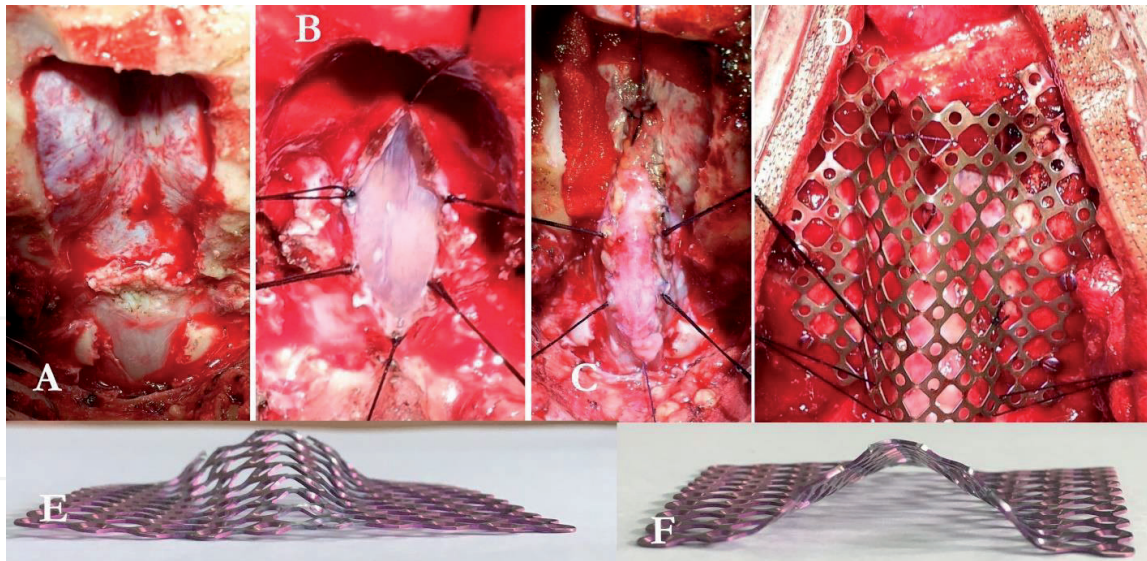


Figure 1.

Different stages of stealth cranioplasty: (A) craniectomy and C1 posterior arch laminectomy, (B) arachnoid preserving durotomy and 6 tackings from the margin, (C) duraplasty, (D) placing of the stealth cranioplast and tenting, (E) stealth cranioplast from front and (F) from rear.

A titanium mesh measuring about 5×5 cm is bent in the middle into a longitudinally half split cone to mimic the cockpit and the flat sides of the mesh are bent outwards to give them the contour of the wings of a Stealth bomber (**Figure 1E and F**). The widened part of the cone is cut in a crescent to create more space around the CVJ. The titanium mesh Stealth cranioplast is placed over the craniectomy gap with the wider portion at the lower end over the foramen magnum and is fixed with 6–7 mini screws. The six tackings are now tacked with the cranioplasty giving the duraplasty the shape of a hexagonal tent (**Figure 1D**).

The “stealth cranioplasty” augments the posterior fossa volume and maintains that and the tacking of the duraplasty maintains the patency of the newly formed cisterna magna.

All the patients of the series were followed up for a period of 7–54 months. Eight patients improved having a Chicago Chiari Outcome Scale (CCOS) score of 13–15, while 3 patients remained unchanged. All the patients had remarkable shape change of the posterior fossa from a flat lower part to a spherical and voluminous lower part on postop CT scan. Diameter of the FM also increased evidently (**Figure 2A and B**). On post-operative MRI, good re-establishment of cisterna magna was noted in all the patients. Marked reduction of syrinx was observed in two patients (**Figure 2C and D**). Eight patients had moderate to mild reduction of syrinx while one patient had no change. No post-operative complication or worsening of pre-operative symptoms were seen and none of the patients needed redo surgery.

Though our technique is not an all-encompassing one, we developed our novel procedure based on the well-established theory of overcrowded shallow posterior fossa causing herniation of the contents through the foramen magnum. We thought of cranioplasty first to make more space in the posterior fossa, especially around the foramen magnum as well as to prevent recurrence from posterior compression by the muscles and fibrous tissue on the unprotected dura following to the craniectomy. The arachnoid preserving duraplasty was done with the intention to avoid CSF-related complications like CSF leak, pseudomeningocele and meningitis. Later, we thought of maintaining the newly formed CSF space by tenting the duraplasty with the cranioplasty. Initially, we used to put a titanium mesh as it is, but with time we faced some complications and started to shape the titanium mesh into the shape

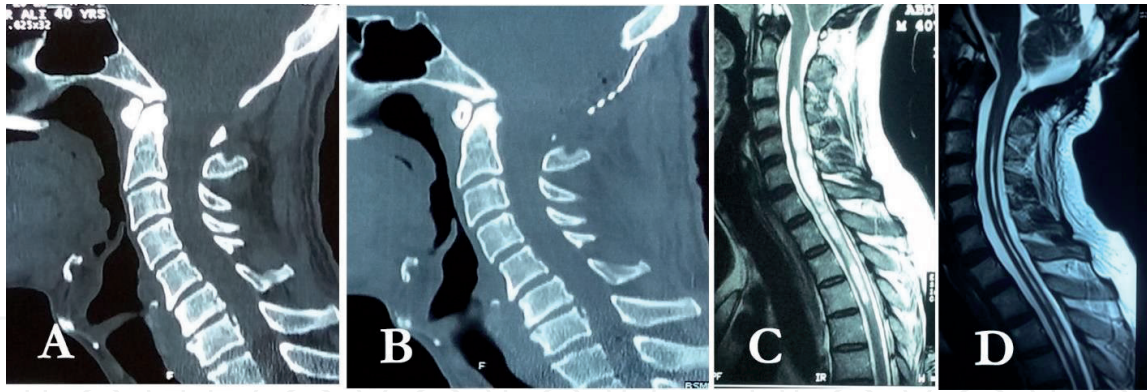


Figure 2.

Pre and postoperative images: (A) preoperative CT scan showing shallow posterior fossa and narrow foramen magnum, (B) postoperatively which has clearly increased in volume and diameter respectively, (C) preoperative MRI shows tonsillar herniation, absence of cisterna magna and big syrinx, and (D) postoperative MRI showing tonsillar ascent, appearance of good retrocerebellar CSF space and obvious resolution of syrinx.

of a Stealth bomber, thus we call it “Stealth cranioplasty”. The Stealth cranioplasty can also prevent cerebellar slump as we flatten the upper portion to support the cerebellum. As a whole, we intended to increase the posterior fossa volume to restore and maintain normal anatomy and physiology around the foramen magnum including the CSF dynamics as well as to prevent cerebellar slump, CSF related complications and recurrence. Reduced financial and psychological burden on the patients came as a byproduct as they did not have complications and did not need any redo surgery so far. As of March 2019, we performed Stealth cranioplasty on 17 symptomatic adults for CM1 with SM and all are doing well without any complication or recurrence.

4. Final remarks and future directions

It was the Japanese neurosurgeons, who pioneered the cranioplasty for CM1. After that, quite a few attempts have been made to manage CM1 by cranioplasty in different formats. Even though, not a regular practice for CM1 surgery, cranioplasty can successfully be performed in selected cases with good outcome.

Different techniques of cranioplasty have been devised with different concepts. Whatever the strategy is preferred, the ultimate goal is to give CM1 patients the utmost benefit. Cranioplasty was first adopted with the aim to increase the volume of the posterior cranial fossa as most of the surgeons of this genre believe that the shallow posterior fossa is the main pathology behind development of CM1. The next other important pathology related to CM is the aberration of the CSF dynamics around the CVJ, which is also believed to be a consequence of the abnormal physiology resulting from the small posterior fossa. The cranioplasties also aim to manage this problem of CSF dynamics and with most of the cranioplasty procedures, this can be managed successfully. Apart from these two, the other valid objectives to choose cranioplasty in treatment of CM can be, dealing and preventing complications like cerebellar ptosis, dural ectasia, CSF related complications, post-surgery headaches and recurrences.

Till now, there is no common method for managing all cases of CM. Thus, every CM should be dealt with its individuality. The genetics of CM is being revealed now with time and the genetic basis of the pathophysiology of CM may allow scientists to manage all CM patients in a single manner in future. Until then, cranioplasty in different formats may serve as good means of dealing most of the straightforward cases of CM as the primary treatment modality in different combinations.

Cranioplasty can play effective role in addressing the primary pathology as well as the way to prevent and manage most of the possible complications. In general, this can be adopted as a routine procedure for most of the cases.

Acknowledgements

I am indebted to my colleagues and patients for their enormous support in so many ways in writing this chapter.

Conflict of interest

None.

Author details

Asifur Rahman
Department of Neurosurgery, Bangabandhu Sheikh Mujib Medical University,
Dhaka, Bangladesh

*Address all correspondence to: bijoun14@yahoo.com

IntechOpen

© 2020 The Author(s). Licensee IntechOpen. This chapter is distributed under the terms of the Creative Commons Attribution License (<http://creativecommons.org/licenses/by/3.0>), which permits unrestricted use, distribution, and reproduction in any medium, provided the original work is properly cited. 

References

- [1] Chiari H. Concerning alterations in the cerebellum resulting from cerebral hydrocephalus. *Pediatric Neurosurgery*. 1987;**13**(1):3-8
- [2] Koehler P. Chiari's description of cerebellar ectopy (1891): With a summary of Cleland's and Arnold's contributions and some early observations on neural-tube defects. *Journal of Neurosurgery*. 1991;**75**(5):823-826
- [3] Massimi L, Peppucci E, Peraio S, Di Rocco C. History of Chiari type I malformation. *Neurological Sciences*. 2011;**32**(3):263-265
- [4] Pearce J. Arnold chiari, or "Cruveilhier cleland Chiari" malformation. *Journal of Neurology, Neurosurgery & Psychiatry*. 2000;**68**(1):13
- [5] Carmel P, Markesbery W. Early descriptions of the Arnold-Chiari malformation. The contribution of John Cleland. *Journal of Neurosurgery*. 1972;**37**(5):543-547
- [6] Fries FN, Hendrix P, Brinker TJ, Loukas M, Tubbs RS. Otto Menck (1876-) and the first description of skull base anomalies causing cerebellar tonsillar ectopia: One of the first mentions of the Chiari I malformation. *Child's Nervous System*. 2017;**33**(5):825-827
- [7] Tubbs RS, Oakes WJ. *The Chiari Malformations: A Historical Context*. The Chiari Malformations. New York: Springer; 2013. pp. 5-11
- [8] Alden TD, Ojemann JG, Park T. Surgical treatment of Chiari I malformation: Indications and approaches. *Neurosurgical Focus*. 2001;**11**(1):1-5
- [9] Lee HS, Lee S-H, Kim ES, Kim J-S, Lee J-I, Shin HJ, et al. Surgical results of arachnoid-preserving posterior fossa decompression for Chiari I malformation with associated syringomyelia. *Journal of Clinical Neuroscience*. 2012;**19**(4):557-560
- [10] Kennedy BC, Kelly KM, Phan MQ, Bruce SS, McDowell MM, Anderson RC, et al. Outcomes after suboccipital decompression without dural opening in children with Chiari malformation type I. *Journal of Neurosurgery: Pediatrics*. 2015;**16**(2):150-158
- [11] Navarro R, Olavarria G, Seshadri R, Gonzales-Portillo G, McLone DG, Tomita T. Surgical results of posterior fossa decompression for patients with Chiari I malformation. *Child's Nervous System*. 2004;**20**(5):349-356
- [12] Munshi I, Frim D, Stine-Reyes R, Weir BK, Hekmatpanah J, Brown F. Effects of posterior fossa decompression with and without duraplasty on Chiari malformation-associated hydromyelia. *Neurosurgery*. 2000;**46**(6):1384-1390
- [13] Pomeraniec IJ, Ksendzovsky A, Awad AJ, Fezeu F, Jane JA. Natural and surgical history of Chiari malformation type I in the pediatric population. *Journal of Neurosurgery: Pediatrics*. 2016;**17**(3):343-352
- [14] Quon JL, Grant RA, DiLuna ML. Multimodal evaluation of CSF dynamics following extradural decompression for Chiari malformation type I. *Journal of Neurosurgery: Spine*. 2015;**22**(6):622-630
- [15] Gardner WJ, Goodall RJ. The surgical treatment of Arnold-Chiari malformation in adults: An explanation of its mechanism and importance of encephalography in diagnosis. *Journal of Neurosurgery*. 1950;**7**(3):199-206
- [16] Krieger MD, McComb JG, Levy ML. Toward a simpler surgical

management of Chiari I malformation in a pediatric population. *Pediatric Neurosurgery*. 1999;**30**(3):113-121

[17] Kurzbuch AR, Jayamohan J, Magdum S. Decompressive surgery for Chiari I malformation in children without dural repair: A still effective and safe procedure? *Child's Nervous System*. 2019;**35**:1-8

[18] Badie B, Mendoza D, Batzdorf U. Posterior fossa volume and response to suboccipital decompression in patients with Chiari I malformation. *Neurosurgery*. 1995;**37**(2):214-218

[19] Batzdorf U, McArthur DL, Bentson JR. Surgical treatment of Chiari malformation with and without syringomyelia: Experience with 177 adult patients. *Journal of Neurosurgery*. 2013;**118**(2):232-242

[20] Bonney PA, Maurer AJ, Cheema AA, Duong Q, Glenn CA, Safavi-Abbasi S, et al. Clinical significance of changes in pB-C2 distance in patients with Chiari type I malformations following posterior fossa decompression: A single-institution experience. *Journal of Neurosurgery: Pediatrics*. 2016;**17**(3):336-342

[21] Cools MJ, Quinsey CS, Elton SW. Chiari decompression outcomes using ligamentum nuchae harvest and duraplasty in pediatric patients with Chiari malformation type I. *Journal of Neurosurgery: Pediatrics*. 2018;**22**(1):47-51

[22] Oral S, Yilmaz A, Kucuk A, Tumenturk A, Menku A. Comparison of dural splitting and duraplasty in patients with Chiari type I malformation: Relationship between tonsillo-dural distance and syrinx cavity. *Turkish Neurosurgery*. 2019;**29**(2):229-236

[23] Radmanesh A, Greenberg JK, Chatterjee A, Smyth MD, Limbrick DD, Sharma A. Tonsillar pulsatility before and after surgical decompression for

children with Chiari malformation type 1: An application for true fast imaging with steady state precession. *Neuroradiology*. 2015;**57**(4):387-393

[24] Singhal GD, Singhal S, Agrawal G, Singhal D, Arora V. Surgical experience in pediatric patients with Chiari-I malformations aged ≤ 18 years. *Journal of Neurosciences in Rural Practice*. 2019;**10**(1):85

[25] Hida K, Iwasaki Y, Koyanagi I, Sawamura Y, Abe H. Surgical indication and results of foramen magnum decompression versus syringo-osubarachnoid shunting for syringomyelia associated with Chiari I malformation. *Neurosurgery*. 1995;**37**(4):673-679

[26] Zhang L, Yi Z, Duan H, Li L. A novel autologous duraplasty in situ technique for the treatment of Chiari malformation type I. *Journal of Neurosurgery*. 2017;**126**(1):91-97

[27] Rahman A, Rana MS, Bhandari PB, Asif DS, Uddin ANW, Obaida ASMA, et al. "Stealth cranioplasty:" A novel endeavor for symptomatic adult Chiari I patients with syringomyelia: Technical note, appraisal, and philosophical considerations. *Journal of Craniovertebral Junction and Spine*. 2017;**8**(3):243

[28] Aghakhani N, Parker F, David P, Morar S, Lacroix C, Benoudiba F, et al. Long-term follow-up of Chiari-related syringomyelia in adults: Analysis of 157 surgically treated cases. *Neurosurgery*. 2009;**64**(2):308-315

[29] Alfieri A, Pinna G. Long-term results after posterior fossa decompression in syringomyelia with adult Chiari type I malformation. *Journal of Neurosurgery: Spine*. 2012;**17**(5):381-387

[30] Armonda RA, Citrin CM, Foley KT, Ellenbogen RG. Quantitative cine-mode

magnetic resonance imaging of Chiari I malformations: An analysis of cerebrospinal fluid dynamics. *Neurosurgery*. 1994;**35**(2):214-224

[31] Ladner TR, Dewan MC, Day MA, Shannon CN, Tomycz L, Tulipan N, et al. Evaluating the relationship of the pB-C2 line to clinical outcomes in a 15-year single-center cohort of pediatric Chiari I malformation. *Journal of Neurosurgery: Pediatrics*. 2015;**15**(2):178-188

[32] Batzdorf U. Chiari I malformation with syringomyelia: Evaluation of surgical therapy by magnetic resonance imaging. *Journal of Neurosurgery*. 1988;**68**(5):726-730

[33] Alzate JC, Kothbauer KF, Jallo GI, Epstein FJ. Treatment of Chiari type I malformation in patients with and without syringomyelia: A consecutive series of 66 cases. *Neurosurgical Focus*. 2001;**11**(1):1-9

[34] Stanko KM, Lee YM, Rios J, Wu A, Sobrinho GW, Weingart JD, et al. Improvement of syrinx resolution after tonsillar cauterization in pediatric patients with Chiari type I malformation. *Journal of Neurosurgery: Pediatrics*. 2016;**17**(2):174-181

[35] Milhorat TH, Johnson WD, Miller JI, Bergland RM, Hollenberg-Sher J. Surgical treatment of syringomyelia based on magnetic resonance imaging criteria. *Neurosurgery*. 1992;**31**(2):231-245

[36] Rocque BG, Oakes WJ. Surgical treatment of Chiari I malformation. *Neurosurgery Clinics*. 2015;**26**(4):527-531

[37] Ratre S, Yadav N, Yadav YR, Parihar VS, Bajaj J, Kher Y. Endoscopic management of Arnold-Chiari malformation type I with or without syringomyelia. *Journal of Neurological*

Surgery Part A: Central European Neurosurgery. 2018;**79**(01):045-051

[38] Zagzoog N, Reddy KK. Use of minimally invasive tubular retractors for foramen magnum decompression of Chiari malformation: A technical note and case series. *World Neurosurgery*. 2019;**128**:248-253

[39] Tokuno H, Suzuki T, Nishimura S, Hakuba A, editors. Operative treatment of Chiari malformation with syringomyelia. In: *Proceedings of the 8th European Congress of Neurosurgery*; September 6-11, 1987; Barcelona. Springer; 1988

[40] Sakamoto H, Nishikawa M, Hakuba A, Yasui T, Kitano S, Nakanishi N, et al. Expansive suboccipital cranioplasty for the treatment of syringomyelia associated with Chiari malformation. *Acta Neurochirurgica*. 1999;**141**(9):949-961

[41] Holly LT, Batzdorf U. Management of cerebellar ptosis following craniocervical decompression for Chiari I malformation. *Journal of Neurosurgery*. 2001;**94**(1):21-26

[42] Di Rocco C, Velardi F. Acquired Chiari type I malformation managed by supratentorial cranial enlargement. *Child's Nervous System*. 2003;**19**(12):800-807

[43] Nishikawa M, Ohata K, Baba M, Terakawa Y, Hara M. Chiari I malformation associated with ventral compression and instability: One-stage posterior decompression and fusion with a new instrumentation technique. *Neurosurgery*. 2004;**54**(6):1430-1435

[44] Takayasu M, Nishizawa T, Yoshida J. Simple Expansive Suboccipital Cranioplasty Following Foramen Magnum Decompression for the Treatment of Syringomyelia Associated with Chiari I Malformation.

Syringomyelia: Springer; 2001.
 pp. 159-163

[45] Takayasu M, Takagi T, Hara M, Anzai M. A simple technique for expansive suboccipital cranioplasty following foramen magnum decompression for the treatment of syringomyelia associated with Chiari I malformation. *Neurosurgical Review*. 2004;**27**(3):173-177

[46] Itoh Y, Kuwahara N, Hirano Y, Sasajima T, Suzuki A, Mizoi K. Surgical Treatment of Syringomyelia Associated with Chiari I Malformation: Advantage of Cranioplasty Using Hydroxyapatite Implants. *Syringomyelia: Springer*; 2001. pp. 188-193

[47] Sheikh BY. Simple and safe method of cranial reconstruction after posterior fossa craniectomy. *Surgical Neurology*. 2006;**65**(1):63-66

[48] Heller JB, Lazareff J, Gabbay JS, Lam S, Kawamoto HK, Bradley JP. Posterior cranial fossa box expansion leads to resolution of symptomatic cerebellar ptosis following Chiari I malformation repair. *The Journal of Craniofacial Surgery*. 2007;**18**(2):274-280

[49] Di X, Luciano MG, Benzel EC. Acute respiratory arrest following partial suboccipital cranioplasty for cerebellar ptosis from Chiari malformation decompression: Report of 2 cases. *Neurosurgical Focus*. 2008;**25**(6):E12

[50] Chou Y-C, Sarkar R, Osuagwu FC, Lazareff JA. Suboccipital craniotomy in the surgical treatment of Chiari I malformation. *Child's Nervous System*. 2009;**25**(9):1111-1114

[51] Furtado SV, Anantharam BA, Reddy K, Hegde AS. Repair of Chiari III malformation using cranioplasty and an occipital rotation flap: Technical note and review of literature. *Surgical Neurology*. 2009;**72**(4):414-417

[52] Oró JJ, Mueller DM. Posterior fossa decompression and reconstruction in adolescents and adults with the Chiari I malformation. *Neurological Research*. 2011;**33**(3):261-271

[53] Bambakidis NC, Dickman CA. *Surgery of the Craniovertebral Junction*. New York: Thieme; 2012

[54] Assina R, Meleis AM, Cohen MA, Iqbal MO, Liu JK. Titanium mesh-assisted dural tenting for an expansile suboccipital cranioplasty in the treatment of Chiari 1 malformation. *Journal of Clinical Neuroscience*. 2014;**21**(9):1641-1646

[55] Choi J-I, Dhong ES, Lim D-J, Kim S-D. Reduction cranioplasty for macrocephaly with long-standing hydrocephalus and non-fused Fontanelle in Chiari malformation type I. *Child's Nervous System*. 2014;**30**(10):1763-1766

[56] Udani V, Holly LT, Chow D, Batzdorf U. Posterior fossa reconstruction using titanium plate for the treatment of cerebellar ptosis after decompression for Chiari malformation. *World Neurosurgery*. 2014;**81**(5-6):836-841

[57] Alsahlawi A, Ekhzaimy A, Alshowair D, Ajlan A. Decompressive cranioplasty in a patient with osteopetrosis. *World Neurosurgery*. 2017;**108**:991.e1-991.e5

[58] Korshunov A, Kushel Y. *Expansive Suboccipital Cranioplasty in Chiari-1 Malformation (a Case Report and Technical Notes)*. Moscow: Media Sphera Publishing Group; 2017. p. 92

[59] Tjokorda GM, Tjokorda GS. A less invasive suboccipital decompression-cranioplasty for Chiari type I malformation: Is it beneficial? *Interdisciplinary Neurosurgery*. 2018;**14**:59-62

[60] Valentini LG, Saletti V, Erbetta A, Chiapparini L, Furlanetto M. Chiari 1 malformation and untreated sagittal synostosis: A new subset of complex Chiari? *Child's Nervous System*. 2019;**35**:1-13

IntechOpen

IntechOpen