

We are IntechOpen, the world's leading publisher of Open Access books Built by scientists, for scientists

6,900

Open access books available

185,000

International authors and editors

200M

Downloads

Our authors are among the

154

Countries delivered to

TOP 1%

most cited scientists

12.2%

Contributors from top 500 universities



WEB OF SCIENCE™

Selection of our books indexed in the Book Citation Index
in Web of Science™ Core Collection (BKCI)

Interested in publishing with us?
Contact book.department@intechopen.com

Numbers displayed above are based on latest data collected.
For more information visit www.intechopen.com



Towards the Study of Liver Failure: Protocol for a 90% Extended Hepatectomy in Mice

Maria J. Lizardo Thiebaud, Eduardo Cervantes-Alvarez and Nalu Navarro-Alvarez

Abstract

Studies have shown that extended hepatectomy mimics post-hepatectomy liver failure (PHLF) and could also be used to study other small-for-flow syndromes. Extended hepatectomy can be defined as the removal of more than 70% of liver volume. At the molecular level, there seems to be a delayed entrance to the cell cycle, and thus liver dysfunction ensues. Therefore, there is an imperious need to study the mechanisms of such delay to understand how it can be regulated. While the classical 70% hepatectomy model to study liver regeneration has been previously described thoroughly, there are no protocols describing the surgical procedure for a 90% extended hepatectomy (90% EHx). Therefore, we here describe a detailed and reproducible protocol for such model, defining specific aspects that must be considered as well as the most common complications and troubleshooting strategies.

Keywords: liver regeneration, 90% extended hepatectomy, liver failure

1. Introduction

Liver regeneration is the process by which lost tissue is replaced through compensatory hyperplasia of the remaining healthy tissue [1–3]. The regenerative capacity of the liver has been studied since the early nineteenth century [4], when scientists observed changes in liver tissue after surgical procedures. By using portosystemic shunts, they first speculated that overall flow was important for liver regeneration, and not specifically portal blood flow. Later on, a combined model including lobectomies and shunts was used as the main model for liver regeneration [4]. Finally, the acknowledgment that portal blood flow was crucial for liver homeostasis gave rise to the “humoral theory,” and with this, the race to find factors in the portal blood that promoted liver regeneration began [4].

Most of what we currently know about liver regeneration is thanks to the results obtained with surgical models. These models are the most precise, since timing and volume removal can be controlled. In fact, the surgical technique for a 2/3 hepatectomy in rats as a model for liver regeneration has been described and perfected since first published by Higgins and Anderson in 1931 [5–7]. With advances in anesthesia and analgesia, the extension of the 2/3 hepatectomy provides a useful model for the study of liver regeneration and liver failure [8–10].

Studies have shown that extended hepatectomy in rats and mice mimics post-hepatectomy liver failure (PHLF), as well as other small-for-flow syndromes observed in humans, including the small-for-size syndrome (SFSS) seen after transplantation [8, 11–14].

PHLF is a syndrome that can result following liver resection for the removal of a tumor or in the context of living donor liver transplantation (LDLT). PHLF is characterized by postoperative liver dysfunction, with clinical signs of hyperbilirubinemia, coagulopathy, portal hypertension, and ascites [15, 16]. PHLF represents the leading cause of mortality post-PHx (>60%), which varies from 0.5 to 8% depending on the extent of resection and the quality of the underlying parenchyma [5, 6, 17–19]. When assessing parameters for prediction of post-hepatectomy complications, the major liver resection has three times more chance of developing PHLF [20].

The precise mechanisms behind PHLF are poorly understood, but it appears to depend not only on the quality and the quantity of the remaining liver parenchyma [1] but on its ability to surmount the effects of surgical resection. Specifically, the tissue must be capable of limiting hepatocyte death, resisting metabolic stress, and preserving or recovering an adequate synthetic function [21–25]. For liver regeneration to occur, there must be homeostasis. Preventing liver failure thus enhances regeneration [17, 26].

Depending on the quality of the parenchyma, there is a predicted threshold of the future liver remnant. This threshold is used to plan extended resections [14, 16, 27]. In order for the liver to function correctly and to cover the minimum demands of the organism, the total liver volume (TLV) has to be at least 20%, or more than 0.5% of the patient's body weight [16, 18, 19, 28]; otherwise, failure can develop. Animal models have the same characteristics, and by using a percentage of liver volume removed, one can predict the development of liver failure. In fact, several studies have shown that in rodents, acute liver failure (ALF) may develop after 90% EHx [8–10]. At the molecular level, there appears to be a delay in the entrance to the cell cycle and as a consequence, liver dysfunction [10].

Due to the multifactorial processes involved in these syndromes, animal models are important tools to improve our understanding of the pathogenesis of ALF and also for the development of new therapeutic approaches. Considering the above, challenging the hepatostat with surgical removal of extensive liver volume, 90% EHx is a helpful model for the study of acute liver failure in the context of liver surgery [19]. Therefore, we here describe a reproducible and detailed protocol for the establishment of a surgical liver failure model in rodents through 90% extended hepatectomy.

2. Experimental design

When using animals as models, many factors have to be considered as delineated as follows.

2.1 Anatomy

The anatomy of the liver in mice differs substantially from that of the humans (**Figure 1a** and **b**). It measures approximately $1.5\text{--}2 \times 1$ cm and weighs 1–1.5 g [9]. It is constituted of four main lobes, the right lobe (RL), the left lobe (LL), the median lobe (ML), and the omental or caudate lobe (CL). The RL is divided in the right superior lobule (RSL) and right inferior lobule (RIL) (**Figure 1a** and **b**). The ML is partially divided in half by the gallbladder, whereas the CL is further divided in anterior and posterior lobules (**Figure 1a** and **b**). Each segment has an attributed

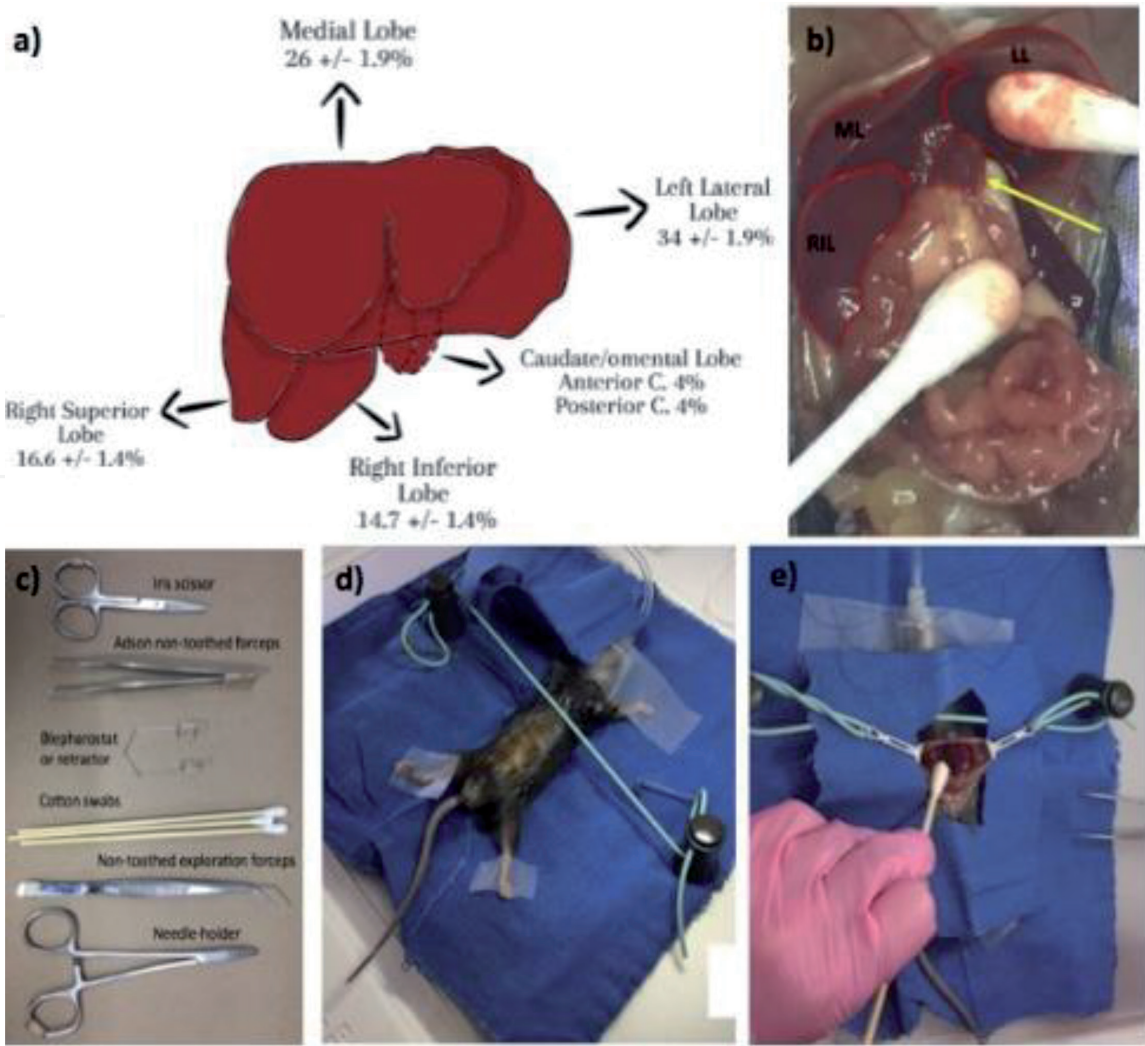


Figure 1.
(a) Anatomy of the mouse liver with the relative volume of each lobe, modified from Martins et al. (2007).
(b) Anatomy of the liver lobes as seen in vivo. The yellow arrow signals the caudate lobe. (c) The surgical instruments used in the procedure. (d) Positioning of the mouse on a surgical platform covered by sterile covers. The mouse is immobilized with tape. (e) View of abdominal cavity once it is open and appropriately uncovered. LL, left lobe; ML, medial lobe; RIL, right inferior lobe.

percentage of contribution to the total liver volume (TLV), which constitutes the basis for the planning of a partial (PHx) or extended hepatectomy (EHx). The ML represents 30% of the TLV, with a range between 24 and 28%. The LL represents 40% of the TLV, with a range between 32 and 36%. The RL represents 24% of the TLV, with the RSL and RIL contributing between 12% and 16% each. And lastly, the CL represents 6–8% of the TLV.

2.2 Sex, age, timing of surgery, health status, and nutrition of the subjects

In animals, it is known that age and sex affect the liver’s regeneration capacity. Compared to young mice, older mice have a reduced capacity of regeneration due to decreased growth hormone levels [22]. In regard to sex, female hormones are known to affect most of the physiological processes in the body, and the regeneration is no exception [29]. Therefore, the preferred characteristics of the subjects are male mice with an age ranging from 8 to 14 weeks and a weight more than 20 g [1, 21–23].

The circadian rhythm and glucocorticoids have been demonstrated to have an effect on liver regeneration [30, 31]. Specifically, performing the surgery passed noon, there seems to be a delay in the regeneration process mediated through the differential transcription of *wee1*, which controls cell cycle proteins, thus

disturbing the progression of the cycle. Externally, cortisol levels are known to affect DNA synthesis by altering the levels of important enzymes [32]. In fact, it has been shown that the combination of adrenalectomy and partial hepatectomy enhances liver regeneration [33]. Therefore, depending on the specific objective of the study, it is advisable to perform the surgeries in the morning.

The subject's nutrition and health status may affect liver regeneration, especially during the initial phases when hepatocytes are entering the cell cycle [22, 34]. Earlier studies have shown that metabolism affects liver regeneration. Indeed, insulin is one of the main cofactors for liver regeneration [35]. Despite the fact that insulin aids in the process, enhancing insulin secretion through glucose supplementation after partial hepatectomy has been shown to decrease liver regeneration [36]. This could be explained by the effect glycogen synthesis has in other metabolic pathways in the hepatocyte.

Following 70% of liver tissue removal, glycogen storage is reduced. The animal thus develops hypoglycemia, which can be severe enough to cause the animal's demise. To prevent that, supplementation becomes reasonable; however, extrinsic glucose affects hepatic fat accumulation. To compensate hypoglycemia, catabolic hormones are produced, which aid in proliferation of hepatic tissue. The hepatic tissue is oxidizing fatty acids meaning most of the machinery will be concentrated either in beta-oxidation or the cell cycle. Introducing carbohydrates (glucose, fructose, or sorbitol) to the diet is therefore detrimental [34]. The molecular mechanisms are still under study. If carbohydrates are combined with other nutrients, including lipids or/and amino acids, this effect can be prevented. In fact, supplementing lipids or amino acids increases the mitotic activity of cells in a regenerating liver [34].

Likewise, a long-term or short-term low-carbohydrate diet before surgery slows down the process of regeneration. A study where mice being fed with a very low-carbohydrate diet before surgery showed impaired proliferative capacity in hepatocytes. The diet consisted of 5.5% of carbohydrate and a 70% of fat without lowering caloric intake. Though a low-carbohydrate diet seems to accelerate fat accumulation in hepatocytes, other pro-regeneration activities were affected. A stall in the priming phase of liver regeneration was confirmed as key cytokine RNA levels in liver tissue were low, and there was a decrease in phosphorylation of second messengers of important mitogenic signaling cascades [37].

In other words, the unique metabolic state in which hepatocytes are found during liver regeneration is not to be altered. To favor the regenerative process, only beneficial substrates such as amino acids or lipids should be used. With the objective of preventing severe hypoglycemia, we recommend adding dextrose before and not after the surgery.

In the same line, it has been shown that selective bowel decontamination for gram-negative bacteria reduces the development of PHLF in a rat model [38]. The reasoning behind this is based on the fact that during hepatectomy there is significant bacterial translocation, which, when in check by the immune system, promotes liver regeneration. Keeping an appropriate sterile environment in the animal facility thus becomes an absolute requirement.

3. Materials

3.1 Animals

In general, this procedure describes extended hepatectomy performed in 8–14 weeks of age B57CL/6 male mice. All animal studies have been approved by the Universidad Panamericana's ethics committee (protocol #E1704) and have therefore been performed in accordance with the ethical standards laid down in the 1964 Declaration of Helsinki and its later amendments.

3.2 Anesthesia

The procedure may last less than 30 min in skillful hands, but it may lengthen depending on the complexity of the anatomy and the experience of the operator. Therefore, in choosing the anesthetic, the best choice is isoflurane (Sofloran Vet) since others have been shown to be hepatotoxic [7]. Not only is the recovery with isoflurane good, but it is also fast, which helps in evaluating the efficacy of the surgical procedure.

3.3 Analgesia

Analgesia is key to a good surgical procedure. Buprenorphine is the analgesic of choice since it has been proven to diminish pain efficiently [39]. About half an hour before beginning, a subcutaneous injection of buprenorphine is recommended at a dose of 0.05–1 mg/kg, followed by its administration every 8–12 h for the next 72 h. Meloxicam is a good alternative and has the advantage of being used as a single dose/day, compared to the twice daily administration of buprenorphine [39].

3.4 Materials, instruments, and equipment

3.4.1 Materials

- Isoflurane (Sofloran Vet)
- Sterile normal saline (NS) (Baxter ABB1306AE)
- Sterile normal saline with 10% dextrose (D10)
- Iodine (Germisin, Altamirano 027)
- 70% ethanol (Alcohol Luna)
- Sterile wooden cotton swabs (we usually require 4–5)

3.4.2 Sutures

- 4-0 silk suture for the viscera (SOFILK S-182 USSC sutures)
- 5-0 vicryl for peritoneum closure (Vicryl JP493 Ethicon)
- 5-0 nylon (Mononylon Ethilon P698 Ethicon) for the skin

3.4.3 Standard surgical instruments

- Microsurgery scissors, also known as Iris scissor (Trauma, Lanceta), to cut the skin, peritoneum, and the stumps once they are tied (**Figure 1c**).
- Straight, non-toothed microdissecting forceps (Trauma or Weldon Instrumental, Lanceta) to hold the skin and peritoneum.
- Curved, non-toothed microdissecting forceps (Trauma, Lanceta), helps when doing the knots on the lobules.
- Retractors (a blepharostat can be used) (Braintree Scientific).

- Mayo-Hegar needle holder (Trauma, Lanceta) for suturing the peritoneum and skin.

3.4.4 Equipment

- Anesthesia machine/isoflurane vaporizer (SomnoSuite, Low-Flow Anesthesia System)
- Surgical bed (Surgisuite Multi-Function Surgical Platform, standard)

4. Methods: recipient anesthesia and peri- and postoperative care

Critical: Administer intraperitoneally or subcutaneously 500 µl of NS+D10 2 h before the surgery.

1. Sedate the mice using isoflurane 2–3% for induction and 1% for maintenance.
2. During the surgery, as well as postoperatively, the mouse has to be placed on a warm pad, to prevent hypothermia (**Figure 1d**). After surgery the mice are left in the warm pad until they are able to move and stand up without stimuli.
3. Buprenorphine must be administered 30 min before surgery and following a schedule (each 8–12 h) for the following 72 h.
4. To prevent dehydration 500 µl of normal saline should be administered intra-peritoneally or subcutaneously.
5. During follow-up, we use a score to evaluate the status of the mouse as seen in **Table 1**. Though the score was validated in 70% hepatectomized mice, in our hands, it has worked well in establishing a prognosis in mice with an extended hepatectomy. A score of less than 5 at 6 h and 12 h has a bad prognosis. The values correlate with serum levels of IL-6, liver enzymes, and histological features of regeneration [40]. We also use this score for decision-making. Depending on the score, one can consider placing the mouse more time on a warming pad as well as euthanizing if the score does not increase after 12–24 h. While regeneration will progress as expected in 70 and 85% hepatectomy, a 90% hepatectomy is fulminant and causes acute liver failure and death within 24–48 h.

Category	0	1	2
Activity	Stay still Touch without response (TOR)	Stay still Touch with response (TWR, limp away)	Walks free
Fur	Wet abdomen and butt/ unkempt fur	Between	Dry and neat fur
Body posture	Hunched (TOR)	Moderate hunched (TWR)	Normal stretch
Breath	Deep		Normal (nonobservable)
Eyes	Half-close (TOR)	Half-close (TWR)	Open and alert

Table 1.
Mouse body condition score for the major liver resection (taken from Xu et al.).

4.1 Procedure for extended 90% hepatectomy (timing 40–50 min)

1. Weight the mouse.
2. Following anesthesia induction, the abdomen should be shaved; however, this can be done before anesthesia (**Figure 1d**).
3. Clean the dorsum of the mouse with ethanol before placing it on the surgical bed covered with sterile fields.
4. Cleaning of the abdomen must be done with iodine and ethanol 70%.
5. A midline incision is made in two planes (skin and peritoneum). Visibility is of critical importance during the procedure. Separation is done with a blepharostat or simple clips as described by Mitchell and Willenbring [31].
6. Start by visualizing the full anatomy of the liver (**Figure 1b and e**).
7. Once the liver is visualized, the falciform ligament may be cut.

Caution: The falciform ligament must be cut carefully and not too close to the diaphragm since the fascia can be cut, causing a hole in the pleural cavity.

8. Next, the first lobe to be removed will be the median lobe (**Figure 2a–c**). By using cotton swabs, mobilize the median lobe upward (toward the diaphragm), and place a silk suture under it (**Figure 2a**).

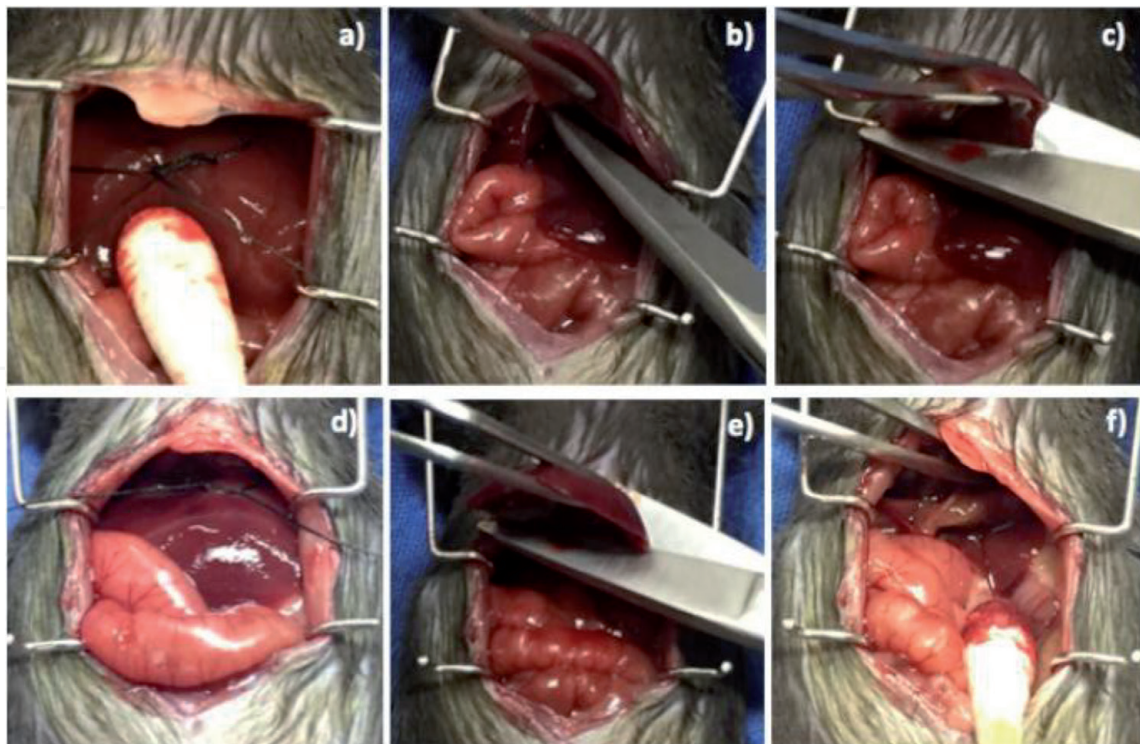


Figure 2.

For the removal of the ML, (a) the suture is accommodated leaving several centimeters from the base of the medial lobe. The lobules are cut separately. (b) The right ML is cut first as it is the most visible of the two. (c) The left ML is cut last, making sure not to perforate the gallbladder. (d) The suture is accommodated surrounding the LL. (e) The LL is excised. (f) The stump and a well-perfused caudate lobe are visualized.

Caution: Cotton swabs are used instead of forceps since the tissue is fragile and bleeds easily.

1. Once that is accomplished, return the lobe to its original position with the cotton swab.
2. There is no need of dissecting the different vessels.
3. Tie the knot at the base of the lobe, making sure to leave enough remnant in the stump as knots that are too close to the base can damage the circulation in the inferior vena cava and suprahepatic veins, compromising the rest of the lobes (**Figure 2a**).

Critical step: One good reference of how long the stump must be is the origin of falciform ligament or the gallbladder.

Troubleshooting: if the stump is too big, the functional volume will not be as accurate.

4. As the knot tends to slide downward, which increases the remnant tissue, one must make sure that the ends are well placed as described in step 10 before tying the knot.

Critical step: To accommodate the ends of the silk suture along the borders of the lobe, pull carefully the lobe downward with a cotton swab.

Critical step: Afterward, double-check the tightness of the knot manually.

1. Subsequently, the ends of the suture are cut.
2. Upon noticing a change of color in the sutured lobe, the lobe to be resected can be held with forceps and then cut with the microsurgery scissors (**Figure 2b** and **c**).

Caution: Care must be taken not to cut through the gallbladder as the bile is toxic to tissues of the abdominal cavity. A good advice is to cut the portions separately.

Caution: Once tied, the resection of the lobes needs to be done with extreme caution, since the knot can be cut unintentionally.

Critical step: Remember to always check for hemostasis.

3. The next lobe to be resected is the left lobe, as shown in (**Figure 2d–f**). Following the same technique as for the median lobe, lift the lobe toward the diaphragm with a cotton swab to place a silk suture under it, return the lobe to its original position, and tie the knots strong enough to avoid bleeding. Be careful not to section the liver.

Critical step: Always separate the left lateral lobe from the caudate lobe as sometimes there is a ligament that unites them both.

4. After tying the knots and cutting the edges, resect the lobe leaving only the required remnant (**Figure 2e–f**).

Caution: Once tied, the resection of the lobes needs to be done with extreme caution, since the knot can be cut unintentionally.

Troubleshooting: If the stump is too big, the functional volume will not be as accurate.

1. After resecting the median lobe and the left lateral lobe, the right inferior lobule is visible. To increase visualization, the intestines may be moved outside the abdominal cavity with a cotton swab. We recommend placing them within a wet gauze to prevent the intestines from drying (**Figure 3a**).
2. When visualized, the inferior right lobe is moved toward the inferior vena cava with a cotton swab to place the silk suture under it. The silk suture is accommodated parallel to the lobule (**Figure 3b**).
3. Once that is done, replace the lobule over the silk suture using a cotton swab.

Critical step: The knot must be made using very fine forceps as tying it tends to move the lobule out of the knot (**Figure 3c**).

1. Four to five knots have to be placed as described above.
2. The ends of the silk suture are cut.
3. Once the lobule changes color, one can proceed to cut it (**Figure 3d and e**).

Caution: When resecting the right lobe, one must place the suture with diligence, making sure not to touch the kidney.

Caution: Once tied, the resection of the lobes needs to be done with extreme caution, since the knot can be cut unintentionally.

Caution: Sites of bleeding need to be identified.

1. Notice that if one leaves the superior right lobule together with the caudate lobe, approximately 22–24% of hepatic volume can be left, thus becoming a partial hepatectomy of 82–86%.
2. The last lobule left to be removed is the superior right lobule (**Figure 4**). This is technically difficult since it is located deep within the vault of the diaphragm. The use of clips reduces the technical difficulty.
3. When using silk sutures, we recommend doing the knot outside the cavity (**Figure 4a**). Once this is done, with a swab the superior right lobule is moved toward the inferior vena cava (**Figure 4b**), rapidly placing the silk suture knot parallel to it. With the swab, one locates the lobule within the knot.

Critical step: As mentioned before, the knot must be tied using forceps with very fine tips and within the abdominal cavity (**Figure 4c and d**).

1. The first knot does not have to be tight; the second one must be tightened with the fingers, applying as much force as possible.
2. The lobule can be cut once it changes color (**Figure 4e**).

Caution: The resection of the lobes needs to be done with extreme caution, since the knot can be cut unintentionally.

3. After hemostasis is reassured (**Figure 4f**), the abdominal cavity can be closed.

Caution: Always check for perfusion of the caudate lobe, as seen in **Figure 4g**.

Critical step: We recommend suturing the peritoneum separately from the skin (**Figure 5**). This helps prevent evisceration as mice tend to remove the stitches.

1. The peritoneum is closed with an absorbable suture like 5-0 vicryl or PDS, using a running suturing technique to keep tension at the closure (**Figure 5b and c**).
2. The skin is closed with 4-0 nylon using a simple interrupted suturing technique or clips (**Figure 5d–f**).

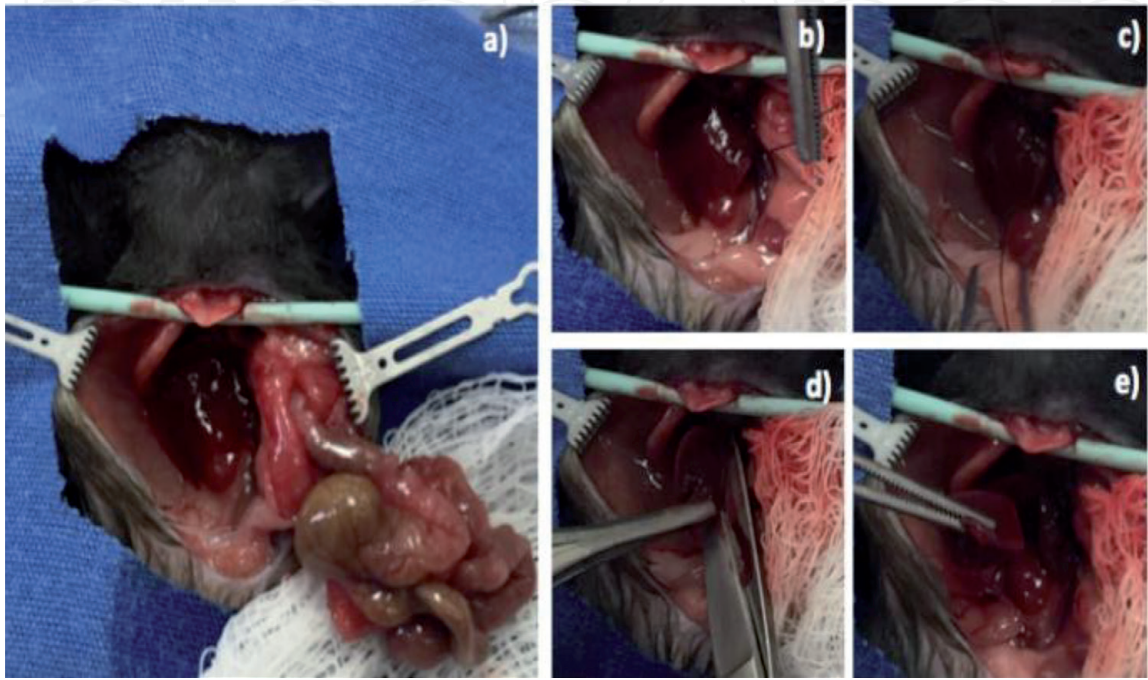


Figure 3.
(a) For the extirpation of the RL, evisceration must be made, and the intestine should be covered by a wet gauze. (b) The silk suture is placed beneath the RIL. (c) The knot is carefully tightened. (d) The lobe is excised. (e) A forceps can be used to remove the excised tissue.

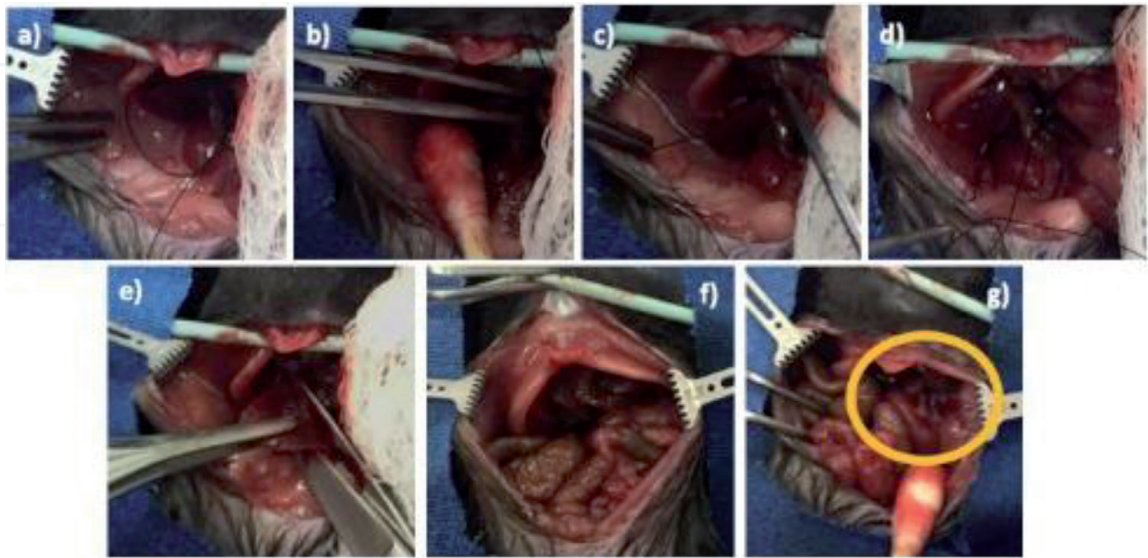


Figure 4.
For removal of the RSL, (a) the knot is made outside the peritoneal cavity and (b) is positioned carefully around the lobule with the help of the forceps. (c) The knot is tightened with the forceps inside the peritoneal cavity. (d) If the correct force is applied, the silk suture does not cut through the tissue, and no bleeding is seen. (e) The lobe is removed carefully. (f) The remaining stumps within the cavity is shown. (g) The only remaining lobe will be the caudate lobe.

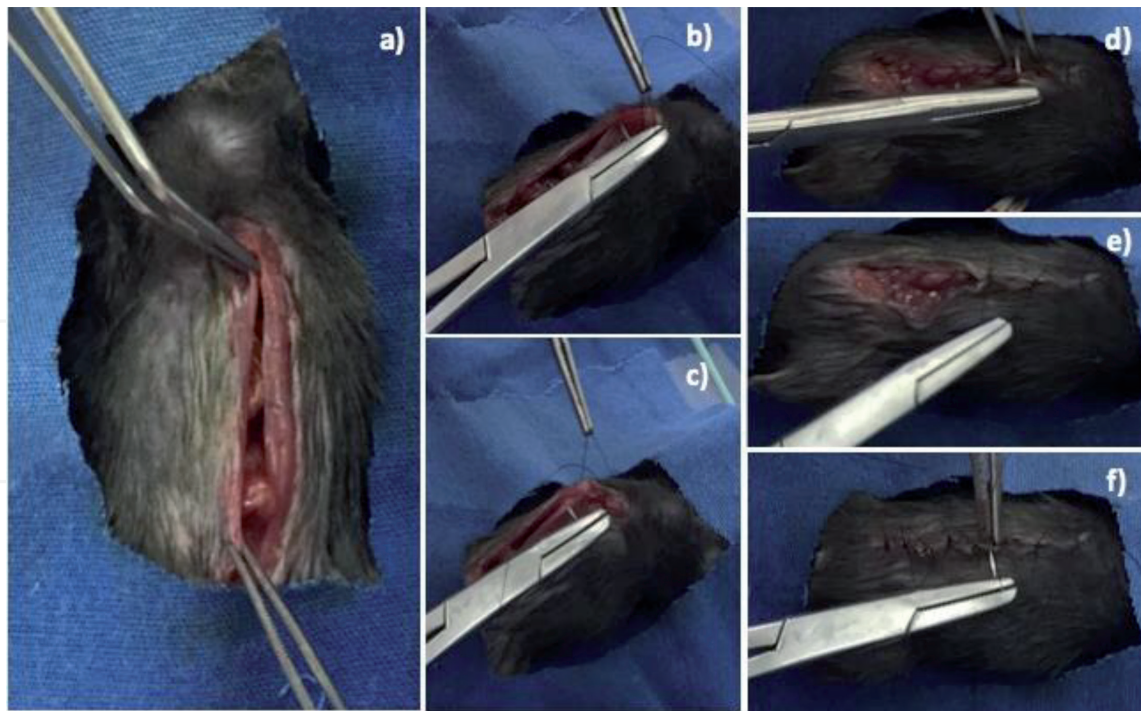


Figure 5.
 (a) Apposition of the borders of the peritoneum is made before beginning the suture of the incision. (b) A simple continuous suture is made on the peritoneum lining. (c) The suture is performed from proximal to distal. (d) The skin is sutured with simple interrupted sutures, (e) from the xiphoid process to the pelvis area. (f) The space between the sutures must be even.

5. Troubleshooting

One important aspect of every surgical procedure is the anesthesia. Incorrect dosing can be fatal to the subject. Weighting the animal and calculating the anesthetic correctly are crucial.

Following the steps of the procedure, using the adequate number of silk suture, is important as thinner sutures can cut the tissue when tying the knot. This produces unwanted bleeding.

As to the knot, inadequate tying and incorrect placement may complicate the procedure. If the knot is not tight enough after excision of the tissue, the bleeding can be very profuse and difficult to stop. In competent hands, a second knot can be placed. This stops the bleeding. Sometimes, the bleeding is not noticed until the animal dies after 12–24 h of the procedure. The main cause of death is usually internal bleeding due to technical errors with the knot.

As mentioned before, if the knot is placed at the median lobe too proximate to the inferior vena cava, the perfusion of the remnant lobe is compromised. In this case, perfusion of the caudate lobe (**Figure 6**) indicates that the EHx becomes a full hepatectomy. The under-perfused tissue will not be able to enter the process of regeneration before acute liver failure establishes.

The stump volume is important in achieving a real EHx. If the stump volume is too big, not only will the animal be left with a caudate lobe, it will also be left with a partial lobe, whether it is the median, the left, or the right lobe. The only way to notice this is after the surgery, as the animal will show clinical features of liver failure. If liver failure does not develop, that means the model failed and more remnant tissue was left in place than the actual 10% that was supposed to be left for a 90% EHx.

A summary of the main complications and errors is found in **Table 2**.

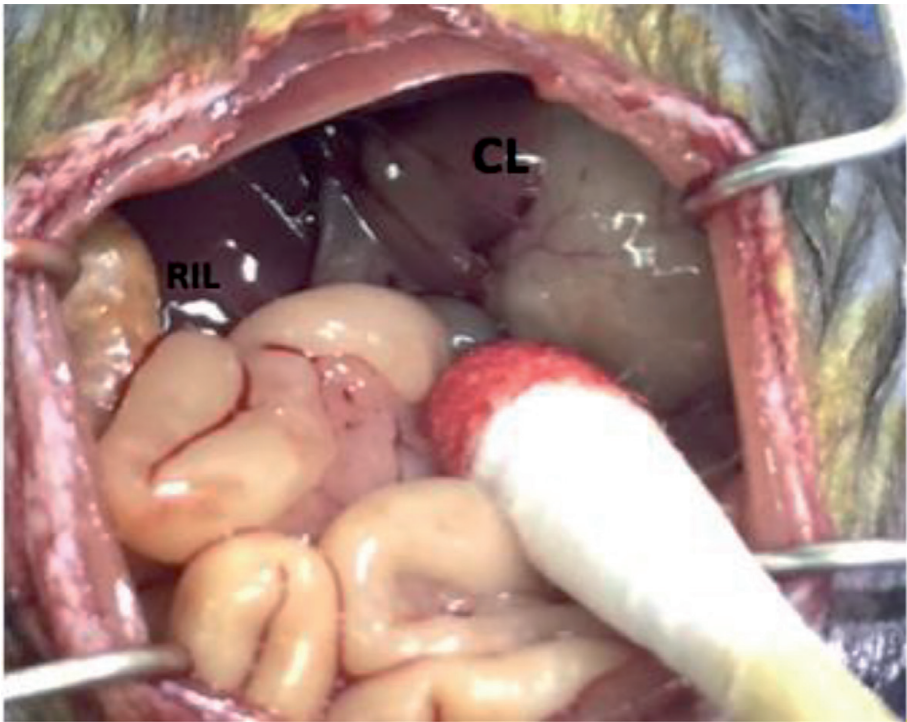


Figure 6. After resection of the median lobe, when tying too high toward the inferior vena cava, the hepatic circulation is affected as seen in the color acquired by the CL.

Troubleshooting	Step	Problem	Possible reason	Solution
Death during procedure	17–25	Bleeding	Tightness of knot	Use forceps to tie knot first proximal to the tissue, deep within the cavity
Death in less than 24 h	8–25	Bleeding	Tightness of knot	Ensure tightness of knot manually
				Avoid cutting through the knot
More than 48-h survival	8–25	Survival	Stump volume	Cut enough tissue as to approximate the % of functional liver volume you want to resect
Bad perfusion of caudate lobe	8–13	Fulminant hepatic failure	Knot made too high upon the hilum of the median lobe	Use the gallbladder as reference for doing the stump; leave at least 2 mm of stump

Table 2. Troubleshooting.

6. Quantifying results

6.1 Liver regeneration

To assess liver regeneration, the liver-to-body weight ratio (LBWR) can be calculated by considering the weight of the animal after the surgery and weight of the remnant lobe (the caudate lobe). The stumps are not considered in the ratio unless the stumps made were too big and have regenerated. The LBWR tells the volume of regenerated tissue in proportion to the body. As mentioned before, the liver has a hepatostat, and thus the body weight has to be considered.

For the assessment of mitosis in liver samples, a basic H&E or an immunohistochemistry against Ki-67 or bromodeoxyuridine (BrdU) can help count the number

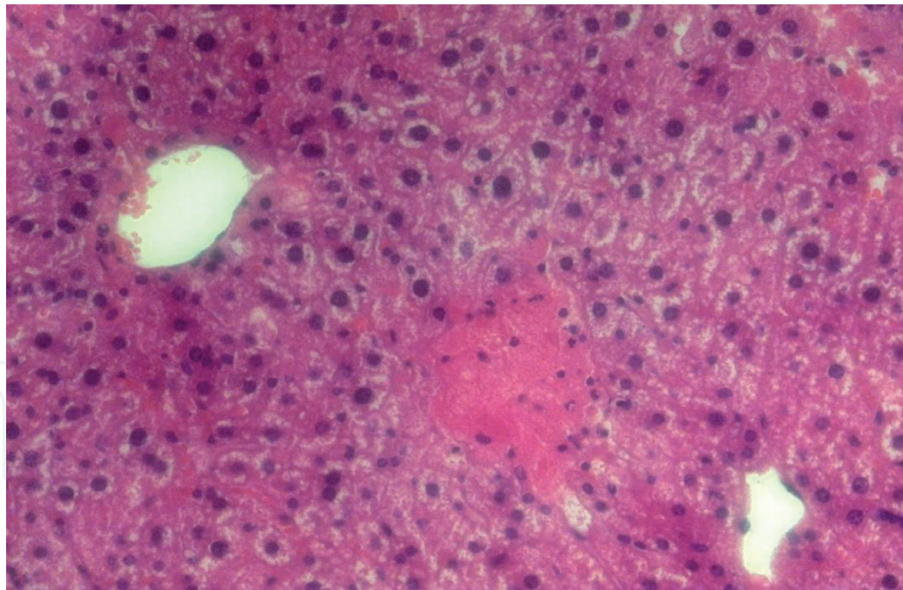


Figure 7.
Tissue slide stained with H&E showing steatosis and a necrotic area in a sample of the liver 24 h post-hepatectomy.

of replicating cells. Mitotic cells are identified by the condensation of the chromatin and loss of nuclear membrane. Identifying the late phases of mitosis is much easier. Quantifying the positivity of cells to Ki-67 reflect that these cells are in the cell cycle. Ki-67 is known to modulate most of the phases in the cell cycle but has its peak when the cell reaches the mitosis phase. Bromodeoxyuridine assay works by administering intramuscularly a dose (50 mg/kg) of BrdU to the animal before sacrifice. BrdU is an analogue of thymidine, and as such it becomes incorporated to the DNA. When an antibody against BrdU is used, cells that are in the S phase or beyond can be identified.

6.2 Liver failure

To assess liver failure in the live animal, the quantification of liver enzymes through colorimetric assays is helpful. Clinical assessment is sensible. As described above, the value of the mouse body condition score after the major liver resection can predict the outcome of the procedure [40]. A score less than or equal to 5 measured consecutively within 24 h post-hepatectomy correlated with increased levels of liver enzymes, pro-inflammatory cytokines, and decreased regeneration measured through ki-67 staining in liver tissue.

In the dead animal, the LBWR is key to assess the degree of regeneration, which is inversely proportional to liver dysfunction. Once the tissue is procured, microscopically, steatosis is a hallmark of liver failure (**Figure 7**). On the other hand, the calculation of the survival rate helps predict the hours an animal with liver failure is able to survive.

Biomarkers can be developed to assess the possibility of liver regeneration or liver failure. Nonetheless, the value of these biomarkers will depend on the existence of therapeutics to enable regeneration or prevent liver failure. Thus, there is a need of using surgical models to study these payoffs, which are two factual extremes of a method frequently used in clinical practice.

7. Conclusions

We have here described a reproducible mouse model for a 90% extended hepatectomy which mimics closely small-for-flow syndromes and thus an important acute liver failure scenario. Even though the obvious problem in this setting and

the objective of this extended hepatectomy model is to severely reduce liver mass, which describes the term small for size, liver dysfunction is now increasingly recognized to occur due to a small-for-flow syndrome [41–43]. As Golriz and authors suggest, the appropriate term for this syndrome should be small for size and flow [44]. The critical turning point in the understanding of this phenomenon is that portal flow to the remaining liver mass or liver graft is excessive, leading to histopathological consequences including sinusoidal endothelial denudation, periportal hemorrhage, arterial vasospasm, portal vein thrombosis, and biliary strictures [45, 46]. Considering the physiopathology that originates this type of acute liver failure, it has been experimentally demonstrated that interventions aimed to reduce portal overpressure such as the use of vasoconstrictors or splenic artery ligation have positive effects on liver regeneration and hepatocellular viability [41, 42]. In the clinical setting, Kaido and authors have successfully lowered the limit of graft-to-recipient weight ratio to 0.6% in adult-to-adult living donor liver transplantation by maintenance of an intraoperative final portal pressure below 15 mmHg, which may involve ligation of portosystemic shunts or even splenectomy [43]; it is worth noting that traditionally the minimum ratio considered as safe for liver transplantation or resection is 0.8%, based on a study where probability of graft survival at 90 days is less than 54% [47].

Acknowledgements

This research has been funded by the Universidad Panamericana through the grant “Fomento a la Investigación UP 2017,” under project code UP-CI-2017-CS-MX-02.2.

Conflict of interest

The authors declare no conflict of interest.

Nomenclature

BrdU	bromodeoxyuridine
CL	caudate lobe
D10	dextrose 10%
Ehx	extended hepatectomy
LBWR	liver-to-body weight ratio
LLL	left lateral lobe
ML	medial lobe
NS	normal saline
PHx	partial hepatectomy
PHLF	post-hepatectomy liver failure
RIL	right inferior lobe
RSL	right superior lobe
SFSS	small-for-size syndrome
TLV	total liver volume

IntechOpen

Author details

Maria J. Lizardo Thiebaud¹, Eduardo Cervantes-Alvarez^{2,3}
and Nalu Navarro-Alvarez^{1,2,4*}

¹ Universidad Panamericana, School of Medicine, México City, Mexico

² Department of Gastroenterology, Instituto Nacional de Ciencias Medicas y Nutrición, Salvador Zubirán, México City, Mexico

³ PECEM, Faculty of Medicine, Universidad Nacional Autónoma de México, Mexico City, Mexico

⁴ Department of Surgery, Massachusetts General Hospital, Center for Transplantation Sciences, Harvard Medical School, Boston, MA, United States

*Address all correspondence to: nnavarro@up.edu.mx

IntechOpen

© 2019 The Author(s). Licensee IntechOpen. This chapter is distributed under the terms of the Creative Commons Attribution License (<http://creativecommons.org/licenses/by/3.0>), which permits unrestricted use, distribution, and reproduction in any medium, provided the original work is properly cited. 

References

- [1] Pahlavan PS, Feldmann RE, Zavos C, Kountouras J. Prometheus' challenge: Molecular, cellular and systemic aspects of liver regeneration. *The Journal of Surgical Research*. 2006;**134**(2):238-251
- [2] Michalopoulos GK, DeFrances MC. Liver regeneration. *Science*. 1997;**276**:60-66
- [3] Taub R. Liver regeneration: From myth to mechanism. *Nature Reviews. Molecular Cell Biology*. 2004;**5**(10):836-847
- [4] Mortensen KE, Revhaug A. Liver regeneration in surgical animal models—A historical perspective and clinical implications. *European Surgical Research*. 2011;**46**(1):1-18
- [5] Martins PNA, Theruvath TP, Neuhaus P. Rodent models of partial hepatectomies. *Liver International* [Internet]. 2008;**28**(1):3-11. DOI: 10.1111/j.1478-3231.2007.01628.x
- [6] Higgins G, Anderson R. Experimental pathology of the liver I restoration of the liver of the white rat following partial surgical removal. *Archives of Pathology*. 1932;**12**:186-202
- [7] Greene AK, Puder M. Partial hepatectomy in the mouse: Technique and perioperative management. *Journal of Investigative Surgery*. 2003;**16**:99-103
- [8] Makino H, Togo S, Kubota T, Morioka D, Morita T, Kobayashi T, et al. A good model of hepatic failure after excessive hepatectomy in mice. *The Journal of Surgical Research*. 2005;**127**(2):171-176
- [9] Hori T, Ohashi N, Chen F, Baine AMT, Gardner LB, Jermanus S, et al. Simple and sure methodology for massive hepatectomy in the mouse. *Annals of Gastroenterology*. 2011;**24**(4):307-318
- [10] Lehmann K, Tschuor C, Rickenbacher A, Jang JH, Oberkofler CE, Tschopp O, et al. Liver failure after extended hepatectomy in mice is mediated by a p21-dependent barrier to liver regeneration. *Gastroenterology* [Internet]. 2012;**143**(6):1609-1619.e4. DOI: 10.1053/j.gastro.2012.08.043
- [11] Darnis B, Mohkam K, Schmitt Z, Ledochowski S, Vial JP, Duperret S, et al. Subtotal hepatectomy in swine for studying small-for-size syndrome and portal inflow modulation: Is it reliable? *HPB*. 2015;**17**(10):881-888
- [12] Panis Y, McMullan DM, Emond JC. Progressive necrosis after hepatectomy and the pathophysiology of liver failure after massive resection. *Surgery*. 1997;**121**(2):142-149
- [13] Van Den Broek MAJ, Olde Damink SWM, Dejong CHC, Lang H, Malagó M, Jalan R, et al. Liver failure after partial hepatic resection: Definition, pathophysiology, risk factors and treatment. *Liver International*. 2008;**28**(6):767-780
- [14] Yagi S, Uemoto S. Small-for-size syndrome in living donor liver transplantation. *Hepatobiliary & Pancreatic Diseases International* [Internet]. 2012;**11**(6):570-576. DOI: 10.1016/S1499-3872(12)60227-6
- [15] Kauffmann R, Fong Y. Post-hepatectomy liver failure. *Hepatobiliary Surgery and Nutrition*. 2014;**3**(5):238-246
- [16] Lafaro K, Buettner S, Maqsood H, Wagner D, Bagante F, Spolverato G, et al. Defining post hepatectomy liver insufficiency: Where do we stand? *Journal of Gastrointestinal Surgery*. 2015;**19**(11):2079-2092
- [17] Ray S, Mehta NN, Golhar A, Nundy S. Post hepatectomy liver

failure—A comprehensive review of current concepts and controversies. *Annals of Medicine and Surgery* [Internet]. 2018;**34**(2222):4-10. DOI: 10.1016/j.amsu.2018.08.012

[18] Dimitroulis D, Tsaparas P, Valsami S, Mantas D, Spartalis E, Markakis C, et al. Indications, limitations and maneuvers to enable extended hepatectomy: Current trends. *World Journal of Gastroenterology*. 2014;**20**(24): 7887-7893

[19] Viebahn CS, Yeoh GCT. What fires prometheus? The link between inflammation and regeneration following chronic liver injury. *International Journal of Biochemistry and Cell Biology*. 2008;**40**(5):855-873

[20] Nanashima A, Abo T, Arai J, Matsumoto H, Kudo T, Nagayasu T. Functional liver reserve parameters predictive for posthepatectomy complications. *The Journal of Surgical Research* [Internet]. 2013;**185**(1):127-135. DOI: 10.1016/j.jss.2013.05.021

[21] Wang Y, Ye F, Ke Q, Wu Q, Yang R, Bu H. Gender-dependent histone deacetylases injury may contribute to differences in liver recovery rates of male and female mice. *Transplantation Proceedings*. 2013;**45**(2):463-473

[22] Michalopoulos GK. Principles of liver regeneration and growth homeostasis. *Comprehensive Physiology*. 2013;**3**(1):485-513

[23] Enkhbold C, Morine Y, Utsunomiya T, Imura S, Ikemoto T, Arakawa Y, et al. Dysfunction of liver regeneration in aged liver after partial hepatectomy. *Journal of Gastroenterology and Hepatology*. 2015;**30**(7):1217-1224

[24] Helling TS. Liver failure following partial hepatectomy. *HPB* [Internet]. 2006;**8**(3):165-174. DOI: 10.1080/13651820510035712

[25] Palmes D, Budny TB, Dietl KH, Herbst H, Stratmann U, Spiegel HU. Detrimental effect of sinusoidal overperfusion after liver resection and partial liver transplantation. *Transplant International*. 2005;**17**(12):862-871

[26] van Mierlo KMC, Schaap FG, Dejong CHC, Olde Damink SWM. Liver resection for cancer: New developments in prediction, prevention and management of postresectional liver failure. *Journal of Hepatology* [Internet]. 2016;**65**(6):1217-1231. DOI: 10.1016/j.jhep.2016.06.006

[27] Lin XJ, Yang J, Chen XB, Zhang M, Xu MQ. The critical value of remnant liver volume-to-body weight ratio to estimate posthepatectomy liver failure in cirrhotic patients. *The Journal of Surgical Research* [Internet]. 2014;**188**(2):489-495. DOI: 10.1016/j.jss.2014.01.023

[28] Guglielmi A, Ruzzenente A, Conci S, Valdegamberi A, Iacono C. How much remnant is enough in liver resection? *Digestive Surgery*. 2012;**29**(1):6-17

[29] Michalopoulos GK. Liver regeneration after partial hepatectomy: Critical analysis of mechanistic dilemmas. *American Journal of Pathology* [Internet]. 2010;**176**(1):2-13. DOI: 10.2353/ajpath.2010.090675

[30] Matsuo T, Yamaguchi S, Mitsui S, Emi A, Shimoda F, Okamura H. Control mechanism of the circadian clock for timing of cell division in vivo. *Science* (80-). 2003;**302**(5643):255-259

[31] Mitchell C, Willenbring H. A reproducible and well-tolerated method for 2/3 partial hepatectomy in mice. *Nature Protocols*. 2008;**3**(7):1167-1170

[32] Tsukamoto I, Kojo S. Effect of glucocorticoid on liver regeneration after partial hepatectomy in the rat. *Gut*. 1989;**30**(3):387-390

- [33] Barbason H, Bouzahzah B, Herens C, Marchandis J, Sulon J, van Cantfort J. Circadian synchronization of liver regeneration in adult rats: the role played by adrenal hormones. *Cell and Tissue Kinetics*. 1989;**22**:451-460. Available from: [papers2://publication/uuid/BF06944C-5B46-4AC2-B2DB-589386E42EE5](https://pubmed.ncbi.nlm.nih.gov/1589386/)
- [34] Holecek M. Nutritional modulation of liver regeneration by carbohydrates, lipids, and amino acids: A review. *Nutrition*. 1999;**15**(10):784-788
- [35] Block GD, Locker J, Bowen WC, Petersen BE, Katyal S, Strom SC, et al. Population expansion, clonal growth, and specific differentiation patterns in primary cultures of hepatocytes induced by HGF/SF, EGF and TGF α in a chemically defined (HGM) medium. *Journal of Cell Biology* [Internet]. 1996;**132**(6):1133-1149. Available from: <http://www.ncbi.nlm.nih.gov/pmc/articles/PMC2120765/pdf/jc13261133.pdf>
- [36] Huang J, Rudnick DA. Elucidating the metabolic regulation of liver regeneration [Internet]. *American Journal of Pathology*. American Society for Investigative Pathology. 2014;**184**:309-321. DOI: 10.1016/j.ajpath.2013.04.034
- [37] Chen H, Lin Y, Sun W, Cai Y, Li H. Liver regeneration is impaired in mice with acute exposure to a very low carbohydrate diet. *Digestive Diseases and Sciences*. 2017;**62**(5):1256-1264
- [38] Ren W, Wang X, Zhang A, Li C, Chen G, Ge X, et al. Selective bowel decontamination improves the survival of 90% hepatectomy in rats. *The Journal of Surgical Research* [Internet]. 2015;**195**(2):454-464. DOI: 10.1016/j.jss.2015.01.024
- [39] Tubbs JT, Kissling GE, Travlos GS, Goulding DR, Clark JA, King-Herbert AP, et al. Effects of buprenorphine, meloxicam, and flunixin meglumine as postoperative analgesia in mice. *Journal of the American Association for Laboratory Animal Science*. 2011;**50**(2):185-191
- [40] Xu Y, Navarro-Alvarez N, Yang C, Markmann JF, Dong J, Yeh H. A reliable scoring system after major liver resection in mice. *The Journal of Surgical Research* [Internet]. 2016;**204**(1):75-82. DOI: 10.1016/j.jss.2016.03.066
- [41] Carrapita J, Abrantes AM, Campelos S, Gonçalves AC, Cardoso D, Sarmiento-Ribeiro AB, et al. Impact of splenic artery ligation after major hepatectomy on liver function, regeneration and viability. *Scientific Reports* [Internet]. 2016;**6**:1-12. DOI: 10.1038/srep34731
- [42] Kim D-S, Ji WB, Han JH, Choi YY, Park H-J, Yu Y-D, et al. Effects of splanchnic vasoconstrictors on liver regeneration and survival after 90% rat hepatectomy. *Annals of Surgical Treatment and Research*. 2018;**94**(3):118
- [43] Kaido T, Mori A, Ogura Y, Hata K, Yoshizawa A, Iida T, et al. Lower limit of the graft-to-recipient weight ratio can be safely reduced to 0.6% in adult-to-adult living donor liver transplantation in combination with portal pressure control. *Transplantation Proceedings* [Internet]. 2011;**43**(6):2391-2393. DOI: 10.1016/j.transproceed.2011.05.037
- [44] Golriz M, Majlesara A, El Sakka S, Ashrafi M, Arwin J, Fard N, et al. Small for size and flow (SFSF) syndrome: An alternative description for posthepatectomy liver failure. *Clinics and Research in Hepatology and Gastroenterology* [Internet]. 2016;**40**(3):267-275. DOI: 10.1016/j.clinre.2015.06.024
- [45] Asencio JM, Vaquero J, Olmedilla L, García Sabrido JL. "Small-for-flow"

syndrome: Shifting the “ size” paradigm.
Medical Hypotheses. 2013;**80**(5):573-577

[46] Demetris AJ, Kelly DM, Eghtesad B, Fontes P, Wallis Marsh J, Tom K, et al. Pathophysiologic observations and histopathologic recognition of the portal hyperperfusion or small-for-size syndrome. The American Journal of Surgical Pathology. 2006;**30**(8):986-993

[47] Kiuchi T, Kasahara M, Uryuhara K, Inomata Y, Uemoto S, Asonuma K, et al. Impact of graft size mismatching on graft prognosis in liver transplantation from living donors. Transplantation. 1999;**67**(2):321-327