

We are IntechOpen, the world's leading publisher of Open Access books Built by scientists, for scientists

6,900

Open access books available

185,000

International authors and editors

200M

Downloads

Our authors are among the

154

Countries delivered to

TOP 1%

most cited scientists

12.2%

Contributors from top 500 universities



WEB OF SCIENCE™

Selection of our books indexed in the Book Citation Index
in Web of Science™ Core Collection (BKCI)

Interested in publishing with us?
Contact book.department@intechopen.com

Numbers displayed above are based on latest data collected.
For more information visit www.intechopen.com



Laparoscopic Rare Abdominal Hernia Treatment

*Emrah Akin, Baris Mantoglu, Fatih Altintoprak
and Necattin Firat*

Abstract

Diaphragm and abdominal wall hernias are rare, and they may be congenital or acquired. Spiegel hernia incidence is between 0.1 and 2%. Morgagni hernia is comprising only 2–3% of all diaphragmatic hernias. Most Spiegel and Morgagni hernias are diagnosed late because of their non-specific symptoms and asymptomatic clinical presentation. The major symptoms are abdominal pain, vomiting, and dyspnea. Computed tomography (CT) shows the hernia sac content, strangulation or incarceration in the content, and detailed anatomical information about surrounding tissue. Surgery is the main treatment option except patients who have severe comorbidity. Spiegel hernia surgery can be performed open or laparoscopic. Intraperitoneal onlay mesh (IPOM), total extraperitoneal procedure (TEP), transabdominal preperitoneal (TAPP) procedure, or partial transabdominal laparoscopic methods are minimal invasive surgery options. In the repair of Morgagni hernia, surgical options may be laparoscopy, laparotomy, thoracotomy, or thoracoscopy.

Keywords: rare abdominal hernias, laparoscopic hernia treatment, Spiegel hernia, Morgagni hernia

1. Spiegel hernia

1.1 Introduction

Spiegel hernia is a rare congenital or acquired abdominal wall hernia [1]. It is between 0.1 and 2% of all abdominal wall hernias and is one of the diseases that a surgeon can face during his professional life with the frequency of not exceeding the number of fingers of a hand. Transverse abdominis aponeurosis in the area between the semilunar line and the lateral sheath of the rectus is called Spiegel's fascia, and from this point preperitoneal fat tissue or intraabdominal organs protruding are defined as Spiegel hernia (SH) [2]. Ninety percent of hernias occur on the transverse line approximately 6 cm above the interspinous line [3]. It has an increasing frequency with age, peaks in the fifth decade, and is more common in women and left side of the abdominal wall [4]. In the diagnosis, the presence of palpable swelling in the left lower quadrant with Valsalva maneuver is sufficient for surgical decision. Clinical suspicion is important in the absence of a palpable mass.

1.2 History

The semilunar line is the medial border of the transverse abdominis muscle in the cranio-caudal extension and was first described by the Belgian anatomist, Adriaan van der Spiegel, in the seventeenth century. Its clinical presence was demonstrated in 1764 by a Belgian anatomist, Josef Klinkosh, and was named after him in honor of Spiegel [5]. The disease, which traditionally underwent open surgical procedures with mesh or non-mesh primarily, has been laparoscopically treated by the first time by Carter and Mites in 1992 [6]. The first laparoscopic extra-abdominal approach was published in 1999 by Moreno-Egea [7]. Nowadays, laparoscopy with intraperitoneal onlay mesh, transabdominal preperitoneal approach, total extraperitoneal approach, and partial extraperitoneal treatment options is applied.

1.3 General information

1.3.1 Physiopathology

Musculo-aponeurosis of the transversus abdominis extends in the cranial region from the costa to the inguinal region where the tendon conjugate ends in the caudal direction and its medial edge is called linea semilunaris. The lateral sheath of the rectus muscle also extends from the costal margin to the pubis. The Spiegel fascia is located between these two lines and includes fused transverse abdominis aponeurosis and internal oblique muscle [8]. The arcuate or semicircular line defines the boundary of the posterior sheath of the rectus, and as classical information below this line, three muscular aponeuroses proceed over the rectus sheath. Spiegel's hernia is a defect that occurs in the Spiegel's fascia where transverse abdominis and internal oblique fascia layers have lost their integrity but the external oblique remains intact (**Figure 1**). This information explains why these types of hernias are separated from incisional hernias, the difficulty of detecting them at the physical examination, and the fact that they cannot be detected without opening the external oblique layer during surgery [9].

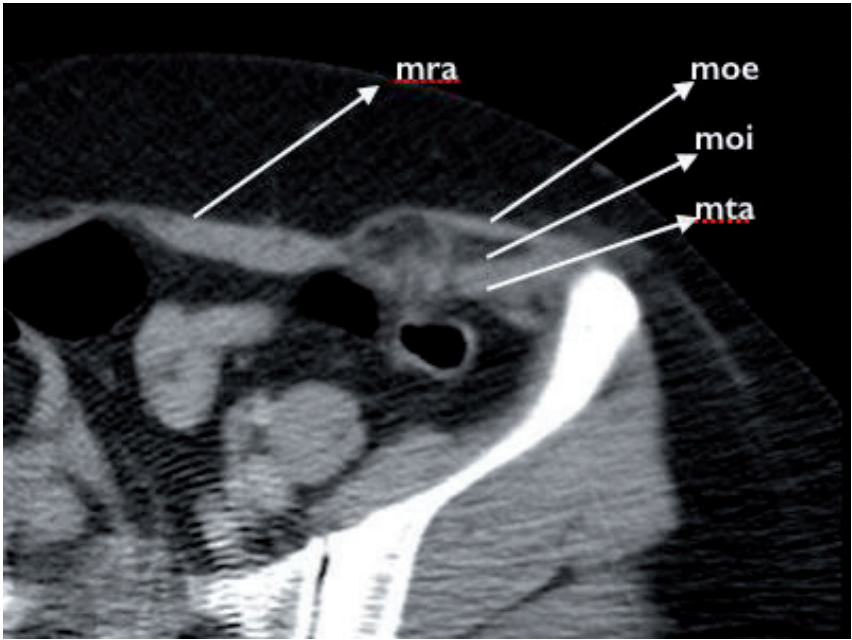


Figure 1. Spiegel hernia at computerized tomography which consists only two layers of the abdomen wall. moe-musculus obliq externus, moi-musculus obliq internus, mta-musculus transversus abdominis, mra-musculus rectus abdominis.

There are various theories that this type of abdominal hernias consists of two layers, not all three layers of the abdominal wall. Smaller perforating vascular structures were thought to weaken this anatomy but could not be confirmed by observations. It was also thought that almost a parallel route of internal oblique muscle and transversus abdominis muscle may be another reason. In addition, it has been shown that the frequency of SH below the arcuate line is not a reason for the weakness of the abdominal wall in a structure where all three muscle layers maintain their integrity [1]. The theory has lost its validity with a series of 27 cases in which the patients had herniation above the arcuate line. The disease can be seen congenitally in infants and children as a result of the defect of the mesenchymal layers and is usually associated with increased incidence of cryptorchidism in this age group [10]. On the other hand, the disease is mostly acquired in adults. Pathophysiologically, different series have shown that the disease begins with protruding extraperitoneal fat tissue due to small divisions between the fascia layers. Over time, this small interstitial hernia develops and becomes palpable when it forms the peritoneal sac. This natural course explains the increase in the frequency of the disease with age. Probably hernia presents at any time; reasons that increase intraabdominal pressure are chronic obstructive pulmonary disease (COPD), obesity, chronic constipation, pregnancy, and abnormalities that weaken the abdominal wall including connective tissue diseases and aging which eventually expands the hernia and become symptomatic [11].

1.3.2 Symptomatology and clinical presentation

Patients usually present with lower abdominal pain and palpable swelling or both. Young patients may have only a small hernia defect with pain, or some may experience swelling with deep palpation. If a palpable mass is present, it may be reduced or not reduced [12]. Typically, the fascia defect is smaller than the sac, and irreducibility is more common, as it is described as a T- or fungus-shaped dead space between internal oblique and external oblique. This phenomenon also explains the tendency to emergency clinical presentation. Obstruction and strangulation rates have been reported between 10 and 29% in different studies and are not uncommon [13, 14].

1.3.3 Diagnosis

The presence of a palpable mass at the lateral edge of the rectus with increased intraabdominal pressure is sufficient for the diagnosis and surgical decision of SH if there is no previous surgical history. However, in the presence of SH, external oblique fascia or thick fat layer in obese patients may prevent the swelling in physical examination, and at this point clinical suspicion is important in diagnosis. Ultrasonography (USG) as an advanced radiological evaluation may also indicate the size of the fascia defect but is an individual-dependent method. Computed tomography or magnetic resonance imaging (MRI) will be more useful in the evaluation of the hernia content, its relationship with the layers of the abdominal wall, and thus in the selection of the surgical method, but sometimes these tests may also be negative in the absence of palpable swelling. Transperitoneal laparoscopy is useful in both diagnosis and treatment, but it can detect only those with peritoneal sac. Laparoscopic total extraperitoneal method may be appropriate for the detection of hernias containing extraperitoneal fat tissue, which is the most common clinical presentation especially in patients under the age of 50 years, but it is not easy to detect the hernias above the arcuate line for this method, and it is difficult to make TEP decision for each patient with abdominal pain in the lower quadrant [15].

If there is a strong enough suspicion about a small interstitial SH, the diagnosis can be made by open surgery. For asymptomatic patients and those with significant medical comorbidity, surgery is the only effective treatment option because of the high risk of acute clinical presentation.

1.3.4 Surgical indication

The choice of open or laparoscopic surgery is related to the surgeon's experience, the patient's BMI, and the stage of the hernia, according to this:

Stage I: Relatively young patients with a fascia defect below 2 cm. They typically present with well-localized pain and absence of palpable mass. Open surgical method is appropriate in these patients. At surgery, the surgeon may not be able to detect a hernia sac, but exploration should be completed by opening the external oblique fascia and examining all musculofascial layers. Primary repair is often sufficient. In a study of 70 cases published by Larsen and Failey, recurrence was reported as 4.3% in patients treated primarily with open technique [16]. If mesh is to be applied, it can be extraperitoneal or placed in the retromuscular space medially and surrounded by deep planes of the external oblique muscle laterally. In this technique, the frequency of mesh reaction, wound infection, and recurrence is higher.

Stage II: Patients with a fascia defect between 2 and 5 cm and a peritoneal hernia sac. In these patients, the presence of a hernia sac can be palpable or not therewithal hernia contents can be reduced or not. These patients can be operated open or laparoscopically. Small defects can only be closed with laparoscopic primary suture. For larger defects, IPOM, TEP, TAPP, and partial extraperitoneal laparoscopic repair options are available. TEP and TAPP are the techniques of detachment of the peritoneum and repairing of the defect of working extraperitoneal or transperitoneal as similar to inguinal hernia surgery. A MEDLINE search of the published literature shown that 232 cases in which the results of SH patients operated between 1997 and 2017 were evaluated; the most common choice was IPOM 32%, TEP 30%, and TAPP 22%. In laparoscopic mesh repair, onlay mesh, mesh extended to the retrorectus cavity, mesh repair placed in the extraperitoneal space were defined at the largest case series of 107 cases of laparoscopic repair which was published by Weber et al. [17]. The risk of neurovascular injury in the posterolateral abdominal wall due to the tacker usage for abdominal wall fixation of these meshes is reported to be higher in IPOM and TAPP operations.

Stage III: It is relatively old patients whose facial defects are superior to 5 cm; the integrity of the abdominal wall is mostly deteriorated. The hernia is easily palpable and deductible. In these patients, open surgery is recommended because abdominal wall reconstructions and abdominoplasty may be required. Component separation techniques are not recommended when the hernia is located laterally, but peritoneal flap hernioplasty may be useful. In a series of 22 cases published by Moreno and Egea comparing the results of laparoscopic and open surgery, morbidity and length of stay were significantly higher in the open group, with less pain, less wound infection, and better cosmetic results in the laparoscopic group [7]. In addition, concurrent surgery and wide visualization can be considered as the advantage of laparoscopic approach.

We prefer to perform IPOM technique in our clinic, and herein we will discuss about this technique here. In IPOM, the peritoneal flap is not required, and the surgeon is more familiar with the intraabdominal approach and the advantages of the trocar positioning. However, when selecting mesh type, the surgeon should be careful because of contact with the visceral organs and possible future intraabdominal adhesions. However, to date, no case series of mesh complications have been

reported. One patient recurrence has been reported by Kelly et al. after a 40-case series in which laparoscopic intervention was performed [18].

1.4 Intraperitoneal onlay mesh technique (IPOM)

1.4.1 Operating room layout

The patient is placed in the supine position on the operating table with her legs closed. The laparoscopic tower is placed on the right or left side of the patient. The patient's arm opposite the hernia defect is closed. The surgical team settles on the operating table in the opposite direction of the hernia defect. Nasogastric and Foley catheters are placed.

1.4.2 Surgical instruments

- Standard laparoscopy equipment consisting of a camera, monitor, light, and insufflator.
- 10 mm diameter and 30° angle camera.
- 3 trocar, one 10 mm, 25 mm in diameter.
- Endo Instruments (Atraumatic clamp, dissector, scissors, hook, portegue, aspirator).
- Endo Close®.
- Sealing device with a diameter of –5 mm.
- Composite or dual-coated special-shaped patch according to the size of hernia defect.
- Fixing material for mesh fixation and peritoneal closure (mechanical punch, tissue glue, or nonabsorbable suture material).

1.4.3 Port location selection and surgical technique

After the patient is stained and covered under sterile conditions under general anesthesia, the abdomen is entered through the right or left upper quadrant distant from the hernia defect with the Hasson technique. After placing the 10 mm trocar and exploring the abdomen, two more 5 mm trocar are inserted under direct vision with transillumination from the farthest point to the hernia defect, making both working ports 90° (**Figure 2**).

The size, localization, and the organs of the hernia defect are evaluated by intraabdominal exploration. The hernia content is evaluated for strangulation or incarceration. After hernia contents are reduced to the abdomen, adhesions are separated by sharp and blunt dissections with energy devices. Even if the hernia sac is visible, it does not need to be removed. Henceforth defect repair is initiated (**Figure 3**).

After suturing the cranial and caudal edges of the mesh with polypropylene to composite or dual mesh, which is suitable for hernia sac size, than introduced through the abdomen from 10 mm port. With the help of Endo Close®, which is inserted through the 2 mm incisions from the outside of the abdomen at the points

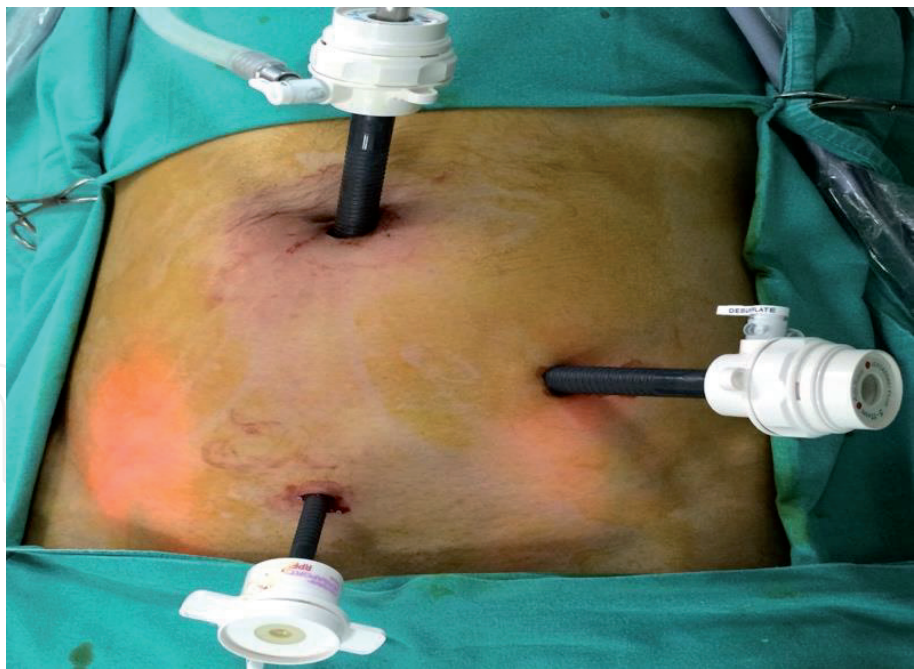

Figure 2.
Trocar placement for Spiegel hernia.

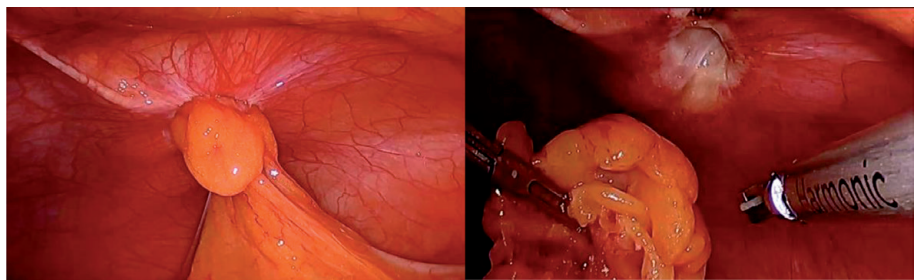


Figure 3.
Transabdominal perspective to Spiegel hernia and reduction hernia component.

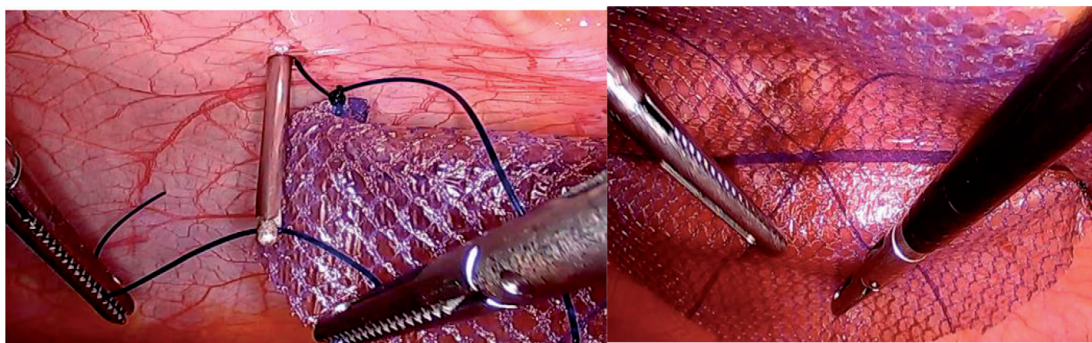


Figure 4.
Suture catching and replacement of dual mesh.

where the mesh will be hung from the upper and lower edges of the hernia defect, polypropylene sutures are caught one by one and pulled out of the abdomen; thus the mesh is fixed to the abdominal wall by its cranial and caudal ends. Mesh can be fixed to the abdominal wall by double-row stapling technique, with cyanoacrylate or with the help of various types of adhesives. When using staples, it is important to pay attention on neurovascular injuries to the abdominal wall.

Drains are not recommended in the abdomen, trocar is pulled under direct vision, and the abdomen is desufflated. The patient tolerated oral feeding on the same day of the surgery and discharged the on the next day (**Figure 4**).

2. Morgagni hernia

2.1 Introduction

Diaphragmatic hernias are among the rare abdominal hernias. The diaphragm may be called the roof of the abdomen due to its localization. The diaphragm connects the natural foramen, including the aorta, esophagus, inferior vena cava, and abdominal and thoracic spaces. Congenital defects of the diaphragm include posteromedial hernia, anteromedial hernia, central tendon defect, and diaphragm eventration [19]. Anteromedial diaphragmatic hernias constitute 2–3% of diaphragmatic hernias [20]. Ninety-one percent of these hernias can be located on the right side of the sternum and 5% on the left side of the sternum [21]. Diaphragmatic hernias can be congenital or post-traumatic.

2.2 History

Anteromedial diaphragmatic hernias were first recognized by an Italian anatomist and pathologist, Giovanni Batista Morgagni, in 1769 during an autopsy and were described in an article by the author entitled “The Sets and Causes of Diseases, Investigated by Anatomy” [22]. Since then, the disease has been called with Morgagni’s name. In the pathophysiology of the disease, it is thought to be that there is a fusion defect in the midline of the diaphragm in the embryological period. Only 5% of Morgagni hernias are treated in adulthood, because most of these cases become symptomatic and treated in childhood. In the literature, different surgical approaches to the treatment of Morgagni hernia have been described and are divided into two types as transthoracic (median sternotomy, thoracotomy, or thoracoscopic assisted) and transabdominal (laparotomy or laparoscopic) [23]. There is still no consensus as to which is the best technique. However, since Kuster and colleagues reported their first laparoscopic repair in 1992, minimally invasive techniques have become the gold standard for diaphragmatic hernia repair due to the low recurrence rates, short postoperative hospital stay, and near-perfect cosmetic results [24].

2.3 General information

2.3.1 Physiopathology

Diagnosis of Morgagni hernia may rarely be delayed until adolescence and adulthood. This may be due to the asymptomatic course in some patients or the presentation of minimal atypical respiratory symptoms. The diagnosis is made after these minimal symptoms, which are generally atypical in elderly patients, are aggravated due to chronic constipation, chronic cough, pregnancy, obesity, or trauma.

2.3.2 Symptomatology and clinical presentation

The content of hernia is frequently omentum and transverse colon. Rarely, the small intestines and stomach can also be detected within the hernia sac.

Because hernia defect grows over time and there is a possibility of strangulation or incarceration of the organs it contains, surgical treatment is indicated when Morgagni hernia is diagnosed [25].

2.3.3 Diagnosis

The gold standard for diagnosis is multislice abdominal computed tomography [26]. Abdominal CT examination, besides providing advanced anatomical information, enables us to determine the size of the hernia defect and which organs are formed or the presence of strangulation or incarceration. All this information is very important for preoperative planning.

2.4 Surgical indication

In a study in which Young et al. evaluated the results of 43 patients retrospectively regarding the choice of surgical technique, laparoscopy, laparotomy, and thoracotomy were found to have similar complication and recurrence rates [27]. In this study, 23% of the patients were treated laparoscopically and have shorter hospital stay than other techniques which was evaluated as the advantage of laparoscopy. In the repair of hernia defect, primary closure or mesh repair is available. The primary closure method can be performed technically intracorporeal or transfacial extracorporeal. Nonabsorbable 00 sutures are preferred for primary repair. In the transfacial extracorporeal technique, Endo Close® is inserted into the abdomen through mini incisions (described by Yamamoto) [28], and the sutures that were previously sent into the abdomen are held one by one and pulled out of the abdomen and ligated to the hernia defect. The sutures are passed one by one 1 or 2 cm apart and are thrown to cover the cranial and caudal borders of the hernia defect. When sutures are hung outside the abdomen at the same time, it is seen that the hernia defect is closed. Square patches made of prolene mesh can be placed between the sutures so that the sutures do not interrupt the peritoneum and diaphragm.

2.4.1 Operating room

The patient is taken to the operating table in the supine position with his legs open. 45° reverse Trendelenburg position is given. The laparoscopic tower is placed on the patient's right or left bedside (**Figure 5**).

2.4.2 Surgical instruments

- Standard laparoscopy equipment consisting of camera, monitor, light, and insufflator (**Figure 6**).
- 10 mm diameter and 30° angle camera.
- Three trocar, one 10 mm, two 5 mm in diameter.
- Veress needle.
- Endo Instruments (Atraumatic clamp, dissector, scissors, hook, portegue, aspirator).
- Endo Close® sealing device with a diameter of –5 mm.

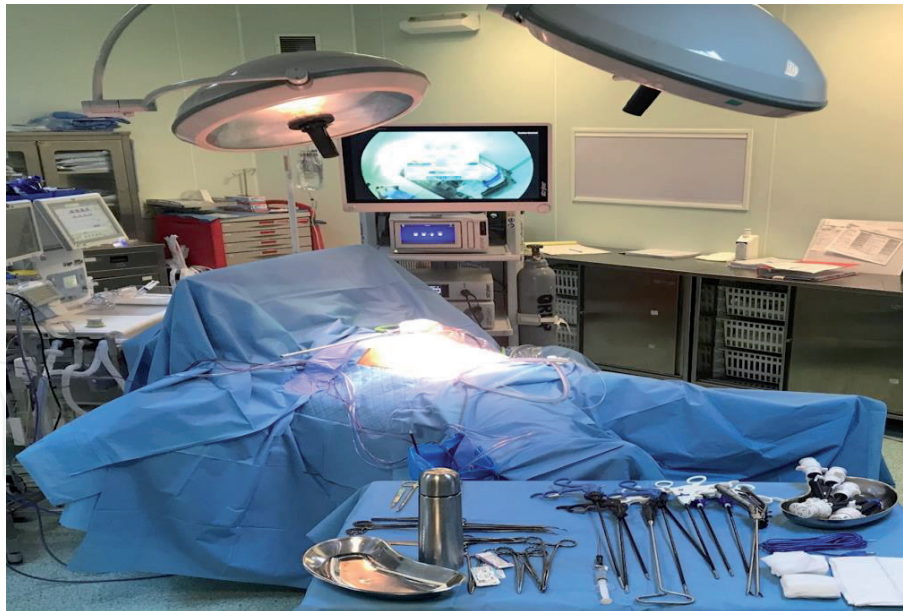


Figure 5.
Operating room at a Morgagni hernia operation.

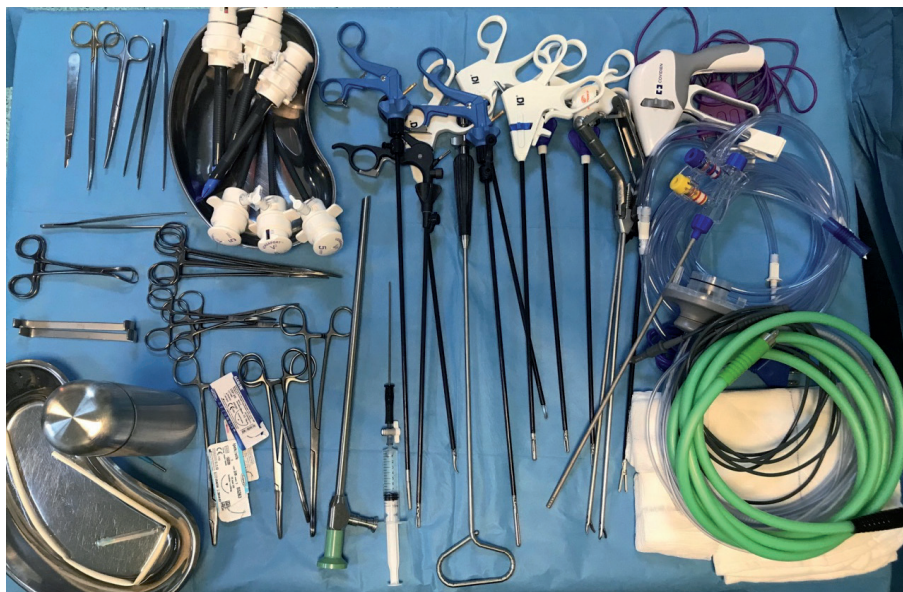

Figure 6.
Conventional laparoscopic surgical instruments.

- 20 x 30 cm composite or dual-coated special-shaped patch.
- Fixing material for mesh fixation and peritoneal closure (mechanical stapler, tissue glue, or nonabsorbable suture material).

2.4.3 Port placement and surgical technique

Under general anesthesia, the patient is stained and covered under sterile conditions, and entered into the abdomen with a left lateralized incision at a distance of 5 cm to umbilicus with the Hasson technique. After placing a 10 mm trocar and exploring the abdomen, one more 10 mm trocar and one more 5 mm trocars are inserted through the left and right midclavicular line under direct vision (**Figure 7**).

After exploration of the abdomen and the presence of concomitant hiatal hernia, the size of the hernia defect, its localization, and the organs it contains are

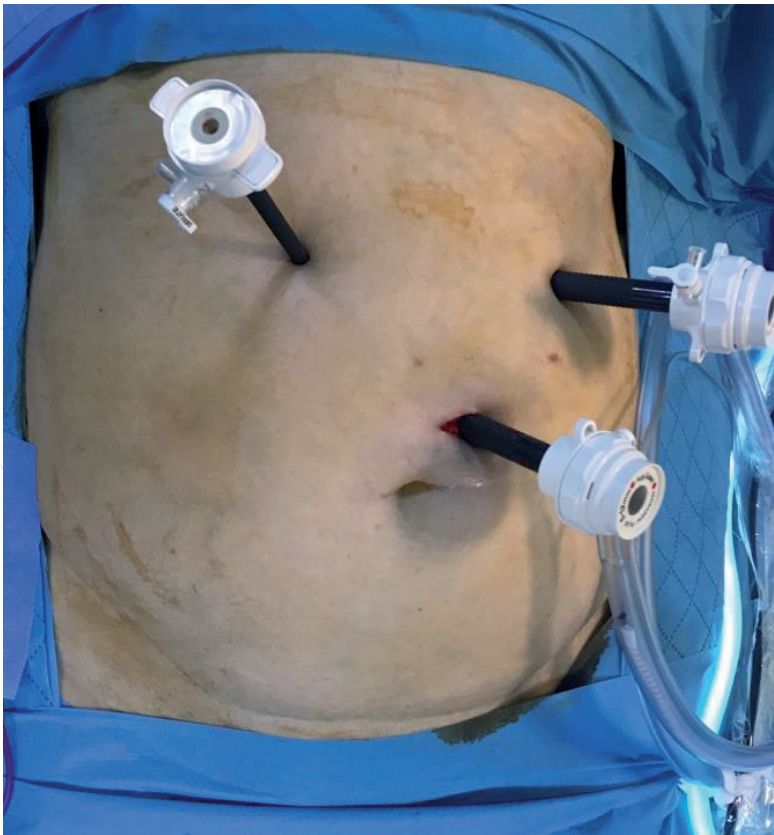


Figure 7.
Trocar placement for Morgagni hernia.

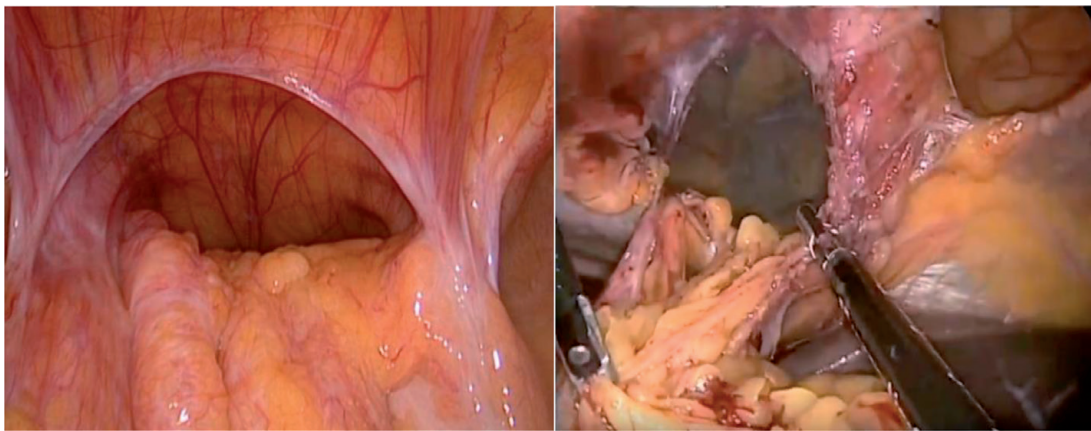


Figure 8.
A huge right-sided Morgagni hernia and reduction of hernia.

evaluated. After the reduction of the hernia contents to the abdomen, defect repair is started (**Figure 8**). As shown by Kuster et al., hernia sac dissection is not recommended due to the possible complications such as pneumothorax, hemothorax, and pulmonary effusion [29].

The primary repair option can be applied intracorporeally or extracorporeally. In the intracorporeal technique, the suture is applied superficially through the tendons and fibers of the diaphragm, with nonabsorbable suture material and with a separate technique, to cover the entire defect. In the extracorporeal technique, the sutures are applied by tying the nonabsorbable sutures that have been introduced through the abdomen with the help of Endo Close® by pulling them out of the abdomen through millimeter incisions from the abdominal wall (**Figure 9**).

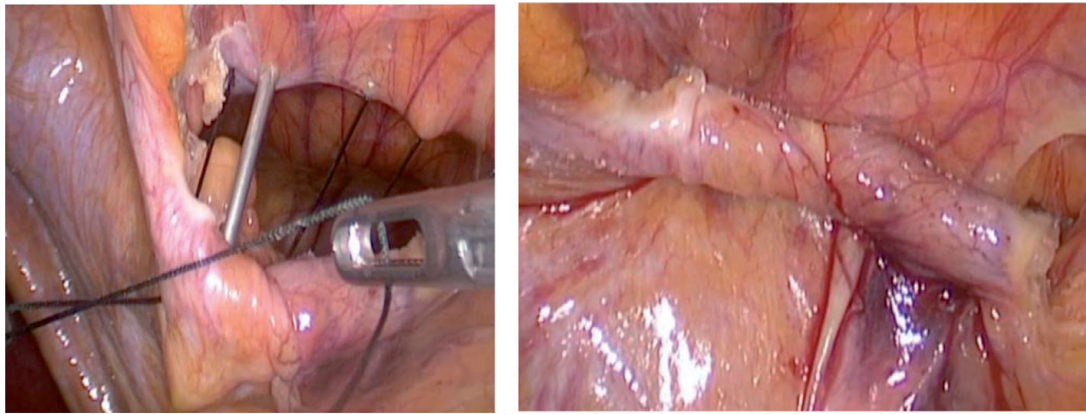


Figure 9.
Intracorporeal suture technique using suture catcher.

Both techniques should ensure that the defect is completely covered. Recurrence was not reported in patients who underwent thoracotomy and laparotomy including 36 cases performed by Aghajanzadeh et al. [30].

2.4.4 Use of mesh

Although the use of mesh is a standard practice in the repair of many hernias, the choice of mesh usage in Morgagni hernia may vary. Postoperative fistula development and migration to intrathoracic or intraabdominal cavity limit the use of composite mesh. However, it is recommended to use mesh in cases where the defect cannot be closed with primary suture technique due to the weak diaphragm or large defect (20–30 cm) [31–33]. In addition, Abraham et al. performed a series of 20 diseases in 6 patients with mesh repair and 4 patients with both mesh and primary repair, and no recurrence was reported at 20-month follow-up [34]. Similarly, in a series of three cases by Godazandeh et al., a polyvinylidene fluoride-coated patch was used, and no recurrence was reported at 18 months of follow-up [35]. Another option to consider when mesh repair is preferred is fixation of the mesh. It should be kept in mind that lung, heart, and diaphragmatic

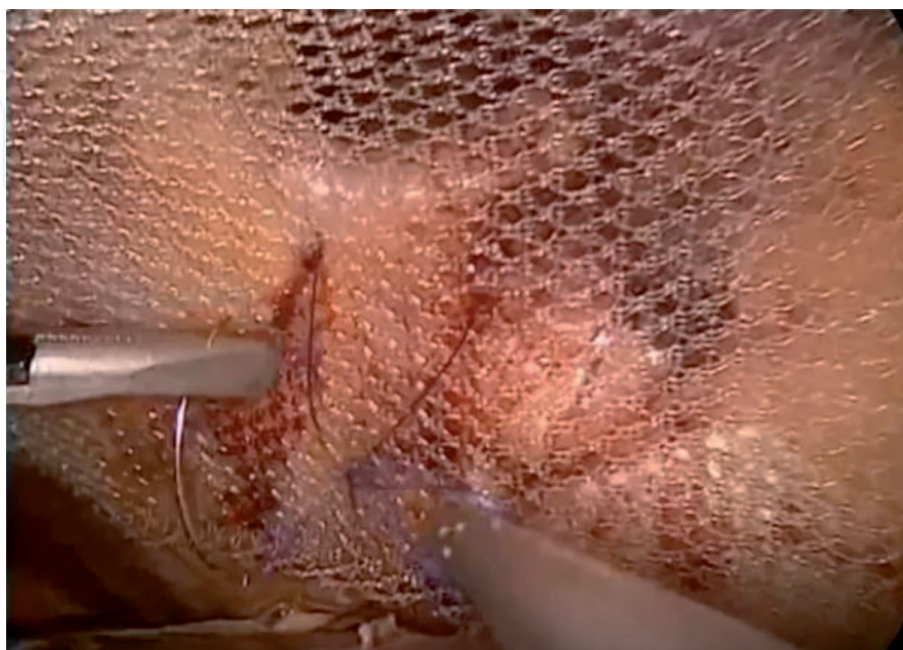


Figure 10.
Intracorporeal primer suture technique for mesh fixing with portegue.

injuries secondary to possible intrathoracic adhesions can be caused during fixation (Köckerling et al.). Köckerling et al. emphasized that the use of tacker should be avoided in mesh fixation as it can cause fatal complications [36]. When the pneumoperitoneum is evacuated, it is suggested that the fixation may not be applied with the help of the volume effect of the liver, but if it will be applied, it is recommended to fix the diaphragm with superficial sutures by intracorporeal or extracorporeal technique (**Figure 10**).

Conflict of interest

The authors declare no conflict of interest.

Author details

Emrah Akin¹, Baris Mantoglu¹, Fatih Altintoprak^{2*} and Necattin Firat¹

1 Department of General Surgery, Sakarya Research and Educational Hospital, Adapazari, Sakarya, Turkey

2 Faculty of Medicine, Department of General Surgery, Sakarya University, Adapazari, Sakarya, Turkey

*Address all correspondence to: fatihaltintoprak@yahoo.com

IntechOpen

© 2019 The Author(s). Licensee IntechOpen. This chapter is distributed under the terms of the Creative Commons Attribution License (<http://creativecommons.org/licenses/by/3.0>), which permits unrestricted use, distribution, and reproduction in any medium, provided the original work is properly cited. 

References

- [1] Mittal T, Kumar V, Khuller R, et al. Diagnosis and management of Spigelian hernia: A review of the literature and our experience. *Journal of Minimal Access Surgery*. 2008;**4**:95-98
- [2] Spangen L. Spigelian hernia. *World Journal of Surgery*. 1989;**13**:573-580
- [3] Skandalakis PN, Zoras O, Skandalakis JE, et al. Spigelian hernia: Surgical anatomy, embryology, and technique of repair. *The American Surgeon*. 2006;**72**:42-48
- [4] Ruiz de la Hermosa A, Amunategui Prats I, Machado Liendo P, Nevarez Noboa F, Muñoz Calero A. Spigelian hernia. Personal experience and review of the literature. *Revista Española de Enfermedades Digestivas*. 2010;**102**:583-586
- [5] Takayama S, Imafuji H, Funahashi H, Takeyama H. Laparoscopic Spigelian and inguinal hernia repair with the Kugel patch. *Surgical Laparoscopy, Endoscopy and Percutaneous Techniques*. 2010;**20**:e76-e78
- [6] Carter JE, Mizes C. Laparoscopic diagnosis and repair of Spigelian hernia: Report of a case and technique. *American Journal of Obstetrics and Gynecology*. 1992;**167**:77-78
- [7] Moreno-Egea A, Carrasco L, Girela E, Martín JG, Aguayo JL, Canteras M. Open vs laparoscopic repair of Spigelian hernia: A prospective randomized trial. *Archives of Surgery*. 2002;**137**:1266-1268
- [8] Skandalakis PN, Zoras O, Skandalakis JE, Mirilas P. Spigelian hernia: Surgical anatomy, embryology, and technique of repair. *The American Surgeon*. 2006;**72**:42-48
- [9] Read RC. Observations on the etiology of Spigelian hernia. *Annals of Surgery*. 1960;**152**:1004-1009
- [10] Jones BC, Hutson JM. The syndrome of Spigelian hernia and cryptorchidism: A review of the paediatric literature. *Journal of Paediatric Surgery*. 2015;**50**:325-330
- [11] Zimmerman LM, Anson BJ, Morgan EH, McVay CB. Ventral hernia due to normal banding of the abdominal muscles. *Surgery*. 1944;**78**:535
- [12] Law TT, Ng KK, Ng L, et al. Elective laparoscopic totally extraperitoneal repair for Spigelian hernia: A case series of four patients. *Asian Journal of Endoscopic Surgery*. 2018;**11**(3):244-247. DOI: 10.1111/ases.12454
- [13] River LP. Spigelian hernia. *The Annals of Surgery*. 1942;**116**:405
- [14] Zimmerman LM, Anson BJ, Morgan EH, McVay CB. Ventral Hernia due to normal banding of the abdominal muscles. *Surgical Gynaecology of Obstetric*. 1944;**78**:535
- [15] Webber V, Low C, Skipworth RJE, et al. Contemporary thoughts on the management of Spigelian hernia. *Hernia*. 2017;**21**(3):355-361. DOI: 10.1007/s10029-017
- [16] Larson DW, Farley DR. Spigelian hernia: Repair and out- come for 81 patients. *World Journal of Surgery*. 2002;**26**:1277-1281
- [17] Rankin A, Kostusiak M, Sokker A. Spigelian hernia: Case series and review of the literature. *Visceral Medicine*. 2019;**35**(2):133-136. DOI: 10.1159/000494280
- [18] Kelly ME, Courtney D, McDermott FD, Heeney A, Maguire D, Geoghegan JG, et al. Laparoscopic Spigelian hernia repair: A series of 40 patients. *Surgical Laparoscopy, Endoscopy and Percutaneous Techniques*. 2015;**25**:e86-e89

- [19] Soldo I, Baca I, Sever M, et al. Laparoscopic treatment of Morgagni hernia: Report of three cases. *Acta Clinica Croatica*. 2017;**56**:318-322. DOI: 10.20471/acc.2017.56.0216
- [20] Harrington SW. Clinical manifestations and surgical treatment of congenital types of diaphragmatic hernia. *The Review of Gastroenterology*. 1951;**18**(4):243-256
- [21] Horton JD, Haffmann LJ, Hetz SP, et al. Presentation and management of Morgagni hernias in adults: A review of 298 cases. *Surgical Endoscopy*. 2008;**22**:1413-1420. DOI: 10.1007/s00464-008-9754-x
- [22] Morgagni GB. *The Seats and Causes of Diseases Investigated by Anatomy*. Vol. 3. London, England: Millar & Caddell; 1769. p. 205
- [23] Hassan A, Alabdrabalmaer M, Alealiuri M, et al. Incidental Morgagni hernia found during laparoscopic repair of hiatal hernia: Case report and review of literature. *International Journal of Surgery Case Reports*. 2019;**57**:97-101
- [24] Kuster GG, Kline LE, Garzo G. Diaphragmatic hernia through the foramen of Morgagni: Laparoscopic repair case report. *Journal of Laparoendoscopic Surgery*. 1992;**2**:93-100
- [25] Comer JP, Clagett OT. Surgical treatment of hernia of the foramen of Morgagni. *The Journal of Thoracic and Cardiovascular Surgery*. 1966;**52**:461-468
- [26] Li S, Liu X, Shen Y, et al. Laparoscopic repair of Morgagni hernia by artificial precardium patch in an adult obese patient. *Journal of Thoracic Disease*. 2015;**7**:754-757
- [27] Young CM, Saddoughi SA, Aho JM, et al. Comparison of laparoscopic versus open surgical management of Morgagni hernia. *The Annals of Thoracic Surgery*. 2019;**107**(1):257-261
- [28] Yamamoto Y, Tanabe K, Hotta R, et al. Laparoscopic extra-abdominal suturing technique for the repair of Larrey's diaphragmatic hernia using the port closure needle (Endo Close®): A case report. *International Journal of Surgery Case Reports*. 2016;**28**:34-37
- [29] Kuster GG, Kline LE, Garzo G. Diaphragmatic hernia through the foramen Morgagni: Laparoscopic repair case report. *Journal of Laparoendoscopic Surgery*. 1992;**2**:93-100
- [30] Aghajanzadeh M, Khadem S, Khajeh JS, et al. Clinical presentation and operative repair of Morgagni hernia. *Interactive CardioVascular and Thoracic Surgery*. 2012;**15**(4):608-611. DOI: 10.1093/icuts/iu5203
- [31] Mariceu D, Loubani M, O'Grady H. Late presentation of a large Morgagni hernia in an adult. *BMJ Case Reports*. 2014;**2014**. DOI: 10.1136/bcr.2013-202440
- [32] Schiergens JS, Koch JG, Khalil PN, et al. Right-sided diaphragmatic rupture after repair of a large Morgagni hernia. *Hernia*. 2015;**19**(4):671-675. PMID: 26405726
- [33] Huston JM, King H, Maresh A, et al. Hernia of Morgagni: A case report. *The Journal of Thoracic and Cardiovascular Surgery*. 2008;**135**(1):212-213. DOI: 10.1016/j.jtcus.2007.09.040
- [34] Abraham V, Myla Y, Verghene S, et al. Morgagni-Larrey hernia. A review of 20 cases. *The Indian Journal of Surgery*. 2012;**74**(5):391-395. DOI: 10.1007/s12262-012-0431-x
- [35] Godazandeh G, Mokhtari-Eshieve F. Laparoscopic repair

of Morgagni hernia: Three case
presentation and the literature. Case
Reports in Surgery. 2016; **2016**:42268539.
DOI: 10.1155/2016/4268539

[36] Köckerling F, Schug-Pass C,
Bittner R. A word of caution: Never
use tacks for mesh fixation to the
diaphragm! Surgical Endoscopy.
2018; **32**(7):3295-3302