

We are IntechOpen, the world's leading publisher of Open Access books Built by scientists, for scientists

6,900

Open access books available

185,000

International authors and editors

200M

Downloads

Our authors are among the

154

Countries delivered to

TOP 1%

most cited scientists

12.2%

Contributors from top 500 universities



WEB OF SCIENCE™

Selection of our books indexed in the Book Citation Index
in Web of Science™ Core Collection (BKCI)

Interested in publishing with us?
Contact book.department@intechopen.com

Numbers displayed above are based on latest data collected.
For more information visit www.intechopen.com



Intraocular Forced Convection Mechanism Defect as Probable Cause of Normal-Tension Glaucoma

Humberto D. Silva, Eduardo D. Silva, Maria Tamires D. Silva, Cristiana P. Dória and Cristiane P. Dória

Abstract

This paper describes several pathologies associated with pathological movements that can cause physical effort on the optic nerve and damage to vision. The accumulation of intraocular metabolic residues increases ocular globe mass and can change its position in the orbit, as well as increase the cornea and crystalline, accommodation resistance, in addition to being able to increase the aqueous humor output resistance. A series of discreet pathologies may result in optic nerve impairment: cyclotorsion and saccadic movement, position in the orbit, and increased intraocular pressure. The cyclotorsion movements can be stimulated by the superior visual field restriction, due to the metabolic residue accumulation in the light transmission regions of this visual field, preventing correct fusion of the images.

Keywords: binocular motion physiology, refraction error, ocular hypertension, retinal diseases, cataract, saccadic eye movements, photosensitive epilepsy, headache, anterior uveitis, cyclotorsion

1. Introduction

To recover a visual deficiency, the first author, who will be called the patient, began his research in 1996. The patient had no cataract, but had had eyelid ptosis in both eyes for over 10 years. He was wearing corrective lenses NV, OD +0.25 and OS +0.75, and had visual acuity OD 6/10 and OS 9/10 without corrective lenses when the first symptoms of presbyopia appeared. Thus, the patient was stimulated to look for a solution, since, besides hating the use of corrective lenses, he suffered from vision on the way home after using a computer for 4 hours in a row; by the time he arrived home, however, his vision was recovered. The patient assumed that this visual variation was associated to the degradation of the oculomotor movement. The strengthening of the oculomotor muscles was expected to control the quality of the visualized image. Exercises alternately focusing on near and far objects, called here the work, however, were interrupted due to recurrence of anterior uveitis in the left eye because of an unknown cause, 2 years after the second crisis. In this crisis, the patient delayed seeking professional help, and his intraocular pressure

reached 40 mmHg. Many other crises have occurred. The patient was able to consult with an ophthalmologist before each uveitis crisis, when he felt a crisis coming on with pain in the left eye upper nasal position, perceived by pressing the eye with the eyelid closed. As the specialist consulted did not treat the uveitis as such, but only the associated pain, the patient began to use a drop of uveitis medicine one time in a day, and sometimes the next day, in order not to prejudice his health. In 2000, after working toward relaxation of the oculomotor musculature, the patient returned to the exercises. Around 5 years later, the patient began a search for more information in the literature, after visual perception of the light colors as lighter, and the dark, darker. This is a sign of a significant increase in intraocular transparency.

From 2009, the patient formed a study team, with the objective of gaining new knowledge and discussing the symptoms. Thus, in 2010, the works, initially empirical, passed to scientific form, with participation, in Paris, in the scientific conferences, sixth DSL and fourth ACE-X, with their respective publications [1, 2]. In 2011, authorized by the Universidade Federal de Pernambuco (UFPE) (Federal University of Pernambuco), the research group “Mass transfer in flexible porous medium” was created in the Conselho Nacional de Desenvolvimento Científico e Tecnológico (CNPq) (National Council for Scientific and Technological Development). The CNPq is an agency of the Ministério da Ciência, Tecnologia, Inovações e Comunicações (Ministry of Science, Technology, Innovation and Communications), of the Federal Government of Brazil. Physically, a flexible porous medium may be compared to a cleaning sponge but also serves as a model for demonstrating mass transfer movement by forced convection into the cornea, the lens, the trabecular meshwork, the retina, as well as in the muscles.

Currently the patient uses corrective lenses DV, OD $-1.50 -1.25 \times 85$ and OS $-2.75 -1.00 \times 85$, and presents visual acuity DV 20/400 OD and OD 20/400 and with corrective lenses 20/50 OU. In [3] it is shown that the prescribed corrective lens are not important for treatment evaluation of the elimination of intraocular metabolic residues.

This paper shows how ocular pathologies can physically affect the optic nerve, as it is known that some ocular pathologies are acquired as a result of an accumulation of dehydrated metabolic residues because of a deficiency in the intraocular mass transfer by forced convection [1–11]. The treatment of these pathologies is based on recovery of the intraocular metabolic residue by rehydration and drainage processes.

2. Nomenclature, function, and analysis

Visual field: Visual spatial array produces or reflects the visual rays of the image transmitted to the brain.

Right visual field (RVF): Visual spatial array that produces or reflects the visual rays of the image transmitted to the brain's left hemisphere.

Left visual field (LVF): Visual spatial array that produces or reflects the visual rays of the image transmitted to the brain's right hemisphere.

Central fixation point (P): The visual field point that is projected into the fovea centralis in both eyes.

Binocular visual field: The space region producing the projection visual rays image in the temporal retina.

Peripheral visual field: The space region producing the projection visual rays image in the nasal retina.

Visual axis: Imaginary straight line passing through the central fixation point and the fovea centralis or intersection of visual plane with vertical meridian plane.

Visual plane: Defined by the two visual axes.

Horizontal meridian plane: The ocular bulb intersection plane, in the horizontal meridian perimeter line.

Vertical meridian plane: The plane of intersection of the ocular bulb, in the perimeter line vertical meridian.

Rectus muscles: These maintain the central fixation point projection in the fovea centralis.

Superior oblique muscle: This controls the corneal accommodation to adjust the projected image on the nasal fovea horizontal meridian perimeter line to the image projected on the contralateral temporal fovea horizontal meridian perimeter line, admitted as fixed. It commands the forced convection system extrinsic muscle action. Its action includes an incyclotorsion physical effort.

Inferior oblique muscle: This has an excyclotorsive physical effort and is antagonistic to the superior oblique muscle physical effort, to avoid the pathological incyclotorsive movement.

Ciliary muscle: This controls lens accommodation to obtain the best-projected image on the temporal fovea and view objects at varying distances.

Corneal accommodation: The cornea curvature adaptation to compensate for the deformations of the conical projections through two distinct foci using image fusion.

Optic disc (OD): Oval region of the eye nasal retina without cones and rods.

Blind spot (BS): A visual field oval region that is projected onto the optical disc of ipsilateral eye.

Optical disc neural correspondent (NC): A visual field oval region, this is projected on the phototransducers, of the contralateral eye temporal retina, which has its periphery as the neural correlates of the phototransducers neural from optic disc periphery of the ipsilateral eye to the visual field.

Forced convection mechanism: The eye has two independent systems of forced convection: one under the extrinsic muscle action and the other under the intrinsic muscle action. The extrinsic muscles move the mobile mass in the cornea, trabecular meshwork, and retina, and the intrinsic muscles move the mobile mass in the lens and Schlemm's canal [4].

Iris: Main functions. Reduces the light diffusion in the projected image in the retina and prevents aqueous humor return when the pressure in the anterior chamber is greater than in the posterior one during the cornea accommodation process [2, 3]. After cataract surgery, there may be reflux of aqueous humor from the anterior chamber to the posterior chamber during the period of adaptation to the artificial lens, and metabolic residue contaminates the artificial intraocular lens causing posterior capsular opacification.

2.1 Main vision characteristics

Figure 1 shows a components schematic diagram necessary for image formation, image transmission to the brain, and how image fusion occurs. At the top of the diagram is shown the visual field. From this region, light rays are emitted or reflected to be projected into the retina. The projected image inversion projected onto the retina is a physical form of the selection of light rays that form the image of an object or body situated in the visual field. The physical principle can be best verified by a pinhole camera. The central fixation point "P" divides the visual field into the right (RVF) and left (LVF) visual fields, which are transmitted to the contralateral brain hemispheres. The visual field can also be divided into the binocular visual field, the region seen by both eyes, and the peripheral visual field, the region seen by one eye. Then, on the temporal retina, the image produced in the contralateral

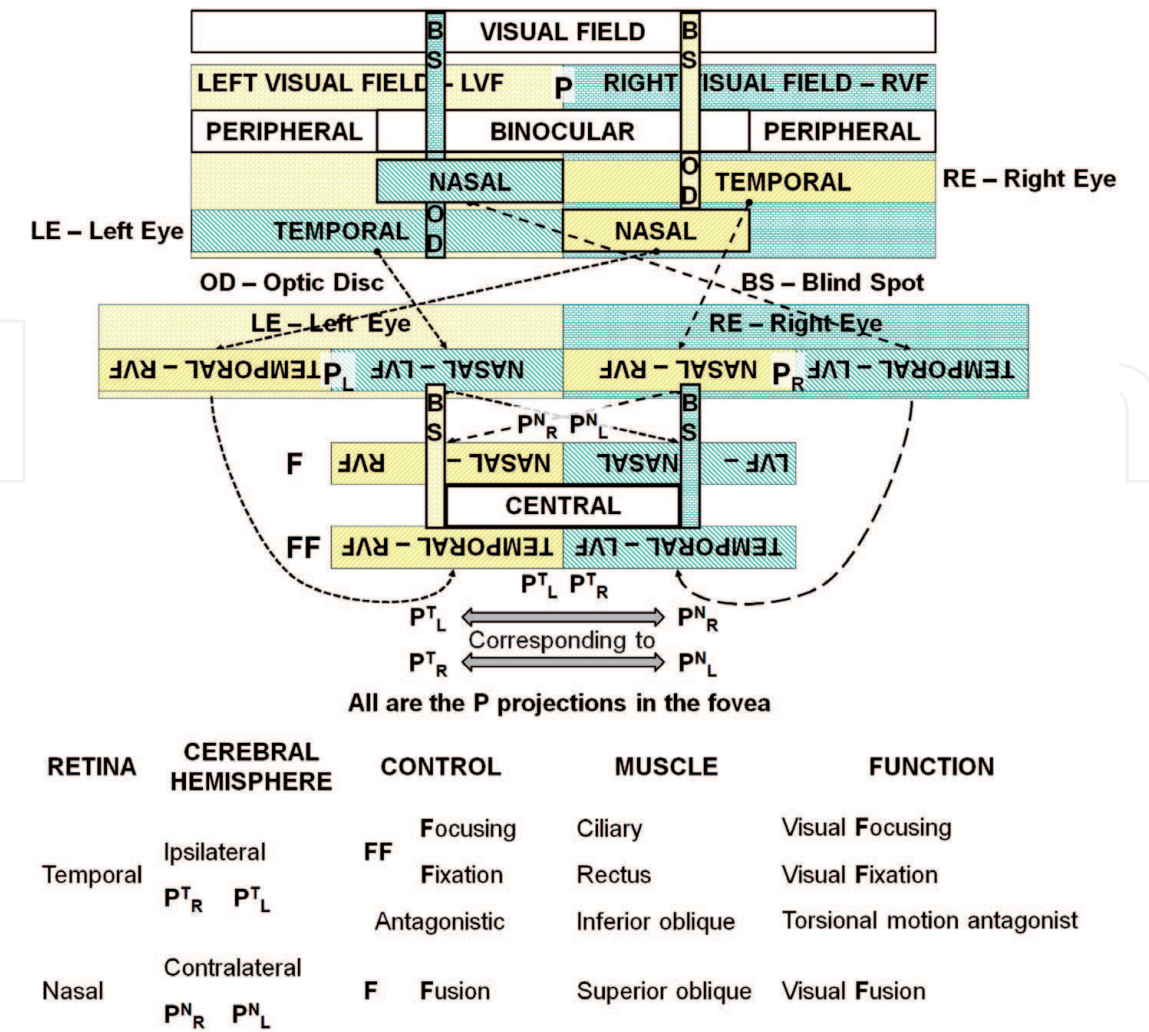


Figure 1.
Main vision characteristics.

visual field (eye nasal visual field) is projected, and on the nasal retina, the image produced in the ipsilateral visual field (eye temporal visual field) is projected. The projected image to an optical disc region without photoreceptors cannot be transmitted to the contralateral cerebral hemisphere. The projected image in the temporal retina is transmitted to the brain's ipsilateral hemisphere, and the projected image in the nasal retina is transmitted to the brain's contralateral hemisphere.

2.2 Binocular vision physiology

In the summary, below, as shown in Figure 1, the binocular vision main controls are described. The projected image in the temporal retina is transmitted to the cerebral ipsilateral hemisphere, which controls the rectus muscles movement, to improve eyeball position fixation and controls the ciliary muscle movement to accommodate the lens and improve focusing. The image projected on the nasal retina is transmitted to the contralateral cerebral hemisphere, which controls the superior oblique muscle movement, changing the cornea curvature to adjust the projected image size in the nasal retina to the projected image in the contralateral temporal retina.

Figure 2 shows the fusion process of the retinal nasal image with the contralateral eye temporal image. Of course, a single movement by the oculomotor muscle reflects the movement of all the other muscles and consequently causes changes in these images. These changes, however, have not been taken into consideration here,

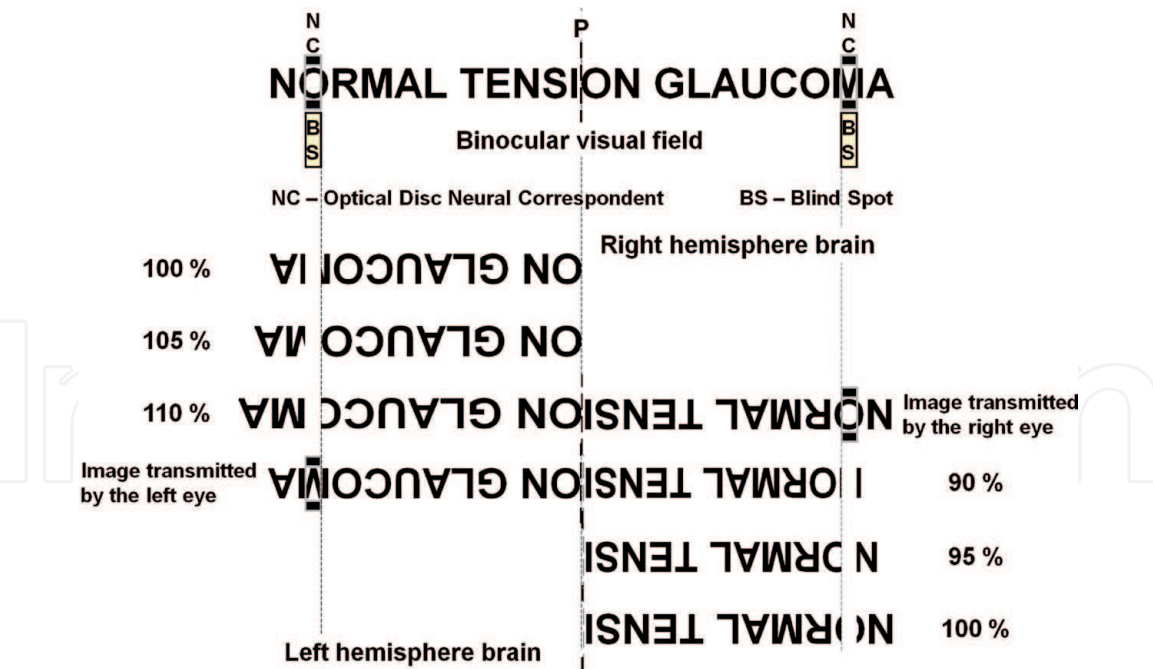


Figure 2.
Image fusions (superior oblique muscle action).

as to emphasize the action of the superior oblique muscle action on the nasal images received by the brain. In binocular vision, the “NC” and “BS” regions are coincident and have identical perimeter images. For example, if we take the written title of a work in the binocular visual field, three regions can be seen: the “P” fixation point, the “BS” regions that are projected in the ipsilateral eyes nasal retinas, and the “NC” regions that are projected in the contralateral eye temporal retinas (when the binocular visual gaze is in the lateral limit the nose profile protrudes through the ipsilateral dashed line). **Figure 2** shows how these images are transmitted to the brain. The image transmitted by the temporal retina is the reference image in the fusion of images, so it does not have primary changes related to the fusion of images. The image transmitted by the nasal retina is presented with an increase of 10% for the right eye and a 10% reduction for the left eye. In the brain, the neural region related to the optic disc (OD) region of the retina corresponds to the “BS” region of the visual field and is the corresponding neural region “NC.” Note that the variation of 10% causes in the visual field the displacement of the “BS” regions to the left, so the two regions are not in the location shown in **Figure 2**. In the fusion of images, the brain commands the superior oblique muscle of the contralateral eye so as to adjust the projected image in the nasal retina to the projected image in the temporal retina of the ipsilateral eye. **Figure 2** shows the merger performed in two steps. Any change in the temporal image corresponds to a displacement of the “NC” region in the visual field. The image projected in the temporal retina is the main one because, in addition to being a reference in the fusion of the images, it is transmitted to the ipsilateral hemisphere to control the contralateral limbs and the movement of the ipsilateral eye. Given this, the reason for lateral dominance may be admitted as a genetic or acquired deficiency.

Lens accommodation and of the cornea are the two independent intraocular mass transfer movements, by forced convection. To eliminate metabolic residues without storing them, it is necessary to maintain the concentration of metabolic compounds uniform throughout the mobile mass, so that the simple draining of the mobile mass removes the metabolic residues without leaving accumulations. In order to standardize the concentration of metabolic residue produced, it is

necessary to equalize the mobile mass movement in all intraocular regions. Over many years, these accumulated residues are agglutinated and form droplets that grow with the adjacent droplets to modify image projections on the retina and consequently modify the dimensions and position of the eyeballs as well as the ocular movements. Because of these ocular changes, the patient begins to suffer and to present the symptoms and signs of various ocular pathologies. As a result, the elimination of agglutinated residues through the anterior chamber can become lodged in the trabecular meshwork and increase the aqueous humor passage resistance, resulting in increased intraocular pressure.

2.3 Focusing, fixation, and fusion

Binocular vision is based on fixation by the eyes on an object of the visual field (rectus muscle action). To fix the eyes on an object, it is necessary that the eyes are able to focus the object (ciliary muscle action), so this action must be faster than the fixing action. When focusing and fixing on an object it, is necessary to adjust the binocular images to compensate, between them, for the distortions produced by the conical projections due to the horizontal distance between the eyes (superior oblique muscle action). Thus, action must be slower than the fixation action. In the appendix, a first-order linear model is used to analyze, by comparison, the rapidity effects among the changed muscular actions of state in the focalization, fixation, and fusion of the images, for binocular vision. Here, 0% is the initial state and 100% is the final state. The analytical equation that establishes the transition between the equilibrium states (initial and final) depends on the parameter τ (time constant). Thus, three time constants are required: τ_C (ciliary muscle), τ_R (rectus muscles), and τ_S (superior oblique muscle). For this, the relation among the time constants is given by Eq. (1).

$$\tau_C < \tau_R < \tau_S$$

(1)

3. Vision physiology, symptom, and sign analysis

Binocular motion physiology: In **Figure 3a** we have “F” as the fixation point in the visual field, as projected onto the fovea of the respective eyes. “I,” the point of interest in the lateral visual field, has its projections on the nasal and temporal retinas of the respective ipsilateral and contralateral eyes. “M,” the movable fixation point, maintains its projections on the fovea of the respective eyes as it moves along

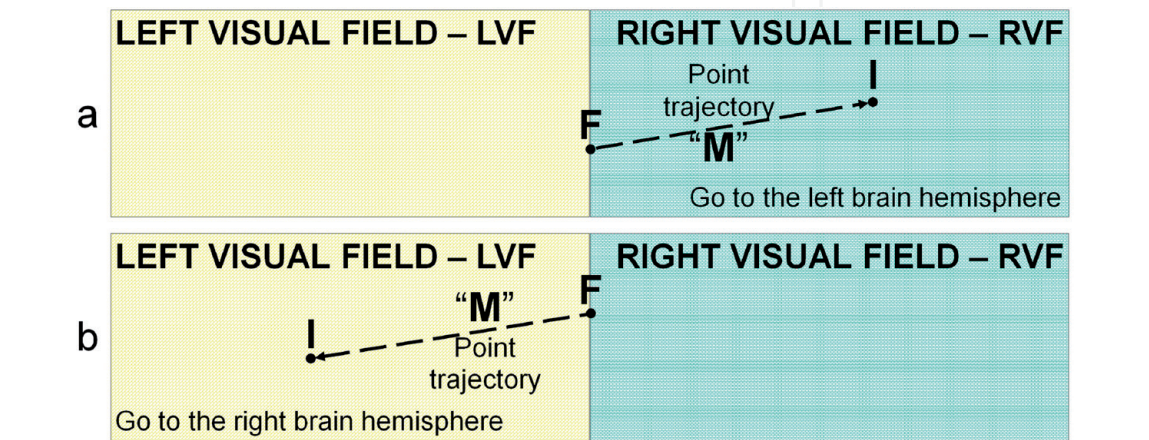


Figure 3.
Two possibilities of eye movements. (a) Eye shift in the right visual field. (b) Eye shift in the left visual field.

an visual field surface imaginary line, when the eyes travel the smallest angular displacement between the “F” and “I” points.

When the ocular direction shifts from point “F” to point “I,” point “M,” the contralateral eye visual axis intersection with the surface of the visual field (initially coincides with point “F”), is shifted to point “I.” The “M” point moves across an imaginary line on the surface of the lateral visual field with the smallest angular displacement of the axial axis of the contralateral eye. In this trajectory, the contralateral eye maintains its focus at the “M” point because the ciliary accommodation time constant, τ_C , is much less than the ocular displacement time constant, τ_R (rectus muscles). Therefore, relative to the visual field laterality, the image projected on the contralateral ocular temporal retina is the primary image because it is the image used by the brain to control eye movement. The image projected on the nasal retina of the ipsilateral eye is the secondary image, because it is the image used by the brain to control the cornea accommodation movement, a slower movement, due to the time constant of the cornea accommodation, τ_S (superior oblique muscle), which is much longer than the ocular displacement time constant, τ_R (rectus muscles). Therefore, in this eye movement, the dominant eye is contralateral to the laterality of the “I” point visual field, and the auxiliary eye is ipsilateral because its movement depends on the fusion of the images to keep the projection onto its fovea, the “M” point.

On the return trajectory, **Figure 3b**, the current fixation point “F” is the previous “I” point, and the current interest point “I” is the previous “F” point; hence the current movable fixation point “M” will have an ipsilateral trajectory to the anterior trajectory of “M.” Then, the dominant and auxiliary eyes will be contralateral in the anterior trajectory, so eye dominance is circumstantial.

Refraction error: Eyesight adaptation to dark is the common pathological symptom that precedes refractive error (see [3]). In 1619 Scheiner, *apud* [12], proved in his experiments, made with holes in a card, that an object is seen in each direction at a different distance. You can reproduce the effects perceived by Scheiner, by fixing the gaze on a distant object, through a pinhole in a paper pressed against the eyelid. When you move the paper without removing it from the eyelid, you can perceive the image of the object jumping from one position to another or moving its shape. The jump indicates the same pathology observed by Scheiner, and the change in form is another presentation of the same pathology [2]. This pathology can be acquired by the dehydrated accumulation of intraocular metabolic residues agglutinated in the form of drops. These drops form lenses that can produce overlapping images (causing blurred vision, floaters, monocular polyopia, and photopsia with and without photochromatic dispersion) and, depending on their transparency, make light transmission difficult. In the postoperative period of cataract surgery, patients report having a clearer view through the operated eye (greater light transmission in the artificial lens). Patients may report blurred vision and secretions released from the anterior surface of the cornea (corneal accommodation variation) and floaters (the metabolic mass stored in the lens prevented their viewing). In Ref. [2] the different symptoms of myopia, hypermetropia, astigmatism, and presbyopia are shown as visual disturbances of the same origin, the intraocular accumulation of dehydrated metabolic secretions.

Ocular hypertension: This can be caused by an imbalance in the production, concentration, and drainage of eye movable mass. Increased mass transfer resistance across the trabecular meshwork is an important impediment to aqueous humor drainage. Corneal accommodation movement failure hinders its mass transfer movement, thus being the major factor in the metabolic residue storage in the cornea [5]. The cornea stored metabolic residue elimination process consists in the movement of its curvature, in order to recover its healthy accommodation. In this process, the residues leave the two surfaces and are eliminated by dilution or suspension. On the anterior

surface, the lacrimal fluid drags the residues, and on the posterior surface, the residues are dragged by the aqueous humor. If an important tear drag occurs when the patient is sleeping in the supine position, it may cause nostril obstruction, throat irritation, and hoarseness. Drainage of aqueous humor with suspended residues can impregnate the trabecular meshwork with the residues and increase resistance to outflow causing ocular hypertension. In the postoperative period of cataract surgery, the patient eliminates metabolic residues on both cornea surfaces, due to fusion of images and corneal accommodation; thus metabolic residues may impregnate the trabecular meshwork and cause ocular hypertension. It is possible, by a natural process, for the intraocular pressure return to its previous value.

Retinal mass transfer defect

- *Negative afterimage*: Common pathology in which retinal forced convection mechanism failure reduces the metabolic residue outflow may cause deposits in the choriocapillaris. The residue accumulation metabolic in the choriocapillaris makes it difficult for the retina's mobile mass to flow, thus increasing the time constant for the outflow to meet the new operating requirements. Then the phototransducers will take longer to react to color changes, and the observer will notice the complementary color during the transient state.
- *Retinal detachment*: Metabolic residues stored in the retina reduce its flexibility and create regions with different rigidity. The radius variation of retina curvature, due to fusion of the images, can cause physical efforts between the regions with different rigidity and cause its break, besides modifying the characteristics of the vitreous humor, due to the contact with the affected region.
- *Macular degeneration*: Transfer deficiency of retinal nutrients caused by metabolic residue accumulation leads to histotoxic hypoxia. Hypoxia stimulates angiogenesis and results in wet macular degeneration [6].

Lens mass transfer defect

- *Amblyopia*: The insufficient mechanism of forced convection of the lens prevents the healthy renewal of the moving mass in its interior, so the metabolic residue is agglutinated into particles and kept in suspension. The suspended particles refract, in diffused light, the incident light rays; thus the brain loses control over the ciliary muscle, for lack of clear image [5]. The amblyopic eye can project images through a small slit, because in this way the intraocular light scattering is reduced.
- *Cataract*: This pathology can be acquired by dehydrated accumulation of metabolic residue produced by the lens and agglutinated in droplet form. These droplets also cause refractive error that interferes with lens mass transfer movement control. As the metabolic residue is cloudy, its dehydration causes opacity (See [3, 8]). Cataract surgery extinguishes ciliary muscle movements and, consequently, affects the forced convective mass transfer mechanism in the Schlemm canal, which may cause metabolic residue accumulation that may increase intraocular pressure.

Pathological eye movements and related symptoms

- *Cyclotorsion* [13]: Common pathological movement resulting from the cornea accommodation difficulty. This pathology can produce movement perception in static images or graphic montages, make it difficult to count elements of an

equal character set without the use of a pointer, and cause dizziness and nausea (incyclotorsion, excyclotorsion).

Saccadic eye movements: Common pathological movements caused by the metabolic residue accumulation stored in drops (forming small lenses with different transparencies, sizes, and viscosities) in the cornea and lens [7]. The rectus muscles perform these movements and are antagonistic to the instantaneous displacements of image projection on the temporal retina caused by the change of droplets in the passage of light rays. See Scheiner's experiment, *apud* [12]. Vergence eye movements are only observed if saccadic movements exist.

- *Photosensitive epilepsy*: This is triggered by resonant neural impulses caused by visual stimuli [2]. Resonant impulses may be formed by antagonistic responses to eye control stimuli. Antagonistic responses can be constructed by image transmissions through alternations between the metabolic residue droplets stored in the cornea and lens. Droplet alterations may be produced as result of lens accommodation. Then, when the accommodation process begins, the droplets are physically repositioned causing changes in the size and position of the image projection on the retina, which can be interpreted by the brain as a change in distance from the fixation point. The change in distance forces the brain to send a new neural stimulus to accommodate the lens, in many cases antagonistic, modifying the position of the droplets. Frequent recurrence of these actions can trigger resonant neural impulses. Therefore, the eye that holds the interest point in its temporal retina controls the movement of the eyes, as shown in *binocular motion physiology*. But, because refractive error occurs in both eyes, the point of interest may either be projected on the temporal retinas or on both nasal retinas. (Note: in normal vision, the point of interest is projected on the temporal retina of one eye and on the nasal of the other.) Projecting the interest point on the temporal retinas causes the brain to generate conflicting commands in both eyes. By projecting the interest point on the nasal retinas, the brain loses its command sense.
- *Anterior uveitis*: This may be caused by superior oblique muscle overuse. It is symptomatically characterized by pain caused by a slight pressure on the muscle through the eyelid. In the patient, this always occurred in the left eye upper nasal region.
- *Pterygium*: Excessive movement of the rectus muscle may cause this, in order to compensate for a jump in image as a result of the formation of metabolic residual drops as observed by Scheiner's experiment, *apud* [12].
- *Fixation instability*: This is easily observed in a dark environment, through the light path projected on the retina resulting from the head oscillatory rotation when the gaze fixed on a luminous LED. Motion perception in still images [14], stereoscopic depth, as well as the need for a pointer to count a large set of equal characters are some of the symptoms resulting from this pathology. Imperfections of the anterior surface of the cornea can be an important indicator of this serious pathology.
- *Tendinitis*: The occurrence was observed during manual activities with the near fixation point, during the removal of intraocular metabolic residues; however, the pathology may be combined with the *fixation instability*.
- *Disequilibrium*: This may occur because of pathological cyclotorsional movement. It may or may not be discreet. It can even form a dry callus [3].

- *Bruxism*: When trying to eliminate binocular diplopia, the patient may feel forced to contract other muscles (head and limbs). Because the jaw is the only moving bony part of the head, the patient may, “as an aid,” contract the chewing muscles during eye correction exercises. Repetition of this contraction during sleep may be the cause of the condition.
- *Headache*: In eye treatment, the patient should not use analgesic. Headache is a nerve compression symptom that can be treated with eye alignment, and the pain disappears immediately [7].
- *Superior eyelid ptosis*: May be voluntarily stimulated to reduce light entry through the cornea because of intraocular light diffusion [4, 11].
- *Auditory perception*: In 2003, in the routine examination, the patient was first diagnosed with the absence of 6 kHz frequency perception in the left ear, and then the patient noticed the ipsilateral permanent presence of noise. Several otorhinolaryngologists have examined, and no cause has been diagnosed. The patient realizes that the noise intensity varies during eye exercises and there are occasions when the noise disappears [3].

4. Results analysis

4.1 Storage and evacuation processes of intraocular metabolic residue

This paper presents four states of metabolic residue accumulation during the process of stimulating eye movements for rehydration and drainage. In the first state, metabolic residues form droplet agglutinations without significant variations of their forms. In the second state, metabolic residue forms agglutinations in droplets with important variations in their forms. In the third state, metabolic residues are in suspension. In the fourth state, metabolic residues form films impregnated in the intraocular layers.

In the first state, the residue droplets maintain their different dimensions (constant volume), shapes, refractions, opacities, and high viscosities, so they form small lenses that can project the same image to the retina in different regions, with different dimensions, shapes, and intensities. This pathology was first observed in Scheiner's experiments in 1619, *apud* [12]. The drops, depending on their positions and shapes, in relation to incident light can cause chromatic scattering. The moving medium circulation between the drops can rehydrate them and transfer them to the second state.

In the second state, the droplets of the residues keep their different volumes fixed but vary their dimensions, shapes, opacities, and viscosities, so they form small, variable refractive lenses that can project radial beams with periodic expansions and reductions. These movements have different frequencies, depending on the movements of different drops, and can cause chromatic dispersion, depending on their shapes and positions, in relation to the incident light. Depending on the circulation of the moving medium, there may be dehydration of the droplets, and they may lose their movement, that is, move to the first state, or there may be rehydration of the droplets, and they may pass to the third state in suspension.

In the third state, the metabolic residues are in suspension. The residues in suspension diffuse the intraocular light. Intraocular diffusion can cause visual discomfort if there is pupillary constriction, a tendency in older people. Stimulated mydriasis enhances this discomfort. Miosis and prolonged stay of suspended residues stimulate upper eyelid ptosis to reduce the opening for light penetration. Depending on the

circulation of the mobile medium, the suspended residues may become dehydrated or rehydrate. If dehydrated, the viscosity increases and is agglutinated into droplets, passing to a second state (droplets in different shapes). If rehydrated, the viscosity is reduced and eliminated through the nasal and oral routes or by the trabecular mesh. Elimination through the nasal and oral routes may cause tearing, burning in the cornea, obstruction of the nostril, and mild inflammation in the throat. The trabecular route can obstruct and increase intraocular pressure. From this state there may be migration to the first state through thin-layer deposits on the cornea or lens layers. This is the initial state of the metabolic residue storage process as well as the final state in the drainage process, depending on the moving medium circulation.

In the fourth state, the metabolic residues are stored as films in the intraocular layers. Symptoms can be perceived through the visualized sinuositities while moving the eye, observing a flat visual field. The mere circulation of the mobile medium is insufficient to rehydrate the metabolic residue films and transform them into aqueous suspension of the third state. To rehydrate the metabolic residue in this state requires an impulsive movement of the mobile mass.

The four states of intraocular storage are always present, but there are alternations between symptoms, although they may appear together. Thus visual acuity depends on the state predominance, the amount, and the way metabolic residue is accumulated. The rehydration exercises and drainage of metabolic residue depend on the symptoms.

4.2 Influence of bilateral upper eyelid blepharoplasty on cornea curvature

Table 1 shows, chronologically, the patient's intraocular pressure, on several dates, and, in addition, important information to show the situations experienced by the patient during the time while drainage work of intraocular metabolic residues was being analyzed. To renew the driver's license using corrective lenses in February 2014, the patient had to exercise his left eye for 10, 2 days apart, and then rest for 2 days, because there was little chance of approval, mainly because of the left eye. On the day of the exam, the left eye was fine, but the contralateral eye was in minimal approval condition. When an eye improves, the contralateral worsens. Five years later, in March 2019, the patient's driver's license was renewed with corrective lenses without any special attention, but 133 days later the patient's acuity was assessed with DV 20/50 OR, wearing corrective lenses. Visual acuity is not an important parameter to assess the drainage status of accumulated intraocular metabolic residue.

The patient noticed that his eyelid opening was compromised by corneal topography in April 2016, **Figure 4a**. The patient had never worn contact lenses. In May 2017 a bilateral upper blepharoplasty was performed. **Table 1** shows the highest pressure in the series was recorded in June, 2017, 49 days after surgery. 135 days later, lower intraocular pressure values were recorded. Upper blepharoplasty allows the light incidence in the region hidden by the upper eyelid ptosis and stimulates rehydration of metabolic residue stored in the region hidden by upper eyelid ptosis. Rehydration of a large volume of stored residue causes significant increase in drainage of metabolic residue through the oral and nasal routes, as well as through the trabecular meshwork. Intense passage of residue through the trabecular meshwork may obstruct the passage of aqueous humor and increase pressure. With the continuity of the exercises, obstruction can be removed from the trabecular meshwork and intraocular pressure reduced. Increased intraocular pressure should be observed in many patients after cataract surgery. Cataract reduces the light incidence on the retina and favors metabolic residue accumulation. A cataract surgery allows a higher light incidence in the retina, thus contributing to the rehydration

Pachymetry - 0.542 mm OD, 0.544 mm OS			
Calendar date	IOP mmHg		Observation
	OD	OS	
November 28, 2007	18	17	Uveitis OS Discreet PSC OU
October 31, 2008	16	16	Lens id.
April 27, 2009	16	16	Lens id.
November 30, 2009	16	15	Incipient cataract PSC OU Little most evident OS
August 30, 2010	17	14	Cataract id.
December 21, 2011	---	---	Uveitis OS
February 14, 2012	16	16	Cataract (+) OD, (+/++) OS
February 24, 2014	---	---	Eye exam for new driver's license
July 14, 2014	16	14	Cataract (+/++) OD, (++) OS
April 9, 2015	14	14	Cataract id.
September 14, 2015	17	16	Cataract id. (OS increased)
March 10, 2016	16	14	Cataract (++) OU (PSC OE)
April 5, 2016	---	---	1st corneal topography
September 29, 2016	16	14	Cataract (++) PSC OU (OS increased)
May 8, 2017	---	---	Upper eyelid blepharoplasty - OU
June 26, 2017	18	17	Cataract id.
September 4, 2017	---	---	2nd corneal topography
November 9, 2017	15	14	Cataract id.
March 5, 2018	---	---	3rd corneal topography
October 23, 2018	---	---	4th corneal topography
November 29, 2018	15	15	Cataract id.
March 18, 2019	---	---	Eye exam for new driver's license Cataract (++) OD, (+++) OS, (OD increased)
July 29, 2019	15	15	VA DV 20/400 OD, 20/400 DS With corrective lens 20/50 OU

Table 1.
Chronological presentation of medical examinations and surgery.

of an important volume of metabolic residue that can obstruct the trabecular meshwork and increase intraocular pressure. Since cataract surgeries and upper blepharoplasty are not followed by orthoptic exercises, in the postoperative period, it is important to develop a trabecular meshwork cleaning procedure to resolve cases in which intraocular pressure does not return to preoperative levels. Intraocular pressure should always be evaluated during residue drainage work, as well as in the postoperative period of cataract surgery and upper blepharoplasty.

Figure 4 shows, in four corneal topographies, the evolution of the anterior corneal surface curvature recovery, produced by the rehydration and drainage exercises of intraocular metabolic residues. The rehydration and drainage of intraocular metabolic residue can solve different pathologies related to anterior surfaces of the cornea. Although not the best way to evaluate the eyelid opening, this was the way available to the authors, in search of parameters that could evaluate the evolution of

the work. The ocular region was recorded in the same laboratory on the dates presented in **Table 1** and **Figure 4**. The diameters, horizontal and vertical, were found for each mapping, in relation to their own scales. **Figure 4** shows, with dashed lines, how scales and diameters were evaluated. **Table 2** shows that the horizontal diameters of the two eyes did not show significantly different percentages (OD 14.3%,

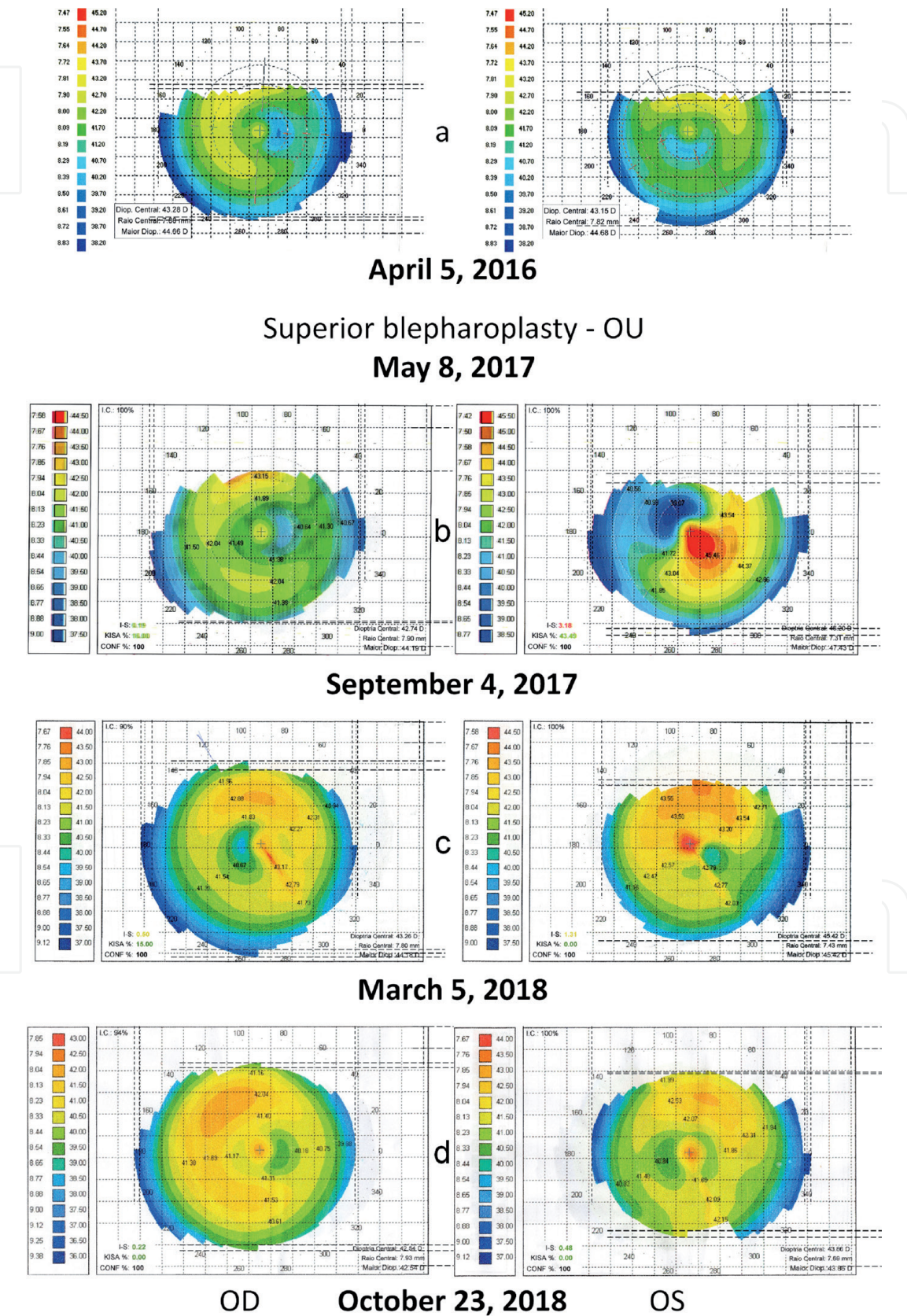


Figure 4.
Four corneal topography exams from the same patient. (a) On April 5, 2016 (before superior blepharoplasty - OU, on May 8, 2017). (b) On September 4, 2017. (c) On March 5, 2018. (d) On October 23, 2018.

month / year		a - 4 / 2016		b - 9 / 2017		c - 3 / 2018		d - 10 / 2018	
Eye	Position	Ø	ε	Ø	ε	Ø	ε	Ø	ε
OD	HORIZ	9,85	15,8%	10,07	13,9%	9,87	15,7%	10,02	14,3%
	VERT	6,91	34,8%	6,91	34,8%	8,92	15,8%	8,39	20,9%
OS	HORIZ	9,27	20,8%	9,74	16,8%	9,81	16,2%	9,89	15,5%
	VERT	6,75	36,3%	7,02	33,8%	7,54	28,9%	7,39	30,2%
Comeal diameter reference [6]				HORIZ	11,7			VERT	10,6

Table 2.
Diameters and errors relative to a pattern.

OS 15.5%) but the vertical diameters of the two eyes show significantly different percentages (OD 20.9%, OS 30.2%), that is, their evolution had not yet stabilized. The vertical diameter of both eyes exposed to the instrument was reduced because of simultaneous eyelid ptosis. The percentage error was calculated using as default the values cited in [6]. The percentage value is a referential error, serving only to compare the respective eye diameters. As such, the vertical diameter of the left eye is still far from the dimension of the collateral eye, i.e., the vertical limits had not yet fully recovered. The evolution shown in **Figure 4** shows the need for orthoptic exercises after upper eyelid blepharoplasty to recover eyelid opening and probably after cataract surgery.

4.3 Current state of intraocular cleansing

Although the results presented do not seem encouraging, there are interpretations that minimize the apparent divergence of the successful progress of the work. At the beginning of the study, the patient had presbyopia, had had eyelid ptosis in both eyes for over 15 years, and had no cataract. Blepharoplasty in both eyes was performed in 2017, when the cataract was at an advanced stage. This shows that the patient spent 17 years trying to rehydrate and drain metabolic residue with serious upper visual field constraints [8]. That is, the patient did not have the opportunity to recover the mechanisms of intraocular mass transfer by forced convection and, as a result, developed cataracts. Cataract is the storage of dehydrated metabolic residue in the lens due to a defect in the mechanism of mass transfer in the lens by forced convection [3, 8]. Even so, it was possible to recover from some pathologies described in the works [9, 14]. Rehydration of intraocular metabolic residue is a slow and difficult process to perform because it does not require any external physical effort or any agent that reduces the viscosity of dehydrated residue. It does, however, require changes in habits and a lot of sleep, and success may depend on acquired physiology, congenital and hereditary, as well as diet, among others. The intermediate stages of intraocular cleaning indicate that rehydration of the concentrated metabolic residue reduces its concentration and viscosity due to the increase in mobile mass added to the stagnant residue. Thus increasing its stagnant volume may represent an increase in the extent of the stagnant area, resulting in cataract evolution, if any, but with lower density and viscosity, which are not evaluated. Due to the rehydration and drainage process, the patient showed signs in the cycle of improving and degrading visual acuity. The patient did not have access to any test that evaluated the storage of intraocular metabolic residue. **Figure 4** shows the evolution of corneal curvature in several tests. The patient has already overcome two

pathologies, dark adaptation, for which there is no measurement standard and can read a text right after looking at the sun. It is important to know that activities in the dark stimulate rehydration of intraocular metabolic residue (sleeping in the dark), fixation instability favors dehydration of intraocular metabolic residue, and eyelid ptosis impairs the mechanism of intraocular mass transfer by forced convection. It is worth noting that headache and its immediate recovery through eye alignment, without medication, are symptoms of suffering caused in the oculomotor support system of the eyeball and an important sign of displacement in its support base, due to the disposition intraocular storage of metabolic residues.

5. Conclusion

With much simplification, the eye can be described as having three power supplies and four excretory paths, controlled by two forced convection systems [10]. There are three sources of food: tear fluid (feeds the corneal epithelium and excretes through the nasal and mouth cavities as well as the digestive system), aqueous humor (feeds the lens and corneal stroma and excretes through the venous system), and through Bruch's membrane (the circulatory system feeds and excretes the retina). There are two systems of forced convection, the intrinsic muscles (the crystalline and Schlemm canal) and the extrinsic muscles (cornea, trabecular mesh, and retina), which drive mass transfer. The physical properties of a cleaning sponge can be used as a metaphor for four greatly simplified mass transfer models. The four adaptations are these: a cleaning sponge to represent bidirectional movements on its sides, for the feeding and excretion of the lens; a cleaning sponge with its closed sides, to represent the bidirectional movements on its two other sides for feeding and excretion of the retina (Bruch's membrane) [6]; a cleaning sponge with closed sides to represent the unidirectional passage on both sides for the passage of aqueous humor and metabolic residue (trabecular meshwork) [1, 11]; and finally, two cleaning sponges, juxtaposed to closed flat surfaces, to represent bidirectional movements on their free sides for feeding and excretion of the epithelium and corneal stroma (epithelium, Bowman's membrane, and stroma) [1, 6]. Intraocular metabolic residues are stored when mass transfer mechanisms are insufficient to maintain constant, concentration, and agitation of dissolved or suspended metabolic residue components in the moving mass. An insufficiency of these mechanisms causes the mobile mass to stagnate in both forced convection systems and to store the metabolic residue due to dehydration. Dehydrated residues are stored simultaneously in the cornea, trabecular mesh, Schlemm's canal, lens, and retina. Vicious and frequent habits can cause mobile mass stagnation.

Metabolic residue is released if there is a physical work of forced convection systems capable of excreting concentrated metabolic residue in solution or suspension in the mobile medium. The release of fixed metabolic residue depends on its rehydration to transform it into a solution or suspension. The cornea, trabecular mesh, lens, Schlemm's canal, and retina simultaneously excrete accumulated residues. Orthoptic exercises can stimulate the physical effort to excrete metabolic residue, as well as rehydrate the fixed residues; these, however, cause sleep. Cataract surgery stimulates the forced convection system because it unbalances the efforts of the extrinsic muscle due to increased light transmission and change in refractive power resulting from intraocular lens implantation. Therefore, postoperative symptoms caused by cataract surgery are similar to those caused by orthoptic exercises that excrete intraocular metabolic residue.

When stimulated, stored metabolic residues can be rehydrated and simultaneously expelled from all intraocular regions. The accumulated metabolic residues in the corneal epithelium can be expelled through the cavities, nasal and mouth, as well as through the digestive system. Through the nasal cavity, they can plug up the nostrils as well as become dehydrated and form a deposit in the nasal passages. Through the oral cavity, they can be expelled but, even without fever, can cause cough and inflammation of the throat and vocal cords, which makes swallowing difficult and often produces a hoarse or muffled voice. Through the digestive system there is nothing observed. Accumulated metabolic residue in the corneal, crystalline, and retinal stroma can be expelled through the venous system and cause slight body aches (feeling unwell, malaise) without fever. Corneal and crystalline residues cross the anterior chamber, trabecular meshwork, and Schlemm's canal before reaching the venous system. In addition to these symptoms, there may be the production of tears and headache. The production of tears is linked to cleansing and may be a photoneural perception of impeding light transmission across the anterior surface of the cornea. A headache may be linked to physical exertion between the Zinn ring and the eyeball because the most efficient treatment is the alignment of the eyes to a fixation point. This alignment can correct the diopter difference between the eyes and acts much faster than the use of analgesic; if delayed, its application impairs its efficiency. Patients after cataract surgery also eliminate intraocular metabolic residue, so they should have the same symptoms, depending on the eliminated mass. However, symptoms may appear only 2 months after surgery, because metabolic residues rehydration is a slow process. On the other hand, the slight body aches do not last more than a day, but throat inflammation can last up to 5 days. Under these circumstances and without fever, if the patient ever seeks medical attention, it is not likely to return to the ophthalmologist unless the patient receives guidance.

The stored intraocular residues simultaneously cause some physical and symptomatic pathologies. Among the major ocular pathologies are the increase in eye mass and volume, and, consequently, the eyeball changes the shape, inertia moment, position in the eye socket, refractive disposition and error in intraocular light transmission, dislocation of its mass center, saccadic movements, cyclotorsion, fixation instability, and increased intraocular pressure. Refractive disposition and error in intraocular light transmission are consequences of the formation of metabolic residue droplets. Error in intraocular light transmission causes error in image transmission. Error in image transmission is image refraction in different dimensions, intensity, and locations when there is slight variation in lens accommodation or visual axis angular displacement. This pathology was verified in Scheiner's experiments in 1619, *apud* [12]. In response, to maintain the fixation point on the fovea, the rectus muscles receive a compensatory movement impulse, in the opposite direction to the unwanted displacement of image projection on the retina, which results in saccadic movement. Importantly, the saccadic pathological movement occurs in conjunction with two other pathologies, cyclotorsion and fixation instability, which can aggravate the consequences. Then the initial thrust and final deceleration of saccadic movement occurs in a structurally unbalanced system, so it can produce physical effort between the attachment points of the eyeball. The eyeball has three fixation points on the superior orbital fissure (posterior orbit), the trochlea of superior oblique, and maxillary bone (origin of the inferior oblique muscle). Frequent acceleration and deceleration of saccadic movement can cause frequent and important impulsive physical efforts in the anteroposterior axis and in the opposite direction, causing frequent variations in intraocular pressure. Frequent impulsive physical efforts and variations in intraocular pressure can slowly damage the optic nerve. If this situation is combined with the patient's high intraocular

pressure, it would be very difficult to control the pressure alone by reducing the production of aqueous humor.

Acknowledgements

The English text of this paper has been revised by Sidney Pratt, Canadian, MAT (The Johns Hopkins University), RSAdip-TESL (Cambridge University). There was no public or private financial participation for publication in this work.

Appendix

A. Dynamic comparison of the state change agility between the activities of focusing, fixation, and images fusion

Figure 5 shows three graphs of Eq. (2), which is the analytical solution of state change in a first-order linear model. The graphs were obtained by replacing the time constant (τ) by the time constants (τ_C , τ_R , and τ_S) according to Eq. (3). The relation was defined from the numerical analysis compatibility, associated with the agility for object visualization.

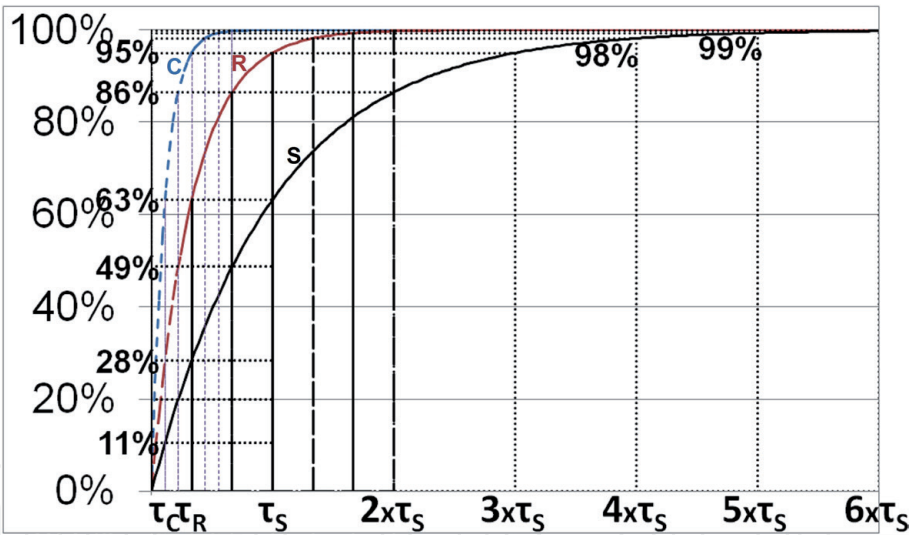


Figure 5.
Muscle contraction percentage graph, Eq. (2), (C) Ciliary muscle contraction (time constant τ_C). (R) Rectus muscle contraction (time constant τ_R). (S) Superior oblique muscle contraction (time constant τ_S).

$$f(t) = 100 \times (1 - e^{-t/\tau}) \tag{2}$$

$$3\tau_C = \tau_R = \tau_S/3 \tag{3}$$

A.1 Analysis of the relationship $\tau_C = \tau_R/3$

Voluntary action, in order to observe an object of interest, requires the movement of the eyes toward it, under the rectus muscles control (τ_R). For this, it is necessary, in the first place, to focus on the object (τ_C) at the moment of its projection in the fovea. Therefore, focalization agility is then considered to be three times higher

than fixation agility. The effect of the variation of the projection of the image on the retina, due to the accommodation of the lens, occurs more rapidly than the effect of the angular displacement of the eyeball, because the amount of mass displaced by the eyeball is much larger than the amount of mass that is moved to crystalline accommodation. Graph 3 shows that at time $t = \tau_C = \tau_R/3$, the focus had completed 63% of the work, while the displacement is 28%. That is, the numerical result is compatible with the associated analysis between the focus and fixation agility.

A.2 Analysis of the relationship $\tau_R = \tau_S/3$

People who have the perfect vision feel safer with binocular viewing than with monocular viewing. However, it is necessary that there is the nasal image fusion with the contralateral eye temporal image. In this way, the brain corrects the conical deformations caused by the distance between the eyes foci and uses twice as many neurotransmitters to interpret the received image, producing mathematically more than twice the accuracy than obtained with the monocular visualization. However, when the distance between the foci of the eyes is negligible in relation to a distant object under observation, the accuracy between the binocular and monocular visualizations is negligible; however, it is necessary to always use the binocular visualization to avoid habitual use of the same eye and thus stimulate ocular dominance.

Fusion of the images is the last step in the binocular visualization process, i.e., when the eyes are concluding their targeting on to the fixation point, fusion of images is at its beginning. Based on this, it was concluded that the time constant of the cornea accommodation (τ_S) is equal to three times the time constant for the eye fixation in the direction of the object (τ_R). Graph 3 shows that at time $t = \tau_R = \tau_S/3$, the fixation has 63% of the work completed, while the image fusion is 28%; that is, the numerical result is compatible with the associated analysis between the agility of the fixation and the accommodation of the cornea. Fusing images stabilizes the eye fixation direction.

Author details


Humberto D. Silva^{1*}, Eduardo D. Silva¹, Maria Tamires D. Silva², Cristiana P. Dória² and Cristiane P. Dória²

¹ Universidade Federal de Pernambuco, Recife, Brazil

² Independent Professional, Recife, Brazil

*Address all correspondence to: hdoria@ufpe.br

IntechOpen

© 2019 The Author(s). Licensee IntechOpen. This chapter is distributed under the terms of the Creative Commons Attribution License (<http://creativecommons.org/licenses/by/3.0>), which permits unrestricted use, distribution, and reproduction in any medium, provided the original work is properly cited. 

References

- [1] Silva HD, Dória LCP, Dória CP, Dória CP, Silva MCTD, Silva HD Jr, et al. Nutrients and metabolic secretions transfer in cornea. Defect and Diffusion Forum. 2011;**312-315**:737-742. DOI: 10.4028/www.scientific.net/DDF.312-315.737
- [2] Silva HD, Dória LCP, Dória CaP, Dória CeP, Silva MCTD, Silva HD Jr, et al. Simulation of the errors of refraction in the human eye. In: Öchsner A, da Silva LFM, Altenbach H, editors. Analysis and Design of Biological Materials and Structures. Advanced Structured Materials Book Series V. 14. Berlin, Heidelberg: Springer: 2012. p. 185-185. DOI: 10.1007/978-3-642-22131-6_15
- [3] Silva HD, Silva ED, Silva MTD, Dória CP, Dória CP. Analysis of the disturbances caused by intraocular forced convection mechanism failure. In: Zilfyan A, editor. Difficulties in Cataract Surgery. London: IntechOpen; 2018. pp. 45-64. DOI: 10.5772/intechopen.72248
- [4] Silva HD, Silva ED, Silva MTD, Dória CP, Dória CP. Movimento oculomotor e algumas patologias. In: Maravieski SP, editor. Teorias e Métodos da Biofísica book. Ponta Grossa (PR): Atena Editora; 2019. pp. 36-42. Available from: <https://www.atenaeditora.com.br/wp-content/uploads/2019/03/E-book-Teorias-e-Metodos-da-Biofisica-2.pdf>
- [5] Silva HD, Dória LCP, Dória CaP, Dória CeP, Silva MCTD, Silva HD Jr, et al. Analysis of failure mechanism of forced convection in the cornea of the human eye. In: Öchsner A, da Silva LFM, Altenbach H, editors. Analysis and Design of Biological Materials and Structures. Advanced Structured Materials Book Series V. 14. Berlin, Heidelberg: Springer: 2012. p. 217-226. https://doi.org/10.1007/978-3-642-31470-4_16
- [6] Silva HD, Silva ED, Dória LCP, Dória CP, Dória CP, Silva MCTD, et al. Forced convection mechanism failure in the eye can cause macular degeneration. Defect and Diffusion Forum. 2013;**334-335**:230-234. DOI: 10.4028/www.scientific.net/DDF.334-335.230
- [7] Silva HD, Silva ED, Dória LCP, Dória CP, Dória CP, Silva MCTD, et al. Forced convection mechanism failure in the eye can cause cataract. Defect and Diffusion Forum. 2013;**334-335**:225-229. DOI: 10.4028/www.scientific.net/DDF.334-335.225
- [8] Silva HD, Silva ED, Silva MTD, Dória CP, Dória CP. Consequences of upper visual field restriction. Brazilian Journal of Development. 2019;**5**(8):11288-11293. DOI: 10.34117/bjdv5n8-011
- [9] Silva HD, Dória LCP, Dória CP, Dória CP, Silva MCTD, Silva HD Jr, et al. Mass transport mechanism in the retina of the human eye. Defect and Diffusion Forum. 2012;**326-328**:18-23. DOI: 10.4028/www.scientific.net/DDF.326-328.18
- [10] Silva HD, Silva ED, Dória CP, Silva MTD, Dória CP. Forced convection intraocular system modeling. Brazilian Journal of Development. 2019;**5**(7):10541-10551. DOI: 10.34117/bjdv5n7-200
- [11] Silva HD, Dória LCP, Dória CaP, Dória CeP, Silva MCTD, Silva HD Jr, et al. Simulation of variation of intraocular pressure. In: Öchsner A, da Silva L, Altenbach H, editors. Characterization and Development of Biosystems and Biomaterials. Advanced Structured Materials Book Series V. 29. Berlin, Heidelberg: Springer: 2012. p. 235-253. Available from: https://link.springer.com/chapter/10.1007%2F978-3-642-31470-4_16

[12] Werner L, Trindade F, Pereira F, Werner L. Physiology of accommodation and presbyopia. *Arquivos Brasileiros de Oftalmologia*. 2000;**63**(6):487-493. DOI: 10.1590/S0004-27492000000600011

[13] Bicas HEA, Jorge AAH. *Oftalmologia: fundamentos e aplicações*. 1st. ed. Tecmedd editor: São Paulo, SP; 2007

[14] Murakamia I, Kitaokac A, Ashida H. A positive correlation between fixation instability and the strength of illusory motion in a static display. *Vision Research*. 2006;**46**:2421-2431. DOI: 10.1016/j.visres.2006.01.030