

# We are IntechOpen, the world's leading publisher of Open Access books Built by scientists, for scientists

6,900

Open access books available

186,000

International authors and editors

200M

Downloads

Our authors are among the

154

Countries delivered to

TOP 1%

most cited scientists

12.2%

Contributors from top 500 universities



WEB OF SCIENCE™

Selection of our books indexed in the Book Citation Index  
in Web of Science™ Core Collection (BKCI)

Interested in publishing with us?  
Contact [book.department@intechopen.com](mailto:book.department@intechopen.com)

Numbers displayed above are based on latest data collected.  
For more information visit [www.intechopen.com](http://www.intechopen.com)



# Goiter: Overview of Aetiopathogenesis and Therapy

*Dhananjaya Melkunte Shanthaiah, Piyush Gupta and Neeraj Kumar Agrawal*

## Abstract

The goiter was described in history for long time. Many luminaries suffered from it. The enlargement of thyroid is known as goiter, it can arise from various causes and each has separate aetiopathogenesis and treatment. As an overview for the book, this chapter delves into each aspect, whereas the details are in separate chapter.

**Keywords:** goiter, hypothyroidism, hyperthyroidism, thyroiditis, carcinoma thyroid

## 1. Introduction

Thyroid gland is a butterfly shaped organ lying in the anterior aspect of the neck. The major function of the gland is the production of thyroid hormones, namely Triiodothyronine and Tetraiodothyronine. These hormones are the major regulators of the various metabolic processes in the human body.

Various pathological processes affect the organ. One of the clinical manifestations of these pathological processes is enlargement of the gland. In general the abnormal enlargement of thyroid gland is defined as goiter by American thyroid association [1].

Historically goiter was mentioned in literature of various languages around the world. Ancient Indian physicians have described the condition called as Galaganda in detail in Ayurveda books written between fourteenth century BC and 400 A.D [2]. Many sculptures and paintings around the world have goiter being depicted suggest the prevalence of knowledge regarding goiter among the common people during those ages.

During 1600 BC Chinese used to treat the condition with the sea weed [3]. Even though ancient doctors use to treat the condition with sea weed, the exact pharmacological basis behind this treatment was understood only after the discovery of Iodine by Bernard Courtois in 1811 [4].

Association of iodine deficiency with goiter was first discovered during 19th century by various researchers like Lugol (1786–1851) and Coindet (1774–1834). But it was in the David Marine who proved requirement of iodine for normal thyroid function in a trial conducted between 1917 and 1922 in Ohio [5]. In 1835 Case of goiter with exophthalmos were described by Robert James Graves [6]. Thyroid hormone in pure form was extracted by Edward Kendall in 1914 at Mayo clinic [7].

Major progress occurred during twentieth century in management of Graves' disease with development of different treatment modalities like radioactive iodine and thionamides. Twenty-first century was marked with development of safer surgical practices and in depth understanding of the goiter pathology leading to better management of the condition.

2. Anatomy and embryology of thyroid gland

Thyroid gland is located anteriorly in lower neck and extending between C5 to T1 vertebrae. A normal adult thyroid gland is approximately 40–60 mm longitudinal and 13–18 mm AP diameter in size [8]. Mean ultrasound volume is around 7–10 ml and weighing of 9–21 g.

Microscopically the gland is divided into lobes and lobules. Lobules are further subdivided into follicles. These follicles are made up of principal (follicular) cells which are a type of epithelial cell. These cells produce colloid (iodo-thyroglobulin).

Other types of epithelial cells seen in gland are parafollicular cells (c cell) which lie adjacent to follicles. C cell produce calcitonin.

Thyroid gland development starts by third to fourth week of gestation and originates from primitive pharynx and the neural crest cells. The development begins as a diverticulum at the dorsum of tongue. This diverticulum forms hypoglossal duct which passes from foramen caecum to infrahyoid region. The supra hyoid part of thyroglossal duct degenerates whereas the infra hyoid part develops into thyroid gland.

The gland is supplied by superior thyroid artery, inferior thyroid artery and thyroidea ima. Venous drainage is provided by superior, middle and inferior thyroid vein.

The lymphatic drainage courses to prelaryngeal, pretracheal and paratracheal lymph node.

3. Classification of goiter

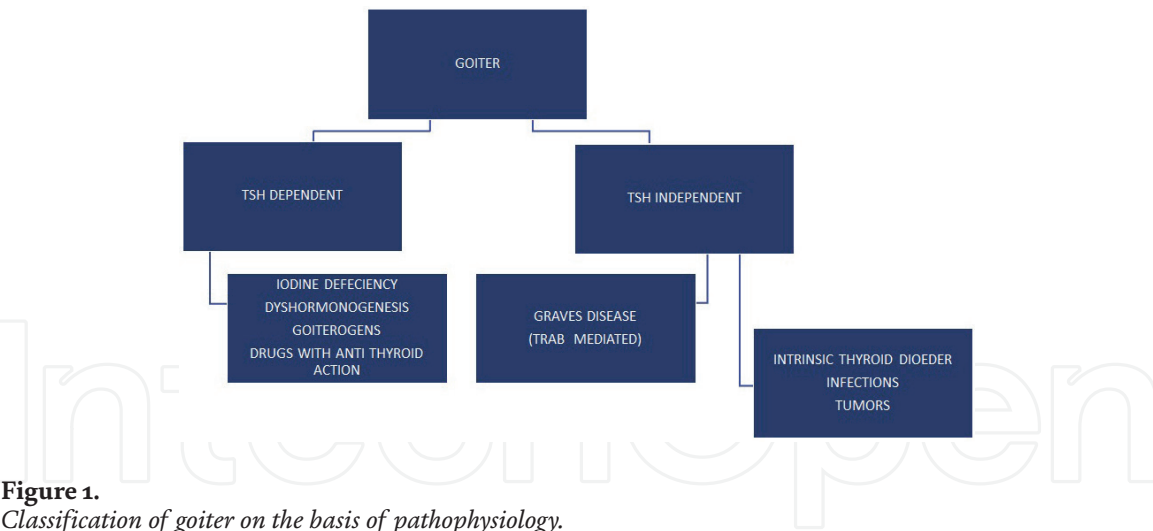
Goiter can be classified based on anatomically, etiologically, pathophysiologically and functionally (Table 1 and Figure 1).

3.1 Dyshormonogenesis

Autosomal recessive disorders (exception DUOX 2 mutation). Enzymatic defect in one of the steps of thyroid hormone synthesis. The most common cause being the deficiency of thyroid peroxidase enzyme. Prevalence is more among females.

<b>Anatomical classification of goiter</b>
Cervical goiter
Retrosternal goiter
Intrathoracic goiter
<b>Functional classification</b>
Toxic goiter
Non-toxic goiter
• Euthyroidism
• Hypothyroidism
<b>Morphological classification</b>
Diffuse goiter
Nodular goiter
• Solitary nodular goiter
• Multinodular goiter

Table 1.  
Anatomical, functional and morphological classification of goiter.



**Figure 1.**  
*Classification of goiter on the basis of pathophysiology.*

Most of the cases present clinically before third decade with as earliest as in neonatal period with goiter and hypothyroidism. In Pendred syndrome dysmorphogenetic goiter is associated with deafness.

### 3.2 Dietary factors

#### 3.2.1 Iodine deficiency

Twenty-nine percent of world population lives in area where soil is deficient in iodine, e.g., the Himalayan region in India. The most common cause of goiter worldwide is iodine deficiency. More than 30% of population having median urine iodine less than 20 mcg/l developed goiter [9]. Daily requirement of iodine is 100–150 mcg/day, but the requirement increases in pregnant and lactating women.

#### 3.2.2 Dietary goitrogens

Soy and Millet contains flavonoids which impair thyroid peroxidase activity. Cyanogenic glucosides in Cassava, Lima beans compete for iodine uptake in thyroid follicles. Similarly cruciferous vegetables like cabbage cauliflower, broccoli contains glucosinolates which also competes with thyroidal iodine uptake.

### 3.3 Drugs causing goiter

Drugs like Lithium, Amiodarone apart from Antithyroid drugs are known to cause goiter. Rare causes include Interferon Alfa, Rifampicin, Phenytoin, and Phenobarbitone.

### 3.4 Hashimotos thyroiditis

The condition is named after Japanese physician Hakaru Hashimoto. This autoimmune thyroid disorder is characterized by diffuse lymphocytic infiltration of thyroid gland along with follicular destruction. Serologically the patients have high titer of anti-thyroglobulin and anti TPO antibodies. Hashimoto's thyroiditis is the next most common cause of hypothyroidism after iodine deficiency. But subset of patient may remain clinically and biochemically euthyroid for rest of the life. The condition has female to male prevalence ratio of 7:1.

### 3.5 Multinodular goiter

David Marine and Selwyn Taylor proposed that chronic intermittent stimulus leads to variable thyroid hyperplasia resulting in multinodular goiter [10]. Various factors including genetic heterogeneity of follicular cells, secondary elevation of TSH due to iodine deficiency, goitrogens, and inborn error of thyroid hormone synthesis are considered to be factors involved in pathogenesis of condition.

### 3.6 Infiltrative thyroid disorder

Various infiltrative disorders like amyloidosis, histiocytosis, cystinosis and sarcoidosis may affect thyroid gland.

### 3.7 Graves' disease

This autoimmune condition is characterized by presence of TRAB (TSH receptor autoantibodies) in the serum. The clinical feature ranges from hyperthyroidism, orbitopathy, dermopathy and goiter.

### 3.8 Thyroid adenoma

These are benign tumors, classified as either follicular (most common form) or papillary (rare) type. Adenomas may be hyper functioning when they are termed toxic adenoma. Follicular adenoma are histopathologically divided into Fetal (micro follicular), Colloid (macro follicular), Embryonal (atypical), Hurthle cell adenoma (oxyphil or oncocytic tumor) types. Among these with the exception of colloid type all other histopathological types have potential for micro invasion.

### 3.9 Thyroid malignancies

Thyroid malignancies are classified as papillary carcinoma (most common type), follicular carcinoma, medullary thyroid carcinoma, anaplastic carcinoma, thyroid lymphoma (rare) clinical features are explained below.

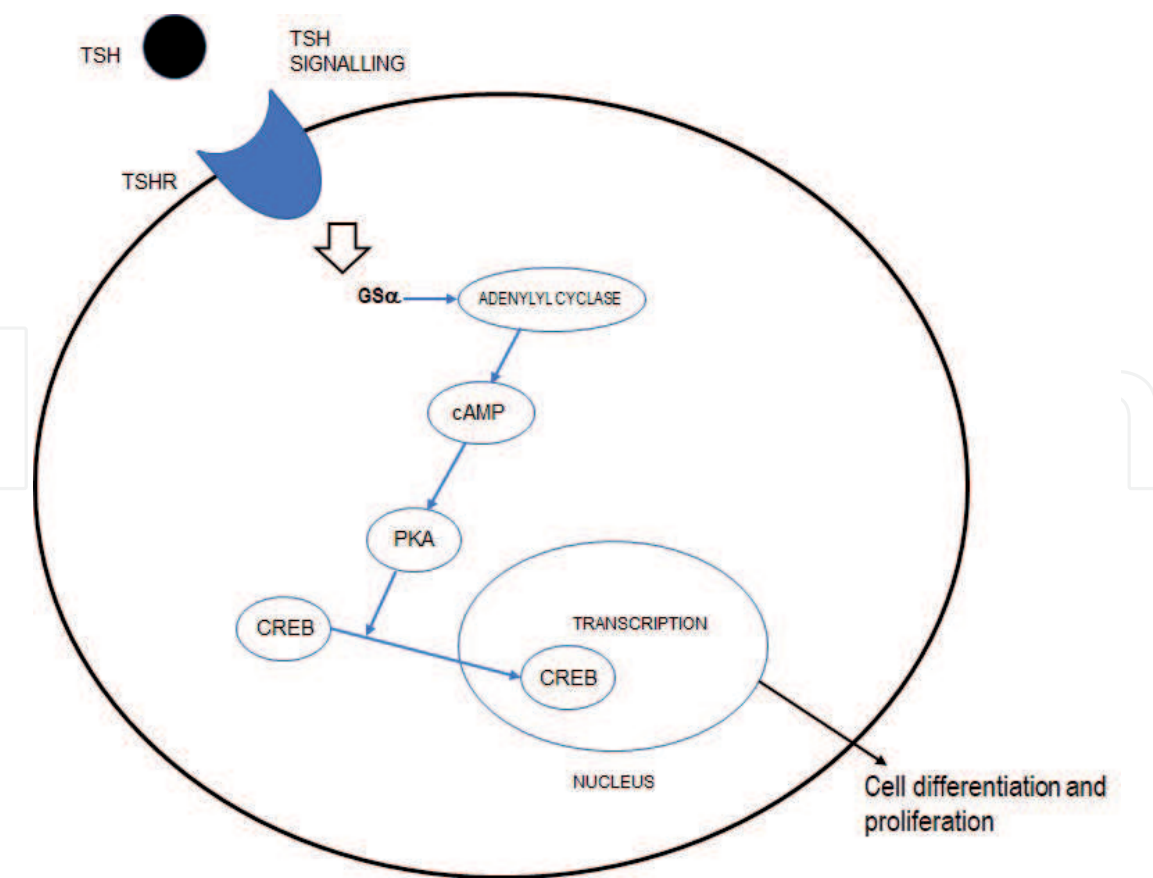
## 4. Pathophysiology of goiter

Thyroid stimulating hormone is the major trophic factor for thyroid gland. TSH acts on TSH receptors present on thyroid cells which are G protein coupled receptors. Downstream signaling leads to gene transcription leading to cell proliferation and differentiation (**Figure 2**).

The most common condition causing TSH dependent Goiter is iodine deficiency.

Goiter in chronic Hashimoto's thyroiditis is also secondary to elevated TSH levels.

In conditions like Graves' disease TSH receptors are stimulated by TSH stimulating antibodies Infection and neoplasia are examples for non-humoral causes of thyroid enlargement. Neoplastic enlargement occurs secondary to clonal expansion are usually associated with underlying genetic alterations.



**Figure 2.**  
*TSH signaling pathway.*

**5. Differential diagnosis of swelling in anterior aspect of neck**

**5.1 Approach to patient with goiter**

*5.1.1 History and examination*

Extensive history should be taken in all patients with goiter (**Table 2**). Following points should be highlighted while taking history like place of residence (patients from high altitude areas iodine deficient), dietary iodine intake, family history of thyroid disorders, radiation exposure and any history of goitrogenic drugs intake.

1. Goiter
2. Neurogenic tumors
3. Thymoma
4. Bronchogenic cysts
5. Pericardial cysts
6. Lymphoma
7. Teratoma
8. Thyroglossal cyst

**Table 2.**  
*Differential diagnosis of swelling in anterior aspect of neck.*



Major concern of nodular thyroid disorder is development of malignancy. Hence history regarding risk factors for malignancy like age (<20 and >60 years), male sex, previous radiation exposure, family history of thyroid malignancy, MEN 2A syndrome should be obtained.

5.2 Clinical evaluation

5.2.1 Physical examination

The thyroid examination is done with patient in sitting or standing position. Goiter is classified according to World Health Organization (WHO) classification [11] (Table 3).

Thyroid gland is palpated from behind the patient with neck relaxed and looked for size, consistency, nodules, and tenderness and lymphadenopathy.

Consistency of the enlarged gland helps in making diagnosis. Lesions which are hard for palpation suggest malignancy but rarely Reidel’s thyroiditis may present like this. The gland feels rubbery in Hashimoto’s thyroiditis. Diffuse tenderness can be elicited in sub-acute Thyroiditis.

Palpable thrill and hearing of bruit during auscultation over the gland suggest hypervascularity, it is seen in condition like Graves’ disease.

During local examination one should look for lymphadenopathy and following group of lymph nodes should be examined (1) supraclavicular nodes, (2) anterior cervical chain lymph nodes, (3) posterior cervical chain lymph nodes, and (4) sub-mental lymph nodes.

5.2.1.1 Pemberton’s maneuver

The patient is advised to rise both the arm till they touch the face on respective sides. The test is considered positive if patient develops facial plethora. Thyroid gland obstructing thoracic inlet which lead to venous obstruction is considered to be the underlying mechanism.

Grade 0: No goiter is palpable or visible.
Grade 1: Palpable goiter, not visible when neck is held in normal position
Grade 2: A clearly swollen neck (also visible in normal position of the neck) that is consistent with a goiter on palpation

Table 3.  
WHO classification of goiter.

Increased sweating	Onycholysis
Hyperpigmentation	Thinning of the hair
Systolic hypertension	Increase appetite
Weight loss	Palpitation
Heat intolerance	Insomnia
Hyper defecation	Menstrual irregularity oligo-/hypomenorrhea
Eye: lid retraction, lid lag, exophthalmos, ophthalmoplegia	

Table 4.  
Symptoms and signs of hyperthyroidism.

General	Dermatological	Neuromuscular
<ul style="list-style-type: none"><li>• Lethargy</li><li>• Somnolence</li><li>• Weight gain</li><li>• Cold Intolerance</li></ul>	<ul style="list-style-type: none"><li>• Dry flaky skin and hair</li><li>• Myxedema</li><li>• Malar flushes</li><li>• Vitiligo</li></ul>	<ul style="list-style-type: none"><li>• Aches and pains</li><li>• Muscle stiffness</li><li>• Carpel tunnel syndrome</li><li>• Hoarseness</li></ul>
Cardiovascular	• Carotenemia	• Cerebellar ataxia
<ul style="list-style-type: none"><li>• Bradycardia</li><li>• Angina</li><li>• Congestive heart failure</li><li>• Pericardial Effusion</li></ul>	Gastro-intestinal	• Delayed deep tendon reflex
	<ul style="list-style-type: none"><li>• Constipation</li><li>• Ileus</li><li>• Ascites</li></ul>	• Myotonia
Hematological	Reproductive system	• Depression
<ul style="list-style-type: none"><li>• Anemia</li></ul>	<ul style="list-style-type: none"><li>• Infertility</li><li>• Menorrhagia</li></ul>	• Psychosis

**Table 5.**  
*Signs and symptoms of hypothyroidism.*

General examination includes looking signs of hyperthyroidism, hypothyroidism and metastatic involvement of different organs in suspected thyroid malignancy.

Signs and symptoms of hyperthyroidism and hypothyroidism are enlisted in **Tables 4** and **5** respectively.

Symptoms of thyroid malignancy: Most commonly manifest as solitary nodule which are usually painless in nature. Malignant conversion of thyroid nodules is more common among males than females. Hoarseness of voice and dysphagia suggest local involvement of recurrent laryngeal nerve and digestive tract.

Malignant nodules on palpation range from soft to hard consistency. Regional lymphadenopathy suggests lymph node metastasis.

5.2.2 Investigation

5.2.2.1 Thyroid function test

Thyroid function test is evaluated starting with measurement of measurement of serum TSH level. If TSH level are less than normal values then next step is to measure T3 and T4 level (total T4: 4.5–12.5 µg/dL, free T4: 0.8–1.7 ng/dL, total T3: 0.8–2.0 ng/ml, free T3: 2.3–4.2 pg./mL) suggest subclinical hyperthyroidism whereas elevated T3 and T4 level suggest overt hyperthyroidism. Both overt and subclinical hyperthyroidism suggest Graves’ disease or toxic MNG.

If TSH levels are less than normal value then next step is to measure T4 level. Subclinical hypothyroidism is considered when value of TSH levels between 5 and 10 µU/ml with normal T4 level. Iodine deficiency and Hashimoto’s thyroiditis are the most common cause of subclinical or overt hypothyroidism.

5.2.2.2 Thyroid peroxidase antibodies

Presence of the antibody in serum suggest autoimmune thyroid disorder

5.2.2.3 Thyroid ultrasound

Even though all patients with enlarged thyroid gland requires sonographic assessment to rule out malignancy, risk decreases in patients having TSH below normal or in low normal range. There are certain indications which make ultrasound assessment



mandatory like palpable solitary nodule, palpable multinodular goiter, and suspicion of nodule in patient with difficult neck palpation, rapid growth of a goiter, thyroid asymmetry, firm consistency, tenderness, normal TSH and negative TPO antibodies.

#### 5.2.2.4 Fine-needle aspiration cytology

Indications for FNAC include rapid growth of the swelling which suggest malignant transformation, signs of inflammation (abscess formation) and nodules with indeterminate or suspicious features (ultrasound proven).

#### 5.2.2.5 Computed tomography of neck

Computed tomography of neck not usually advised is required rarely to assess the extension of large cervical goiters and sub sternal goiters.

#### 5.2.2.6 Technetium-99 m ( $^{99m}\text{Tc}$ ) thyroid scans/radioiodine uptake scans

Routine use of thyroid scintigraphy is not indicated in the assessment of goiter. A hot area in scintigraphy suggest benign lesion which can be of help to rule out malignant lesions when FNAC report of the thyroid nodules are equivocal. When TSH level is low and clinical features are suggestive of hyperthyroidism technetium-99 scan/Radio iodine uptake scan are useful to differentiate between Graves' disease, thyroiditis and toxic adenoma.

## 6. Treatment

Treatment of goiter depends on whether TSH levels are normal or abnormal.

If TSH is elevated than normal, Levothyroxine supplementation is given for patient with overt hypothyroidism starting with a dose of 1.6 mcg/kg body weight per day in non-pregnant adults.

There are certain Indications for treatment of subclinical hypothyroidism like Anti-TPO positivity, menstrual irregularity, infertility, chronic kidney disease, pregnancy.

If TSH is less than normal range then the treatment modality depends on the nature of the illness in Graves' disease we have got three effective treatment modalities, i.e., thionamides (anti-thyroid drugs), radioiodine or surgery. Starting dose of Methimazole ranges from 10 to 40 mg per day in divided doses initially followed by single daily dose. Beta blockers are used for relief of tachycardia in non-asthmatic patients.

In multinodular goiter and toxic adenoma treatment modality is either radioiodine ablation surgery.

Iodine radioisotope I-131 is usually used for radioiodine ablation. It takes 6–18 weeks for thyroid tissue ablation post radioiodine administration. Treatment of subclinical hyperthyroidism is considered in patient older than age of 65 years and patient with other comorbidities like heart disease, osteoporosis, and post-menopausal women not on HRT.

Surgery is indicated in patients with large goiters with compressive symptoms, malignancy, and failed medical therapy.

## 7. Conclusions

The goiter is a known disorder affecting females more than males. It has various etiologies classified depending on the levels of TSH. The treatment of goiter is according to the etiology.

## Conflict of interest

The authors declare no conflict of interest.

## Author details

Dhananjaya Melkunte Shanthaiah<sup>1</sup>, Piyush Gupta<sup>2</sup> and Neeraj Kumar Agrawal<sup>1\*</sup>

<sup>1</sup> Department of Endocrinology and Metabolism, Institute of Medical Sciences - BHU, India

<sup>2</sup> Department of General Surgery, University of Massachusetts, Worcester, USA

\*Address all correspondence to: [drnkavns@gmail.com](mailto:drnkavns@gmail.com)

## IntechOpen

© 2019 The Author(s). Licensee IntechOpen. This chapter is distributed under the terms of the Creative Commons Attribution License (<http://creativecommons.org/licenses/by/3.0>), which permits unrestricted use, distribution, and reproduction in any medium, provided the original work is properly cited. 

## References

- [1] Definition of Goiter. Available from: <https://www.thyroid.org/goiter> [Accessed: 04 June 2019]
- [2] Leoutsakos V. A short history of the thyroid gland. *Hormones*. 2004;**3**:268-271
- [3] Sarkar S, Banerjee S, Sarkar R, Sikder B. A review on the history of 'Thyroid Surgery'. *The Indian Journal of Surgery*. 2016;**78**(1):32-36. DOI: 10.1007/s12262-015-1317-5
- [4] Zimmermann MB. Research on iodine deficiency and goiter in the 19th and early 20th centuries. *The Journal of Nutrition*. 2008;**138**(11):2060-2063
- [5] Carpenter KJ. David Marine and the problem of goiter. *The Journal of Nutrition*. 2005;**135**(4):675-680
- [6] Ellis H. Robert Graves: Graves' disease of the thyroid. *Journal of Perioperative Practice*. 2012;**22**(5):176-176. DOI: 10.1177/175045891202200507
- [7] Lindholm J, Laurberg P. Hypothyroidism and thyroid substitution: Historical aspects. *Journal of Thyroid Research*. 2011;**2011**:809341. DOI: 10.4061/2011/809341
- [8] Chaudhary V, Bano S. Thyroid ultrasound. *Indian Journal of Endocrinology and Metabolism*. 2013;**17**(2):219-227. DOI: 10.4103/2230-8210.109667
- [9] WHO, UNICEF, ICCIDD. Assessment of Iodine Deficiency Disorders and Monitoring Their Elimination. Geneva: WHO; 2001
- [10] Medeiros-Neto G. Multinodular goiter [Updated: September 26, 2016]. In: Feingold KR, Anawalt B, Boyce A, et al., editors. *Endotext* [Internet]. South Dartmouth, MA: MDText.com, Inc.; 2000
- [11] Azizi F et al. Assessment, Monitoring and Evaluation of Iodine Deficiency Disorders in the Middle East and Eastern Mediterranean Region. Teheran: Sara Publications; 2002