

We are IntechOpen, the world's leading publisher of Open Access books Built by scientists, for scientists

6,900

Open access books available

185,000

International authors and editors

200M

Downloads

Our authors are among the

154

Countries delivered to

TOP 1%

most cited scientists

12.2%

Contributors from top 500 universities



WEB OF SCIENCE™

Selection of our books indexed in the Book Citation Index
in Web of Science™ Core Collection (BKCI)

Interested in publishing with us?
Contact book.department@intechopen.com

Numbers displayed above are based on latest data collected.
For more information visit www.intechopen.com



Laparoscopic Retromuscular Repair of Ventral Hernias: eTEP and eTEP-TAR

Victor G. Radu

Abstract

Professors Jean Rives and Rene Stoppa published that the retrorectus space is the best for mesh placement in open ventral hernia repair and their technique has become the gold standard. This chapter presents a new technique in laparoscopic ventral hernia repair (LVHR), which combines the advantages of Rives-Stoppa procedure with the advantages of minimally invasive surgery (MIS)—it is about enhanced-view totally extraperitoneal (eTEP) approach. Restoration of the architecture of the abdominal wall and also of its functionality and the possibility to extend laterally the retromuscular dissection, if it is needed, performing transversus abdominis release (TAR) give laparoscopic retromuscular repair of ventral hernias the chance to become the gold standard in LVHR.

Keywords: eTEP, eTEP-TAR, laparoscopic ventral hernia repair, abdominal wall reconstruction, laparoscopic retromuscular repair, laparoscopic rives-Stoppa

1. Introduction

In 2012 Jorge Daes published the enhanced-view totally extraperitoneal (eTEP) approach in inguinal hernia repair. His procedure inspired Igor Belyansky to extend the retrorectus dissection cranially and cross over the midline, remaining outside of the peritoneal cavity and connecting both the retrorectus spaces. In this way he performed endoscopically the Rives-Stoppa procedure (eRS) and transversus abdominis release (eTEP-TAR), respectively, publishing a novel approach in ventral hernia repair.

1.1 History

The laparoscopic techniques in ventral hernia repair are improved from the “bridged-IPOM” performed by Leblanc in the 1990s to “IPOM plus”—a concept introduced 20 years later by J.F. Kukleta, who closed the defect and used the mesh for augmentation of the abdominal wall repaired [1, 2].

The evolution did not stop there and conversely still continues by not trying to find the ideal mesh but instead the ideal mesh placement. In 2002 Marc Miserez repaired a ventral hernia placing the mesh pre-peritoneally, and Wolfgang Reinpold placed the mesh under the rectus muscles by trans-hernial access (MILOS technique) [2–4].

In 2016, Igor Belyansky published a new technique combining the eTEP access described by Jorge Daes with the principles of TAR described by Yuri Novitsky [5–8]. The result (eRives/eTEP-TAR) is very promising, and the technique has the potential to become one of the best solutions in laparoscopic ventral hernia repair (LVHR) [6].

2. Ventral hernia classification

In 2009, a group of international experts from EHS published a new classification of ventral hernias, based on location and dimensions of the hernial defect.

The primary ventral hernias are classified as medial (epigastric and umbilical) and lateral (spigelian and lumbar). In relation with the diameter, these hernias can be small, medium, or large (**Table 1**) [9].

In a similar way, the ventral incisional hernias can be medial or lateral.

The medial incisional hernias are located in the area limited by xiphoid (cranially), pubic symphysis (caudally), and the lateral edge of rectus muscles.

An easily memorable classification from M1 to M5 going from the xiphoid to pubic bone was proposed. Therefore, they define 5 M zones [9]:

Classification of the midline incisional hernias includes five zones, from xiphoid process to pubic symphysis from 3 to 3 cm (**Figure 1**).

- M1: subxiphoidal
- M2: epigastric
- M3: umbilical
- M4: infraumbilical
- M5: suprapubic [9]

The borders of the lateral area are defined as:

1. Cranial: the costal margin
2. Caudal: the inguinal region
3. Medial: the lateral margin of the rectal sheath
4. Lateral: the lumbar region

In this way, the lateral hernias are classified as follows (**Figure 2**).

- L1: subcostal
- L2: flank
- L3: iliac
- L4: lumbar

Measurement of the incisional hernias.

EHS					
Primary Abdominal Wall Hernia Classification		Diameter cm	Small <2cm	Medium ≥2-4cm	Large ≥4cm
Midline	Epigastric				
	Umbilical				
Lateral	Spigelian				
	Lumbar				

Table 1.
The European hernia society classification for primary abdominal wall hernias [9].

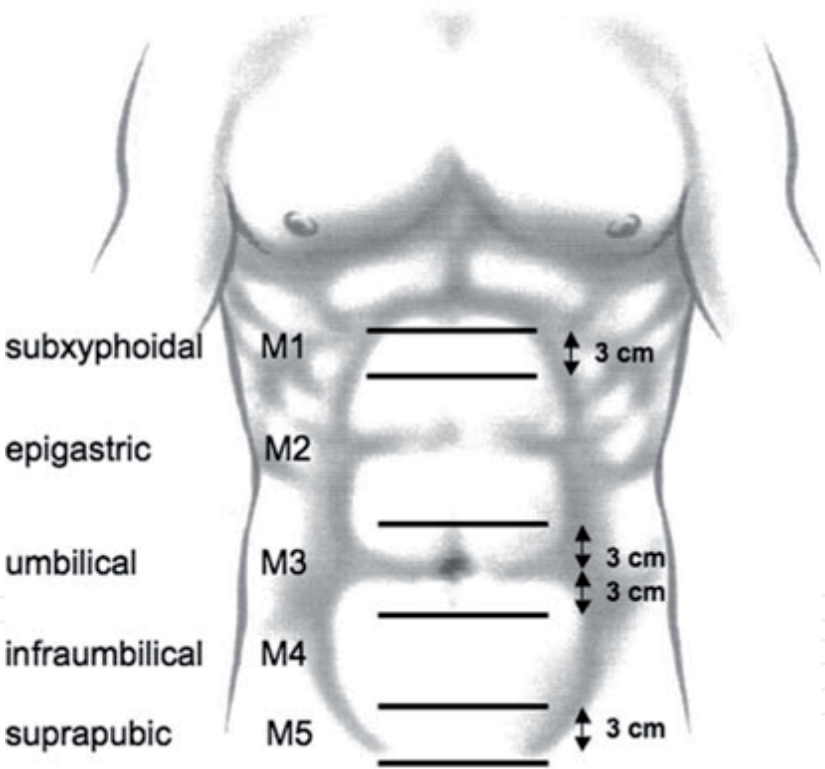


Figure 1.
To classify midline incisional hernias between the two lateral margins of the rectus muscle sheaths, five zones were defined [9].

In contrast to the primary abdominal wall hernias, incisional hernias come in many different sizes and shapes.

The length of the hernia defect was defined as the greatest vertical distance between the most cranial and the most caudal limit of the hernia defect. In case of multiple hernia defects from one incision, the length is between the cranial margin of the most cranial defect and the caudal margin of the most caudal defect (**Figure 3**).

This technique has no contraindications related to the width of the defects. As in open retromuscular surgery, the eTEP approach can be used to repair all varieties of ventral hernias, from small umbilical hernias to large and complex ventral hernias.

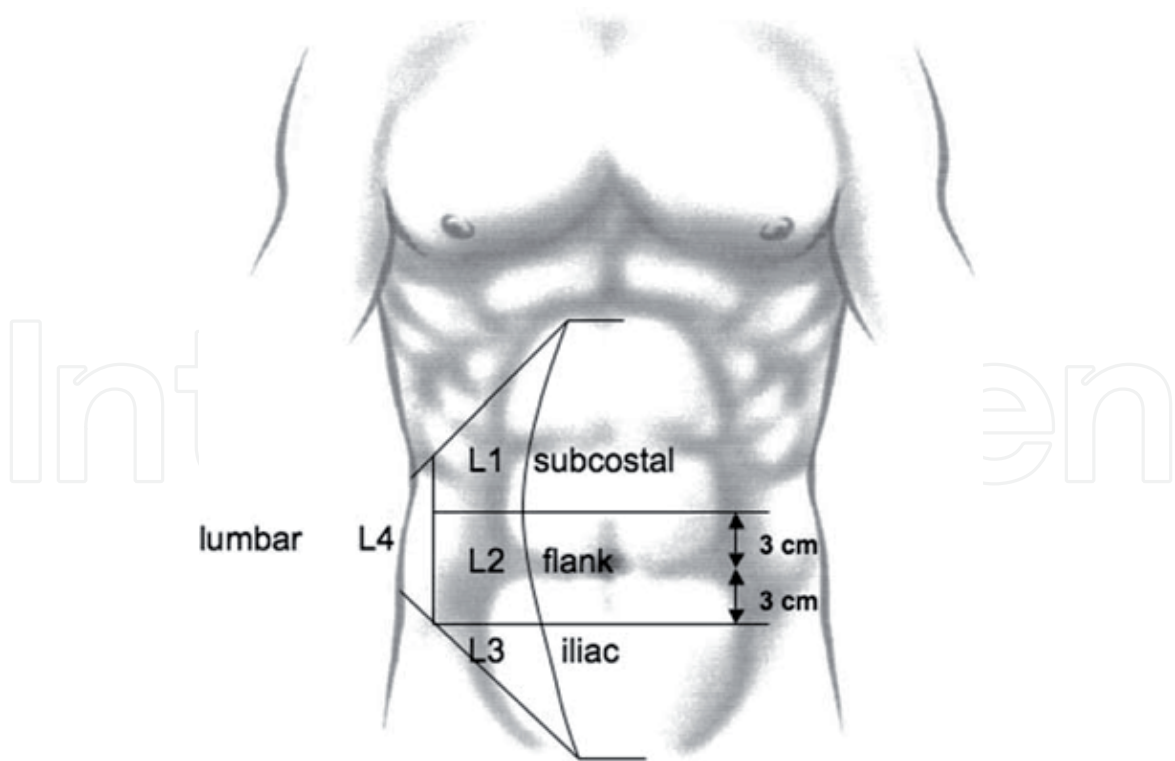


Figure 2.
To classify lateral incisional hernias, four zones lateral of the rectus muscle sheaths were defined [9].

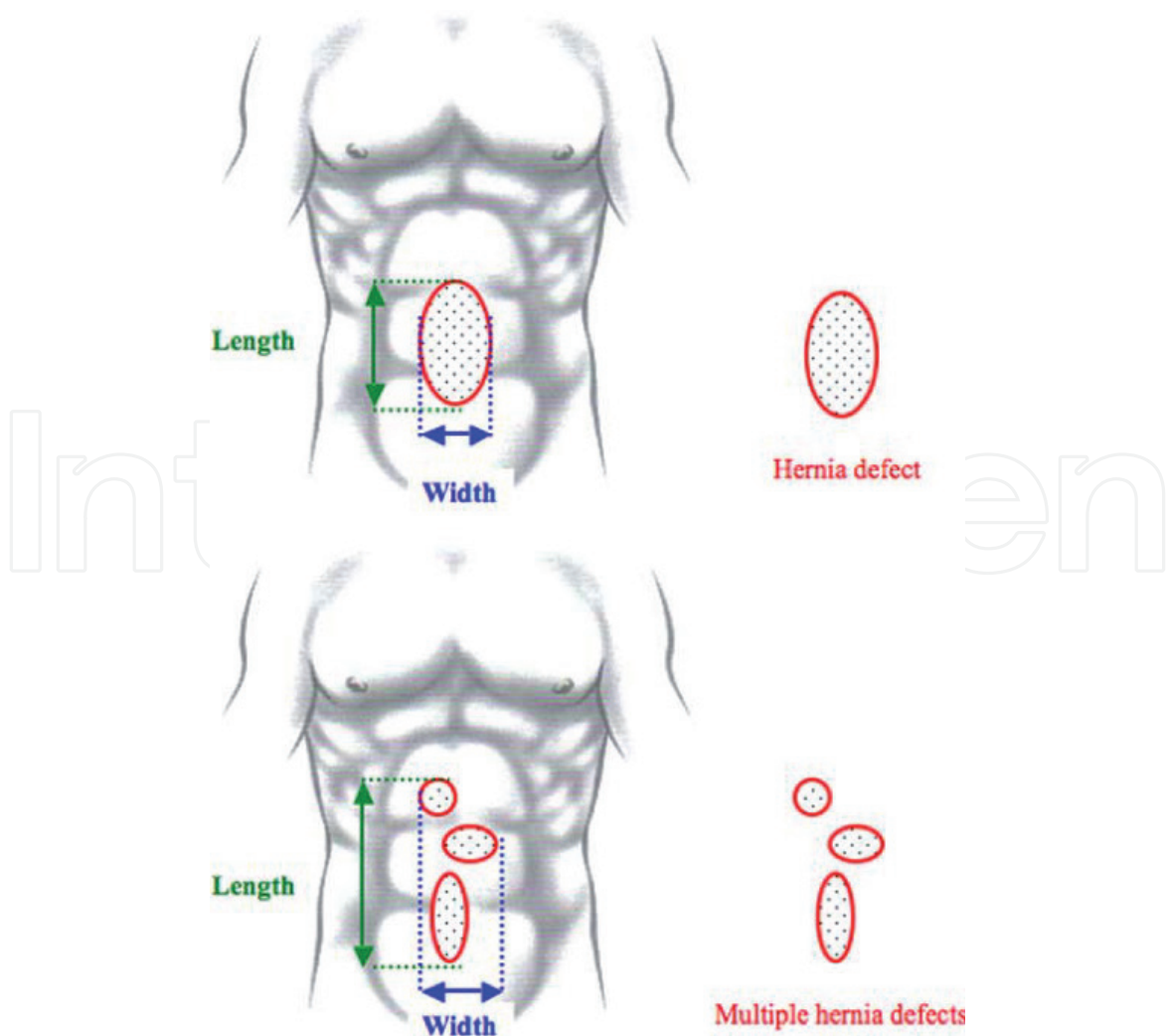


Figure 3.
Definition of the width and the length of incisional hernias [9].

3. The biomechanics of the abdominal wall and abdominal cavity

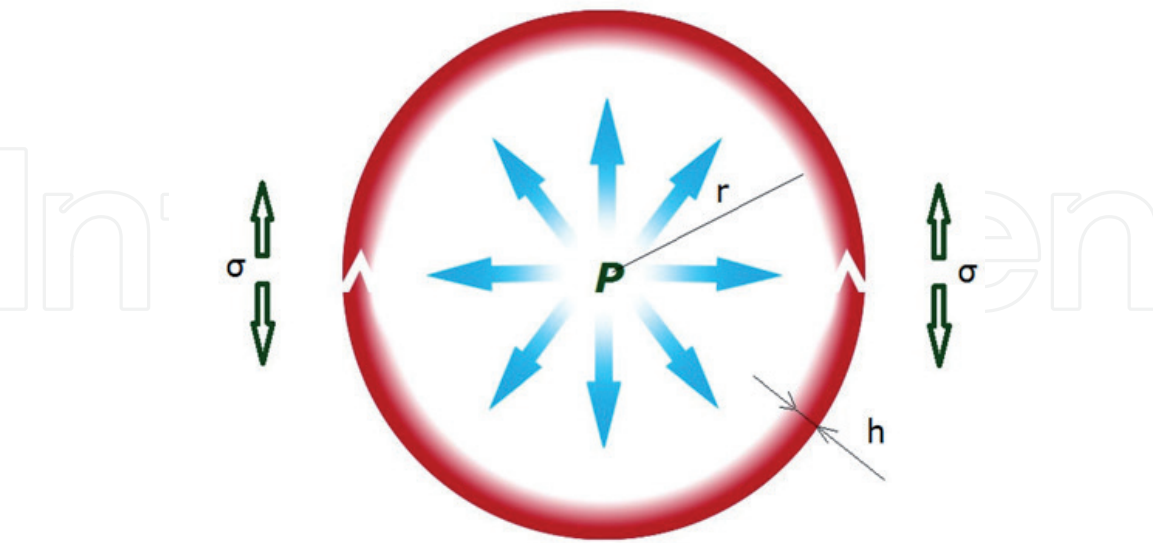
The advantages of the retrorectus dissection are well known. Once the rectus muscles are removed from their encasement in the rectus sheaths, linea alba can be restored, the muscles being able to be translated medially 3 cm, 5 cm, and 3 cm, respectively, in the upper, middle, and lower third of the abdomen, as Ramirez wrote in the paper describing his component separation technique. In this way large defects up to 10 cm width can be closed.

Because of an excellent arterial blood supply, the retrorectus space serves as a well-vascularized position where mesh prostheses become incorporated. This sublay mesh position has benefits at both a molecular level and a pure mechanical level. The perifilamentous collagen deposition on the mesh has a higher type I/III ratio compared with mesh placed onlay. The predominance of mature collagen (type I) confers a higher tensile strength of the wound [10].

The tone of the abdominal wall muscles induces an intra-abdominal pressure between 5 and 7 mmHg. According to Laplace's law, this pressure acts equally on the abdominal wall, determining a tension in the abdominal wall which is a positive tension (**Figure 4**) [11].

The restoration of architecture and functionality of the abdominal wall conducts restoration of the physiological tension in the abdominal wall. The focus of these procedures is the reconstruction of the linea alba, the “central tendon” of the abdominal wall.

The posterior layer will have the role of barrier between the mesh and the viscera. It is very important to suture the posterior layer totally tension free, to avoid rupture of the suture line. To suture without tension is possible preserving the peritoneal structures (the falciform ligament, the umbilical ligament, or/and the hernia sac) as a bridge between the posterior rectus sheaths. The resistance of the posterior layer will be charged by the mesh.



Law of Laplace: $T = P \times r$

(T = tension; P = pressure; r = radius of cavity)

$\sigma = T / h$

(σ = stress; h = wall thickness)

Figure 4.
Law of Laplace [12].

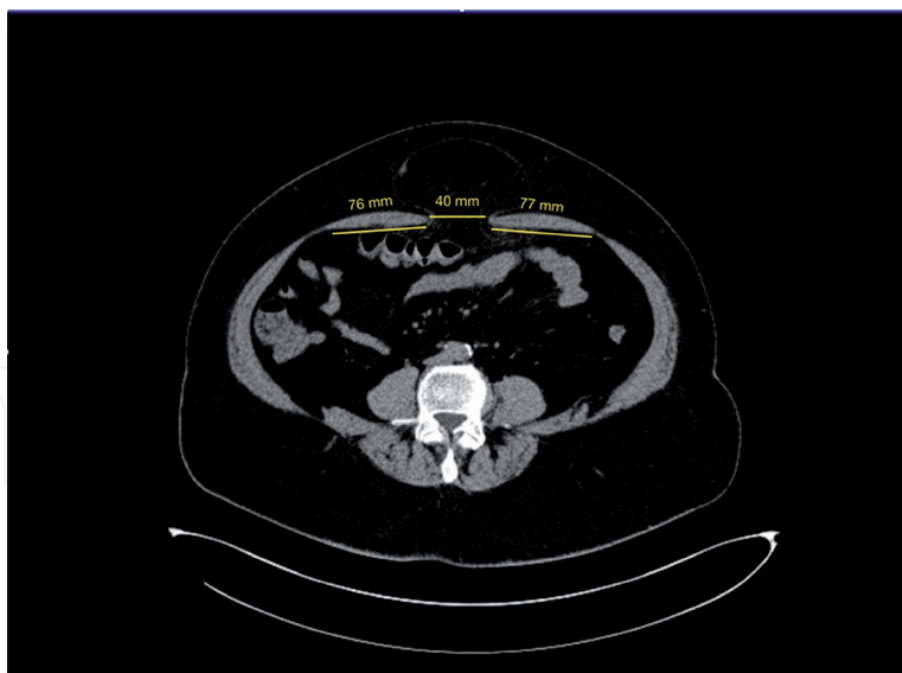


Figure 5.
Carbonell's algorithm: $2 \times RW:DW \geq 2:1$.

The preoperative CT scan is very useful. It allows us to locate the defect, measure it, and establish the strategy for the surgery.

Rives-Stoppa technique is sufficient when the sum of bilateral rectus muscle width is at least $2 \times$ maximal defect width (**Figure 5**).

Additional myofascial release (TAR) may be necessary if maximal defect width closely approximates or exceeds $2 \times$ rectus width (**Figure 6**). This is Alfredo Carbonell's algorithm, presented at the 9th Annual Abdominal Wall Reconstruction Summit, Montana, USA, 2018.

The principles of the eTEP technique are:

- Closure of the defect
- Use of uncoated mesh, placed outside of the abdominal cavity
- Minimizing fixation of the mesh, without compromising the result of hernia repair

Thinking of the abdomen as a "cylinder" with many layers, the principles mentioned above can be realized, connecting three spaces:

1. The preperitoneal space, represented in the upper part of the abdomen by the falciform ligament and in the lower part of the abdomen by the umbilical ligament
2. The retrorectus spaces
3. The pretransversalis spaces, by enlarging the retromuscular dissection laterally to the semilunaris lines

Connection of these spaces can be performed crossing over the midline.

If the hernia is located in the upper part of the abdomen, crossover of the midline will be performed below the umbilicus and anterior to the umbilical ligament,

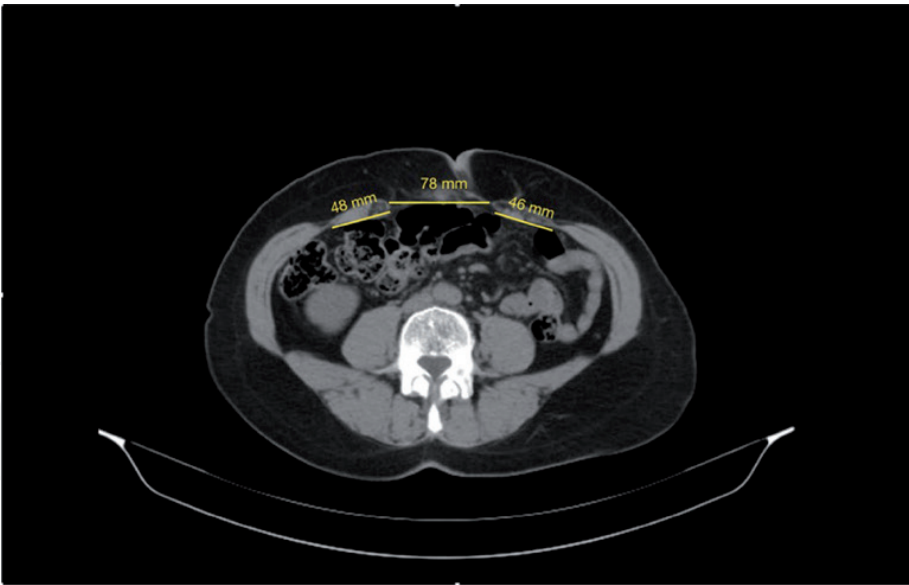


Figure 6.
Carbonell's algorithm: $2 \times RW:DW \leq 2:1$.

and, conversely, if the hernia is located in the lower part of the abdomen, crossover the midline will be performed from above, anterior to the falciform ligament.

The position of the patient is very important.

For the median ventral hernias, the patient will be placed in supine position, and the table will be flexed. In this position the distance between costal margins and iliac crests is increased, which allows an optimal port placement, and also the conflict is avoided between the surgeon's hand and the patient's thigh (**Figure 7**).

We will place the patient on a lateral decubitus in lateral locations of hernias, especially for lumbar hernia (L4), keeping also the table flexed. The technical aspects in repairing of lumbar hernias will be presented separately.

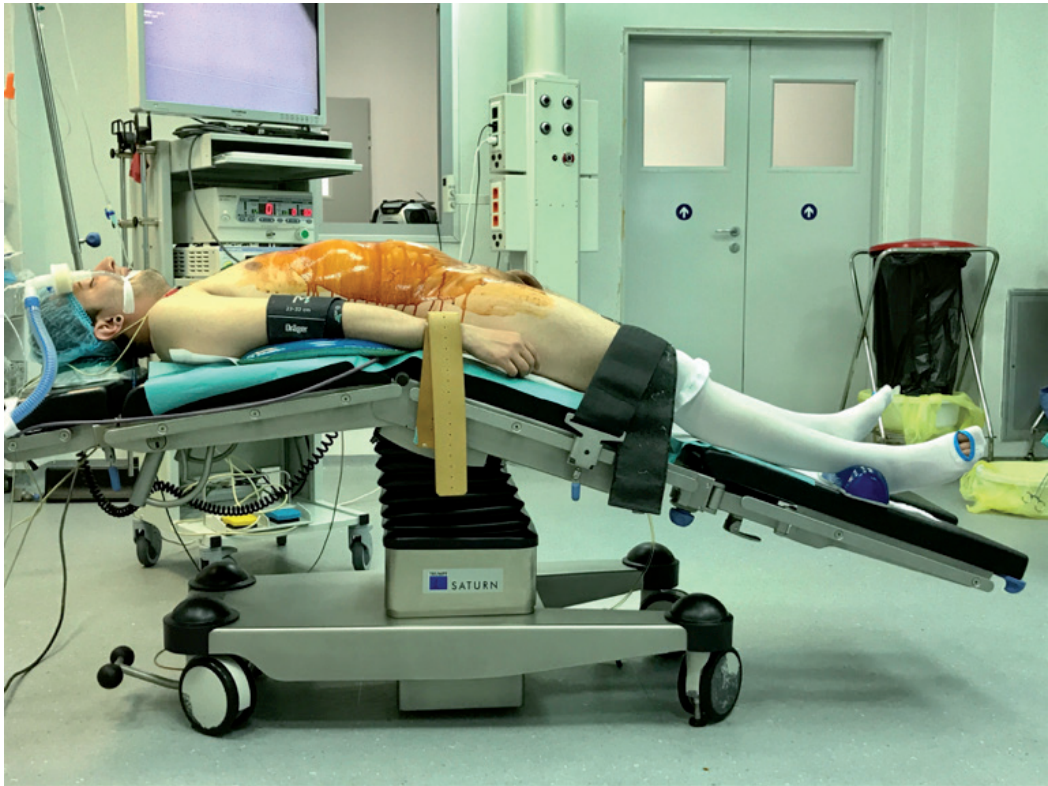


Figure 7.
Position of the patient.

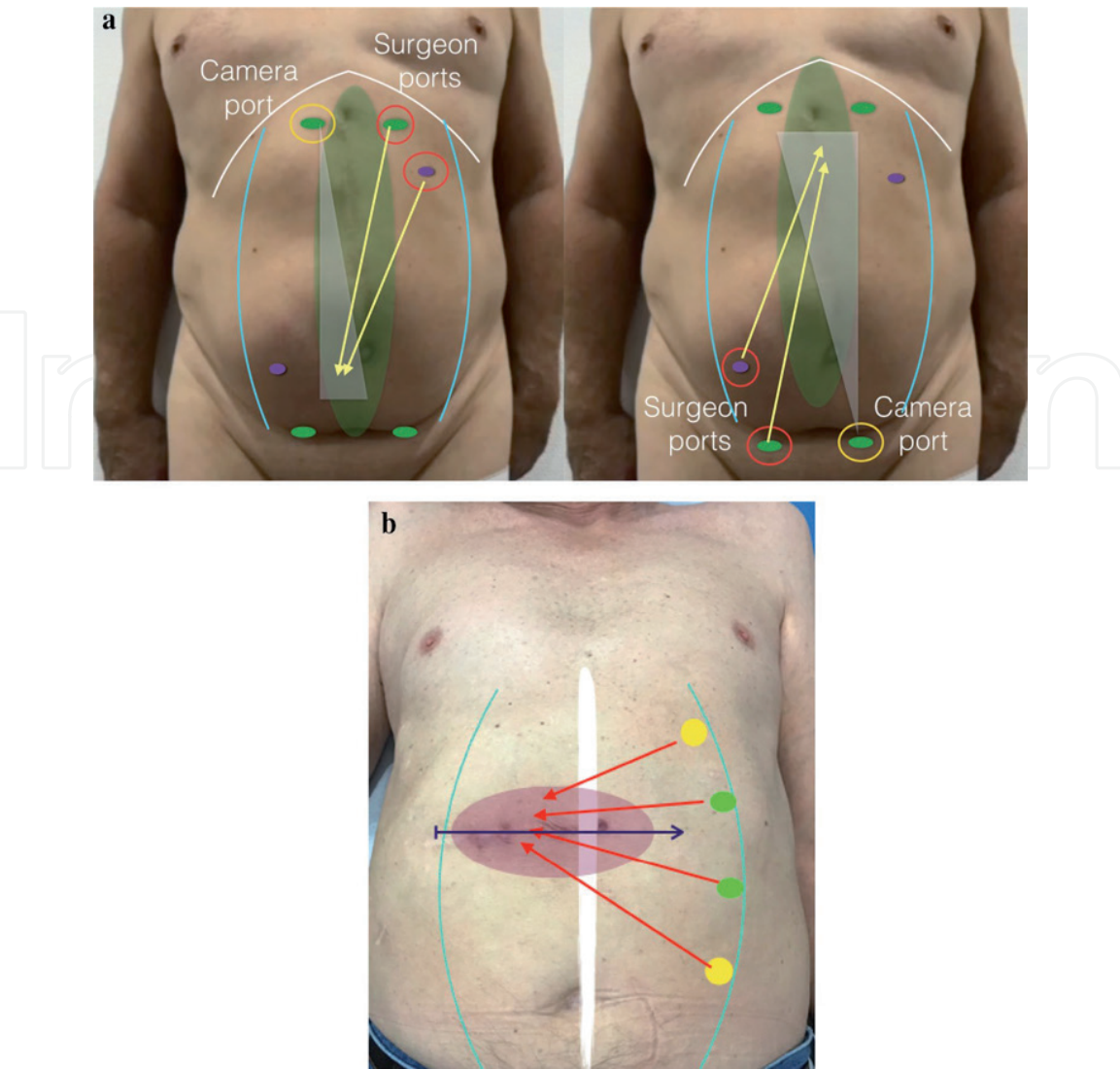


Figure 8.
(a) Port placement, (b) port placement.

The key stages of this procedure are:

1. Access of the retrorectus space and port placement
2. Crossover of the midline preperitoneally
3. Connection of both retrorectus spaces

3* TAR (when needed [6])

4. Closure of the defect
5. Mesh placement
6. Exsufflation

1. Access of the retrorectus space and port placement.

The access of the retrorectus space is performed using an optic port placed medially to the semilunaris. The linea semilunaris is the most important landmark for port placement.

As a rule, the ports have to be placed in the opposite side of the abdomen related to the hernia location (**Figure 8a** and **b**).

After the retrorectus space is achieved by CO₂ insufflation, the ports are placed under direct vision just medially to the semilunaris line (**Figure 9**).

2. It is better to cross over the midline in the virgin part of the wall, on the opposite side to where the defect is located, to minimize the risk of injury of the viscera, which can be adherent to the abdominal wall.

Crossing over the midline to the contralateral retrorectus space is performed anterior to the falciform ligament, when we start from left to right (if the defect is in the lower abdomen) (**Figure 10a**) and, respectively, anterior to the umbilical ligament (if the defect is in the upper abdomen), and dissection starts from the right to left (**Figure 10b**).

3. Connection of both retrorectus spaces.

By dissection of both retrorectus spaces (left and right) and connecting them by incising the posterior sheaths on their medial aspects, we get a common large retromuscular space (the left retrorectus space connected to the right retrorectus space). This space is linked by the preperitoneal bridge represented by the falciform ligament and/or umbilical ligament. The retrorectus dissection is limited laterally by the semilunaris lines, where the neurovascular bundles pass through the posterior sheath to the rectus muscles (**Figure 11**).

3*. TAR. When the defect is too large to be closed, the TAR procedure is added. The incorporation of TAR was found beneficial in cases with a wide defect (10 cm), tension on the posterior layer, and narrow retrorectus space (< 5 cm) or when dealing with a poor compliant abdominal wall [6]. Adding the TAR is necessary for closure of the defect and also for placement of a large mesh to obtain a good overlapping.

As a right-handed surgeon, I perform TAR from the top to bottom on the right side and bottom-up on the left.

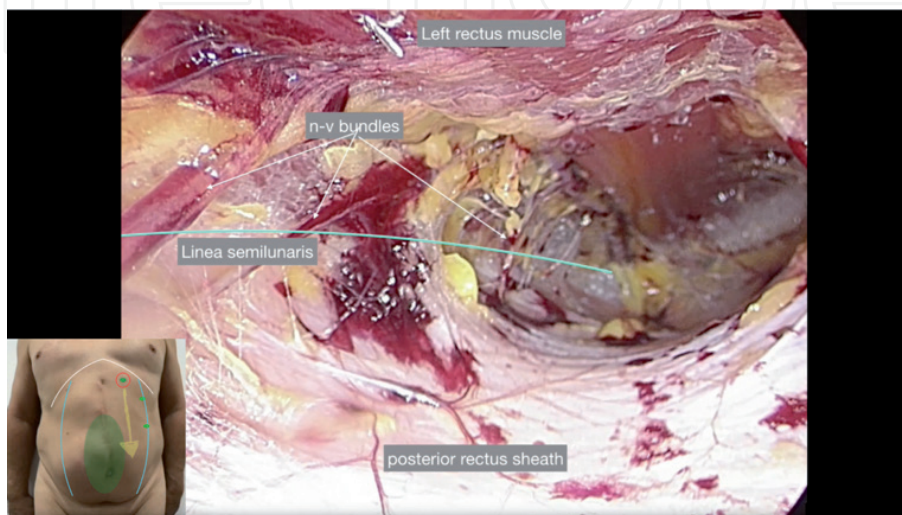


Figure 9.
Development of the retrorectus space.

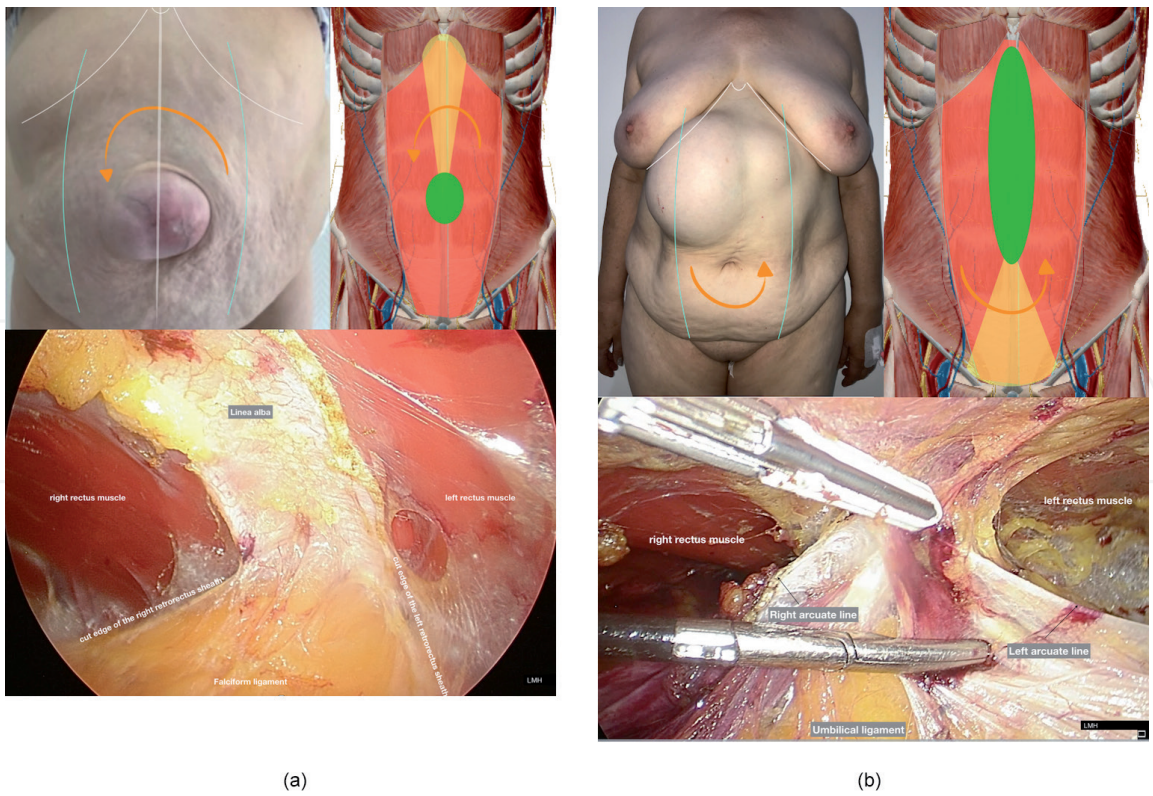


Figure 10.
(a) Crossing over the linea alba above the umbilicus. (b) Crossing over the linea alba below the umbilicus.

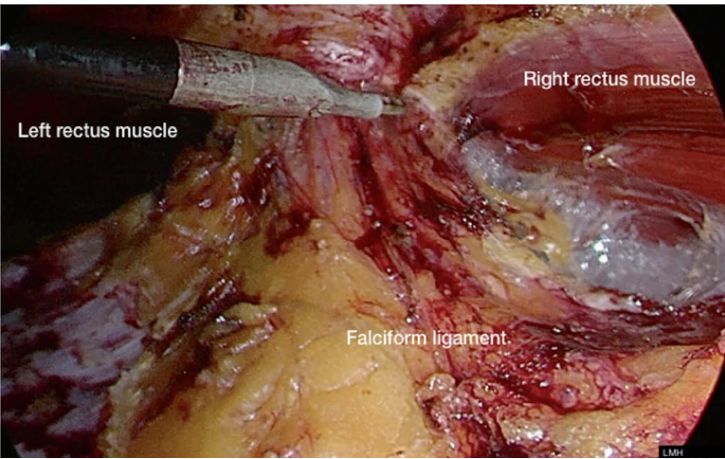


Figure 11.
Retromuscular dissection: connecting both retrorectus spaces.

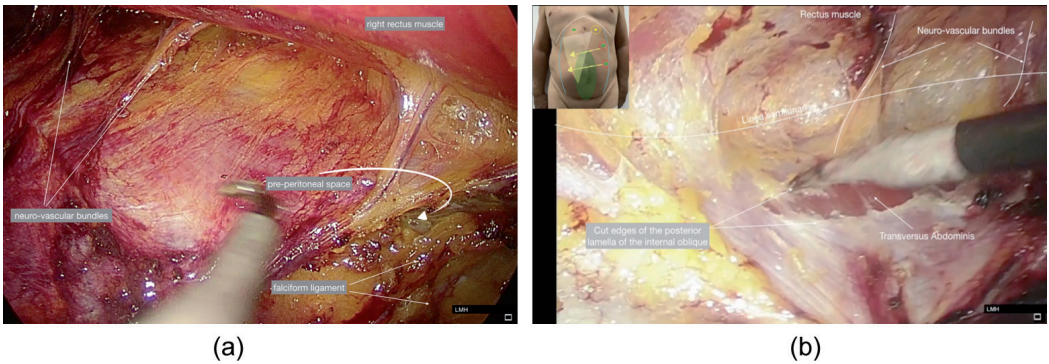


Figure 12.
(a) TAR top-bottom: Landmarks. (b) TAR top-bottom.

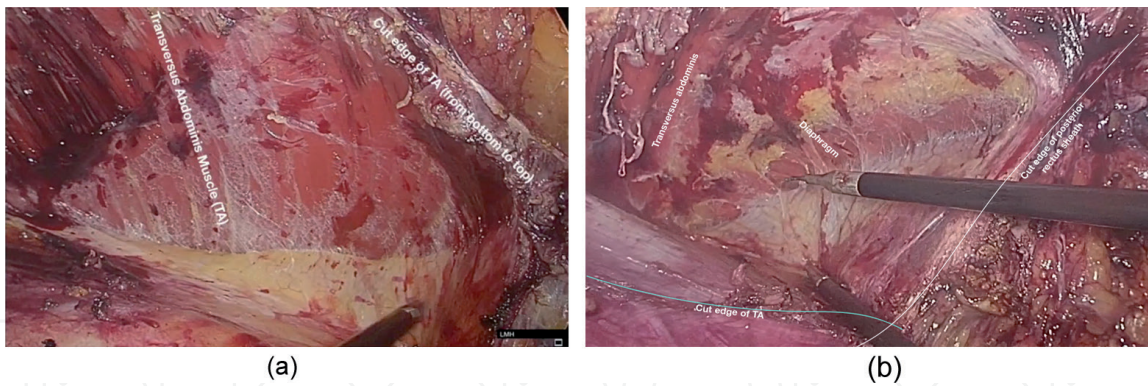


Figure 13.
(a) Posterior component separation. (b) Posterior component separation.

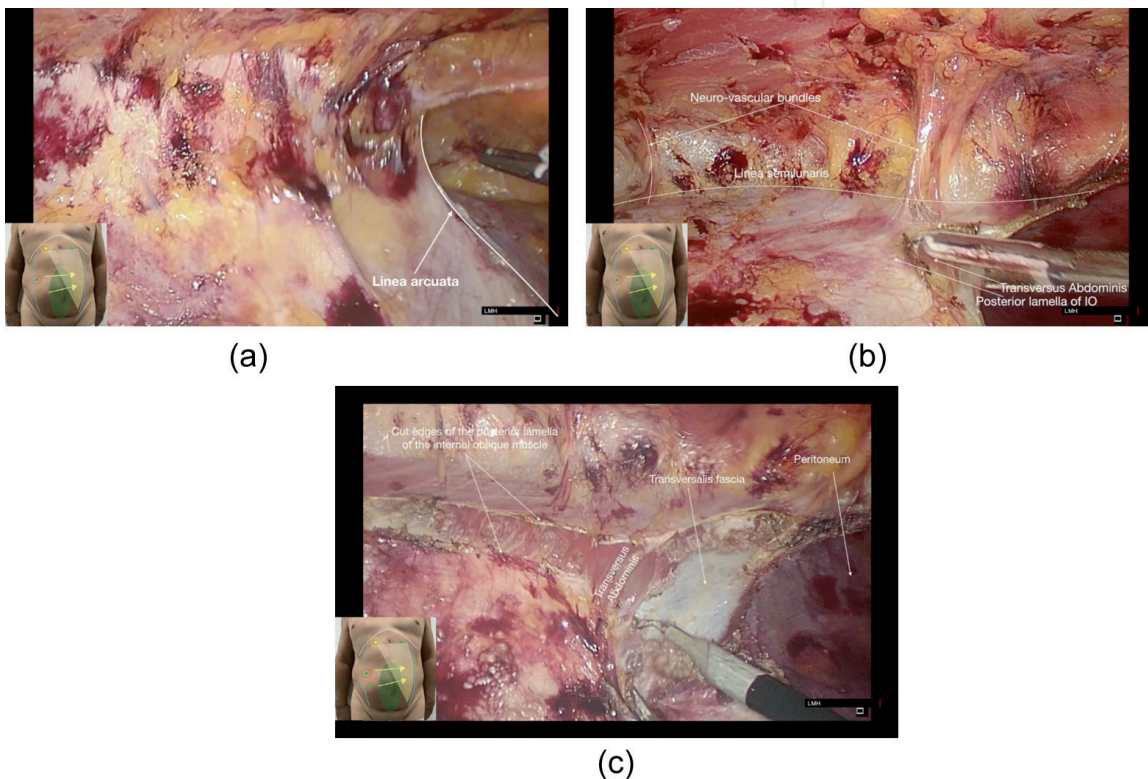


Figure 14.
(a) Landmark: linea arcuata. (b) TAR bottom-up. (c) TAR after cutting of the posterior lamella of I.O.

3.1 Top-bottom TAR

It is easy to identify the transversus abdominis fibers through transparency of the posterior rectus sheath. Before drawing the TAR cutline, it is necessary to see the neurovascular (NV) bundles and the semilunar line (**Figure 12a**). The TAR line will be placed medially to these structures.

First the posterior lamella of the internal oblique muscle is incised and then transversus abdominis (TA) (**Figure 12b**). The incision must be curved medially to protect the integrity of diaphragm when the dissection is extended cranially.

After TA is released, of course dissection is extended as lateral as possible and as cranial as possible depending on hernia location (**Figure 13 a and b**).

3.2 Bottom-up TAR

In addition to the previous landmarks discussed (linea semilunaris and NV bundles) in bottom-up TAR, identification of the arcuate line is necessary (**Figure 14 a**).

First the Bogros space is dissected, and the preperitoneal dissection is enlarged cranially, behind the posterior sheath. In this way TAR can be performed without cutting the peritoneum (**Figure 14b** and **c**).

Of course, enlarging dissection laterally up to the psoas muscle allows medial mobilization of the posterior rectus sheaths.

In the subxiphoidian hernia (M1), it is very important to extend dissection behind the diaphragm. Keeping the right anatomical plane, dissection can be extended up to the central tendon of diaphragm (**Figure 15**). It is important to mention that in all the cases, there is a landmark of the limit between the transversus abdominis and diaphragm. This limit is represented by a thin fatty tissue—“the yellow line” (**Figure 16**).

In the suprapubic hernia (M5), a large retropubic prevesical dissection is recommended to obtain a good overlap.

Some aspects to keep in mind:

- TAR lines must be curved medially to the top to connect to subxiphoidian space and protect integrity of the diaphragm.
- The TA and diaphragm are in the same anatomical plane; they are separated by a thin fat tissue, which is very constant.
- In caudal direction, the release of TA must pass the arcuate line to get a large fascial flap, and there is no tension in the suture of the posterior layer.

4. Closure of the defect and restoration of linea alba

The defect in the posterior layer has to be closed as barrier between the mesh and the bowel (**Figure 17**).

Restoration of the linea alba is the aim of this technique. This is achieved closing the defect by suturing the anterior rectus sheaths on midline (**Figure 18**).

It is recommended to keep in the suture the peritoneal sac; in this way dead space is avoided, and postoperative seroma occurrence is prevented.

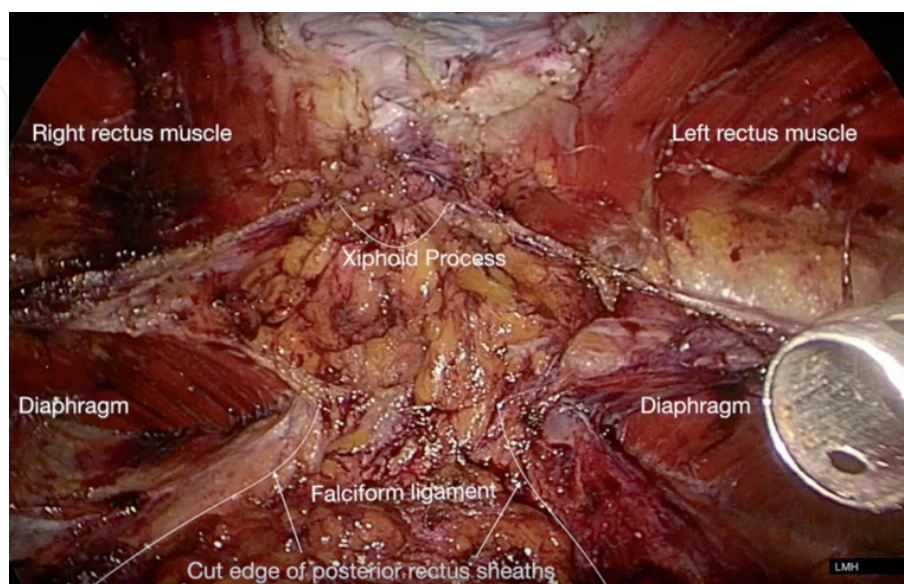


Figure 15.
Dissection behind the xyphoid process.

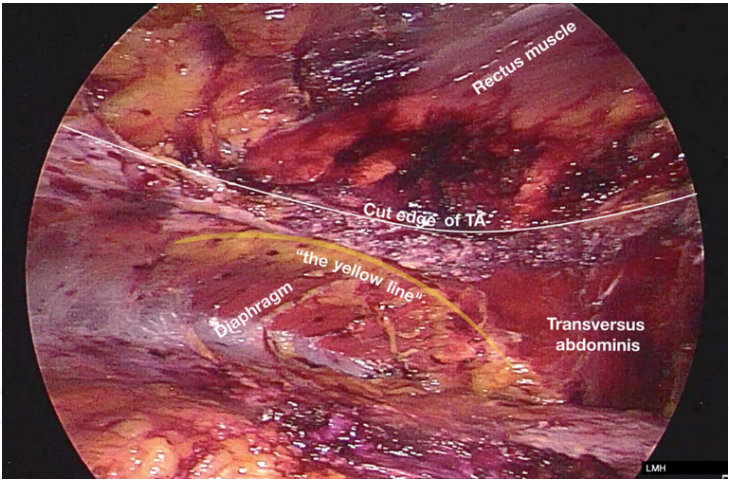


Figure 16.
“Yellow line”: The limit between the transversus abdominis and diaphragm.

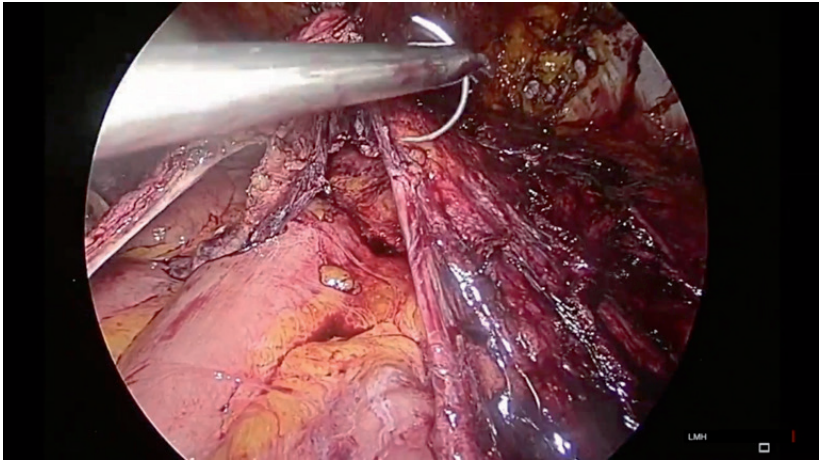


Figure 17.
Closure of the posterior layer.

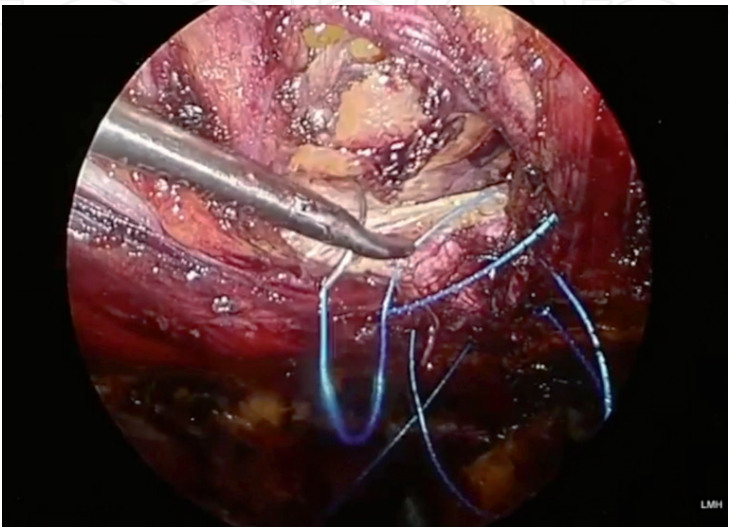


Figure 18.
Restoration of linea alba.

5. The mesh placement into the retrorectus space will be done after measurement of the entire dissected area which has to be covered by the mesh (**Figure 19**).

Usually I do not fix the mesh. A large dissection and a good overlapping, even posterior to the bones (pubic bones or costal margin) added to a correct closure of the defect, is enough for mesh fixation.

In our practice, after correct dissection and thorough hemostasis, we do not consider drainage necessary.

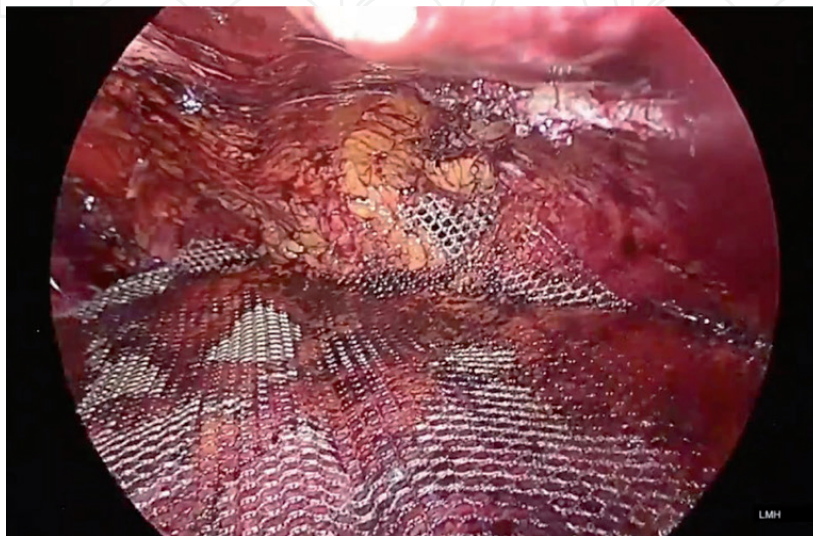


Figure 19.
Mesh placement.

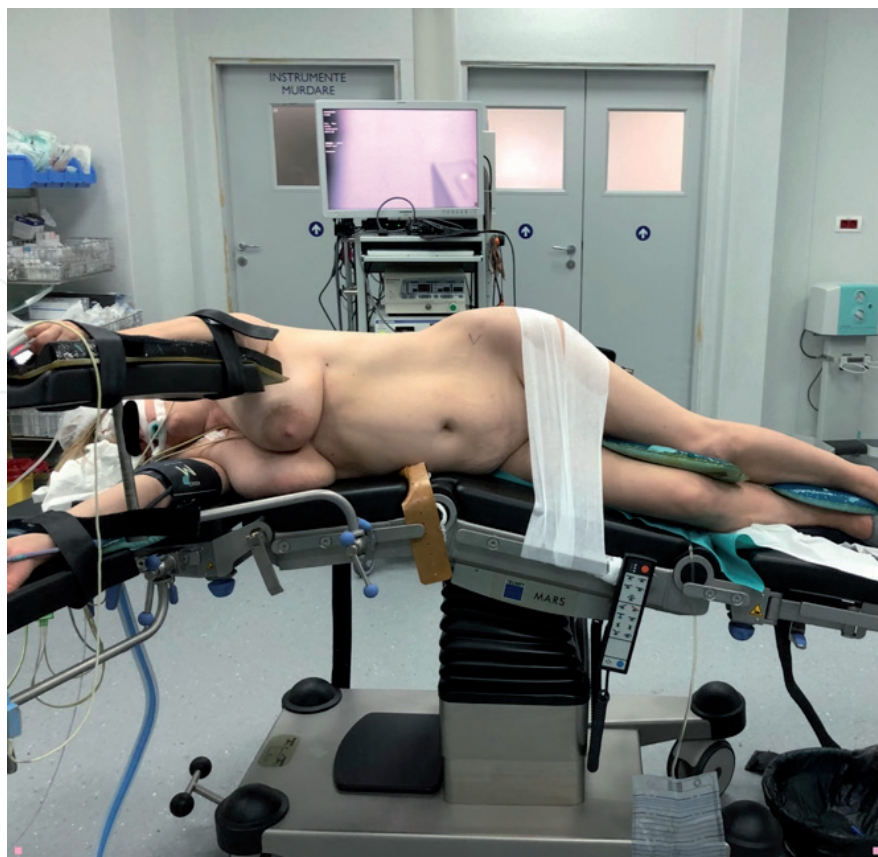

Figure 20.
Position of the patient in sTEP L4 hernia repair.

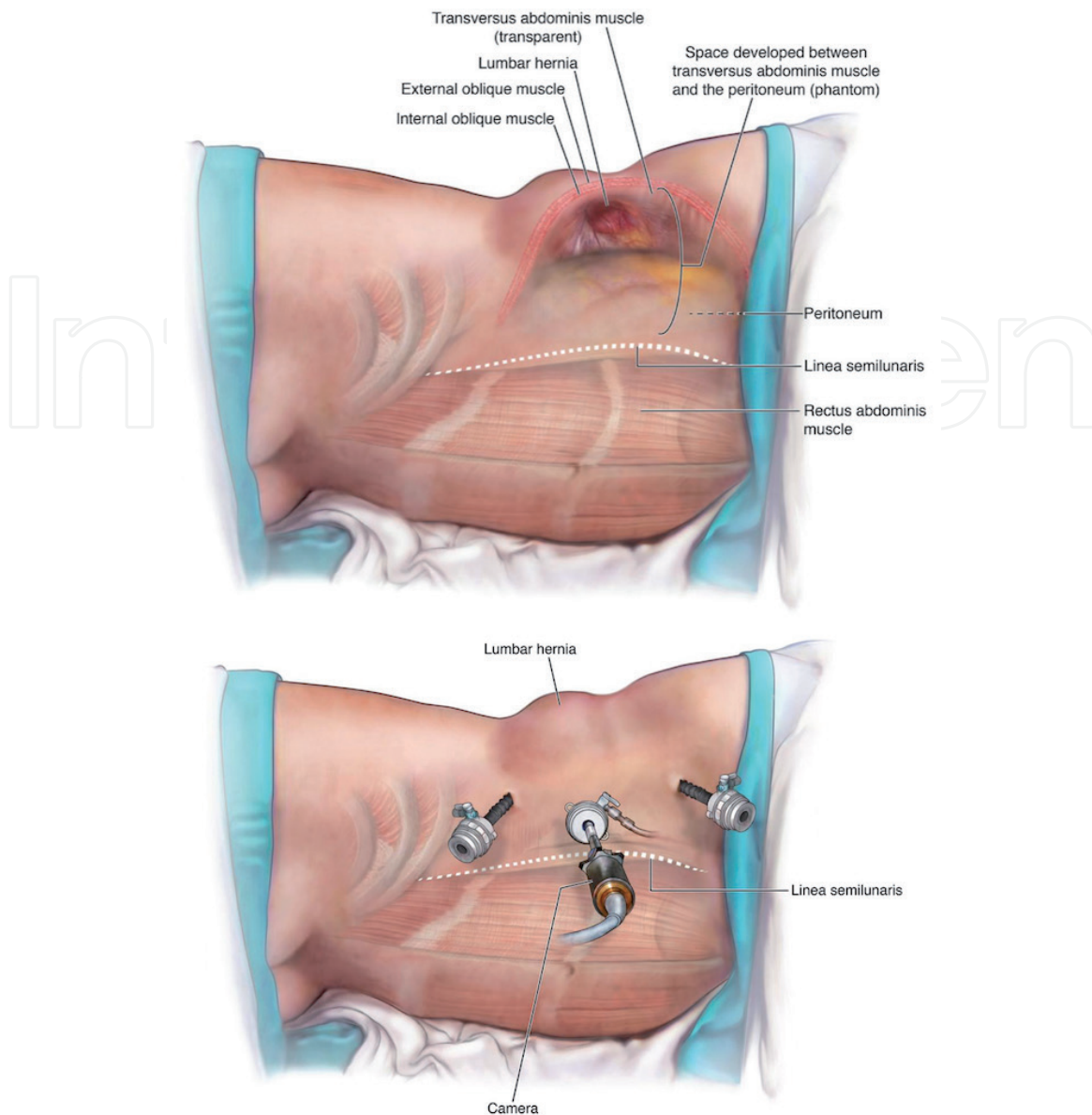


Figure 21.
 Development of the pretransversalis space, laterally to the linea semilunaris and port placement. (Courtesy of Dr. Jorge Daes).

6. Slow exsufflation, under direct vision, allows us to ensure the mesh remains in the correct position

A different approach is performed for lumbar hernia repair (L4).

The position of the patient is on lateral decubitus, and the table is also flexed to increase the distance between the costal margin and the iliac crest (**Figure 20**).

The landmark for port placement is also lateral edge of the rectus muscle, but the ports will be placed laterally to this line.

The aim is to develop the retromuscular space without penetration into peritoneal cavity, close the defect, and place a mesh outside of the abdominal cavity (**Figure 21a and b**).

For that the key stages of the procedure are:

1. Insufflation of the peritoneal cavity and placing a port inside, in the hypochondrium, to identify the rectus muscle.
2. Development of preperitoneal pretransversalis space and port placement.

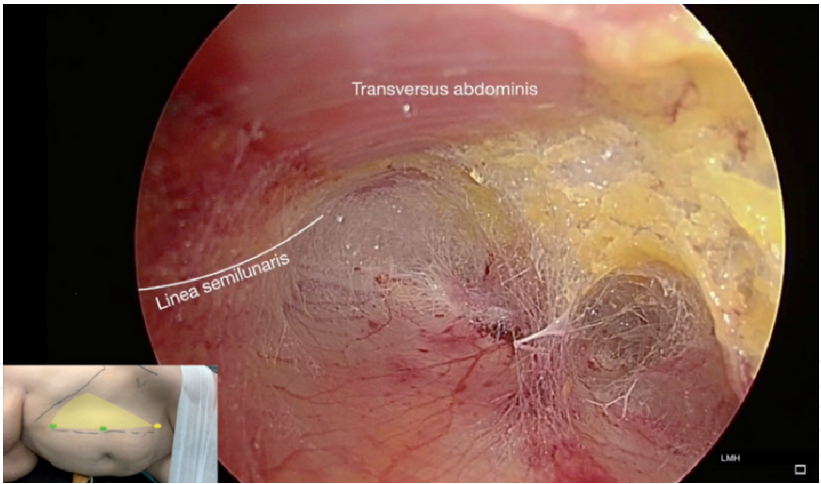


Figure 22.
Pretransversalis space, laterally to the linea semilunaris.

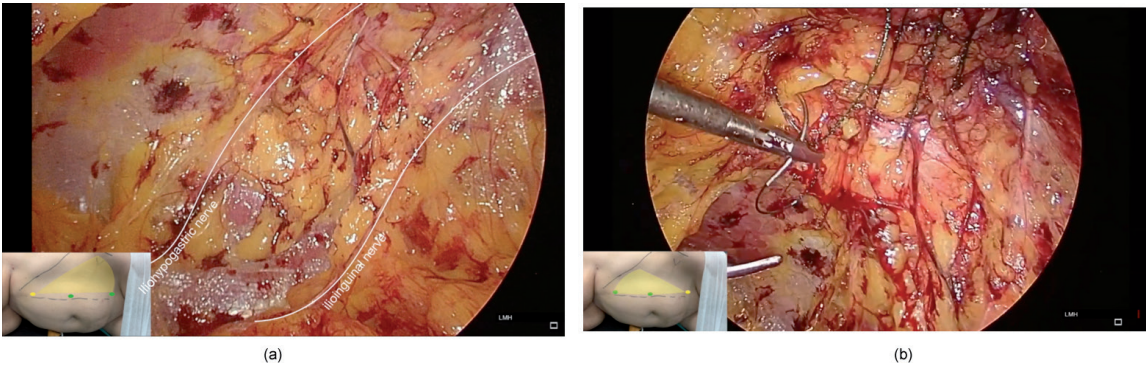


Figure 23.
(a) Iliohypogastric and ilioinguinal nerves must be protected during dissection in the lumbar region. (b) closure of the defect.

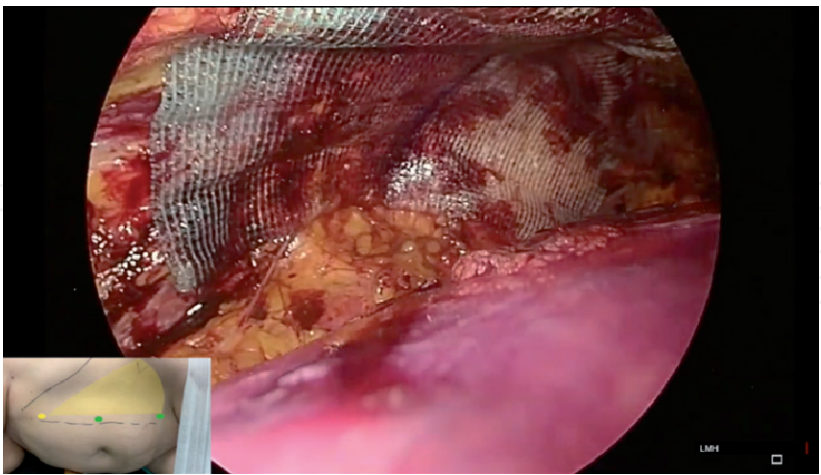


Figure 24.
Mesh placement.

Under direct vision, a second port is placed laterally to the semilunaris line and preperitoneally, and the gas to this port is connected to develop the preperitoneal space. An optic port is useful at this step.

The third port is placed also under direct vision, laterally to the semilunaris line.

Now, keeping the first port site will retract this port from the peritoneal cavity and change its direction laterally, in the preperitoneal space already created (**Figure 22**).

3. Dissection and closure of the defect (**Figure 23a and b**)

It is very important to understand the retroperitoneal lumbar anatomy, because during the retromuscular dissection, the iliohypogastric, ilioinguinal, and femoral-cutaneous nerves will come across and must be protected (**Figure 23**).

4. Mesh placement is the last step, respecting the overlap principle. Usually a self-gripping mesh is placed or a polypropylene mesh fixed with glue (**Figure 24**).

5. Slow exsufflation, under direct vision, allows us to ensure the mesh remains in the correct position.

3.3 Postoperative care

Soon postoperatively the patients are encouraged for an active mobilization. We do not recommend binders, but if the patients are more comfortable with binders, of course we accept to put it.

Coffee and chewing gum are recommended as soon as possible, and a liquid-semisolid diet is allowed for dinner. The level of pain after this surgery is usually very low. On our first study related to eTEP technique, we mentioned that in mean an eTEP patient gets 2.7 doses of painkiller (NSAI) for every 24 h of hospital stay.

The median length of hospitalization was in this study less than 24 hours postoperatively, even for eTEP-TAR cases. Usually the patients are discharged on the following day to their residence.

We began to actively assess the quality of life of our patients, and they filled out our questionnaire; in the study we published the results of questionnaires filled out by 42 from 60 patients which are expressed below:

In conclusion the eTEP techniques in ventral hernia repair (eRS and eTEP-TAR) combine the advantages of open retromuscular technique with the advantages of MIS.

Author details

Victor G. Radu

Life Memorial Hospital, Medlife, Bucharest, Romania

*Address all correspondence to: dr.victor.radu@gmail.com

IntechOpen

© 2020 The Author(s). Licensee IntechOpen. This chapter is distributed under the terms of the Creative Commons Attribution License (<http://creativecommons.org/licenses/by/3.0>), which permits unrestricted use, distribution, and reproduction in any medium, provided the original work is properly cited. 

References

- [1] LeBlanc K, Allain Brent W. Jr. Laparoscopic Repair of Ventral Wall Abdominal Hernia - 3rd Edition: Prevention and Management [Online]. Available from: http://laparoscopy.blogs.com/prevention_management_3/2010/10/laparoscopic-repair-of-ventral-wall-abdominal-hernia.html. [Accessed: 02 September 2017]
- [2] Bittner R et al. Guidelines for laparoscopic treatment of ventral and incisional abdominal wall hernias (International Endohernia Society (IEHS)-part 1). *Surgical Endoscopy*. Jan. 2014;**28**(1):2-29
- [3] Miserez M, Penninckx F. Endoscopic totally preperitoneal ventral hernia repair. *Surgical Endoscopy*. Aug. 2002;**16**(8):1207-1213
- [4] Schwarz J, Reinhold W, Bittner R. Endoscopic mini/less open sublay technique (EMiLOS)—A new technique for ventral hernia repair. *Langenbeck's Archives of Surgery*. Feb. 2017;**402**(1):173-180
- [5] Belyansky I, Zahiri HR, Park A. Laparoscopic transversus abdominis release, a novel minimally invasive approach to complex abdominal wall reconstruction. *Surgical Innovation*. Apr. 2016;**23**(2):134-141
- [6] Belyansky I et al. A novel approach using the enhanced-view totally extraperitoneal (eTEP) technique for laparoscopic retromuscular hernia repair. *Surgical Endoscopy*. Sep, 2017;**32**:1531-1532
- [7] Daes J. The enhanced view-totally extraperitoneal technique for repair of inguinal hernia. *Surgical Endoscopy*. Apr. 2012;**26**(4):1187-1189
- [8] Novitsky YW. Posterior component separation via transversus abdominis muscle release: The TAR procedure. In: *Hernia Surgery*. Cham: Springer International Publishing; 2016. pp. 117-135
- [9] Muysoms FE et al. Classification of primary and incisional abdominal wall hernias. *Hernia*. Aug. 2009;**13**(4):407-414
- [10] Novitsky YW, editor. *Hernia Surgery*. Cham: Springer International Publishing; 2016
- [11] De Keulenaer BL, De Waele JJ, Powell B, Malbrain MLNG. What is normal intra-abdominal pressure and how is it affected by positioning, body mass and positive end-expiratory pressure? *Intensive Care Medicine*. Jun. 2009;**35**(6):969-976
- [12] Radu VG, Lica M. The Endoscopic Retromuscular Repair of Ventral Hernia: The eTEP Technique and Early Results. *Hernia*. 2019. DOI: 10.1007/s10029-019-01931-x/