

We are IntechOpen, the world's leading publisher of Open Access books Built by scientists, for scientists

6,900

Open access books available

186,000

International authors and editors

200M

Downloads

Our authors are among the

154

Countries delivered to

TOP 1%

most cited scientists

12.2%

Contributors from top 500 universities



WEB OF SCIENCE™

Selection of our books indexed in the Book Citation Index
in Web of Science™ Core Collection (BKCI)

Interested in publishing with us?
Contact book.department@intechopen.com

Numbers displayed above are based on latest data collected.
For more information visit www.intechopen.com



The Eye and the Zika Virus

Dayron Fernando Martínez-Pulgarín,

Carlos Miguel Córdoba-Ortega

and Fabio Daniel Padilla-Pantoja

Abstract

Ocular involvement in Zika virus (ZIKV) infection can be present both in adults and infants as acquired and congenital diseases respectively. Through experimental studies, there has been clarified important mechanisms of ocular pathogenesis that allow the establishment of potential objectives for antiviral drugs development. The spread of the virus at the ocular level could be hematogenous or axonal, however the hematogenous route through the choroid is suggested as the most important initial mechanism for infection. Ocular manifestations vary according to the age of presentation, being mild and self-limited in adults and potentially devastating in children, related to congenital Zika syndrome (CZS). Ocular diagnosis is made based in clinical features and contact/travel history to countries of epidemiological importance; fundoscopy, optical coherence tomography, fluoresceinic/green indocyanine angiography, cultures, serological and molecular tests are useful diagnostic tools. Ocular management is focused according to the clinical context of each patient. Prevention is carried out in a comprehensive manner and further research is directed to vaccine development and specific antiviral treatment. Proper attention requires a multidisciplinary team in order to reach complete visual evaluation and early rehabilitation.

Keywords: Zika virus, congenital Zika syndrome, uveitis, optic nerve hypoplasia, conjunctivitis

1. Introduction

Zika virus (ZIKV) is a mosquito-borne viral disease caused by a flavivirus from the Flaviviridae family and transmitted by species belonging mainly to genus *Aedes*, discovered in 1947 in Uganda in infected rhesus monkeys [1, 2] with the first human cases reported in Africa and Asia [3]. Latin America and the Caribbean started to be affected with outbreaks, the first one reported in 2015 in Brazil [4]. Systemic symptoms include fever, maculo-papular rash, headache, arthralgia and conjunctivitis [2, 5].

Ocular involvement of ZIKV is not an uncommon manifestation in a patient with Zika virus infection. There are two main situations in which ocular pathology can occur: The first one is the manifestation of the virus in an adult patient, including the non-purulent conjunctivitis and more rarely ocular inflammation, especially in the anterior segment [6, 7]. Non-purulent conjunctivitis occurs between 55 and 63% of patients, as reported in outbreaks from Yap Islands and French Polineise, however according to other studies, conjunctivitis only occurs between 10 and 25% of patients infected with ZIKV [8–10].

The second way implies ocular abnormalities of congenital etiology, that belongs to the congenital Zika syndrome (CZS) [11]. The most prevalent congenital disorder is brain calcifications (42.6; 95%CI, 30.8–54.4), meanwhile the prevalence of ocular disorders was less frequent (4.2; 95% CI, 1.0–7.5) [10]. The overall presentation rate of ocular manifestations in infants with CZS is 21.4–55% [11, 12]. Infection due to ZIKV in the first trimester of pregnancy can trigger the presentation of CZS in 1–13% of the cases with ocular manifestations in patients present up to 70% of cases [13].

First report in literature about ocular manifestation in CZS was published in 2016 with three cases of children with mothers exposed to the virus during gestational age, leading to macular chorioretinal atrophy in all cases [14]. A second report of ocular anomalies related to CZS was done in a 10 case-series, informing horizontal nystagmus in 10% of cases, exophoria in 40% of cases, esophoria in 20% of cases, macular alterations like gross pigment mottling and/or chorioretinal atrophy and optic nerve anomalies like hypoplasia with double-ring sign, pallor, and/or increased cup-to-disk ratio in 75 and 45% of evaluated eyes respectively [15]. An interesting fact about these ocular anomalies is that it is not required the presence of microcephaly to get an ocular involvement, like was reported by Ventura et al. in an infant with cerebral calcifications and an unilateral chorioretinal scar in macular region [16].

In the same year, it was reported a case series including 29 patients with microcephaly due to CZS, in which 36.5% had some degree of ocular involvement: Lens subluxation, bilateral iris coloboma, optic nerve abnormalities and chorioretinal atrophy in 5.9, 11.8, 47.1 and 64.7% of cases respectively [17]. Afterwards, in 2017, in a bigger sample (70 children with microcephaly), 36% were positive to ophthalmological findings like macular and optic nerve anomalies (26% of ocular cases), strabismus/nystagmus (10% of ocular cases) and suboptimal visual acuity (100% of ocular cases) [18]. Zin et al. reported a cohort of 112 children with 21.4% of cases with positive ocular findings: 79.2% of cases with optic nerve abnormalities, 58.3% with retinal involvement, 25% with nystagmus, 4.2% with microphthalmia [19].

In Colombia and near countries like Venezuela, exists studies reporting ocular findings [20], like a study with 43 microcephalic children, of which 12% presented optic nerve hypoplasia, 63% macular pigment mottling, 7% lacunar maculopathy and 12% developed congenital glaucoma [21]. Alvarado-Socarras et al. reported a case series of children born from women infected with ZIKV, where two children had intraretinal hemorrhages, hyper/hypopigmented lesions. The increased risk for ocular ZIKV in these cases where derived from the presence of microcephaly and the infection during pregnancy [22].

In an attempt to assess the risk factors associated to ocular manifestations, Ventura et al. conducted a cross-sectional study including 40 microcephalic children, 60% of them with ZIKV positive infection. There was a statistically significant relationship of ocular manifestations to children with smaller cephalic diameter at birth (95%CI, –2.56 to –0.51; $P = 0.004$) and infants whose mothers reported symptoms during the first trimester (95%CI, 0.02–0.67; $P = 0.04$) [23]. It is relevant to mention that not only ocular structural changes are manifest in children with CZS, but also functional abnormalities like ocular motor disorders, visual fields defects (45.1% of cases), low contrast sensitivity (81.3% of cases), hypoaccommodation and refractive errors. Prevalence rate of severe visual impairment without structural changes is present in 84.6% of cases, related to cortical/cerebral involvement [24]. According to Baran et al., visual acuity losses occur in children with gestational infection, with a slowing of visual development even in the absence of microcephaly [25].

It is not necessary the presence of microcephaly in children or ZIKV systemic symptoms in pregnant women to manifest ocular abnormalities. Ocular involvement caused by Zika virus should be included in differential diagnosis, especially in endemic areas, of any patient presenting ocular manifestations and a history of

fever. This chapter describes the most important aspects of the ocular compromise caused by ZIKV, items that the clinicians should consider when approaching a patient with a suspected ocular involvement by the mentioned virus.

2. Ocular pathogenesis

ZIKV, similar to other flaviviruses, has an icosahedral envelope with positive single-stranded RNA as a genetic material that encodes a polyprotein processed by viral and cellular proteases into three structural proteins: capsid proteins, membrane and envelope that form the viral particle and mediate the binding of the virus, allowing entry and encapsidation. Seven non-structural proteins (NS) (NS1, NS2A, NS2B, NS3, NS4A, NS4B and NS5), play a role for polyproteins processing and the induction of an innate antiviral response in the host. The main surface glycoprotein involved in the binding of the host cell and the fusion of the viral membrane is the envelope protein, which allows the fixation and fusion of the viral particle to the host cell and is a useful tool in the diagnosis [26]. Viral reproduction is achieved through non-structural proteins (NS1–NS5), which serve as self-dividing peptidases, together with viral RNA-dependent RNA polymerase [27].

Through the endocytosis process, the virion enters the cytoplasm of the cells [28]. Non-structural proteins bind to the endoplasmic reticulum, where viral replication of RNA is performed using cell structure and dynamics and released by cellular apoptosis. Subsequently, it takes the viral phase that occurs between 3 and 5 days after the first symptoms, then hematogenous spread to organs and tissues occurs. It is believed that the virus could have neuronal (pantropic) and other organ tropism, because viral RNA has been found in the brain, as well as in the liver, kidney, heart and spleen [29]. There are also other forms of transmission called non-vector, such as vertical transmission [30, 31], sexual transmission and blood transfusion [32, 33].

The pathophysiology of the ocular findings is not known in detail so far. It has been studied in animal models and deceased fetuses that have tried to demonstrate the great retinal compromise that includes macular abnormalities such as pigment spots and chorioretinal atrophy, loss of retinal pigment epithelium, perivascular choroidal inflammatory infiltrate and optic nerve abnormalities such as hypoplasia, paleness and increased cup-disc ratio. Other publications describe additional findings, such as iris coloboma, lens subluxation, cataracts, glaucoma, and microphthalmia [15, 34, 35]. At the ocular level, Zika virus infection can affect any part of the uveal tract (iris, ciliary body, retina and choroid), since most clinical cases have defects in the posterior segment [14, 15]. The hematoretinal barrier formed by vascular endothelial cells of the inner retina and external RPE (Retinal Pigment Epithelium) cells constitutes the first protective barrier that is responsible to control the entry of innate immune cells and pathogens into the posterior eye segment [36, 37]. The type I interferon (IFN) response is an important defense mechanism against most flaviviruses. A129 mice, which are deficient in IFN α and β receptors, have been commonly used as an animal model to study ZIKV infection [38, 39].

By detection of RNA nucleic acids in animal models, it has been suggested that the ocular infection can spread hematogenously to the brain and the eye simultaneously, although it is not possible to rule out the transfer through the optic nerve, in which there has been shown that houses the higher concentration of viral antigen. Therefore, the spread of the virus at the ocular level could be hematogenous or axonal, as studies show, however the viral peak during viremia suggests the hematogenous route through the choroid as a more important initial mechanism. After day 3, the progressive increase in viral RNA levels in the eye is markedly different from that of peripheral blood [40]. In a hypothetical study using

human target cells, it was shown that the pathophysiology of ocular ZIKV begins when it spreads throughout the retinal bed through the retinal arteries affecting the endothelial cells and the retinal pericytes of the internal hemato-retinal barrier and then compromises the choroid to infect the external hemato-retinal barrier by compromising the RPE cells and allowing the amplification and spread of the virus in the retinal bed. It was found that retinal endothelial cells are highly permissive for ZIKV and showed important cytopathic effects. It was shown that Müller cells are not permissive for ZIKV infection and photoreceptor cells appear to be even less so. The highest levels of ZIKV transcription were observed in retinal pericytes [41].

It has been documented that the entry and binding of several viruses at the cellular level is facilitated by the TAM (tyrosine kinase) receptors as well as the TLR [36] (toll like receptor) that play an important role in the organization of the innate responses of the retina in the microbial infection. Among them, AXL (TAM type receptor) was identified as the main receptor involved and together with the TLR3 (toll like receptor) that is involved in the viral infection, they allow the binding of the virus and its respective anchorage to the cellular guest machinery. These findings suggest that ZIKV can use AXL as an input receptor to gain access to hemato-retinal barrier cells and therefore cause retinal pathology. Host cells employ intracellular pathogen recognition receptors, such as TLR and RIG-I-like receptors, for the recognition and initiation of innate immune responses, in particular with the generation of the interferon pathway (IFN type I). ISG15 induced by type I IFN is generally considered an antiviral gene that plays a protective role in the retina against ZIKV infection. Although, ISG15 has been shown to influence viral replication both positively and negatively. The expression of several IFN-induced antiviral genes has also been demonstrated, including OAS2 and MX1 [40–42].

In animal models it has been seen that by day 9 of the infection process, there is activation of local glial cells and the start of cell recruitment given a subtle increase in the gene expression of MHC, B2m and STAT1. In addition, there is an increase in TNF α , granzyme, perforin and IFN γ without evidence of CD3 or CD8 T markers, suggesting that possibly NK cells reach the eye in the early stages of the disease [40, 42]. A few days later (days 12–16), when mice develop clinical signs of encephalitis, chemokine expression in the eyes peaks. The analysis of the profile of cytokines and adhesion molecules reveals a marginal increase in the levels of β 2-m, GM-CSF and MCP1 and a moderate increase in the expression of ICAM-1, IL-6 and VCAM-1; and higher levels of RANTES expression (Regulators after activation, normal T cells expressed and presumably secreted) are evidenced in ZIKV infected cells. This elevation recruits inflammatory cells in the retinal microenvironment and produces chronicity [41]. Recent studies in mouse models suggest that ZIKV is located in the iridocorneal angle and in the trabecular meshwork where through the already mentioned mechanisms, they induce cell death at the level of the trabecular meshwork, leading to induction of inflammatory response that causes trabeculitis and could be one of the potential mechanisms for the IOP increase and glaucomatous pathology [43]. Furthermore, once the infection is located at the ocular level, panuveitis can be generated in the presence of ZIKV in the layers of the cornea, choroid, bipolar and ganglion cells of the retina and optic nerve and therefore the viral RNA can be secreted from tear glands or detached from the cornea to the tears [44].

Several studies have been conducted in animal models to try to address the pathophysiological mechanism involved in the development of eye disorders. Van den Pol et al. studied an animal model in infected newborn mice, which exhibit a brain development process similar to the human brain fetus in the second trimester. They mainly analyzed the brain and the visual pathway, identifying the damage caused by ZIKV in the entire visual system, including the retina, the optic chiasma, the suprachiasmatic nucleus, the lateral geniculate nucleus and/or the superior

colliculus. The theory postulated that ZIKV can be transported axonally, which improves the spread of the virus within the brain, with a fundamental role of glial cells to understand the mechanism behind neurological and ocular findings [45].

Singh et al. also conducted an animal model study that only analyzed the pathophysiology of retinal findings demonstrating that retinal cells, including those of the RPE, are permissible for ZIKV replication and express receptors for them. In addition, they are susceptible to ZIKV-induced cell death, leading to retinal lesions because of the virus ability to break the integrity of the hematorretinal barrier. They suggested that ISG15 (Interferon-stimulated gene 15) and its antiviral activity, plays a role in the innate defense of the retina against ZIKV infection [46].

In a subsequent study with a murine model, Zhao et al. showed that ZIKV can infect the retina in immunodeficient and immunocompetent mice and affect multiple retinal layers. ZIKV preferentially infects RPE and Müller cells, which are key support cells for neuronal survival, function and repair of retinal lesions. Müller cell ablation causes neurological and vascular pathological effects that resemble the ocular characteristics of congenital eye disease due to ZIKV. Müller cells show a decreased neurotrophic function with a post-infection up-regulation of cytokines

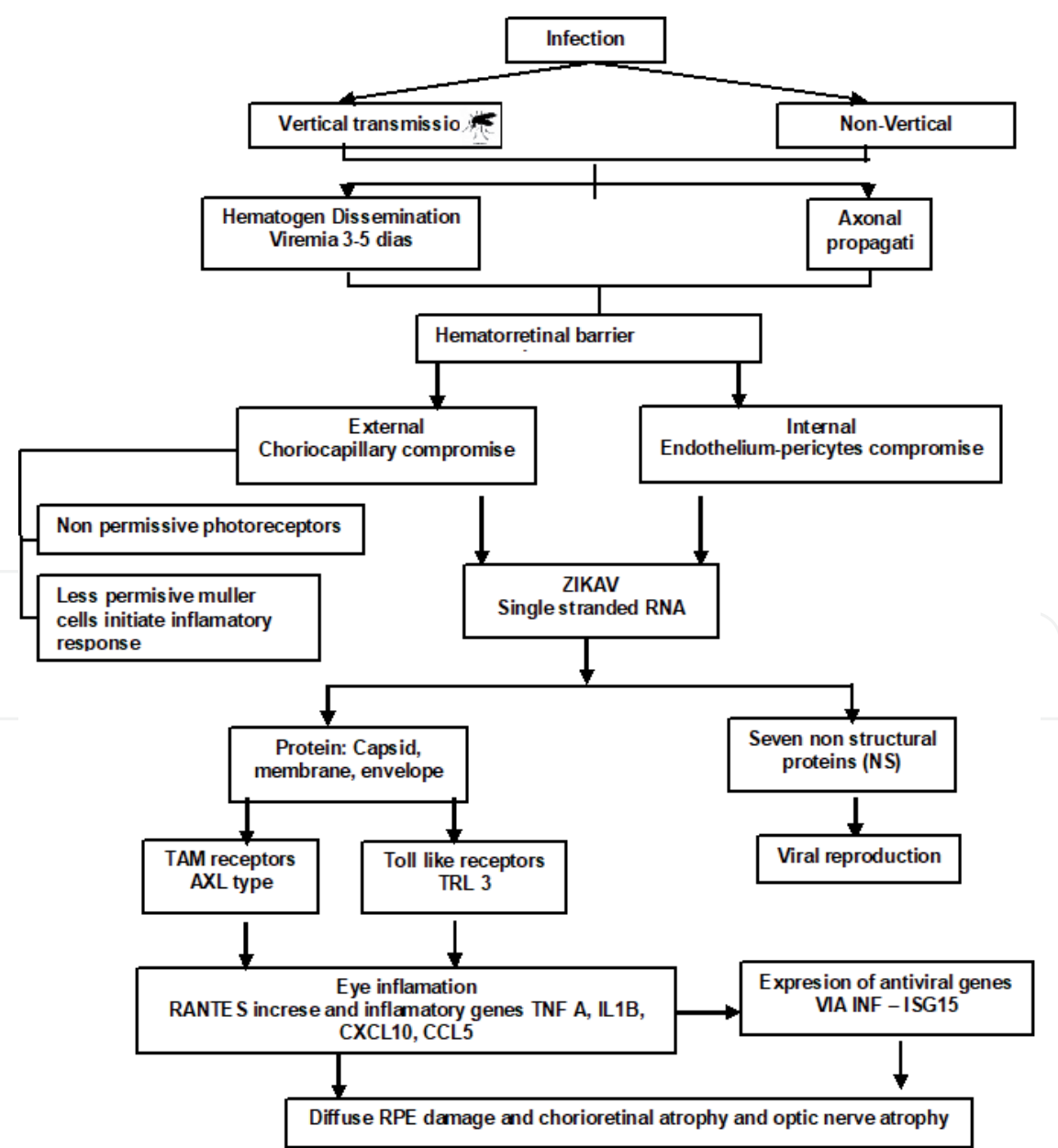


Figure 1.
Pathogenic infection process by ZIKV to the retinal pigment epithelium.

levels [47]. In a more recent study, Aleman et al. [48]. provided the first evidence in-vivo in humans that shows central retinal degeneration with severe loss of ganglion cells and a borderline thinning of nerve fibers, as well as a less prominent loss of photoreceptors. The findings provide the first evidence to date, in humans, that ganglion cells -and perhaps surrounding glia cells- are the primary cellular targets in the retina of patients with ZIKV infection, which is consistent with the murine disease model that suggest a depletion of this neuronal population in the uterus as a result of the infection [44]. **Figure 1**, resumes some of the pathogenic theories involving the ZIKV and its infection to some of the retinal cells.

3. Ophthalmologic manifestations

3.1 Ocular findings in infants with congenital Zika virus infection

The most important findings of ophthalmologic abnormalities associated with Zika virus infection are reported in infants with microcephaly due to Zika congenital infection, leading to a broad spectrum of ophthalmological manifestations. It is proposed that the ocular findings could be a result of the direct effect of Zika virus itself and not only a consequence of microcephaly, because of the known deleterious effects of the virus on the central nervous system [14, 49–51]. The increased neurotropism of the virus explains why the retina and optic nerve are the main structures affected in infants with congenital Zika virus syndrome. It has been proposed that the typical optic nerve hypoplasia is more related to microcephaly, and the retinal anomalies specially found in the neurosensory retina are associated to an inflammatory reaction due to the virus toxin. The majority of findings are bilateral [23, 52]. There is no report of uveitis in congenital cases [53].

Zika exposure without infection during gestation does not seem to affect ocular status, visual acuity or visual development. When the Zika virus is vertically transmitted to the fetus and the subsequent infection is confirmed, the infant may show ophthalmologic and visual function damage. There has been described retinal abnormalities in children with microcephaly attributed to Zika virus infection during pregnancy, found in 60–85% of the affected patients with ocular findings, including optic nerve abnormalities and macular alterations [23, 51]. It is hypothesized that the most severe ophthalmic manifestations occur when the infection takes place in the first or second trimester of pregnancy, because of the Zika's tropism related to the neural precursors, which are available in the early phases of cerebral differentiation [10, 23, 54, 55]. It has been found that retinal findings are more prevalent when the infection takes place in the first trimester and the related viral load may be relevant to the final process that results affecting the macula. In the other hand, the optic nerve could be affected in all trimesters [5].

3.1.1 Optic nerve findings and macular abnormalities

Optic nerve hypoplasia is one of the most important findings in infants with congenital Zika virus infection [51]. This condition can be identified with the double ring sign as a manifestation of a small and undeveloped optic nerve [23, 52, 56, 57] (**Figure 1**). Other typical signs of insult to the optic nerve include pallor and increased cup-to-disk ratio [13, 15, 56, 57] (**Figure 2**). The most frequent macular findings associated with congenital Zika virus infection include gross pigment mottling, foveal reflex loss and chorioretinal atrophy, which differs from toxoplasmosis scars because of the absence of intraocular inflammatory signs and the presentation of a typical dark pigmentation rim around the atrophic area [15, 18, 58].

The circumscribed macular atrophy observed in the affected children seems to be pathognomonic to congenital Zika syndrome [5, 6, 50]. The macular atrophy caused by Zika virus infection is mostly associated with involvement of the outer retinal layers and choriocapillaris (**Figure 3**). Inner retinal vascular abnormalities could also be present and associated with post-viral neurological sequelae of Zika virus infection, in addition to the well-known outer retinal effects of the infectious disease [59].

3.1.2 Anterior segment findings

Anterior ocular findings related to Zika virus infection include iris coloboma, cataracts, lens subluxation, intraocular calcifications and microphthalmia even in the absence of microcephaly [34, 60]. However, it is known that the incidence of structural eye alterations, visual acuity loss and fundus abnormalities are significantly higher when the infected child exhibits concomitant microcephaly [14, 25].

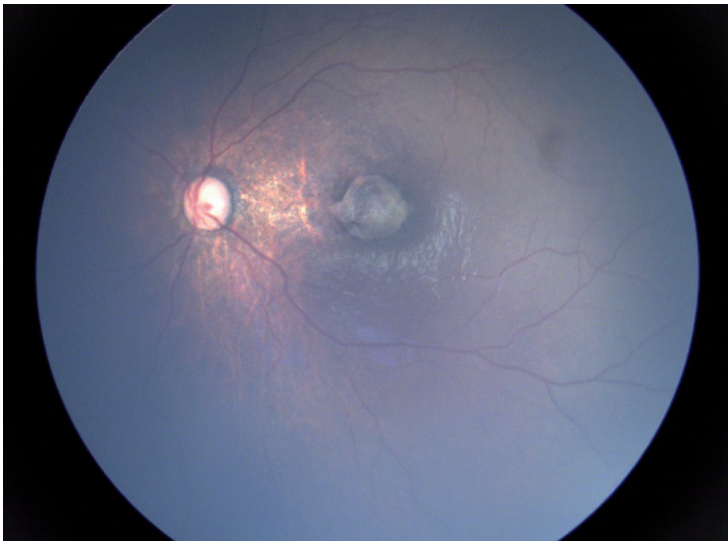


Figure 2.
Optic disc hypoplasia with double-ring sign associated with hyperpigmented mottling and one sharply demarcated chorioretinal atrophy on the macula. Image courtesy from Camila Ventura, MD, PhD. Altino Ventura foundation (FAV) - HOPE eye hospital. reproduced with permission.

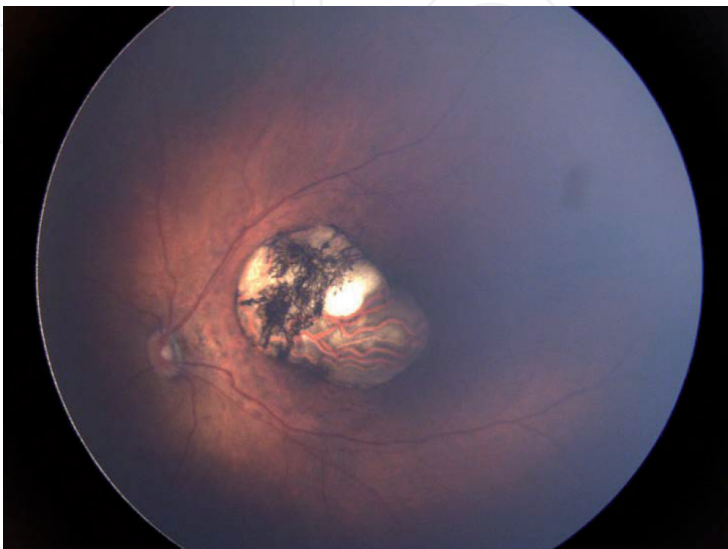


Figure 3.
Macular chorioretinal atrophy, hyperpigmented mottling, vascular attenuation and optic disc hypoplasia. Image courtesy of Camila Ventura, MD, PhD. Altino Ventura foundation (FAV)-HOPE eye hospital. reproduced with permission.

3.1.3 Ocular motility alterations and vascular findings

Among infants with congenital Zika virus infection, the most commonly reported ocular motility disturbances include early-onset strabismus, nystagmus and ocular flutter [21, 25, 60]. The vascular findings are mainly subretinal hemorrhages and abnormalities in peripheral retinal vasculature, including abnormal termination of the retinal vessels, tortuosity and vascular attenuation [21].

3.1.4 Congenital glaucoma

This condition is rare (2.6%) but can occur in infants presenting with CZS and microcephaly. The related findings include an enlarged and cloudy cornea, buphthalmos, photophobia and excessive tearing [11, 57, 61].

The important increase in the prevalence of microcephaly in newborn infants in the Americas, in association with the previously described abnormal and vision-threatening ocular findings, should promptly lead to suspect the diagnosis of congenital infection due to Zika virus in these epidemic regions, which could be confirmed with real-time polymerase chain reaction in the first 5 days of acute phase of infection, after ruling out TORCH infections [62]. It is clear that infants with microcephaly should be screened for ocular lesions, but it is so important to consider that infants without microcephaly may have eye lesions. Then all children of the epidemic areas, such as South America, Central America and the Caribbean, with potential maternal Zika virus exposure at any time during pregnancy should be screened for ocular implication regardless of the presence of central nervous system alterations, because ocular findings could be underdiagnosed if microcephaly continues to be the main inclusion criterion in the screening of this group of children [16, 19, 63]. In addition, all newborns with mothers infected with Zika virus during pregnancy should have an early ophthalmological evaluation including the proper posterior pole examination through full dilation of the pupil [17, 64, 65].

3.2 Ocular findings in adults

The most important difference between infants and adults is that in adults there could be seen symptoms and signs of an active infectious process with the chance of detecting the Zika virus during a viremic period. In adults, only 20% of adults are symptomatic, and therefore the majority of adults with an acute Zika virus infection are asymptomatic [66]. Instead, in infants the related ocular findings are usually scars, as a manifestation of a post-infection process.

Symptomatic patients infected with Zika virus can exhibit a non-purulent conjunctivitis as a non-specific manifestation in the mild course of the disease [8, 67, 68]. Hypertensive iridocyclitis secondary to Zika virus infection has been reported during the acute phase of the disease, associated with ocular discomfort, redness and blurry vision, variable ciliary injection and anterior chamber reaction, miosis and elevation of the intraocular pressure. The findings usually ease after the viremia decreases and the use of topical treatment with steroids, cycloplegic and ocular hypotensive agents [69–71].

Other ocular findings in adults during acute infection include unilateral acute maculopathy, which exhibits a grayish annulus and pigment mottling as fundoscopic alterations, as well as disruption of the outer retinal and retinal pigment epithelium architecture in the central macula on optical coherence tomography and early hypofluorescence with irregular late central staining on angiogram, in addition to prompt resolution with visual function recovery [72, 73]. Neuroretinitis with a macular-star pattern has also been described in literature [74]. There could

be found associated placoid or multifocal non-necrotizing chorioretinal lesions, especially in immunocompromised patients, that usually evolve with scarring and posterior improvement of visual acuity. Then, these chorioretinal lesions may be a manifestation of the active phase of infection in patients with viremia [24, 40, 75].

4. Systemic diagnosis

After clinical evaluation in individuals showing clinically compatible symptoms, the laboratory diagnosis of acute infection is based on the use of molecular tests for direct detection of viral nucleic acids (RNA) in blood and other biological samples and serological tests with tests of Enzymatic immunosorption (ELISA) or immunofluorescence assays (IFA) which allow the detection of IgM and IgG antibodies in serum. In a specialized manner, virus neutralization assays can also be performed to confirm the specificity of the ELISA or IFA tests, as well as cell cultures to isolate the virus [8, 76].

During the acute phase of the infection, the diagnosis is based on the detection of viral nucleic acid (RNA) by (RT-PCR) polymerase chain reaction of reverse transcription in blood, urine and saliva samples as well as in others biological samples such as CSF, amniotic fluid, semen [77], fetoplacental tissue and aqueous humor. Furtado et al. reported the case of a patient using aqueous humor to perform RT-PCR [70]. Two separate samples should be collected: the first during the acute phase and the second in the next 2–3 weeks [78]. If the result is negative, serological tests such as IGM should be supplemented, if they are positive, the plaque reduction neutralization test (PRNT) is performed as complement to determine whether or not there is a recent infection [76]. The conjunctival fluid contains virus for up to 7 days compared to urine and saliva samples of less than 20 days [79, 80].

4.1 Case confirmation

The Center for Disease Control recommends that an initial clinical evaluation should be performed in all infants with evidence of exposure to ZIKV or with suggestive laboratories, regardless of whether they have abnormalities consistent with ZIKV infection. There should be also evaluated those infants with abnormal clinical or neuroimaging findings, such as intracranial calcifications that were detected prenatally or during childbirth, and whose mothers were potentially infected with ZIKV during pregnancy [81].

According to the ECDC, a case is defined as confirmed when at least one of the following laboratory criteria is present: nucleic acid detection (RNA), antigens in a clinical sample; virus isolation in a clinical sample; detection of specific antibodies (IGM) in serum samples and confirmation by neutralization test; seroconversion or quadruple increase in the titer of specific antibodies against ZIKV in paired serum samples. A case is defined as probable if specific IgM antibodies are detected in serum. Epidemiological criteria must be taken into account [82]. It is recommended to perform funduscopy under pharmacological dilation in those patients with risk factors at least once within the first month and repeat at 3 months as a follow-up for those patients with confirmed diagnosis.

5. Ophthalmic diagnosis

ZIKV infection can occur with a wide spectrum of ocular findings, the most characteristic being the mottled pigment and chorioretinal atrophy that are

commonly observed in the posterior pole especially in the macular area. There has been reported cases in the literature with manifestations that include conjunctivitis, uveitis [70], unilateral acute idiopathic maculopathy, chorioretinal lesions of acute onset, self-resolution, non-necrotizing multifocal placoids or manifestations such as manifestation of active chorioretinitis due to virus [75], optic neuropathy and congenital glaucoma [61], retinal vasculopathy [59], and hypertensive iridocyclitis [71].

The funduscopy is clinically important as a diagnostic tool and atrophic pigmented macular and peri-macular lesions, diffuse RPE damage and chorioretinal atrophy can be observed [14]. There are reports where funduscopy revealed pigmented external retinal lesions, retinal vascular abnormalities as tortuosity and dilation and atrophy of the optic nerve [11, 83]. In the peripheral retina a hypolucid spot can be observed as well as scattered subretinal hemorrhages external to the macula.

In fluorescein angiography early blockage and late staining in the retinal pigment epithelium is present. In autofluorescence, multimodal images showed a group of hyperautofluorescent lesions, it has also been described that there were focal areas of presumed choroiditis visualized as hypercinesic lesions in indocyanine green angiography [83].

Furtado et al. reported the case of a patient diagnosed with Zika by molecular and serological tests as well as positive ZIKV RNA in (RT-PCR) in aqueous humor obtained by anterior chamber paracentesis and described bilateral conjunctival hyperemia, bilateral non-granulomatous keratic precipitates and positive cellularity in the anterior chamber [70]. Parke et al. presented the case of a patient in whom alterations in the RPE with a gray ring around the fovea were observed and evidence by optical coherence tomography in the external retina and with macular area compromise. The above findings were in relation to a positive result for molecular testing with PRNT neutralization reduction technique of ZIKV [73].

5.1 Optical coherence tomography

For a better understanding of the ocular findings and as a follow-up to the characteristics probably related to ZIKV infection at the ocular level, some studies that analyzed the retinal tissue have been performed, Ventura et al. for example described the related findings by OCT in a series of consecutive cross-sectional cases that included 8 infants. The main OCT findings in the affected eyes included disruption of the ellipsoid zone and hyperreflectivity underlying the retinal pigment epithelium, thinning of the retina and choroid, and a colobomatous excavation [84].

Oliveira et al. described that the OCT results show a wide range of retinal damage caused by congenital ZIKV infection, and reinforced the findings compatible with chorioretinal atrophy [85]. Campos et al. described a case report with similar findings that correspond to retina thinning with atrophy of the external retina, including the outer nuclear layer and the ellipsoid zone, associated with hyperreflectivity of the RPE and increased OCT penetration into deeper layers of the choroid and sclera (**Figure 4**) [86].

Henry et al. used images of fluorescein-like fundus lesions and indocyanine green angiography, autofluorescence and optical coherence tomography associated with ZIKV and described acute and multifocal posterior non-necrotizing placoid epitheliopathy lesions that could be characteristic of active chorioretinitis due to ZIKV [75]. The findings described by OCT suggested that the neurotropism manifested by the ZIKV corresponds to significant necrosis areas of the retinal tissue.

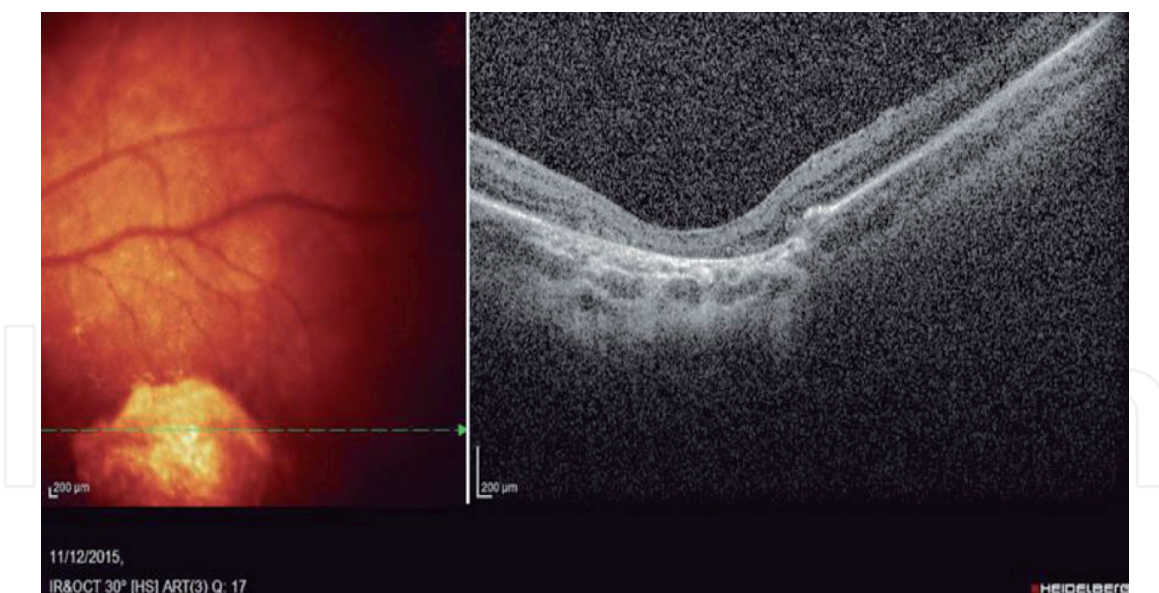


Figure 4.
 Spectral domain OCT of a macular lesion in an infant with presumed Zika virus-associated microcephaly, demonstrating retinal thinning with atrophy of the outer retina, including the outer nuclear layer and ellipsoid zone, associated with retinal pigment epithelium hyper-reflectivity and increased penetration of OCT into deeper layers of the choroid and sclera. Taken from Campos AG, Lira RP, Arantes TE. Optical coherence tomography of macular atrophy associated with microcephaly and presumed intrauterine Zika virus infection. *Arq bras Oftalmol.* 2016;79(6):400–1. Reproduced with the permission from the author according to creative commons attribution license.

6. Systemic treatment

There is no specific approved antiviral treatment nor vaccines for the ZIKV infection to date. Actual treatment due to this virus is focused in control of symptoms (rest, fluid ingestion, antipyretics as paracetamol) [2, 53]. There are several compounds been tested in-vitro, each one with different action mechanism between each other's: Inhibition of the replication of the virus at early and late phases (For instance the Direct Acting Agents);inhibition of the molecular attachment, endocytosis and fusion mechanisms of the virus leading to block the viral entry, like duramycin, suramin and nanchangmycin [87, 88]. Some different molecules are being studied in animal models such as Z2 synthetic peptide inhibitor and the cholesterol-25-hydroxylase, which interfere vertical transmission in pregnant mice and cause cholesterol oxidation respectively [89, 90]. Novobiocin, lopinavir-ritonavir and bromocriptine cause an inhibition of the protease activity (NS2B-NS3 vial protease protein) [91, 92].

There is a growing interest in developing a vaccine against the ZIKV that could be used, especially in pregnant women. Animal models have been implemented, like knockout mice with shortcomings in IFN-I or IFN-II receptors, recreating many of the characteristics of the infection. The vaccine candidates that are been studied are in phase I or II, being the most promising a ZIKV-purified inactivate virus, or nucleic acid and adenovirus-based vaccines against the prM and E proteins providing long term protection in monkeys and mice [93–97].

7. Ocular treatment

There is no existence of guidelines or clinical trials about the treatment of ocular manifestation in ZIKV infection. The available data is extracted of case reports and case series. It is mandatory to focus the treatment according to the ophthalmic

clinical context of each patient. In a patient with ophthalmologic manifestations that are presumed to be derived from ZIKV, it is necessary to exclude other causes before, then specific treatment is established.

In adults, ocular compromise in acute phases of the ZIKV infection could be treated with topical steroids, cycloplegic, and hypotensive topical medication according to ocular signs and symptoms present at that moment. Ocular compromise in children require a multidisciplinary approach and a focused treatment according to the present ocular conditions [53]. Cases with refractive errors, anisometropias, hypoaccommodation, amblyopia, and strabismus requires visual development therapies (eyeglasses, patching, orthoptics, and strabismus surgery) that are key in visual rehabilitation [12, 98].

Cases of anterior uveitis derived from ZIKV infection, usually are self-limiting course, which makes redundant the need of therapy [99]. However, there are cases of hypertensive acute anterior uveitis treated with β -Blockers and carbonic anhydrase inhibitor eyedrops accompanied or not with topical steroids and cycloplegics with normalization after treatment [70, 71, 100]. Kodati et al. reported an adult case of posterior uveitis and chorioretinal lesions in an immunocompetent patient treated with loteprednol etabonate 0.5% three times daily, then reaching visual acuities of 20/20, with remaining photopsias [69].

Cases of bilateral optic neuritis in adults related to ZIKV were treated with intravenous methylprednisolone for 3 days followed by oral prednisolone for 11 additional days leading to a modest and partial recovery of visual acuity [61, 101]. Ocular flutter in a ZIKV post-infection state patient with neurological additional symptoms were described with improvement after intravenous immunoglobulin for 5 days [60].

Retinal disease associated to ZIKV, sometimes manifested as perifoveal microaneurysms with no involvement of visual function did not require any additional treatment beyond observation [59]. Acute maculopathy with bull's-eye shape were reported in an adult case, with total improvement of visual acuity after 6 weeks without any treatment [73]. There is a study where the pharmacological inhibition of ABCG1, a membrane transporter of cholesterol, resulted in reduced ZIKV infectivity of RPE [42].

Glaucoma in Congenital Zika syndrome is a visual-threatening condition that need special attention and early treatment, where the use of hypotensive topical medications and surgery like trabeculotomy, trabeculectomy, trabeculotomy plus trabeculectomy or goniotomy are the most used strategies [13, 21, 57, 61].

8. Visual prognosis in children with congenital ZIKV infection

The infants affected with congenital Zika virus syndrome may manifest many structural ocular findings in addition to the typical ones than involve the posterior pole, presenting low contrast sensitivity, visual field defects, hypoaccommodation, refractive errors and ocular motor disorders such as strabismus and nystagmus, commonly associated to neurological conditions, that finally interfere with the development of stereopsis and binocular vision. The sum of all of these findings results in severe visual impairment, regardless of the abnormalities of the retina and optic nerve [24].

There has been reported that even in the absence of apparent ocular abnormalities, there is a high prevalence of visual impairment between infants with microcephaly due to congenital Zika syndrome, suggesting that cerebral visual impairment, as a result of extensive damage to the central nervous system, could be the most frequent cause of blindness in affected infants [98, 102, 103]. This condition is known as cortical visual impairment, which is a reduction in visual response due to a neurologic issue. Then, the visual prognosis could be committed even in absence of ocular

damage because of the severe cerebral malformation and abnormal brain development related to Zika infection. The affected infants usually have some vision and then they could exhibit improvement of their abilities over time. There could be seen the necessity of multidisciplinary teams for early cognitive and visual stimulation of newborns affected by congenital Zika virus syndrome, in order to decrease the impact of these infants and their families and achieve better quality of life. Further studies with long follow-up periods are needed to recognize the impact of the described ocular and neurological abnormalities, as well as for a better understanding and description of the natural history related to Zika infection and its ocular sequelae [13].

The early recognition, assessment and intervention of children with congenital Zika virus syndrome is crucial, especially in those ones that present hypoaccommodation and refractive errors, because they could show a significant improvement in visual acuity if they receive an early intervention with proper eyeglasses, as part of an integral visual stimulation therapy. For achieving significant changes in their refractive status it is necessary to guarantee periodical updates over time.

9. Visual prognosis in adults

In general terms, there is a benign visual evolution in adults, because the symptoms and signs are associated with a self-limited viral process related to the acute phase of Zika virus infection that usually resolves once the virus is cleared. Then, the vision returns to normal in the majority of the cases.

Non-purulent conjunctivitis is the most common non-congenital and self-limited ocular manifestation of Zika virus infection [101]. The adults that course with chorioretinal lesions, like immunocompromised patients that are in higher risk for presenting these fundus alterations, usually evolve as acute-onset and self-resolving lesions, with scarring and posterior improvement of visual acuity. Then this finding of Zika virus chorioretinitis may be a clear representation of the active phase of infection in a significant context of viremia. In the case of diagnosis of unilateral acute maculopathy related to Zika virus infection, the patient can be carefully monitored because there is usually visual function recovery, with improvement in the pigment epithelial and outer retinal architecture on optical coherence tomography after the acute illness [52].

There has been described many non-congenital ocular complications related to arboviral infection, including episcleritis, keratitis, uveitis, vitritis, macular atrophy, retinal vascular occlusion, optic neuritis and macular edema, with no specific or pathognomonic ocular lesion for Zika virus infection. Most patients recover completely, but there is always a small percentage of patients that evolve with permanent damage and subsequently can lead to long-life visual impairment [65]. Uveitis can be identified in adults during active Zika virus infection and has a benign prognosis. It is considered the principal difference between the ocular manifestations seen in acquired Zika infection and those observed in congenital Zika virus syndrome, because uveitis has been only reported in the acquired cases during viremia. Most cases evolve to complete regression and recovery of visual acuity after the viremia decreases and the use of topical treatment with steroids, cycloplegic and ocular hypertension drops [12].

10. Conclusion

Ocular involvement by ZIKV is related to the ability to break the blood-retinal barrier and axonal transportation, leading to manifestations in children and adults.

Among the affected infants, the most common ophthalmologic manifestations include optic nerve hypoplasia, increased cup-to-disk ratio, macular scarring and focal pigmentary retinal mottling, as well as anterior ocular findings and ocular motility alterations. The most severe ophthalmic manifestations occur when the infection takes place in the first trimester of pregnancy, exposure to the virus during pregnancy can cause devastating effects on the developing fetus, specially affecting the central nervous system. The associated pattern of birth defects is known as congenital Zika virus syndrome among adults, the manifestations are usually self-limited and in some cases require some kind of treatment. It is needed to focus the treatment according to the ophthalmic clinical context of each patient. Cases with CZS should be enrolled in an integral and multidisciplinary team for providing early-intervention services including cognitive and visual rehabilitation. Further studies are necessary to recognize the impact of ocular damage and neurological abnormalities and its long-term consequences in the affected children.

Acknowledgements

The authors thank Camila Ventura, MD, PhD from Altino Ventura Foundation (FAV) and HOPE Eye Hospital, and Adriana Gondim de Moura Campos from Universidade Federal de Pernambuco for having provided images from their daily clinical practice and previous works, being a great complement to this chapter.

Author details

Dayron Fernando Martínez-Pulgarín^{1,2,3*}, Carlos Miguel Córdoba-Ortega^{1,2} and Fabio Daniel Padilla-Pantoja^{1,2}

1 Department of Ophthalmology, School of Medicine, Universidad Nacional de Colombia, Bogota, Colombia

2 Basic and Clinic Ophthalmology Research Group, School of Medicine, Universidad Nacional de Colombia, Bogota, Colombia

3 Research Group and Incubator Public Health and Infection, Faculty of Health Sciences, Universidad Tecnológica de Pereira, Pereira, Colombia

*Address all correspondence to: dayronfernando@hotmail.com

IntechOpen

© 2019 The Author(s). Licensee IntechOpen. This chapter is distributed under the terms of the Creative Commons Attribution License (<http://creativecommons.org/licenses/by/3.0>), which permits unrestricted use, distribution, and reproduction in any medium, provided the original work is properly cited. 

References

- [1] Dick G, Kitchen SF, Haddow A. Zika virus (I). Isolations and serological specificity. *Transactions of the Royal Society of Tropical Medicine and Hygiene*. 1952;**45**(5):509-520
- [2] Ferraris P, Yssel H, Misse D. Zika virus infection: An update. *Microbes and Infection*. 2019
- [3] Martinez-Pulgarin DF, Acevedo-Mendoza WF, Cardona-Ospina JA, Rodriguez-Morales AJ, Paniz-Mondolfi AE. A bibliometric analysis of global Zika research. *Travel Medicine and Infectious Disease*. 2016;**14**(1):55-57
- [4] Rodríguez-Morales AJ, Trujillo AM, Sánchez-Duque JA, Cardona-Ospina JA, Villamil-Gómez WE, Jimenez-Canizalez CE, et al. Introductory Chapter: Clinical and Epidemiological Implications of Zika Virus Infection - The Experience of RECOLZIKA in Colombia; 2018
- [5] Pinazo-Duran MD, Silva ED. Zika virus. A teratogenic agent for the eyes. *Archivos de la Sociedad Española de Oftalmología*. 2017;**92**(2):51-53
- [6] Benzekri R, Belfort R Jr, Ventura CV, de Paula FB, Maia M, Leite M, et al. Ocular manifestations of Zika virus: What we do and do not know. *Journal Français d'Ophthalmologie*. 2017;**40**(2):138-145
- [7] de Andrade GC, Ventura CV, Mello Filho PA, Maia M, Vianello S, Rodrigues EB. Arboviruses and the eye. *International Journal of Retina and Vitreous*. 2017;**3**:4
- [8] Sahiner F, Sig AK, Savasci U, Tekin K, Akay F. Zika virus-associated ocular and neurologic disorders: The emergence of new evidence. *The Pediatric Infectious Disease Journal*. 2017;**36**(12):e341-e3e6
- [9] Buathong R, Hermann L, Thaisomboonsuk B, Rutvisuttinunt W, Klungthong C, Chinnawirotpisan P, et al. Detection of Zika virus infection in Thailand, 2012-2014. *The American Journal of Tropical Medicine and Hygiene*. 2015;**93**(2):380-383
- [10] Nithiyanantham SF, Badawi A. Maternal infection with Zika virus and prevalence of congenital disorders in infants: Systematic review and meta-analysis. *Canadian Journal of Public Health*. 2019
- [11] de Paula FB, Ventura CV, Maia M, Belfort R Jr. Zika virus and the eye. *Current Opinion in Ophthalmology*. 2017;**28**(6):595-599
- [12] Ventura C, Ventura LO. Ophthalmologic manifestations associated with Zika virus infection. *Pediatrics*. 2018;**141**(s2):S161-S166
- [13] de Oliveira Dias JR, Ventura CV, de Paula FB, Prazeres J, Ventura LO, Bravo-Filho V, et al. Ocular abnormalities in congenital Zika syndrome: Are the ophthalmoscopic findings “the top of the iceberg”? *Progress in Retinal and Eye Research*. 2018;**66**:85-106
- [14] Ventura CV, Maia M, Bravo-Filho V, Góis AL, Belfort R. Zika virus in Brazil and macular atrophy in a child with microcephaly. *The Lancet*. 2016;**387**(10015):228
- [15] Ventura CV, Maia M, Ventura BV, Linden VV, Araujo EB, Ramos RC, et al. Ophthalmological findings in infants with microcephaly and presumable intra-uterus Zika virus infection. *Arquivos Brasileiros de Oftalmologia*. 2016;**79**(1):1-3
- [16] Ventura CV, Maia M, Dias N, Ventura LO, Belfort R. Zika: Neurological and ocular findings in

infant without microcephaly. *The Lancet*. 2016;**387**(10037):2502

[17] de Paula FB, de Oliveira Dias JR, Prazeres J, Sacramento GA, Ko AI, Maia M, et al. Ocular findings in infants with microcephaly associated with presumed Zika virus congenital infection in Salvador, Brazil. *JAMA Ophthalmology*. 2016;**134**(5):529-535

[18] Vercosa I, Carneiro P, Vercosa R, Girao R, Ribeiro EM, Pessoa A, et al. The visual system in infants with microcephaly related to presumed congenital Zika syndrome. *Journal of AAPOS*. 2017;**21**(4):300-304.e1

[19] Zin AA, Tsui I, Rossetto J, Vasconcelos Z, Adachi K, Valderramos S, et al. Screening criteria for ophthalmic manifestations of congenital Zika virus infection. *JAMA Pediatrics*. 2017;**171**(9):847-854

[20] Acosta-Reyes J, Navarro E, Herrera MJ, Goenaga E, Ospina ML, Parra E, et al. Severe neurologic disorders in 2 fetuses with Zika virus infection, Colombia. *Emerging Infectious Diseases*. 2017;**23**(6):982-984

[21] Yepez JB, Murati FA, Pettito M, Penaranda CF, de Yepez J, Maestre G, et al. Ophthalmic manifestations of congenital Zika syndrome in Colombia and Venezuela. *JAMA Ophthalmology*. 2017;**135**(5):440-445

[22] Alvarado-Socarras JL, Aux-Cadena CP, Murillo-Garcia DR, Rodriguez-Morales AJ. Ophthalmologic evaluation in infants of mothers with Zika: A report from Colombia. *Travel Medicine and Infectious Disease*. 2019

[23] Ventura CV, Maia M, Travassos SB, Martins TT, Patriota F, Nunes ME, et al. Risk factors associated with the Ophthalmoscopic findings identified in infants with presumed Zika virus congenital infection. *JAMA Ophthalmology*. 2016;**134**(8):912-918

[24] Ventura CV, Ventura Filho MC, Ventura LO. Ocular manifestations and visual outcome in children with congenital Zika syndrome. *Topics in Magnetic Resonance Imaging*. 2019;**28**(1):23-27

[25] Baran LCP, da Costa MF, Vidal KS, Damico FM, Barboni MTS, da SLD, et al. Alterations in visual acuity and visual development in infants 1-24 months old either exposed to or infected by Zika virus during gestation, with and without microcephaly. *Journal of AAPOS*. 2019;**23**:215.e1-215.e7

[26] Chan JF, Choi GK, Yip CC, Cheng VC, Yuen KY. Zika fever and congenital Zika syndrome: An unexpected emerging arboviral disease. *The Journal of Infection*. 2016;**72**(5):507-524

[27] Smith DR, Sprague TR, Hollidge BS, Valdez SM, Padilla SL, Bellanca SA, et al. African and Asian Zika virus isolates display phenotypic differences both In vitro and In vivo. *The American Journal of Tropical Medicine and Hygiene*. 2018;**98**(2):432-444

[28] Hajra A, Bandyopadhyay D, Hajra SK. Zika virus: A global threat to humanity: A comprehensive review and current developments. *North American Journal of Medical Sciences*. 2016;**8**(3):123-128

[29] Salinas S, Foulongne V, Loustalot F, Fournier-Wirth C, Moles JP, Briant L, et al. [Zika virus, an emerging threat]. *Medical Science (Paris)*. 2016;**32**(4):378-386

[30] Calvet G, Aguiar RS, Melo ASO, Sampaio SA, de Filippis I, Fabri A, et al. Detection and sequencing of Zika virus from amniotic fluid of fetuses with microcephaly in Brazil: A case study. *The Lancet Infectious Diseases*. 2016;**16**(6):653-660

- [31] Martines RB, Bhatnagar J, Keating MK, Silva-Flannery L, Muehlenbachs A, Gary J, et al. Evidence of Zika virus infection in brain and placental tissues from two congenitally infected newborns and two fetal losses — Brazil, 2015. *Morbidity and Mortality Weekly Report*. 2015;**65**:159-160
- [32] Motta IJ, Spencer BR, Cordeiro da Silva SG, Arruda MB, Dobbin JA, Gonzaga YB, et al. Evidence for transmission of Zika virus by platelet transfusion. *Obstetric Anesthesia Digest*. 2017;**37**(1):53
- [33] Slenczka W. Zika virus disease. *Microbiology Spectrum*. 2016;**4**:163-173
- [34] de Paula FB, Zin A, Ko A, Maia M, Ventura CV, Belfort R Jr. Anterior-segment ocular findings and microphthalmia in congenital Zika syndrome. *Ophthalmology*. 2017;**124**(12):1876-1878
- [35] Fernandez MP, Parra Saad E, Ospina Martinez M, Corchuelo S, Mercado Reyes M, Herrera MJ, et al. Ocular histopathologic features of congenital Zika syndrome. *JAMA Ophthalmology*. 2017;**135**(11):1163-1169
- [36] Pandey RK, Yu F-S, Kumar A. Targeting toll-like receptor signaling as a novel approach to prevent ocular infectious diseases. *The Indian Journal of Medical Research*. 2013;**138**(5):609-619
- [37] Constable PA, Lawrenson JG. Glial cell factors and the outer blood retinal barrier. *Ophthalmic & Physiological Optics*. 2009;**29**(5):557-564
- [38] Rossi SL, Tesh RB, Azar SR, Muruato AE, Hanley KA, Augustine AJ, et al. Characterization of a novel murine model to study Zika virus. *The American Journal of Tropical Medicine and Hygiene*. 2016;**94**(6):1362-1369
- [39] Dowall SD, Graham VA, Rayner E, Atkinson B, Hall G, Watson RJ, et al. A susceptible mouse model for Zika virus infection. *PLoS Neglected Tropical Diseases*. 2016;**10**(5):e0004658
- [40] Manangeeswaran M, Kielczewski JL, Sen HN, Xu BC, Ireland DDC, McWilliams IL, et al. ZIKA virus infection causes persistent chorioretinal lesions. *Emerging Microbes & Infections*. 2018;**7**(1):96
- [41] Roach T, Alcendor DJ. Zika virus infection of cellular components of the blood-retinal barriers: Implications for viral associated congenital ocular disease. *Journal of Neuroinflammation*. 2017;**14**(1):43
- [42] Singh PK, Khatri I, Jha A, Pretto CD, Spindler KR, Arumugaswami V, et al. Determination of system level alterations in host transcriptome due to Zika virus (ZIKV) infection in retinal pigment epithelium. *Scientific Reports*. 2018;**8**(1):11209
- [43] Singh PK, Kasetti RB, Zode GS, Goyal A, Juzych MS, Kumar A. Zika virus infects trabecular meshwork and causes trabeculitis and glaucomatous pathology in mouse eyes. *mSphere*. 2019;**4**(3):1-14
- [44] Miner JJ, Sene A, Richner JM, Smith AM, Santeford A, Ban N, et al. Zika virus infection in mice causes panuveitis with shedding of virus in tears. *Cell Reports*. 2016;**16**(12):3208-3218
- [45] van den Pol AN, Mao G, Yang Y, Ornaghi S, Davis JN. Zika virus targeting in the developing brain. *The Journal of Neuroscience*. 2017;**37**(8):2161-2175
- [46] Singh PK, Guest JM, Kanwar M, Boss J, Gao N, Juzych MS, et al. Zika virus infects cells lining the blood-retinal barrier and causes chorioretinal atrophy in mouse eyes. *JCI Insight*. 2017;**2**(4):e92340

- [47] Zhao Z, Yang M, Azar SR, Soong L, Weaver SC, Sun J, et al. Viral retinopathy in experimental models of Zika infection. *Investigative Ophthalmology & Visual Science*. 2017;**58**(10):4355-4365
- [48] Aleman TS, Ventura CV, Cavalcanti MM, Serrano LW, Traband A, Nti AA, et al. Quantitative assessment of microstructural changes of the retina in infants with congenital Zika syndrome. *JAMA Ophthalmology*. 2017;**135**(10):1069-1076
- [49] Miranda HA 2nd, Costa MC, Frazao MAM, Simao N, Franchischini S, Moshfeghi DM. Expanded spectrum of congenital ocular findings in microcephaly with presumed Zika infection. *Ophthalmology*. 2016;**123**(8):1788-1794
- [50] Prakalapakorn SG, Meaney-Delman D, Honein MA, Rasmussen SA. The eyes as a window to improved understanding of the prenatal effects of Zika virus infection. *Journal of AAPOS*. 2017;**21**(4):259-261
- [51] Valentine G, Marquez L, Pammi M. Zika virus-associated microcephaly and eye lesions in the newborn. *Journal of the Pediatric Infectious Diseases Society*. 2016;**5**(3):323-328
- [52] Guevara JG, Agarwal-Sinha S. Ocular abnormalities in congenital Zika syndrome: A case report, and review of the literature. *Journal of Medical Case Reports*. 2018;**12**(1):161
- [53] Marquezan MC, Ventura CV, Sheffield JS, Golden WC, Omiadze R, Belfort R Jr, et al. Ocular effects of Zika virus-a review. *Survey of Ophthalmology*. 2018;**63**(2):166-173
- [54] Tang H, Hammack C, Ogden SC, Wen Z, Qian X, Li Y, et al. Zika virus infects human cortical neural progenitors and attenuates their growth. *Cell Stem Cell*. 2016;**18**(5):587-590
- [55] Faizan MI, Abdullah M, Ali S, Naqvi IH, Ahmed A, Parveen S. Zika virus-induced microcephaly and its possible molecular mechanism. *Intervirology*. 2016;**59**(3):152-158
- [56] Calle-Giraldo JP, Rojas CA, Hurtado IC, Barco C, Libreros D, Sanchez PJ, et al. Outcomes of congenital Zika virus infection during an outbreak in Valle Del Cauca, Colombia. *The Pediatric Infectious Disease Journal*. 2019;**38**(7):735-740
- [57] de Oliveira DR, Ventura CV, Esporcatte BLB, Gracitelli CPB, Dias NC, Ventura LO, et al. Glaucoma workup in congenital Zika syndrome. *Journal of Glaucoma*. 2019;**28**(4):313-317
- [58] Gely-Rojas L, Pérez R, García-Fragoso L, García-García I. Association of Zika virus exposure in utero with ocular phenotypes in a group of newborns in Puerto Rico. *Puerto Rico Health Sciences Journal*. 2018;**37**:s77-s80
- [59] Singh MS, Marquezan MC, Omiadze R, Reddy AK, Belfort R Jr, May WN. Inner retinal vasculopathy in Zika virus disease. *American Journal of Ophthalmology Case Reports*. 2018;**10**:6-7
- [60] Karam E, Giraldo J, Rodriguez F, Hernandez-Pereira CE, Rodriguez-Morales AJ, Blohm GM, et al. Ocular flutter following Zika virus infection. *Journal of Neurovirology*. 2017;**23**(6):932-934
- [61] De Moraes CG, Pettito M, Yopez JB, Sakuntabhai A, Simon-Loriere E, Zaidi MB, et al. Optic neuropathy and congenital glaucoma associated with probable Zika virus infection in Venezuelan patients. *JMM Case Report*. 2018;**5**(5):e005145

- [62] Jurgens I, Rey A. Ocular findings in patients with microcephaly can suggest presumed congenital zika virus infection. *Acta Ophthalmologica*. 2018;**96**(4):423-424
- [63] Ventura CV, Fernandez MP, Gonzalez IA, Rivera-Hernandez DM, Lopez-Alberola R, Peinado M, et al. First travel-associated congenital zika syndrome in the US: Ocular and neurological findings in the absence of microcephaly. *Ophthalmic Surgery, Lasers & Imaging Retina*. 2016;**47**(10):952-955
- [64] Bandyopadhyay D, Hajra A. ZIKA virus: A new threat to the eyes. *European Journal of Internal Medicine*. 2017;**44**:e9-e10
- [65] McCarthy M. Severe eye damage in infants with microcephaly is presumed to be due to Zika virus. *BMJ*. 2016;**352**:i855
- [66] Centers for Disease Control and Prevention NCFEaZIDN, Division of Vector-Borne Diseases (DVBD). About Zika. 2019. Available from: <https://www.cdc.gov/zika/about/index.html>
- [67] Agrawal R, Oo HH, Balne PK, Ng L, Tong L, Leo YS. Zika virus and the eye. *Ocular Immunology and Inflammation*. 2018;**26**(5):654-659
- [68] Platt DJ, Miner JJ. Consequences of congenital Zika virus infection. *Current Opinion in Virology*. 2017;**27**:1-7
- [69] Kodati S, Palmore TN, Spellman FA, Cunningham D, Weistrop B, Sen HN. Bilateral posterior uveitis associated with Zika virus infection. *The Lancet*. 2017;**389**(10064):125-126
- [70] Furtado JM, Esposito DL, Klein TM, Teixeira-Pinto T, da Fonseca BA. Uveitis associated with Zika virus infection. *The New England Journal of Medicine*. 2016;**375**(4):394-396
- [71] Fontes BM. Zika virus-related hypertensive iridocyclitis. *Arquivos Brasileiros de Oftalmologia*. 2016;**79**(1):63
- [72] Wong C, Ng S, Cheung C, Wong T, Mathur R. Zika-related maculopathy. *Retinal Cases & Brief Reports*. 2017:1-3
- [73] Parke DW 3rd, Almeida DR, Albini TA, Ventura CV, Berrocal AM, Mittra RA. Serologically confirmed Zika-related unilateral acute maculopathy in an adult. *Ophthalmology*. 2016;**123**(11):2432-2433
- [74] Panday A, Sandy S, King D, Ramdeen S. A case of suspected symptomatic Zika neuroretinitis. *IDCases*. 2017;**9**:104-105
- [75] Henry CR, Al-Attar L, Cruz-Chacon AM, Davis JL. Chorioretinal lesions presumed secondary to Zika virus infection in an immunocompromised adult. *JAMA Ophthalmology*. 2017;**135**(4):386-389
- [76] Barzon L, Trevisan M, Sinigaglia A, Lavezzo E, Palù G. Zika virus: From pathogenesis to disease control. *FEMS Microbiology Letters*. 2016;**363**(18):1-17
- [77] Sikka V, Chattu V, Popli R, Galwankar S, Kelkar D, Sawicki S, et al. The emergence of zika virus as a global health security threat: A review and a consensus statement of the INDUSEM joint working group (JWG). *Journal of Global Infectious Diseases*. 2016;**8**(1):3-15
- [78] Hayes EB. Zika virus outside Africa. *Emerging Infectious Diseases*. 2009;**15**(9):1347-1350
- [79] Adebajo T, Godfred-Cato S, Viens L, Fischer M, Staples E, Kuhnert-Tallman W. Update: Interim guidance for the diagnosis, evaluation, and Management of Infants with possible congenital Zika virus infection — United States, October

2017. MMWR. Morbidity and Mortality Weekly Report. 2017;**66**(41):1089-1099

[80] Sun J, Wu D, Zhong H, Guan D, Zhang H, Tan Q, et al. Presence of Zika virus in Conjunctival fluid. *JAMA Ophthalmology*. 2016;**134**(11):1330-1332

[81] Hazin AN, Poretti A, Turchi CM, Huisman TA. Computed tomographic findings in microcephaly associated with Zika virus. *The New England Journal of Medicine*. 2016;**374**(22):2192-2193

[82] Control. ECfDPa. Interim guidance for healthcare providers and Zika virus laboratory diagnosis. Stockholm; 2016

[83] Ahmad SS, Amin TN, Ustianowski A. Zika virus: Management of infection and risk. *BMJ*. 2016;**352**:i1062

[84] Ventura CV, Ventura LO, Bravo-Filho V, Martins TT, Berrocal AM, Gois AL, et al. Optical coherence tomography of retinal lesions in infants with congenital Zika syndrome. *JAMA Ophthalmology*. 2016;**134**(12):1420-1427

[85] de Oliveira Dias JR, Ventura CV, Borba PD, de Paula FB, Pierroti LC, do Nascimento AP, et al. Infants with congenital zika syndrome and ocular findings from São Paulo, Brazil: Spread of infection. *Retinal Cases and Brief Reports*. 2018;**12**(4):382-386

[86] Campos AG, Lira RP, Arantes TE. Optical coherence tomography of macular atrophy associated with microcephaly and presumed intrauterine Zika virus infection. *Arquivos Brasileiros de Oftalmologia*. 2016;**79**(6):400-401

[87] Rausch K, Hackett BA, Weinbren NL, Reeder SM, Sadovsky Y, Hunter CA, et al. Screening bioactives reveals Nanchangmycin as a broad

Spectrum antiviral active against Zika virus. *Cell Reports*. 2017;**18**(3):804-815

[88] Albulescu IC, Kovacicova K, Tas A, Snijder EJ, van Hemert MJ. Suramin inhibits Zika virus replication by interfering with virus attachment and release of infectious particles. *Antiviral Research*. 2017;**143**:230-236

[89] Yu Y, Deng YQ, Zou P, Wang Q, Dai Y, Yu F, et al. A peptide-based viral inactivator inhibits Zika virus infection in pregnant mice and fetuses. *Nature Communications*. 2017;**8**:15672

[90] Li C, Deng YQ, Wang S, Ma F, Aliyari R, Huang XY, et al. 25-Hydroxycholesterol protects host against Zika virus infection and its associated microcephaly in a mouse model. *Immunity*. 2017;**46**(3):446-456

[91] Yuan S, Chan JF, den-Haan H, Chik KK, Zhang AJ, Chan CC, et al. Structure-based discovery of clinically approved drugs as Zika virus NS2B-NS3 protease inhibitors that potently inhibit Zika virus infection in vitro and in vivo. *Antiviral Research*. 2017;**145**:33-43

[92] Chan JF, Chik KK, Yuan S, Yip CC, Zhu Z, Tee KM, et al. Novel antiviral activity and mechanism of bromocriptine as a Zika virus NS2B-NS3 protease inhibitor. *Antiviral Research*. 2017;**141**:29-37

[93] Poland GA, Kennedy RB, Ovsyannikova IG, Palacios R, Ho PL, Kalil J. Development of vaccines against Zika virus. *The Lancet Infectious Diseases*. 2018;**18**(7):e211-e219

[94] Abbink P, Stephenson KE, Barouch DH. Zika virus vaccines. *Nature Reviews. Microbiology*. 2018;**16**(10):594-600

[95] Masmajan S, Baud D, Musso D, Panchaud A. Zika virus, vaccines, and antiviral strategies. *Expert*

Review of Anti-Infective Therapy.
2018;**16**(6):471-483

[96] Larocca RA, Abbink P, Peron JP, Zanutto PM, Iampietro MJ, Badamchi-Zadeh A, et al. Vaccine protection against Zika virus from Brazil. *Nature*. 2016;**536**(7617):474-478

[97] Xu K, Song Y, Dai L, Zhang Y, Lu X, Xie Y, et al. Recombinant chimpanzee adenovirus vaccine AdC7-M/E protects against Zika virus infection and testis damage. *Journal of Virology*. 2018;**92**(6):1-16

[98] Ventura LO, Lawrence L, Ventura CV, Dutton GN, Marinho P, Ferro PF, et al. Response to correction of refractive errors and hypoaccommodation in children with congenital Zika syndrome. *Journal of AAPOS*. 2017;**21**(6):480-484.e1

[99] Zandi S, Bodaghi B, Garweg JG. Review for disease of the year: Treatment of viral anterior uveitis: A perspective. *Ocular Immunology and Inflammation*. 2018;**26**(7):1135-1142

[100] Merle H, Najioullah F, Chassery M, Césaire R, Hage R. Zika-related bilateral hypertensive anterior acute uveitis. *JAMA Ophthalmology*. 2017;**135**(3):283-284

[101] Zaidi MB, De Moraes CG, Petitto M, Yopez JB, Sakuntabhai A, Simon-Lorieri E, et al. Non-congenital severe ocular complications of Zika virus infection. *JMM Case Report*. 2018;**5**(6):e005152

[102] Ventura LO, Ventura CV, Dias NC, Vilar IG, Gois AL, Arantes TE, et al. Visual impairment evaluation in 119 children with congenital Zika syndrome. *Journal of AAPOS*. 2018;**22**(3):218-222 e1

[103] Ventura LO, Ventura CV, Lawrence L, van der Linden V, van der Linden A, Gois AL, et al. Visual impairment in children with congenital Zika syndrome. *Journal of AAPOS*. 2017;**21**(4):295-299.e2