

We are IntechOpen, the world's leading publisher of Open Access books Built by scientists, for scientists

6,900

Open access books available

186,000

International authors and editors

200M

Downloads

Our authors are among the

154

Countries delivered to

TOP 1%

most cited scientists

12.2%

Contributors from top 500 universities



WEB OF SCIENCE™

Selection of our books indexed in the Book Citation Index
in Web of Science™ Core Collection (BKCI)

Interested in publishing with us?
Contact book.department@intechopen.com

Numbers displayed above are based on latest data collected.
For more information visit www.intechopen.com



Scleral-Fixated Intraocular Lens: Indications and Results

Simona-Delia Nicoară

Abstract

Currently, ideal cataract surgery should end with the placement of an intraocular lens (IOLs) in the bag. However, in the clinical setting we have to manage cases without enough capsular support to allow the physiological IOL placement. Progress has been made in terms of IOL designs and implantation techniques. The options should be analyzed not only in accordance with surgeon's experience but also with patient's age, local, and systemic comorbidities. Thus, in the absence of an appropriate capsule, IOL can be placed in the anterior chamber, fixated to the iris or to the sclera wall. In this paper, the personal experience of one surgeon with ab externo scleral-fixated IOLs is presented, with the aim to outline the place of this surgical technique in the correction of aphakia. A retrospective study was carried out, including 57 patients in which an IOL was fixated to the sclera, throughout January 2015–April 2019. The causes of aphakia, preoperative and postoperative best-corrected visual acuities (BCVA), and intra- and postoperative complications are analyzed. Statistical tests were applied in order to draw significance. In most instances, BCVA has remained stable, with no significant complications, making sclera fixation IOL a viable solution in the correction of aphakia.

Keywords: scleral-fixated IOL, aphakia, cataract surgery, eye trauma, lens dislocation

1. Introduction

Ideal correction of aphakia means the placement of the intraocular lens (IOLs) in the bag which relies on good capsular support [1–3]. In these circumstances, IOL is well centered to the pupillary axis, maximizing the chances of optimal surgical and refractive outcomes [2].

In the absence of adequate posterior capsular support, like in complicated cataract surgery with disruption of the posterior capsule, it is often possible to place the IOL in the sulcus with excellent visual outcome [1, 3].

However, in the clinical practice there are situations like trauma, diseases, and complicated cataract surgery that result in inadequate anterior and posterior capsular support, making the conventional in-the-bag or in the sulcus placement of the IOL impossible.

Addressing this situation can be managed in several ways, like anterior chamber (ACIOLs), iris-fixated (IFIOLs), and scleral-fixated (SFIOLs) [2, 3]. Choosing the best technique in the absence of capsular support can be challenging, although all these variants proved to have similar benefits and risks [2, 3].

A vitreoretinal surgeon is relatively frequently confronted with the situation to place an IOL in an eye without capsular support following the various conditions: trauma, complicated cataract surgery, and different ocular diseases. Trauma is of special interest, since it affects younger patients and is frequently followed by other changes in eye anatomy that add difficulty to the IOL implantation procedure. General conditions such as Marfan syndrome and homocystinuria affect young people with long life expectancy, so finding the best long-term solution for them is mandatory.

After an overview on the possibilities to correct aphakia in the absence of capsular support, with focus on the SFIOLs, personal experience with SFIOLs will be presented.

2. Correction of aphakia in the absence of capsular support: Overview

When facing an aphakic eye with no capsular support, the IOL can be placed in the anterior chamber, fixated to the iris (in its extreme or mid-periphery) or fixated to the sclera. The surgical techniques in all of these approaches have improved considerably over the last decades with subsequent optimization of visual and ocular outcomes [3].

2.1 ACIOLs

Placement of an IOL in the AC requires a healthy endothelium and a normal depth of the AC [2]. This technique has the advantages of being simple and quick. Modern designs of ACIOLs with flexible open-loop haptics and anteriorly vaulted optics make them beneficial for many patients [2]. However, they are not suitable for patients with glaucoma, endothelial compromise, significant iris trauma, or diabetic retinopathy.

Complications related to ACIOLs, even if rarer now, are still cited: uveitis-glaucoma-hyphema (UGH) syndrome and cystoid macular edema [2]. The general idea is that ACIOLs are in decline, as their placement requires bigger incisions, more astigmatism with suturing, and slower visual recovery [2].

2.2 IFIOLs

Some surgeons' experience reveals that IFIOLs are more efficient than ACIOLs and even developed an ideal patient profile benefiting from them: older, with average-sized anterior segments, especially if they have some remnants of capsule and vitreous that help stabilize the lens. The haptics have to be fixated to the iris as peripherally as possible. The complications associated with this type of implant are intra- and postoperative hyphema, cystoid macular edema, uveitis, and glaucoma. Even if the IFIOL is properly fixated, there is a certain degree of IOL mobility, with subsequent mechanical trauma from pseudophacodonesis, which is why most surgeons do not indicate them in younger patients [2]. Another reason of concern is suture longevity, requiring another surgery down the road [2].

The sutureless iris-claw IOLs are inserted through a 5-mm incision and are attached to the mid-peripheral iris with the help of an in-clavation needle that grabs iris tissue between claws on either side of the lens while the pupil is kept miotic. A study of 2 years follow-up showed good visual functional recovery and lack of complications related to this technique [2].

2.3 SFIOLs

An IOL can be fixated at the sclera in several ways: with sutures, with no sutures by tunneling of the haptics, and with fibrin glue.

Suturing an IOL to the sclera is the most technically demanding procedure among the others discussed here, but it has two major advantages: durability and security.

When dealing with a dislocated IOL, several factors have to be considered: IOL type, extent of dislocation, and status of the capsular bag. If a one-piece in the bag IOL is partially dislocated, trans-scleral suture fixation is preferred. If a one-piece IOL is completely dislocated, it is recommended to be replaced with a three-piece IOL which is sutured to the sclera. If retinal pathology is associated, it is preferable to leave the eye aphakic to quiet down and perform the implantation in a second step. For example, once the retinal detachment is fixed and stable, a scleral-fixated three-piece IOL is carried out.

SFIOLs have drawbacks too. The patient is left with a subconjunctival suture, so in case of conjunctival erosion, the suture is exposed and makes way for bacteria to enter the eye and cause endophthalmitis. Therefore, it is desirable to bury the sutures. In order to prevent conjunctival erosion, Lewis imagined a method to bury the knot under a triangular scleral flap performed before entering the eye and the covering of the knot with the hinged scleral tissue at the end of surgery [3].

To avoid the use of sutures, tunneling of IOL haptics was imagined [2].

Another method to secure the IOL at the sclera is with fibrin glue. The pioneer of this technique advocates that it inhibits pseudophacodonesis better than the other variants. IOL movement inside the eye generates inflammation which is at the origin of cystoid macular edema [2].

An issue related to IOL fixation at the sclera comes from the fact that surgery is performed at pars plana, which is a region where anterior segment surgeon does not feel very comfortable. This is why this technique is preferred mostly by vitreoretinal surgeons.

All of the abovementioned alternatives to fixate an IOL inside an aphakic eye without capsular support produce good visual outcomes. Decision-making process relies on several factors: eye anatomy, other pathologies, patient's age, visual potential, and surgeon's comfort. It is equally important to know when a certain technique is contraindicated. Ideally, ophthalmic surgeon should master several techniques and be able to adjust plans during surgery [2].

3. Scleral-fixated intraocular lens: Indications and results: Personal experience

3.1 Aim

In this paper, the personal experience of one surgeon with ab interno scleral-fixated IOLs is presented, with the aim to outline the place of this surgical technique in the correction of aphakia.

3.2 Methods

This is a retrospective study that includes 57 aphakic eyes belonging to 57 patients who underwent ab interno scleral fixation of IOL during January 2015 to April 2019 at our tertiary care Ophthalmological Department, Emergency County Hospital from Cluj-Napoca, Romania. The patients were in the 10–89 years age group.

The detailed history was taken from each patient regarding any systemic or ocular condition. A written informed consent was taken from each patient before procedure.

Ophthalmological examination included grading of the visual acuity (VA) with the decimal system, followed by slit lamp examination of the anterior and posterior

segment, examination of retinal periphery, and measurement of intraocular pressure by applanation tonometry. B-scan and OCT were performed whenever necessary. A-scan biometry was carried out before the procedure in all cases to find the value of the IOL to be implanted.

The data were analyzed statistically with the Program SPSS 21.0. Chi-square test was used to find statistical significance. A p-value < 0.05 was considered significant.

This study was approved by the Ethics Committee belonging to the “Iuliu Hatieganu” University of Medicine and Pharmacy, and it is performed in accordance with the Declaration of Helsinki regarding the clinical studies involving human subjects.

3.3 Surgical procedure

All patients were operated by the same surgeon in local anesthesia, with the exception of one 10-year-old child with Marfan syndrome.

Pars plana vitrectomy (PPV) was performed in all cases to remove the lens/nucleus/IOL from the vitreous. The three subluxated lenses were removed by pars plana approach (lensectomy).

Conjunctival peritomies were created superiorly, then at horizontal meridians. Triangular partial-thickness (about 1/3 of the scleral thickness) limbal-based scleral flaps were dissected at horizontal meridians (9 o'clock and 3 o'clock position).

Intraocular pressure (IOP) was maintained with pars plana scleral infusion throughout surgery.

A 6-mm sclerocorneal tunnel incision was created superiorly, at 12 o'clock position, and anterior chamber (AC) was entered with a 2.2-mm knife. All vitreous was removed from the anterior chamber, if present, with the posterior vitrector. In the meantime, the two sutures (10-0 PC9 polypropylene) had been fixed to the IOL haptics of the specially designed IOL (**Figure 1**).

The long-curved needle carrying the 10-0 PC9 suture entered the AC and then exteriorized through the sclera, at 9 o'clock meridian, about 1–2 mm posterior from the posterior surgical limbus. The procedure was repeated similarly with the second needle (**Figure 2**).

The IOL was inserted in the sulcus, while the sutures were pulled, in order to center it. The haptics were secured at the sclera with knots that were buried under the previously fashioned scleral flaps (**Figure 3**).

Corneoscleral incision was sutured with 10-0 polypropylene sutures and the conjunctiva, with 8-0 vicryl sutures (**Figure 4**).

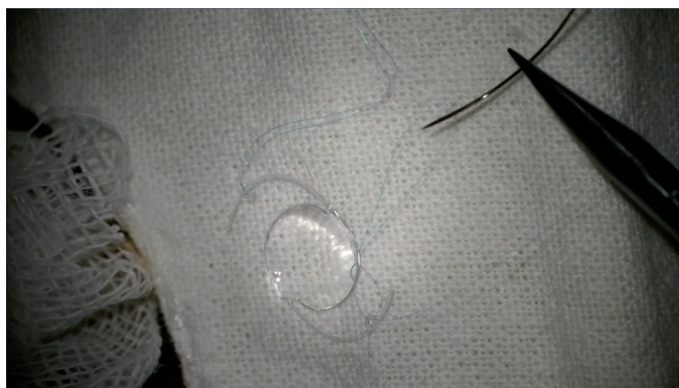

Figure 1.
IOL for scleral fixation - model CZ 70 BD (Alcon).

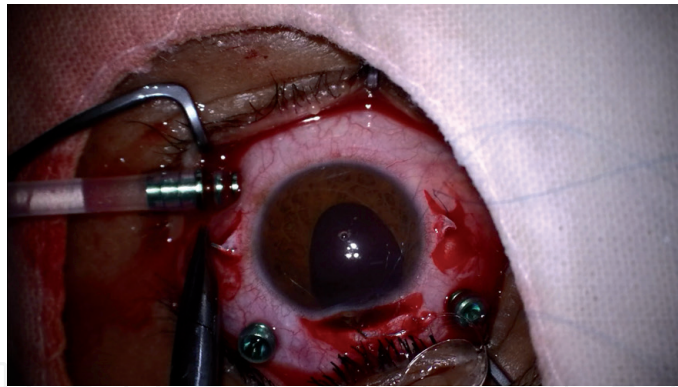


Figure 2.
Ab interno IOL implantation by suturing it to the sclera. Scleral flaps are visible at the horizontal meridian.

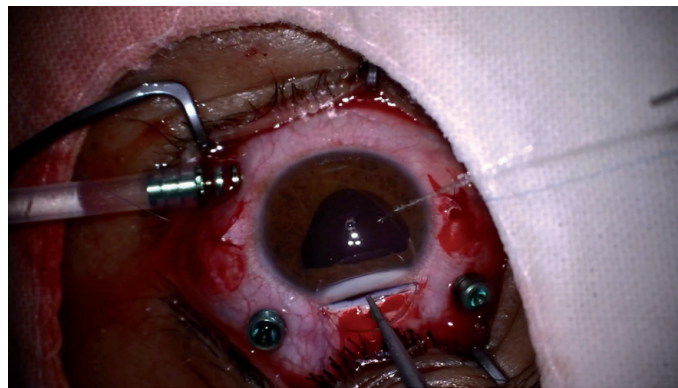


Figure 3.
IOL is pushed behind the iris, whereas the 2 sutures are pulled in order to center it.

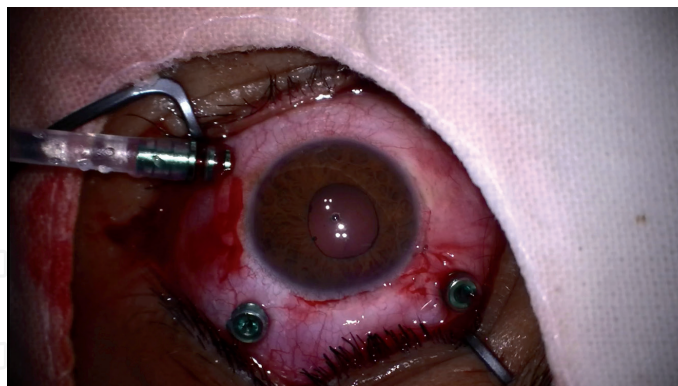


Figure 4.
IOL is well centered, the conjunctiva is sutured, the 3 ports of PPV are visible.

All patients were examined the next day after surgery, followed 1 week and then every month, for 3 months. At each visit, best-corrected visual acuity (BCVA) was noted and slit lamp examination, indirect ophthalmoscopy, and IOP measurement were performed. Wherever necessary, ultrasound and OCT examination were carried out.

In all cases, CZ70BD (Alcon, Fort Worth, TX) has been used. It incorporates eyelets on each haptic through which sutures can be passed that help to prevent suture slippage and subsequent IOL dislocation. Since this IOL has only two eyelets, two-point fixation technique has been used in all cases. The suture of choice was 10-0 polypropylene with PC9 needles.

3.4 Results

Fifty-seven patients were included in this study, with a mean age of 64.22 years. Minimum age in our series was 10 years, whereas maximum age was 89 years. Age distribution of patients is presented in **Table 1**.

Out of 57 patients, 40 were males (70.17%) and 17 were females (29.82%).

The cause that led to aphakia requiring scleral fixation of the IOL was represented by trauma in 30 patients (52.63%), complicated cataract surgery in 24 patients (42.10%), and subluxated lens in 3 patients (5.26%).

Medium age within the three groups was 61.10 years within the trauma group, 65.20 years within the postcataract surgery group, and 37 years within the subluxated lens group. These data are summarized in **Table 2**.

Within the trauma group, 24 patients were males (80%) and 6 patients were females (20%). Within the complicated cataract surgery group, 15 patients were males (62.50%) and 9 were females (37.50%). Within the subluxated lens group, one patient was male (33.33%) and two were females (66.66%).

T-test found a p-value <0.05 when comparing gender distribution between the first two groups: there was significantly more men than women within the trauma group as opposed to the postcataract surgery group.

Preoperative BCVA ranged between hand motion (HM) and 5/10, and it is illustrated in **Table 3**.

Preoperative BCVA according to the cause is illustrated in **Table 4**.

In nine cases (15.78%), there was a history of retinal detachment (RD) prior to IOL suture: five within the group of patients with complicated cataract surgery and four within the trauma group. In these circumstances, the strategy was to operate first RD, and if the retina was stable after tamponade agent removal, scleral fixation of the IOL was performed.

In five cases from the trauma group, an IOL was luxated into the vitreous cavity. In all situations we replaced it with an IOL specially designed for scleral fixation: CZ70BD (Alcon, Fort Worth, TX).

In six cases from the trauma group, an intraocular foreign body had been removed by PPV several months prior to IOL fixation.

Age decade	Number of patients	%
<50	12	21.05
51–60	8	14.03
61–70	10	17.54
71–80	19	33.33
>80	8	14.03

Table 1.
Age distribution of patients with scleral-fixed IOL.

Cause	Number of cases	%	Medium age (years)
Trauma	30	52.63	61.10
Postcataract	24	42.10	65.20
Surgery Subluxated lens	3	5.26	37

Table 2.
Causes of aphakia and medium age according to it.

BCVA	Before surgery (%)	Last visit after surgery (%)
<1/50	7 (12.28)	4 (7.01)
≥1/50 <1/10	32 (56.14)	28 (56.14)
≥1/10	18 (31.57)	25 (43.85)

Table 3.
BCVA before and at the last visit after surgery.

Cause/BCVA	<1/50	≥1/50 <1/10	≥1/10
Trauma	4	13	13
Previous cataract	3	16	5
Surgery subluxated lens	—	3	—

Table 4.
Preoperative BCVA according to the cause.

In two cases we noted breaking of sutures during surgery which was solved by replacing it. Breakage of one IOL haptic was encountered in one case, and it was solved by IOL replacement.

Intraoperatively soft eye was encountered in 11 cases (19.29%), and it was solved by adjusting the infusion pressure.

The most common complication during surgery was hemorrhage: 20/57 cases (35.08%). It was mild/moderate, and self-limiting, and it happened during puncturing the sclera with the PC9 needle in all cases. The blood was washed out with the PPV infusion system.

In the postoperative period, vitreous hemorrhage persisted in 10 cases (17.54%) and resolved spontaneously in 9 of them. PPV was performed in the remaining case, 4 weeks after IOL fixation, with good outcome: BCVA 5/10.

In three cases (5.26%), mild corneal edema was noted, with complete resolution under medical treatment.

Postoperative anterior uveitis was noted in seven patients (12.28%) who responded positively to medical treatment. In one of them, uveitis was present before IOL fixation; therefore we consider that our procedure reactivated it, rather than produced it.

Cystoid macular edema (CME) was identified in three cases (5.26%).

In one case, we had to reposition the IOL, due to high astigmatism (−6D) caused by IOL tilt, with good final outcome: BCVA 7/10.

Chronic glaucoma requiring long-term topical treatment was diagnosed in three patients in our series (5.26%), all within the trauma group.

We report no chronic corneal edema, no retinal detachment, and no suture break with subsequent IOL dislocation in the postoperative period in this series.

Uncorrected visual acuity improved in all cases within this series. BCVA of 5/10 or better was noted in 22 cases (38.59%). **Table 3** shows BCVA at the last control visit (3 months after surgery).

3.5 Discussion

Recovery of the visual function in an aphakic patient is challenging. Aphakic glasses are not an option, because of their high magnification and subsequent aniseikonia [4]. Contact lenses are difficult to handle, especially in older patients

(medium age in our group was 64.22 years) who have never worn them before. Therefore, the only viable option in these cases is to place an IOL inside the eye. Since the capsular support is not adequate for IOL placement in the bag or in the sulcus, the available placement possibilities are anterior chamber, iris fixation (in its extreme or mid-periphery), or suture at the sclera.

Scleral fixation of an IOL is a safe option, and therefore it is the most used one in our practice. This preference is also explained by the fact that a vitreoretinal feels more comfortable working around pars plana and behind the iris plane, as compared to the AC.

The medium age of our patients (64.22 years) is higher as reported in the literature [4]. This might be partially explained by the high number of cases with previous complicated cataract surgeries (42.10%), since we are a referral center in the area. However, the medium age within the group with complicated cataract surgery is not significantly higher than within the trauma group: 65.20 years vs. 61.10 years, respectively. One observation is that five patients with posttraumatic IOL dislocation in the vitreous cavity were included in the trauma group, contributing to the increase of the medium age in this group.

As expected, men accounted for the majority of trauma cases: 24/30 (80%). In the group with complicated cataract surgery, male predominance, even if not so obvious, was still identified: 15/24 (62.50%).

3.5.1 Comments related to the IOL

In all cases we used the IOL model CZ70BD (Alcon, Fort Worth, Texas) (**Figure 1**). This is a rigid PMMA IOL. Foldable IOLs designed for sclera fixation were not available.

Since this IOL has only two eyelets, two-point fixation technique has been used in all cases. Therefore, it is more susceptible to IOL tilt which leads to higher-order aberrations that cannot be corrected with eyeglasses. In our series, in one single case we had to reposition a tilted IOL that determined high astigmatism (6D). Final outcome, after repositioning the IOL, was favorable, with BCVA 7/10.

Studies comparing the tilt concluded that it was significantly higher in SFIOL patients than in the ones with IOL in-the-bag [5].

Another IOL designed for being sutured at the sclera, Akreos AO 60 (Bausch & Lomb, Rochester, NY), has four haptics, each with its own eyelet for suture passage. The four-point fixation is theoretically associated with a lesser risk of tilt and dislocation, though there is no study comparing the differences in tilt between CZ70BD and Akreos AO 60 so far [6, 7]. Another major difference between the two implants is that Akreos AO 60 is hydrophilic and therefore susceptible to optic opacification by calcium salt deposition in case of air or gas filling of the eye [8]. Since the probability of future PPVs followed by internal tamponade in these complex cases is not negligible, Akreos AO 60 is not the optimal choice for these patients.

IOL dislocation following suture breakage is one serious complication, and it determines sudden visual drop. Since the last reported control visit in our patients is 3 months, the risk of this complication is still present, especially as most studies report it between 2 and 5 years after surgery [9]. The 10–0 polypropylene sutures that we used in all our patients are designated for sewing and ligation soft tissues in cardiovascular, neurological, and ophthalmic surgeries. Even if these sutures are firm and durable, there are reports indicating that they might not be a long-term solution to fixate an IOL [9]. Therefore, some surgeons recommend the use of 9–0 polypropylene sutures in these circumstances. Nevertheless, suture breakage was reported even with this type of sutures, especially in young adults and children [9]. An issue of concern related to the 9–0 polypropylene suture is related to the size of the knot. A bigger knot is associated with a higher risk of sclera atrophy,

erosion, and resultant endophthalmitis [9]. This drawback is overcome by creating the sclera flaps covering the knots or by using an intrascleral Z suture instead of the knot [4].

When evaluating a surgical procedure in ophthalmology, there are two important interfering elements to discuss: its impact on visual acuity and the complications related to it.

3.5.2 Visual acuity

In our series, BCVA of 5/10 or better was noted in 22 cases (38.59%). This is lower than reported by other authors [4, 10, 11], but the difference is that we did not exclude from our study the patients with associated lesions: RD, IOFB, and ruptured globe. In these circumstances, the final functional prognosis is influenced not only by IOL implantation technique but mainly by the consequences of other major ocular injuries.

The main advantage of surgery was that uncorrected visual acuity improved in every case in our series.

3.5.3 Complications

Since we used the infusion line of the PPV system, we were able to manage intraoperatively soft eye which may have had serious implications on functional recovery. Also, AC opening was performed cautiously, avoiding its sudden decompression which might have favored choroidal bleeding and detachment. The pars plana-placed infusion line allowed the maintenance of a relatively constant IOP throughout surgery.

We fashioned the sclera flaps before opening the AC, because the eye was more stable. Creating these flaps, even if laborious, is a very important step, aimed to increase the postoperative comfort of the patient and decrease the risk of endophthalmitis by burying the knots under them, which we did in all cases. Therefore, we report no case of postoperative endophthalmitis in this series.

Hemorrhage during surgery occurred in 20/57 cases (35.08%), and it was mild/moderate and self-limiting. It was produced during puncturing the sclera with the PC9 needle in all cases. This maneuver is performed “blindly” without actually seeing the tip of the needle but rather “feeling” it in its way through the sclera.

In the postoperative period, hemorrhage persisted in 10 cases (17.54%) but resolved spontaneously in 9 of them. In one case we had to reoperate the patient by PPV, 4 weeks after IOL suturing, since the hemorrhage had no tendency to clear. Final outcome was positive, with visual acuity of 5/10.

Postoperative astigmatism varied between -1.00D. cyl and -6D. cyl . The causes of astigmatism are corneal incision which is larger than in circumstances in which foldable IOLs are used, tight sutures, and IOL misalignment or tilt [3]. As previously mentioned, the high astigmatism due to IOL tilt forced us to reposition the IOL in only one situation that resolved positively, with final VA 7/10. Astigmatism could be significantly reduced by using foldable lenses for scleral fixation that can be inserted through smaller incisions.

Iris manipulation when fixating an IOL to the sclera is definitely more intense than when placing a foldable IOL in the bag; therefore an inherent complication is anterior uveitis, which we encountered in seven cases in our series (12.28%), a lower percentage than we found in the literature [3, 9]. Anterior uveitis responded promptly to medical therapy and resolved within 2–4 weeks after surgery.

CME was identified in three cases (5.26%) and prevented the increase of visual acuity. One possible explanation for it might be IOL instability inside the eye [2].

3.5.4 Advantages of scleral-fixated IOLs

One major advantage of scleral-fixated IOL, especially for a vitreoretinal surgeon, is that any future vitreoretinal surgery procedure can be performed with no risk of IOL dislocation, as may happen in anterior placed IOLs [12]. Moreover, these complicated cases in which secondary IOLs are indicated are at risk to develop posterior segment complications that require proper examination and even surgical treatment. Pupil dilatation and examination of the retina and vitreous are much easier in an eye with scleral-fixated IOL than in one with ACIOL or iris-fixated IOL [12]. Besides, PPV which is usually performed before suturing IOL at the sclera considerably decreases the risk of future posterior segment complications in these patients.

In all our cases, prior to suturing IOL at the sclera, PPV has been performed. This contributed to visual function improvement by eliminating all the debris, blood, and inflammatory cells from the vitreous cavity which are specific for the posttraumatic and complicated postcataract surgery settings [12].

Scleral-fixated IOL should be the preferred technique to correct aphakia also because it is more physiological than anterior segment IOL placement, which may be associated with the risk of corneal touch and loss of endothelium, anterior uveitis, and glaucoma in the long run [5]. Chronic glaucoma requiring long-term topical treatment was diagnosed in three patients in our series (5.26%), all in the trauma group, which allows us to speculate that posttraumatic injuries, rather than the surgical technique itself, were more likely to cause it.

Some surgeons advocate that in experienced hands, fixating an IOL to the sclera offers a visual prognosis which is good enough to favor this procedure as the standard of care for correcting aphakia in patients with insufficient capsular support [12]. With its limitations and lack of long-term follow-up, our study supports this idea. Larger sample and longer-term follow-up are necessary to establish the safety and complications associated with scleral-fixated IOLs. Also, there is room for innovating IOL designs and surgical techniques, like sutureless glueless scleral fixation IOL [13].

4. Conclusions

Ab interno scleral fixation of a rigid IOL was a safe and viable technique to correct aphakia in patients with inappropriate capsular support in this series.

During surgery, the most frequent complication was mild vitreous hemorrhage which was self-limiting and did not prevent the recovery of visual acuity.

The complications noted in the postoperative period were few and did not influence the overall visual prognosis.

The limitations of this study are the relatively small sample of patients and the short-term follow-up.

Studies on higher number of patients and with longer follow-up are mandatory in order to outline the status of scleral-fixated IOL as the standard of care for correcting aphakia in patients with insufficient capsular support.

Acknowledgements

Not applicable.
No funding.

Conflict of interest

The author declares no conflict of interest related to the publication of this paper.

IntechOpen

IntechOpen

Author details

Simona-Delia Nicoară
“Iuliu Hațieganu” University of Medicine and Pharmacy, Emergency County
Hospital, Cluj-Napoca, Romania

*Address all correspondence to: simonanicoara1@gmail.com

IntechOpen

© 2019 The Author(s). Licensee IntechOpen. This chapter is distributed under the terms of the Creative Commons Attribution License (<http://creativecommons.org/licenses/by/3.0>), which permits unrestricted use, distribution, and reproduction in any medium, provided the original work is properly cited. 

References

- [1] Wagoner MD, Cox TA, Ariyasu RG, Jacobs DS, Karp CL, American Academy of Ophthalmology. Intraocular lens implantation in the absence of capsular support: A report by the American Academy of ophthalmology. *Ophthalmology*. 2003;**110**(4):840-859
- [2] Brennan K. It's (Not) in the Bag: IOL Fixation. *Review of Ophthalmology* [Internet]. Available from: <https://www.reviewofophthalmology.com/article/its-not-in-the-bag-iol-fixation>
- [3] Stem MS, Todorich B, Woodward MA, Hsu J, Wolfe JD. Scleral-fixated intraocular lenses: Past and present. *Journal of VitreoRetinal Diseases*. 2017;**1**(2):144-152. DOI: 10.1177/2474126417690650
- [4] Reddy JML. Scleral fixation IOL: Outcome and complications. *Journal of Evolution of Medical and Dental Sciences*. 2016;**5**(20):991-993. DOI: 10.14260/jemds/2016/230
- [5] Hayashi K, Hayashi H, Nakao F, Hayashi F. Intraocular lens tilt and decentration, anterior chamber depth, and refractive error after trans-scleral suture fixation surgery. *Ophthalmology*. 1999;**106**(5):878-882. DOI: 10.1016/S0161-6420(99)00504-7
- [6] Fass ON, Herman WK. Four-point suture scleral fixation of a hydrophilic acrylic IOL in aphakic eyes with insufficient capsule support. *Journal of Cataract and Refractive Surgery*. 2010;**36**(6):991-996. DOI: 10.1016/j.jcrs.2009.12.043
- [7] Fass ON, Herman WK. Sutured intraocular lens placement in aphakic post-vitrectomy eyes via small-incision surgery. *Journal of Cataract and Refractive Surgery*. 2009;**35**(9):1492-1497. DOI: 10.1016/j.jcrs.2009.04.034
- [8] Cao D, Zhang H, Yang C, Zhang L. Akreos adapt AO intraocular lens opacification after vitrectomy in a diabetic patient: A case report and review of the literature. *BMC Ophthalmology*. 2016;**16**:82. DOI: 10.1186/s12886-016-0268-3
- [9] Wasiluk E, Krasnicki P, Dmuchowska DA, Proniewska-Skrettek E, Mariak Z. The implantation of the scleral-fixated posterior chamber intraocular lens with 9/0 polypropylene sutures—long-term visual outcomes and complications. *Advances in Medical Sciences*. 2019;**64**(1):100-103
- [10] Lee VY, Yuen HK, Kwok AK. Comparison of outcomes of primary and secondary implantation of sclera fixated posterior chamber intraocular lens. *The British Journal of Ophthalmology*. 2003;**87**(12):1459-1462. DOI: 10.1136/bjo.87.12.1459
- [11] Ghanem VC, Ghanem EA, Ghanem RC. Monoscleral fixation IOL after extra capsular extraction of subluxated lenses in patients with Marfan syndrome. *Arquivos Brasileiros de Oftalmologia*. 2004;**64**:763-767. DOI: org/10.1590/S0004-27492004000500013
- [12] Saxena D, Patel C. Visual outcome in scleral fixated intraocular lenses. *Journal of Evolution of Medical and Dental Sciences*. 2016;**5**(55):3716-3717. DOI: 10.14260/jemds/2016/852
- [13] Cheung CS, VanderVeen DK. Intraocular lens techniques in pediatric eyes with insufficient capsular support: Complications and outcomes. *Seminars in Ophthalmology*. 2019;**34**(4):293-302