

# We are IntechOpen, the world's leading publisher of Open Access books Built by scientists, for scientists

6,900

Open access books available

186,000

International authors and editors

200M

Downloads

Our authors are among the

154

Countries delivered to

TOP 1%

most cited scientists

12.2%

Contributors from top 500 universities



WEB OF SCIENCE™

Selection of our books indexed in the Book Citation Index  
in Web of Science™ Core Collection (BKCI)

Interested in publishing with us?  
Contact [book.department@intechopen.com](mailto:book.department@intechopen.com)

Numbers displayed above are based on latest data collected.  
For more information visit [www.intechopen.com](http://www.intechopen.com)



# Histopathology and Molecular Pathology of Vitiligo

*Amit Kumar Yadav*

## Abstract

Vitiligo is a common skin disorder that manifests as whitish macules. There is no special geographic or sex predilection. Vitiligo is a multifactorial disorder. The various theories proposed include neutral theory, autoimmune theory, zinc- $\alpha$ 2-glycoprotein theory, viral infection, intrinsic theory and melanocytorrhagy theory. However, the currently favored opinion is that there is a convergence of various theories known as the convergence theory. The basic defect is the absence of functional melanocytes from the epidermal melanin unit. This absence can be demonstrated by using special stains like Fontana-Masson, immunohistochemistry like HMB-45 and Melan-A and electron microscopy. Margins of lesions especially early lesions show inflammatory cells principally CD4+ and CD8+ T cells. The cornerstone of management in vitiligo is correct categorization of a case into stable and unstable vitiligo. This distinction is based mainly on clinical criteria. It is recommended that while evaluating biopsies, histopathological examination should be primarily concentrated on evaluating five histopathological variables—spongiosis, epidermal lymphocytes, basal cell vacuolation, dermal lymphocytes and melanophages. These parameters are then scored using a scoring system, and the recommended diagnoses based on these scores are given. Adoption of a systematic reporting system brings more consistency and objectivity in the diagnosis.

**Keywords:** vitiligo, multifactorial, convergence theory, melanocytes, histological scoring

## 1. Introduction

Vitiligo is a common acquired, idiopathic, progressive disorder which is characterized by the development of depigmented milky white macules of variable sizes. These often enlarge and coalesce to form extensive areas of leukoderma [1–3]. It equally affects both sexes with a worldwide prevalence of 0.1–2% [4]. It is a psychologically devastating and frequently resistant to treatment [5, 6]. The basic defect in vitiligo is a selective destruction of functional melanocytes [7].

The role of histopathology in the diagnosis of vitiligo is not yet fully established. So much so that routinely in these cases biopsy is not performed. The diagnosis is made primarily on clinical grounds.

## 2. Pathogenesis

Vitiligo is a multifactorial disorder [8, 9]. In its genesis both genetic and non-genetic factors are believed to play a role. It is observed that clinically no two patients of vitiligo are alike. This suggests that etiology also varies among different patients. Due to the observed variation in clinical manifestations of the disease, it seems likely that etiology of vitiligo may differ among patients [10]. These several theories have been combined into the convergence theory [11] which is currently the most accepted theory.

Briefly in the earliest theory, it was proposed by Lerner that vitiligo was neural in origin [12]. This theory could explain the segmental form of vitiligo which follows dermatomal distribution and is associated with hyperhidrosis and emotional disturbances. In another study the role of sympathetic nervous system in vitiligo was studied [13]. It was observed that the cutaneous blood flow in the lesional skin was three times higher than the normal skin in cases of segmental vitiligo. However, in other cases of non-segmental vitiligo, this was not observed.

Studies on the expression of neural proteins like neuropeptide Y (NPY), calcitonin gene-related peptide (CGRP), vasoactive intestinal polypeptide (VIP) and polyclonal general neuronal marker (PGP) have shown variable results. In one study NPY expression was found to be increased in cases of segmental vitiligo [14]. It is proposed that precipitating factors like stress lead to increased NPY expression [15].

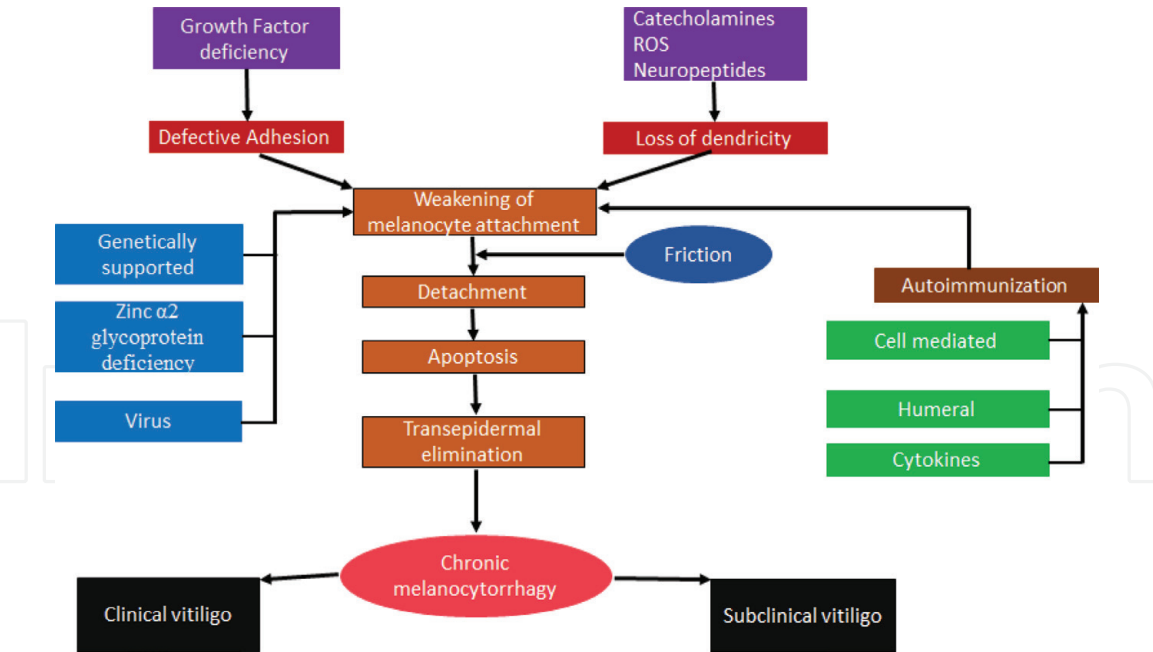
But this theory failed to explain the other forms of vitiligo. For that matter generalized or non-segmental vitiligo is better explained by autoimmune hypothesis. In previously done studies, antibodies against various targets like tyrosine hydroxylase, melanin-concentrating hormone receptor-1 (MCHR1), tyrosinase [16] and pigment cell surface antigens [17] have been demonstrated. In a study carried out to evaluate the various immunoglobulins, it was observed that 80% of active vitiligo patients showed the presence of IgG and IgM against melanocytes [17]. Other studies have shown the presence of anti-thyroglobulin antibodies, antithyroid antibodies, anti-thyroperoxidase and anti-smooth muscle antibody in these cases [18, 19].

Besides humoral immunity, cell-mediated immunity may also play an important role. Immunohistochemical examination of perilesional skin in vitiligo patients showed increased CD8:CD4 ratio and HLA-DR production along suprabasal and basal keratinocytes. Macrophages were found to be quite numerous [20]. However, not only the immune cells and antibodies but expression of various cytokines is also increased. Chief among these which have been studied are tumor necrosis factor- $\alpha$  (TNF- $\alpha$ ), interferon- $\gamma$  (IFN- $\gamma$ ) and IL-10 [21, 22]. IL-17 has also been shown to be significantly increased in cases of vitiligo [23].

The redox (reduction–oxidation) state of vitiliginous patients has been studied by many authors. These studies have shown increased serum levels of selenium, superoxide dismutase (SOD) and malondialdehyde (MDA) [24, 25]. Increased levels of these substances indicate the presence of oxidative stress in vitiligo. Increased levels of tetrahydrobiopterin [26] and xanthine oxidase [27] leading to increased levels of  $H_2O_2$  may also be contributory.

Few authors have pointed towards the role of zinc- $\alpha$ 2-glycoprotein (ZAG) in the pathogenesis of vitiligo. They hypothesize that lack of ZAG causes impaired melanocytic adhesion to other cells in the epidermis [28, 29]. The efficacy of zinc in the treatment of vitiligo may be due to its ability to precipitate ZAG at the site of vitiligo [30].

The role of viral infection in vitiligo has been proposed by certain authors. The potential candidates include hepatitis C virus (HCV) [31], cytomegalovirus (CMV) [32], Epstein–Barr virus (EBV), hepatitis e virus, herpes virus and HIV [33]. However, the evidence available is scant and not conclusive enough to attribute a significant role for viral agents in vitiligo.



**Figure 1.**  
*Pathogenesis of vitiligo.*

The intrinsic theory states that in vitiligo there is loss of melanocytes due to various abnormalities which lead to increased apoptosis [34] and accelerated cell senescence [35, 36]. Studies done previously have shown various abnormalities in the melanocytes including cytoplasmic vacuolization, DNA marginalization, dendrite loss and detachment [36, 37]. The evidence in favor of increased apoptosis in vitiligo includes reduced expression levels of the antiapoptotic proteins Bcl-2 and FLIP in vitiliginous skin as compared to normal skin [34]. On the other hand, marked increase in the expression of proapoptotic factors such as Bax and p53 along with the various caspases has also been observed [34].

The melanocytorrhagy theory states that in vitiligo there is chronic melanocyte detachment and loss caused by trauma and other stressors which include catecholamines, free radicals or autoimmune elements [38].

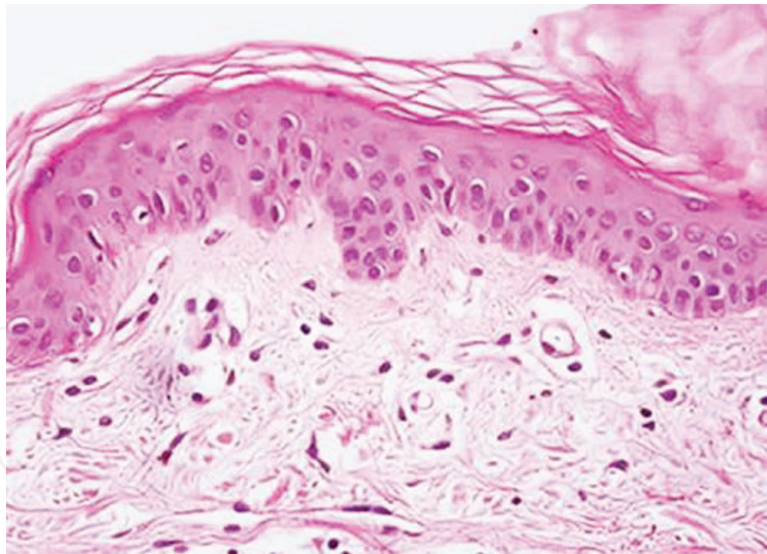
However, the consensus opinion of majority of experts is that vitiligo occurs due to convergence of these various pathways [39]. These are also depicted in (Figure 1). The author also is in agreement with this view; however, it is likely that in various subtypes of vitiligo the relative contribution of these pathways may vary. For example, in segmental vitiligo the neural theory may be more relevant than the other theories, whereas the same may not hold true for vitiligo vulgaris.

### 3. Histopathology

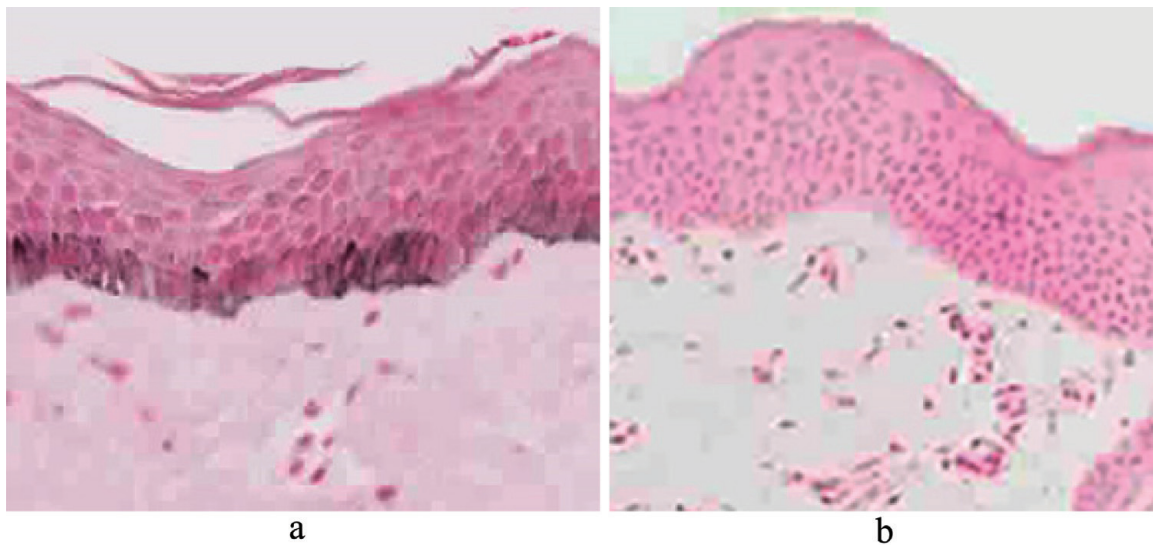
In order to understand the histopathology of vitiligo, it is essential to first understand the concept of *epidermal melanin unit* [40]. Melanocytes are neural crest derivatives, and they reach their final destination of basal layer of the epidermis and hair follicles via a process of migration. Each melanocyte then transfers its melanosomes to approximately 36 keratinocytes via a unique mechanism known as the shedding vesicle system. In the normal skin in the basal layer of the epidermis for every five basal keratinocytes, there is a presence of a single melanocyte [41].

The basic histopathological finding in vitiligo is the absence of functional melanocytes in the basal layer of the epidermis (Figure 2) [42–44]. This absence can also be demonstrated by using special stains like Fontana-Masson (Figure 3) [45].





**Figure 2.**  
*Vitiligo showing the absence of melanocytes in basal layer of the epidermis (H&E, X400).*



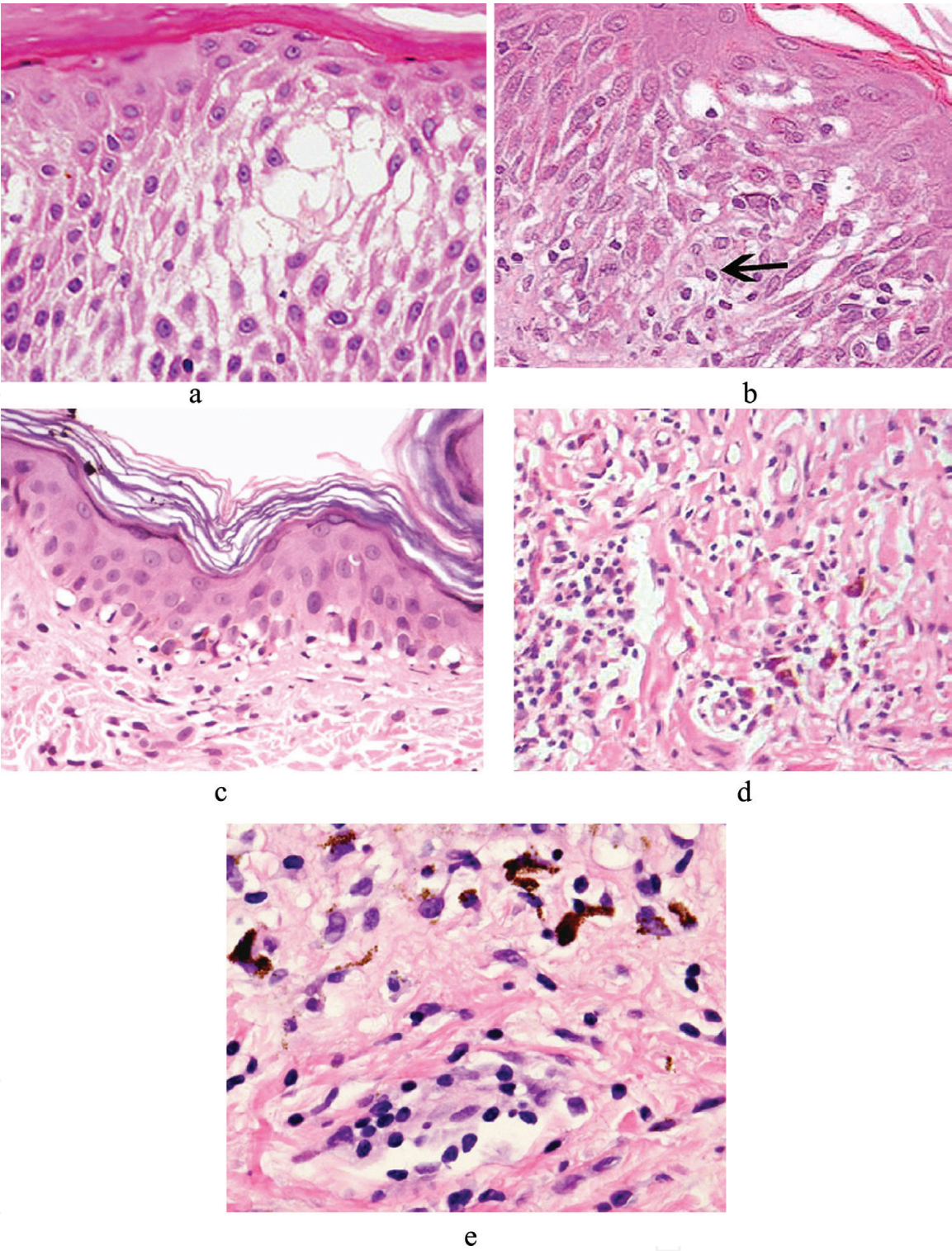
**Figure 3.**  
*(a) Fontana-Masson showing the presence of melanin pigment and melanocytes in the epidermis (X400).  
(b) Fontana-Masson showing the absence of melanin pigment and melanocytes in the epidermis (x400).*

Immunohistochemistry for melanocyte-specific markers like HMB-45 and Melan-A and electron microscopy can also be performed for this purpose.

Other changes that have been observed include degenerative changes in the nerves and adnexa like sebaceous glands and hair follicles especially in long-standing cases [46].

In the margins of lesions especially early lesions, often inflammatory cells are seen. Principally, these cells comprise of CD4+ and CD8+ T cells [47]. These cells have been shown to demonstrate melanocyte-specific cytotoxicity [48]. At the margins of the lesions, melanocytes have been observed to show morphological changes like cellular enlargement, cytoplasmic vacuolization and long dendritic processes [29].

However, usually skin biopsy is not performed for making the diagnosis as it is primarily a clinical diagnosis. The cornerstone of its management is correct categorization of a case into its two broad types—stable and unstable vitiligo. This distinction is at present based mainly on clinical criteria because the histopathological



**Figure 4.** (a) Spongiosis (H&E, x400). (b) Intraepidermal lymphocytes (H&E, x400). (c) Basal cell vacuolation (H&E, x400). (d) Dermal lymphocytosis (H&E, x200). (e) Dermal melanophages (H&E, x400).

features are not fully established. In a study carried out by the author, a reliable and systematic approach towards this diagnostic challenge has come up [49]. In that study the biopsies (3-mm punch) were taken from the margin of the active lesion.

The author recommends that while evaluating biopsies from cases of vitiligo histopathological examination should be primarily focused on evaluating five histopathological variables—spongiosis, epidermal lymphocytes, basal cell vacuolation, dermal lymphocytes and melanophages (**Figure 4**). The morphological criteria used to assess these parameters are listed in **Table 1**. All the cases are then scored



S. no.	Histological feature	Criteria
1	Spongiosis	Presence of at least one focus showing intercellular oedema in the epidermis
2	Epidermal lymphocytes	Presence of at least one lymphocyte in the epidermis
3	Basal cell vacuolation	Presence of at least one focus showing basal cell degeneration in the form of vacuolation
4	Melanophages	Presence of at least one focus in the superficial reticular dermis showing melanophages

**Table 1.**  
*Histomorphological criteria for spongiosis, epidermal lymphocytes, basal cell vacuolation and melanophages.*

S. no.	Histological feature	Observation	Score
1	Spongiosis	Present/absent	1/0
2	Epidermal lymphocytes	Present/absent	1/0
3	Basal vacuolation	Present/absent	1/0
4	Dermal lymphocytes >100	Present/absent	1/0
5	Melanophages	Present/absence	1/0

**Table 2.**  
*Vitiligo histological scoring system.*

S. no.	Total score	Diagnosis
1.	5	Unstable vitiligo
2.	4	Unstable vitiligo
3.	3	Favours unstable, clinical correlation required
4.	2	Favours stable, clinical correlation required
5.	0–1	Strongly favours stable vitiligo, clinical correlation essential

**Table 3.**  
*Final recommended diagnostic categories based on score.*

using a scoring system devised by the authors **Table 2**, and the recommended diagnoses based on these scores are shown in **Table 3**. The counting for dermal lymphocytes was done in high power (x400) of a Nikon microscope. The scoring system can be applied to both segmental and non-segmental vitiligo. Adoption of a systematic reporting system brings more consistency and objectivity in the diagnosis.

4. Conclusions

Vitiligo is a common skin disorder which is characterized by the presence of depigmented milky white macules of variable sizes. Although there are various theories on its etiopathogenesis, the consensus opinion is that vitiligo occurs due to convergence various pathways. The basic histopathological finding in vitiligo is the absence of functional melanocytes in the basal layer of the epidermis. However, in order to evaluate for stability, the histopathological examination should be primarily focused on evaluating spongiosis, epidermal lymphocytes, basal cell

vacuolation, dermal lymphocytes and melanophages. It is recommended to score these parameters, and the final report should incorporate recommended diagnosis based on the score. This will bring more objectivity and consistency in reporting these biopsies.

## Acknowledgements

The author wishes to acknowledge the help provided by Dr. Niti Khunger, Consultant, Dermatology, VMMC & Safdarjung Hospital, and Dr. Pallavi Mishra, Resident, VMMC & Safdarjung Hospital.

## Conflict of interest

The author wishes to declare that there are no conflicts of interest.

## Notes/thanks/other declarations


None declared.

## Author details

Amit Kumar Yadav  
Department of Pathology, Vardhman Mahavir Medical College and Safdarjung Hospital, New Delhi, India

\*Address all correspondence to: [path.yadav@gmail.com](mailto:path.yadav@gmail.com)

## IntechOpen

© 2019 The Author(s). Licensee IntechOpen. This chapter is distributed under the terms of the Creative Commons Attribution License (<http://creativecommons.org/licenses/by/3.0>), which permits unrestricted use, distribution, and reproduction in any medium, provided the original work is properly cited. 



## References

- [1] Koranne RV, Sachdeva KG. Vitiligo. *International Journal of Dermatology*. 1988;**27**:676-681
- [2] Nordlund JJ, Lerner AB. Vitiligo: It is important. *Archives of Dermatology*. 1982;**118**:5-8
- [3] Sharquie KE. Vitiligo. *Clinical and Experimental Dermatology*. 1984;**9**:117-126
- [4] Handa S, Kaur I. Vitiligo: Clinical findings in 1436 patients. *The Journal of Dermatology*. 1999;**26**:653-657
- [5] Namazi MR. Phenytoin as a novel anti-vitiligo weapon. *Journal of Autoimmune Diseases*. 2005;**2**:11
- [6] Mantovani S, Garbelli S, Palermo B, et al. Molecular and functional bases of self-antigen recognition in long-term persistent melanocyte-specific CD8+ T cells in one vitiligo patient. *The Journal of Investigative Dermatology*. 2003;**121**:308-314
- [7] Xia Q, Zhou WM, Liang YH, et al. MHC haplotypic association in Chinese Han patients with vitiligo. *Journal of the European Academy of Dermatology and Venereology*. 2006;**20**:941-946
- [8] Daneshpazhooh M, Mostofizadeh GM, Behjati J, Akhyani M, Mahmoud Robati R. Anti-thyroid peroxidase antibody and vitiligo: A controlled study. *BMC Dermatology*. 2006;**6**:3
- [9] Alkahateeb A, Fain PR, Thody A, Bennett DC, Spritz RA. Epidemiology of vitiligo and associated autoimmune disease in Caucasian probands and their families. *Pigment Cell Research*. 2003;**16**:208-214
- [10] Manolache L, Benea V. Stress in patients with alopecia areata and vitiligo. *Journal of the European Academy of Dermatology and Venereology*. 2007;**21**:921-928
- [11] Le Poole IC, Das PK, Van den Wijngaard RM, Bos JD, Westerhof W. Review of the etiopathomechanism of vitiligo: A convergence theory. *Experimental Dermatology*. 1993;**2**:145-153
- [12] Lerner AB. Vitiligo. *The Journal of Investigative Dermatology*. 1959;**32**:285-310
- [13] Wu CS, Yu HS, Chang HR, Yu CL, Yu CL, Wu BN. Cutaneous blood flow and adrenoceptor response increase in segmental-type vitiligo lesions. *Journal of Dermatological Science*. 2000;**23**:53-62
- [14] Al'Abadie MS, Senior HJ, Bleehen SS, Gawkrödger DJ. Neuropeptide and neuronal marker studies in vitiligo. *The British Journal of Dermatology*. 1994;**131**:160-165
- [15] Yehuda R, Brand S, Yang RK. Plasma neuropeptide Y concentrations in combat exposed veterans: Relationship to trauma exposure, recovery from PTSD, and coping. *Biological Psychiatry*. 2006;**59**:660-663
- [16] Kemp EH, Emhemad S, Akhtar S, Watson PF, Gawkrödger DJ, Weetman AP. Autoantibodies against tyrosine hydroxylase in patients with non-segmental (generalised) vitiligo. *Experimental Dermatology*. 2011;**20**:35-40
- [17] Harning R, Cui J, Bystryń JC. Relation between the incidence and level of pigment cell antibodies and disease activity in vitiligo. *The Journal of Investigative Dermatology*. 1991;**97**:1078-1080
- [18] Ingordo V, Gentile C, Iannazzone SS, Cusano F, Naldi L. Vitiligo

and autoimmunity: An epidemiological study in a representative sample of young Italian males. *Journal of the European Academy of Dermatology and Venereology*. 2011;**25**:105-109

[19] Uncu S, Yaylı S, Bahadır S, Okten A, Alpay K. Relevance of autoimmune thyroiditis in children and adolescents with vitiligo. *International Journal of Dermatology*. 2011;**50**:175-179

[20] Le Poole IC, van den Wijngaard RM, Westerhof W, Das PK. Presence of T cells and macrophages in inflammatory vitiligo skin parallels melanocyte disappearance. *The American Journal of Pathology*. 1996;**148**:1219-1228

[21] Grimes PE, Morris R, Avaniss-Aghajani E, Soriano T, Meraz M, Metzger A. Topical tacrolimus therapy for vitiligo: Therapeutic responses and skin messenger RNA expression of proinflammatory cytokines. *Journal of the American Academy of Dermatology*. 2004;**51**:52-61

[22] Taher ZA, Lauzon G, Maguiness S, Dytoc MT. Analysis of interleukin-10 levels in lesions of vitiligo following treatment with topical tacrolimus. *The British Journal of Dermatology*. 2009;**161**:654-659

[23] Bassiouny DA, Shaker O. Role of interleukin-17 in the pathogenesis of vitiligo. *Clinical and Experimental Dermatology*. 2011;**36**:292-297

[24] Ines D, Sonia B, Riadh BM, Amel el G, Slaheddine M, Hamida T, et al. A comparative study of oxidant-antioxidant status in stable and active vitiligo patients. *Archives of Dermatological Research*. 2006;**298**(4):147-152

[25] Dammak I, Boudaya S, Ben Abdallah F, Turki H, Attia H, Hentati B. Antioxidant enzymes and lipid peroxidation at the tissue level in patients with stable and active vitiligo.

*International Journal of Dermatology*. 2009;**48**:476-480

[26] Hasse S, Gibbons NC, Rokos H, Marles LK, Schallreuter KU. Perturbed 6-tetrahydrobiopterin recycling via decreased dihydropteridine reductase in vitiligo: More evidence for H<sub>2</sub>O<sub>2</sub> stress. *The Journal of Investigative Dermatology*. 2004;**122**:307-313

[27] Shalbaf M, Gibbons NC, Wood JM, Maitland DJ, Rokos H, Elwary SM, et al. Presence of epidermal allantoin further supports oxidative stress in vitiligo. *Experimental Dermatology*. 2008;**17**:761-770

[28] Bagherani N, Yaghoobi R, Omidian M. Hypothesis: Zinc can be effective in treatment of vitiligo. *Indian Journal of Dermatology*. 2011;**56**:480-484

[29] Yaghoobi R, Omidian M, Bagherani N. Vitiligo: A review of the published work. *The Journal of Dermatology*. 2011;**38**:419-431

[30] Hale LP. Zinc alpha-2-glycoprotein regulates melanin production by normal and malignant melanocytes. *The Journal of Investigative Dermatology*. 2002;**119**:464-470

[31] Akbayir N, Gökdemir G, Mansur T, Sökmen M, Gündüz S, Alkim C, et al. Is there any relationship between hepatitis C virus and vitiligo? *Journal of Clinical Gastroenterology*. 2004;**38**:815-817

[32] Toker SC, Sarycaoglu H, Karadogan SK, Mistik R, Baskan EB, Tunaly b. Is there any relation between vitiligo and cytomegalovirus? *Journal of the European Academy of Dermatology and Venereology*. 2007;**21**:141-142

[33] Niamba P, Traoré A, Taïeb A. Vitiligo in a black patient associated with HIV infection and repigmentation under antiretroviral therapy. *Annales de Dermatologie et de Vénéréologie*. 2007;**134**:272-273

- [34] Lee AY, Youm YH, Kim NH, Yang H, Choi WI. Keratinocytes in the depigmented epidermis of vitiligo are more vulnerable to trauma (suction) than keratinocytes in the normally pigmented epidermis, resulting in their apoptosis. *The British Journal of Dermatology*. 2004;**151**:995-1003
- [35] Bondanza S, Maurelli R, Paterna P, Migliore E, Giacomo FD, Primavera G, et al. Keratinocyte cultures from involved skin in vitiligo patients show an impaired in vitro behaviour. *Pigment Cell Research*. 2007;**20**:288-300
- [36] van den Wijngaard R, Wankowicz-Kalinska A, Le Poole C, Tigges B, Westerhof W, Das P. Local immune response in skin of generalized vitiligo patients. Destruction of melanocytes is associated with the prominent presence of CLA<sup>+</sup> T cells at the perilesional site. *Laboratory Investigation*. 2000;**80**:1299-1309
- [37] Boissy RE, Liu YY, Medrano EE, Nordlund JJ. Structural aberration of the rough endoplasmic reticulum and melanosome compartmentalization in long-term cultures of melanocytes from vitiligo patients. *The Journal of Investigative Dermatology*. 1991;**97**:395-404
- [38] Gauthier Y, Cario Andre M, Taïeb A. A critical appraisal of vitiligo etiologic theories. Is melanocyte loss a melanocytorrhagy? *Pigment Cell Research*. 2003;**16**:322-332
- [39] Halder RM, Chappell JL. Vitiligo update. *Seminars in Cutaneous Medicine and Surgery*. 2009;**28**:86-92
- [40] Haass NK, Herlyn M. Normal human melanocyte homeostasis as a paradigm for understanding melanoma. *The Journal of Investigative Dermatology. Symposium Proceedings*. 2005;**10**:153-163
- [41] Lee AY, Kim NH, Choi WI, Youm YH. Less keratinocyte-derived factors related to more keratinocyte apoptosis in depigmented than normally pigmented suction blistered epidermis may cause passive melanocyte death in vitiligo. *The Journal of Investigative Dermatology*. 2005;**124**:976-983
- [42] Le Poole IC, Das PK. Microscopic changes in vitiligo. *Clinics in Dermatology*. 1997;**15**:863-873
- [43] Le Poole IC, van den Wijngaard RM, Westerhof W, Dutrieux RP, Das PK. Presence or absence of melanocytes in vitiligo lesions: An immunohistochemical investigation. *The Journal of Investigative Dermatology*. 1993;**100**:816-822
- [44] Kim YC, Kim YJ, Kang HY, Sohn S, Lee ES. Histopathologic features in vitiligo. *The American Journal of Dermatopathology*. 2008;**30**:112-116
- [45] Alikhan A, Felsten LM, Daly M, Petronic-Rosic V. Vitiligo: A comprehensive overview Part I. Introduction, epidemiology, quality of life, diagnosis, differential diagnosis, associations, histopathology, etiology, and work-up. *Journal of the American Academy of Dermatology*. 2011;**65**:473-491
- [46] Wańkowicz-Kalińska A, van den Wijngaard RM, Tigges BJ, Westerhof W, Ogg GS, Cerundolo V, et al. Immunopolarization of CD4<sup>+</sup> and CD8<sup>+</sup> T cells to Type-1-like is associated with melanocyte loss in human vitiligo. *Laboratory Investigation*. 2003;**83**:683-695
- [47] Boissy RE, Dell'Anna ML, Picardo M. On the pathophysiology of vitiligo: Possible treatment options. *Indian Journal of Dermatology, Venereology and Leprology*. 2012;**78**:24-29

[48] van den Boorn JG,  
Konijnenberg D, Dellemijn TA, van  
der Veen JP, Bos JD, Melief CJ, et al.  
Autoimmune destruction of skin  
melanocytes by perilesional T cells  
from vitiligo patients. *The Journal*  
*of Investigative Dermatology*.  
2009;**129**:2220-2232

[49] Yadav AK, Singh P, Khunger N.  
Clinicopathologic analysis of stable  
and unstable vitiligo: A study of  
66 cases. *The American Journal of*  
*Dermatopathology*. 2016;**38**(8):608-613