

We are IntechOpen, the world's leading publisher of Open Access books Built by scientists, for scientists

6,900

Open access books available

186,000

International authors and editors

200M

Downloads

Our authors are among the

154

Countries delivered to

TOP 1%

most cited scientists

12.2%

Contributors from top 500 universities



WEB OF SCIENCE™

Selection of our books indexed in the Book Citation Index
in Web of Science™ Core Collection (BKCI)

Interested in publishing with us?
Contact book.department@intechopen.com

Numbers displayed above are based on latest data collected.
For more information visit www.intechopen.com



Extracorporeal Shock Wave Therapy in Chronic Wound Care

Simona Maria Carmignano

Additional information is available at the end of the chapter

<http://dx.doi.org/10.5772/intechopen.89592>

Abstract

Chronic wounds are wounds, which failed healing and timely reparative process to produce anatomic and functional integrity over a period of 3 months. New physical therapy for chronic wounds is extracorporeal shock wave therapy (ESWT). ESWT generators can be focused, defocused, and radial. ESWT is non-invasiveness, low-associated complication rates, efficacy for indications refractory to other standards of practice, and cost-effectiveness. ESWT determines mechanotransduction that is possible as most of the cells of the body, thank to surface receptors and other transmission signals. In the specific field of ESWT, different biochemical substances are able to influence the processes of different cell lineages, besides to induce the formation of new small blood vessels. So, ESWT enhanced cell proliferation at the local wound tissue level, stimulated extracellular matrix metabolism, decreased apoptosis, and downregulated oxygen-mediated burst of leukocytes, probably stimulating homing and differentiation of stem cells with high tissue regenerating potential. From numerous experimental and clinical data, it is possible to conclude that ESWT would improve not only the wounds healing process but also the regeneration events.

Keywords: extracorporeal shock wave therapy, wound healing, chronic wound, regenerative medicine

1. Introduction

Chronic wounds are defined as wounds, which failed healing and timely reparative process to produce anatomic and functional integrity over a period of 3 months [1].

All wounds beyond their etiological origin such as venous or arterial insufficiency or diabetes can be potentially chronic. The transition from an acute to a chronic wound injury can occur at any stage of his recovery [2–4].

Clinical treatment includes wound bed preparation with surgical and nonsurgical debridement [5], application of specialized dressings providing the wound with a moist environment [6], and medical or surgical intervention to achieve adequate vascular inflow and outflow and sufficient offloading to avoid pressure necrosis [7]. A relatively new physical therapy application for chronic wounds is represented by extracorporeal shock wave therapy (ESWT) [8]. Other approaches include hyperbaric oxygen therapy (HBOT) [9, 10], vacuum-assisted wound closure [11–13], low level laser therapy [14, 15], and electrical stimulation [16].

2. ESWT and chronic wound healing

Nowadays, in clinical practice, three different types of ESW generators are available, equipped with different types of sources, and they can also be differentiated as: focused, defocused, and radial. Focused ESWT is generated by electromagnetic, electro-hydraulic, and piezoelectric sources [17–20].

Pressure pulses rise rapidly in the range of 10–100 MegaPascal Pressure (MPa) and concentrate the acoustic energy beam with a penetration depth of approximately 12 cm. A metallic half-ellipsoid-shape reflector focused the almost spherical acoustic waves, which has been generated in the first focal point of ellipsoid directly to a second focal pit that is the therapeutic target [21, 22].

ESWT defocused produces an acoustic planar wave, generated by electromagnetic and electrohydraulic devices. These applicators use a parabolic reflector that generates a parallel wave with a diameter size of the reflector in order to apply the shock waves to a larger area [23, 24]. Radial waves (rSW) are a low-to-medium-energy shock wave (less than 0.1 mJ/mm²) generated through the acceleration of a projectile pneumatically propelled inside a barrel in the handpiece of the device. The high kinetic energy is transferred directly to the skin, on which the applicator is directly placed, and then transmitted radially (hence the expression “radial waves”) to the target zone [25], scattering and dampening by the third power of the penetration depth in the tissue while deepening up to 3.5 cm, without focusing the shock wave field in the tissue.

Compared with the conventional focused shock wave—whose focus is centered on the target site instead of on the tip of the applicator and whose wave shows a higher peak and a very short rise in pressure—the radial shock wave differs for the centering of the focus (placed on the tip of the applicator instead of on the target site) and the shape of the waves themselves (showing a lower peak pressure and a very long rise), and the propagation is limited to the most superficial (but larger) areas of the body [26].

3. ESWT and basic science: mechanotransduction and modulation of gene transcription

Therapeutic efficacy of low-energy defocused ESWT on delayed healing or chronic wounds has been demonstrated in experimental studies and clinical trials [27]. Advantages of ESWT,

compared with other therapeutic interventions, include non-invasiveness, associated complication rates, efficacy of indications refractory to other standards of practice, and cost-effectiveness [28].

ESWT determines the mechanotransduction that is a complex process characterized by several steps: (1) transduction of mechanical forces in receptors detected by signals on cells, (2) conversion of mechanical signal into electrical and biochemical messages for obtaining a cellular response, cytoplasmic level, (3) transfer of a signal from the sensor to effectors molecules, in nucleus, and finally (4) biological changes determined by gene activation. It is a biological mechanism that involves numerous cells and organs [29–31]: for example, endothelial cells respond to shear stress stimulation, but also others as tenocytes, bone cells, and fibroblasts.

ESWT induces production of different biochemical substances that are able to influence the processes of different cell lineages, besides to induce the formation of new small blood vessels [32].

In fact, a lot of studies showed how ESWT is effective in stimulating several endogenous growth factors such as epidermal growth factor, insulin-like growth factor 1, vascular endothelial growth factor (VEGF), and (nitric oxide) NO production, inducing angiogenesis and promoting the healing of tendons, muscles, cartilage, bone and skin, fractures, ulcers, and complex lesions [33, 34].

Angiogenesis is one of the basic conditions for supporting healing processes in the different affected tissues. Structural mechanical stress, induced by ESWT changes in cytoskeleton and increase in NOS activity and VEGF-A expression, acts as an angiogenesis process. Furthermore in vitro, it modulates the release of anti-inflammatory cytokine (IL1, IL-6, and IL10) and transforming growth factor 1TGF1-VEGF, that promote the migration of macrophages, fibroblasts, and epithelial cells, enhancing collagen deposition into the damaged area [35–40].

Furthermore, if applied in multiple ESWT treatments, it was possible to obtain active degradation of the fibrous abnormal tissues, thanks to a synergistic modifications in pro- and anti-fibrotic proteins (TGF- β 1 and matrix metalloproteinase 2, respectively), thus underlining a possible role in fibrotic tissue reabsorption/remodeling [41, 42].

ESWT influences the toll-like receptor 3 (TLR3) pathway [43], which plays a fundamental role in pathogen recognition and activation of innate immunity, so ESWT modulates the inflammatory responses related to immunology pathway [44–49].

The most recent and relevant ESWT evidence is the effect on modulation of gene expression, thus increasing the possibility of a regenerative action.

In animal models, ESWT has been shown to produce favorable molecular microenvironment in the wound tissue, suppress early pro-inflammatory cytokines and chemokines, and enhance expression of several wound healing relevant genes [46, 50, 51].

ESWT increases the Platelet-Cell Adhesion Molecule-1 (PECAM-1) production on leukocytes and on endothelial cells, which mediate a physical link between the cell surface and the nuclear envelope, and it is critically involved in the trans-endothelial migration processes at inflammatory sites, endothelial cell migration, and formation of new blood vessels. This may transmit mechanical or biochemical signals that may modulate the genetic expression

of cells [50, 52]. Furthermore, PECAM-1 is not only involved in cell adhesion but also is intimately involved in signaling, for example, by binding and modulating nuclear/cytoplasmatic β catenin localization. At the membrane, β -catenin forms complexes with E-cadherin to generate cell adhesion complexes responsible for maintaining the structural integrity of many epithelial tissues. On the other hand, accumulation of β -catenin in the nucleus, in response to Wnt signaling pathways (a group of signal transduction pathways, made of proteins that pass signals into a cell through cell surface receptors), facilitates complex formation with T cell-specific (TCF) transcription factors. TCF leads to activation of a genetic program influencing a range of cellular processes, as cell growth and cell movement [53, 54] (**Figure 1**).

ESWT indirect effect on modulation of gene transcription has been found to include expression of c-Myc gene, regulation of metalloproteinase matrilysin (the smallest member of metalloproteinase enzymes), modulation of the activating protein-1 (AP-1) transcription complex, particularly cc-Jun and Fra-1 components that are essential for MMP-1 gene expression, urokinase-type plasminogen activator receptor, zonula occludens-1 (ZO-1) protein, and cyclin D1 [55].

In vivo shock wave treatment increases Ras-dependent superoxide, which in turn regulated cytosolic extracellular regulated kinase (ERK) phosphorylation and hypoxia-inducible factor-1 α transactivation, which is considered as the master transcriptional regulator of cellular and developmental response to hypoxia [56].

ESWT treatment upregulates expression of cell nuclear antigen (PCNA), which is important for both DNA synthesis and repair; furthermore, it increases TGF genes (mRNA) [57].

TGF α is predominantly expressed in keratinocytes and has a profound autocrine mitogenic effect on keratinocytes, augments angiogenesis in wound healing, and it is upregulated in keratinocytes after skin injuries; TGF β 1 mRNA shows higher values in ESW-treated fibroblasts, relating to increased expression of VEGF and endothelial NOS (eNOS), also known as constitutive NOS (cNOS), as well as genes encoding collagens types I and III [58, 59].

Shock wave treatment is capable of inducing an increase of activated fibroblasts, CD34-positive fibrocytes, and fXIIIa-positive dendritic cells; this process is thought to lead to the deposition of new collagen, characterized by thinner collagen fascicles and parallel orientation to the dermoepidermal junction. Additionally, ESWT may play a significant role in the increase in CD31-positive vessel density in the dermis allowing an improved tissue metabolism [60]. In animal models, ESWT modulates expression of angiogenesis pathway-specific genes such as those encoding for ELR motif (glutamic acid-leucine-arginine sequence) positive (ELR + -CXC) chemokines, CC-chemokines, and cytokines [51].

In addition, shock wave exposure induces strong expression of stromal cell-derived mRNA factor 1, which influences medium induced chemo-attraction of CD34+ cells, hematopoietic stem cells, and the effect on bone marrow-derived mononuclear cells facilitating cell differentiation to endothelial phenotype [61].

So, ESWT-enhanced cell proliferation at the local wound tissue level stimulated extracellular matrix metabolism, decreased apoptosis, and downregulated oxygen-mediated burst of leukocytes, probably stimulating homing and differentiation of stem cells with high tissue regenerating potential.

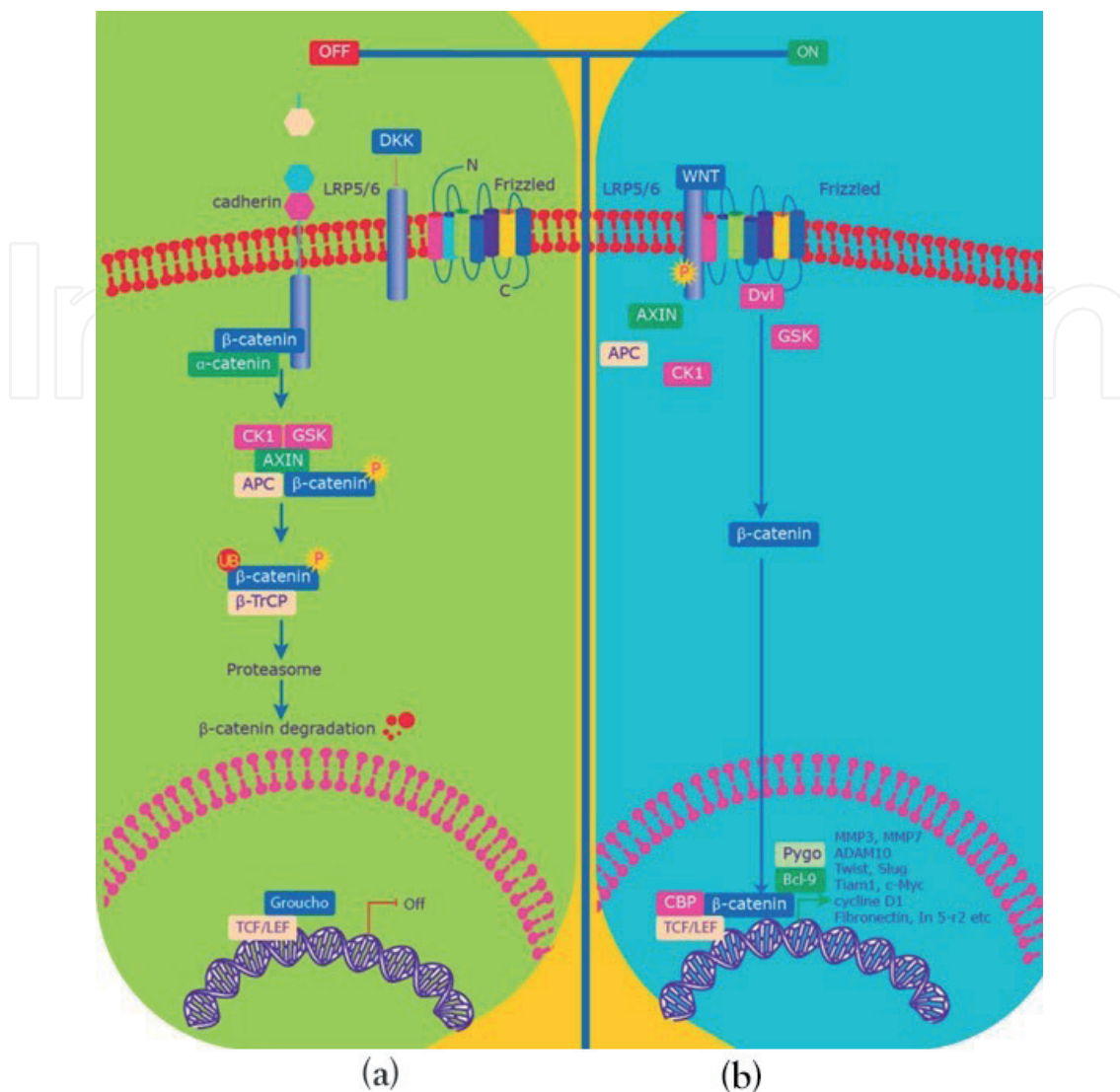


Figure 1. (a) Wnt signaling—“Off” In the absence of Wnt, β -catenin is phosphorylated, so transcriptional process is stopped (b) Wnt signaling—“On” In the presence of Wnt ligands, a signaling cascade is initiated. β -catenin accumulates in the cytoplasm and is free to translocate into the nucleus where it acts as transcriptional coactivator of transcriptional factors of the TCF/LEF family. Modified from: <https://www.sigmaaldrich.com/technical-documents/articles/biology/wnt-b-catenin.html>.

4. ESWT in chronic wound: clinical studies

In the published literature, there are hypothesis-generating experimental data as well as clinical observations that suggest a heretofore unproven systemic effect of ESWT.

Schaden et al. in 2007 [62] demonstrated safety and potential efficacy of electrohydraulic unfocused shock waves applied to acute and chronic wounds (33.3% acute and 66.7% chronic wounds) of various etiologies (post-traumatic, venous, pressure, and arterial wounds). A total of 208 patients were included in the study and treated with the unfocused electrohydraulic device (DermaGold). Each treatment was placed onto wound dressing applied: from 100 to 1000 pulses were applied according to wound size (100 pulses/cm²) initially, weekly, and then biweekly. The study describes the complete reepithelialization of wounds in 75% patients:

significant association was found between complete epithelialization and wound size (wounds $<10\text{ cm}^2$ healed in 81.0 vs. 61.8% for wounds $>10\text{ cm}^2$) as well as between complete healing and wound duration (wounds persisting >1 month showed 57.1% healing rate vs. wounds <1 month that had a healing rate of 83%). With regard to wound etiology, venous stasis ulcers showed the lowest healing rates (36%), whereas all other wound etiologies showed at least a healing rate of 66% (arterial insufficiency ulcer—66.7%, decubital ulcer—71.4%, disturbed healing wounds—75.6%, posttraumatic tissue necrosis—86.6%, and burn wounds—100%).

Application of high energy unfocused shock waves for difficult wounds was confirmed by a work carried out by Saggini et al. [63]. In this study, 30 patients affected by chronic ulcers in the lower limb from more than 3 months that were unresponsive to conservative or advanced dressing treatments or mechanical debridement were included. A group of 10 consecutive patients, randomly recruited, with chronic ulcers in the lower limb treated on the basis of regular conservative dressings have been used as a control group. Electrohydraulic unfocused ESWT treatment consisted of 100 impulses at 0.037 mJ/mm^2 each per cm^2 of the row wound area (Evotron). The focal volume of the hand handled probes was 10–15 mm in diameter, and the total energy applied for each impulse was 3.5 mJ, with a frequency of 4 Hz or 240 impulses/minute. At the end of the study period, 16 ulcers healed completely (50%). Every patient underwent single sessions every 2 weeks, with a minimum of four and a maximum of 10 sessions for a complete treatment.

The wounds were classified on the basis of the location, width (cm), length (cm), row surface area (cm^2), percentage of granulation tissue, percentage of fibrin tissue or necrotic tissue, presence of exudates, bacterial colonization (positive culture swabs or tissue scrapings), and pain.

Presence of exudates was determined as: none, minimal, moderate, and heavy, adapted from the wound bed preparation score developed by Falanga [64]. Complete healing was documented within the first four to six sessions. In all of the wounds, the amount of exudates decreased considerably, and the increasing percentage of granulation tissue compared with the fibrin/necrotic tissue was statistically significant. At the end of the study period, in the non-healed ulcers, a considerable improvement in the wound bed blood supply was documented. Improvement of all these parameters was noted within the first four to six sessions.

Wang et al. [65] included 74 patients with diabetic skin ulcers of the foot for comparing ESWT and hyperbaric oxygen therapy (HBOT). They were randomly divided into two groups (38 subjects in each group). ESWT, electrohydraulic focused, protocol provides two sessions for 6 weeks ($300 + 100\text{ pulses/cm}^2$ at an energy flux density of 0.11 mJ/mm^2). The HBOT was performed five times a week for a total of 20 treatments using a sealed multiplace chamber at a pressure of 2.5 atmospheres for 90 minutes total (25-minute sessions with 5-minute breaks). Post-treatment wound care was the same in both groups. Outcome variables included clinical assessment of the ulcers with photo documentation, blood flow perfusion scan, bacteriological examination, histological study, and immune-histochemical analysis. In ESWT group, results showed a significant increase of eNOS, VEFG, and proliferation cell nuclear antigen (PCNA) and a decrease of terminal deoxynucleotidyl transferase-mediated UTP nick end labeling (TUNEL) with reduction of apoptotic phenomena. It reported significant improvement in local blood perfusion in the participants that had DFU and treated with ESWT (0.61, $P < 0.002$) compared with those treated with HBOT (0.50). Complete ulcer healing

was found in 31% of the ESWT group compared with 22% of the HBOT group. Furthermore, in more than 50% was observed a reduction of wound surface and was observed in 89% of shock wave-treated ulcers compared with 72% of HBOT-treated ulcers. They concluded that ESWT of chronic diabetic foot ulcer is superior to HBOT, and it appears that ESWT results in increased angiogenesis and cellular events consistent with decreased cell apoptosis.

Other scientific literature, Wang et al. [66], confirmed that ESWT appeared to be more effective than HBOT for treatment of chronic wound, in a prospective open-label, randomized, but not blinded study. Patients were randomly divided into two groups: the ESWT, group consisted of 39 patients with total of 44 chronic diabetic foot ulcers, while the HBOT group consisted of 38 patients and 40 foot ulcers. ESWT treatment was carried out with an electrohydraulic-unfocused device, derma PACE device, and the dosage was ulcer size dependent with the numbers of impulses equal to the treatment area in $\text{cm}^2 \times 8$, with a minimum of 500 impulses at energy setting E2 (equivalent to 0.23 mJ/mm^2 energy flux density) at a rate of 4 shocks per second twice per week for a total of six treatments. The HBOT group received hyperbaric was performed with patients in a sealed multi-place chamber at a pressure of 2.5 atmospheres absolute daily for a total of 20 treatments. The assessment, at 3 and 6 weeks, then once every 3 months, was carried out by local blood flow perfusion scan and histopathological examination after biopsy specimens. Clinical assessment of the ulcer status was performed by physical examination including visual observation and photo-documentation.

Clinical results showed completely healed ulcers in 57 and 25% ($P = 0.003$); $\geq 50\%$ improved ulcers in 32 and 15% ($P = 0.071$); unchanged ulcers in 11 and 60% ($P < 0.001$), and none worsened for the ESWT and the HBOT group, respectively. Another interesting observation was that even though prior to study-based treatment levels of oxygenation were comparable, oxygenation levels were significantly higher after shockwave therapy than after HBOT ($P = 0.002$). In histopathological examination, the ESWT group showed considerable increases in cell proliferation, cell concentration, and cell activity and a decrease in cell apoptosis as compared to the HBOT group.

Moretti et al. [67] evaluate the effect of ESWT in 30 patients affected by neuropathic diabetic foot ulcers. One group was treated with standard care and ESWT with an focused electromagnetic device, three sessions (every 72 hours), with 100 pulses per 1 cm^2 of wound delivered at each session at a flux density of 0.03 mJ/mm^2 ; while the control group was treated with only standard care. The wound area and its following reductions were measured with the Rhinoceros program running and the reepithelialization was measured as the time to complete ulcer healing was measured as the number of days from the start of treatment to the date in which each patient achieved complete wound healing. If the healing did not occur within the 20 weeks of the study, the patient was considered to be non-healing. The proportions of ulcers that healed in 20 weeks in the A and B groups were 53.33 and 33.33%, respectively. For the ulcers that healed during the 20-week period, the healing times were 60.8 ± 4.7 days (mean \pm DS) in group A and 82.2 ± 4.7 days (mean \pm DS) in group B patients ($P < 0.001$). A significant difference was observed in the index of the re-epithelization between the two groups, with values of $2.97 \pm 0.34 \text{ mm}^2/\text{die}$ (mean \pm DS) in the ESWT group and $1.30 \pm 0.26 \text{ mm}^2/\text{die}$ (mean \pm DS) in the control group ($P < 0.001$). Both the healing rate and the healing time were increased in the ESWT group, and the differences were statistically significant.

Larking et al. [68] investigated the response to ESWT of pressure ulcers in a randomized, placebo-controlled crossover study. All patients included in the study were patients with disabilities, presenting pressure ulcers for more than 3 months in different anatomical sites. The protocol consisted of a 3-week baseline observation period to confirm stable wound conditions, and subsequently, ulcers were allocated randomly to ESWT or placebo group and followed-up for 4 weeks receiving treatment each week. After this 4-week period and a 2-week washout period, study crossover to the other treatment ensued. Interestingly, regardless of which group they belonged to (initial treatment group or cross-over treatment group), all nine ulcers showed significant improvement (average of three measurements of ulceration was recorded) at 6–8 weeks after the initial shockwave treatment. This phenomenon was discussed as follows that shock waves may first determine debridement of the wounds receiving proper wound bed, which is then conditioned for healing.

Ottomann et al. in 2012 [69] performed a prospective randomized phase II trial of accelerated reepithelialization of superficial second-degree burn wounds using extracorporeal shock wave therapy. A total of 100 patients were included and then randomly assigned in two groups: control group received a standard treatment debridement of devitalized skin (epidermis) and topical antiseptic therapy and the experimental group received the standard treatment and a single application of defocused ESWT (100 impulses/cm at 0.1 mJ/mm) applied once to the study burn, after debridement. Patients receiving shock wave therapy showed significantly reduced mean time to complete (>95%) second-degree burn wound epithelialization (9.6 ± 1.7 vs. 12.5 ± 2.2 days). The study concludes that application of a single defocused shock wave treatment to the superficial second-degree burn wound after debridement/topical antiseptic therapy significantly was able to accelerate healing.

Saggini et al. in 2013 [70] by a randomized, controlled trial, with blind assessment, assessed the efficacy of unfocused shock wave treatment in patients with diabetic ulcers, pressure ulcers, traumatic ulcers, and vascular ulcers, through the analysis of the percentage of wound healing (calculated as the reduction in wound area divided for the initial area percent), the antibacterial effect, through the evaluation of specific buffers and searching for possible occurrence of infection during therapy. A total of 124 patients with ulcers at least from 3 to 24 months were treated with a frequency of 1 session every 7 days for 7 weeks. A total of 62 subjects were included in Group A and treated with ESWT unfocused probe with Dermagold electrohydraulic system; the mean energy applied for each pulse in Group A was equal to 0.10 mJ/mm² per cm² (0.09/0.11 mJ/mm²) with a total energy density equal to 1250 J. A total of 62 subjects were included in Group B but 22 withdrawn, so 40 were treated with ESWT electrohydraulic unfocused device (Evotron); the mean energy applied in Group B was equal to 0.037 mJ/mm² per cm² with a total energy density equal to 462 J. In both Groups A and B were administered 300–600 impulses per session relating to the wound area at a frequency of 4 Hz or 240 pulses per minute. Results showed a reduction of 80% of mean area of wound in Group A: particularly, the 23 diabetic wounds in this group achieved a 85% mean decrease of the row surface area from a mean surface area of 1.45 cm² to a final average surface area of 0.2 cm²; the 10 pressure wounds demonstrated a 68% mean decrease of the row surface area rising from a mean surface area equal to 9.8 cm² to a final surface area of 3.1 cm². The 10 traumatic wounds obtained an 85% decrease of the row surface area rising from a mean surface area of 1 cm²

to a mean surface area of 0.15 cm². Nineteen vascular wounds demonstrated a 76% decrease of the row surface area rising from a mean surface area of 2.75 cm² to a mean surface area of 0.65 cm². At the end of protocol (7 weeks), 44 patients achieved complete wound healing, while the remaining 18 obtained a partial recovery. As for the pain, there was a 79% mean visual analogical scale (VAS) reduction. The mean surface area in Group B, equal to 3.4 cm² at the beginning, decreased by 67%: diabetic wounds in this group achieved a 60% mean decrease of the row surface area rising from a mean surface area of 1.2 cm² to a final average surface area of 0.48 cm²; traumatic wounds obtained an 85% decrease of the row surface area rising from a mean surface area of 1.2 cm² to a mean surface area of 0.18 cm²; pressure wounds demonstrated a 72% mean decrease of the row surface area rising from a mean surface area equal to 8.8 cm² to a final surface area of 2.5 cm²; vascular wounds demonstrated a 61% decrease of the row surface area rising from a mean surface area of 3.5 cm² to a mean surface area of 1.37 cm²; as for wounds in patients with cryoglobulinemia was found a 33% decrease of the row surface area. At the end of therapy, 40% of patients had reached a completed healing, 37.5% a partially healed, and 22.5% unchanged. As for pain, in Group B, there was a 48% mean VAS reduction (2.7 reduction points compared to the initial value) with a final mean value equal to 3 (range 1–6). No wound in Group B developed infection during therapy; such evidence may confirm and correlate to bactericidal effect of this system because of dejection of *Staphylococcus aureus* in culture swabs. Authors concluded that the greater improvement in Group A is linked to the higher total flux density of energy transferred from the probe, as regards the application time, a significant reduction in wound areas was observed after 7 weeks and a peak of increase of the results, in terms of wound size reduction, between the third and the fourth week of treatment, so therefore the time required to obtain the regenerative effects would be at least 7 days between one.

Omar et al. [71] in a single blinded randomized controlled study included 35 patients with chronic diabetic foot ulcer. They assessed the efficacy of ESWT on the healing rate, wound surface area, and wound bed preparation. In experimental group (19 patients/24 ulcers), patients received ESWT with a pneumatic unfocused device, twice a week at a frequency of 100 pulse/cm² and energy flux density of 0.11 mJ/cm²; all patients received standardized wound care consisting of debridement, blood-glucose control agents, and footwear modification for pressure reduction.

Clinical outcome measures focused on wound surface area (WSA), the percentage of reduction in the WSA, rate of healing and wound bed preparation at baseline, after the end of the interventions (W8), and at 20-week follow-up (W20).

Results showed completely healed ulcers in 33.3 and 54% in ESWT-groups and 14.28 and 28.5% in the control group after intervention (W8), and at follow-up (W20), respectively. The average healing time was significantly lower (64.5 ± 8.06 days vs. 81.17 ± 4.35 days, $P < 0.05$) in the ESWT-group compared with the control group. The authors concluded that ESWT-treated ulcers had a significant reduction in wound size and median time required for ulcer healing.

Nossair et al. [72] evaluated the effectiveness of shock wave therapy in enhancing diabetic wound healing. Forty patients with lower limb ulcerations were included in this study and

divided randomly into two groups: one treated with shock wave therapy (pneumatic unfocused device) beside medications and traditional wound care methods (Group A), while the other treated with medical treatment and traditional wound care (Group B). The protocol consists of a course of three sessions (a session every 1 week for 12 weeks), with 500 pulses per 1 cm² of wound delivered at each session at a flux density of 0.1 mJ/mm²; three sessions, one session every week.

The control group performed the essentials of foot ulcer care, namely debridement, adequate pressure relief, and treatment of infection. Assessments were made at baseline and after 12 weeks as reducing wound surface area and epithelialization rate. After 12 weeks, there was significant decrease in the surface area of both group, and they become (1.92 ± 3.28) and (4.65 ± 3.43) for shock wave and control group, respectively. A significant difference was observed in the wound surface area and in the rate of epithelialization between both groups after 12 weeks. The rate of epithelialization for shock wave and control group were ($83.26 \pm \pm 27.43$)% and (48.66 ± 31.68)%, respectively, ($P < 0.001$). The results of this study revealed that there was a significant difference in wound surface area only after 12 weeks (post-treatment) of the treatment between in shock wave group and the control group ($P = 0.0001$).

Another scientific work [73] describes the safety and efficacy of ESWT in patients with non-healing diabetic foot ulcer of various etiologies such as peripheral arterial disease and neuropathy. Five patients received electromagnetic unfocused ESWT in 6–8 weekly sessions, delivered as 500 shocks at wound margin and 1000 shocks distal to the wound (lower leg), spread over the entire muscle area at a flux density of 0.25 mJ/mm², using the Cactor hand piece of the Duolith SD1 device.

Clinical assessment was carried out 2 weeks after the final session of treatment. Wound area was measured using digital photography, pressure sensitivity was evaluated by the monofilament test, and calculation of the ankle brachial index (ABI) was done at each visit.

After 6–8 weekly sessions of ESWT, a significant reduction in ulcer surface area was observed in four patients with a mean post-treatment ulcer size of $6.33 \text{ cm}^2 \pm 5.00$ (mean reduction: $1.21 \pm 0.82 \text{ cm}^2$, $P = 0.03$).

All patients showed improvement in the ABI and monofilament test after treatment (mean ABI and monofilament test score of 0.9 ± 0.12 , p value: 0.00 and 4/10 after treatment, respectively). It is interesting that the increase of ABI in all patients after treatment confirms the strong angiogenic effect of ESWT leading to enhanced limb perfusion. The majority of clinical trials investigate the effectiveness of short-term ESWT, instead Wang et al. [74] evaluate the long-term effects of ESWT in chronic foot with 5-year follow-up; they included 38 patients with 40 ulcers in the diabetes mellitus (DM) group and 29 patients with 32 ulcers in the non-diabetes mellitus (non-DM) group. All patients received unfocused ESWT with a derma PACE device, and dosage is ulcer size dependent. The number of pulses was calculated as follows: $\frac{1}{4}$ of the treatment area ($\text{cm}^2 \times 8$); but it had reach to 500 shocks (4Hz-equivalent to 0.11 mJ/mm² energy flow density) twice/week for six treatments.

The follow-up examinations were performed in 1, 3, 6, and 12 months and then once a year. The evaluations included clinical assessment of the ulcer status, including the size, shape, and depth with photo documentation, local blood flow perfusion scan, and the mortality and morbidity including the rates of amputation in 1 and 5 years after ESWT. Tissue viability was evaluated by local blood flow perfusion scan preoperatively and at 6 weeks, 1 year, and 5 years postoperatively.

After ESWT, the blood flow perfusion rates significantly improved in both DM ($P = 0.011$) and non-DM ($P = 0.033$) groups. The improvements of blood flow perfusion rate began at 6 weeks and lasted for up to 1 year after ESWT. The blood perfusion rates significantly decreased in both groups from 1 to 5 years compared with the data before treatment, at 6 weeks ($P = 0.006$) and 1 year ($P < 0.001$). The blood flow perfusion rate of the non-DM group is significantly better than that of the DM group from 1 to 5 years after ESWT ($P = 0.04$).

The clinical outcomes, mortality, and morbidity were compared with a control data of 149 patients with diabetic foot ulcers previously treated by the author. The experimental group shown a better overall clinical outcomes of healed and improved ulcers at 1 year (73 vs. 64.4%) compared with the historical controls, although the differences did not reach statistical significance ($P = 0.338$). The mortality rate was 9.4% in the historical controls and 0% at 1 year ($P = 0.044$) and 24% at 5 years ($P = 0.017$) in the experimental ESWT patients. The historical controls showed significantly higher amputation rates compared with the ESWT group at 1 year ($P < 0.001$) and 5 years ($P < 0.001$) and more operations other than amputation than ESWT group the at 1 year ($P = 0.003$) and at 5 years ($P = 0.010$), respectively. At the conclusion of this study, Wang et al. concluded that ESWT appears effective in the treatment of chronic diabetic and non-diabetic foot ulcers. However, the effects of ESWT significantly decreased from 1 to 5 years after treatment.

5. Discussion

The importance to describe current perspectives of management of soft tissue wounds is linked to the serious medical and social problem for which it stands, and the purpose of this narrative review is to evaluate evidence of effectiveness of ESWT on chronic wound and indicate an application guideline in relation to our experience [75, 76]. The primary goal in the treatment of soft tissue wounds is to produce beneficial stimuli in the tissue, which stimulate and support tissue repair and regeneration.

Modern wound bed preparation strategies are to applied immediate [77–79] and after the rational use of advanced wound care therapies when wounds do not respond sufficiently to good standard care after 4 weeks or sooner as circumstances dictate: negative pressure wound therapy, HBOT, biophysical electrical stimulation, diathermy, pulsed electromagnetic fields, pulsed radiofrequency energy, and low-frequency non-contact ultrasound—MIST and ESWT [80]. The described ESWT studies revealed a lack of uniformity classification of ulcers (etiology, grade, and size) and a variety of types and parameters

of treatment and the duration of ulcers varied across identified studies (1–24 months) or the initial ulcer size (1 cm² up to 10 cm²); therefore, it is appropriated to group them based on measuring the therapeutic effect of ESWT. In this chapter review, the relevant clinical outcomes were focused on wound healing and reepithelialization time. However, the methods used to define them are varied. The evidences have shown clinical efficacy as regards speed of healing highlighting the size of the wound. Furthermore, ESWT is a safe mode and associated with a low rate of complications during its application both short-term and medium-term periods of follow-up. All included studies provided sufficient details to allow the repetition of the intervention protocol. However, we can highlight differences in frequency, dosage, duration and the generator type, the duration of the protocols, and the device used. This heterogeneity of parameters can make difficult comparisons between studies with aim to standardize the application of ESWT in chronic ulcers. In many cited studies, the number of pulses in a single ESWT session ranged from 10 to 500 pulses/cm² (206.4 ± 172.3 pulses/cm²), but the most frequent value was 100 pulses/cm² of wound area. Not all studies did describe frequency parameters which instead can be considered important in order to evaluate the application and effects of ESWT. According to the review of clinical research studies, in the case of chronic wounds, ESWT sessions were typically once or twice per week, as well as once every 2 weeks. The total number of treatment sessions ranged between three and six. The average time of a single ESWT session was 1–3 minutes, depending on the size of the wound.

So, ESWT represents a new application of translational medicine and a current border not only as an advanced physical therapy but also as a regenerative application [81]. This regenerative potential is linked to mechanotransduction, thanks to cytoplasmic cellular and extracellular cascade [82], that generates a gene expression modulation. This complex biological phenomenon determines a change in the key factors of regenerative skin process.

In fact, ESWT can reduce expression of several metalloproteinases and interleukins (MMPs and ILs) [83]; it stimulates proliferation and collagen synthesis, mediated by early up-regulation of proliferating cell nuclear antigen (PCNA) and TGF-beta1 gene expression, endogenous NO release and synthesis and TGFbeta1 protein and then collagen synthesis [84]; in vitro it improves functional activities of ruptured tendon-derived tenocytes (proliferation and migration), which could probably contribute to tendon healing in vivo [85]; it can enhance osteogenic differentiation of mesenchymal stem cells, through superoxide-mediated signal transduction [86]; furthermore, the ESWT facilitates the regeneration process of the soft tissues by early expression of angiogenesis-related growth factors [87–90].

In addition, shock wave exposure induces strong expression of stromal cell-derived mRNA factor 1, which influences medium induced chemoattraction of CD34+ cells and hematopoietic stem cells, and the effect on bone marrow-derived mononuclear cells facilitates cell differentiation to endothelial phenotype. These molecular effects and gene expression are reflected in positive clinic results [8]. All this reduces the health and social costs.

Considering all this evidences, I could recommend for treatment chronic ulcers unfocused ESWT with fractionated energy in 2 weekly steps, because in this way, there is greater regenerative activation.

6. Conclusion

From these experimental and clinical data, it is possible to conclude that ESWT would improve not only the wound healing process, but also the regeneration events. The knowledge relative to the mechanotransduction has had over the years a consolidation process, instead the modulation of gene transcription related to the regenerative processes on the treatment of chronic ulcers can be considered as a new border for other clinical studies and clinical trials.

Disclosure

The author reports no conflicts of interest in this work.

Author details

Simona Maria Carmignano^{1,2*}

*Address all correspondence to: simona.carmignano@gmail.com

1 Department of Medicine, Surgery and Dentistry "Salernitan Medical School", University of Salerno, Baronissi, Italy

2 C.T.R. Rehabilitation Therapeutic Center, Basilicata, Italy

References

- [1] Mustoe TA, O'Shaughnessy K, Kloeters O. Chronic wound pathogenesis and current treatment strategies: A unifying hypothesis. *Plastic and Reconstructive Surgery*. 2006;**117**:35-41
- [2] Demidova-Rice TN, Hamblin MR, Herman IM. Acute and impaired wound healing: Pathophysiology and current methods for drug delivery, part 1: Normal and chronic wounds: Biology, causes, and approaches to care. *Advances in Skin & Wound Care*. 2012;**25**(7):304-314
- [3] Robson MC, Barbul A. Guidelines for the best care of chronic wounds. *Wound Repair and Regeneration*. 2006;**14**(6):647-648
- [4] Hunt TK, Hopf H, Hussain Z. Physiology of wound healing. *Advances in Skin & Wound Care*. 2000;**13**:6-11
- [5] Schultz G, Mazingo D, Romanelli M, Claxton K. Wound healing and TIME; new concepts and scientific applications. *Wound Repair and Regeneration*. 2005;**13**(Suppl 4):S1-S11
- [6] Falanga V. Wound bed preparation and the role of enzymes: A case for multiple actions of therapeutic agents. *Wounds*. 2000;**4**(Suppl 2):S47-S57

- [7] Ennis WJ, Menses P. Wound healing at the local level: The stunned wound. *Ostomy/Wound Management*. 2000;**46**:39S-348S
- [8] Dymarek R, Halski T, Ptazkowski K, Slupska L, Rosinczuk J, Taradaj J. Extracorporeal shock wave therapy as an adjunct wound treatment: A systematic review of the literature. *Ostomy/Wound Management*. 2014;**60**(Suppl 7):S26-S39
- [9] Mathieu D. Hyperbaric oxygen therapy in the management of non-healing wounds. In: Bakker DJ, Cramer FS, editors. *Hyperbaric Surgery*. Flagstaff, AZ: Best Publishing Company; 2002. pp. 317-339
- [10] Al-Waili NS, Butler GJ. Effects of hyperbaric oxygen on in-inflammatory response to wound and trauma: Possible mechanism of action. *Scientific World Journal*. 2006;**6**:425-441
- [11] Morykwas MJ, Argenta LC, Shelton-Brown EI, McGuirt W. Vacuum-assisted closure: A new method for wound control and treatment: Animal studies and basic foundation. *Annals of Plastic Surgery*. 1997;**38**:553-562
- [12] Moisidis E, Heath T, Boorer C, Ho K, Deva AK. A prospective, blinded, randomized, controlled clinical trial of topical negative pressure use in skin grafting. *Plastic and Reconstructive Surgery*. 2004;**114**:917-922
- [13] Ubbink DT, Westerbos SJ, Evans D, Land L, Vermeulen H. Topical negative pressure for treating chronic wounds. *Cochrane Database of Systematic Reviews*. 2008;**3**:1-34
- [14] Yu W, Naim JO, Lanzafame RJ. The effects of photo-irradiation on the secretion of TGF and PDGF from fibroblasts in vitro. *Lasers in Surgery and Medicine*. 1994;**6**(Suppl):8
- [15] McLoda TA, Seegmiller JG, Baxter GD. Low-level laser therapy facilitates superficial wound healing in humans: A triple-blind, sham-controlled study. *Journal of Athletic Training*. 2004;**39**(Suppl 3):S223-S229
- [16] Kloth LC. Electrical stimulation for wound healing: A review of evidence from in vitro studies, animal experiments, and clinical trials. *The International Journal of Lower Extremity Wounds*. 2005;**4**:23-44
- [17] Notarnicola A, Moretti B. The biological effects of extracorporeal shock wave therapy (ESWT) on tendon tissue. *Muscle, Ligaments and Tendons Journal*. 2012;**2**(Suppl 1):S 33-S 57
- [18] Wess O, Ueberle F, Dührssen RN, et al. Working group technical developments—Consensus report. In: Chaussy C, Eisenberger F, Jocham D, Wilbert D, editors. *High Energy Shock Waves in Medicine*. Stuttgart: Thieme; 1997. pp. 59-71
- [19] Rompe JD, Kirkpatrick CJ, Küllmer K, Schwitalle M, Krischek O. Dose-related effects of shock waves on rabbit tendo Achillis. A sonographic and histological study. *Journal of Bone and Joint Surgery. British Volume*. 1998;**80**(suppl 3):S546-S552
- [20] Gerdesmeyer L, Henne M, Göbel M, Diehl P. Physical principles and generation of shockwaves. In: Towson, editor. *Extracorporeal Shock Wave Therapy: Clinical Results, Technologies, Basics*. Brooklandville, Baltimore County, Maryland, United States: Data Trace Publishing Company; 2006. pp. 11-20

- [21] Shrivastava SK, Kailash. Shock wave treatment in medicine. *Journal of Biosciences*. 2005;**30**(Suppl 2):S269-S275
- [22] Speed C. A systematic review of shockwave therapies in soft tissue conditions: Focusing on the evidence. *British Journal of Sports Medicine*. 2014;**48**(21):1538-1542
- [23] Goertz O, Lauer H, Hirsch T, Ring A, Lehnhardt M, Langer S, et al. Extracorporeal shock waves improve angiogenesis after full thickness burn. *Burns*. 2012;**38**(Suppl 7):S1010-S1018
- [24] Saggini R, Di Stefano A, Saggini A, Bellomo RG. Clinical application of shock wave therapy in musculoskeletal disorders: PART I. *Journal of Biological Regulators and Homeostatic Agents*. 2015;**29**(3):533-545
- [25] Gollwitzer H, Gloeck T, Roessner M, Langer R, Horn C, Gerdesmeyer L, et al. Radial extracorporeal shock wave therapy (rESWT) induces new bone formation in vivo: Results of an animal study in rabbits. *Ultrasound in Medicine & Biology*. 2013;**39**(1):126-133
- [26] Marks W, Jackiewicz A, Witkowski Z, Kot J, Deja W, Lasek J. Extracorporeal shock-wave therapy (ESWT) with a new-generation pneumatic device in the treatment of heel pain. A double blind randomised controlled trial. *Acta Orthopaedica Belgica*. 2008;**74**:98-101
- [27] Thiel M. Application of shock waves in medicine. *Clinical Orthopaedics and Related Research*. 2001;**387**:18-21
- [28] Mittermayr R, Antonic V, Hartinger J, et al. Extracorporeal shock wave therapy (ESWT) for wound healing: Technology, mechanisms, and clinical efficacy. *Wound Repair and Regeneration*. 2012;**20**(4):456-465
- [29] Hwang Y, Barakat AI. Dynamics of mechanical signal transmission through prestressed stress fibers. *PLoS One*. 2012;**7**(Suppl 4):e35343
- [30] Maniotis AJ, Chen CS, Ingber DE. Demonstration of mechanical connection between integrins, cytoskeletal filaments, and nucleoplasm that stabilize nuclear structure. *Proceedings of the National Academy of Sciences*. 1998;**94**:849-854
- [31] Na S, Collin O, Chowdhury F, et al. Rapid signal transduction in living cells is a unique feature of mechanotransduction. *Proceedings of the National Academy of Sciences*. 2008;**105**:6626-6631
- [32] d'Agostino MC, Craig K, Tibalt E, Respizzi S. Review shock wave as biological therapeutic tool: From mechanical stimulation to recovery and healing, through mechanotransduction. *International Journal of Surgery*. 2015;**24**:147-153
- [33] Eming SA, Martin P, Tomic-Canic M. Wound repair and regeneration: Mechanisms, signaling, and translation. *Science Translational Medicine*. 2014;**6**(265):265sr6
- [34] Tonnesen MG, Feng X, Clark RA. Angiogenesis in wound healing. *The Journal of Investigative Dermatology. Symposium Proceedings*. 2000;**5**(1):40-46

- [35] Huang C, Holfeld J, Schaden W, Orgill D, Ogawa R. Mechanotherapy: Revisiting physical therapy and recruiting mechanobiology for a new era in medicine. *Trends in Molecular Medicine*. 2013;**19**(9):555-564
- [36] Tara S, Miyamoto M, Takagi G, et al. Low-energy extracorporeal shock wave therapy improves microcirculation blood flow of ischemic limbs in patients with peripheral arterial disease: Pilot study. *Journal of Nippon Medical School*. 2014;**81**(1):19-27
- [37] Tepeköylü C, Wang FS, Kozaryn R, et al. Shock wave treatment induces angiogenesis and mobilizes endogenous CD31/CD34-positive endothelial cells in a hindlimb ischemia model: Implications for angiogenesis and vasculogenesis. *The Journal of Thoracic and Cardiovascular Surgery*. 2013;**146**(Suppl 4):S971-S9S8
- [38] Ciampa AR, de Prati AC, Amelio E, et al. Nitric oxide mediates anti-inflammatory action of extracorporeal shock waves. *FEBS Letters*. 2005;**579**(30):6839-6845
- [39] Gotte G, Amelio E, Russo S, Marlinghaus E, Musci G, Suzuki H. Short-time non-enzymatic nitric oxide synthesis from L-arginine and hydrogen peroxide induced by shock waves treatment. *FEBS Letters*. 2002;**520**(Suppl 1-3):S153-S155
- [40] Davis TA, Stojadinovic A, Anam K, et al. Extracorporeal shock wave therapy suppresses the early proinflammatory immune response to a severe cutaneous burn injury. *International Wound Journal*. 2009;**6**(1):11-21
- [41] Fischer S, Mueller W, Schulte M, et al. Multiple extracorporeal shock wave therapy degrades capsular fibrosis after insertion of silicone implants. *Ultrasound in Medicine & Biology*. 2015;**41**(3):781-789
- [42] Heine N, Prantl L, Eisenmann-Klein M. Extracorporeal shock wave treatment of capsular fibrosis after mammary augmentation—Preliminary results. *Journal of Cosmetic and Laser Therapy*. 2013;**15**(6):330-333
- [43] Holfeld J, Tepeköylü C, Kozaryn R, et al. Shockwave therapy differentially stimulates endothelial cells: Implications on the control of inflammation via toll-like receptor 3. *Inflammation*. 2014;**37**(Suppl 1):S65-S70
- [44] Tepeköylü C, Lobenwein D, Blunder S, et al. Alteration of inflammatory response by shock wave therapy leads to reduced calcification of decellularized aortic xenografts in mice. *European Journal of Cardio-Thoracic Surgery*. 2015;**47**(Suppl 3):e80-e90
- [45] Mariotto S, de Prati AC, Cavalieri E, Amelio E, Marlinghaus E, Suzuki H. Extracorporeal shock wave therapy in inflammatory diseases: Molecular mechanism that triggers anti-inflammatory action. *Current Medicinal Chemistry*. 2009;**16**(19):2366-2372
- [46] Kuo YR, Wang CT, Wang FS, Yang KD, Chiang YC, Wang CJ. Extracorporeal shock wave treatment modulates skin fibroblast recruitment and leukocyte infiltration for enhancing extended skin-flap survival. *Wound Repair and Regeneration*. 2009;**17**(1):80-87
- [47] Shao PL, Chiu CC, Yuen CM, et al. Shock wave therapy effectively attenuates inflammation in rat carotid artery following endothelial denudation by balloon catheter. *Cardiology*. 2010;**115**(2):130-144

- [48] Sukubo NG, Tibalt E, Respizzi S, Locati M, D'Agostino MC. Effect of shock waves on macrophages: A possible role in tissue regeneration and remodeling. *International Journal of Surgery*. 2015;**24**(Pt B):124-130
- [49] Vulpiani MC, Vetrano M, Savoia V, Di Pangrazio E, Trischitta D, Ferretti A. Jumper's knee treatment with extracorporeal shock wave therapy: A long-term follow-up observational study. *The Journal of Sports Medicine and Physical Fitness*. 2007;**47**(3):323-328
- [50] Zins SR, Amare MF, Tadaki DK, Elster EA, Davis TA. Comparative analysis of angiogenic gene expression in normal and impaired wound healing in diabetic mice: Effects of extracorporeal shock wave therapy. *Angiogenesis*. 2010;**13**(4):293-304
- [51] Stojadinovic A, Elster EA, Anam K, et al. Angiogenic response to extracorporeal shock wave treatment in murine skin isografts. *Angiogenesis*. 2008;**11**(4):369-380
- [52] DeLisser HM, Christofidou-Solomidou M, Strieter RM, et al. Involvement of endothelial PECAM-1/ CD31 in angiogenesis. *The American Journal of Pathology*. 1997;**151**:671-677
- [53] Fujiwara K. Platelet endothelial cell adhesion molecule-1 and mechanotransduction in vascular endothelial cells. *Journal of Internal Medicine*. 2006;**259**:373-380
- [54] Komiya Y, Habas R. Wnt signal transduction pathways. *Organogenesis*. 2008;**4**(Suppl 2):S68-S75
- [55] Ilan N, Cheung L, Pinter E, Madri JA. Platelet-endothelial cell adhesion molecule-1 (CD31), a scaffolding molecule for selected catenin family members whose binding is mediated by different tyrosine and serine/threonine phosphorylation. *The Journal of Biological Chemistry*. 2000;**275**:21435-21443
- [56] Wang FS, Wang CJ, Chen YJ, et al. Ras induction of superoxide activates ERK-dependent angiogenic transcription factor HIF-1 α and VEGF-A expression in shock wave-stimulated osteoblasts. *The Journal of Biological Chemistry*. 2004;**279**:10331-10337
- [57] Cunji G, Weiyong S, Melpo CS, et al. PECAM-1 functions as a specific and potent inhibitor of mitochondrial-dependent apoptosis. *Blood*. 2003;**102**:169-179
- [58] Gauglitz GG, Siegfried Z, Spiegel F, et al. Functional characterization of cultured keratinocytes after acute cutaneous burn injury. *PLoS One*. 2012;**7**(2):e29942
- [59] Berta L, Fazzari A, Ficco AM, Enrica PM, Catalano MG, Frairia R. Extracorporeal shock waves enhance normal fibroblast proliferation in vitro and activate mRNA expression for TGF- β 1 and for collagen types I and III. *Acta Orthopaedica*. 2009;**80**(5):612-617
- [60] Saggini R, Saggini A, Spagnoli AM, et al. Extracorporeal shock wave therapy: An emerging treatment modality for retracting scars of the hands. *Ultrasound in Medicine & Biology*. 2016;**42**(Suppl 1):S185-S195
- [61] Aicher A, Heeschen C, Sasaki K, Urbich C, Zeiher AM, Dimmeler S. Low-energy shock wave for enhancing recruitment of endothelial progenitor cells: A new modality to increase efficacy of cell therapy in chronic hind limb ischemia. *Circulation*. 2006;**114**:2823-2830

- [62] Schaden W, Thiele R, Kolpl C, et al. Shock wave therapy for acute and chronic soft tissue wounds. A feasibility study. *The Journal of Surgical Research*. 2007;**143**:1-12
- [63] Saggini R, Figus A, Troccola A, Cocco V, Saggini A, Scuderi N. Extracorporeal shock wave therapy for management of chronic ulcers in the lower extremities. *Ultrasound in Medicine & Biology*. 2008;**34**(8):1261-1271
- [64] Falanga V, Saap LJ, Ozonoff A. Wound bed score and its correlation with healing of chronic wounds. *Dermatologic Therapy*. 2006;**19**:383-390
- [65] Wang CJ, Kuo YR, Wu RW, et al. Extracorporeal shockwave treatment for chronic diabetic foot ulcers. *The Journal of Surgical Research*. 2009;**152**(1):96-103
- [66] Wang CJ, Wu RW, Yang YJ. Treatment of diabetic foot ulcers: A comparative study of extracorporeal shockwave therapy and hyperbaric oxygen therapy. *Diabetes Research and Clinical Practice*. 2011;**92**(Suppl 2):S187-S193
- [67] Moretti B, Notarnicola A, Maggio G, et al. The management of neuropathic ulcers of the foot in diabetes by shock wave therapy. The management of neuropathic ulcers of the foot in diabetes by shock wave therapy. *BMC Musculoskeletal Disorders*. 2009;**10**:54-62
- [68] Larking AM, Duport S, Clinton M, Hardy M, Andrews K. Randomized control of extracorporeal shock wave therapy versus placebo for chronic pressure ulceration. *Clinical Rehabilitation*. 2010;**24**:222-229
- [69] Ottomann C, Stojadinovic A, Lavin PT, et al. Prospective randomized phase II trial of accelerated reepithelialization of superficial second-degree burn wounds using extracorporeal shock wave therapy. *Annals of Surgery*. 2012;**255**(Suppl 1):S23-SS9
- [70] Saggini R, Fioramonti P, Bellomo RG, et al. Chronic ulcers: Treatment with unfocused extracorporeal shock waves European. *Journal of Inflammation*. 2013;**11**(2):99-509
- [71] Omar MT, Alghadir A, Al-Wahhabi KK, Al-Askar AB. Efficacy of shock wave therapy on Chronic diabetic foot ulcer: A single-blinded randomized controlled clinical trial. *Diabetes Research and Clinical Practice*. 2014;**106**(Suppl 3):S 548-SS554
- [72] Nossair AA, Eid MM, Salama AB. Advanced protocol of shock wave therapy for diabetic foot ulcer. *Journal of American Science*. 2013;**9**(4):633-638
- [73] Variji Z, Aghazadeh N, Hasanzadeh H, Flrooz A. Extracorporeal shock wave therapy in the treatment of non-healing diabetic ulcer: A pilot study. *Journal of Clinical & Experimental Dermatology Research*. 2015;**6**(4):289
- [74] Wang CJ, Wu CT, Yang YJ, Liu RT, Kuo YR. Long-term outcomes of extracorporeal shock-wave therapy for chronic foot ulcers. *The Journal of Surgical Research*. 2014;**189**:e366-e372
- [75] Jones KR, Fennie K, Lenihan A. Evidence-based management of chronic wounds. *Advances in Skin & Wound Care*. 2007;**20**(11):591-600
- [76] Ryan S, Perrier L, Sibbald RG. Searching for evidence-based medicine in wound care: An introduction. *Ostomy/Wound Management*. 2003;**49**(11):67-75

- [77] Werdin F, Tennenhaus M, Schaller HE, Rennekampff HO. Evidence-based management strategies for treatment of chronic wounds. *Eplasty*. 2009;**9**:e19
- [78] Stanley A, Osler T. Senescence and the healing rates of venous ulcers. *Journal of Vascular Surgery*. 2001;**33**:1206-1211
- [79] Lobmann R, Ambrosch A, Schultz G, Waldmann K, Schiweck S, Lehnert H. Expression of matrixmetalloproteinases and their inhibitors in the wounds of diabetic and non-diabetic patients. *Diabetologia*. 2002;**45**:1011-1016
- [80] Frykberg RG, Banks J. Challenges in the treatment of chronic wounds. *Advances in Wound Care*. 2015;**4**(Suppl 9):S560-S582
- [81] Ioannidis JP. Materializing research promises: Opportunities, priorities and conflicts in translational medicine. *Journal of Translational Medicine*. 2004;**2**:5-10
- [82] Ingber DE. Cellular mechanotransduction: Putting all the pieces together again. *The FASEB Journal*. 2006;**20**(7):811-827
- [83] Han SH, Lee JW, Guyton GP, Parks BG, Courneya JP, Schon LC. J. Leonard Goldner award 2008. Effect of extracorporeal shock wave therapy on cultured tenocytes. *Foot & Ankle International*. 2009;**30**(Suppl 2):93-98
- [84] Chen YJ, Wang CJ, Yang KD, et al. Extracorporeal shock waves promote healing of collagenase-induced Achilles tendinitis and increase TGF-beta1 and IGF-I expression. *Journal of Orthopaedic Research*. 2004;**22**(Suppl 4):854-861
- [85] Leone L, Vetrano M, Ranieri D, Raffa S, Vulpiani MC, Ferretti A, et al. Extracorporeal shock wave treatment (ESWT) improves in vitro functional activities of ruptured human tendon-derived tenocytes. *PLoS One*. 2012;**7**(Suppl 11):S49-S759
- [86] Wang FS, Yang KD, Chen RF, Wang CJ, Sheen-Chen SM. Extracorporeal shock wave promotes growth and differentiation of bone-marrow stromal cells towards osteoprogenitors associated with induction of TGF-beta1. *The Journal of Bone and Joint Surgery. British Volume*. 2002;**84**(Suppl 3):S457-S461
- [87] Schaden W, Fischer A, Sailer A. Extracorporeal shock wave therapy of nonunion or delayed osseous union. *Clinical Orthopaedics and Related Research*. 2001;**387**:90-94
- [88] Ma HZ, Zeng BF, Li XL. Upregulation of VEGF in subchondral bone of necrotic femoral heads in rabbits with use of extracorporeal shock waves. *Calcified Tissue International*. 2007;**81**(Suppl 2):S 124-SS131
- [89] Wang CJ, Huang HY, Pai CH. Shock wave-enhanced neovascularization at the tendon-bone junction: An experiment in dogs. *The Journal of Foot and Ankle Surgery*. 2002;**41**(Suppl 1):S16-S22
- [90] Wang FS, Wang CJ, Chen YJ, et al. Ras induction of superoxide activates ERK-dependent angiogenic transcription factor HIF-1alpha and VEGF-A expression in shock wave-stimulated osteoblasts. *The Journal of Biological Chemistry*. 2004;**279**(Suppl 11):S10331-S10337

