

We are IntechOpen, the world's leading publisher of Open Access books Built by scientists, for scientists

6,900

Open access books available

186,000

International authors and editors

200M

Downloads

Our authors are among the

154

Countries delivered to

TOP 1%

most cited scientists

12.2%

Contributors from top 500 universities



WEB OF SCIENCE™

Selection of our books indexed in the Book Citation Index
in Web of Science™ Core Collection (BKCI)

Interested in publishing with us?
Contact book.department@intechopen.com

Numbers displayed above are based on latest data collected.
For more information visit www.intechopen.com



A Minimally Invasive Hemostatic Strategy for Cesarean Scar Pregnancy and Cervical Pregnancy

*Satoru Takeda, Jun Takeda, Takashi Yorifuji
and Taro Koshiishi*

Abstract

Cesarean scar pregnancy (CSP) and cervical pregnancy are categorized as non-tubal ectopic pregnancy, because these are associated with a high burden of maternal and fetal morbidity including early uterine rupture, prevalence of placenta previa accrete spectrum, massive hemorrhage, and hysterectomy. Although management methods vary according to the week of gestation, recent reviews and reports support an interventional or a combination of surgical and medical approaches for treatment of unruptured CSP and cervical pregnancy rather than medical approach alone. In cases of massive hemorrhage, pressure hemostasis using balloon tamponade should first be performed. If such hemostasis proves to be ineffective, surgical excision or transcatheter arterial embolization (TAE) should be selected next. TAE reportedly achieves a high hemostasis rate. However, complications such as subsequent endometrial hypoplasia, menstruation disorder, infertility, placenta accreta, and uterine rupture have been reported, even in cases that have undergone successful hemostasis with TAE using an absorbable embolus. Recently, a minimally invasive hemostatic strategy in obstetrics, which aims to preserve uterine function and enhance the safety of subsequent pregnancies, has been developed. Therefore, we should reconsider uterus-preserving hemostatic strategies for critical hemorrhage and management of non-tubal ectopic pregnancy under these circumstances by using safe and minimally invasive treatment modalities.

Keywords: arterial embolization, balloon tamponade, cervical pregnancy, cesarean scar pregnancy, massive hemorrhage, methotrexate

1. Introduction

Cesarean scar pregnancy (CSP) and cervical pregnancy are categorized as non-tubal ectopic pregnancy and may cause massive hemorrhage, uterine rupture, and hysterectomy. In CSP and cervical pregnancy cases, it is possible that the location of the gestational sac (GS) may lead to a misdiagnosis of abortion. Another possibility is a failure to detect CSP until massive hemorrhage occurs following curettage. Therefore, diagnosis and treatment strategies in early pregnancy are

important. Delay in the diagnosis and management may lead to massive hemorrhage, which is difficult to control. This complication can be treated with life-saving hysterectomy or uterine arterial embolization, which requires massive blood transfusion [1]. Management based on the pathophysiology of the implantation site that has a rich blood supply is essential. Although management methods vary according to the week of gestation, typical strategies include surgical treatment, administration of drugs such as methotrexate (MTX), and combinations of these treatments. In addition, hemostatic procedures vary and include balloon tamponade, transcatheter arterial embolization (TAE), and surgical treatments such as curettage, evacuation, wedge resection, and hystero-resectoscopy, for control and prevention of hemorrhage.

In the field of obstetrics, TAE is known to be highly effective in controlling uterine hemorrhage and hematoma. This procedure reportedly achieves a high hemostasis rate, and thus, the frequency of hysterectomy has sharply decreased [2, 3]. However, complications such as subsequent endometrial hypoplasia, menstruation disorder, infertility, pregnancy loss, placenta accreta, and uterine rupture have been reported, even in cases that have undergone successful hemostasis with TAE using an absorbable embolus [4–6]. Recently, a minimally invasive hemostatic strategy in obstetrics, which aims to preserve uterine function and enhance the safety of subsequent pregnancies, has been developed [2, 7]. Therefore, we should reconsider uterus-preserving hemostatic strategies for critical hemorrhage and management of non-tubal ectopic pregnancy under these circumstances by using safe and minimally invasive treatment modalities. We herein discuss how to select the optimal hemostatic strategy and its management based on literatures and our experiences of non-tubal ectopic pregnancy.

2. Pathology and frequency

When the uterus is observed by ultrasonography more than 3 months after cesarean section (by transverse incision in the lower uterine segment), endometrial defect and defect or thinning of the myometrium at the site of the uterine incision are recognized as a triangular echo-free space at a frequency of approximately 50% [8].

Implantation at this site is considered to be the origin of CSP [9]. Delay in the diagnosis and treatment of CSP may cause uterine rupture and massive hemorrhage, resulting in hysterectomy or massive blood transfusion in serious cases. In the case of CSP, the site of villous anchoring is the isthmus of the uterus or the cervical canal where the endometrium and cervical mucosa are thinner than in the uterine body. Therefore, chorionic villi are likely to penetrate into the myometrium, inducing conditions similar to placenta increta and placenta percreta. The clinical picture and course vary according to the site of villous anchoring [1].

It has been reported that the frequency of CSP is 0.04–0.19% among all pregnancies, 0.15% among those with prior cesarean section, and 6.1% among ectopic pregnancies associated with prior cesarean section [10]. Recently, a national cohort study showed that the estimated incidence of CSP was 0.015% in the UK [11]. It is speculated that the incidence of CSP may increase in the future as the rate of cesarean section rises.

3. Diagnosis

Chorionic villi are smaller and penetrate less deeply into the myometrium in the early stages of pregnancy. Therefore, they are considered to be easier

to remove, and it is also believed that the uterus is more likely to be preserved, in early pregnancy. After 9 or 10 weeks of gestation, the placenta invades the myometrium more deeply, and there is abundant blood flow into the placental bed, increasing the risk of massive hemorrhage. The risk of uterine rupture and placental invasion into the bladder is also increased. When accurately diagnosing CSP, it is important to observe the boundary area between the uterine body and the cervix in early pregnancy. The decisive factors in making a diagnosis of CSP are the presence of a gestational sac (GS) in that area and villous adhesion to the anterior wall (Table 1) [1, 8, 12–14]. Transvaginal ultrasonography is useful for identifying the implantation of chorion frondosum in the scar area (Table 2, Figure 1); the reported sensitivity of this modality is 84.6% [14]. The combined use of color Doppler ultrasonography allows clinicians to estimate the viability of gestational tissue [10, 13], providing useful information for selection of the most appropriate

1. Diagnosis using transvaginal ultrasonography and contrast-enhanced magnetic resonance imaging
<ul style="list-style-type: none">• Evaluation of the implantation site• Evaluation of blood flow around the villous tissue invading the scar area (Figures 2 and 3)• Evaluation of thinning of the scar area, presence/absence of continuity of the myometrium, and presence/absence of villous invasion into the bladder
2. Evaluation of the viability of the villi
<ul style="list-style-type: none">• Blood hCG level• Color Doppler ultrasonography
3. Presence/absence of vaginal bleeding

Table 1.
Key points in diagnosing cesarean scar pregnancy.

1. There is no gestational sac in the uterine cavity.
2. In the sagittal view of the uterus, thinning and a wedge-shaped defect of the anterior wall myometrium are detectable in the wound area of the previous cesarean section, and the gestational sac is present in that area.
3. Villi (high echoic area) are observed on the bladder side of the anterior wall of the uterus.
4. Color Doppler ultrasonography shows blood flow in the gestational sac and areas around the scar.

Table 2.
Ultrasonographic findings of cesarean scar pregnancy.

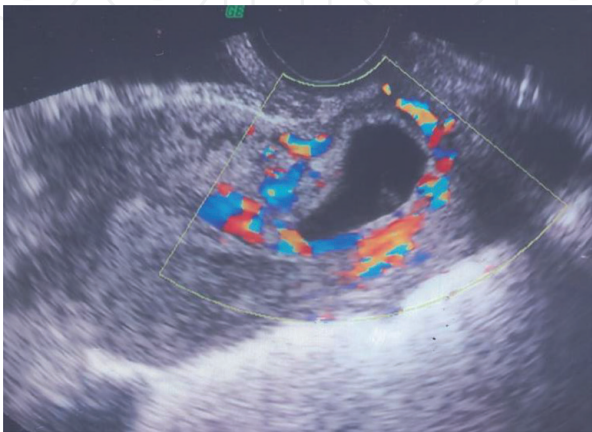


Figure 1.
Findings of transvaginal color Doppler ultrasonography (produced with permission from [1]). The gestational sac accompanied by blood flow in the surrounding tissues is seen near the scar of the previous cesarean section (endogenic type). There is no gestational sac in the uterine cavity.

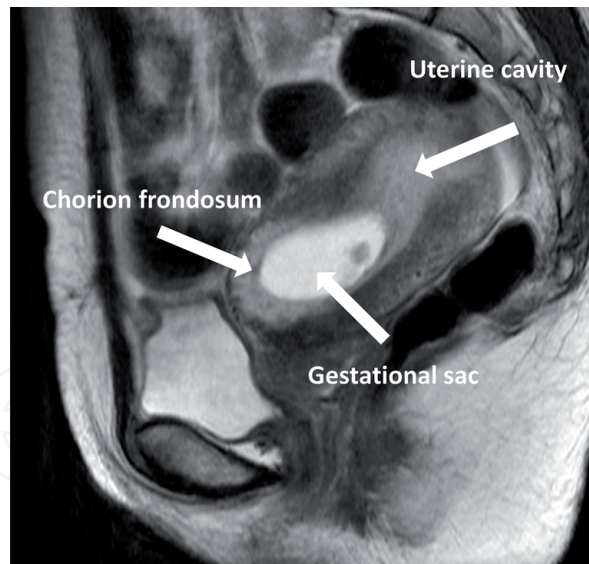


Figure 2.

Findings of T2-weighted magnetic resonance imaging (produced with permission from [1]). This is a case of cesarean scar pregnancy with positive fetal heartbeats at 9 weeks of gestation. The chorion frondosum is bounded on the bladder and extends into the thinned myometrium of the scar.

treatment method. The descending GS in the event of an inevitable abortion and GS in CSP can be distinguished by the presence/absence of blood flow in the villous area [1]. Magnetic resonance imaging (MRI) is also useful for determining the thickness of the myometrium in the wound site and the depth of villous invasion into the bladder, as well as for identifying nutrient vessels (**Figure 2**) [1]. When invasion into the bladder is suspected in the middle stages of pregnancy or thereafter, confirmation by cystoscopy is required.

4. Management of cesarean scar pregnancy (CSP)

Although expectant management of CSP with positive fetal heart activity may still be a choice [11, 15], termination of CSP and cervical pregnancy should be offered to these women and families as one of the therapeutic options. The basic policy for the management of CSP and cervical pregnancy is termination of pregnancy and preservation of the uterus, because these are associated with a high burden of maternal and fetal morbidity including complicated miscarriage, early uterine rupture, prevalence of placenta previa accreta spectrum, massive hemorrhage, hysterectomy, maternal and fetal death, etc. The method of treatment should be selected according to the gestational week, presence/absence of fetal heart beats, the blood hCG level, and abundance of the blood supply adjacent to villi or the gestational sac.

Chemotherapeutic drugs such as methotrexate (MTX) are administered systemically or locally, with or without potassium chloride (KCl), to avoid surgical treatment for CSP [16–19]. However, achieving the desired healing with drug treatment alone can be time-consuming, and hemorrhage or infection may occur concomitantly during the process of treatment. MTX treatment alone as the first-line therapy showed low success rate. In addition, adverse reactions to drugs, such as stomatitis and leucocytopenia, may also occur. Recent reviews and reports support an interventional or a combination of surgical and medical approaches rather than medical approach alone [20–24]. In a national cohort study, surgical management appears to be associated with a high success rate, low complication rate, and short posttreatment follow-up [11].

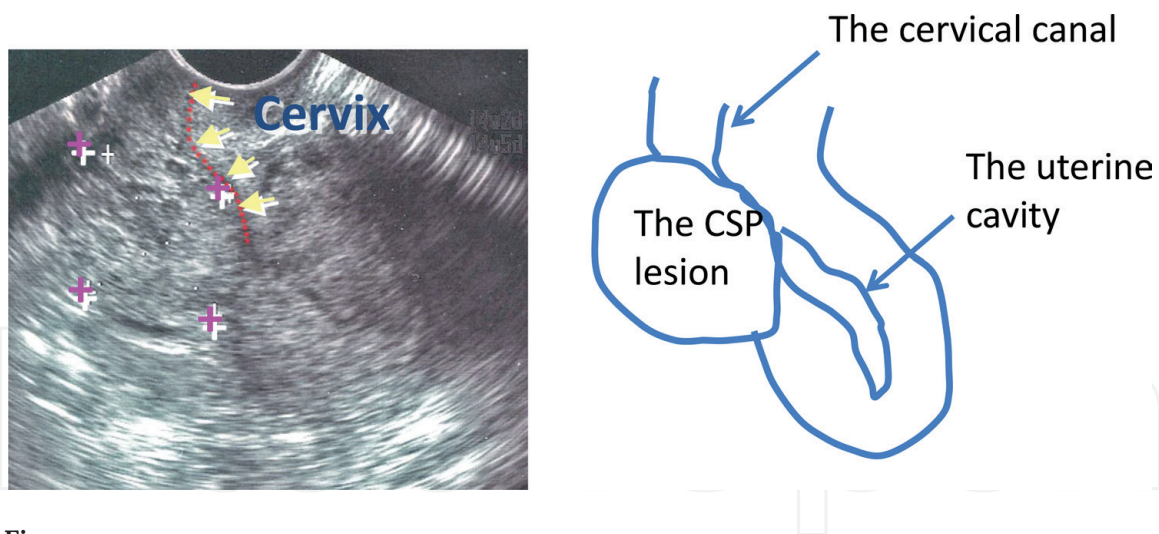


Figure 3. Protrusion of the cesarean scar pregnancy lesion toward the bladder (produced with permission from [1]). The cesarean scar pregnancy lesion is seen protruding toward the outside of the uterus (exogenic type) and forming a mass.

If there is a CSP mass protruded toward outside of the uterus (exogenic type) (**Figure 3**), or a mass attached to defect or thinning (<2 mm) of lower uterine myometrium, the lesion may be removed laparoscopically or by laparotomy and then sutured [25–27], because these types of CSPs could be complicated with uterine rupture and bleeding early in pregnancy. But evidence-based treatment still remains unclear in these cases.

4.1 Surgical approach

4.1.1 Curettage

Curettage or evacuation allows preservation of fertility, can be performed under intravenous or spinal anesthesia, and is minimally invasive [1, 18, 20, 22–25, 27, 28]. Curettage or evacuation may be performed under ultrasound guide after administration of MTX and/or KCl. In addition, it requires only a short period of hospitalization in successful cases. On the other hand, there is the risk of massive hemorrhage or uterine perforation during surgery as well as complications such as uterine rupture and residual tissue. Additional treatment such as balloon compression hemostasis or TAE may be required to deal with bleeding [27].

It has been reported that massive hemorrhage, difficult to control, occurred after curettage in patients who had a low hCG level but had abundant blood flows in the lesion, prompting caution in the management of such patients [1]. This is because neovascularity may persist even when the hCG level is decreased after villi have been devitalized by chemotherapy or dilation and curettage (D&C).

4.1.2 Other surgical procedures

In patients with massive hemorrhage after D&C or with CSP diagnosed after massive hemorrhage, priority is given to hemostasis. Therefore, CSP is removed by transvaginal resection [26] or laparotomic resection [29], and uterine artery ligation [30], cervical suture [31], or TAE is performed. When deep villous invasion is predicted in view of the gestational week, the fertilized ovum should be removed by abdominal resection and suture in cases with wound rupture or dehiscence or subserous protrusion of the lesion.

Along with recent advancements in laparoscopic techniques, cases undergoing less invasive laparoscopic or hysteroscopic resection of the lesion have been

reported [14, 18, 20, 22, 23]. Surgical resection of the lesion and wound repair (wedge resection and repair) is reportedly less likely to require additional treatment and is highly effective for the prevention of recurrence. However, at present, data on the scientific basis of treatment and recurrence of CSP are lacking.

5. Management of cervical pregnancy

Several case reports and literatures support surgical therapy alone or in combination with MTX and/or mifepristone rather than medical therapy alone for treatment of cervical pregnancy as the same as those of CSP [21, 32–35]. Uterine artery embolization for treatment and prevention of hemorrhage during curettage or evacuation is also effective to preserve the uterus [36–39].

To control bleeding during curettage and evacuation, hemostatic techniques such as hemostatic clamps or cervical cerclage to block cervical blood supply and balloon tamponade by Foley catheter or a cervical ripening balloon were reported [40–44]. Recently, more minimally invasive total hysteroscopic treatment for cervical pregnancy and also conservative treatment, using a cervical ripening double-balloon catheter alone, were reported [44, 45]. These seem to be an effective, safe, and minimally invasive and single promising treatment without any medical and surgical treatment. These individual managements have to be validated on a large patient population.

6. Control of bleeding

Massive hemorrhage reportedly occurs in some cases after evacuation of the uterus. D&C has on occasion been performed without an accurate diagnosis. In such cases, balloon tamponade, TAE, and surgical treatment are effective management strategies. If balloon tamponade or TAE is successful in controlling hemorrhage, conservative treatment is also a feasible option. If bleeding is under control, there are several possible treatment options for preservation of the uterus. These options have their own advantages and disadvantages, and selection of the most appropriate treatment varies according to the facility and the time of day. Therefore, the treatments should be tailored to individual patients based on the situation and their wishes regarding fertility.

In cases experiencing massive hemorrhage, pressure hemostasis using balloon tamponade should first be performed. If such hemostasis proves to be ineffective, surgical excision or TAE should be selected next. When performing cesarean scar resection, the right and left uterine arteries are to be clamped.

6.1 Balloon tamponade

This is a hemostatic technique used for overall uterine hemorrhage in the puerperal period including atonic bleeding, incomplete cervical laceration, crush syndrome, and bleeding from the separation surface of placenta previa. Balloon tamponade is also effective and useful for uterine hemorrhage from CSP and cervical pregnancy (**Figure 4**) [46]. In an emergency, insertion and placement of the balloon are technically easy and can be performed expeditiously; this technique is simple and minimally invasive. It is also possible to determine within a short period of time whether hemostasis can be achieved by tamponade alone (tamponade test) [47]. Even when switching to TAE is necessary, the radiology department does not need to be consulted, and the amount of bleeding during preparation for TAE can be decreased. This technique is also useful for temporary hemostasis when a patient must be transferred to an advanced medical facility.

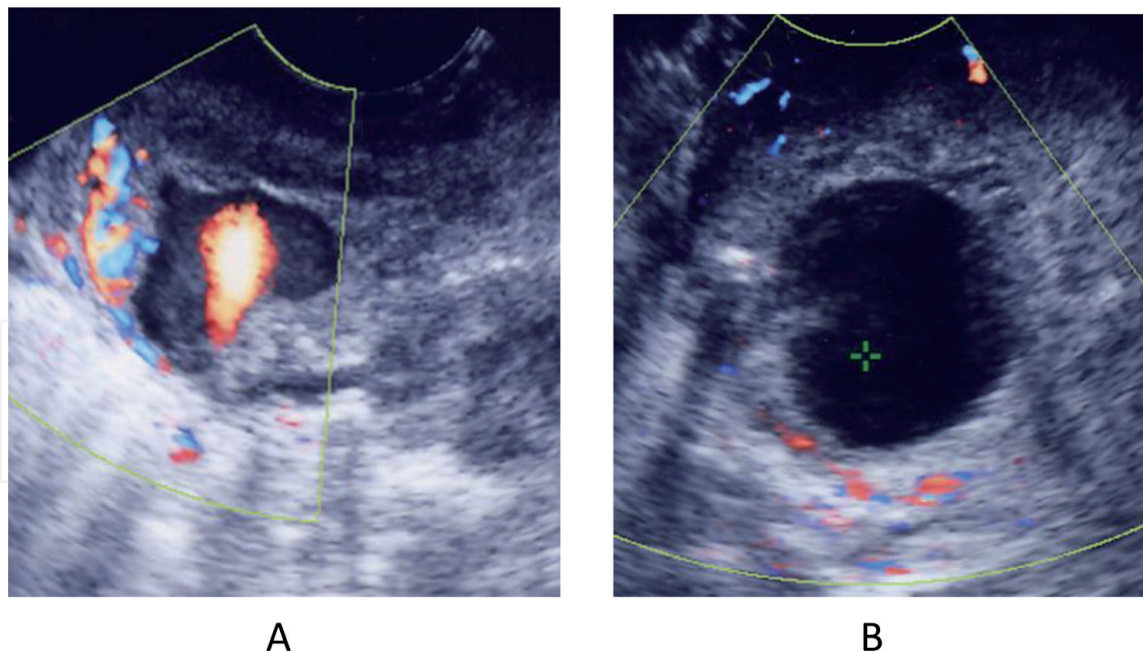


Figure 4.
 Compression hemostasis by balloon tamponade (produced with permission from [1]). (A) In a case with cesarean scar pregnancy, after dilation and curettage, a hematoma (pooling of blood) was observed in the wound area, which prominently showed blood spurting out into its cavity. This case is the same as the one at 9 weeks of gestation in **Figure 2**. (B) The blood flow disappears after inflation with a Minimetro®. A balloon should be inserted from the uterine os guided by ultrasound. Physiological saline (20–30 mL) is then infused into the balloon. The balloon should be gently pulled to confirm that it will not easily prolapse into the vaginal cavity and that bleeding from the uterine os has been halted. Recently, the bleeding point after dilation and curettage could be precisely detected by contrast-enhanced ultrasonography, and a balloon could be inflated at the bleeding point until bleeding stops.

The balloon should be gently pulled to confirm that it would not easily prolapse into the vaginal cavity and that bleeding from the cervical os has been halted. Long gauze should be retained in the vaginal cavity to prevent prolapse of the balloon. A urethral catheter should be placed in the bladder to prevent urinary retention. If there is no massive hemorrhage that would surpass the absorption capacity of the retained gauze, the balloon is to be removed in 24–48 h. The presence of uncontrollable bleeding immediately after the insertion should be deemed a negative result of the tamponade test, and the procedure is then switched to TAE or laparotomic hemostasis without hesitation.

6.2 Transcatheter arterial embolization (TAE)

If bleeding is not controllable by the procedures described above, arterial embolization should be performed without hesitation. TAE is advantageous in that it allows embolization of not only the artery in question but also anastomotic branches while confirming the bleeding point. The rates of hemostasis achievement are reportedly in the range of 89–97% [1, 3].

It is known that, in CSP cases, abnormal growth and anastomosis of inflow vessels occur when the shaggy chorion grows not in the uterine body but in the vicinity of the site of entry into the uterine artery; this causes pathological features different from those associated with the uterine blood flow distribution in normal pregnancy. Therefore, unlike the conventional uterine arterial blood flow, vascular anastomoses are not restricted to those derived from the internal iliac artery. Various anastomoses involving the external iliac artery, lumbar artery, inferior mesenteric artery, sacral artery, superior gluteal artery upstream of the internal iliac artery system, and the external iliac artery system are observed.

Rebleeding may occur due to recanalization or insufficient embolization, and it is difficult to control bleeding when there is abundant blood flow from the external iliac artery region. Therefore, attention should be paid to the patient's general condition after implementation of TAE. In most cases, bleeding can be controlled by TAE. If TAE is ineffective, or if bleeding persists, it is recommended that the aforementioned balloon tamponade be added to the management. Gelatin sponge is usually used as a temporary solid embolic substance lasting for several days to about 2 weeks. In addition, metal coils as permanent solid embolic substances and N-butyl-2-cyanoacrylate as a permanent liquid embolic substance are also available. The incidence rate of adverse reactions is 6–7.8%. Fever is the most frequent untoward effect. Other adverse reactions include endometrial necrosis, adhesion, myometrial necrosis, ovarian insufficiency, bladder necrosis, gluteal muscle necrosis, and pelvic suppuration [1, 3]. Pregnancy after TAE for postpartum hemorrhage may be associated with increased risk of obstetric hemorrhage due to placenta accreta spectrum. Therefore, precautions in perinatal management are required in managing the subsequent pregnancy.

6.3 Surgical hemostasis

If bleeding is uncontrollable employing the procedures described above, laparotomic hemostasis should be selected as the last resort. Since TAE became available, application of this technique has mostly been limited to cases of uterine rupture in the affected area. Hysterectomy, ligation of the uterine artery, or wedge resection and repair of the lesion in the scar should be performed. Prompt selection of the optimal procedure, taking into consideration the amount of bleeding, size of the lesion, whether the patient desires fertility preservation, etc., is necessary. Patients with indications for these procedures often have concomitant obstetric coagulopathy. Therefore, sufficient supplementation of coagulation factors is also essential prior to surgery [2, 7].

6.4 Treatment of coagulopathy

In cases of massive hemorrhage, patients must be kept in good systemic condition, and local hemostasis must be achieved while paying attention to the possible occurrence of coagulopathy under monitoring of fibrinogen levels as point-of-care testing in order to perform early diagnosis and treatment of coagulopathy [7]. When coagulopathy is present, local hemostasis, such as balloon tamponade, surgical sutures, and TAE, is difficult to achieve because of hemorrhagic tendency. In these cases of coagulopathy, the blood fibrinogen level is often <100 mg/dL. Therefore, the treatment of coagulopathy should be performed by combined administration of concentrated coagulation factors (fibrinogen concentrate and cryoprecipitate) and fresh-frozen plasma promptly to obtain a blood fibrinogen level of at least 150–200 mg/dL [7, 48]. If coagulopathy is eliminated, the conventional hemostatic procedures become effective.

7. A minimally invasive hemostatic strategy in CSP and cervical pregnancy

Curettage alone is reportedly not a suitable first-choice procedure because using curettage only may lead to serious complications such as massive hemorrhage or uterine rupture, necessitating additional treatment in 76.2% (16/21) of patients [1]. On the other hand, the methotrexate (MTX) monotherapy is time-consuming

in terms of achieving cure and may be accompanied by hemorrhage or infection. Reduction of the chorionic tissue by MTX therapy to decrease blood flow, followed by curettage or laparotomy, rather than MTX or curettage alone, achieves a higher cure rate and is associated with fewer complications such as hemorrhage, infection, and sepsis.

For the management of CSP and cervical pregnancy in the first trimester, we first perform ultrasonography to confirm the implantation site of the gestational sac, observe the status and thickness of the myometrium in surrounding areas and the presence/absence of fetal heart beats, and determine the gestational week. At the same time, we measure the blood hCG level and evaluate blood flow around the gestational sac by Doppler ultrasonography. Changes in the blood hCG levels and the status of blood flow are useful for judging the viability of chorionic villi and the efficacy of estimating chemotherapy. If there is abundant blood flow in the myometrium as well as in the tissues surrounding the gestational sac, villous invasion site on the myometrium is suspected. In such cases, implementation of D&C alone is expected to cause massive hemorrhage.

When there are fetal heart beats, potassium chloride (KCl) is administered directly to the fetus to cause cessation of the heart beating. MTX is administered systemically (1 mg/kg body weight) or by local injection to the villous area at the same time. Subsequently, MTX is administered systemically every 7–10 days. In patients with high blood levels of hCG, MTX therapy used to be performed to decrease the hCG level to a target of 20,000 mIU/mL, or even lower, followed by TAE and curettage. The rates of blood transfusion and/or blood loss of >2500 mL in these combined treatment (MTX + TAE + D&C) were significantly decreased, compared with those in D&C alone, 9.5 and 83.3% respectively.

The rate of additional surgical treatment, such as wedge resection or hysterectomy, in combined treatment, was none, compared with D&C alone, 0 and 50.0%, respectively. There were no complications such as uterine rupture, postoperative infections, menstrual abnormalities, and ovarian dysfunction in D&C alone and combined treatment. These combined treatments yielded satisfactory results with a decreased volume of blood loss, no additional surgical treatment, and a high cure rate, compared with D&C alone (**Figure 5, Tables 3 and 4**).

Currently, prophylactic TAE before D&C is avoided whenever possible, with the aim of preventing short-term complications and uterine rupture in the subsequent pregnancy, and also shortening hospital stay. A target blood hCG levels after MTX is also changed to <40,000 mIU/mL for adverse effects of MTX. Then, ultrasound-guided D&C to evacuate the gestational sac is performed a week later after MTX therapy. Bleeding point during D&C could be found by contrast-enhanced ultrasonography, and a cervical ripening miniballoon (Minimetro[®]) could be inserted at the bleeding point and inflated until bleeding stops [46, 49]. If bleeding continues, TAE or laparoscopic wedge resection would be performed as soon as possible. Nine patients with CSP (6–12 weeks gestation) and one (7 weeks gestation) with cervical pregnancy were treated under new management. Seven cases were successfully treated with D&C and balloon tamponade after MTX. Additional treatments were needed in three cases for bleeding. This combined therapy resulted in all complete cure and no additional surgical therapy without complications.

Moreover, if early detection of CSP is possible, more minimally invasive treatments might be another option of treatment such as double balloon conservative therapy or hysteroscopic resection without MTX therapy. We also experienced one case with CSP to be successfully treated after cessation of fetal heart beats by local injection of KCl. She selected conservative therapy without chemotherapy and surgical therapy and then was just followed up in outpatient clinic. It took 6 months to be cured completely, but there were no complications and no bleeding. Even in

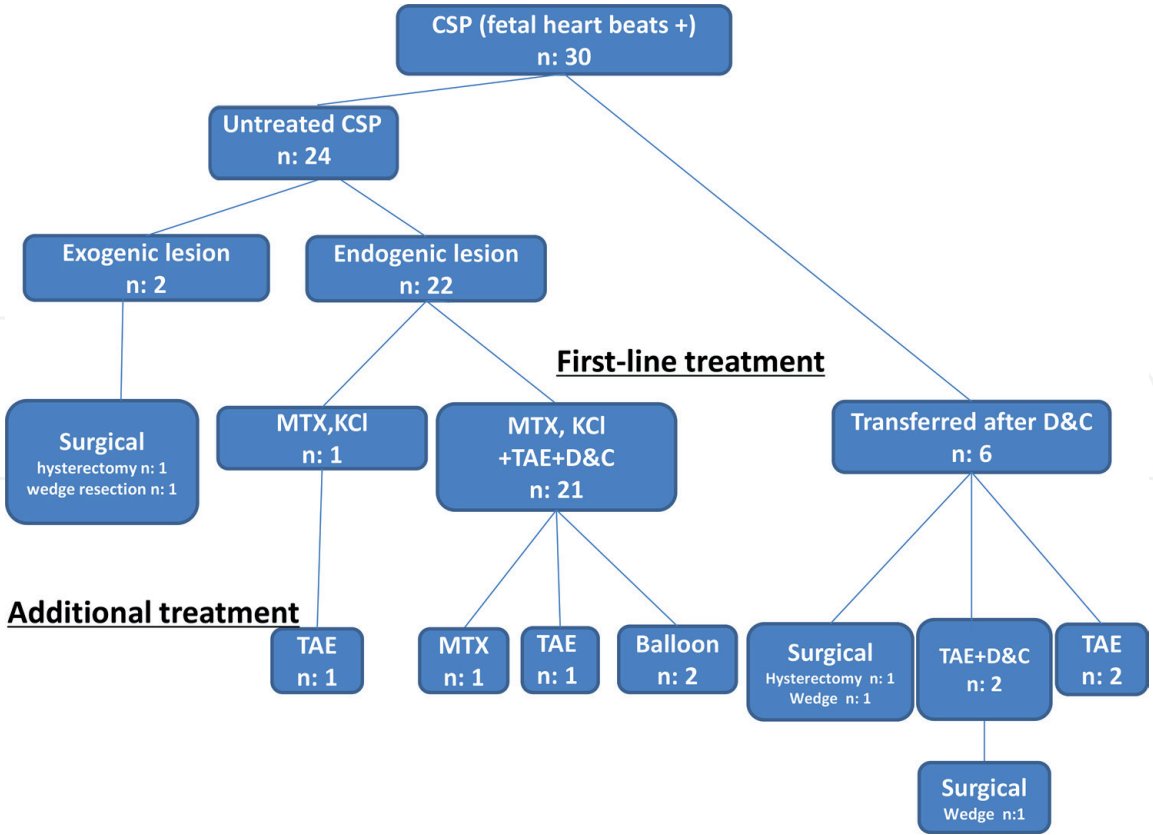


Figure 5. Treatment results of cesarean scar pregnancy with fetal heart beats under uterus-preserving management. Thirty patients diagnosed with cesarean scar pregnancy with positive fetal heartbeat in the first trimester were treated at Saitama Medical Center and Juntendo University Hospital from 1998 to 2010. The average maternal age was 33.3 ± 5.8 years (mean ± SD), and average gestational age on admission was 6.6 ± 1.5 weeks of gestation. The average hCG level on admission was 29,534 ± 26,284 mIU/mL, and its level on dilation and curettage was 19,995 ± 24,765 mIU/mL. Twenty-one patients were treated under our uterus-preserving management policy and six patients were transferred to our hospital due to uncontrollable hemorrhage after dilation and curettage. This management strategy yielded satisfactory results with a decreased volume of blood loss and a high cure rate.

Characteristic	D&C alone (n:6)	MTX + TAE + D&C (n:21)	P-value
Age (years)	34.5 + 3.0 (32–39)	34.0 + 5.8 (23–42)	0.84
Number of previous CS (n)	1.5 + 0.8 (1–3)	1.3 + 0.6 (1–3)	0.47
Gestational age at diagnosis (weeks)	7.8 + 2.4 (6–12)	6.3 + 1.1 (5–8)	0.19
Blood hCG levels at diagnosis (mIU/mL)	17,551.3+ 20,483.0	37,876.1+ 33,816.3	0.18
Blood hCG levels at D&C (mIU/mL)	15,360.8+ 20,344.9	17,840.5+ 19,111.9	0.78

There are no significant differences in characteristics between D&C alone and combined treatment.

Table 3. Comparison of background between cases with dilation and curettage (D&C) alone and those with methotrexate + transcatheter arterial embolization + D&C.

	D&C alone (n:6)	MTX + TAE + D&C (n:21)	P-value
Blood transfusion/>2500 mL blood loss	83.3% (5/6)	9.5% (2/21)	0.001
Wedge resection/hysterectomy	50.0% (3/6)	0% (0/21)	0.007
Hospital stay (days)	15.5 + 10.4	9.6 + 8.4	0.163
<i>Combined procedures (MTX + TAE + D&C) yielded satisfactory results with a decreased volume of blood loss, no additional surgical treatment, and a high cure rate, compared with D&C alone.</i>			

Table 4.
Comparison of outcome and additional treatment between D&C alone and methotrexate + transcatheter arterial embolization + dilation and curettage (D&C).

cases with placenta previa on cesarean delivery scar, who were managed to leave the placenta in situ for placenta accreta spectrum disorders after cesarean section near term (median 36 weeks gestation; range 28–38 weeks gestation) in order to preserve the uterus without hysterectomy, the conservative therapy was successful in 25 (69.4%) cases without any additional surgery [50]. Placental resorption occurred postpartum (median 89 days; range 6–510 days). Hysterectomy was performed for the other 11 cases, primarily owing to hemorrhage and/or infection. Considering smaller uterine blood supply and amount of gestational tissues in the first trimester than those in near term, conservative management after cessation of fetal heart beats in cesarean scar pregnancy may have higher success rate, if possible, with close postpartum follow-up for at least several months.

8. Conclusion

The basic policy for the management of non-tubal ectopic pregnancy, such as CSP and cervical pregnancy, is termination of pregnancy and preservation of the uterus, and the method of treatment should be selected according to the gestational week, presence/absence of fetal heart beats, the blood hCG level, and abundance of the blood supply adjacent to villi or the gestational sac. Recent reviews and reports support an interventional or a combination of surgical and medical approaches for treatment of unruptured CSP and cervical pregnancy rather than medical approach alone. In a national cohort study, surgical management appears to be associated with a high success rate, low complication rate, and short posttreatment follow-up.

Massive hemorrhage reportedly occurs in some cases with spontaneous rupture or after evacuation of the uterus without an accurate diagnosis. In cases experiencing massive hemorrhage, pressure hemostasis using balloon tamponade should first be performed. If such hemostasis proves to be ineffective, surgical excision or TAE should be selected next. If balloon tamponade or TAE is successful in controlling hemorrhage, conservative treatment is also a feasible option. In cases with coagulopathy, the blood fibrinogen level is often <100 mg/dL. Therefore, the treatment of coagulopathy should be performed by combined administration of concentrated coagulation factors (fibrinogen concentrate and cryoprecipitate) and fresh-frozen plasma promptly to obtain a blood fibrinogen level of at least 150–200 mg/dL.

Recently, a minimally invasive hemostatic strategy in obstetrics, which aims to preserve uterine function and enhance the safety of subsequent pregnancies, has been developed. Therefore, we should reconsider uterus-preserving hemostatic

strategies for critical hemorrhage and management of non-tubal ectopic pregnancy under these circumstances by using safe and minimally invasive treatment modalities. Moreover, if early detection of CSP is possible, more minimally invasive treatment might be another option of treatment such as double balloon conservative therapy or hysteroscopic resection without chemotherapy. Conservative therapy without chemotherapy and surgical therapy may be the other option. They were just followed up closely in outpatient clinic after cessation of fetal heart beats by local injection of KCl.

The optimal treatment of CSP and cervical pregnancy is still unclear at present. Further evaluation of several therapies and hemostatic techniques by treating a large number of patients is necessary.

Conflict of interest

None.

Author details

Satoru Takeda^{1,2*}, Jun Takeda¹, Takashi Yorifuji¹ and Taro Koshiishi³

1 Department of Obstetrics and Gynecology, Faculty of Medicine, Juntendo University, Tokyo, Japan

2 Aiiku Research Institute for Maternal, Child Health and Welfare, Tokyo, Japan

3 Hagukumi Clinic for Mama and Kids, Kanagawa, Japan

*Address all correspondence to: stakeda@juntendo.ac.jp

IntechOpen

© 2019 The Author(s). Licensee IntechOpen. This chapter is distributed under the terms of the Creative Commons Attribution License (<http://creativecommons.org/licenses/by/3.0>), which permits unrestricted use, distribution, and reproduction in any medium, provided the original work is properly cited. 

References

- [1] Yorifuji T, Takeda J, Koshiishi T, Takeda S. Cesarean scar pregnancy. In: Takeda S, Hiramatsu Y, Konishi I, Sakuragi N, editors. OGS NOW, No. 10. Massive Obstetric Hemorrhage: Critical Care for Intractable Bleeding and Definite Strategies of Hemostasis. Tokyo: Medical View; 2012. pp. 64-71 in Japanese
- [2] Takeda S, Takeda J, Makino S. A minimally invasive hemostatic strategy in obstetrics aiming to preserve uterine function and enhance the safety of subsequent pregnancies. *Hypertens Res Pregnancy*. 2019;7:9-15. DOI: 10.14390/jsshp.HRP2018-013
- [3] Sone M, Nakajima Y, Woodhams R, Shioyama Y, Tsurusaki M, Hiraki T, et al. Interventional radiology for critical hemorrhage in obstetrics: Japanese Society of Interventional Radiology (JSIR) procedural guidelines. *Japanese Journal of Radiology*. 2015;33(4):233-240. DOI: 10.1007/s11604-015-0399-0
- [4] Inoue S, Masuyama H, Hiramatsu Y, Multi-Institutional Study Group of Transarterial Embolization for Massive Obstetric Haemorrhage in Chugoku & Shikoku Area Society of Obstetrics and Gynecology. Efficacy of transarterial embolisation in the management of post-partum haemorrhage and its impact on subsequent pregnancies. *The Australian & New Zealand Journal of Obstetrics & Gynaecology*. 2014;54(6):541-545. DOI: 10.1111/ajo.12228
- [5] Takeda J, Makino S, Ota A, Tawada T, Mitsuhashi N, Takeda S. Spontaneous uterine rupture at 32 weeks of gestation after previous uterine artery embolization. *The Journal of Obstetrics and Gynaecology Research*. 2014;40(1):243-246. DOI: 10.1111/jog.12122
- [6] Sano Y, Takeda J, Kuroda K, Makino S, Itakura A, Takeda S. Embrittlement of uterus after uterine artery embolization: A case of uterine perforation. *Hypertension Research in Pregnancy*. 2016;4:42-44. DOI: 10.14390/jsshp.HRP2015-017
- [7] Takeda J, Makino S, Takeda S. Hemostasis for massive hemorrhage during cesarean section. In: Schmolzer G, editor. *Cesarean Delivery*. London: IntechOpen; 2019 in press
- [8] Chen HY et al. Observation of cesarean section scar by transvaginal ultrasonography. *Ultrasound in Medicine & Biology*. 1990;16:443-447
- [9] Larsen JV, Solomon MH. Pnegnancy in a uterine sca sacculus-an unusual cause of postabortal haemorrhage. A case report. *South African Medical Journal = Suid-Afrikaanse Tydskrif vir Geneeskunde*. 1978;53:142
- [10] Seow KM, Huang LW, Lin YH, Lin MY, Tsai YL, Hwang JL. Cesarean scar pregnancy: Issues in management. *Ultrasound in Obstetrics & Gynecology*. 2004;23:247-253. DOI: 10.1002/uog.974
- [11] Harb HM, Knight M, Bottomley C, Overton C, Tobias A, Gallos ID, et al. Caesarean scar pregnancy in the UK: A national cohort study. *BJOG: An International Journal of Obstetrics and Gynaecology*. 2018;125(13):1663-1670. DOI: 10.1111/1471-0528.15255
- [12] Vial Y, Petignat P, Hohlfield P. Pregnancy in cesarean scar. *Ultrasound in Obstetrics & Gynecology*. 2000;16:592-593. DOI: 10.1046/j.1469-0705.2000.00300-2.x
- [13] Jurkovic D, Hillaby K, Woelfer B, Lawrence A, Salim R, Elson CJ. First trimester diagnosis and management of pregnancies implanted into the lower uterine caesarean section scar. *Ultrasound in Obstetrics & Gynecology*. 2003;21:220-227. DOI: 10.1002/uog.56

- [14] Rotas MA, Haberman S, Levгур M. Cesarean scar ectopic pregnancies: Ethiology, diagnosis and management. *Obstetrics and Gynecology*. 2006;**107**:1373-1377. DOI: 10.1097/01.AOG.0000218690.24494.ce
- [15] Cali G, Timor-Tritsch IE, Palacios-Jaraquemada J, Monteagudo A, Buca D, Forlani F, et al. Outcome of cesarean scar pregnancy managed expectantly: Systematic review and meta-analysis. *Ultrasound in Obstetrics & Gynecology*. 2018;**51**(2):169-175. DOI: 10.1002/uog.17568
- [16] Fylstra DL. Ectopic pregnancy within a cesarean scar: A review. *Obstetrical & Gynecological Survey*. 2002;**57**(8):537-543. DOI: 10.1097/01.OGX.0000025517.33346.1E
- [17] Timor-Tritsch IE, Monteagudo A, Santos R, Tsymbal T, Pineda G, Arslan AA. The diagnosis, treatment, and follow-up of cesarean scar pregnancy. *American Journal of Obstetrics and Gynecology*. 2012;**207**(1):44.e1-44.13. DOI: 10.1016/j.ajog.2012.04.018
- [18] Timor-Tritsch IE, Monteagudo A. Unforeseen consequences of the increasing rate of cesarean deliveries: Early placenta accreta and cesarean scar pregnancy. A review. *American Journal of Obstetrics and Gynecology*. 2012;**207**(1):14-29. DOI: 10.1016/j.ajog.2012.03.007
- [19] Jabeen K, Karuppaswamy J. Non-surgical management of caesarean scar ectopic pregnancy—A five-year experience. *Journal of Obstetrics and Gynaecology*. 2018;**38**(8):1121-1127. DOI: 10.1080/01443615.2018.1451986
- [20] Birch Petersen K, Hoffmann E, Rifbjerg Larsen C, Svarre Nielsen H. Cesarean scar pregnancy: A systematic review of treatment studies. *Fertility and Sterility*. 2016;**105**(4):958-967. DOI: 10.1016/j.fertnstert.2015.12.130
- [21] Alalade AO, Smith FJE, Kendall CE, Odejinmi F. Evidence-based management of non-tubal ectopic pregnancies. *Journal of Obstetrics and Gynaecology*. 2017;**37**(8):982-991. DOI: 10.1080/01443615.2017.1323852
- [22] Maheux-Lacroix S, Li F, Bujold E, Nesbitt-Hawes E, Deans R, Abbott J. Cesarean scar pregnancies: A systematic review of treatment options. *Journal of Minimally Invasive Gynecology*. 2017;**24**(6):915-925. DOI: 10.1016/j.jmig.2017.05.019
- [23] Kim SY, Yoon SR, Kim MJ, Chung JH, Kim MY, Lee SW. Cesarean scar pregnancy; diagnosis and management between 2003 and 2015 in a single center. *Taiwanese Journal of Obstetrics & Gynecology*. 2018;**57**(5):688-691. DOI: 10.1016/j.tjog.2018.08.013
- [24] Giampaolino P, De Rosa N, Morra I, Bertrando A, Di Spiezio SA, Zizolfi B, et al. Management of cesarean scar pregnancy: A single-institution retrospective review. *BioMed Research International*. 2018;**2018**:6486407. DOI: 10.1155/2018/6486407. eCollection 2018
- [25] Gonzalez N, Tulandi T. Cesarean scar pregnancy: A systematic review. *Journal of Minimally Invasive Gynecology*. 2017;**24**(5):731-738. DOI: 10.1016/j.jmig.2017.02.020
- [26] Wang DB, Chen YH, Zhang ZF, Chen P, Liu KR, Li Y, et al. Evaluation of the transvaginal resection of low-segment cesarean scar ectopic pregnancies. *Fertility and Sterility*. 2014;**101**(2):602-606. DOI: 10.1016/j.fertnstert.2013.10.024
- [27] Peng M, Li L, Ding Y, Yu L, Deng Y, Zheng J, et al. Exploration of the successful treatment algorithms used in 23 cases of early live cesarean scar pregnancy. *Gynecologic and Obstetric Investigation*. 2015;**79**(2):139-144. DOI: 10.1159/000368400

- [28] Jurkovic D, Knez J, Appiah A, Farahani L, Mavrellos D, Ross JA. Surgical treatment of cesarean scar ectopic pregnancy: Efficacy and safety of ultrasound-guided suction curettage. *Ultrasound in Obstetrics & Gynecology*. 2016;**47**(4):511-517. DOI: 10.1002/uog.15857
- [29] Ades A, Parghi S. Laparoscopic resection of cesarean scar ectopic pregnancy. *Journal of Minimally Invasive Gynecology*. 2017;**24**(4):533-535. DOI: 10.1016/j.jmig.2016.11.006
- [30] Kwon YS, Cho YM, Im KS, Yoo SB, Hyung SW. Transient occlusion of uterine arteries in procedures with high risk of uterine bleeding. *Journal of the Society of Laparoendoscopic Surgeons*. 2019;**23**(1):pii: e2018.00072. DOI: 10.4293/JLS.2018.00072
- [31] Jurkovic D, Ben-Nagi J, Ofilli-Yebovi D, Sawyer E, Helmy S, Yazbek J. Efficacy of Shirodkar cervical suture in securing hemostasis following surgical evacuation of cesarean scar ectopic pregnancy. *Ultrasound in Obstetrics & Gynecology*. 2007;**30**(1):95-100. DOI: 10.1002/uog.4058
- [32] Heikinheimo O, Leminen A, Cacciatore B, Rutanen EM, Kajanoja P. Advanced cervical pregnancy: Uterus-sparing therapy initiated with a combination of methotrexate and mifepristone followed by evacuation and local hemostatic measures. *Acta Obstetrica et Gynecologica Scandinavica*. 2004;**83**(2):211-213
- [33] Bakour SH, Thompson PK, Khan KS. Successful conservative management of cervical ectopic pregnancy with combination of methotrexate, mifepristone, surgical evacuation and tamponade using a double balloon three-way catheter. *Journal of Obstetrics and Gynaecology*. 2005;**25**(6):616-618. DOI: 10.1080/01443610500243620
- [34] Gómez García MT, Aguarón Benítez G, Barberá Belda B, Callejón Rodríguez C, González Merlo G. Medical therapy (methotrexate and mifepristone) alone or in combination with another type of therapy for the management of cervical or interstitial ectopic pregnancy. *European Journal of Obstetrics, Gynecology, and Reproductive Biology*. 2012;**165**(1):77-81. DOI: 10.1016/j.ejogrb.2012.06.024
- [35] Di Spiezio Sardo A, Vieira MDC, Laganà AS, Chiofalo B, Vitale SG, Scala M, et al. Combined systemic and hysteroscopic intra-amniotic injection of methotrexate associated with hysteroscopic resection for cervical pregnancy: A cutting-edge approach for an uncommon condition. *The Eurasian Journal of Medicine*. 2017;**49**(1):66-68. DOI: 10.5152/eurasianjmed.2017.16215
- [36] Trambert JJ, Einstein MH, Banks E, Frost A, Goldberg GL. Uterine artery embolization in the management of vaginal bleeding from cervical pregnancy: A case series. *The Journal of Reproductive Medicine*. 2005;**50**(11):844-850
- [37] Martinelli P, Maruotti GM, Oppedisano R, Agangi A, Mazzarelli LL, Votino C, et al. Is uterine artery embolization for cervical ectopic pregnancy always safe? *Journal of Minimally Invasive Gynecology*. 2007;**14**(6):758-763. DOI: 10.1016/j.jmig.2007.05.017
- [38] Ben Farhat L, Ben Salah Y, Askri A, Dali N, Hendaoui L. Conservative treatment of a cervical twin pregnancy with uterine artery embolization. *Diagnostic and Interventional Radiology*. 2010;**16**(3):248-250. DOI: 10.4261/1305-3825.DIR.2073-08.1
- [39] Zhou Q, Young D, Vingan H. Uterine artery embolization for cervical ectopic pregnancy. *Radiology Case Reports*. 2015;**10**(4):72-75. DOI: 10.1016/j.radcr.2015.08.004. eCollection 2015 Dec

- [40] Mashiach S, Admon D, Oelsner G, Paz B, Achiron R, Zalel Y. Cervical shirodkar cerclage may be the treatment modality of choice for cervical pregnancy. *Human Reproduction*. 2002;**17**(2):493-496. DOI: 10.1093/humrep/17.2.493
- [41] Mancuso A, Carlo Stella N, Dugo C, de Vivo A, Priola V. A simple surgical approach in the treatment of cervical pregnancy. *Journal of Obstetrics and Gynaecology*. 2007;**27**(2):191-192. DOI: 10.1080/01443610601137747
- [42] Faschingbauer F, Mueller A, Voigt F, Beckmann MW, Goecke TW. Treatment of heterotopic cervical pregnancies. *Fertility and Sterility*. 2011;**95**(5):1787.e9-1787.13. DOI: 10.1016/j.fertnstert.2010.10.043
- [43] Moragianni VA, Hamar BD, McArdle C, Ryley DA. Management of a cervical heterotopic pregnancy presenting with first-trimester bleeding: Case report and review of the literature. *Fertility and Sterility*. 2012;**98**(1):89-94. DOI: 10.1016/j.fertnstert.2012.04.003
- [44] Mangino FP, Romano F, Di Lorenzo G, Buonomo F, De Santo D, Scrimin F, et al. Total hysteroscopic treatment of cervical pregnancy: The 2-step technique. *Journal of Minimally Invasive Gynecology*. 2019;**pii**:S1553-4650(19)30053-6. DOI: 10.1016/j.jmig.2019.01.009
- [45] Timor-Tritsch IE, Monteagudo A, Bennett T-A, Foley C. A new minimally invasive treatment for cesarean scar pregnancy and cervical pregnancy. *American Journal of Obstetrics and Gynecology*. 2016;**351**:e1-e8. DOI: 10.1016/j.ajog.2016.03.010
- [46] Yorifuji T, Takeda J, Makino S, Tanaka T, Itakura A, Takeda S. Evaluation of the effectiveness of metreurynters for balloon tamponade. *Hypertension Research in Pregnancy*. 2018;**6**:26-29. DOI: doi.org/10.14390/jsshp.HRP2018-001
- [47] Makino S, Takeda J, Hirai C, Itakura A, Takeda S. Uterine balloon tamponade as a test to assess further treatment. *Acta Obstetrica et Gynecologica Scandinavica*. 2015;**94**(5):556. DOI: 10.1111/aogs.12599
- [48] Takeda J, Takeda S. Management of disseminated intravascular coagulation associated with placental abruption and measures to improve outcomes. *Obstetrics & Gynecology Science*. 2019;**62**:e52. DOI: 10.5468/ogs.2019.62.e52
- [49] Makino S, Hirai C, Itakura A, Takeda S, Yoshikawa H, Li Z, et al. Evaluation of uterine blood flow: A new method using contrast-enhanced ultrasound. *European Journal of Obstetrics, Gynecology, and Reproductive Biology*. 2015;**191**:143-144. DOI: 10.1016/j.ejogrb.2015.04.009
- [50] Miyakoshi K, Otani T, Kondoh E, Makino S, Tanaka M, Takeda S. Perinatal research network in Japan. Retrospective multicenter study of leaving the placenta in situ for patients with placenta previa on a cesarean scar. *International Journal of Gynaecology and Obstetrics*. 2018;**140**(3):345-351. DOI: 10.1002/ijgo.12397