

We are IntechOpen, the world's leading publisher of Open Access books Built by scientists, for scientists

6,900

Open access books available

186,000

International authors and editors

200M

Downloads

Our authors are among the

154

Countries delivered to

TOP 1%

most cited scientists

12.2%

Contributors from top 500 universities



WEB OF SCIENCE™

Selection of our books indexed in the Book Citation Index
in Web of Science™ Core Collection (BKCI)

Interested in publishing with us?
Contact book.department@intechopen.com

Numbers displayed above are based on latest data collected.
For more information visit www.intechopen.com



Extensive Repair in Type A Aortic Dissection: To Save the Patient or to Ensure a Durable Repair?

Benoit Cosset, Sarah Abdellaoui, Hugo Huvelle, Amine Fikani and Fadi Farhat

Abstract

Type A aortic dissection (TAAD) is a serious condition requiring emergency surgical management. The main objective of the treatment is the patient survival. Thus, the surgeon has to perform a well-mastered surgical technique without extending the operative time and emphasizing operative risk. Nevertheless, patients with history of TAAD present long-term complications on the aorta, mainly aneurysmal evolution and dissection recurrence. In order to decrease the long-term excess mortality of this population, it is necessary to respect some rules during the surgery. Concerning the proximal segment of the ascending aorta, the aortic root has to be replaced by a composite graft (Bentall technique) or a valve sparing inclusion (David technique) when the dissection reaches the sinuses of Valsalva or when aortic valve regurgitation is observed. Concerning the distal segment of the ascending aorta, the distal anastomosis has to be performed without aortic clamping. Concerning the descending thoracic aorta, hybrid surgery should be performed on patients with malperfusion syndrome and patients with high risk factors for aneurysmal evolution.

Keywords: type A aortic dissection, aneurysm formation, extensive repair, aortic valve sparing, frozen elephant trunk

1. Introduction

Type A aortic dissection (TAAD) represents a double challenge: a short-term challenge with a 30-day mortality around 25% [1] and a long-term challenge with an excess of morbidity and mortality for this population [2]. Concerning the short-term evolution, the intrahospital mortality is mainly influenced by patient history and preoperative complications [2]. Concerning the long-term evolution, the excess of morbidity and mortality seems correlated to two main complications: complications of hypertension such as strokes and ischemic heart disease and complications of aneurysmal evolution of the descending aorta such as aortic rupture and reoperations [3]. Thus, the main challenge of the surgical management of the TAAD is to strike a balance between keeping an early mortality rate as low as possible and preventing long-term morbidity.

2. Save the patient

2.1 Short-term mortality: statistics and causes

Type A aortic dissection (TAAD) is a serious pathology with high short-term mortality rates. Indeed, series find a 50% mortality at 48 hours for nonoperated patients and an intrahospital mortality between 20 and 30% for operated patients [1].

This high mortality rate is due to the great number of serious complications associated to the TAAD. The main mortality cause in the TAAD is acute aortic rupture [1]. Concerning the cardiac complications, we observe an aortic regurgitation in 40–75% [4, 5], a cardiac tamponade in 20%, and a myocardial infarction in 10–15%. These complications lead to congestive heart failure in 10% of cases. The other complications are neurological such as spinal ischemia, stroke and coma, mesenteric ischemia, and renal failure.

The analysis of short-term mortality shows that the characteristics of the patient (age, history of aortic valve replacement) and the preoperative complications of the TAAD (migrating chest pain, preoperative limb ischemia, hypotension, shock, cardiac tamponade) have more impact on the early survival than the type of surgical management [2]. These results demonstrate that even with optimal medical and surgical management, TAAD will remain a serious pathology with high mortality rate. These short-term mortality risk factors distinguish the patients in two categories at the time of the surgery: stable patients and unstable patients. Patients are defined as unstable in case of cardiac tamponade, myocardial ischemia, congestive heart failure, shock, cerebrovascular accident, coma, mesenteric ischemia, and acute renal failure. The latter having short-term mortality rate twice as high as stable patients (31.4 versus 16.7%) [2]. This distinction is important for the choice of the surgical technique, which should depend in part upon the stability of the patient at the time of the surgery.

Management of patients with neurological complications at the onset of the dissection is still debated. To assess this issue, Tsukube presented the results of patients with coma on arrival [6]. They decided to operate immediately when coma was inferior to 5 hours. The surgical technique was a central repair performed under deep hypothermia with antegrade cerebral perfusion. For this group, intrahospital mortality was equal to 14%. Concerning the other patients, they were treated initially medically and in a second time surgically. Intrahospital mortality was equal to 67%. In terms of severity, the national institute of health stroke scale decreased significantly after the surgery in the immediate group. These results, confirmed by other series [7], show that coma, if managed immediately, should not be an operative contraindication.

Concerning the management of acute neurological deficit, Estrera showed that this complication, when managed surgically by central repair, was associated with an acceptable mortality rate (7 versus 100% of mortality for unoperated patients) [8].

Finally, surgery remains superior to optimal medical management even though the patient is unstable, in coma or over 80.

2.2 Long-term mortality statistics and causes

Even if the TAAD is an acute disease necessitating emergency treatment, this pathology presents an important long-term morbi-mortality. Thus, 10 years survival is between 50 and 70% [3, 9, 10], and 10 years re-operation rate is around 15% [11].

Several factors contribute to this excess morbi-mortality. In Tanaka's study [12], 243 patients were operated on for TAAD, and mortality causes at follow up were cancer, heart disease and acute aortic rupture for, respectively, 37, 23 and 13% of the cases. The reoperation rate for aortic aneurysm was 5.7%. These results are similar to Kirsch's outcomes in his 2002 study [11].

Even if cancer and heart diseases cannot be decreased by the initial surgical strategy, death by acute aortic rupture and reoperation for aortic aneurysm could be prevented by the first surgery. Within this framework, the question is raised to treat not only the immediate complications of the aortic dissection but also to perform an optimal aortic repair in order to prevent long-term complications of the TAAD.

3. Ensure a durable repair

The main objective of the surgical treatment is to ensure the patient's survival. Thus, the replacement of the ascending aorta containing the primary tear and the re-establishment of the dominant flow through the true lumen prevent from acute aortic rupture and mostly correct vascular complications [13].

As seen before, the secondary objective of the surgical treatment is now to provide the best repair in order to prevent complications on the aortic valve and on the aorta. The challenge is to complete this preventing treatment without compromising the short-term survival. In this context, the European Society of Cardiology (ESC) provided recommendations upon the surgical treatment of the TAAD.

3.1 Proximal segment of the ascending aorta

- Concerning the aortic root management, the discussion is to identify the patients who need an aortic root replacement and the patients who need a more conservative aortic root treatment.
- As reported by the analysis of the International Registry of Acute Dissection (IRAD), aortic root replacement compared with conservative root management is not associated with increased inhospital mortality. Thus, the comparison based on 1995 patients found 18% of hospital mortality in root replacement group and 21.3% of hospital mortality in conservative root group (odds ratio [OR], 0.989; 95% CI, 0.710–1.379; $P = 0.949$ after covariate adjustment) [14]. Midterms observations at 3 years did not showed statistical difference between the two techniques concerning overall mortality ($91.6 \pm 1.3\%$ survival for conservative root management, $92.5 \pm 1.7\%$ survival for aortic root replacement management, $P = 0.623$) and freedom from reintervention ($99.3 \pm 0.1\%$ for conservative root group and $99.2 \pm 0.1\%$ for root replacement group $P = 0.770$). However, aortic root replacement must not be performed systematically. Thus, the latter is recommended for patients with sinuses of Valsalva involved by the dissection and for patients who need surgery on the aortic valve. An aortic root replacement is also recommended for patients with aneurysmal evolution risk factors such as Marfan's syndrome, increased sinuses of Valsalva diameter, and young patients.

Several techniques are suitable for aortic root replacement. In this situation, the aortic valve is the key factor.

- In most cases, the valve is normal, and a simple regurgitation by annulus enlargement is observed. Then, an aortic valve sparing repair is recommended [15]. As shown by Farhat [16], aortic valve sparing repair procedure did not show higher short-term and mid-term mortality rate compared with conservative management and Bentall procedure (15.7% for inhospital mortality and 84.7% survival at 1 year after David procedure). If initially two techniques were applied, the remodeling technique as described by Yacoub and the reimplantation technique described by David, the latter seems superior, mainly concerning the low reoperation rate [17] (**Figure 1**). Indeed, Leyh on a series of 30 patients found a $95 \pm 5\%$ freedom from reoperation in reimplantation group (David procedure) versus a $38 \pm 23\%$ remodeling group (Yacoub procedure) ($P = 0.13$). Yet, the cutoff for reintervention for secondary aortic insufficiency in the remodeling group was an annulus diameter over 27 mm at the time of the surgery, regardless to an associated aortic insufficiency.
- When the valve is pathological or in case of bicuspid aortic valve, an aortic valve replacement using a Bentall technique is recommended (**Figure 2**).

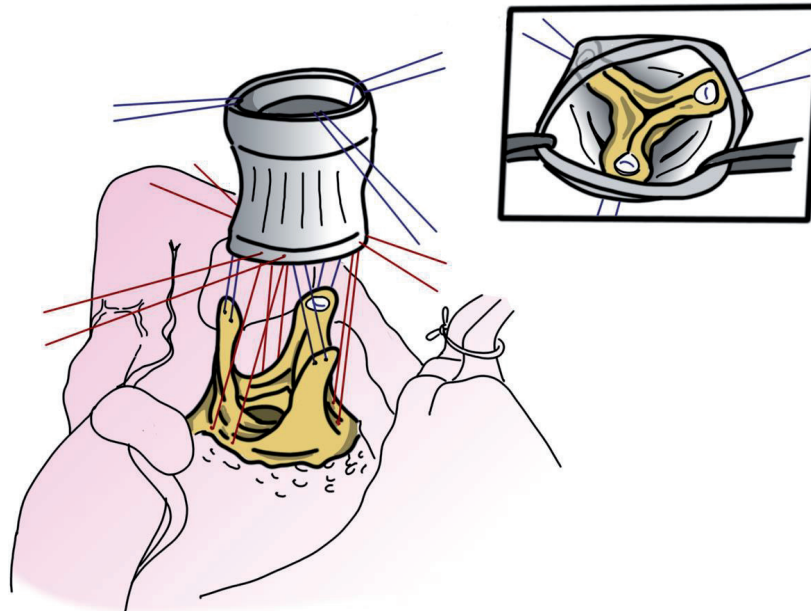


Figure 1.
David procedure.

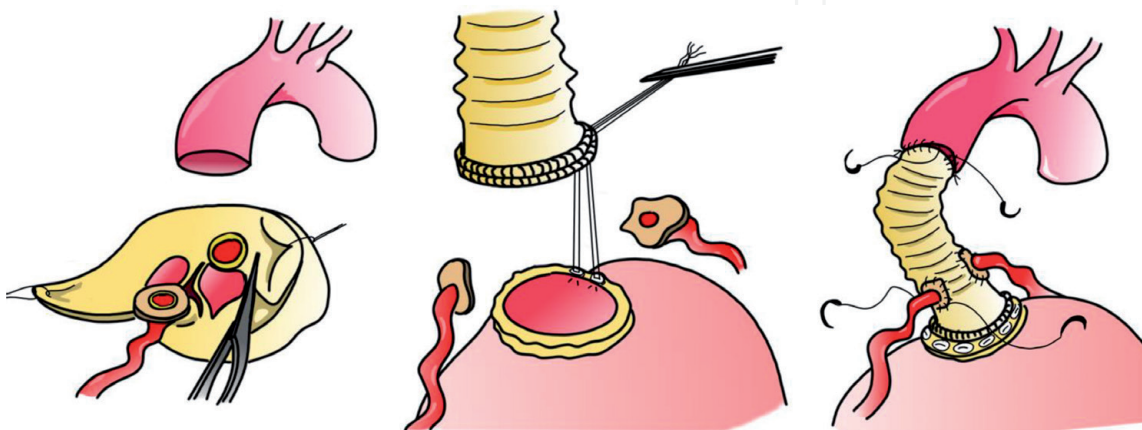


Figure 2.
Bentall procedure.

- Without aortic valve regurgitation, when the dissection does not involve the sinus of Valsalva, a simple aortic replacement with a composite graft tube can be performed.

Reimplantation valve sparing aortic root replacement (David procedure) consists of replacing the aortic root by composite graft without replacing the aortic valve. The coronary ostia are also reimplanted into the graft. This technique treats aortic regurgitation caused by annulus enlargement.

Bentall procedure involves aortic valve replacement using an aortic valve prosthesis and an aortic root replacement using a composite graft. The coronary ostia are reimplanted into the graft.

3.2 Distal segment of the ascending aorta

Whatever the extension of the repair, the distal anastomosis has to be performed without aortic clamping, under circulatory arrest [15] (ESC 2014 class 1 recommendation). Neurological protection can be provided either by deep or moderate hypothermia. If deep hypothermia (under 22°C) has been performed for decades, recently, several studies such as El-Sayed have demonstrated that moderate hypothermia at 28°C associated with antegrade cerebral perfusion was able to ensure good neurological and visceral protection. This technique provides a low rate of postoperative neurological complications (6%) within a limited cardiopulmonary bypass time (183 +/- 56 minutes) [18].

In its guidelines, the European Society of Cardiology does not recommend a type of hypothermia [15]. Nevertheless, good results of moderate hypothermia in combination with antegrade cerebral perfusion should enable generalization of this approach.

The main question for this repair is to determine how far the repair has to be performed.

Several factors will have an influence on the length of the reparation:

- The localization of the primary tear
 - The localization of the primary tear is performed by computed tomography (CT) or magnetic resonance imaging (MRI) but should be confirmed by peroperative findings. Thus, a cross clamped aorta does not allow the inspection of the aortic arch. For this reason, an open distal anastomosis is mandatory.
 - The primary tear is localized in the aortic arch in 30% of the cases of TAAD [19]. In this case, the discussion is to identify patients who need a hemiarch replacement and those who need a complete aortic arch replacement, with or without a frozen elephant trunk. The analysis of the German Registry for Acute Aortic Dissection Type A (GERAADA) demonstrated that complete aortic arch replacement compared with hemiarch replacement neither increases the in-hospital mortality (25.7 vs. 18.7% $P = 0.067$) nor the onset of new neurological deficit (12.5 vs. 13.6% $P = 0.78$) [20]. Concerning the long-term follow-up, Di Eusebio did not show any statistical difference between total arch replacement and conservative arch management [21]. Thus, 7-year survival hazard ratio was equal to 1.001 ($P = 0.8$), and freedom from aortic reintervention was equal to 1.507 ($P = 0.4$). These results are similar to other studies on the subject [22]. As a conclusion, there is no difference concerning the short- and

long-term mortality or freedom from aortic reintervention. Thus, when the entry tear is localized in the aortic arch, a total aortic arch replacement could be reasonably performed.

- In some cases, the primary tear is localized in the descending thoracic aorta, and the ascending aorta is affected by a retrograde dissection. A hybrid surgery using a frozen elephant trunk technique is the best way to manage this situation. A two-time procedure can also be performed by the realization of a complete arch repair followed by the implantation of an endoprosthesis in the descending thoracic aorta through a femoral approach.
- The presence of a malperfusion syndrome
 - Malperfusion syndrome has two origins: dynamic malperfusion secondary to compression of the true lumen by the false lumen and static malperfusion secondary to the extension of the dissection into the branch vessel. In many cases of malperfusion syndromes, these two mechanisms are combined (**Figure 3a**).

Concerning the management of the malperfusion syndrome, two strategies can be applied: performing digestive endovascular (fenestration or branch stenting) reperfusion before the ascending aorta repair or conversely performing ascending aorta repair first and treat only persistent malperfusion syndrome.

Regarding the first strategy, Yamashiro [23] showed upon a short series of 10 patients with visceral malperfusion, the advantages of performing visceral arterial branch bypass before central repair, and cardiopulmonary bypass. Others suggest performing a fenestration of the intimal flap rather than abdominal open surgery. Thus, Kamman [24] provide a patient-specific algorithm suggesting treating malperfusion syndrome first, waiting for the resolution of the malperfusion, and then performing central repair. This algorithm is based upon several studies which show the poor survival rate of TAAD complicated with malperfusion syndrome especially for patients with mesenteric ischemia requiring surgery (63.2 versus 23.8% $P < 0.001$) [25]. Nevertheless, this delaying strategy is questionable since it is associated with a high mortality rate. Thus, a large proportion of patients (33% in Patel series [26], 40% in Yang series [27]) die from aortic rupture or organ failure before the central repair.

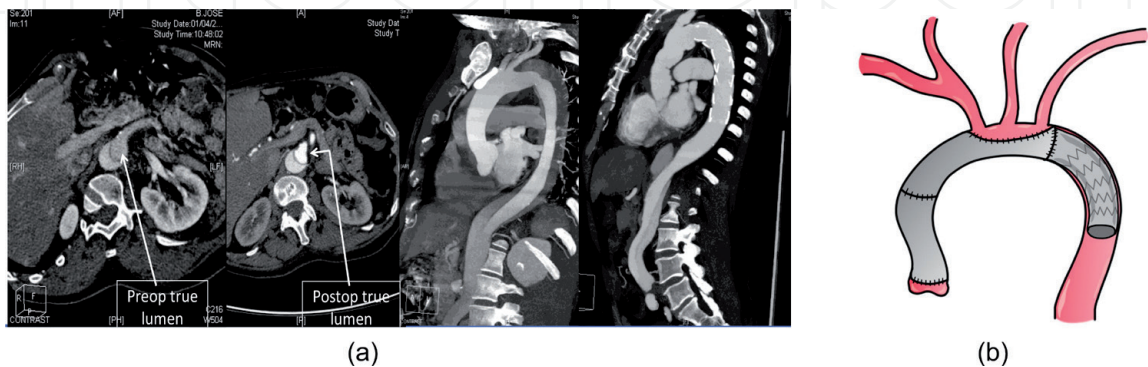


Figure 3.
(a) Type A aortic dissection complicated by malperfusion syndrome. (A) Preoperative CT: type A aortic dissection: low opacification of the true lumen with an impaired vascularization of the superior mesenteric artery. (B) Postoperative CT: type A aortic dissection treated by frozen elephant trunk: improvement of the mesenteric artery CT signal. (b) Frozen elephant trunk procedure: (A) frozen elephant trunk implantation scheme. E-vita open prothesis.

Concerning the second strategy, many authors [28, 29] propose to close the primary tear first. This approach, by redirecting the flow into the true lumen, decreases the need for latter revascularization, since in many cases the malperfusion syndrome is mainly dynamic. In Geirsson series [4], only 62.5% of patients with coronary malperfusion required coronary artery bypass and 42.9% of patients, with limb ischemia required distal revascularization after central repair. These results were similar in Charlton's study [5].

Regard to the central repair, a hybrid approach using the frozen elephant trunk technique or a two-time surgery extends the true lumen, decreases the false lumen diameter, the global aortic diameter, and creates a thrombosis of the false lumen [30] (**Figure 3b**). Thus, the vascular group of the European Association for Cardio-Thoracic Surgery (EACTS) provided a IIa class recommendation for the use of frozen elephant trunk technique in TAAD with primary tear localized in the distal aortic arch or in the proximal half of the descending thoracic aorta in order to treat or prevent a malperfusion syndrome [31].

- The prevention of aneurysm formation

As seen before, aneurysm formation is one of the main causes of excess mortality and reoperation in patients with history of TAAD [12]. Thus, preventing this complication is an important objective of the TAAD management. To answer this issue, two surgical techniques using hybrid surgery exist:

- The frozen elephant trunk technique. This surgery includes a total arch replacement associated to a per-procedural stent delivery through the aortic true lumen. Concerning the prevention of aneurysm formation in the descending thoracic aorta, Uchida [32] proved the superiority of this technique compared with ascending aortic replacement or hemiarch replacement. Thus, he observed a decrease of late thoracic aorta event (95.7 *vs* 73.0% $P = 0.01$) mainly induced by thrombosis of the false lumen (100% of thrombosis in frozen elephant trunk group *vs* 29% in the other group). However, some limits persist concerning the frozen elephant trunk technique: this surgery is demanding, emphasize the operative time, and require experimented surgeon. Moreover, some series have shown an increasing of neurological complications [33].
- A two-time surgery including a complete aortic arch replacement followed by the implantation of an endoprosthesis in the descending thoracic aorta through a femoral artery. A matter of debate is the moment of the second intervention. Most teams perform MRI or CT control till reaching aortic diameter superior to 55 mm. This approach can be discussed. Indeed, as demonstrated by the *Society of Thoracic Surgeons Endovascular Surgery Task Force*, intimal flap fibrosis appears over time [21]. This fibrosis jeopardizes endovascular treatment and frequently leads to open surgery [34]. Moreover, actual guidelines for aortic aneurysm treatment are the same whatever the etiology: at the descending thoracic aorta: a maximal diameter superior to 60 mm for open surgery and 55 mm for endovascular treatment [35]. Unfortunately, this cutoff is not suitable to dissected aorta which is a fragilized vessel. For example, Kimura found a median diameter before aortic rupture at 56 mm [36] in patient with history of TAAD.

Yet, performing a hybrid surgery in the descending thoracic aorta does not prevent in all cases from aneurysm formation. At the thoracic level, false lumen

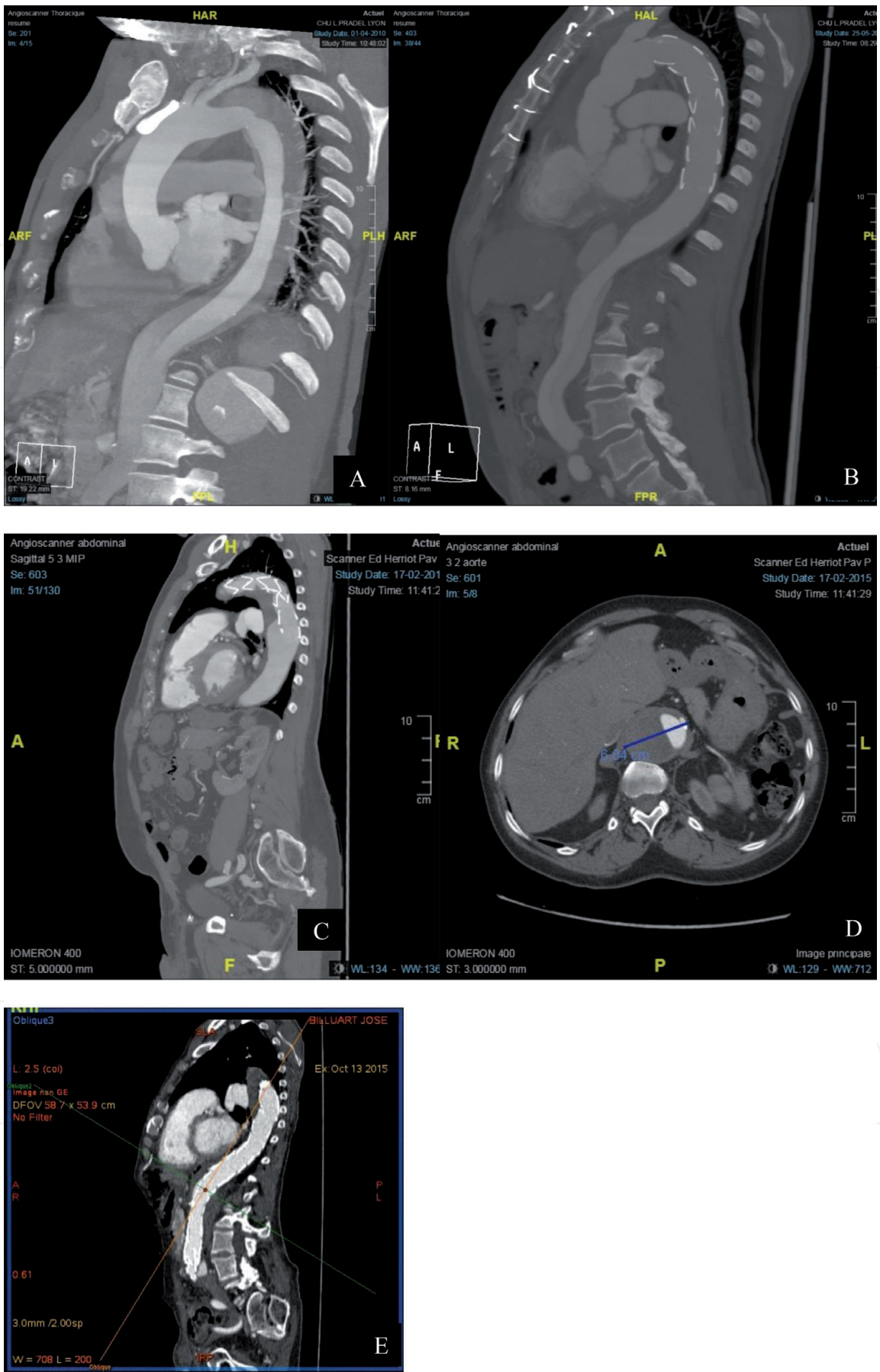


Figure 4. Aneurysmal evolution after frozen elephant trunk procedure. (A) Preoperative CT of a type A aortic dissection. (B) Postoperative CT after frozen elephant trunk implantation (E-vita open prosthesis). (C and D) 5 years postoperative. CT: Aneurysmal evolution on the descending aorta at the thoraco abdominal junction despite the thrombosis of the false lumen at the thoracic stage. (E) CT post fenestrated aortic stent graft implantation.

thrombosis induces inflammatory reaction inside the aortic wall. This inflammation is problematic; indeed, several studies have demonstrated the role of this inflammatory state in aneurysm progression, particularly through the production of metalloproteases and proinflammatory cytokines [37], these two elements leading to neo-angiogenesis and destruction of the extracellular matrix in the aortic wall. At the abdominal level, aortic aneurysm is frequently observed after hybrid surgery of dissected thoracic aorta (**Figure 4**). Several factors explain this evolution: a patent false lumen at this level, the modification of the aortic wall shear stress, the creation of a helicoidal flow downstream the endoprosthesis [38] (**Figure 5**).

To prevent this complication, Matalanis [39] proposes to perform a total aortic repair combining surgical ascending aorta repair and endovascular treatment of the descending aorta. This last treatment includes the deployment of a covered stent graft in the proximal part of descending aorta and rupture of the intimal flap for the last part of the aorta (Sabilize approach). This rupture is performed through the deployment and the dilatation under balloon of uncovered stent graft. Thus, a unique aortic channel is created, avoiding aneurysmal evolution of the false channel. Even if this technique seems appealing, reservations with regards persist. Indeed, according to Matalanis study, this technique provides specific complications such as additional visceral stenting (40% of cases), iliac stenting (20% of cases), and reintervention for endoleak (20% of cases). Moreover, only 53% had a complete false lumen thrombosis. Finally, as yet there is no long-term follow-up concerning the aortic dimension (median follow-up: 26 month) [40].

As we see, if surgical solutions exist, the prevention of aneurysm formation in the descending thoracic aorta using hybrid surgery is still discussed. Thus, the European Association for Cardio-Thoracic surgery expresses only a class IIb recommendation with a C level of evidence for this indication.

In this context, this surgery must be provided to selected patients. In order to identify which patients should be considered for a frozen elephant trunk implantation, several studies have searched for risk factor of aneurysm formation after TAAD [41, 42]. In 2003, Yeh from a series of 144 patients operated for TAAD

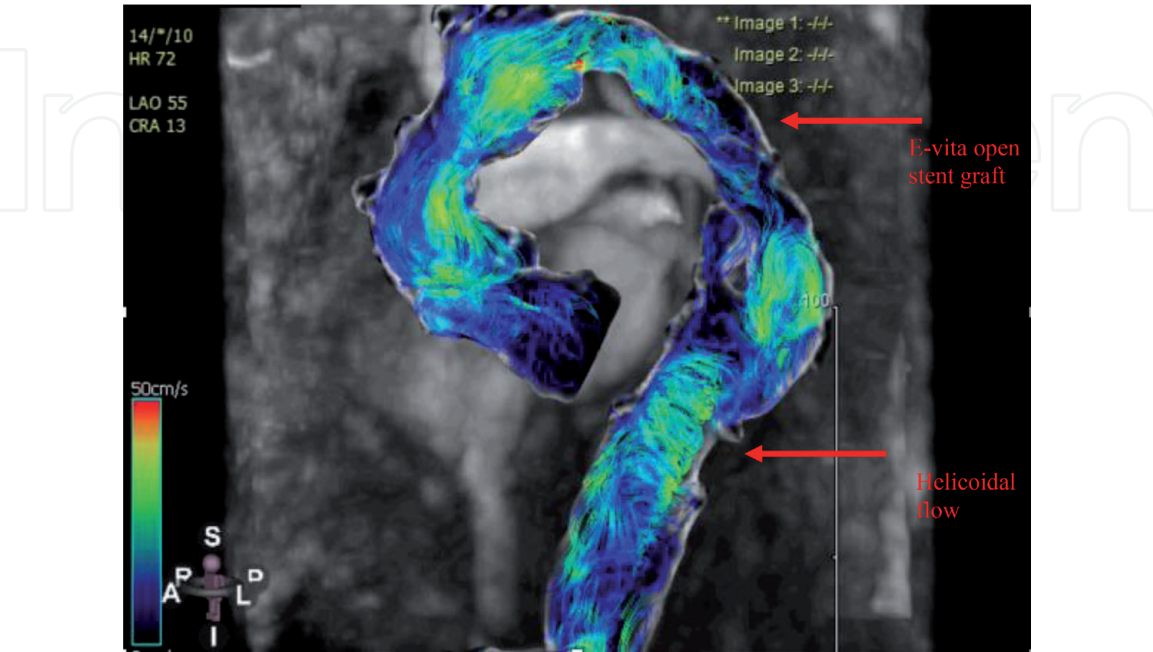


Figure 5.
4D phase-contrast MRI after treatment of a type A aortic dissection by frozen elephant trunk.

with a 3 years follow-up showed that preoperative isthmic diameter enlargement (OR = 1.11, $P = 0.0025$) and patent false lumen (OR = 13.28, $P = 0.002$) were risk factors for aneurysmal evolution [28]. Kirsch, with a longer follow-up, found a $56.1 \pm 9.4\%$ rate of reinterventions at 15 years. About 84.2% of these reinterventions were the consequence of aneurysmal evolution. After multivariate analysis, risk factors appeared to be youth, recent intervention, and type 1 dissection. Finally, the literature analysis identifies patent false lumen, preoperative isthmus diameter enlargement, preoperative descending thoracic aorta diameter enlargement over 40 mm, and long-term uncontrolled blood pressure as risk factors for descending thoracic aorta aneurysm.

Performing a descending thoracic aorta treatment by hybrid approach at the initial phase, in selected patient, could be a solution for reduction of excess mortality and morbidity of this population. Thus, patients presenting a TAAD with a descending thoracic aorta diameter superior to 40 mm could benefit from a hybrid treatment of this aortic segment.

Finally, in case of chronic dissection with aneurismal evolution reaching both ascending and thoracic descending aorta, two techniques can be discussed: a two-stage technique combining surgery on the ascending aorta via sternotomy and endovascular treatment of the descending aorta or a one-stage technique via bilateral thoracotomy (clamshell incision), with right subclavian and femoral perfusions and deep hypothermic circulatory arrest, allowing the replacement of the ascending, arch and descending aorta at different levels as described by Kouchoukos [43]. This last procedure provides low complications rates (mortality: 2.5%, reoperation for bleeding: 7.5%, neurological event: 2.4%) and a freedom from reoperation rate at 10 years equal to 84.4%.

It is important to remind that this preventive treatment has to be integrated in a global management, involving medical and surgical care, including genetic screening and strict blood pressure control. Eggebrecht demonstrated that a large part of patients with aortic dissection history (40%) had resistant hypertension despite multiple drug therapy [44], especially when patients were young and obese. These results underline the necessity to refer these patients to specialists in hypertension. Furthermore, the large number of loss of view in series [19] demonstrates that TAAD is still considered merely as an acute disease. This vision is mistaken: aortic dissection is a chronic disease, beginning in an acute way, reaching the entire aorta and requiring medical and surgical long-term follow-up.

Visualization of the aortic flow through the streamline technique: Presence of a helicoidal flow downstream the endoprosthesis.

- The surgeon's experience

The surgeon's experience is a key element of the surgical management. TAAD is a challenging pathology requiring complex surgical techniques such as aortic valve sparing and frozen elephant trunk implantation. If the operator is not familiar with aortic valve sparing repair, it is suitable to perform a Bentall intervention instead. In the same idea, performing an arch replacement followed by an endoprosthesis implantation in the descending aorta can be preferred to a frozen elephant trunk approach.

3.3 Type B aortic dissection with arch extension

Type B aortic dissection (TBAD) with retrograde arch extension occurs in 25% of cases of TBAD [45]. However, even if this situation is not rare, there are no recommendations concerning the management of this case.

Tsai [46] analyzed the International Registry of Acute Dissection Database. He found that patients with TBAD and arch extension received the same treatment than pure TBAD: medical treatment when there was no complication and endovascular or surgical treatment in case of complication. Open surgery on the aortic arch was performed in case of complication related with arch pathology: aortic arch expansion, aortic arch rupture, or malperfusion in the arch vessels. In comparison with TBAD without arch extension, mortality rates between the two groups were similar (short-term: $P = 0.61$, long-term: $P = 0.82$).

When surgery on the aortic arch is necessary, total arch replacement with frozen elephant trunk seems to be the best option. Indeed, this technique enables the aortic arch to be replaced and the primary tear to be closed when it is situated in the proximal part of the thoracic descending aorta. Moreover, an endoprosthesis can be deployed in a second time if the primary tear is not occluded by the frozen elephant trunk.

Finally, TBAD with arch extension should be treated as TBAD. Aortic arch replacement combined with frozen elephant trunk should be performed in case of complication related with an arch pathology.

4. Conclusion


TAAD is a serious condition requiring emergency surgical treatment. If saving the patient remains the main objective of the surgery, long-term follow-up leads us to improve initial surgical treatment, mainly to prevent long-term aneurysmal evolution, either on the aortic root or on the descending thoracic aorta. Concerning the proximal segment, guidelines are clear: aortic root has to be replaced if the sinuses of Valsalva are involved by the dissection. Concerning the descending thoracic aorta, there is still no consensus, but studies show that hybrid surgery should be performed in case of malperfusion syndrome and when patients presents high risk factors for aneurysmal evolution.

Author details

Benoit Cosset, Sarah Abdellaoui, Hugo Huvelle, Amine Fikani and Fadi Farhat*
Department of Cardiovascular Surgery B, Hospital Louis Pradel, Hospices Civils de Lyon, Université Lyon 1, Lyon, France

*Address all correspondence to: fadi.farhat@chu-lyon.fr

IntechOpen

© 2019 The Author(s). Licensee IntechOpen. This chapter is distributed under the terms of the Creative Commons Attribution License (<http://creativecommons.org/licenses/by/3.0>), which permits unrestricted use, distribution, and reproduction in any medium, provided the original work is properly cited. 

References

- [1] Trimarchi S, Eagle KA, Nienaber CA, Rampoldi V, Jonker FHW, De Vincentiis C, et al. Role of age in acute type A aortic dissection outcome: Report from the international registry of acute aortic dissection (IRAD). *The Journal of Thoracic and Cardiovascular Surgery*. 2010;**140**:784-789
- [2] Berretta P, Patel H, Gleason T, Sundt M, Myrmel T, Desai N, et al. IRAD experience on surgical type A acute dissection patients: Results and predictors of mortality. *Annals of Cardiothoracic Surgery*. 2016;**5**:346-351
- [3] Chiappini B, Schepens M, Tan E, Dell'Amore A, Morshuis W, Dossche K, et al. Early and late outcomes of acute type A aortic dissection: Analysis of risk factors in 487 consecutive patients. *European Heart Journal*. 2005;**26**:180-186
- [4] Jex RK, Schaff HV, Piehler JM, Orszulak TA, Puga FJ, King RM, et al. Repair of ascending aortic dissection. Influence of associated aortic valve insufficiency on early and late results. *The Journal of Thoracic and Cardiovascular Surgery*. 1987;**93**:375-384
- [5] Erbel R, Oelert H, Meyer J, Puth M, Mohr-Katoly S, Hausmann D, et al. Effect of medical and surgical therapy on aortic dissection evaluated by transesophageal echocardiography. Implications for prognosis and therapy. The European Cooperative Study Group on Echocardiography. *Circulation*. 1993;**87**:1604-1615
- [6] Tsukube T, Hayashi T, Kawahira T, Haraguchi T, Matsukawa R, Kozawa S, et al. Neurological outcomes after immediate aortic repair for acute type A aortic dissection complicated by coma. *Circulation*. 2011;**124** (11 Suppl):S163-S167
- [7] Pocar M, Passolunghi D, Moneta A, Mattioli R, Donatelli F. Coma might not preclude emergency operation in acute aortic dissection. *The Annals of Thoracic Surgery*. 2006;**81**(4):1348-1351
- [8] Estrera AL, Garami Z, Miller CC, Porat EE, Achouh PE, Dhareshwar J, et al. Acute type A aortic dissection complicated by stroke: Can immediate repair be performed safely? *The Journal of Thoracic and Cardiovascular Surgery*. 2006;**132**(6):1404-1408
- [9] Sabik JF, Lytle BW, Blackstone EH, McCarthy PM, Loop FD, Cosgrove DM. Long-term effectiveness of operations for ascending aortic dissections. *The Journal of Thoracic and Cardiovascular Surgery*. 2000;**119**:946-962
- [10] Castrovinci S, Pacini D, Di Marco L, Berretta P, Cefarelli M, Murana G, et al. Surgical management of aortic root in type A acute aortic dissection: A propensity-score analysis. *European Journal of Cardio-Thoracic Surgery*. 2016;**50**:223-229
- [11] Kirsch M, Soustelle C, Houel R, Hillion ML, Loisan D. Risk factor analysis for proximal and distal reoperations after surgery for acute type A aortic dissection. *The Journal of Thoracic and Cardiovascular Surgery*. 2002;**123**:318-325
- [12] Tanaka M, Kimura N, Yamaguchi A, Adachi H. In-hospital and long-term results of surgery for acute type A aortic dissection: 243 consecutive patients. *Annals of Thoracic and Cardiovascular Surgery*. 2012;**18**:18-23
- [13] Westaby S, Saito S, Katsumata T. Acute type A dissection: Conservative methods provide consistently low mortality. *The Annals of Thoracic Surgery*. 2002;**73**:707-713

- [14] Di Eusanio M, Trimarchi S, Peterson MD, et al. Root replacement surgery versus more conservative management during type A acute aortic dissection repair. *The Annals of Thoracic Surgery*. 2014;**98**:2078-2084
- [15] Erbel R, Aboyans V, Boileau C, Bossone E, Di Bartolomeo R, Aggebrecht H, et al. 2014 guidelines on the diagnosis and treatment of aortic diseases. *European Heart Journal*. 2014;**35**:2873-2926
- [16] Farhat F, Bejan-Angoulvant T, Abdallah H, Jegaden O. Reimplantation valve sparing procedure in type A aortic dissection: A predictive factor of mortality and morbidity? In: Grundmann R, editor. *Diagnosis and Treatment of Abdominal and Thoracic Aortic Aneurysms Including the Ascending Aorta and the Aortic Arch*. Rijeka, Croatia: IntechOpen; 2011
- [17] Leyh RG, Fischer S, Kallenbach K, Kofidis T, Pethig K, Harringer W, et al. High failure rate after valve-sparing aortic root replacement using the “remodeling technique” in acute type A aortic dissection. *Circulation*. 2002;**106**(12 Suppl 1):I229-I233
- [18] El-Sayed Ahmad A, Papadopoulos N, Risteski P, Moritz A, Zierer A. The standardized concept of moderate-to-mild ($\geq 28^{\circ}\text{C}$) systemic hypothermia during selective antegrade cerebral perfusion for all-comers in aortic arch surgery: Single-center experience in 587 consecutive patients over a 15-year period. *The Annals of Thoracic Surgery*. 2017;**104**(1):49-55
- [19] Bachet J, Goudot B, Dreyfus G. Surgery for acute type A aortic dissection: The Hopital Foch experience (1977-1998). *The Annals of Thoracic Surgery*. 1999;**67**:2006-2009
- [20] Easo J, Weigang E, Hölzl PPF, Horst M, Hoffmann I, Blettner M, et al. Influence of operative strategy for the aortic arch in DeBakey type I aortic dissection: Analysis of the German registry for acute aortic dissection type a. *The Journal of Thoracic and Cardiovascular Surgery*. 2012;**144**:617-623
- [21] Svensson LG, Kouchoukos NT, Miller DC, Bavaria JE, Coselli JS, Curi MA, et al. Expert consensus document on the treatment of descending thoracic aortic disease using endovascular stent-grafts. Society of Thoracic Surgeons endovascular surgery task force. *The Annals of Thoracic Surgery* 2008;**85**(1 Suppl):S1-41
- [22] Di Eusanio M, Berretta P, Cefarelli M, Jacopo A, Murana G, Castrovinci S, et al. Total arch replacement versus more conservative management in type A acute aortic dissection. *The Annals of Thoracic Surgery*. 2015;**100**(1):88-94
- [23] Li B, Ma W-G, Liu Y-M, Sun L-Z. Is extended arch replacement justified for acute type A aortic dissection? *Interactive Cardiovascular and Thoracic Surgery*. 2015;**20**(1):120-126
- [24] Yamashiro S, Arakaki R, Kise Y, Inafuku H, Kuniyoshi Y. Management of visceral malperfusion complicated with acute type A aortic dissection. *Interactive Cardiovascular and Thoracic Surgery*. 2015;**21**(3):346-351
- [25] Kamman AV, Yang B, Kim KM, Williams DM, Michael Deeb G, Patel HJ. Visceral malperfusion in aortic dissection: The michigan experience. *Seminars in Thoracic and Cardiovascular Surgery*. 2017;**29**(2):173-178
- [26] Di Eusanio M, Trimarchi S, Patel HJ, Hutchison S, Suzuki T, Peterson MD, et al. Clinical presentation, management, and short-term outcome of patients with type A acute dissection complicated by mesenteric malperfusion: Observations from

the international registry of acute aortic dissection. *The Journal of Thoracic and Cardiovascular Surgery*. 2013;**145**(2):385-390.e1

[27] Patel HJ, Williams DM, Dasika NL, Suzuki Y, Deeb GM. Operative delay for peripheral malperfusion syndrome in acute type A aortic dissection: A long-term analysis. *The Journal of Thoracic and Cardiovascular Surgery*. 2008;**135**(6):1288-1295-1296

[28] Geirsson A, Szeto WY, Pochettino A, McGarvey ML, Keane MG, Woo YJ, et al. Significance of malperfusion syndromes prior to contemporary surgical repair for acute type A dissection: Outcomes and need for additional revascularizations. *European Journal of Cardio-Thoracic Surgery*. 2007;**32**(2):255-262

[29] Charlton-Ouw KM, Sandhu HK, Leake SS, Jeffress K, Miller CC, Durham CA, et al. Need for limb revascularization in patients with acute aortic dissection is associated with mesenteric ischemia. *Annals of Vascular Surgery*. 2016;**36**:112-120

[30] Takagi H, Umemoto T, the ALICE Group. A meta-analysis of total arch replacement with frozen elephant trunk in acute type A aortic dissection. *Vascular and Endovascular Surgery*. 2016;**50**:33-46

[31] Shrestha M, Bachet J, Bavaria J, Carrel TP, De Paulis R, Di Bartolomeo R, et al. Current status and recommendations for use of the frozen elephant trunk technique: A position paper by the vascular domain of EACTS. *European Journal of Cardio-Thoracic Surgery*. 2015;**47**:759-769

[32] Uchida N, Shibamura H, Katayama A, Shimada N, Sutoh M, Ishihara H. Operative strategy for acute type A aortic dissection: Ascending aortic or hemiarch versus total arch replacement with frozen elephant

trunk. *The Annals of Thoracic Surgery*. 2009;**87**:773-777

[33] Yan Y, Xu L, Zhang H, Xu ZY, Ding XY, Wang SW, et al. Proximal aortic repair versus extensive aortic repair in the treatment of acute type A aortic dissection: A meta-analysis. *European Journal of Cardio-Thoracic Surgery*. 2016;**49**:1392-1401

[34] Abraha I, Romagnoli C, Montedori A, Cirocchi R. Thoracic stent graft versus surgery for thoracic aneurysm. *Cochrane Database of Systematic Reviews*. 2016;**6**:CD006796

[35] Svensson LG, Kouchoukos NT, Miller DC, Bavaria JE, Coselli JS, Curi MA, et al. Expert consensus document on the treatment of descending thoracic aortic disease using endovascular stent-grafts. *The Annals of Thoracic Surgery*. 2008;**85**:S1-S41

[36] Kimura N, Itoh S, Yuri K, Adachi K, Matsumoto H, Yamaguchi A, et al. Reoperation for enlargement of the distal aorta after initial surgery for acute type A aortic dissection. *The Journal of Thoracic and Cardiovascular Surgery*. 2015;**149**(2 Suppl):S91-S98

[37] Cifani N, Proietta M, Tritapepe L, Di Gioia C, Ferri L, Taurino M, et al. Stanford-a acute aortic dissection, inflammation, and metalloproteinases: A review. *Annals of Medicine*. 2015;**47**:441-446

[38] Clough RE, Waltham M, Giese D, Taylor PR, Schaeffer T. A new imaging method for assessment of aortic dissection using four-dimensional phase contrast magnetic resonance imaging. *Journal of Vascular Surgery*. 2012;**55**:914-923

[39] Matalanis G, Ip S. A new paradigm in the management of acute type A aortic dissection: Total aortic repair. *The Journal of Thoracic and Cardiovascular Surgery*. 2019;**157**(1):3-11

[40] Girardi LN. Is a more extensive operation justified for acute type A dissection repair? *The Journal of Thoracic and Cardiovascular Surgery*. 2019;**157**(1):12-13

[41] Almeida AG, Nobre AL, Pereira RA, Costa-Pereira A, Tavares C, Cravino J, et al. Impact of aortic dimensions and pulse pressure on late aneurysm formation in operated type A aortic dissection. A magnetic resonance imaging study. *The International Journal of Cardiovascular Imaging*. 2008;**24**:633-640

[42] Yeh C-H, Chen M-C, Wu Y-C, Wang Y-C, Chu J-J, Lin PJ. Risk factors for descending aortic aneurysm formation in medium-term follow-up of patients with type A aortic dissection. *Chest*. 2003;**124**:989-995

[43] Kouchoukos NT, Kulik A, Castner CF. Clinical outcomes and rates of aortic growth and reoperation after 1-stage repair of extensive chronic thoracic aortic dissection. *The Journal of Thoracic and Cardiovascular Surgery*. 2018;**155**(5):1926-1935

[44] Eggebrecht H, Schmermund A, von Birgelen C, Naber CK, Bartel T, Wenzel RR, Erbel R. Resistant hypertension in patients with chronic aortic dissection. *Journal of Human Hypertension*. 2005;**19**:227-231

[45] Estrera AL, Miller CC, Safi HJ, Goodrick JS, Keyhani A, Porat EE, et al. Outcomes of medical management of acute type B aortic dissection. *Circulation*. 2006;**114**(1 Suppl):I384-I389

[46] Tsai TT, Isselbacher EM, Trimarchi S, Bossone E, Pape L, Januzzi JL, et al. Acute type B aortic dissection: Does aortic arch involvement affect management and outcomes? Insights from the international registry of acute aortic dissection (IRAD). *Circulation*. 2007;**116**(11 Suppl):I150-I156