

We are IntechOpen, the world's leading publisher of Open Access books Built by scientists, for scientists

6,900

Open access books available

185,000

International authors and editors

200M

Downloads

Our authors are among the

154

Countries delivered to

TOP 1%

most cited scientists

12.2%

Contributors from top 500 universities



WEB OF SCIENCE™

Selection of our books indexed in the Book Citation Index
in Web of Science™ Core Collection (BKCI)

Interested in publishing with us?
Contact book.department@intechopen.com

Numbers displayed above are based on latest data collected.
For more information visit www.intechopen.com



Early Postoperative Monitoring of the Liver Graft

*Demetrio V. Pérez Civantos, Alicia Muñoz Cantero,
Manuel Robles Marcos, Francisco Fuentes Morillas,
María A. Santiago Triviño, María O. Cerezo Arias,
María D. Pérez Frutos and Alberto Córdoba López*

Abstract

Liver transplantation (LT) is a common current technique for end-stage liver disease. Complications after the surgical procedure, though uncommon, can be of very different origin and can also be severe enough to lead to liver and multiorgan failure and finally graft loss and/or recipient's death. Intensivists and the surgical team must be familiarized with these early complications to detect them as soon as possible in order to use the best diagnostic tools and take the best therapeutic measures to restore anatomical integrity and organ function to optimize the liver graft. In this chapter, we present an updated state of the art for efficiently tackling with all different, most usual complications that an LT patient can present during early postoperative period.

Keywords: liver transplantation, liver graft dysfunction, liver posttransplant complications, liver function monitoring, posttransplant critical care

1. Introduction

Liver transplantation (LT) is the only therapy for end-stage liver disease. It has become a common surgical procedure. The postoperative severe complications may compromise both patient's graft and life survival, so an early suspicion, detection, and therapeutic solution are the only way to change the threatening of post-LT complications.

The need of allografts has largely extended the set of criteria (ECD) for organ acceptability, increasing the risk of complications and adverse outcomes [1, 2].

Little is known about the parameters that can alert of early complications of liver graft function, need of retransplantation, vascular complications, reinterventions, and long intensive care stay.

Hereby we present the state of the art on the early detection and management of the most frequently complications found during the postoperative period of liver transplantation in the intensive care unit (ICU). We discuss the management of clinical, laboratory, and ancillary tests' findings that can help medical and surgical staff to tackle and take decisions when suspecting early hepatic graft malfunctioning. Early diagnosis could allow medical and surgical teams to take most difficult decisions to salvage the graft and to restore severe deteriorated patient's health condition.

Laboratory tests as well as scores (model for end-stage liver disease, MELD; acute physiology and chronic health evaluation, APACHE II; sequential organ failure assessment, SOFA; and model of early allograft function, MEAF) have good performance but can only do a late evaluation of patient status and graft function. The indocyanine green plasma disappearance rate is an interesting liver function test but produces some ambiguous results during the first days after transplantation. The liver maximal function capacity test is a novel and promising method for evaluating metabolic liver activity, but its use is limited for economic reasons and extrahepatic factors.

Recently somatic near-infrared spectroscopy of liver graft (LSrO₂) has shown to be helpful to early monitor vascular graft supply after LT [3].

2. Vascular complications of the liver graft

Vascular complications after LT though seldom found are dreaded ones, as they carry high incidence of both loss of the graft and patient morbimortality [1].

Complications that affect the hepatic artery (HA) after LT can lead to ischemia of the liver graft which can result in graft morbidity, loss, or even patient death. The clinical feature of these complications varies and depends on the type (thrombosis or stenosis) and timing (early or late presentation) and the promptness of diagnosis [4–10]. Despite continuous improvements of the surgical technique, these complications represent one of the main causes of the failure of LT, with an incidence ranging from 2.6 to 20% in adult recipients [4–10].

2.1 Early monitoring of vascular graft supply and vascular complications

As it is hard to establish an effective screening of the risk of each patient undergoing LT, it is of paramount importance to bear in mind the possibility of early appearance as most studies and clinical experience have failed to demonstrate clear risk factors [4–12].

At the ICU it is difficult to monitor early graft vascular supply. Duplex ultrasound (DUS) is the usual tool used for this purpose, but it only provides information at a given point of time of the study but no continuous information.

Adequate perfusion and oxygenation to liver graft after transplantation are essential for its viability. LSrO₂ through near-infrared spectroscopy (NIRS) can help by showing real-time oxygen content of the graft. Recently, our group carried out a study on post-LT patients for evaluating the efficacy of NIRS on detecting early vascular graft complications [12, 13]. Impairment of the liver graft microcirculation and tissue hypoxia are both a common pathology in all these complications with eventual loss of the graft without early intervention [14]. Early detection of this impairment could reduce the overall morbidity and mortality of LT by allowing earlier treatment. Measurement of hepatic LSrO₂ has been shown to correlate significantly with the microcirculatory impairment and liver dysfunction induced by ischemia and reperfusion injury [12, 15].

The mean initial value of LSrO₂ that our group observed was 74 (SD 5.7) with a tendency of a slight progressively increment along the following hours, showing a mean value of 76 (SD 4.1) at hour 24. When studying correlation of LSrO₂, relevant and significant findings at hour 3 were found between this parameter and hemoglobin (Hb) ($p = .004$), as well as with cardiac index (CI) ($p = .044$). It was also found with the Apache II scale ($p = .041$) but not with SOFA ($p = .069$).

At hour 24, we also found significant correlation between LSrO₂ and Hb ($p = .002$). No correlation was met with lactate at any moment (hour 1, hour 8, and hour 24) of the study ($p = .113$, $p = .293$, and $p = .141$, respectively).

Importantly, neither at the beginning nor at the end of the study was there a correlation observed between LSrO₂ and liver biochemistry.

Finally, among hemodynamic parameters, a correlation was encountered between LSrO₂ and CI at hour 3 ($p = .044$). DUS data expressed as resistive index and pulsatility index (RI and PI) did not correlate with LSrO₂ at hour 24 ($p = .738$ and $p = .799$, respectively). We could not also find any statistical connection between LSrO₂ and cold-warm ischemia time and at arrival after 24 hours ($p = .780$ and $p = .951$).

LSrO₂ could early detect all severe vascular complications and all events that led to a decrease in blood or oxygenation supply to the liver graft, permitting to advance in taking diagnostic and therapeutic measures.

LSrO₂ is a new monitoring tool that brings valuable information about hepatic flow and oxygenation early after liver transplant that deserves to be weighed.

2.1.1 Arterial complications

2.1.1.1 HAT

Hepatic artery thrombosis (HAT) [16] differs depending on time of presentation, usually ranging from 1 to 28 days (mean 7.4 days) [4].

HAT represents the most common vascular complication, accounting for more than 50% of all vascular complications [13]. Late reports show a lower HAT incidence, ranging from 1 to 25% [13, 17, 18]. It is the first cause of non-function of the graft [13].

The clinical presentation of HAT ranges from a mild elevation of liver function tests (LFT) and bilirubin levels in 75% of patients to fulminant hepatic necrosis. Other symptoms vary from biliary complications in 15%, fever and sepsis in 6%, and graft dysfunction or failure in 4% [13]. The clinical expression depends on the timing and the existence of collaterals. Early HAT is mostly expressed as a non-functioning graft, and late HAT is associated with biliary tract complications (bile duct strictures and/or biliary leaks).

Early HAT usually is manifested with fever, increased leukocytosis, and important elevation in liver enzyme levels. The natural history of early HAT can be summarized as biliary tract necrosis followed by uncontrolled septic shock in the immunosuppressed population and even the patient's death [6, 13, 19–22]. The cause of early HAT is still under debate and remains unknown [6, 19, 21–23]. Up to 20% of HAT cases are due to surgical causes [6, 19, 21–23].

Early diagnosis is mandatory to allow immediate treatment. Elevation of transaminase levels, LSrO₂ monitoring [3] showing a $> 10\%$ reduction from basal data, duplex ultrasound (DUS will show absence of HA signal sensibility of 92%) and increased resistive index (RI). Visceral angiography will confirm the diagnosis [19, 22, 24].

Approximately 20% of them can be treated successfully with surgical revascularization with a Fogarty balloon-tip catheter and refashioning of the arterial anastomosis the very same day of diagnosis [4]. Percutaneous endovascular interventions including intra-arterial thrombolysis (IAT), percutaneous transluminal angioplasty (PTA), and stent placement have shown hopeful outcomes in the literature [13]. Anticoagulant or antiplatelet therapy is also advisable [13, 16]. Survival rates are 40% in symptomatic vs. 82% in asymptomatic patients [13]. Sylva et al. reported an overall mortality of 23% [20].

Different factors that cannot be involved in the appearance of HAT are etiology of recipient end-stage liver disease, previous LT, donor sex and age, cause of donor death, recipient sex and age, type of preservation solution, cold ischemia time, experience of the surgeon, type of arterial anastomosis, intraoperative transfusion requirement of red blood cells and fresh frozen plasma, acute rejection, and CMV infection. Donor age of greater than 60 years and back-table artery reconstruction have been found significantly associated with this complication [4].

2.1.1.2 HAS

Hepatic artery stenosis (HAS) is not rarely found and its incidence ranges 2–13% [13, 16]. It is defined as a narrowing of the transverse diameter of the HA, resulting in ischemia mainly revealed by elevated liver function tests [13, 25–31]. Significant HAS is defined as a reduction of >50% on angiogram associated with a resistive index (RI) <0.5 and a peak systolic velocity >400 cm/s by Duplex ultrasound (DUS) [8, 13, 26, 32]. LScO₂ reduction of >10% from basal levels and maintained during first hours can alert of HAC [3]. HAS also carries a high rate in morbidity and mortality. It has been postulated that HAT and HAS are two contiguous components of the broader allotransplant ischemic complications [13, 25–28, 30–35].

2.1.1.3 HAP

Hepatic artery pseudoaneurysm (HAP) is defined as a dilated hepatic artery, which occurs after iatrogenic injury in most cases, causing blood leaking and pool outside the artery wall into surrounding tissue with a persistent communication between the HA and the adjacent cavity [13].

Volpin et al. [36] informed of an incidence of 2.5% and Boleslawski et al. of 0.64% [37].

The clinical presentation varies from an asymptomatic state to an incidental finding upon abdominal pain associated with fever and gastrointestinal bleeding (25%), massive bleeding through abdominal drain (31%), and hemorrhagic shock (81%).

Several predisposing factors have been suggested, including peritoneal infections, technical difficulties during anastomosis, and biliary leak [24, 27, 35–62]. The rate of microorganisms cultured from HAP is 50% and from abdominal fluid 31% [36]. Diagnosis of HAP is based on DUS, contrast-enhanced CT scan, or angiography [36]. Treatment is based on reoperation or interventional radiology [36, 37, 42, 45, 63]. Urgent ligation of HA has a mortality that ranges from 28 to 85% [36, 40, 41, 45]. Boleslawski et al. [37] reported good results with HA ligation without revascularization.

2.1.1.4 HAR

HAR is defined as a severe hemorrhage from the trunk or from the main branch of the HA. It is a very serious complication that results in the disruption of blood supply to the graft. This is an exceptional but dramatic complication that carries a very high rate incidence of graft loss and mortality.

In most cases, this condition complicates a pseudoaneurysm of the HA, leading to major bleeding that requires emergency operation. Many authors report the role of infectious pathogens as causative agents of pseudoaneurysms [13]. Diagnosis of HAP is available with different radiological techniques, but in half of cases, HAP is not recognized before rupture, requiring immediate surgery [37].

In case of rupture and acute bleeding, there are many therapeutic possibilities: endovascular intervention with embolization with or without stenting, surgical

intervention for anastomotic revision, aorto-hepatic grafting, HA ligation, or emergency retransplantation. Mortality remains very high, and no consensus exists about indication for the type of procedure [13, 37, 40, 45, 47, 64].

Boleslawski et al. [37] reported the largest series of ruptured posttransplant HAP and highlighted the efficacy of primary HA ligation with good (70–80%) early and late survival.

2.1.2 Venous complications

Compared to arterial complications, venous complications (VC) are less frequent, with an estimated overall incidence of <3% [65–72]. They can be potentially devastating, leading to graft failure and representing an important source of morbidity and mortality, especially if they occur in early period of post-LT [68, 71, 72].

Incidence is higher in pediatric population [68, 69, 73, 74].

The etiology of VC mostly involves venous anastomosis; those are portal, cava, and hepatic veins.

Portal vein complications (PVCs) are relative uncommon, occurring in 1–3% of LT [65–68, 70–72, 75]. These complications are related to high morbidity and graft loss [67, 68]. These complications are more common with split liver and living donor LT and in pediatric LT [72, 76].

Regarding PVCs we can make the diagnosis by DUS, contrast-enhanced ultrasound (CEUS), contrast-enhanced computed tomography (CECT), and magnetic resonance venography (MRV) [67, 68, 77]. Therapeutic management of PVCs ranges from endovascular procedures (as the first-line treatment) with highly successful results [50, 69, 74, 78] to surgical thrombectomy and anastomosis revision.

2.1.2.1 Portal vein thrombosis (PVT)

Incidence ranges from 0.3 to 2.6% [51, 71]. The clinical presentation depends on the time of thrombosis. Early thrombosis (<72 h) is presented as acute liver insufficiency or graft failure. If PVT occurs late (>day 30), clinical symptoms depend on the portocaval collateral circulation existence. Portal hypertension manifestations including upper gastrointestinal bleeding due to esophagogastric varices and ascites are the most frequent symptoms, and liver failure is rare [35, 71, 75]. PVC usually occurs during the first week after LT [27, 35, 52, 79]. The most common causes of PVT are technical errors related to venous redundancy, kinking, or stenosis of the anastomosis [71].

Therapeutic options for PVT range from systemic anticoagulation, catheter-based thrombolytic therapy via transjugular intrahepatic portosystemic shunt (TIPS), to surgical revision until retransplantation. The best three percutaneous options in literature are transhepatic vein angioplasty (with or without stent placement), percutaneous thrombolytic treatment via TIPS, and transsplenic approach [53, 54].

In clinical practice, the treatment depends on timing of appearance, if early liver failure or multiorgan failure appear, it compels surgical revision and if PVT is late to occur and no alteration in liver function test, observation, or medical treatment and complementary percutaneous treatment is required. If PVT is late in developing and with clinical manifestation of acute gastroesophageal bleeding or ascites, that will require percutaneous or TIPS procedures [55].

2.1.2.2 PVS

The true incidence of portal vein stenosis (PVS) is not known. The only data in literature concerning the incidence of venous complications is <3% [72].

When PVS is diagnosed, it can be present with acute graft failure or portal hypertension [56]. In practice the vast majority of patients are asymptomatic, and the finding is incidental on routine scanning ultrasound. In the case of symptomatic PVS, clinical signs will be those of portal hypertension as gastrointestinal bleeding due to gastroesophageal varices, ascites, and splenomegaly. Abnormal liver function tests are not constant.

Risk factor for developing PVS is the same as for PVT. The significant size mismatch is likely a cause of developing a stenosis [72].

DUS is the first tool for PVS diagnosis; it is highly sensitive but not specific. Some authors as Wei et al. [57] consider a pre- and post-stenosis gradient of >5 as compatible with PVS. Other authors prefer to rely on portal caliper diameter, and a reduction of $>75\%$ is suggestive [58].

In case there are no important clinical signs, the patient may be solely observed. If clinical picture is progressively deteriorating, a therapeutic access as transhepatic approach or transjugular access [58] must be done. A single balloon dilatation is sufficient to maintain patency in 77.7% of patients. In selected cases, a stent can be placed to prevent recurrence [59]. The use of three anticoagulant therapies (low-molecular-weight heparin, warfarin, and aspirin) may reduce the recurrence of thrombosis [60].

2.1.2.3 CVC

Caval vein complications (CVC) are extremely infrequent. They can be due to kinking, stenosis, or thrombosis and clinically appear as lower limb edema, ascites, pleural effusion, Budd-Chiari syndrome, and liver or renal failure [61, 65, 70].

Technical errors are the leading cause of CVC. Diagnosis should be made by DUS, contrast-enhanced CT, or cavography. Percutaneous radiological interventions are the methods of choice for therapeutical approach [59, 62, 80–83].

3. Biliary complications after liver transplantation

The most frequent and important causes of morbidity and mortality in LT recipients are stenosis, biliary leaks, and stones. The estimated incidence is 10–25% [84]. Most can be managed successfully with endoscopic retrograde cholangiography (ERC).

3.1 Types of complications

Biliary complications (stenosis, leaks, and stones) after LT can be classified as early (within 4 weeks) or late. Biliary strictures can be further divided into intrahepatic anastomotic stenoses, not anastomotic and diffuse stenoses. Other complications, such as bile emptying, Oddi sphincter dysfunction, mucocele, and hemobilia, are rare (Table 1).

3.2 Risk factors

There are several risk factors for development of biliary complications after LT (Table 2):

- Type of biliary reconstruction: ductal choledochocholedochostomy versus choledochojejunostomy in Roux-en-Y; the complication rate is similar [85].
- Routine tube placement in T: it is associated with a higher incidence of biliary complications, such as stenosis, biliary leaks, and cholangitis [86].

Bile leaks and biloma
Strictures
Anastomotic
Nonanastomotic
Diffuse intrahepatic
Common bile duct filling defects
Stones
Sludge
Casts
Sphincter of Oddi dysfunction
Other complications
Hemobilia
Mucocele
Bactobilia

Table 1.
Biliary complications after liver transplantation.

Roux-en-Y anastomosis
Use of T-tubes
Improper surgical technique
Inappropriate suture material or excessive tension at the anastomosis
Excessive use of electrocauterization for control of bile duct bleeding
Mismatch in size between donor and recipient bile ducts
ABO mismatched grafts
Acute hepatic artery thrombosis
Hepatic artery stenosis
Ischemia/reperfusion injury (ischemic-type biliary lesions)
Infections
Non heart-beating donors
Primary sclerosing cholangitis

Table 2.
Risk factors for the development of biliary complications after liver transplantation.

- Other risk factors (especially stenosis): acute thrombosis of the hepatic artery, stenosis of the hepatic artery, biliary leak, technical factors during surgery (excessive dissection of the periductal tissue during acquisition, excessive use of electrocautery for the control of bile duct bleeding) both in the donor and the recipient, the tension of the anastomosis, small caliber of the bile duct and the size of the donor and recipient not matching, ischemia injury/reperfusion, pre-LT diagnosis of cytomegalovirus infection, donation after cardiac death, ABO blood mismatch in the group, increased donor age, prolonged periods of cold and warm ischemia, and primary sclerosing cholangitis (Table 2) [85].

3.3 Diagnostic approach

In asymptomatic LT recipients that have elevations in serum levels of amino-transferases, bilirubin, alkaline phosphatase, and/or gamma-glutamyl transferase. Occasionally, they have nonspecific symptoms (fever and anorexia), abdominal

pain in the right upper quadrant (especially with biliary leaks), pruritus, jaundice, and biliary ascites. However, pain may be absent due to immunosuppression and hepatic denervation [85].

The initial evaluation should include hepatic ultrasound (US) with Doppler of the hepatic vessels (**Figure 1**). If US Doppler suspects stenosis or occlusion of the hepatic artery, a computed tomographic (CT) angiogram should be obtained or a liver angiogram should be performed.

Liver biopsy is performed to exclude rejection, although it is usually deferred in patients with bile dilation and/or the presence of stones in the common bile duct due to the risk of causing a bile leak [87].

The abdominal US may not be sensitive enough (sensitivity 38–66%) to detect biliary obstruction [88]. Therefore, an additional evaluation with more sensitive techniques is recommended in patients with clinical suspicion.

If there is a strong clinical suspicion and US that indicates an obstruction of the bile duct with or without stones or a bile leak, cholangiography should be obtained [85]. Although ERC or percutaneous transhepatic cholangiography (PTC) remains the gold standard, magnetic resonance cholangiopancreatography (MRCP) is a reliable technique (96% sensitivity and 94% specificity) [89]. Currently, MRCP is considered an optimal noninvasive diagnostic tool for the evaluation of biliary complications after TL, if the abdominal US is normal and there is a high suspicion of a biliary complication [89].

ERC is perhaps the best diagnostic/therapeutic intervention in patients with conduit-to-conduit anastomosis. We reserved PTC for patients in whom ERC was not successful and in patients with Roux-en-Y choledochojejunostomy [90].

3.4 Stenosis

The incidence ranges from 4 to 16% [85]. Stenoses that occur early after TL are due to technical problems, while late stenoses are due to vascular insufficiency and scarring and fibrosis problems. Bile leakage is an independent risk factor for the development of anastomotic stenoses. Stenoses were more common with reconstruction with Roux-en-Y choledochojejunostomy.

They are classified as anastomotic or non-anastomotic, according to the place.

3.4.1 Anastomotic stenosis (AS)

It occurs within the first 12 months after LT. It has a good response to short-term stenting (3–6 months). However, patients require long-term surveillance, since the restrictions are often repeated.

The cholangiographic appearance characteristic of an AS is that of a narrowing of the area of the biliary anastomosis. In some patients, it may manifest itself in the first or second month after TL due to postoperative edema and inflammation [85]. This type responds to endoscopic balloon dilation and placement of the plastic stent; in most patients, it will be resolved in 3 months. The majority of patients with AS require continuous ERC (every 3 months) with balloon dilation and long-term stenting (12–24 months). Due to the high success rates, we suggest that endoscopic management be considered.

There is growing experience in the temporary placement (3–12 months) of self-expanding metal stents (cSEMS) covered to reduce the need for repeated stent exchanges [91]. There is insufficient data to support the systematic use, but the cSEMS may be beneficial in patients who fail therapy with plastic stents and dilatation [91].

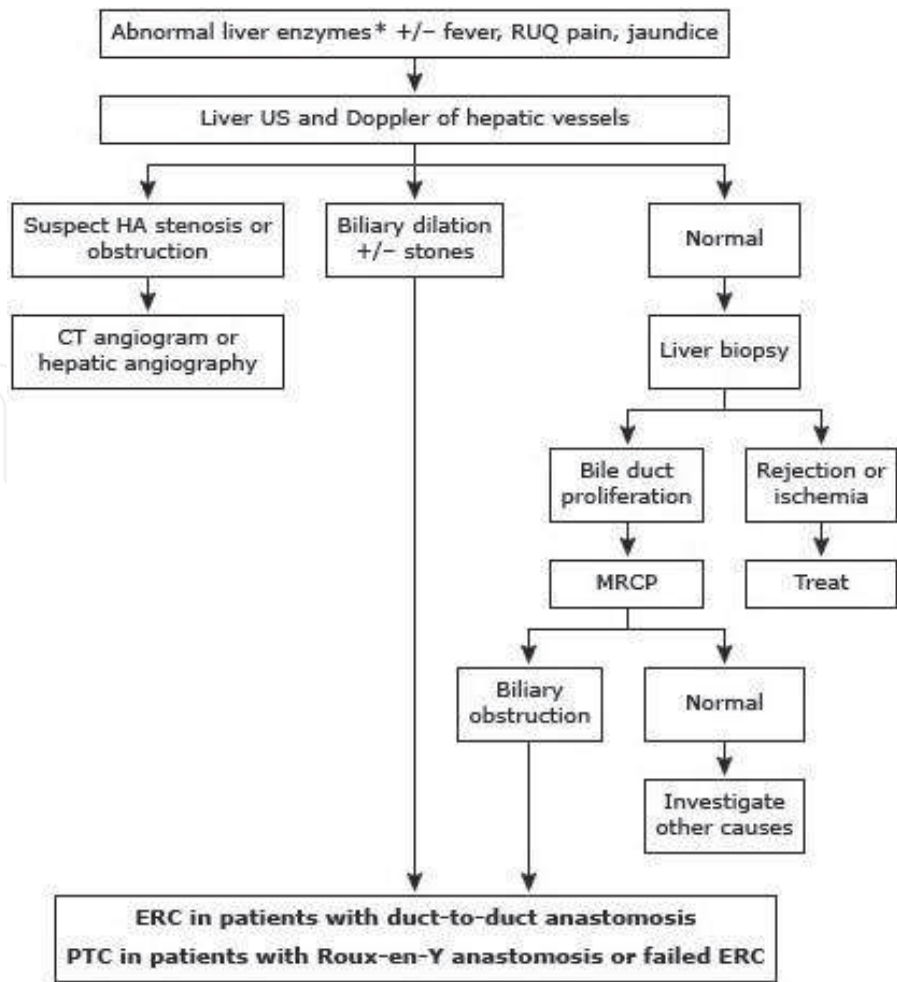


Figure 1.
Algorithm for the diagnosis and evaluation of suspected biliary obstruction after liver transplantation.

In 4–17% of cases, ERC cannot be performed successfully because the AS could not be crossed with a guidewire. Previous leaks of bile and high blood transfusion requirements during surgery are risk factors for the initial failure of ERC. The majority of these patients will require surgery. In patients with Roux-en-Y choledochojejunostomy, ERC is often unsuccessful, and we suggest treatment with PTC and dilation, followed by placement of a percutaneous transhepatic catheter [92]. Surgical revision (usually a repair or conversion to a Roux-en-Y choledochojejunostomy) may be an alternative in stable patients with a duct-to-duct stenosis that is difficult to treat.

3.4.2 Non-anastomotic stenoses (NAS)

These are mainly due to thrombosis of the hepatic artery or other forms of ischemia. Less commonly, they may be due to the recurrence of the underlying disease, such as primary sclerosing cholangitis. Its incidence is 0.5–10%.

NAS can occur proximal to the anastomosis in the extrahepatic or intrahepatic bile duct. There may be multiple stenoses that affect the hilum and intrahepatic ducts, causing a cholangiographic appearance that resembles primary sclerosing cholangitis. Bile sludge can accumulate proximal to the stenosis, leading to recurrent episodes of cholangitis.

NAS are more difficult to treat than AS. NAS endoscopic therapy consists of a balloon dilatation followed by sphincterotomy and plastic stents with replacement every 3 months. NAS results are not as favorable as AS. Only 50% have a long-term

response with endoscopic therapy with dilatation and stent placement. In addition, up to 50% undergo a transplant or die [93]. As a general rule, ischemic events that lead to diffuse stenosis of the intrahepatic bile duct are associated with poor graft survival.

Surgical revision may finally be necessary in strictures that are refractory to endoscopic or percutaneous treatment. A Roux-en-Y choledochojejunostomy is performed in patients with conduit-to-conduit anastomoses. In those who already have a Roux-en-Y anastomosis, it may be necessary to reposition the bile duct of the graft in a better vascularized area.

3.5 Biliary leaks

They have an incidence between 2 and 25%. The presence of a bile leak is an independent risk factor for the development of early or late stenoses. Leakage of the anastomosis, the cystic duct, the T-tube tract, or (in living donor or an LH divided into the liver) the cut surface of the liver may occur. Biliary leaks can be divided into early and late.

3.5.1 Early bile leaks

They occur at the site of the anastomosis and are often related to technical problems. Predisposing factors include the lack of perfusion of the hepatic artery and other technical reasons. They must be suspected in case of peritonitis or fluid collections in imaging tests.

In cases where a T-tube is placed, small anastomotic leaks can be diagnosed with a T-tube cholangiogram and can be controlled by leaving the tube open. In patients without a T-tube, ERC is the standard diagnostic method. Hepatobiliary scintigraphy (HIDA) can be useful in cases where there is a low suspicion of leakage [94].

The placement of a plastic stent, with or without biliary sphincterotomy, is successful in 90 to 95%. As a result, ERC is the treatment of choice. In some cases, small leaks can be treated with biliary sphincterotomy alone. The stent remains 2 months and is not changed during this period unless there is a clinical suspicion of obstruction.

Anastomotic leaks from Roux-en-Y choledochojejunostomy are less common. It can be diagnosed with a HIDA scan if the patient does not have a drainage catheter in place. ERC is often not feasible due to anatomical difficulties. Management is usually performed with internal-external percutaneous drainage and more frequently requires surgical treatment.

3.5.2 Late leaks of bile

They are usually related to the removal of the tube in T. It should be suspected in patients who develop pain when the tube is removed in T. ERC is indicated (with or without sphincterotomy) with transpapillary stenting [95]. Surgery or a percutaneous transhepatic approach is reserved for patients in whom the endoscopic approach is unsuccessful. Some centers use nasobiliary tubes instead of stents.

3.6 Biloma

They are produced by rupture of the duct and extravasation of bile in the hepatic parenchyma or abdominal cavity, in patients with necrosis of the bile duct secondary to thrombosis of the hepatic artery. Most post-LT bilomas occur in the perihepatic area, outside the liver. If the biloma occurs in the hepatic parenchyma

and communicates with the biliary tree, it may resolve spontaneously or, in some cases, be treated with endoscopy and a transpapillary stent. Large bilomas that do not communicate with the bile ducts should be treated with percutaneous drainage and antibiotics. Surgery is indicated when it cannot be effectively controlled with nonsurgical methods.

3.7 Filling defects of the common bile duct

They can be due to gallstones, sludges, blood clots, cylinders, and/or migrated stents [88]. Gallstones, cylinders, and sludge are relatively common after TL, with an incidence between 2.5 and 12%. The related mechanisms are stenosis, warm and cold ischemia, bacterial infection, and obstruction [95].

3.7.1 Stones

They appear late after the TL. In the majority of cases (59–66%), a session of ERC with biliary sphincterotomy was sufficient for cleaning the canal.

3.7.2 Molds

They are seen more frequently in the context of ischemia (e.g., thrombosis of the hepatic artery), when there is a diffuse stenosis of the hilum [96]. Mold cleaning can be difficult to achieve with endoscopic methods. Combined endoscopic and percutaneous methods can be performed successfully [96]. Often several combinations of sphincterotomy, balloon and basket extraction, stent placement, and lithotripsy are necessary, and many patients will eventually require treatment with PTC. Patients with Roux-en-Y choledochojejunostomy should be treated with a percutaneous method.

3.8 Sphincter of Oddi dysfunction

It has been described in 2–7% [79]. The pathogenesis is not clear; one hypothesis is that the denervation of the common bile duct in the ampullary region (secondary to surgery) leads to the development of a hypertonic sphincter, which causes dilatation of the ducts and cholestasis. In most studies, the diagnosis was based on clinical suspicion and response to biliary sphincterotomy [79].

3.9 Other complications

3.9.1 Mucocoele

It is a rare complication after LT caused by an accumulation of mucus from the cells lining the remnant of the cystic duct, leading to extrinsic compression of the bile duct. Its formation is insidious and therefore difficult to diagnose. A CT scan or US will reveal the mucocoele as an accumulation of fluid in the region of the hepatic portal. The diagnosis can be confirmed with MRCP [95]. Most patients will require surgical or radiological drainage.

3.9.2 Hemobilia

It may occur in patients undergoing percutaneous liver biopsy or percutaneous transhepatic cholangiography. This condition can cause transpapillary bleeding, along with biliary obstruction, due to the formation of clots. The treatment is

conservative but may require angiography with embolization. Biliary obstruction can be treated with percutaneous drainage or ERC.

3.9.3 Bactobilia

Patients who have undergone LT are predisposed to bacterial colonization of the bile ducts. Mechanical obstruction, plastic stents, gallstones, and sphincterotomy significantly increased the risk of bactobilia. The majority are asymptomatic. It is possible that bactobilia is a predisposing factor for the development of biliary complications after LT.

3.9.4 Biliary plaster syndrome

It refers to the presence of biliary cylinders and debris that cause biliary obstruction. Associated risk factors include hepatic artery stenosis and biliary stenosis [97]. Patients who develop biliary emptying syndrome have poor graft survival and a worse post-LT result than LT recipients without biliary emptying syndrome. Several endoscopic approaches have been described with varying success.

4. Rejection in liver transplant

4.1 Introduction

The human immune system is a host defense mechanism against the invasion of pathogens. However, a side effect of the ability of the host immune system to recognize and attack “nonself” tissues is rejection of grafted tissues posttransplantation. The exogenous modulation of the host immune system to allow sustained graft function has proceeded along with—and often preceded—our understanding of the physiologic mechanism of rejection and tolerance [98, 99].

The immunologic disparity among members of the same species of mammals that leads to recognition of “self” tissue and to rejection of nonself tissue is based on the differences in cell surface molecules that are expressed. In humans, these major histocompatibility antigens are termed human leukocyte antigens (HLAs). HLAs are subdivided into two classes: class I (HLA-A, HLA-B, and HLA-C), expressed on the surface of all nucleated cells, and class II (HLA-DR, HLA-DQ, and HLA-DP), expressed on the surface of antigen-presenting cells (APCs) [98–101].

The recognition of nonself tissue occurs via two distinct immunologic pathways: direct and indirect allorecognition. Direct allorecognition consists of host T-helper cells recognizing donor HLA disparity expressed on the donor cell surface. Indirect allorecognition consists of recipient APCs (e.g., activated macrophages, dendritic cells, and B lymphocytes) phagocytosing donor cellular debris, including HLAs, which are then processed and re-presented on the APC surface to be recognized by recipient T-helper cells (CD4⁺ lymphocytes) (**Figure 2**) [100].

In either pathway, co-stimulation signals between CD4⁺ T-helper lymphocytes and CD8⁺ cytotoxic T lymphocytes trigger a cascade of immunologic events. Interleukin (IL)-2, an important and early signal in immune activation, is secreted by activated CD4⁺ T-helper lymphocytes, stimulating increased T-cell responsiveness, clonal expansion of alloreactive T lymphocytes, and acquisition of the cytolytic phenotype by host T lymphocytes. Direct allorecognition leads to a more immediate and vigorous immune response against foreign tissue, but, in both pathways, additional helper T lymphocytes are recruited and secrete a wide array of cytokines (e.g., IL-1, interferon- γ , tumor necrosis factor- α), facilitating the further

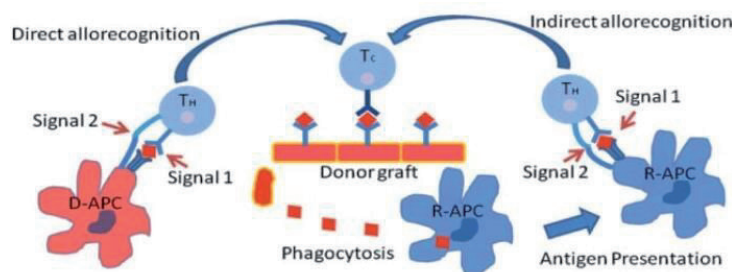


Figure 2.
 Direct and indirect pathways of allorecognition (modified Ref. [100]).

recruitment of cytotoxic T lymphocytes, natural killer cells, and B lymphocytes. B lymphocytes begin to secrete antibody directed against the allogeneic tissue in ever-increasing quantities. B lymphocytes also play an antibody-independent role in graft rejection through the secretion of proinflammatory cytokines and chemokines and the participation in antigen presentation [98–102].

Rejection mechanistically occurs by infiltration of the graft by effector cells, the binding of antibody, and the activation of complement. Unchecked, the phenomenon inexorably leads in graft loss (**Table 1**) [100].

Rejection is classified according to the temporal relation between the implantation of the graft and its dysfunction supported by the histologic features seen in allograft: hyperacute (HAR), acute (AR), and chronic (CR). Each type is mediated by a different host immune mechanism.

4.2 Hyperacute rejection

HAR occurs within a few minutes to a few hours after the reperfusion of the graft. Preformed antibodies directed against antigens presented by the graft mediate activation of complement activation of endothelial cells, and formation of microvascular thrombi, leading to graft thrombosis and loss. The process is irreversible and, currently, no treatment is available.

HAR is mediated by circulating preformed antibodies, normally directed against ABO system (comprising the four main blood types, i.e., A, B, AB, and O) antigens or against major HLA antigens. The screening of potential transplant recipients and strict adherence to ABO verification prevent nearly all HAR [101].

In pretransplantation study, crossmatch testing is performed to identify preformed antibodies against class I HLAs (T-lymphocyte crossmatch testing) and class II HLAs (B-lymphocyte crossmatch testing). Crossmatch testing helps clinicians to identify the presence of antibodies against potential donor antigens and to assess the risks of posttransplant rejection and subsequent graft loss. However, these crossmatching assays are not standardized [98, 101, 102].

At most centers, heart and liver transplantations are performed without a crossmatch (except with system ABO compatibility between donor and recipient), unless the recipient is highly sensitized or has previously received a graft possessing major antigens in common with the current donor.

In *liver transplant* recipients, anti-HLA antibody-mediated HAR has been described, but HAR due to ABO-incompatible blood groups is seen in up to 33% and described as a more delayed form of antibody-mediated rejection, but even this barrier appears surmountable with the use of plasmapheresis along with aggressive immunosuppression. Unlike the renal graft, the hepatic graft can undergo HAR over a number of days, probably secondary to its ability to absorb a large amount of antibody and its functional reserve before the onset of the significant microthrombosis and vascular damage [100–102].

The *diagnosis of HR* in liver transplant recipients is normally suggested by fever and rapid deterioration in graft function: AST >1000, coagulopathy, acidosis, encephalopathy, and distributive shock. The *differential diagnosis* may be that of primary non-function/delayed function and hepatic artery thrombosis [101].

The *histological features* of hyperacute rejection are vascular congestion, fibrin-platelet thrombi within capillaries, neutrophilic vasculitis with fibrinoid necrosis, prominent interstitial edema, and neutrophil infiltrates [98, 100].

In unsuccessful cases the only treatment is *retransplantation*.

4.3 Acute rejection

AR is the most common form of graft rejection. It may develop at any time but is most frequent during the first several months posttransplant. Rarely, it occurs within the first several days posttransplant, a process termed accelerated acute rejection, most likely a combination of amnestic immune response driven by sensitized memory B lymphocytes and activation of the direct allorecognition pathway [99].

AR may be cell mediated, antibody mediated (AMR), or very occasionally mixed. Histologically, AR generates an infiltration of activated T lymphocytes into the graft, resulting in gradually progressive endothelial damage, microvascular thrombosis, and parenchymal necrosis. Pathologic grading schemes have been developed regarding the extent to which AR involves vascular damage, cellular infiltration, or a combination of both [98, 99, 101].

Without intervention, AR inevitably progresses to graft loss. The clinical presentation of AR varies markedly, depending on the specific organ, on the level of immunosuppression, and on the attendant level of inflammation in the affected tissues.

Unless the host immune system is adequately suppressed pharmacologically, transplantation inevitably leads to AR.

A combination of immunosuppressive agents is typically used chronically to prevent AR, including a lymphocyte antagonist (usually a calcineurin inhibitor such as cyclosporine or tacrolimus) and an antiproliferative agent (such as azathioprine or mycophenolate mofetil), with or without corticosteroids. Antilymphocyte antibody therapy is often added during induction of immunosuppression or for treatment of “steroid-resistant” AR. The most common *liver transplantation* regimen consists of two doses of a monoclonal anti-IL2 receptor (basiliximab) as induction therapy and dual maintenance therapy with the CNI, tacrolimus, and the antimetabolite mycophenolate mofetil, which lessens the incidence and severity of rejection without increasing infection rates [100, 101].

AR remains an important clinical problem in liver transplantation. Incidence of AR ranges from 30 to 80%. Various risk factors for its development are known, such as low concentrations of immunosuppressants, prolonged cold ischemia time, and young receptor [102].

The *diagnosis of AR* in liver transplant recipients is normally suggested by fever and elevated levels of transaminases, bilirubin, or alkaline phosphatase. Among patients with T-tube drainage (which is increasingly uncommon), the biliary drainage may be seen to thicken, darken, and decrease in amount. The suspicion of AR mandates graft biopsy and studies to eliminate other possible causes of early hepatic graft failure as Doppler ultrasonography and, in some cases, cholangiography resonance. Biopsy findings are classified, according to a standardized set of criteria, as mild, moderate, and severe, with clear implications for prognosis. Microscopic observation reveals interstitial infiltrates of lymphocytes and macrophages, arteritis, fibrinoid necrosis, and thrombosis. The involvement of the blood vessels is a

poor sign because its usual meaning is that of an episode of rejection that will be refractory to treatment. Biopsy may be relatively contraindicated due to coagulopathy. In some circumstances transjugular biopsy offers a solution to this problem (**Table 3**) [100–102].

The *differential diagnosis* may be that of sepsis or problems with vascular integrity.

AR is normally *treated* with high-dose corticosteroids, but 5–10% of cases are steroid resistant; such recipients are then treated with an antilymphocyte antibody or tacrolimus at higher levels [100].

5. Primary graft liver dysfunction

Primary graft liver dysfunction is defined as the liver dysfunction that occurs from the moment of liver transplantation, which is not explained by the existence of another etiology, neither vascular nor bile.

Although there is improvement on preservation solutions and surgical techniques [103], its incidence varies from 2 to 23% in several studies. It also seems to be the cause of 20–30% of the retransplants. The mortality without it is close to 80%.

The clinical suspect is established during the first hours after the liver transplant due to the presence of hemodynamic instability, metabolic acidosis, severe coagulopathy (prothrombin time >20 seconds), hypertransaminasemia (>1000 U/l), and encephalopathy.

When primary dysfunction does not threaten patient life immediately, it is known as “poor early graft function.” On those several cases whose patient dies if the transplantation is not done, it is known as “primary graft failure” [104].

The pathogenesis of primary graft liver dysfunction is nearly related to the ischemia-reperfusion injury, so there are some predisposing donor factors that impact on recipient outcome [105, 106]. Prophylaxis includes a thorough donor selection and an exhaustive ischemia time control [107–109].

These premises are very important because of the fact that retransplantation is the isolated efficacy treatment.

Diagnosis is encouraged by additional examinations which discard secondary graft dysfunction. Transhepatic cholangiography must demonstrate a permeable bile duct as Doppler ultrasound and arteriography must demonstrate the absence of vascular complications. Liver biopsy is useful to discard a hyperacute rejection [104].

Nowadays the shortage of available donor organs is the major limiting factor in liver transplantation. Optimal deceased donors are generally young, previously healthy persons who develop a fatal brain injury due to causes such as head trauma, intracerebral hemorrhage, or anoxia. The relative paucity of donor organs has led transplant centers to consider organs from marginal donors (**Table 4**) [109–113].

Aside from the marginal donors, there are other factors associated with graft failure (**Table 5**) [113].

5.1 Treatment

As we have commented, the isolated efficacy treatment is retransplant and goes on identifying donors and recipient factors that lead to this kind of injury as avoiding large ischemic times. The proper donor maintenance at the intensive care unit is at most important [103, 107, 108].

Prostaglandins type E1 come be used as preventing treatment.

	Comment	Characteristics	Liver biopsy	Differential diagnosis	Treatment options
Hyperacute rejection	Rare in OLT 1–10 days posttransplant	Rapid deterioration in graft function: AST >1000 Coagulopathy, acidosis	Hemorrhagic necrosis	Primary non-function/ delayed function Hepatic artery thrombosis	Retransplantation Rarely: OKT3, cyclophosphamide, plasmapheresis
Acute rejection	30–70% occurs at mean of 7–9 days	Often clinically silent apart from fever and RUQ pain High AST and bilirubin Coagulation and acid-base undisturbed	Portal inflammation Endotheliitis Bile duct damage	Sepsis Vascular Viral	Methylprednisolone 1 g daily for 3 days

Table 3.
AST, aspartate aminotransferase; MMF, mycophenolate mofetil; OLT, orthotopic liver transplantation; RUQ, right upper quadrant.

Marginal liver graft outcomes
<ul style="list-style-type: none">• Donor age > 70 years• Hepatitis C-positive donors• Cold ischemia time > 12 hours• Donations after cardiac death donors• More than 30% steatosis• Liver splits between two recipients

Table 4.
Marginal liver graft outcomes.

Donor factors	Recipient factors
<ul style="list-style-type: none">• Hepatitis B core antibody positivity• A mean arterial pressure lower than 60 mmHg more than 20 minutes after life support withdrawal (after cardiac death)	<ul style="list-style-type: none">• Hepatitis C virus infection• Presence of malignancy• Previous liver transplantation• BMI > 30• Non-Caucasian race

Table 5.
Donor and recipient factors.

6. Early infection in liver transplantation

Despite advances in liver transplantation, morbidity and mortality due to infectious complications remain the biggest problem [114, 115]. In many centers, infection is the leading cause of death after liver transplantation, particularly after the first year [116]. In series of autopsies, it has been announced that the infection was the cause of death in 64% of the 321 patients studied who died between 1982 and 1997 [117]. Recent advances include in standardized and condoned protocols molecular research of viruses, demonstrating the binding between genetic polymorphisms of the immune response and the risk for specific infections and treatment with new antibiotics, including the latest advances in C virus therapy [118].

The most common infections are bacterial (48%), followed by fungal (22%) and viral (12%). Some series observe an incidence of up to 1–2.5 episodes of infection per patient [119–121], this being the most common cause of fever in liver transplant recipients [122].

It is important to recognize a number of general principles [118, 123]:

1. Signs and symptoms of infection are attenuated by immunosuppression; therefore, the infection may be more difficult to diagnose.
2. Noninfectious causes of fever, such as rejection, medications, etc., can simulate an infection.
3. The variety of possible pathogens is extensive but is influenced by the timing of the infection in relation to transplantation.
4. Antibiotics have interactions with immunosuppressive medication.
5. The infection may be more severe and progress faster than an immunocompetent host.

6. The risks of infection are determined by the balance between factors related to immunosuppressive treatment at full dose (dose, type, and duration of immunosuppressive therapy) and the existence of catheters, nutritional status, condition function of grafting, and the presence of underlying diseases.

Identifying risk factors before transplantation optimizes strategies to prevent infections. Although our ability to predict the risk of infection after transplantation remains limited, there are risk factors that can be modified, such as cytomegalovirus (CMV) positivity and donor and receiver.

An important risk factor is the presence of a latent or unrecognized infection either from the donor or recipient. These infections can be reactivated and cause morbidity after the introduction of immunosuppressants. Therefore, both donors and recipients are routinely tested for infections such as CMV, other herpes viruses, tuberculosis, hepatitis B and C, syphilis, and human immunodeficiency virus.

Colonization of transplant recipients with organisms, such as methicillin-resistant *Staphylococcus aureus* (MRSA) or vancomycin-resistant *Enterococcus* (VRE), can lead to infection posttransplant of these organisms. A significant prevalence of multiresistant gram-negative bacilli, such as expanded betalactase enterobacteria (BLEES) and *Escherichia coli* and carbapenem-resistant *Klebsiella pneumoniae*, has been observed in both the general population and solid organ transplant recipients, as they present risk factors for acquiring multi-resistant bacteria such as previous antibiotic therapy, catheter presence, exposure to the hospital environment, and presence of underlying diseases [124].

Other risk factors have been described, for example, those related to surgical complications. In a series of 101 patients, the risk factors associated with these infections were prolonged surgery of more than 12 hours and reoperation.

Among those related to pretransplantation were predictive infection, a serum value of alanine aminotransferase above 60 IU/L for all types of infections, and a T-helper ratio of 2.8, for fungal and viral infections [125].

Bacterial infections are seen more in those Roux-type Y-procedures than with cholecystectomy, when there were multiple abdominal surgeries or there was a concomitant CMV infection in the postoperative period [126]. Graft dysfunction and the presence of critical pre-surgery diseases also confer an increased risk to acquire posttransplant infections.

The presence of CMV infection increases the risk of other infections, partly due to the immunomodulatory effects of this virus. Likewise, those who have rejection or those who have poor graft function after implantation increase the risk because they receive a more aggressive regimen of immunosuppressants.

The risk and type of infection found differ from the elapsed time after the implant and can be grouped into three major periods: first month, 1–6 months, and after 6 months.

Focusing on the first period or early infections, these are similar to those seen by an immunocompetent patient after surgery. Bacterial infections of nosocomial origin predominate, such as catheter infection, external drainage, or are related to foreign bodies, presence of necrotic tissue, or prolonged tracheal intubation [127]. We must also consider donor transmitted infections when there is an unexplained syndrome consistent with the infection.

Abdominal and lung infection are the most common, both associated with the presence of bacteremias [115].

Abdominal abscess and peritoneal abscess are the result of postoperative complications including gallbladder or surgical hematomas, with the predominant pathogens being enteric organisms [119]. Intrahepatic abscess and bile duct ischemia

manifest as a consequence of hepatic artery thrombosis, occurring in the immediate postoperative period. And cholangitis is caused by blockage of the bile tract, including blockage of the Kher tube. Abdominal wall infections are also common.

Regarding lung infections, they are common in those who require intubations with prolonged mechanical ventilation. *Pseudomonas aeruginosa* and *Enterobacter* are most commonly grown. Other common bacteria include *S. aureus*, *K. pneumoniae*, *Stenotrophomonas maltophilia*, and *Citrobacter freundii* [119].

Colitis related with *Clostridium difficile* can occur in early periods, especially herethat have prolonged hospitalization. More than half of cases occur in the first posttransplant month. In fact, liver transplantation is identified as a risk factor for acquiring a *C. difficile* infection at the hospital due to immunosuppression and antibiotic treatment among other factors [128, 129].

Candida species are common pathogens identified in the first month. Bacteremia, surgical wounds, as well as urinary tract infection are common places of primary infection and can be subsequently disseminated [130]. The presence of esophagitis, oral cavity infection, and folliculitis is usually common. Due to the high mortality in candidemias, these should be treated aggressively, having to take into account the high incidence of *Candida albicans* reported in recent years.

Except for herpes simplex virus (HSV), viral infections are uncommon in the first month after transplantation. Without adequate prophylaxis, HSV reaction reaches up to 50%, in those HIV-positive patients prior to transplantation, usually manifesting as oral or genital ulcers.

7. Extrahepatic complications after liver transplantation

Patients undergoing a liver transplant may have long-term complications in different devices and systems. The most common are infections, de novo tumors, cardiovascular disease (including high blood pressure, hyperlipidemia, obesity, and metabolic syndrome), kidney disease, and diabetes.

These complications usually have a more or less direct relationship with the need for immunosuppressive drugs after implantation to prevent rejection of the implant. The use of high doses of corticosteroids for a long period promotes the onset of diabetes and increases the risk of cardiovascular disease, while the rest of immunosuppressants are associated with more common long-term complications, the appearance of tumors, cardiovascular disease, and kidney failure.

The management of these pathologies does not differ from that received by patients not undergoing a transplant, so they can be detected and treated by different specialists, having direct communication with the hepatologists for the adjustment of medication in the different complications.

Next, we will further develop each of them.

7.1 De novo tumors

The incidence of de novo tumors is three times higher in liver transplant recipients than the rest of the population, making the first or second leading cause of long-term death in the liver implant patient (frequency varies according to the different series) [131].

The most commonly developed tumor is the skin epithelioma, directly related to sun exposure. Other de novo tumors associated with prolonged immunosuppressive treatment in liver transplants include non-Hodgkin lymphoma, Kaposi lymphoma, and oropharyngeal, bladder, cervix, and lung cancers, 10–20% at 10 years of transplantation.

However, the incidence of breast, prostate, or colon tumors has not been increased with respect to the incidence in the general population, except if the etiology of transplantation has been led to primary sclerosing cholangitis associated with ulcerative colitis, in which case the incidence of colon neoplasm increases.

The flattering factors do not differ from the rest of the population, but we must make special impact on primary and secondary prevention in this type of patients, given the situation of immunosuppression. That is why we must make special focus on the prevention of smoking habit, safe sex, and, of course, alcohol withdrawal.

7.2 Cardiovascular disease

Liver transplant recipients have a frequency three times higher than the general population suffering from a major cardiovascular event, considering in this group coronary heart disease, heart failure, sudden death, vascular brain accident, or severe occlusive peripheral artery disease. So the likelihood of suffering a cardiovascular event increases over the years, being 5% in the first 2 years posttransplant, 15% at 10 years after transplantation, and greater than 20% more than 10 years post-transplant. It is considered to be the second or first cause of death in liver transplants according to the different series. This increase in incidence, in addition to immunosuppressive treatment, has been associated with increased cardiovascular risk factors over time, especially metabolic syndrome (HTA, obesity, and dyslipidemia) and diabetes.

Other habits that contribute to the development of cardiovascular disease are smoking and alcohol intake [130].

7.3 Metabolic syndrome

It is defined by the onset of diabetes, dyslipidemias, obesity, and HTA. Up to 50–60% of patients undergoing HT will develop metabolic syndrome [132].

7.3.1 HTA

The incidence of HTA in liver transplant patients is related, in particular, to the vasoconstrictor effect of calcineurin inhibitors and to the mineralocorticoid effect of corticosteroids. It usually occurs in 40–60% of patients in the late period of liver transplantation.

We consider optimal voltage figures between 130 and 80 mmHg of systolic and diastolic blood pressure, respectively, being a little more restrictive than with the limits set for the general population (140 and 90 mmHg), adopting the same established limits as for diabetic patients with renal impairment. We must be restrictive in terms of these figures, always maintaining lower levels in liver transplant patients.

We should avoid drugs such as NSAIDs as soon as possible, as in patients treated with calcineurin inhibitors tend to increase blood pressure levels.

Patients treated with calcineurin inhibitors should receive their antihypertensive treatment late in the afternoon or evening, as these drugs have a nightly blood pressure rhythm, and therefore most of them we found at night. If, however, we cannot decrease tension levels, one might consider reducing the dose of these immunosuppressants [133, 134].

7.3.2 Obesity

Approximately 30% of TH receptors will develop obesity (BMI greater than 30). This is due to the increase in sedentariness due to the situation of pretransplant

disease, the corticoid treatment, the release of restrictive diets once transplanted, and the decrease of physical exercise. The treatment is the same as in any non-immunocompromised patient: physical exercise and low-calorie diets. If necessary, lipase inhibitors could be administered as adjuvant drugs in weight loss; in which case, it would be necessary to monitor immunosuppressant levels more thoroughly to prevent possible interactions that decrease their absorption [132].

7.3.3 Dyslipidemias

The administration of immunosuppressants such as calcineurin inhibitors, mTOR inhibitors, and corticosteroids, independently or in addition to each patient's genetic predisposition, may contribute to rising levels of plasma cholesterol and triglycerides, with increased LDL and decreased HDL, resulting in hypercholesterolemia and hypertriglyceridemia in up to 40% liver transplant recipients. The treatment is using hypolipidizing drugs (statins and fibrates) and diet, as in the rest of the population. Keep in mind that patients who take cyclosporine and need treatment with statin are at higher risk of developing severe myopathy [132].

7.3.4 Diabetes

It has an incidence between 20 and 35% development in transplant patients. Factors that contribute to its emergence are advanced age, obesity, existing pretransplant diabetes, immunosuppressants with diabetic effects, especially tacrolimus, the development of insulin resistance of corticosteroids, and the insulin secretion deficit of calcineurin inhibitors.

Treatment is based on insulin and oral antidiabetics, although most patients with HT will need insulin because of the lower efficacy of ADOs, with the highest insulin needs being in the morning and noon in those patients with corticosteroids, since the pattern is usually in the morning [132].

7.4 Chronic renal failure

The incidence of renal impairment in liver transplant patients is 50–70% higher [135]. The most directly related cause is treatment with calcineurin inhibitors, due to its nephrotoxic effect, although factors such as HTA, diabetes, or other infections that secondarily affect the correct kidney filtration, such as HCV infection, may also contribute. Of these patients treated with calcineurin inhibitors, 10% will develop a chronic end-stage renal disease (glomerular filter age less than 30 ml/min/1.73 m²), in need of hemodialysis therapy or even renal transplantation in 1–2% of cases. This percentage, fortunately, has been declining in recent years coinciding with the lower use of this family of immunosuppressants. Clearly, for patients who develop renal impairment, we must readjust immunosuppressive treatment, reducing the dose of calcineurin inhibitors or substitutes or other non-nephrotoxic immunosuppressants such as inhibitors mTOR or mycophenolate. Similarly, the use of nonsteroidal anti-inflammatory drugs and all drugs that may contribute to worsening kidney function will be avoided [135].

7.5 Other complications

Apart from the most important complications in both frequency and clinical impact, liver transplant recipients may develop other types of related complications in whole or in total or with the intake of immunosuppressive drugs. In this way,

patients taking calcineurin inhibitors may develop neurological problems, especially headache, migraine, insomnia tremor, and paresthesia.

Corticoids: Osteoarticular pathology, especially osteoporosis (50%), Cushingoid facies, alteration in body fat distribution, hirsutism.

Mycophenolate: diarrhea and vomiting, especially with mofetil mycophenolate, less common with sodium mycophenolate, bone marrow depression also favored by concomitant administration of interferon for any other reason.

mTOR inhibitors: bone marrow depression, respiratory problems such as pulmonary fibrosis and organizational pneumonia, difficulty healing wounds.

And all of them can lead to more or less sexual dysfunction.

So it is necessary to do a complete scan and anamnesis to be able to detect these side effects and assess modification of pattern or replacement of it [133, 134].

7.6 Survival

Annual mortality after the first year after liver transplantation is 2–3% per year, higher than in the general population of the same age and gender. The principal causes of death are cardiovascular diseases, appearance of novo tumors, and relapse of hepatitis C [136–139].

The quality of life posttransplantation is not fully satisfactory although it is better than the quality of pretransplant life. Only a percentage of lower patients presents a quality of life lower than the general population, about everything in aspects related with the function staff on paper partner-work family.

8. Conclusions

LT is nowadays a common surgical technique in many hospitals and is undoubtedly the most definitive treatment for end-stage liver disease. Early monitoring and a correct treatment of this kind of patients at the ICU are of utmost importance. The success lies in early detection and treating of complications by using the proper diagnostic and medical or surgical techniques that all intensivists need to know and manage. All the surgical and medical team need to deploy their best competencies to save the graft and the patient's life.

IntechOpen

Author details

Demetrio V. Pérez Civantos^{1,2*}, Alicia Muñoz Cantero¹, Manuel Robles Marcos^{1,2}, Francisco Fuentes Morillas¹, María A. Santiago Triviño¹, María O. Cerezo Arias¹, María D. Pérez Frutos¹ and Alberto Córdoba López¹

¹ Intensive and Critical Care Department, Badajoz University Hospital, University of Extremadura, Badajoz, Spain

² Intensive and Critical Care Medicine, Faculty of Medicine, University of Extremadura, Badajoz, Spain

*Address all correspondence to: demetrio.perez@salud-juntaex.es; dpcivantos@gmail.com

IntechOpen

© 2019 The Author(s). Licensee IntechOpen. This chapter is distributed under the terms of the Creative Commons Attribution License (<http://creativecommons.org/licenses/by/3.0>), which permits unrestricted use, distribution, and reproduction in any medium, provided the original work is properly cited. 

References

- [1] Maluf DG, Edwards EB, Kauffman HM. Utilization of extended donor criteria liver allograft: Is the elevated risk of failure independent of the model for end-stage liver disease score of the recipient? *Transplantation*. 2006;**82**:1653-1657. DOI: 10.1097/01.tp.0000250571.41361.21
- [2] Bonney GK, Aldersley MA, Asthana S, Toogood GJ, Pollard SG, Lodge JP, et al. Donor risk index and MELD interactions in predicting long-term graft survival: A single-centre experience. *Transplantation*. 2009;**87**:1858-1863. DOI: 10.1097/TP.0b013e3181a75b37
- [3] Pérez Civantos D, Muñoz Cantero A, Robles Marcos M, Fuentes Morillas F, Cerezo Arias M, Fariñas Seijas H. Utility of basal regional oximetry as an early predictor of graft failure after liver transplant. *Transplantation Proceedings*. 2019;**51**(2):353-358. DOI: 10.1016/j.transproceed.2018.10.023
- [4] Vivarelli M et al. Ischemic arterial complications after liver transplantation in the adult: Multivariate analysis of the risk factors. *Archives of Surgery*. 2004;**139**:1069-1074
- [5] Langs AN, Marujo W, Stratta RJ, Wood RP, Shaw BW Jr. Vascular complications after orthotopic liver transplantation. *American Journal of Surgery*. 1991;**161**:76-82; discussion 82-83
- [6] Drazan K, Shaked A, Olthoff KM, et al. Etiology and management of symptomatic adult hepatic artery thrombosis after orthotopic liver transplantation (OLT). *The American Surgeon*. 1996;**62**:237-240
- [7] Settmacher U, Stange B, Haase R, et al. Arterial complications after liver transplantation. *Transplant International*. 2000;**13**:372-378
- [8] Abbasoglu O, Levy MF, Vodapally MS, et al. Hepatic artery stenosis after liver transplantation—Incidence, presentation, treatment, and long term outcome. *Transplantation*. 1997;**63**:250-255
- [9] Bhattacharjya S, Gunson BK, Mirza DF, et al. Delayed hepatic artery thrombosis in adult orthotopic liver transplantation—A 12-year experience. *Transplantation*. 2001;**71**:1592-1596
- [10] Oh CK, Pelletier SJ, Sawyer RG, et al. Uni-and multi-variate analysis of risk factors for early and late hepatic artery thrombosis after liver transplantation. *Transplantation*. 2001;**71**:767-772
- [11] Gunsar F, Rolando N, Pastacaldi S, et al. Late hepatic artery thrombosis after orthotopic liver transplantation. *Liver Transplantation*. 2003;**9**:605-611
- [12] Stange BJ, Glanemann M, Nuessler NC, Settmacher U, Steinmuller T, Nehaus P. Hepatic artery thrombosis after adult liver transplantation. *Liver Transplantation*. 2003;**9**:612-620
- [13] Piardi T, Lhuair M, Bruno O, Memeo R, Pessaux P, Kianmanesh R, et al. Vascular complications following liver transplantation: A literature review of advances in 2015. *World Journal of Hepatology*. 2016;**8**(1):36-57
- [14] Boyvat F, Aytekin C, Firat A, Harman A, Karakayali H, Haberal M. Diagnostic and therapeutic management of hepatic artery thrombosis and stenosis after orthotopic and heterotopic liver transplantation. *Transplantation Proceedings*. 2003;**35**:2791-2795
- [15] Zhou J, Fan J, Wang JH, Wu ZQ, Qiu SJ, Shen YH, et al. Continuous transcatheter arterial thrombolysis for early hepatic artery thrombosis after

liver transplantation. *Transplantation Proceedings*. 2005;**37**:4426-4429

[16] Gad EH, Abdelsamee MA, Kamel Y. Hepatic arterial and portal venous complications after adult and pediatric living donor liver transplantation, risk factors, management and outcome (a retrospective cohort study). *Annals of Medicine and Surgery*. 2016;**8**:28-39

[17] Pinna AD, Smith CV, Furukawa H, Starzl TE, Fung JJ. Urgent revascularization of liver allografts after early hepatic artery thrombosis. *Transplantation*. 1996;**62**:1584-1587

[18] Panaro F, Ramos J, Gallix B, Mercier G, Herrero A, Niampa H, et al. Hepatic artery complications following liver transplantation. Does preoperative chemoembolization impact the postoperative course? *Clinical Transplantation*. 2014;**28**:598-605. DOI: 10.1111/ctr.12358

[19] Singhal A, Stokes K, Sebastian A, Wright HI, Kohli V. Endovascular treatment of hepatic artery thrombosis following liver transplantation. *Transplant International*. 2010;**23**:245-256. DOI: 10.1111/j.1432-2277.2009.01037.x

[20] Silva MA, Jambulingam PS, Gunson BK, Mayer D, Buckels JA, Mirza DF, et al. Hepatic artery thrombosis following orthotopic liver transplantation: A 10-year experience from a single centre in the United Kingdom. *Liver Transplantation*. 2006;**12**:146-151

[21] Bekker J, Ploem S, de Jong KP. Early hepatic artery thrombosis after liver transplantation: A systematic review of the incidence, outcome and risk factors. *American Journal of Transplantation*. 2009;**9**:746-757

[22] Pareja E, Cortes M, Navarro R, Sanjuan F, López R, Mir J. Vascular

complications after orthotopic liver transplantation: Hepatic artery thrombosis. *Transplantation Proceedings*. 2010;**42**:2970-2972

[23] Tzakis AG, Gordon RD, Shaw BW, Iwatsuki S, Starzl TE. Clinical presentation of hepatic artery thrombosis after liver transplantation in the cyclosporine era. *Transplantation*. 1985;**40**:667-671

[24] Pastacaldi S, Teixeira R, Montalto P, Rolles K, Burroughs AK. Hepatic artery thrombosis after orthotopic liver transplantation: A review of nonsurgical causes. *Liver Transplantation*. 2001;**7**:75-81

[25] Wozney P, Zajko AB, Bron KM, Point S, Starzl TE. Vascular complications after liver transplantation: A 5-year experience. *AJR. American Journal of Roentgenology*. 1986;**147**:657-663

[26] Saad WE, Davies MG, Saad NE, Westesson KE, Patel NC, Sahler LG, et al. Catheter thrombolysis of thrombosed hepatic arteries in liver transplant recipients: Predictors of success and role of thrombolysis. *Vascular and Endovascular Surgery*. 2007;**41**:19-26

[27] Saad WE, Davies MG, Sahler L, Lee DE, Patel NC, Kitanosono T, et al. Hepatic artery stenosis in liver transplant recipients: Primary treatment with percutaneous transluminal angioplasty. *Journal of Vascular and Interventional Radiology*. 2005;**16**:795-805

[28] da Silva RF, Raphe R, Felício HC, Rocha MF, Duca WJ, Arroyo PC, et al. Prevalence, treatment, and outcomes of the hepatic artery stenosis after liver transplantation. *Transplantation Proceedings*. 2008;**40**:805-807. DOI: 10.1016/j.transproceed.2008.02.041

[29] Hamby BA, Ramirez DE, Loss GE, Bazan HA, Smith TA,

- Bluth E, et al. Endovascular treatment of hepatic artery stenosis after liver transplantation. *Journal of Vascular Surgery*. 2013;57:1067-1072. DOI: 10.1016/j.jvs.2012.10.086
- [30] Rostambeigi N, Hunter D, Duval S, Chinnakotla S, Golzarian J. Stent placement versus angioplasty for hepatic artery stenosis after liver transplant: A meta-analysis of case series. *European Radiology*. 2013;23:1323-1334. DOI: 10.1007/s00330-012-2730-9
- [31] Sommacale D, Aoyagi T, Dondero F, Sibert A, Bruno O, Fteriche S, et al. Repeat endovascular treatment of recurring hepatic artery stenoses in orthotopic liver transplantation. *Transplant International*. 2013;26:608-615. DOI: 10.1111/tri.12089
- [32] Sabri SS, Saad WE, Schmitt TM, Turba UC, Kumer SC, Park AW, et al. Endovascular therapy for hepatic artery stenosis and thrombosis following liver transplantation. *Vascular and Endovascular Surgery*. 2011;45:447-452. DOI: 10.1177/1538574411407088
- [33] Blumhardt G, Ringe B, Lauchart W, Burdelski M, Bechstein WO, Pichlmayr R. Vascular problems in liver transplantation. *Transplantation Proceedings*. 1987;19:2412
- [34] Denys AL, Qanadli SD, Durand F, Vilgrain V, Farges O, Belghiti J, et al. Feasibility and effectiveness of using coronary stents in the treatment of hepatic artery stenoses after orthotopic liver transplantation: Preliminary report. *AJR. American Journal of Roentgenology*. 2002;178:1175-1179
- [35] Langnas AN, Marujo W, Stratta RJ, Wood RP, Shaw BW. Vascular complications after orthotopic liver transplantation. *American Journal of Surgery*. 1991;161:76-82 discussion 82-83
- [36] Volpin E, Pessaux P, Sauvanet A, Sibert A, Kianmanesh R, Durand F, et al. Preservation of the arterial vascularisation after hepatic artery pseudoaneurysm following orthotopic liver transplantation: Long-term results. *Annals of Transplantation*. 2014;19:346-352. DOI: 10.12659/AOT.890473
- [37] Boleslawski E, Bouras AF, Truant S, Liddo G, Herrero A, Badic B, et al. Hepatic artery ligation for arterial rupture following liver transplantation: A reasonable option. *American Journal of Transplantation*. 2013;13:1055-1062. DOI: 10.1111/ajt.12135
- [38] Houssin D, Ortega D, Richardson A, Ozier Y, Stephan H, Soffer M, et al. Mycotic aneurysm of the hepatic artery complicating human liver transplantation. *Transplantation*. 1988;46:469-472
- [39] Lerut J, Gordon RD, Iwatsuki S, Starzl TE. Surgical complications in human orthotopic liver transplantation. *Acta Chirurgica Belgica*. 1987;87:193-204
- [40] Madariaga J, Tzakis A, Zajko AB, Tzoracoleftherakis E, Tepetes K, Gordon R, et al. Hepatic artery pseudoaneurysm ligation after orthotopic liver transplantation—A report of 7 cases. *Transplantation*. 1992;54:824-828
- [41] Bonham CA, Kapur S, Geller D, Fung JJ, Pinna A. Excision and immediate revascularization for hepatic artery pseudoaneurysm following liver transplantation. *Transplantation Proceedings*. 1999;31:443
- [42] Lowell JA, Coopersmith CM, Shenoy S, Howard TK. Unusual presentations of nonmycotic hepatic artery pseudoaneurysms after liver transplantation. *Liver Transplantation and Surgery*. 1999;5:200-203

- [43] Stange B, Settmacher U, Glanemann M, Nuessler NC, Bechstein WO, Neuhaus P. Aneurysms of the hepatic artery after liver transplantation. *Transplantation Proceedings*. 2000;**32**:533-534
- [44] Leonardi LS, Soares C, Boin IF, Oliveira VC. Hemobilia after mycotic hepatic artery pseudoaneurysm after liver transplantation. *Transplantation Proceedings*. 2001;**33**:2580-2582
- [45] Marshall MM, Muiesan P, Srinivasan P, Kane PA, Rela M, Heaton ND, et al. Hepatic artery pseudoaneurysms following liver transplantation: Incidence, presenting features and management. *Clinical Radiology*. 2001;**56**:579-587
- [46] Turrión VS, Alvira LG, Jimenez M, Lucena JL, Ardaiz J. Incidence and results of arterial complications in liver transplantation: Experience in a series of 400 transplants. *Transplantation Proceedings*. 2002;**34**:292-293
- [47] Leelaudomlipi S, Bramhall SR, Gunson BK, Candinas D, Buckels JA, McMaster P, et al. Hepatic-artery aneurysm in adult liver transplantation. *Transplant International*. 2003;**16**:257-261
- [48] Jarzembowski TM, Sankary HN, Bogetti D, Manzelli A, Ong E, Oberholzer J, et al. Living donor liver graft salvage after rupture of hepatic artery pseudoaneurysm. *International Surgery*. 2008;**93**:300-303
- [49] Panaro F, Miggino M, Bouyabrine H, Carabalona JP, Berthet JP, Canaud L, et al. Reversed saphenous bypass for hepatic artery pseudoaneurysm after liver transplantation. *Annals of Vascular Surgery*. 2013;**27**:1088-1097. DOI: 10.1016/j.avsg.2013.01.007
- [50] Charco R, Fuster J, Fondevila C, Ferrer J, Mans E, García Valdecasas JC. Portal vein thrombosis in liver transplantation. *Transplantation Proceedings*. 2005;**37**:3904-3905
- [51] Khalaf H. Vascular complications after deceased and living donor liver transplantation: A single-center experience. *Transplantation Proceedings*. 2010;**42**:865-870. DOI: 10.1016/j.transproceed.2010.02.037
- [52] Kyoden Y, Tamura S, Sugawara Y, Matsui Y, Togashi J, Kaneko J, et al. Portal vein complications after adult-to-adult living donor liver transplantation. *Transplant International*. 2008;**21**:1136-1144. DOI: 10.1111/j.1432-2277.2008.00752.x
- [53] Olcott EW, Ring EJ, Roberts JP, Ascher NL, Lake JR, Gordon RL. Percutaneous transhepatic portal vein angioplasty and stent placement after liver transplantation: Early experience. *Journal of Vascular and Interventional Radiology*. 1990;**1**:17-22
- [54] Kensinger CD, Sexton KW, Baron CM, Lipnik AJ, Meranze SG, Gordon DL. Management of portal vein thrombosis after liver transplantation with a combined open and endovascular approach. *Liver Transplantation*. 2015;**21**:132-134. DOI: 10.1002/lt.24011
- [55] Lodhia N, Salem R, Levitsky J. Transjugular intrahepatic portosystemic shunt with thrombectomy for the treatment of portal vein thrombosis after liver transplantation. *Digestive Diseases and Sciences*. 2010;**55**:529-534. DOI: 10.1007/s10620-009-0735-2
- [56] Schneider N, Scanga A, Stokes L, Perri R. Portal vein stenosis: A rare yet clinically important cause of delayed-onset ascites after adult deceased donor liver transplantation: Two case reports. *Transplantation Proceedings*. 2011;**43**:3829-3834. DOI: 10.1016/j.transproceed.2011.09.068

- [57] Wei BJ, Zhai RY, Wang JF, Dai DK, Yu P. Percutaneous portal venoplasty and stenting for anastomotic stenosis after liver transplantation. *World Journal of Gastroenterology*. 2009;**15**:1880-1885
- [58] Shibata T, Itoh K, Kubo T, Maetani Y, Shibata T, Togashi K, et al. Percutaneous transhepatic balloon dilation of portal venous stenosis in patients with living donor liver transplantation. *Radiology*. 2005;**235**:1078-1083
- [59] Zajko AB, Sheng R, Bron K, Reyes J, Nour B, Tzakis A. Percutaneous transluminal angioplasty of venous anastomotic stenoses complicating liver transplantation: Intermediate-term results. *Journal of Vascular and Interventional Radiology*. 1994;**5**:121-126
- [60] Sanada Y, Kawano Y, Mizuta K, Egami S, Hayashida M, Wakiya T, et al. Strategy to prevent recurrent portal vein stenosis following interventional radiology in pediatric liver transplantation. *Liver Transplantation*. 2010;**16**:332-339. DOI: 10.1002/lt.21995
- [61] Navarro F, Le Moine MC, Fabre JM, Belghiti J, Cherqui D, Adam R, et al. Specific vascular complications of orthotopic liver transplantation with preservation of the retrohepatic vena cava: Review of 1361 cases. *Transplantation*. 1999;**68**:646-650
- [62] Cavallari A, Vivarelli M, Bellusci R, Jovine E, Mazziotti A, Rossi C. Treatment of vascular complications following liver transplantation: Multidisciplinary approach. *Hepato-Gastroenterology*. 2001;**48**:179-183
- [63] Patel JV, Weston MJ, Kessel DO, Prasad R, Toogood GJ, Robertson I. Hepatic artery pseudoaneurysm after liver transplantation: Treatment with percutaneous thrombin injection. *Transplantation*. 2003;**75**:1755-1757
- [64] Golse N, Spina A, Abdelaal A, Mennesson N, Feugier P, Dumortier J, et al. Extra-anatomical hepatic artery reconstruction following post-embolization iatrogenic dissection and arterial anastomotic rupture in two liver transplant recipients. *Gastroentérologie Clinique et Biologique*. 2010;**34**:111-114. DOI: 10.1016/j.gcb.2009.11.003
- [65] Pawlak J, Grodzicki M, Leowska E, Małkowski P, Michałowicz B, Nyckowski P, et al. Vascular complications after liver transplantation. *Transplantation Proceedings*. 2003;**35**:2313-2315
- [66] Duffy JP, Hong JC, Farmer DG, Ghobrial RM, Yersiz H, Hiatt JR, et al. Vascular complications of orthotopic liver transplantation: Experience in more than 4,200 patients. *Journal of the American College of Surgeons*. 2009;**208**:896-903; discussion 903-905. DOI: 10.1016/j.jamcollsurg.2008.12.032
- [67] Pérez-Saborido B, Pacheco-Sánchez D, Barrera-Rebollo A, Asensio-Díaz E, Pinto-Fuentes P, Sarmentero-Prieto JC, et al. Incidence, management, and results of vascular complications after liver transplantation. *Transplantation Proceedings*. 2011;**43**:749-750
- [68] Steinbrück K, Enne M, Fernandes R, Martinho JM, Balbi E, Agoglia L, et al. Vascular complications after living donor liver transplantation: A Brazilian, single-center experience. *Transplantation Proceedings*. 2011;**43**:196-198. DOI: 10.1016/j.transproceed.2010.12.007
- [69] Uller W, Knoppke B, Schreyer AG, Heiss P, Schlitt HJ, Melter M, et al. Interventional radiological treatment of perihepatic vascular stenosis or occlusion in pediatric patients after liver transplantation. *Cardiovascular and Interventional Radiology*. 2013;**36**:1562-1571. DOI: 10.1007/s00270-013-0595-1

- [70] Parrilla P, Sánchez-Bueno F, Figueras J, Jaurieta E, Mir J, Margarit C, et al. Analysis of the complications of the piggy-back technique in 1,112 liver transplants. *Transplantation*. 1999;**67**:1214-1217
- [71] Sánchez-Bueno F, Hernández Q, Ramírez P, Robles R, Acosta F, Rodríguez JM, et al. Vascular complications in a series of 300 orthotopic liver transplants. *Transplantation Proceedings*. 1999;**31**:2409-2410
- [72] Woo DH, Laberge JM, Gordon RL, Wilson MW, Kerlan RK. Management of portal venous complications after liver transplantation. *Techniques in Vascular and Interventional Radiology*. 2007;**10**:233-239
- [73] Yilmaz A, Arikan C, Tumgor G, Kilic M, Aydogdu S. Vascular complications in living-related and deceased donation pediatric liver transplantation: Single center's experience from Turkey. *Pediatric Transplantation*. 2007;**11**:160-164
- [74] Orlandini M, Feier FH, Jaeger B, Kieling C, Vieira SG, Zanotelli ML. Frequency of and factors associated with vascular complications after pediatric liver transplantation. *Jornal de Pediatria*. 2014;**90**:169-175. DOI: 10.1016/j.jped.2013.08.010
- [75] Lerut J, Tzakis AG, Bron K, Gordon RD, Iwatsuki S, Esquivel CO, et al. Complications of venous reconstruction in human orthotopic liver transplantation. *Annals of Surgery*. 1987;**205**:404-414
- [76] Buell JF, Funaki B, Cronin DC, Yoshida A, Perlman MK, Lorenz J, et al. Long-term venous complications after full-size and segmental pediatric liver transplantation. *Annals of Surgery*. 2002;**236**:658-666
- [77] Strovski E, Liu D, Scudamore C, Ho S, Yoshida E, Klass D. Magnetic resonance venography and liver transplant complications. *World Journal of Gastroenterology*. 2013;**19**:6110-6113. DOI: 10.3748/wjg.v19.i36.6110
- [78] Goss JA, Shackleton CR, McDiarmid SV, Maggard M, Swenson K, Seu P, et al. Long-term results of pediatric liver transplantation: An analysis of 569 transplants. *Annals of Surgery*. 1998;**228**:411-420
- [79] Fernandez-Simon A et al. Sphincter of Oddi dysfunction after liver transplantation: Experience in a high volume transplant center. *Hepatology*. 2014;**60**:466
- [80] Weeks SM, Gerber DA, Jaques PF, Sandhu J, Johnson MW, Fair JH, et al. Primary gianturco stent placement for inferior vena cava abnormalities following liver transplantation. *Journal of Vascular and Interventional Radiology*. 2000;**11**:177-187
- [81] Darcy MD. Management of venous outflow complications after liver transplantation. *Techniques in Vascular and Interventional Radiology*. 2007;**10**:240-245
- [82] Yamagiwa K, Yokoi H, Isaji S, Tabata M, Mizuno S, Hori T, et al. Intrahepatic hepatic vein stenosis after living-related liver transplantation treated by insertion of an expandable metallic stent. *American Journal of Transplantation*. 2004;**4**:1006-1009
- [83] Lorenz JM, van Beek D, Funaki B, Van Ha TG, Zangan S, Navuluri R, et al. Long-term outcomes of percutaneous venoplasty and gianturco stent placement to treat obstruction of the inferior vena cava complicating liver transplantation. *Cardiovascular and Interventional Radiology*. 2014;**37**:114-124
- [84] Roos FJM, Poley J-W, Polak WG, Metselaar HJ. Biliary complications

after liver transplantation; recent developments in etiology, diagnosis and endoscopic treatment. *Best Practice & Research Clinical Gastroenterology*. 2017;**31**(2):227-235

[85] Verdonk RC, Buis CI, Porte RJ, Haagsma EB. Biliary complications after liver transplantation: A review. *Scandinavian Journal of Gastroenterology*. 2006;**41**(sup243):89-101

[86] Sotiropoulos GC, Sgourakis G, Radtke A, Molmenti EP, Goumas K, Mylona S, et al. Orthotopic liver transplantation: T-tube or not T-tube? Systematic review and meta-analysis of results. *Transplantation*. 2009;**87**(11):1672-1680

[87] Lefkowitz JH. *The Liver in Organ Transplantation*. WB Saunders; 2000. *Scheuer's Liver biopsy interpretation*. Elsevier

[88] Potthoff A, Hahn A, Kubicka S, Schneider A, Wedemeyer J, Klempnauer J, et al. Diagnostic value of ultrasound in detection of biliary tract complications after liver transplantation. *Hepatitis Monthly*. 2013;**13**(1):6003. DOI: 10.5812/hepatmon.6003

[89] Jorgensen JE, Waljee AK, Volk ML, Sonnenday CJ, Elta GH, Al-Hawary MM, et al. Is MRCP equivalent to ERCP for diagnosing biliary obstruction in orthotopic liver transplant recipients? A meta-analysis. *Gastrointestinal Endoscopy*. 2011;**73**(5):955-996

[90] Chahal P, Baron TH, Poterucha JJ, Rosen CB. Endoscopic retrograde cholangiography in post-orthotopic liver transplant population with roux-en-Y biliary reconstruction. *Liver Transplantation*. 2007;**13**(8):1168-1173

[91] Devière J, Reddy DN, Püspök A, Ponchon T, Bruno MJ, Bourke MJ, et al.

Successful management of benign biliary strictures with fully covered self-expanding metal stents. *Gastroenterology*. 2014;**147**(2):385-395

[92] Balderramo D, Sendino O, Burrel M, Real MI, Blasi A, Martinez-Palli G, et al. Risk factors and outcomes of failed endoscopic retrograde cholangiopancreatography in liver transplant recipients with anastomotic biliary strictures: A case-control study. *Liver Transplantation*. 2012;**18**(4):482-489

[93] Pascher A, Neuhaus P. Biliary complications after deceased-donor orthotopic liver transplantation. *Journal of Hepato-Biliary-Pancreatic Surgery*. 2006;**13**(6):487-496

[94] Kanazawa A, Kubo S, Tanaka H, Takemura S, Yamazaki K, Hirohashi K, et al. Bile leakage after living donor liver transplantation demonstrated with hepatobiliary scan using 9mTc-PMT. *Annals of Nuclear Medicine*. 2003 Sep;**17**(6):507-509

[95] Thuluvath PJ, Pfau PR, Kimmey MB, Ginsberg GG. Biliary complications after liver transplantation: The role of endoscopy. *Endoscopy*. 2005;**37**(9):857-863

[96] Shah JN, Haigh WG, Lee SP, Lucey MR, Brensinger CM, Kochman ML, et al. Biliary casts after orthotopic liver transplantation: Clinical factors, treatment, biochemical analysis. *The American Journal of Gastroenterology*. 2003;**98**(8):1861-1867

[97] Voigtlander T et al. Biliary cast syndrome post-liver transplantation: Risk factors and outcomes. *Liver International*. 2013;**33**:1287-1292

[98] Copstead L-EC, Banasik JL. *Pathophysiology*. 5th ed. USA: Elsevier Saunders; 2013:204-205

[99] Grossman S, Mattson C. *Porth's Pathophysiology: Concepts of Altered*

Health States. 9th ed. USA: Wolters Kluwer; 2013:350-353

[100] Irwin RS, Rippe JM. Irwin & Rippe's Intensive Care Medicine. 8th ed. USA: Wolters Kluwer; 2018:587-589

[101] Parrillo JE, Phillip Dellinger R. Critical Care Medicine: Principles of Diagnosis and Management in the Adult. 5th ed. Philadelphia: Elsevier; 2019:1188-1190

[102] Layon AJ, Mihae Y, Gabrielli A, Wood KE. Civetta, Taylor & Kirby's Critical Care. 5th ed. Wolters Kluwer; 2017:833-835

[103] Moore DE, Feurer ID, Speroff T, Gorden DL, Wright JK, Chari RS, et al. Impact of donor, technical, and recipient risk factors on survival and quality of life after liver transplantation. *Archives of Surgery*. 2005;**140**(3):273

[104] Fernández-Merino FJ, Nuño-Garza J, López-Hervás P, López-Buenadicha A, Moreno-Caparrós A, Quijano-Collazo Y, et al. Impact of donor, recipient, and graft features on the development of primary dysfunction in liver transplants. *Transplantation Proceedings*. 2003;**35**(5):1793

[105] Condron SL, Heneghan MA, Patel K, Dev A, McHutchison JG, Muir AJ. Effect of donor age on survival of liver transplant recipients with hepatitis C virus infection. *Transplantation*. 2005;**80**(1):145

[106] Cuende N, Miranda B, Cañón JF, Garrido G, Matesanz R. Donor characteristics associated with liver graft survival. *Transplantation*. 2005;**79**(10):1445

[107] Sánchez-Perez B, Santoyo J, Fernández-Aguilar JL, Suárez MA, Pérez JA, Jiménez M, et al. Preoperative factors and models predicting mortality in liver transplantation.

Transplantation Proceedings. 2005;**37**(3):1499

[108] Totsuka E, Fung U, Hakamada K, Tanaka M, Takahashi K, Nakai M, et al. Analysis of clinical variables of donors and recipients with respect to short-term graft outcome in human liver transplantation. *Transplantation Proceedings*. 2004;**36**(8):2215

[109] Corradini SG, Elisei W, De Marco R, Siciliano M, Iappelli M, Pugliese F, et al. Preharvest donor hyperoxia predicts good early graft function and longer graft survival after liver transplantation. *Liver Transplantation*. 2005;**11**(2):140

[110] Zapletal Ch FD, Wullstein C, Woeste G, Caspary WF, Golling M, Bechstein WO. Does the liver ever age? Results of liver transplantation with donors above 80 years of age. *Transplantation Proceedings*. 2005;**37**(2):1182

[111] Pirenne J, Monbaliu D, Van Gelder F, Van Hees D, Aerts R, Verslype C, et al. Liver transplantation using livers from septuagenarian and octogenarian donors: An underused strategy to reduce mortality on the waiting list. *Transplantation Proceedings*. 2005;**37**(2):1180

[112] Santori G, Andorno E, Morelli N, Gianelli Castiglione A, Casaccia M, Saltalamacchia L, et al. Impact of ischemia/reperfusion on transplanted livers procured from elderly cadaveric donors. *Transplantation Proceedings*. 2004;**36**(10):2909

[113] Halazun KJ, Quillin RC, Rosenblatt R, Bongu A, Griesemer AD, Kato T, et al. Expanding the margins: High volume utilization of marginal liver grafts among >2000 liver transplants at a single institution. *Annals of Surgery*. 2017;**266**(3):441

[114] Hernández MP, Martin P, Simkins J. Infectious complications after

liver transplantation. *Gastroenterology & Hepatology*. 2015;**11**(11):741-753

[115] Timsit J-F, Sonnevile R, Kalil AC. Diagnostic and therapeutic approach to infectious diseases in solid organ transplant recipients. *Intensive Care Medicine*. 2019;**45**:573-591

[116] Baganate F, Beal EW, Tumin D, et al. Early mortality after liver transplantation: Defining the course and the cause. *Surgery*. 2018;**164**:694

[117] Torbenson M, Wang J, Nichols L, et al. Causes of death in autopsied liver transplantation patients. *Modern Pathology*. 1998;**11**:37

[118] Fishman JA. Infection in organ transplantation. *American Journal of Transplantation*. 2017;**17**:856-879

[119] Colonna JO 2nd, Winston DJ, Brill JE, et al. Infectious complications in liver transplantation. *Archives of Surgery*. 1988;**123**:360

[120] Kim YJ, Kim SI, Wie SH, et al. Infectious complications in living-donor liver transplant recipients: 9-year single-center experience. *Transplant Infectious Disease*. 2008;**10**:316

[121] Singh N, Wagener MM, Gayowski T. Seasonal pattern of early mortality and infectious complications in liver transplant recipients. *Liver Transplantation*. 2001;**7**:884

[122] Chang FY, Singh N, Gayowski T, et al. Fever in liver transplant recipients: Changing spectrum of etiologic agents. *Clinical Infectious Diseases*. 1998;**26**:59

[123] Fishman JA. From the classic concepts to modern practice. *Clinical Microbiology and Infection*. 2014;**20**(Suppl 7):4

[124] Van Duin D, van Delden C. AST infectious diseases community of practice. Multidrug-resistant gram-negative bacteria infections in solid

organ transplantation. *American Journal of Transplantation*. 2013;**13**(Suppl 4):31

[125] Kusne S, Dummer JS, Singh N, et al. Infections after liver transplantation. An analysis of 101 consecutive cases. *Medicine (Baltimore)*. 1988;**67**:132

[126] Paya CV, Wiesner RH, Hermans PE, et al. Risk factors for cytomegalovirus and severe bacterial infections following liver transplantation: A prospective multivariate time-dependent analysis. *Journal of Hepatology*. 1993;**18**:185

[127] Fishman JA, Rubin RH. Infection in organ-transplant recipients. *The New England Journal of Medicine*. 1998;**338**:1741

[128] Riddle DJ, Dubberke ER. *Clostridium difficile* infection in solid organ transplant recipients. *Current Opinion in Organ Transplantation*. 2008;**13**:592

[129] Doron S, Ruthazer R, Werner BG, et al. Hypogammaglobulinemia in liver transplant recipients: Incidence, timing, risk factors, and outcomes. *Transplantation*. 2006;**81**:697

[130] Husain S, Tollemar J, Dominguez EA, et al. Changes in the spectrum and risk factors for invasive candidiasis in liver transplant recipients: Prospective, multicenter, case-controlled study. *Transplantation*. 2003;**75**:2023

[131] Herrero JI. De novo malignancies following liver transplantation: Impact and recommendations. *Liver Transplantation*. 2009;**15**(suppl 2):S90-S94

[132] Charlton M. Obesity, hyperlipidemia, and metabolic syndrome. *Liver Transplantation*. 2009;**15**(suppl 2):S83-S89

[133] Montoro MA, García Pagán JC, Castells A, Gomollón F, Mearin F,

Panés J, et al. Gastroenterology and Hepatology. Commons Problems in the Clinic Practice. 2nd ed. Madrid: Jarpyo Editores; 2012:1005-1016. ISBN: 978-84-92982-31-9

[134] Mc Guire BM, Rosenthal P, Brown CC, Busch AM, Calcaterra SM, Claria RS, et al. Long-term management of the liver transplant patient: Recommendations for the primary care doctor. American Journal of Transplantation. 2009 Sep;9(9):1988-2003. DOI: 10.1111/j.1600-6143.2009.02733.x

[135] Charlton MR, Wall WJ, Ojo AO, Ginès P, Textor S, Shihab FS, et al. Report of the first international liver transplantation society panel consensus conference on renal insufficiency in liver transplantation. Liver Transplantation. 2009;15:S1S34

[136] Guichelaar MMJ, Schmoll J, Malinchoc M, Hay JE. Fractures and avascular necrosis before and after orthotopic liver transplantation: Long-term follow-up and predictive factors. Hepatology. 2007;46:1198-1207

[137] European Liver Transplant Registry. Available from: <http://www.eltr.org>

[138] Watt KDS, Pedersen RA, Kremers WK, Heimbach JK, Charlton MR, et al. Evolution of causes and risk factors for mortality post liver transplant: Results of the NIDDK long term follow up study. American Journal of Transplantation. 2010;10:1420-1427

[139] Karam V, Castaing D, Danet C, Delvart V, Gasquet I, Adam R, et al. Longitudinal prospective evaluation of quality of life in adult patients before and one year after liver transplantation. Liver Transplantation. 2003;9:703-711