

We are IntechOpen, the world's leading publisher of Open Access books Built by scientists, for scientists

6,900

Open access books available

186,000

International authors and editors

200M

Downloads

Our authors are among the

154

Countries delivered to

TOP 1%

most cited scientists

12.2%

Contributors from top 500 universities



WEB OF SCIENCE™

Selection of our books indexed in the Book Citation Index
in Web of Science™ Core Collection (BKCI)

Interested in publishing with us?
Contact book.department@intechopen.com

Numbers displayed above are based on latest data collected.
For more information visit www.intechopen.com



Preventing Rupture: Clipping of Unruptured Intracranial Aneurysms

*Ioan Alexandru Florian, Teodora Larisa Timis,
Cristina Caterina Aldea and Ioan Stefan Florian*

Abstract

Unruptured intracranial aneurysms (UIAs) represent a major public health issue due to their unpredictable natural history. Whether to actively treat them or to maintain them under observation remains a hotly disputed topic. In this chapter, we present a review of the literature regarding the history of clipping and its use in UIAs, as well as the experience of our senior author in this field. We performed an extensive Medline and Google Academic search of the relevant literature. We have also made a retrospective analysis on patients harboring UIAs and multiple intracranial aneurysms (MIAs) clipped by the senior author between 1997 and 2017. About 89 patients had solitary UIAs, alongside 101 with MIAs possessing 257 individual aneurysms in total. All UIA patients were discharged with a favorable neurological outcome and no mortality. Concerning MIAs, the majority of cases had 2 aneurysms, the highest number being 6. And, 61 patients from this group had a favorable outcome. In the hands of experienced vascular neurosurgeons, clipping remains a safe option for both UIAs and MIAs. This procedure offers a long-lasting protection from aneurysmal rupture. In the future, new clip technologies and intraprocedural methods of verifying vessel patency and aneurysmal occlusion may further enhance postoperative results.

Keywords: intracranial aneurysm, multiple aneurysms, unruptured, surgery, clipping

1. Introduction

Once considered as the definitive curative option for intracranial aneurysms (IAs), clipping has steadily lost its footing in the face of the less invasive and lower-risk-laden endovascular procedures. Successful clipping implies completely occluding the aneurysmal sack at its origin on the parent artery, significantly diminishing the risk of rupture and ensuing morbidity. The procedure is especially indicated for ruptured aneurysms. However, there is ongoing debate regarding the necessity for surgery in the case of unruptured intracranial aneurysms (UIAs). Since many of these patients also harbor more than one aneurysm, another controversial aspect in neurosurgery is whether to treat all aneurysms in the same session or to leave the unruptured lesions for a delayed intervention or even for an endovascular

procedure. In this chapter, we present our considerable experience and attitude in the surgical management of unruptured and multiple aneurysms.

Preventing rupture from IAs represents a major concern for neurosurgeons, neuroradiologists, and neurointerventionists, as this represents a catastrophic and potentially life-threatening occurrence in the natural history of this pathology. UIAs are defined as not possessing a known history or signs of rupture or that have been diagnosed incidentally for symptoms unrelated to intracranial hemorrhage. They are a veritable “ticking time bomb” that, under certain conditions, can “detonate” and cause a devastating hemorrhagic stroke with severe and often irreversible consequences. Therefore, preventive surgical treatment of UIAs, especially clipping of the aneurysmal sack, is a valuable and possibly life-saving option.

A successful clipping means that the vascular clip completely isolates the aneurysmal lumen from blood flow at its origin on the parent artery. This point of origin is generally located at either a bifurcation or a sharp turn of an artery. Surgical clipping may prevent rupture of that particular aneurysm, although an incomplete occlusion can result in recurrence. Since the development of less invasive endovascular techniques, clipping has lost most of its standing in the treatment of UIAs, being reserved for hemorrhagic lesions or those otherwise unsuitable for endovascular procedures. Certain highly experienced centers still favor the intracranial approach for UIAs due to the longevity of procedure and excellent postoperative neurological outcome.

Additionally, some patients may harbor more than one aneurysm, occurring either concomitantly or sequentially. These may be diagnosed incidentally, during the rupture of at least one of the aneurysms or at a variable point in time during postprocedural control. The treatment of multiple intracranial aneurysms (MIAs) to this day remains a highly debated topic, lacking a general consensus regarding indications, timing, and modality. Our experience supports the single-stage single-opening surgical treatment of multiple UIAs.

2. Short history and evolution of aneurysm surgery

Although the pathology of intracranial aneurysms had been scrupulously studied by the beginning of the twentieth century, treatment options were scarce and most often fruitless [1]. Harvey Cushing (1869–1939) himself doubted whether these lesions could be approached surgically due to the technical limitations, reduced accessibility and visibility of the lesions, as well as a general lack of experience in the surgical community [1–3]. Up until that point, the treatment of intracranial aneurysms relied on the proximal ligation technique, as described by John Hunter (1728–1793). This resulted in thrombosis and occlusion inside the aneurysm. In 1885, Sir Victor Horsley (1857–1916) was reportedly the first to successfully perform such an intervention for an intracranial aneurysm by ligating the right common carotid artery [1, 2, 4]. Cushing is credited with developing the wrapping technique for the treatment of intracranial aneurysms; however, in 1931 his pupil, Dott Norman McComish (1897–1973), performed the first elective frontal craniotomy in order to wrap and reinforce a ruptured aneurysm with autologous muscle from the patient’s thigh [3–5]. Axel Herbert Olivecrona (1891–1980) was the first to perform a successful surgical trapping and removal of an intracranial aneurysm in 1932, a technique then further elaborated by Walter Dandy (1886–1946) [5]. In 1937, Dandy used a modified version of the Cushing clip to occlude a posterior communicating artery (PCoA) aneurysm via a “hypophyseal approach,” being the first ever documented intervention of its kind [1, 2–5].

Since then, aneurysm clipping has undergone extensive improvements in both technique and instrumentation. The Cushing clip was malleable; however, according to Kenneth George McKenzie (1892–1964), the two sides of the clips were frequently of unequal length, had rough ends, and had a habit of turning in the holder [6]. Furthermore, it could not be reopened or repositioned; thus, an improper placement could compromise the entire intervention [5]. In 1927, McKenzie conceived a more versatile alternative to the instruments used [6–9]. In 1949, Duane William Jr. changed the McKenzie-modified clip holder to punch out more effective U-shaped clips [5]. Olivecrona made a considerable redesign of the clips in 1953 that allowed reopening and repositioning of the clips [4, 5, 9]. However, the drawback to these clips were crushing the aneurysmal neck and producing shearing and tearing of the fragilized vascular walls. Thus, Henry Schwartz introduced the cross-action alpha clip, basically a miniaturized spring forceps that could close by itself [3, 5, 9]. Despite this concept being brilliant, its utilization in aneurysm surgery was problematic due to its large size and the bulkiness of its applicator. In 1952, Frank Mayfield and George Kees Jr. made delicate yet crucial enhancements to clip technology, significantly reducing the size of the shank, while also constructing clips of diverse lengths and angles, as well as having wider blade openings [3–5, 9–11]. They were also responsible for the bayoneted design of the clip that would permit better visualization during manipulation. Joseph McFadden suggested a modification of Kees' design, with rounded blades and blunted tips [3, 11].

Charles Drake (1920–1998) was credited with developing the fenestrated clip in 1969, which could allow placement of the clips on more inaccessible aneurysms without compromising the parent vessel [1, 3, 4]. This was especially useful for treating posterior fossa aneurysms, for which Drake also pioneered innovative techniques and surgical approaches (such as the subtemporal approach for aneurysms of the basilar apex) [4]. George Smith (1916–1964) also made an essential innovation with a vessel-encompassing clip that could occlude aneurysms on the opposite side of the affected artery [3, 12]. Elaborating on this concept, Thoralf Sundt (1930–1992) devised a Teflon-lined clip-graft that could also mend small tears or irregularities in the artery [1, 3–5, 12, 13]. At present, adjustments are still made regarding configuration, instrumentation, and clip composition.

The next most important bound in aneurysm surgery came in the form of the operating microscope, allowing better visualization and illumination of the aneurysm neck and surrounding vessels [1, 4, 5, 14]. Gazi Yasargil, the father of microneurosurgery, had probably the greatest contribution in this field by not only standardizing the use of the operating microscope in aneurysm surgery but also by developing and refining procedures and instruments now commonly used in vascular neurosurgery [1, 3, 4]. The clips he created were specifically designed for use alongside microscopic magnification. Moreover, he also underscored the necessity of understanding cisternal and microvascular anatomy in neurosurgery. Drake's seemingly most remarkable addition to vascular neurosurgery was comprehending the intricate anatomy of posterior circulation aneurysms, as well as improving outcomes following their surgical treatment [4, 5]. Magnetic resonance imaging (MRI) became crucial in the diagnosis of cerebrovascular pathologies. Although, since the first clips introduced in neurosurgery were made of stainless steel, they were not compatible with MRI. After rigorous compatibility testing, Robert Spetzler introduced the pure titanium clips as a nonferromagnetic alternative with the same mechanical properties as other clips available at that time [4, 5, 15, 16].

Yasargil also described the end-to-side anastomosis between the superficial temporal artery and middle cerebral artery (MCA), which bypassed the blood

flow from the extracranial circulation to the intracranial compartment [5]. The bypass techniques are currently used in the management of more complex giant aneurysms, however with less satisfactory outcomes than the standard surgical approaches for smaller aneurysms [5, 17]. A more recent advancement has been the introduction of intraoperative videoangiography by means of fluorescent dyes such as fluorescein sodium or indocyanine green [18]. Charles Wrobel first described this method in 1994 for real-time testing of aneurysmal obliteration and the patency of adjacent arteries [5, 19]. This tool renders intraoperative catheter-based angiography or Doppler ultrasonography obsolete in certain cases and allows repositioning of inconveniently placed clips before the onset of permanent damage [5, 18–20]. Other contemporary innovations include the endoscopic endonasal approaches in order to clip skull base aneurysms; however, this technique awaits further validation [5, 21–23].

Evidently, not all aneurysms were amenable to clipping. Before the dawn of endovascular procedures, surgeons attempted various methods of introducing foreign materials into the aneurysm sack to achieve thrombosis, with variable results. The materials ranged from heated silver enameled wire [24], copper wire [25], and silk sutures [26], to magnetically guided iron suspensions [27] to even animal hair from horse or dog [28]. Despite these techniques being mostly obsolescent, they indisputably paved the way to endovascular treatment of intracranial vasculopathies. The most important step in this direction belonged to the invention of the angiography as a superior instrument for diagnosing intracranial pathologies. The first cerebral angiography was performed by Egas Moniz (1874–1955) in 1927, a technique which remained the only dependable diagnostic method for identifying intracranial lesions until the introduction of computed tomography (CT) nearly 50 years later [1, 4, 29–31]. Fascinatingly enough, an editorial published in *The Lancet* in 1931 predicted the probability of not only diagnosing intracranial aneurysms through this tool but also as an opportunity for therapy in later years [1, 29]. The endovascular coils presently used were preceded by detachable balloons that could be deployed inside vascular lesions and would harden to result in a controlled localized thrombosis [1, 4, 32]. However, this technique resulted in significant complications and was soon replaced. The first successful treatment of an intracranial aneurysm via coiling belonged to Ira Braun in 1985 [1, 4]. Guido Guglielmi undoubtedly had the most significant role in developing modern coils that were electrolytically detachable [33–35].

Ever since, the role of microneurosurgery in the treatment of aneurysms has diminished in the face of a safer, easier, less invasive, and satisfyingly durable procedure with a shorter hospital stay and faster recovery time [36–38]. Many other endovascular techniques and tools have been elaborated in the wake of this innovation the technology experiencing an exponential growth. A thorough description of such instruments is beyond the scope of this chapter. In what follows, we detail the microsurgical treatment options for unruptured solitary and multiple aneurysms, with a special emphasis on clipping, its effects, outcome, and consequences while also sharing our operative experience.

3. Natural history of unruptured aneurysms

To quote physicist Niels Bohr (1885–1962), “Prediction is very difficult, especially about the future.” This also applies to UIAs regarding what can cause them to bleed and when. There is a high variability between populations in the prevalence of UIAs, being cited between 1% and as much as 7% of the general population [39–42]. They are more commonly found in the anterior circulation,

at more advanced ages, and more often in women. The natural history seems to differ according to the shape, location, and size of the lesion, with a significant incongruity between the number of incidentally discovered aneurysms each year (2000–4000 per 100,000 persons/year) and the annual incidence of aneurysmal subarachnoid hemorrhage (aSAH) (approximately 10 per 100,000 persons/year) [43]. In other words, out of 200 to 400 patients diagnosed yearly with an intracranial aneurysm, chances are that only one of these may rupture. The annual and cumulative risk of rupture has been appraised at approximately 1%/year and at 9% at 9 years for the Japanese and Korean populations [44], similar to that of Western countries (0.2–1.6%/year and 10% at 10 years) [45–48]. Factors attributed to impact the natural history of UIAs may be related to the aneurysm itself, the patient, or even external influences.

Concerning patient-related factors, it seems that women have a higher prevalence of UIAs than men, and the peak incidence was found between the fifth and sixth decades of age. Patients with polycystic kidney disease, type IV Ehlers-Danlos syndrome, and Marfan syndrome are more likely to develop UIAs during their lifetime. Hypertension is the comorbidity most likely associated with this finding, while a positive family history is also an important risk factor among siblings. Up to 15–30% of these patients harbor at least two UIAs, either concomitantly or sequentially. The most common modifiable risk factors attributed to UIAs are smoking, alcohol and drug abuse, as well as using oral contraceptives [49].

According to the results of the PHASE 2 of the International Study of Unruptured Intracranial Aneurysms (ISUIA) trial, patients that had no previous aSAH and harbored aneurysms under 7 mm in diameter possessed no risk of rupture for UIAs in the anterior circulation [50]. However, the risk of bleeding was 2.5%/year for aneurysms located at the PCoA and the posterior cerebral circulation. Concerning patients with a history of aSAH, the risk of rupture for aneurysms smaller than 7 mm in the anterior cerebral circulation reached 1.5%/year, whereas for the posterior circulation, it rose to 3.4%/year. Similarly, the Unruptured Cerebral Aneurysm Study (UCAS) performed in Japan proved that size influenced the risk of rupture, starting from 0.36% for microaneurysms (between 3 and 4 mm), climbing at 4.37% for lesions between 10 to 24 mm to reaching as much as 33.4% for giant aneurysms (≥ 25 mm) [42]. Analogous results were also reported for the South Korean population [44]. Apparently, as an aneurysm swells, the risk of subsequent rupture rises [51]. However, according to Serrone et al., the single predictor of aneurysm enlargement was the initial size of the lesion, with the annual risk of growth being evaluated at a mean of 3.5%, though higher for larger aneurysms [52]. The morphology of the aneurysm was also incriminated in influencing the risk of rupture, especially the formation of a daughter sac, the shape of the sac, and regions possessing a thinned arterial wall [53]. Pertaining to UIAs selected for conservative treatment, Ramachandran stated that “None of the metrics—including aneurysm size, nonsphericity index, peak wall tension, and low shear stress area—differentiated the stable from unstable groups with statistical significance,” suggesting that there might not actually be such a thing as a “stable” intracranial aneurysm [54].

Aneurysmal rupture can also occur during stressful or strenuous activities such as sexual intercourse, labor, defecation, physical exertion, or sports [55]. However, these external factors may in fact conceal the climate impact, as numerous studies indicate a higher incidence of aneurysm rupture during the winter season, as well as during daytime [56–59]. Our experience of operated aneurysms also supports this statement, as illustrated in **Figure 1**.

In summary, the natural history of aneurysms is complicated and shrouded in uncertainty, except for one surety: UIAs do not spontaneously heal.

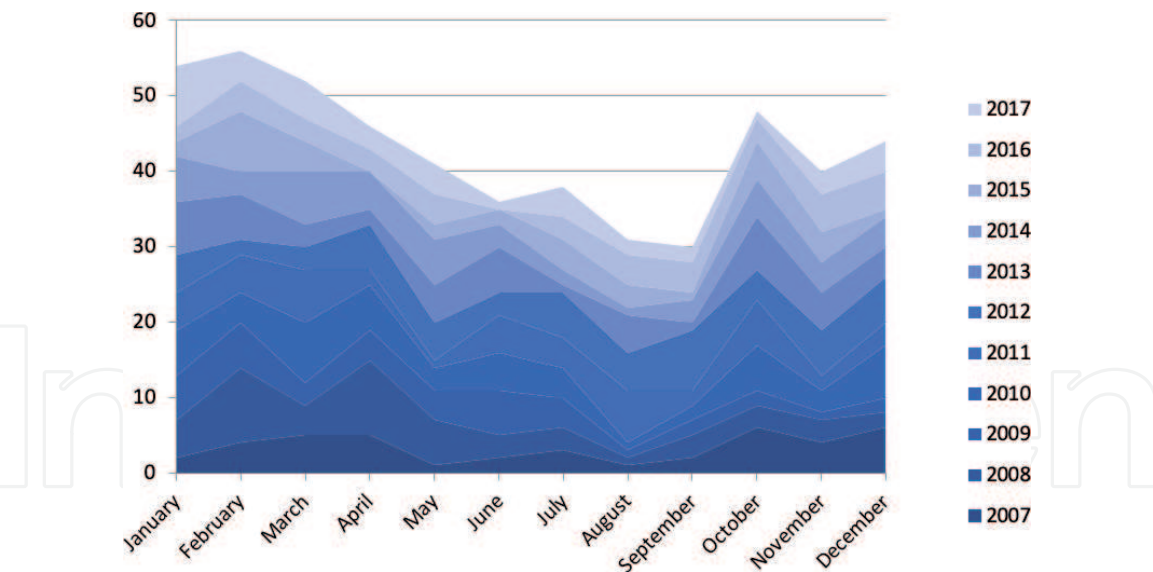


Figure 1.
Multiannual incidence of aneurysmal rupture, as hospitalized and surgically treated in our institution between January and December 2017.

4. Treatment strategies

The purpose of active treatment for UIAs is to permanently and safely occlude the aneurysmal lumen while preserving the normal cerebral vasculature. In order to achieve this, two types of approaches have been conceived: surgical (via craniotomy), which includes clipping and bypass procedures, or endovascular. As certain lesions cannot be safely and efficiently removed from arterial circulation either by clipping or by endovascular procedures, bypass surgery has been elaborated to remove the aneurysm and its parent vessel, without sacrificing arterial supply to the involved tissues.

Currently, there are no controlled randomized studies that single out the superior form of treatment for UIAs. Optimal treatment should focus on the following aspects:

- Age and clinical features of the patient
- Anatomy, size, and location of the aneurysm
- Institutional and personal experience in a certain field
- Technical capabilities of the facility

Since the majority of studies in the reported literature are retrospective in nature, they may suffer from bias. As of yet, the best sources of information regarding the outcome of UIA treatment originate from comparative studies between natural history and complication rates of certain therapies [60]. As our surgical experience exceeds that of endovascular procedures, as well as our standing concerning its importance in the prevention of rupture, we will exclusively present the technical breakdown of aneurysm clipping, according to our practice.

5. Aneurysm clipping: technical breakdown

Although seemingly easy in theory, placing a clip at the neck of the aneurysm (i.e., its point of origin) represents a genuine surgical challenge because of the need

to preserve the anatomical and functional integrity of the normal vasculature, brain parenchyma, and cranial nerves. This not only implies a good proximal control of the arteries but also adequate exposure of the aneurysm and the vessels, beginning with the craniotomy. In the following paragraphs, we describe the key points of aneurysmal clipping.

5.1 Positioning

This is a crucial stage that can either facilitate or hinder the surgical intervention. The patient is placed in a dorsal decubitus. The patient's head should be positioned so that the planned craniotomy is easy to perform, while ensuring that there is no substantial jugular compression (i.e., if the head is rotated excessively to one side) or that proper ventilation is not impeded (i.e., much too little distance between the tip of the mandible and the sternum). The head can be immobilized by a headholder, if this does not hamper venous drainage. We recommend shaving the head, or at the very least the area around the incision, to minimize the risk of infection. Using cutaneous antiseptics such as iodine solution or chlorhexidine, the skin must be thoroughly cleansed, with special attention toward the auricle and the external ear canal.

5.2 Surgical exposure

The skin incision should always be larger than the bone opening, considering the possible need to enlarge the craniotomy. A wide enough craniotomy must be performed for an ideal surgical exposure. Brain relaxation increases visibility and motility, while also diminishing the risk of damaging the brain and vessels. This is vital for certain aneurysms, especially of the skull base (internal carotid artery (ICA), anterior communicating artery (AcoA), basilar apex, etc.) or when attempting to clip mirror aneurysms during the same opening. There are a few methods to achieve brain relaxation, such as hyperventilation, cerebrospinal fluid (CSF) drainage (realized via lumbar drainage or ventriculostomy), intracisternal drainage (the most effective form of intraoperative brain relaxation in our experience, performed by opening the basal cisternae and the Sylvian valley), or with intravenous diuretics (mannitol or furosemide).

5.3 Craniotomy

The bone opening should be entirely adapted to the location, size, and morphology of the aneurysm. It must be able to reveal the Circle of Willis and be spacious enough to allow the exploration of the main blood vessels. The most commonly used craniotomy for aneurysms of the anterior circulation and of the basilar apex is the frontolateral approach as described by Samii, the classical pterional opening being used in MCA aneurysms and for contralateral clipping in the case of multiple aneurysms. A burr hole is placed at the orbitofrontal angle (keyhole), being careful not to open the orbit or the frontal sinus (if it is large enough to reach this point). The craniotome can then be used to complete the flap. Additional burr holes may be needed. In the classical pterional approach, the sphenoid wing should be drilled as close as possible to the anterior cranial fossa. In the event of a tensioned dura, slight elevation of the head and opening the lumbar drainage will result in proper brain relaxation.

5.4 Dura mater incision

The dura can be opened in a cross-shape or a C shape. We favor the latter, leaving the tip of the convexity upward and at least 2 cm above the sphenoid bone. By

suspending the dural flap, we ensure a wide enough opening. The rest of the dura is left in place to protect the brain.

5.5 Arachnoidal dissection

Although sometimes difficult due to extensive adhesions, this step is mandatory for exploring the optochiasmatic region. The opening in the Sylvian valley is made just above the ipsilateral optic nerve, the most constant landmark and the place where the arachnoid is the furthest from the cortex. Next, the opening is extended both laterally and medially using a thin aspirator and microsurgical scissors. Evacuation of the CSF will further relax the brain and offer a large operating field. Dissection resumes medially for ACoA aneurysms and laterally for PCoA aneurysms, whereas it continues along the artery itself for internal carotid artery lesions. Once the valley has been opened, the bifurcation of the ICA is visible, and the neck of the aneurysm can be distinguished. The neck is then dissected and isolated from the surrounding normal vasculature. For middle cerebral artery aneurysms, the ICA should be dissected laterally, as well as the proximal portion of the MCA. This type of opening has some drawbacks, as it first brings the surgeon to the tip of the aneurysmal sac and the proximal control is lacking at this moment. But a delicate dissection proximal to the aneurysm will shortly offer the visibility over the M1 segment, where a temporary clip could be safely placed. The interoptic triangle allows access toward basilar apex aneurysms; however, accessing the neck of the aneurysm itself is much more challenging, especially since the first element that “greet” the surgeon in this approach is the aneurysmal fundus.

The parent vessel has to be exposed proximally to the aneurysm to ensure blood flow control in the case of intraoperative rupture. The main vessel should be adequately exposed before the neck of the aneurysm, which, in turn, should be dissected before the fundus. The perforators adjacent to the lesion must be separated from the neck before placing the permanent clip. If the aneurysm sac is too wide and complex to be clipped, prudent use of the bipolar coagulator can adjust its diameter. Immediately after the clip is placed, the permeability of surrounding vessels and perforators must be demonstrated. If intraoperative rupture occurs, lowering arterial pressure, tamponing, temporary clipping of parent vessel, and aspirating the aneurysmal sac will favor neck definition and placement of definitive clip.

5.6 Clipping

Once the aneurysm has been successfully dissected from the surrounding vessels, a permanent clip is placed at the aneurysmal neck. It has to be parallel to the parent artery in order to avoid stretching or occluding it. The length and shape of the clip should be adapted to the morphology of the aneurysm and must trap the neck entirely, without also trapping perforators or adjacent structures. Sometimes, it is necessary to reduce the volume of the aneurysm by applying a temporary clip proximal to the aneurysm. Timing in this step is crucial, as more than 10 min of temporary occlusion of a major vessel such as the MCA or ICA can lead to severe consequences. Once the aneurysm has shrunk enough, the permanent clip can be carefully applied (**Figure 2**).

5.7 Intraoperative aneurysmal rupture (IAR)

This is a dreadful but preventable incident, more hazardous if it occurs early, such as during induction of anesthesia or while opening of the dura. Arguably

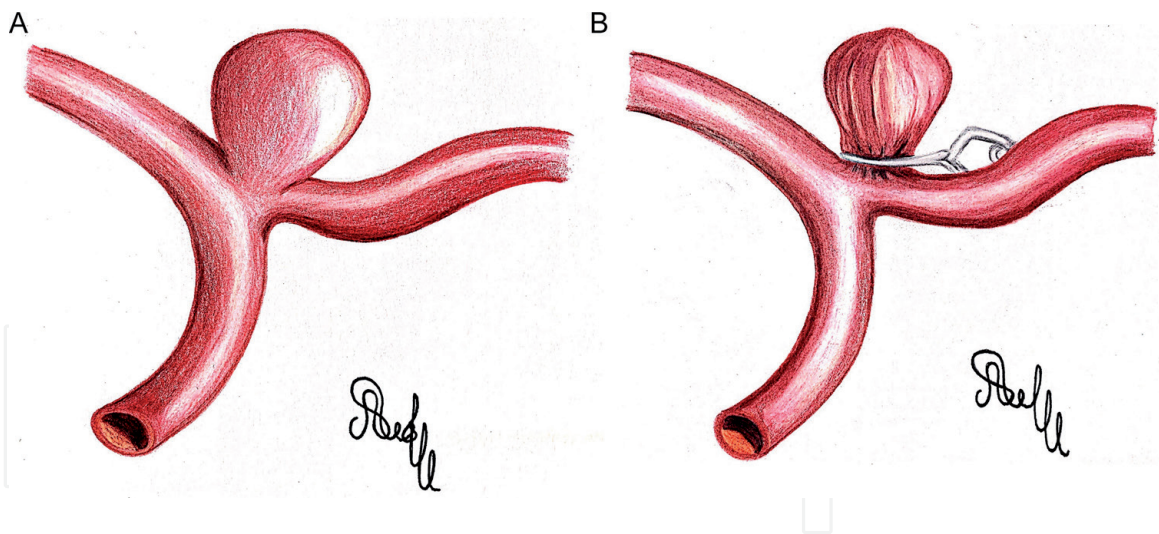


Figure 2.
Representation of an unruptured aneurysm before (A) and after clipping (B) (drawings provided by the first author of this chapter).

the most challenging of IARs may be those of basilar apex aneurysms. The aims in this scenario are hemostasis, avoiding further aneurysmal damage, preventing accidental injury to main vessels and perforators, and, finally, clipping the aneurysm. Certain steps should be followed to avoid IAR: careful positioning of the head to minimize brain traction; vigilant induction of anesthesia and ensuring that hypertension bouts do not occur; a sufficiently wide craniotomy that guarantees appropriate access, as well as adequate brain relaxation (using diuretics or a pre-operative lumbar drainage); and last but not least, sharp instruments are safer for dissection than blunt instruments. Ensuring proximal control before aneurysmal neck dissection can diminish the risk of IAR. Also, using the anatomical paths through the arachnoidal planes will also lower the chance of IAR. In our practice, we apply temporary clips if we anticipate a difficult dissection, for example, giant aneurysms, polylobulated aneurysms, or those that have recently bled. Even so, the occlusion via temporary clip should not exceed a cumulative 20–25 min with repeated placements. However, temporary clips are the most useful in IAR if placed as early as possible.

5.8 Closure

Without exception, this is performed after thorough hemostasis. For this, we employ hemostatic materials (Surgicel[®] or Gelfoam[®]) and the judicious use of the bipolar coagulator. Patience is essential, as rushing this step can compromise the entire operation. In nearly all our surgeries, we use autologous periosteum to perform dural plasty. In our opinion, near-watertight closure of the dura with a 5/0 thread (either with continuous or separate sutures) is sufficient. The bone is inserted back into place and fixed either with titanium mesh and screws or sutures with thick threads passing through small burr holes. Placing an external drainage under the aponeurosis for a period of 24 h is mandatory. The skin closure is performed either continuously or with separate sutures or staples.

5.9 Postoperative control

We usually perform a CTA after closure, with the patient still sedated and intubated. It is much safer to make sure that the vessels are angiographically permeable, or to correct any abnormality under the same anesthesia, than to wait for the patient to awake and develop ischemic complications. We have also used intraoperative

fluorescence angiography to not only verify the occlusion of the aneurysmal sack but also the patency of the surrounding normal vessels.

6. Hemodynamic consequences of aneurysm clipping

The hemodynamic characteristics of intracranial aneurysms are thought to play a pivotal role in their development, evolution, and eventual rupture, interfering and modifying the local biology of the vascular wall [61–63]. The theory suggests that the wall is exposed to a higher degree of shear stress than it can physiologically withstand. This leads to a local weakening and abnormal remodeling, which in time will form an aneurysm. Its growth can be a result of local proliferation of mural cells, a distention of the cellular and intercellular structures, or possibly a mixture of the two. A meticulous *in vitro* study affirmed that growth cannot be entirely the result of simple fluid physics [64], a non-Newtonian model being more precise in ascertaining the altered hemodynamics in intracranial aneurysms [65]. However, as it is impossible to perform direct measurements on hemodynamic stress in patients or living experimental models, methods implying computational fluid dynamics are used to estimate these phenomena [65–67].

Aneurysmal rupture results from the mechanical weakening of the arterial wall that is subsequently unable to contain the force of the flowing blood [68]. The wall shear stress is defined as the tangential frictional force that the blood exerts upon the endothelium, being the highest at the neck and the apex of the aneurysm [65]. The innerworkings of endovascular procedures are closely linked to these hemodynamic conditions, as the presence of a coil determines alterations in wall shear stress and blood flow that conclude with the intraluminal thrombosis of the aneurysm [69]. In MIA, wall shear stress is apparently increased in UIAs distal to a ruptured aneurysm after treatment, whether surgical or endovascular, leading to a theoretical rise in the risk of rupture [66]. Moreover, also in MIA, ruptured aneurysms may possess a more irregular shape, larger size, and dome-to-neck ratio, as well as a lower minimum wall shear stress than with their unruptured counterparts [70].

After clipping, a series of local and distal changes in hemodynamics may occur. Nevertheless, these are not as intensely analyzed as for untreated aneurysms. Successful surgical obliteration of the aneurysm results in the complete cessation of blood flow inside the lumen. However, it is not clear what impact the presence of the aneurysmal clip itself has on the wall shear stress or its effects on the vascular wall. A residual neck (i.e., a portion of the neck that was not occluded by the blades of the clip) may in time lead to aneurysmal regrowth, depending on the size of the remnant as well as its location [71]. Apparently, a distal remnant is at a higher risk for aneurysmal regrowth than a proximal residue. Therefore, it is crucial to ensure an adequate placement of the clip during surgery and to adjust its position if required. The alterations in dynamic flow can also be observed systemically after clipping or coiling, especially in the period after vasospasm caused by aneurysmal rupture [72]. In the study conducted by Inoue et al., patients treated by coiling presented a significantly lower cardiac index, as well as a significantly higher systemic vascular resistance index than the group managed via clipping, although this might have been the result of systemic therapy for managing vasospasm and aggressive volume loading rather than of the procedure itself, especially as the patients in the coiling group arrived in a worse neurological state than those of the clipping group. Needless to say, more studies are required to discern the actual impact that clipping has on the cerebral vasculature, especially concerning aneurysmal regrowth, reoccurrence, and rerupture.

7. Clipping of solitary unruptured aneurysms

The cerebrovascular diseases causing such controversy in regard to treatment are few in number [73]. The reasoning behind this continuous debate is that the prophylactic management of UIAs must be justified by a suitable procedure-related outcome when compared to the anticipated natural history [74]. Despite clipping once being the management centerpiece, the swift refinement of endovascular procedures and innovation of flow diversion devices have steadily replaced surgery as the first line of therapy for UIAs. However, certain countries still favor clipping due to its longevity, effectiveness, and the lower risk of recanalization than endovascular techniques, as well as lower procedure-related costs [75–77]. Consequently, whereas older patients who are unsuitable for surgery may benefit the most from endovascular procedures, clipping is considered preferable for younger patients with lower-grade aneurysms and that may be able to tolerate this intervention [76, 78]. The unruptured intracranial aneurysm treatment score (UIATS) provides a fast and easy method of triaging between the two treatment options; however, it has not yet been prospectively tested on patients harboring UIAs [79].

Studies such as ISAT, ISUIA, and UCAS are among the most cited concerning aneurysm treatment and natural history. The first of these revealed superior 1-year clinical outcomes for ruptured aneurysms by coiling in comparison to clipping, yet these results cannot be accurately extrapolated to clipping of UIAs [80]. The conditions in the unruptured setting are more advantageous, as the purpose of therapy is to ensure lifelong protection against aneurysm rupture, whereas the treatment of ruptured lesions is to allow survival of the patient during the acute phase of SAH without rebleeding or postoperative morbidity. Likewise, MCA aneurysms, which are generally considered more easily approached by surgery, were grossly underrepresented in this study. Several authors obtained much higher rates of complete obliteration via clipping than through endovascular procedures for aneurysms in this location [77, 81, 82]. This is more likely a consequence of the particular configurations of MCA aneurysms, rendering it more difficult to completely occlude the neck via endovascular procedures (wide-necked, possessing a small dome-to-neck ratio, the neck encompassing one of the arterial branches, etc.) [77]. Moreover, these aneurysms are generally adjacent to or surrounded by small perforators that may prohibit the use of stents. This technique also has the fundamental drawback of postprocedural thromboembolic events that may ensue at a higher frequency [83, 84]. In the largest multicenter study of very small UIAs treated via surgery, Bruneau et al. showed that the lesions found distal to the M1 segment were the safest to treat [85]. Despite additional enquires being required to reach a definitive conclusion, it is still worth regarding surgical clipping as the principal treatment modality for UIAs of the MCA.

Aneurysms of the anterior communicating artery are the most frequently reported in a large number of studies, possessing a higher risk of rupture than other locations while also being amenable to both endovascular and microsurgical techniques [36, 74, 86–89]. The term may actually be overly broad, also including aneurysms of the A1 and A2 junctions of the anterior cerebral artery or belonging entirely to these two segments, but being indistinguishable from true ACoA aneurysms on angiographic studies [88]. This location represents a genuine challenge for either approach. On the one hand, microvascular clipping is made difficult by depth, presence of perforators, and placement along the midline, implying increased cerebral traction in the absence of adequate relaxation [87, 89]. On the other hand, certain intrinsically unfavorable characteristics of aneurysms found in this location, such as a small dome, wide neck, multiple adjacent perforators, acute vessel angles, complex morphology, or posterior projection, can hinder

endovascular procedures as well [74, 90]. In their systematic analysis, O'Neill et al. discovered that coiling delivers the most favorable clinical results, while stent-assisted coiling produced the highest incidence of treatment-related morbidity, without improving the rates of angiographically detectable recurrences or retreatment [74]. However, microsurgical clipping offered the most definitive aneurysm repair of the three methods and significantly lower rates of recurrence or reintervention. The best course of action for UIAs of this location remains to be decided.

UIAs of the internal carotid artery, including its smaller branches such as the anterior choroidal artery, ophthalmic artery, hypophyseal artery, and artery PCoA, are also fairly common, some sources citing them as the second most frequent after aneurysms of the ACoA [36, 91, 92]. Because the parent artery is located in proximity to the skull base, the surgical access of these aneurysms is often difficult. In order to address this issue, and many others, the first flow diverter device sanctioned for use was in 2011, being designated for wide-necked intracranial aneurysms of the ICA in adults [37]. Fortunately, small aneurysms of the cavernous segment generally present a low risk of rupture [73]. Therefore, taking into consideration the hemorrhage rates described by ISUIA for aneurysms of this location, it is generally not advisable to treat asymptomatic lesions smaller than 5 mm in any way [39, 73]. Aneurysms larger than 7 mm or those that are symptomatic can be safely treated by either method with satisfactory postoperative results. Once again, endovascular procedures are less invasive, but microsurgical clipping yields a higher rate of complete occlusion [93]. Despite this, due to the hemodynamic charge of the ICA, it is possible that pulsations, differences in wall thickness, and tension may cause clip rotation [94]. Additionally, after retractors are removed, the ensuing brain shift may determine additional kinking and subsequent stenosis of the anterior choroidal artery. ICA bifurcation aneurysms are generally scarce and, as a result, underrepresented in large prospective observational studies, leading to an enigmatic natural history [93]. For aneurysms of the paraclinoid ICA or of the ophthalmic artery, it is advisable to remove the anterior clinoid process to ensure better access and proximal control. This also alleviates the risk of causing postoperative visual disturbances, which represent a common complication of ICA aneurysm management, especially for this segment [95]. Using a bone microrongeur or an ultrasonic aspirator to perform piecemeal removal of the anterior clinoid instead of a high-speed drill leads to fewer such complications [95, 96]. Small UIAs of the paraclinoid ICA that are medially pointing can also be safely approached from the contralateral side, thus diminishing the need of mobilizing the optic nerves as well as of performing anterior clinoidectomy [97]. As a remark, appropriate selection of therapeutic method for unruptured aneurysms of the ICA and its branches should factor in the individualities of the lesions themselves. Ideally, a hybrid unit would allow either approach and the possibility of converting an endovascular procedure into an open surgical intervention in the case of intraprocedural complications (**Figure 3**).

Aneurysms of the posterior circulation, including the basilar artery apex or the posteroinferior cerebellar artery (PICA), have a much higher propensity to rupture [36, 73, 98]. Therefore, a conservative approach would be inadvisable for UIAs of this location. However, there is little data comparing the endovascular and surgical treatment of posterior circulation UIAs. After ISAT and the ensuing paradigm shift, there has been a scarcity of microsurgical reports on basilar apex aneurysms. Tjahjadi et al. reported a significantly higher rate of good and fair outcome (71 and 16%, respectively) after surgery of UIAs of the basilar apex than after clipping of ruptured lesions of the same site (49 and 19%, respectively) [99]. Nanda et al. also reported good outcomes following microsurgical clipping (71.9%) and asserted that a non-dominant PCoA (especially if hypoplastic) can be safely divided in the perforator-free area as to allow additional retraction of the ICA [100]. ISUIA revealed similar clinical outcomes for the patients recruited; however, the

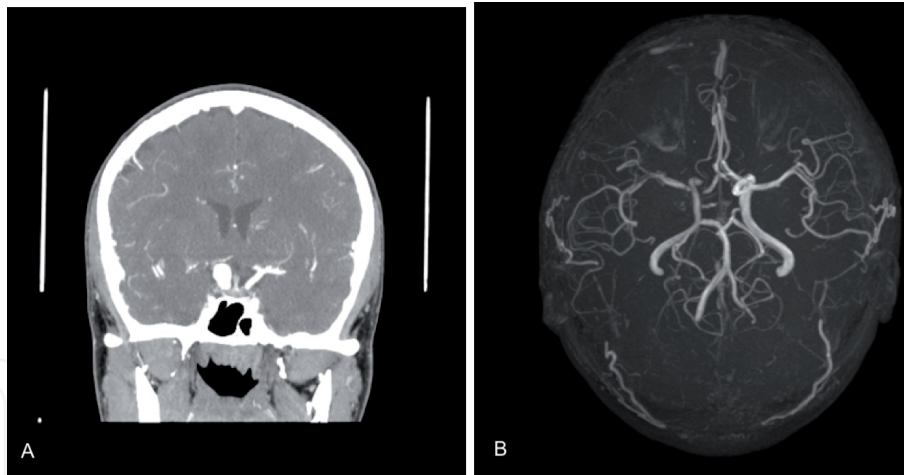


Figure 3.
 Illustrative case 1. (A) Preoperative CTA of a 21-year-old male with an incidentally discovered aneurysm of the right internal carotid artery (paraclinoidal segment). Video 1 is available at: <https://bit.ly/2Z8W6rm>. We used a right frontolateral craniotomy and approached the aneurysm via the Sylvian fissure. We drilled the anterior clinoid process, but the aneurysm ruptured during initial attempt at clipping. Because of its sheer size, we used three fenestrated clips to occlude the aneurysmal sac. The patient was discharged with no neurological deficit. (B) MRI scan, TOF sequence, at 1-year follow-up, showing the presence of the clip and no intraluminal flow.

endovascular procedures only achieved complete occlusion in approximately half of the cases treated [50, 101]. In contrast, aneurysms of the PICA (and to a certain extent the vertebral artery—VA) are still primarily treated via clipping due to their wide necks, generally multilobulated and nonsaccular characteristic, thrombosed lumens, emerging arteries, or distal locations that render coiling substandard [102]. The lower cranial nerves encountered in the surgical field can easily and securely be avoided, especially via the transcondylar approach [103]. Moreover, cases in which microsurgery should be more fervently supported number those with unfavorable endovascular access, very small aneurysm domes, or contraindications for stent usage (intolerance to dual antiplatelet therapy, nickel allergy, etc.) [85, 101].

The previously mentioned UCAS and ISUIA are regarded as the most prudently devised large studies vis-à-vis the natural history of UIA, with numerous guidelines having been published in their wake in order to improve management decision-making [78]. However, imaging control was not compulsory in ISUIA; therefore, it could not tackle the possibility of aneurysms eventually changing their morphology or size. Moreover, there is the question of the UCAS not being relevant for populations outside Japan. There are still centers that recommend treatment for all small aneurysms possessing risk of developing SAH, the presence of a daughter sack or multiple aneurysms [78, 104]. After the ISAT was published, endovascular techniques gained a boost in popularity in the USA for both ruptured and unruptured aneurysms, overtaking surgical treatment in number of procedures performed [105]. Previous analyses show that coiling was associated with fewer complications, lower mortality, faster hospital discharge, and significantly lower costs than clipping [105, 106]. However, in centers outside the USA, where hospitalization, procedure, and nursing costs are lower, the differences concerning patient expenses are smaller. In South Korea, it seems that coiling is more expensive than clipping for UIAs, and this may also be available for developing countries [106]. The principal reason for this is the cost of endovascular implantable devices themselves (stents, coils and flow diverters, etc.), constituting more than 50% of procedure-related costs [107, 108]. Even so, a previous meta-analysis concluded that coiling generated a higher independent outcome and lower mortality rate, being the more cost-effective method of the two [108].

In aspects to randomized studies comparing endovascular therapy to surgery, the literature is extremely limited. The Collaborative Unruptured Endovascular Versus surgery (CURES) trial, which randomized 104 patients harboring unruptured between 3 and 25 millimeters to either coiling ($n = 56$) or clipping ($n = 48$), showed that there were no significant differences regarding in aneurysm occlusion rate, mortality, and morbidity after 1 year [80, 109]. Nevertheless, there were more patients with perioperative neurological deficit after clipping and with hospitalizations beyond 5 days. Mortality and morbidity rates for CURES were lower than reported in the ISUIA regarding both clipping and coiling [109]. Another prospective study, the trial on endovascular management of unruptured intracranial aneurysms (TEAM), which compared coiling to observational management, was halted less than 3 years after initiation as a result of poor recruitment [110].

Another controversial subject is the management of aneurysm remnant or repermeabilization after clipping or coiling. It has been repeatedly demonstrated that microsurgery leads to fewer such instances [75–82]. Although the issue of hemorrhage after initial treatment and its consequences have been extensively covered for ruptured aneurysms, there is currently no such data for UIAs [39]. Patients should therefore be regularly monitored (we recommend yearly CTA investigations), regardless of the form of treatment and any increase in size or change in morphology be contended judiciously.

Currently, the ideal strategy for solitary unruptured aneurysms is elusive. Although of great consequence, an issue seldom considered in these studies is the experience and proficiency of the neurosurgeon [73]. This is expressly observed in high-volume centers with a large number of operated cases, where outcomes are unquestionably much more favorable. Regardless, surgical prophylaxis of rupture via clipping remains a safe, effective, and possibly curative option. It remains to be seen whether the trends will continue to favor endovascular procedures or if an unexpected shift in balance might rejuvenate the popularity of surgical intervention.

8. Clipping of multiple aneurysms

In the Western population, it is estimated that 10–13% of patients with IAs possess MIAs, and it is sometimes difficult to find the source of SAH, but even more so to treat each lesion [70, 111–114]. A number of cases have been correlated with either congenital or chronic disorders such as Gaucher's disease, Fahr's disease, or Behcet's disease, although whether there is an etiologic correlation or merely a diagnostic coincidence is unknown [115–118]. Mirror aneurysms denote a rare condition in which the multiple aneurysms are placed symmetrically in the cerebral hemispheres. The most common sites are the non-cavernous segments of the ICAs [119, 120]. Mirror aneurysms also display a decreased propensity to rupture and improved outcomes than non-mirror aneurysms. Certain risk factors such as female gender (which also strongly influences the number of IAs), advanced age, smoking, uncontrolled hypertension, and increased body mass have been linked to a heightened chance of developing MIA [121, 122]. However, due to contradictory and inconclusive results, it is currently unknown whether the presence of MIAs implies a greater risk of rupture than that of single IAs [122]. Aneurysm morphology and size are thought to play the most important roles in the risk of rupture [91, 70]. Apparently, endovascular procedures lead to fewer neurologic complications than surgical clipping; however clipping yields higher occlusion rates, fewer total complications, and angiographic recurrence [69]. In theory, hemodynamic alterations occurring in an untreated distal UIA after the treatment of a proximal IA might

increase the risk of bleeding, underlying the necessity of treating all aneurysms simultaneously and by any means [66]. It is sometimes feasible to treat all aneurysms at the same time during the same sitting and using the same craniotomy, thus lowering hospital stay, surgical exposure, and risk of complications [119, 123–125].

We support the classical pterional approach for tackling multiple aneurysms of the anterior circulation in the same opening. It offers a wide enough opening to approach even the aneurysms of the M1 segment on the opposite side. This is mostly useful for selected patients with simple contralateral UIA with narrow necks and which project inferiorly or anteriorly [119, 123]. The craniotomy should be performed on the side of the most complex aneurysm, or the one which has ruptured. On one hand, this methodology provides the highest visibility of the aneurysm and shortest distance to the dome and hematoma in case of bleeding. On the other hand, because of the hemodynamic changes that might occur during the clipping of the other IAs, it is easier to control bleeding on this side.

Clipping the contralateral aneurysms first may prevent a complicated and hard to manage bleeding on this side. After that, clipping the aneurysms more proximal to the surgeon can be performed. There are, however, some drawbacks to this technique [123, 126]. Firstly, it implies a heightened brain retraction compared to that of the same-side craniotomy, yet this can be managed by adequate brain relaxation. The maneuverability is lower, and the vision is reduced on the opposite side. However, a larger craniotomy, wider arachnoid dissection, and brain relaxation can aid in this situation. Contralateral MCA bifurcation and PCoA aneurysms are more difficult to find and clip, requiring maneuvering around thin perforators and fragile veins. Hemostasis is not as easy on the distal side in the case of rupture, which is why these IAs should be clipped first. Lastly, this technique requires an experienced vascular neurosurgical team; however, surgical simulation with 3D reconstructions may alleviate results [127]. However, this surgery should only be performed in selected cases, as the risks associated with a single challenging surgery do not compensate for the expenses of two easier interventions (**Figure 4**).

From our operative experience, we contraindicate performing two surgeries on two separate days, as the risk of rupture of the remaining untreated UIAs during this interval is not negligible. If a single opening is not indicated, we recommend approaching the more complex aneurysms first through one craniotomy, and afterward, during the same anesthesia, performing another craniotomy and clipping the residual UIAs. However, there is no consensus regarding this treatment method [119, 120, 126]. Alternatively, a combined surgical-endovascular approach can be performed, with surgery reserved for the ruptured and more difficult aneurysms [128, 129]. To summarize, deciding the management of multiple aneurysms should take into account the individual characteristics of the patient and of each the aneurysms, as well as the experience of the neurosurgical team involved.

9. Aneurysm clipping in elderly

At present, there are no corroborated management guidelines for UIAs in elderly patients, yet the retrospective reports reveal excellent results for both treatment strategies [130–132]. It has been shown that elderly patients with UIAs are less likely to die following aneurysmal rupture SAH than younger and/or female patients [37, 40, 78, 133, 134]. Therefore, a conservative approach may also be considered especially for small UIAs. Even so, the advanced age in itself supposedly increases the risk of periprocedural complications. Surgical interventions are correlated with larger amounts of blood loss, higher treatment-related costs, and longer hospitalizations than endovascular techniques, though provide a complete and maintainable aneurysmal occlusion

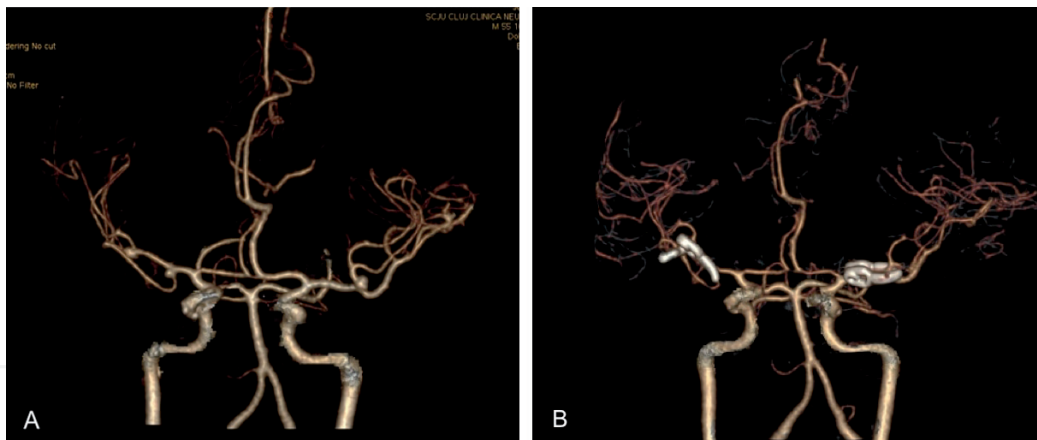


Figure 4. Illustrative case 2. (A) CTA 3D reconstruction of a 55-year-old male with multiple cerebral aneurysms—two on the right middle cerebral artery and one the left middle cerebral artery bifurcation. He presented to emergency department with right-sided weakness with gradual onset 3 days prior to surgery. Video 2 is available at: <https://bit.ly/2Z8W6rm>. He underwent microsurgical clipping via a right frontolateral craniotomy. All the clips were placed in the same procedure. (B) Postoperative CTA 3D reconstruction showing proper clip placement. He was discharged without any additional deficit.

[130, 135, 136]. Despite the differences in regard to mortality being relatively small, they are nonetheless significant and favor endovascular coiling as the safest of the two [136]. Aside from preventing rupture, interventional therapy has demonstrated cognitive improvement without causing further intellectual deficits, in addition to a decrease in anxiety levels [137, 138]. Older patients harboring MIAs without a history of SAH can be managed conservatively, whereas those at risk or with a previous SAH should be treated in a one- or two-staged intervention [119]. Moreover, coiling might prove more appropriate for those with serious comorbidities and in an altered clinical state, while clipping is more suitable in the presence of intracranial vasospasm or hematomas [69]. The same as for younger patients with MIAs, the ruptured lesion should always be managed first and foremost, yet for unruptured MIAs treatment may only be indicated if the risk related to observation outweighs those of therapy.

10. Neurological and clinical outcome after clipping

There are conflicting reports regarding the postprocedural outcomes for these interventions. Short-term outcomes generally favor endovascular procedures, with a higher incidence of postinterventional adverse events after surgery [74, 139]. According to Kim et al., there is no significant difference regarding all-cause mortality at 7 years after the elective treatment of UIAs via either clipping or coiling [140]. The meta-analysis performed by Ruan et al. showed similar outcomes for the two procedures [141]. On the other hand, in their meta-analysis, Falk Delgado et al. reported a higher independent outcome and lower mortality after coiling of UIAs [108]. The outcomes may be improved with the intraoperative use of electrophysiological monitoring, fluorescence angiography, or Doppler ultrasonography [142]. Surgical clipping of UIAs does not negatively impact quality of life nor does it affect cognitive functions in such a way that patients are unable to work or drive at 6 weeks or 1 year after the intervention [143, 144]. The risk of poor outcome for patients below the age of 65 stands at around 2–4% and rises with aneurysm size, which when compared to the 0.3–0.9% risk of annual rupture might outclass the natural history in a few years after treatment [89, 103, 145]. Nonetheless, mortality is extremely low, if not inexistent in these series. Therefore, a more aggressive treatment may be acceptable for UIAs in younger patients. Although some series

have demonstrated clipping of UIAs is effective and has no mortality even in elderly [131], the risk of a poorer outcome increases in this age group, with higher instances of disability and death than endovascular procedures specifically in the presence of comorbidities [132, 136]. Retreatment of intracranial aneurysms is also associated with a higher mortality rate [146]. However, in our experience, clipping of solitary UIAs yields excellent results, with no mortality and a high degree of functional independence, as will be shown in a later subchapter.

11. Complications of surgical clipping

Since clipping is a surgical intervention, there are chances of developing complications related to the procedure, medical and infectious complications as well as those attributable to anesthesia. The following paragraphs will focus on the complications of clipping itself. These can be divided according to timing of onset after the intervention into immediate and delayed complications.

IAR is one of the most frequent and most dreaded periprocedural complications [147]. This is especially the case for inexperienced (and oftentimes reckless) surgeons; however, preoperative GCS has also been shown to play a role in predicting this event [148]. It occurs especially around the time of neck dissection and clip placement or adjustment and is capable of hampering the microsurgical procedure, sometimes being life-threatening [149]. Nevertheless, it is significantly less frequent for UIAs than for the ruptured lesions [147]. A steady technique, proper discovery of the parent artery, temporary clipping proximal to the aneurysm, and aspiration can regain control of the situation and ensure proper clip placement.

Ischemic complications may also arise from improper clip placement or due to thromboembolism from the aneurysm. The type and severity of neurological consequences depend mostly on the location of the aneurysm [150–153]. The most frequent type of postoperative events and possibly even underestimated, ischemia leads to poorer outcomes at discharge and often entails a reintervention [153, 154]. After clipping of UIAs, transcranial Doppler studies show a decrease in transient reduction in cerebrovascular reactivity on the side of the aneurysm, leading to a proneness toward cerebral ischemia [155]. Endovascular procedures apparently bear a higher risk for thromboembolic events and ischemia [156], yet a recent meta-analysis showed that there was no statistical difference between coiling and clipping in respect to this event [141]. Incidence of perforator territory ischemia is higher for aneurysms of the A1 segment, whereas olfactory disturbances are more common for lesions of the ACoA [157]. Silent ischemic lesions are fairly frequent (up to 10% of procedures) and mostly irreversible, though rarely disabling [153, 157]. It has been argued that induced hypertension may reduce the effects of delayed cerebral ischemia [158]. Regardless, there is still no conclusive data to sustain the benefits of induced hypertension, whereas serious adverse events are sometimes unavoidable.

Another undesirable complication is the occlusion of the surrounding arteries, especially deep and subtle perforators. Again, dissection, proper magnification and illumination of the surgical field, and adequate brain relaxation can improve the visibility of the aneurysmal neck and surrounding structures. It is also important to utilize clips adjusted to aneurysm size and morphology. Electrophysiological monitoring, micro-Doppler ultrasonography, or intraoperative angiography can rapidly detect an arterial occlusion and facilitate repositioning of the clip [152, 159].

Clip slippage can happen when advanced atherosclerosis thickens the aneurysmal wall, making it impossible for the clip to close properly [151, 160]. Clip rotation and kinking of the parent vessel can also be the result of uneven arterial walls due to atheromatous

degeneration [94]. Using a double-clip technique can often prevent this from occurring, yet certain aneurysms may require more complex techniques [151, 125, 160].

Aneurysmal residue or incomplete occlusion signifies an aneurysm sac or neck that is still permeable and has a significant chance of rupture [37, 80, 86, 161, 162]. Aneurysmal rest (or dog ear) occurs when a small triangular portion of the neck is not occluded by the aneurysmal blades. In time, and under certain hemodynamic conditions, this residual neck can lead to aneurysm regrowth, and eventual rupture, requiring further imaging studies and possibly another intervention [104]. In the microsurgical series described by Nanda, the majority of recurrences were found at the ACoA, followed by ICA, VA, and PICA [163]. Adequate neck dissection and using suitable clips may avoid this complication [164]. Also using intraoperative angiographic procedures can confirm proper clip placement.

Clipping UIAs of the ophthalmic artery can lead to visual disturbances [162]. Apparently, if visual deficit was present before treatment, clipping may offer a higher degree of improvement than coiling [162, 165]. From our own experience, we can add that the clipping of aneurysms of the paraclinoid segment of the ICA or the superior hypophyseal artery may in some cases result in acute pituitary deficiency. Some of these patients will require lifelong hormone substitution therapy.

Cerebral vasospasm is predominantly a complication of ruptured aneurysms, but it has rarely been described as occurring after clipping of UIA [166]. The exact etiological mechanism is unknown, although it might be multifactorial, especially after aggressive manipulation of the vessels.

Cognitive dysfunction after UIA therapy may occur, regardless of treatment method [137]. Nevertheless, the exact effect clipping has on cognitive functions remains uncertain.

Some patients with surgically treated UIAs may develop a chronic subdural hematoma in time, being at a higher risk for this than patients with ruptured lesions [167]. Risk factors include brain atrophy, male sex, chronic antiplatelet use, and advanced age.

As long as the risk of complications remains, the incentive of perfecting microsurgical techniques will persist. The purpose of gaining surgical experience is to ensure a long-term survival of the patient with the best possible neurological outcome, while also striving to lower or eliminate the chance of adverse events.

12. Our experience

During many years of practice, we learned that trying to make an asymptomatic patient feel better is ridiculously challenging. As for the patients themselves, the notion of living with an “undetected bomb” might be daunting. As we have already shown, the issue of UIAs in a patient harboring multiple aneurysms out of which one has bled is equally controversial in the contemporary scientific literature.

We reviewed the experience of a single neurosurgeon (Professor Ioan Ștefan Florian MD, PhD—Iuliu Hatieganu University of Medicine and Pharmacy, Cluj-Napoca, Romania) in microsurgical clipping over 21 years (1997–2017). This amounted to a consecutive series of 872 patients with intracranial aneurysms (1004 separate lesions in total), both ruptured and unruptured.

From this patient pool, 89 (10.2%) presented with solitary UIA, the ages at the two extremes being 11 and 86 years, respectively. Among these, 46 (51.69%) were admitted with Hunt and Hess grade 0, while the remaining 43 (48.31%) were admitted with grade 1a. Regarding clinical outcome, our most important conclusion was that we encountered no mortality in this particular group. Eighty-seven patients (97.8%) were discharged with a Glasgow Outcome Score (GOS) of 5 (**Figure 5**).

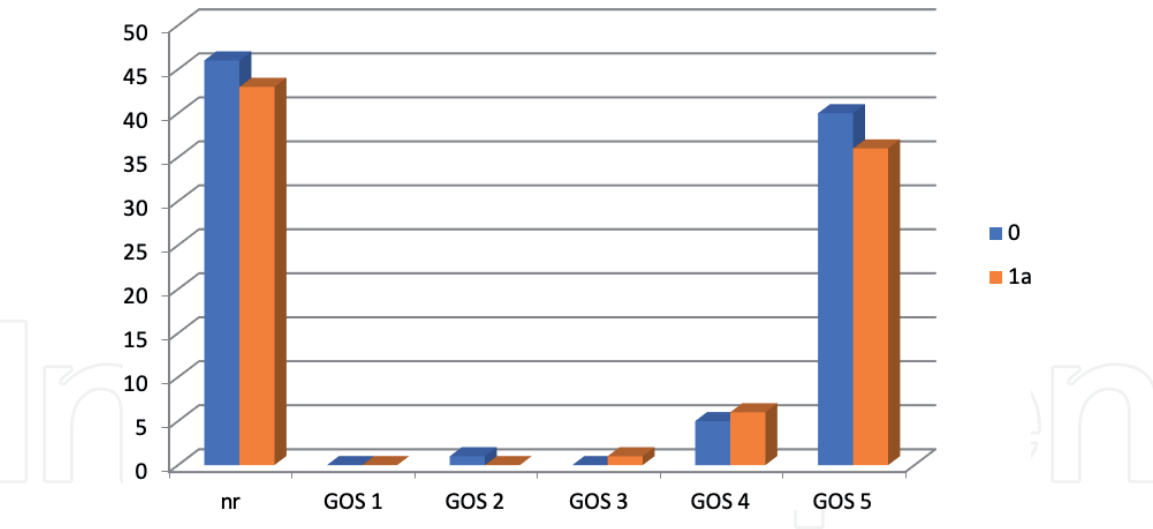


Figure 5.
Outcome of patients with solitary unruptured aneurysms at time of discharge—author’s case series (0, Hunt and Hess grade 0; 1a, Hunt and Hess grade 1a; GOS, Glasgow Outcome Score).

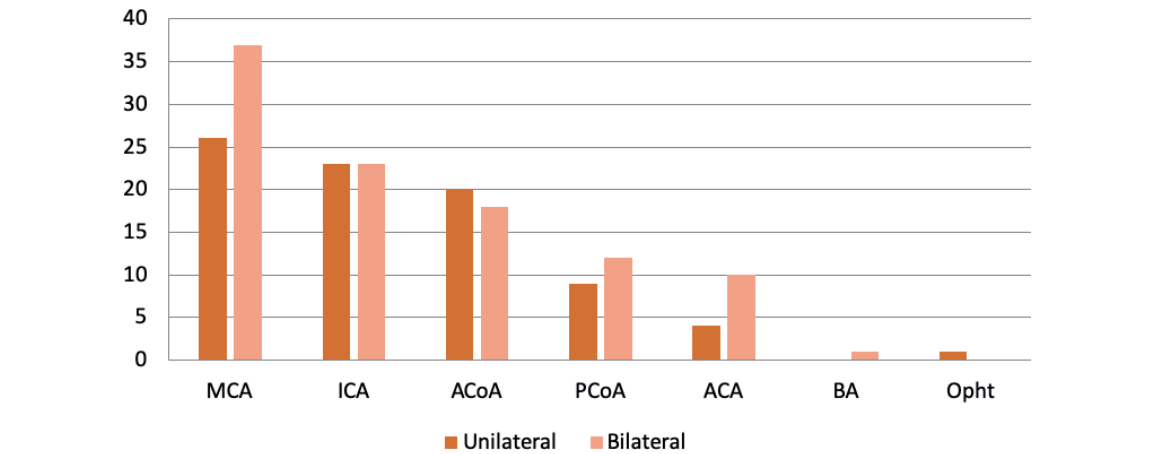


Figure 6.
Location of lesions in the multiple cerebral aneurysms group. MCA, middle cerebral artery; ICA, internal carotid artery; ACoA, anterior communicating artery; PCoA, posterior communicating artery; ACA, anterior cerebral artery; BA, basilar artery; Opht, ophthalmic artery.

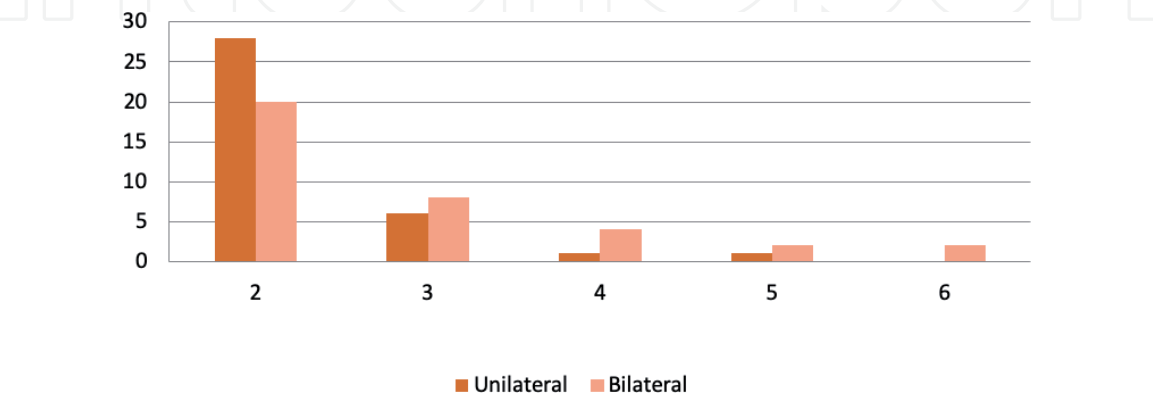


Figure 7.
Number of lesions per patient with multiple intracranial aneurysms. The majority of patients with two aneurysms had both lesions on the same side, whereas for three or more lesions, these were bilateral. The highest number of aneurysms in a single patient was six.

Parameter	Statistical test	Odds ratio	Confidence interval 95%	P
Hunt and Hess scale	Mann-Whitney U	—	—	0.588
Associated complications	Chi square	1.35	0.25–7.75	0.73
Age	<i>t</i>	—	—	0.25
Preoperative days	<i>t</i>	—	—	0.37
Glasgow Outcome Scale	Chi square	1.5	0.9–11.53	0.69
Complications	Chi square	2.6	0.53–13.11	0.22
Mortality	Chi square	0.4	0.03–5.24	0.47

Table 1.
Comparison between the two groups on admission (Hunt and Hess scale, associated complications, and age) and on discharge (preoperative days, Glasgow Outcome Scale, complications, and mortality).

In our series, we identified 101 patients (11.58%) with multiple aneurysms, harboring a total of 257 lesions. The most common location was the middle cerebral artery, followed by the internal carotid and anterior communicating artery (**Figure 6**). Initially, our approach in treating them was to clip the ruptured aneurysms or the ones with the higher risk, leaving the others for a later procedure. However, after we lost two patients with MIA on the night before the second planned intervention due to the rupture of the single unclipped lesion, we overhauled our methodology. The current goal in all cases is single-stage surgery (unilateral fronto-pterional approach) with all aneurysms clipped during the same procedure. If this is unfeasible, we perform a second craniotomy during the same anesthesia, as we believe the process of patient waking elevates the risk of rupture of any unclipped UIA.

Most patients presented with two aneurysms (57.6%). The highest number of aneurysms was six (one patient, female). The male-to-female ratio was 1:3, with the higher number of aneurysms leading to an increase of female predominance. Our series too suggests that MIA is primarily a pathology of the female gender (**Figure 7**).

We analyzed the complication rate, mortality, and state at discharge between groups with unilateral and bilateral aneurysms of the anterior circulation. There were no statistically significant differences between the two groups regarding the rate of complications or the outcome ($P > 0.05$, **Table 1**). When we compared patients with mirror middle cerebral aneurysms to the rest of the lot, no statistically significant difference could be observed either ($P > 0.05$). 60.39% of patients (61) were discharged with a favorable neurological outcome (GOS of 4 or 5).

Our data demonstrates that, with an appropriate selection of cases, surgery yields definitive and favorable results in solitary UIAs if handled by an experienced team. “Single-stage, single-opening surgery” is a viable option for treating the unruptured lesions in the context of multiple intracranial aneurysms.

13. Final remarks and future directions

Clipping of UIAs remains a valuable treatment option in preventing rupture and subsequent hemorrhagic stroke. In the hands of experienced vascular neurosurgeons, it is still a secure and long-lasting procedure, despite the relative ease and comparable safety and durability of endovascular procedures. Since aneurysmal rupture cannot be accurately predicted, clipping stands as a virtually curative procedure. Nevertheless, being an invasive procedure, it still harbors inherent risks. While our experience shows that clipping of solitary UIAs is not associated with mortality and only minimal morbidity, clipping of MIAs can pose a challenge.

Because any unclipped lesion bears a significant risk of rupture, we strongly advocate for the treatment of all aneurysms in patients with MIAs in the same procedure, and if feasible, through the same opening. The techniques and instruments themselves require constant updates in order to minimize postoperative morbidity and mortality while also ensuring ease and comfort in use. In the future, new clip technologies and intraprocedural methods of confirming the patency of parent or perforating vessels (such as fluorescein angiography) may further alleviate postoperative results. Additionally, new ways of training budding neurosurgeons in vascular pathology via interactive virtual simulations and augmented or virtual reality surgeries may rekindle the interest in surgical clipping for future generations.

Conflict of interest

The authors declare that there is no conflict of interest.

Other declarations

All authors contributed equally to the writing of this manuscript.

Author details

Ioan Alexandru Florian^{1,2*}, Teodora Larisa Timis³, Cristina Caterina Aldea^{1,2}
and Ioan Stefan Florian^{1,2}

1 Clinic of Neurosurgery, Cluj County Emergency Clinical Hospital, Cluj-Napoca, Romania

2 Department of Neurosurgery, Iuliu Hatieganu University of Medicine and Pharmacy, Cluj-Napoca, Romania

3 Department of Physiology, Iuliu Hatieganu University of Medicine and Pharmacy, Cluj-Napoca, Romania

*Address all correspondence to: florian.ioan.alexandru@gmail.com

IntechOpen

© 2019 The Author(s). Licensee IntechOpen. This chapter is distributed under the terms of the Creative Commons Attribution License (<http://creativecommons.org/licenses/by/3.0>), which permits unrestricted use, distribution, and reproduction in any medium, provided the original work is properly cited. 

References

- [1] Prestigiacomo CJ. Historical perspectives: The microsurgical and endovascular treatment of aneurysms. *Neurosurgery*. 2006;**59**:S3-39-S3-47
- [2] Cushing H. Contributions to study of intracranial aneurysms. *Guy's Hospital Reports*. 1923;**73**:159-163
- [3] Louw DF, Asfora WT, Sutherland GR. A brief history of aneurysm clips. *Neurosurgical Focus*. 2001;**11**(2):E4
- [4] Peschillo S, Caporlingua A, Caporlingua F, Guglielmi G, Delfini R. Historical landmarks in the management of aneurysms and arteriovenous malformations of the central nervous system. *World Neurosurg*. Apr 2016;**88**:661-671. DOI: 10.1016/j.wneu.2015.10.093. PMID: 26555508.
- [5] Lai LT, O'Neill AH. History, evolution, and continuing innovations of intracranial aneurysm surgery. *World Neurosurgery*. 2017;**102**:673-681. DOI: 10.1016/j.wneu.2017.02.006
- [6] Duane W Jr. A modification of the McKenzie silver clip. *Journal of Neurosurgery*. 1950;**7**:92
- [7] Botterell EH. Kenneth George McKenzie, M.D., F.R.C.S. 1923-1963. *Surgical Neurology*. 1982;**17**(2):81-89
- [8] Alexander E. Kenneth George McKenzie, Canada's first neurosurgeon. *Journal of Neurosurgery*. 1974;**41**:1-9
- [9] Pertuiset B, Siehez JP, Arthuis F, Bordi L, Haisa T, Siddiqni SA. Haemostatic clips and clamps used in surgical neurology with special reference to nonferromagnetic phynox spring clips by Aesculap. *Acta Neurochirurgica (Wien)*. 1990;**102**:127-132
- [10] Dujovny M, Agner C, Ibe O, Perlin A. Self-closing aneurysm clip: A historical review. *Neurological Research*. 2010;**32**(10):1011-1020
- [11] Mayfield FH, Kees G Jr. A brief history of the development of the Mayfield clip. *Journal of Neurosurgery*. 1971;**35**:97-100
- [12] Viers A, Allen MB, Alleyne CH. George W. Smith, M.D. (1916-1964). *Journal of Neurosurgery*. 2012;**117**(4): 800-803
- [13] Sundt TM, Murphey F. Clip-grafts for aneurysm and small vessel surgery. 3. Clinical experience in intracranial internal carotid artery aneurysms. *Journal of Neurosurgery*. 1969;**31**(1):59-71. DOI: 10.3171/jns.1969.31.1.0059
- [14] Pool JL, Colton RP. The dissecting microscope for intracranial vascular surgery. *Journal of Neurosurgery*. 1966;**25**:315-318
- [15] Shellock FG, Shellock VJ. Spetzler titanium aneurysm clips: Compatibility at MR imaging. *Radiology*. 1998;**206**: 838-841
- [16] Lawton MT, Heiserman JE, Prendergast VC, Zabramski JM, Spetzler RF. Titanium aneurysm clips: Part III—Clinical application in 16 patients with subarachnoid hemorrhage. *Neurosurgery*. 1996;**38**:1170-1175
- [17] Yasargil MG. *Microneurosurgery, Clinical Considerations, Surgery of the Intracranial Aneurysms and Results*. Vol. II. New York: Thieme; 1984. 398 p
- [18] Kacucs C, Florian IA, Ungureanu G, Florian IS. Fluorescein angiography in intracranial aneurysm surgery: A helpful method to evaluate the security of clipping and observe blood flow. *World Neurosurgery*. 2017;**105**:406-411
- [19] Wrobel CJ, Meltzer H, Lamond R, Alksne JF. Intraoperative assessment of

- aneurysm clip placement by intravenous fluorescein angiography. *Neurosurgery*. 1994;**35**:970-973
- [20] Washington CW, Zipfel GJ, Chicoine MR, Derdeyn CP, Rich KM, Moran CJ, et al. Comparing indocyanine green videoangiography to the gold standard of intraoperative digital subtraction angiography used in aneurysm surgery. *Journal of Neurosurgery*. 2013;**118**:420-427
- [21] Kassam AB, Gardner PA, Mintz A, Snyderman CH, Carrau RL, Horowitz M. Endoscopic endonasal clipping of an unsecured superior hypophyseal artery aneurysm. Technical note. *Journal of Neurosurgery*. 2007;**107**:1047-1052
- [22] Ensenat J, Alobid I, de Notaris M, Sanchez M, Valero R, Prats-Galino A, et al. Endoscopic endonasal clipping of a ruptured vertebral-posterior inferior cerebellar artery aneurysm: Technical case report. *Neurosurgery*. 2011;**69**(1 suppl operative):onsE121-onsE127 [discussion: onsE127-onsE128]
- [23] Germanwala AV, Zanation AM, et al. *Neurosurgery*. 2011;**68**(1 suppl operative):234-239 [discussion: 240]
- [24] Werner SC, Blakemore AH, King BG. Aneurysm of the internal carotid artery within the skull: Wiring and electrothermic coagulation. *Journal of the American Medical Association*. 1941;**116**:578-582
- [25] Mullan S, Reyes C, Dawley J. Stereotactic copper electric thrombosis of intracranial aneurysms. *Progress in Neurological Surgery*. 1969;**3**:193-211
- [26] Dandy WE. Intracranial arterial aneurysms in the carotid canal. Diagnosis and treatment. *Archives of Surgery*. 1942;**45**:335-350
- [27] Alksne JF, Fingerhut AG, Rand RW. Magnetic probe for the stereotactic thrombosis of intracranial aneurysms. *Journal of Neurology, Neurosurgery, and Psychiatry*. 1967;**30**:159-162
- [28] Gallagher JP: Pilojection for intracranial aneurysms: Report of progress. *Journal of Neurosurgery*. 1964; **21**: 129-134
- [29] Artico M, Spoletini M, Fumagalli L, Biagioni F, Ryskalin L, Fornai F, et al. Egas Moniz: 90 years (1927-2017) from cerebral angiography. *Frontiers in Neuroanatomy*. 2017;**11**:81. DOI: 10.3389/fnana.2017.00081
- [30] Moniz E. Cerebral angiography: Its application in clinical practice and physiology. *Lancet*. 1933;**225**:1144-1147
- [31] Wolpert SM. On the radiologic diagnosis of cerebral aneurysms with plain films and cerebral angiography: A historical survey. *American Journal of Neuroradiology*. 1995;**16**:181-184
- [32] Serbinenko FA. Balloon catheterization and occlusion of major cerebral vessels. *Journal of Neurosurgery*. 1974;**41**:125-145
- [33] Guglielmi G, Vinuela F. Endovascular treatment of intracranial saccular aneurysms with GDC platinum detachable coils: Small-necked aneurysms. In: Pasqualin A, Da Pian R, editors. *New Trends in Management of Cerebro-Vascular Malformations*. Springer, Vienna. 1994; pp 269-271
- [34] Phillips TJ, Mitchell P. Endovascular treatment of intracranial aneurysms. *Imaging in Medicine*. 2010;**2**(6):633-657
- [35] Byrne JV, Guglielmi G. Treatment by endosaccular packing with the guglielmi detachable coil. In: *Endovascular Treatment of Intracranial Aneurysms*. Berlin, Heidelberg: Springer; 1998. pp. 133-165
- [36] Seibert B, Tummala RP, Chow R, Faridar A, Mousavi SA, Divani AA.

Intracranial aneurysms: Review of current treatment options and outcomes. *Frontiers in Neurology*. 2011;**2**:45

[37] Pierot L, Gawlitz M, Soize S. Unruptured intracranial aneurysms: Management strategy and current endovascular treatment options. *Expert Review of Neurotherapeutics*. 2017. DOI: 10.1080/14737175.2017.1371593

[38] Koebbe CJ, Veznedaroglu E, Jabbour P, Rosenwasser RH. Endovascular management of intracranial aneurysms: Current experience and future advances. *Neurosurgery*. 2006;**59**(5 Suppl 3):S93-S102 [discussion S3-13]

[39] Ambekar S, Khandelwal P, Bhattacharya P, Watanabe M, Yavagal DR. Treatment of unruptured intracranial aneurysms: A review. *Expert Review of Neurotherapeutics*. 2016;**16**(10):1205-1216

[40] Aishima K, Shimizu T, Aihara M, Yoshimoto Y. Lifetime effects of small unruptured intracranial aneurysms. *World Neurosurgery*. 2016;**95**:434-440. DOI: 10.1016/j.wneu.2016.08.060

[41] Chen Y, Fan H, He X, et al. China intracranial aneurysm project (CIAP): Protocol for a prospective cohort study of interventional treatment and craniotomy for unruptured aneurysms. *BMJ Open*. 2018;**8**:e019333. DOI: 10.1136/bmjopen-2017-019333

[42] Morita A, Kirino T, Hashi K, et al. The natural course of unruptured cerebral aneurysms in a Japanese cohort. *The New England Journal of Medicine*. 2012;**366**:2474-2482

[43] Poeata I. Intracranial aneurysms. In: Popescu I, Ciuce C, editors. *Treaty of Surgery, Neurosurgery*. 2nd ed. Vol. VI. Bucharest: Editura Academiei Române; 2014. pp. 384-391. [Text in Romanian]

[44] Byoun HS, Huh W, Oh CW, Bang JS, Hwang G, Kwon OK. Natural history of unruptured intracranial aneurysms: A retrospective single center analysis. *Journal of Korean Neurosurgical Association*. 2016;**59**(1):11-16

[45] Güresir E, Vatter H, Schuss P, Platz J, Konczalla J, de Rochement RM, et al. Natural history of small unruptured anterior circulation aneurysms: A prospective cohort study. *Stroke*. 2013;**44**(11):3027-3031

[46] Müller TB, Sandvei MS, Kvistad KA, Rydland J, Håberg A, Vik A, et al. Unruptured intracranial aneurysms in the Norwegian Nord-Trøndelag Health Study (HUNT): risk of rupture calculated from data in a population-based cohort study. *Neurosurgery*. 2013;**73**(2):256-261 [discussion 260; quiz 261]

[47] Korja M, Lehto H, Juvela S. Lifelong rupture risk of intracranial aneurysms depends on risk factors: A prospective Finnish cohort study. *Stroke*. 2014;**45**(7):1958-1963

[48] Le Roux PD, Winn RH. Surgical decision making for the treatment of intracranial aneurysms. In: Winn R, editor. *Youmans and Winn Neurological Surgery*. 7th ed. Philadelphia: Elsevier; 2017. pp. 3232-3256

[49] Thompson BG, Brown RD Jr, Amin-Hanjani S, Broderick JP, Cockroft KM, Connolly ES Jr, et al. Guidelines for the management of patients with unruptured intracranial aneurysms: A guideline for healthcare professionals from the American Heart Association/American Stroke Association. *Stroke*. 2015;**46**(8):2368-2400

[50] Wiebers DO, Whisnant JP, Huston J 3rd, Meissner I, Brown RD Jr, Piepgras DG, et al. Unruptured intracranial aneurysms: natural history, clinical outcome, and risks of surgical

and endovascular treatment. *Lancet*. 2003;**362**:103-110

[51] Inoue T, Shimizu H, Fujimura M, Saito A, Tominaga T. Annual rupture risk of growing unruptured cerebral aneurysms detected by magnetic resonance angiography. *Journal of Neurosurgery*. 2012;**117**:20-25

[52] Serrone JC, Tackla RD, Gozal YM, Hanseman DJ, Gogela SL, Vuong SM, et al. Aneurysm growth and de novo aneurysms during aneurysm surveillance. *Journal of Neurosurgery*. 2016;**125**(6):1374-1382

[53] Suzuki T, Takao H, Suzuki T, Kambayashi Y, Watanabe M, Sakamoto H, et al. Determining the presence of thin-walled regions at high-pressure areas in unruptured cerebral aneurysms by using computational fluid dynamics. *Neurosurgery*. 2016;**79**(4):589-595

[54] Ramachandran M, Retarekar R, Raghavan ML, Berkowitz B, Dickerhoff B, Correa T, et al. Assessment of image-derived risk factors for natural course of unruptured cerebral aneurysms. *Journal of Neurosurgery*. 2016;**124**:288-295

[55] Kawai K, Nonaka K, Suzuki H, Kirino T, Tamura A. Differential effects of activity and climate on onset of subarachnoid hemorrhage. *Neurologia Medico-Chirurgica (Tokyo)*. 2001;**41**(5):229-236

[56] Nyquist PA, Brown RD Jr, Wiebers DO, Crowson CS, O'Fallon WM. Circadian and seasonal occurrence of subarachnoid and intracerebral hemorrhage. *Neurology*. 2001;**56**(2):190-193

[57] Beseoglu K, Hanggi D, Stummer W, Steiger HJ. Dependence of subarachnoid hemorrhage on climate conditions: A systematic meteorological analysis from the Dusseldorf metropolitan

area. *Neurosurgery*. 2008;**62**:1033-1038 [discussion 8-9]

[58] Umemura K, Hirashima Y, Kurimoto M, Kuwayama N, Kubo M, Origasa H, et al. Involvement of meteorological factors and sex in the occurrence of subarachnoid hemorrhage in Japan. *Neurologia Medico-Chirurgica (Tokyo)*. 2008;**48**(3):101-107

[59] de Steenhuijsen Pijters WA, Algra A, van den Broek MF, Dorhout Mees SM, Rinkel GJ. Seasonal and meteorological determinants of aneurysmal subarachnoid hemorrhage: A systematic review and meta-analysis. *Journal of Neurology*. 2013;**260**(2):614-619

[60] Mastorakos P, Ding D, Peterson E, Starke RM. General principles for the management of ruptured and unruptured intracranial aneurysms. In: *Principles of Neurological Surgery*. Elsevier Inc; 2018. pp. 254-263. e2

[61] Frösen J, Tulamo R, Paetau A, et al. Saccular intracranial aneurysm: Pathology and mechanisms. *Acta Neuropathologica*. 2012;**123**(6):773-786

[62] Mut F, Hamzei-Sichani F, Doddasomayajula R, et al. Hemodynamic characteristics of ruptured and unruptured multiple aneurysms at mirror and ipsilateral locations. *American Journal of Neuroradiology*. 2017;**38**(12):2301-2307

[63] Cebal JR, Duan X, Chung BJ, Putman C, Aziz K, Robertson AM. Wall mechanical properties and hemodynamics of unruptured intracranial aneurysms. *AJNR. American Journal of Neuroradiology*. 2015;**36**(9):1695-1703

[64] Tateshima S, Tanishita K, Omura H, Villablanca JP, Vinuela F. Intra-aneurysmal hemodynamics during the growth of an unruptured aneurysm:

In vitro study using longitudinal CT angiogram database. American Journal of Neuroradiology. Apr 2007;**28**(4):622-627

[65] El-Bassiouny OA, Saqr KM, Shehata AI, Hassan T, el Gibaly A, Diaa O. Effects of non-Newtonian viscosity on the hemodynamics of cerebral aneurysms. Applied Mechanics and Materials. 2016;**819**:366-370

[66] Conde Alonso C, Riveiro Rodríguez A, Díaz Molina J, et al. Hemodynamic changes in the treatment of multiple intracranial aneurysms: A computational fluid dynamics study. World Neurosurgery. 2018;**118**:e631-e638

[67] Mohamied Y, Sherwin SJ, Weinberg PD. Understanding the fluid mechanics behind transverse wall shear stress. Journal of Biomechanics. 2017;**50**:102-109

[68] Sforza DM, Putman CM, Cebal JR. Hemodynamics of cerebral aneurysms. Annual Review of Fluid Mechanics. 2009;**41**:91-107

[69] Dong QL, Gao BL, Cheng ZR, et al. Comparison of surgical and endovascular approaches in the management of multiple intracranial aneurysms. International Journal of Surgery. 2016;**32**:129-135

[70] Zhang Y, Yang X, Wang Y, et al. Influence of morphology and hemodynamic factors on rupture of multiple intracranial aneurysms: Matched-pairs of ruptured-unruptured aneurysms located unilaterally on the anterior circulation. BMC Neurology. 2014;**14**(1):253

[71] Byun HS, Rhee K. Intraaneurysmal flow changes affected by clip location and occlusion magnitude in a lateral aneurysm model. Medical Engineering & Physics. 2003;**25**(7):581-589

[72] Inoue T, Iwaasa M, Nagata I, Isotani E, Ishizaka S, Horie N. Impact of clipping versus coiling on postoperative hemodynamics and pulmonary edema after subarachnoid hemorrhage. BioMed Research International. 2014;**2014**(1):1-9

[73] Chen SF, Kato Y, Sinha R, Kumar A, Watabe T, Imizu S, et al. Surgical treatment of patients with unruptured intracranial aneurysms. Journal of Clinical Neuroscience. 2015;**22**(1):69-72

[74] O'Neill AH, Chandra RV, Lai LT. Safety and effectiveness of microsurgical clipping, endovascular coiling, and stent assisted coiling for unruptured anterior communicating artery aneurysms: A systematic analysis of observational studies. Journal of Neurointerventional Surgery. 2017;**9**(8):761-765

[75] Bradac O, Hide S, Mendelow DA, Benes V. Aneurysm treatment in Europe 2010: An internet survey. Acta Neurochirurgica. 2012;**154**(6):971-977. DOI: 10.1007/s00701-012-1340-2

[76] Chua MH, Griessenauer CJ, Stapleton CJ, He L, Thomas AJ, Ogilvy CS. Documentation of improved outcomes for intracranial aneurysm management over a 15-year interval. Stroke. 2016;**47**(3):708-712

[77] Choi JH, Park JE, Kim MJ, Kim BS, Shin YS. Aneurysmal neck clipping as the primary treatment option for both ruptured and Unruptured middle cerebral artery aneurysms. Journal of Korean Neurosurgical Association. 2016;**59**(3):269-275

[78] Tintim C, Machado HS. Clipping versus coiling for intracranial aneurysms: Recent trends. Journal of Anesthesia and Clinical Research. 2017;**08**(06):1-10. DOI: 10.4172/2155-6148.1000732

- [79] Etminan N, Brown RD, Beseoglu K, et al. The unruptured intracranial aneurysm treatment score: A multidisciplinary consensus. *Neurology*. 2015;**85**(10):881-889
- [80] Te D, Findlay JM, Magro E, et al. Surgical clipping or endovascular coiling for unruptured intracranial aneurysms: A pragmatic randomised trial. *Journal of Neurology, Neurosurgery, and Psychiatry*. 2017;**88**:663-668
- [81] van Dijk JM, Groen RJ, Ter Laan M, Jeltema JR, Mooij JJ, Metzemaekers JD. Surgical clipping as the preferred treatment for aneurysms of the middle cerebral artery. *Acta Neurochirurgica*. 2011;**153**(11):2111-2117
- [82] Güresir E, Schuss P, Berkefeld J, Vatter H, Seifert V. Treatment results for complex middle cerebral artery aneurysms. A prospective single center series. *Acta Neurochirurgica*. 2011;**153**:1247-1252
- [83] Yahia AM, Latorre J, Gordon V, Whapham J, Malek A, Fessler RD. Tromboembolic events associated with neuroform stent in endovascular treatment of intracranial aneurysms. *Journal of Neuroimaging*. 2010;**20**:113-117
- [84] Yahia AM, Gordon V, Whapham J, Malek A, Steel J, Fessler RD. Complications of neuroform stent in endovascular treatment of intracranial aneurysms. *Neurocritical Care*. 2008;**8**:19-30
- [85] Bruneau M, Amin-Hanjani S, Koroknay-Pal P, Bijlenga P, Jahromi BR, Lehto H, et al. Surgical clipping of very small unruptured intracranial aneurysms: A multicenter international study. *Neurosurgery*. 2016 Jan;**78**(1):47-52
- [86] Proust F, Debono B, Hannequin D, et al. Treatment of anterior communicating artery aneurysms: Complementary aspects of microsurgical and endovascular procedures. *Journal of Neurosurgery*. 2003;**99**:3-14
- [87] Hernesniemi J, Dashti R, Lehecka M, et al. Microneurosurgical management of anterior communicating artery aneurysms. *Surgical Neurology*. 2008;**70**:8-28 [discussion 29]
- [88] Wong H, Banfield J, Hughes N, Shankar JJS. Are anterior communicating aneurysms truly anterior communicating aneurysms? An observational study. *World Neurosurgery*. 2019. pii: S1878-8750(19)30365-1
- [89] Lai LT, Gragnaniello C, Morgan MK. Outcomes for a case series of unruptured anterior communicating artery aneurysm surgery. *Journal of Clinical Neuroscience*. 2013;**20**:1688-1692
- [90] Finitis S, Anxionnat R, Lebedinsky A, et al. Endovascular treatment of ACom intracranial aneurysms. Report on series of 280 patients. *Interventional Neuroradiology*. 2010;**16**:7-16
- [91] Bhogal P, AlMatter M, Hellstern V, Ganslandt O, Bätzner H, Henkes H, et al. Difference in aneurysm characteristics between ruptured and unruptured aneurysms in patients with multiple intracranial aneurysms. *Surgical Neurology International*. 2018;**9**:1
- [92] Maud A, Rodriguez GJ, Barboza MA. Endovascular treatment of intracranial aneurysms by interventional neurologists: First year single-center experience. *Journal of Vascular and Interventional Neurology*. 2014;**7**(2):13-16
- [93] La Pira B, Brinjikji W, Burrows AM, Cloft HJ, Vine RL, Lanzino G. Unruptured internal carotid artery bifurcation aneurysms: General features and overall results after modern

treatment. *Acta Neurochirurgica*. 2016;**158**(11):2053-2059

[94] Sakuma J, Suzuki K, Sasaki T, Matsumoto M, Oinuma M, Kawakami M, et al. Monitoring and preventing blood flow insufficiency due to clip rotation after the treatment of internal carotid artery aneurysms. *Journal of Neurosurgery*. 2004;**100**(5):960-962

[95] Kikuta K, Kitai R, Koderu T, Arishima H, Isozaki M, Hashimoto N, et al. Predictive factors for the occurrence of visual and ischemic complications after open surgery for paraclinoid aneurysms of the internal carotid artery. *Acta Neurochirurgica. Supplement*. 2016;**123**:41-49

[96] Chang DJ. The "no-drill" technique of anterior clinoidectomy: A cranial base approach to the paraclinoid and parasellar region. *Neurosurgery*. 2009;**64**(3 Suppl):ons96-ons105 [discussion ons105-6]

[97] Serrano LE, Ayyad A, Archavlis E, Schwandt E, Nimer A, Ringel F, et al. A literature review concerning contralateral approaches to paraclinoid internal carotid artery aneurysms. *Neurosurgical Review*. 2018. DOI: 10.1007/s10143-018-01063-3 [Epub ahead of print]

[98] Nanda A, Patra DP, Bir SC, Maiti TK, Kalakoti P, Bollam P. Microsurgical clipping of unruptured intracranial aneurysms: A single Surgeon's experience over sixteen years. *World Neurosurgery*. Apr 2017;**100**: 85-99. DOI: 10.1016/j.wneu.2016.12.099

[99] Tjahjadi M, Kivelev J, Serrone JC, Maekawa H, Kerro O, Jahromi BR, et al. Factors determining surgical approaches to basilar bifurcation aneurysms and its surgical outcomes. *Neurosurgery*. 2016;**78**(2):181-191

[100] Nanda A, Sonig A, Banerjee AD, Javalkar VK. Microsurgical management

of basilar artery apex aneurysms: A single surgeon's experience from Louisiana State University, Shreveport. *World Neurosurgery*. 2014;**82**(1-2):118-129

[101] Tjahjadi M, Serrone J, Hernesniemi J. Should we still consider clips for basilar apex aneurysms? A critical appraisal of the literature. *Surgical Neurology International*. 2018;**9**:44. Published Feb 21, 2018. DOI: 10.4103/sni.sni_311_17

[102] Sanai N, Tarapore P, Lee AC, Lawton MT. The current role of microsurgery for posterior circulation aneurysms: A selective approach in the endovascular era. *Neurosurgery*. 2008;**62**:1236-1249 [discussion 1249-1253]

[103] Palanisamy D, Yasuhiro Y, Kyosuke M, Tsukasa K, Katsumi T, Kato Y. Transcondylar fossa approach to unruptured vertebral artery and vertebral artery-posterior inferior cerebellar artery aneurysms: Surgical outcome. *World Neurosurgery*. 2018;**119**:e783-e791. DOI: 10.1016/j.wneu.2018.07.268

[104] Dellaretti M, Ronconi D, Batista DM, de Souza RF, de Almeida CER, Fontoura RR, et al. Safety and efficacy of surgical treatment of intracranial aneurysms: The experience of a single Brazilian Center. *World Neurosurgery*. 2018;**117**:e580-e587

[105] Lin N, Cahill KS, Frerichs KU, Friedlander RM, Claus EB. Treatment of ruptured and unruptured cerebral aneurysms in the USA: A paradigm shift. *Journal of Neurointerventional Surgery*. 2018;**10**:i69-i76

[106] Zhang X, Tang H, Huang Q, Hong B, Xu Y, Liu J. Total hospital costs and length of stay of endovascular coiling versus neurosurgical clipping for unruptured intracranial aneurysms:

systematic review and meta-analysis. *World Neurosurg.* 2018;**115**: 393-399. DOI: <https://doi.org/10.1016/j.wneu.2018.04.028>

[107] Stone DH, Horvath AJ, Goodney PP, Rzucidlo EM, Nolan BW, Walsh DB, et al. The financial implications of endovascular aneurysm repair in the cost containment era. *Journal of Vascular Surgery.* 2014;**59**(2):283-290. 90.e1

[108] Falk Delgado A, Andersson T, Falk DA. Clinical outcome after surgical clipping or endovascular coiling for cerebral aneurysms: A pragmatic meta-analysis of randomized and non-randomized trials with short- and long-term follow-up. *Journal of Neurointerventional Surgery.* 2017;**9**(3):264-277

[109] Huang W, Du R. 2016-2017 Clinical trials in cerebrovascular neurosurgery. *Journal of Clinical Neuroscience.* 2019;**60**:31-35

[110] Raymond J, Darsaut TE, Molyneux AJ, TEAM Collaborative Group. A trial on unruptured intracranial aneurysms (the TEAM trial): Results, lessons from a failure and the necessity for clinical care trials. *Trials.* 2011;**12**:64. Published Mar 4, 2011. DOI: 10.1186/1745-6215-12-64

[111] Berg P, Beuing O. Multiple intracranial aneurysms: A direct hemodynamic comparison between ruptured and unruptured vessel malformations. *International Journal for Computer Assisted Radiology and Surgery.* 2018;**13**:83

[112] Murrone D, Romanelli B, Ierardi A. Surgical case series of multiple aneurysms: A single-Centre experience of 16 years. *International Journal of Surgery Case Reports.* 2018;**42**:191-195

[113] Dammann P, Wrede KH, Sure U, et al. Risk factors for and clinical

consequences of multiple intracranial aneurysms. *Stroke.* 2018;**49**(4):848-855

[114] Orning JL, Shakur SF, Alaraj A, Behbahani M, Charbel FT, Aletich VA, et al. Accuracy in identifying the source of subarachnoid hemorrhage in the setting of multiple intracranial aneurysms. *Neurosurgery.* 2018;**83**(1):62-68

[115] Reynolds MR, Heiferman DM, Boucher AB, Howard BM, Barrow DL, Dion JE. Multiple intracranial aneurysms in a patient with type I Gaucher disease: A case report and literature review. *British Journal of Neurosurgery.* 2018;**15**:1-3

[116] Eroglu U, Kahilogullari G, Demirel A, Arat A, Unlu A. Fahr's syndrome associated with multiple intracranial aneurysms: A case report. *Turkish Neurosurgery.* 2016;**26**(4):643-645

[117] Ha S, Kim J, Kim CG, Jang SJ. Multiple intracranial aneurysms associated with Behçet's disease. *Journal of Cerebrovascular and Endovascular Neurosurgery.* 2016;**18**(1):32-37

[118] Fkihi A, Argillos K, Belfeki N, Dahmani R, Velmans N. Unruptured multiple intracranial aneurysms associated with Behçet's disease. *Journal de Médecine Vasculaire.* 2017;**42**(4):234-236

[119] Wu C, Zhang Y-Y, Xue Z, et al. Treatment strategies for intracranial mirror aneurysms. *World Neurosurgery.* 2017;**100**:450-458

[120] Mehrotra A, Sharma P, Das KK, Bhaisora KS, Sardhara J, Gupta S, et al. Mirror aneurysms among multiple aneurysms: Lesser of the two evils. *World Neurosurgery.* Aug 2016;**92**:126-132. DOI: 10.1016/j.wneu.2016.04.124

[121] McDowell MM, Sussman E, Claassen J, et al. Demographic and

clinical predictors of multiple intracranial aneurysms in patients with subarachnoid hemorrhage. *Journal of Neurosurgery*. 2017;**112**:961-968

[122] Pan J-W, Zhu Y, Weng Y-X, Jiang H, Zhan R-Y, Shen J. Patient and aneurysm characteristics associated with rupture risk of multiple intracranial aneurysms in the anterior circulation system. *Acta Neurochirurgica*. 2016;**158**(7):1367-1375

[123] Rodríguez-Hernández A, Gabarrós A, Lawton MT. Contralateral clipping of middle cerebral artery aneurysms. *Operative Neurosurgery*. 2012;**71**(September):ons116-ons124

[124] Asiltürk M, Abdallah A. Clinical outcomes of multiple aneurysms microsurgical clipping: Evaluation of 90 patients. *Neurologia i Neurochirurgia Polska*. 2018;**52**(1):15-24

[125] Fotakopoulos G, Elera-Florez H, Hernesniemi J, Colasanti R, Choque-Velasquez J. Seven cerebral aneurysms: A challenging case from the Andean slopes managed with 1-stage surgery. *World Neurosurgery*. 2016;**97**:565-570

[126] Guo S, Xing Y. Surgical treatment of multiple intracranial aneurysms. *Turkish Neurosurgery*. 2014;**24**(2):208-213

[127] Ling C, Wang H, Chen Z, et al. Contralateral approach based on a preoperative 3-dimensional virtual osteotomy technique for anterior circulation aneurysms. *Journal of Stroke and Cerebrovascular Diseases*. 2019;**28**(4):1099-1106

[128] Kheïreddin AS, Filatov IM, Belousova OB, Eliava SS, Iakovlev SB, Sazonov IA, et al. Substantiation of differentiated management of patients with multiple cerebral aneurysms [in Russian]. *Zhurnal Voprosy Neirokhirurgii Imeni N. N. Burdenko*. 2012;**76**(3):45-53 [discussion 53]

[129] Ahmed O, Kalakoti P, Hefner M, Cuellar H, Guthikonda B. Seven intracranial aneurysms in one patient: Treatment and review of literature. *Journal of Cerebrovascular and Endovascular Neurosurgery*. 2015;**17**(2):113-119

[130] Chernyshev OY, Bir SC, Maiti TK, et al. Changing paradigm in the management of elderly patients with intracranial aneurysms: An institutional review. *Journal of Clinical Neuroscience*. 2017;**43**:94-102

[131] Park JH, Kim YI, Lim YC. Clinical outcomes of treatment for intracranial aneurysm in elderly patients. *Journal of Cerebrovascular and Endovascular Neurosurgery*. 2014;**16**(3):193

[132] O'Neill AH, Chandra RV, Slater LA, et al. Influence of comorbidities on treatment of unruptured intracranial aneurysms in the elderly. *Journal of Clinical Neuroscience*. 2019;**62**:38-45

[133] Brown RD, Broderick JP. Unruptured intracranial aneurysms: Epidemiology, natural history, management options, and familial screening. *Lancet Neurology*. 2014;**13**(4):393-404

[134] Gu Y, Tian Y, Leng B, et al. Treatment strategy for unruptured intracranial aneurysm in elderly patients: Coiling, clipping, or conservative? *Cell Transplantation*. 2019;**28**(6):767-774

[135] Kim M, Park J, Lee J. Comparative cost analysis for surgical and endovascular treatment of unruptured intracranial aneurysms in South Korea. *Journal of Korean Neurosurgical Association*. 2015;**57**(6):455-459

[136] Eloy JA, Gandhi CD, Shao B, Silva NA, Sylvester MJ. Unruptured aneurysms in the elderly: Perioperative outcomes and cost analysis of endovascular coiling and

surgical clipping. *Neurosurgical Focus*. 2018;**44**(May):E4. DOI: 10.3171/2018.1.focus17714

[137] Srinivasan VM, Wagner K, Chen SR, et al. Cognitive sequelae of Unruptured and ruptured intracranial aneurysms and their treatment: Modalities for neuropsychological assessment. *World Neurosurgery*. 2018;**120**:537-549

[138] Kubo Y, Ogasawara K, Kashimura H, Otawara Y, Kakino S, Sugawara A, et al. Cognitive function and anxiety before and after surgery for asymptomatic unruptured intracranial aneurysms in elderly patients. *World Neurosurgery*. 2010;**73**:350-353

[139] Song J, Kim BS, Shin YS. Treatment outcomes of unruptured intracranial aneurysm; experience of 1231 consecutive aneurysms. *Acta Neurochirurgica*. 2015;**157**(8):1303-1311

[140] Kim YD, Bang JS, Lee SU, et al. Long-term outcomes of treatment for unruptured intracranial aneurysms in South Korea: Clipping versus coiling. *Journal of Neurointerventional Surgery*. 2018;**10**(12):1218-1223

[141] Ruan C, Long H, Sun H, et al. Endovascular coiling vs. surgical clipping for unruptured intracranial aneurysm: A meta-analysis. *British Journal of Neurosurgery*. 2015;**29**(4):485-492

[142] Jo KI, Kim HR, Yeon JY, Hong SC, Kim JS. Treatment outcomes of surgical clipping for unruptured anterior circulation aneurysm—Single institute experiences in the era of neurophysiologic monitoring and endovascular treatment. *Neurosurgical Review*. 2015;**38**(4):677-682

[143] O'Donnell JM, Morgan MK, Manuguerra M. Functional outcomes and quality of life after microsurgical clipping of unruptured intracranial

aneurysms: A prospective cohort study. *Journal of Neurosurgery*. 2 Mar 2018;**130**(1):278-285

[144] Koźba-Gosztyła M, Czapiga B, Jarmundowicz W, Tomiałowicz Ł. Unruptured intracranial aneurysms: Surgery still safe as a treatment option. *Advances in Clinical and Experimental Medicine*. 2016;**25**(5):911-916

[145] SchmalzPGR, Enriquez-MarulandaA, Alturki A, Stapleton CJ, Thomas AJ, Ogilvy CS. Combined outcomes of endovascular or surgical treatment of Unruptured anterior communicating artery aneurysms: Is a more aggressive management strategy warranted? *World Neurosurgery*. 2018;**115**:e331-e336

[146] Nijeholt GJ LÅ, Moojen WA, MLD B, Hertgers O, Muskens IS. Outcomes of retreatment for intracranial aneurysms—A meta-analysis. *Neurosurgery*. 2018. DOI: 10.1093/neuros/nyy455 [Epub ahead of print]

[147] Darkwah Oppong M, Pierscianek D, Ahmadipour Y, et al. Intraoperative aneurysm rupture during microsurgical clipping: Risk re-evaluation in the post-international subarachnoid aneurysm trial era. *World Neurosurgery*. 2018;**119**:e349-e356. DOI: 10.1016/j.wneu.2018.07

[148] Chen XL, Chen Y, Ma L, et al. Translucent appearance of middle cerebral artery bifurcation aneurysms is risk factor for intraoperative aneurysm rupture during clipping. *World Neurosurgery*. 2017;**101**:149-154

[149] Leipzig TJ, Morgan J, Horner TG, Payner T, Redelman K, Johnson CS. Analysis of intraoperative rupture in the surgical treatment of 1694 saccular aneurysms. *Neurosurgery*. 2005;**56**(3):455-466

[150] Kurisu K, Matsushige T, Sakamoto S, et al. Asymptomatic ischemic risks in

microsurgical clipping for unruptured intracranial aneurysms in anterior circulation. *World Neurosurgery*. 2017;**108**:418-426

[151] Park W, Ahn JS, Lee SH, Park JC, Kwun BD. Results of re-exploration because of compromised distal blood flow after clipping unruptured intracranial aneurysms. *Acta Neurochirurgica*. 2015;**157**(6):1015-1024

[152] Park W, Hong SH, Ahn JS, et al. Intraoperative use of transcranial motor/sensory evoked potential monitoring in the clipping of intracranial aneurysms: Evaluation of false-positive and false-negative cases. *Journal of Neurosurgery*. 2018;**130**(3):936-948. DOI: 10.3171/2017.8.jns17791

[153] Li M, Wu J, Chen X, et al. Symptomatic and silent cerebral infarction following surgical clipping of unruptured intracranial aneurysms: Incidence, risk factors, and clinical outcome. *Neurosurgical Review*. 2018;**41**(2):675-682. DOI: 10.1007/s10143-017-0913-1

[154] McCutcheon BA, Kerezoudis P, Shepherd DL, et al. Quantitative analysis of the effect of institutional case volume on complications after surgical clipping of unruptured aneurysms. *Journal of Neurosurgery*. 2017:1297-1306

[155] Svendsen F, Logallo N, Helland CA, Bøthun ML, Thomassen L, Haaland ØA. Time course of cerebrovascular reactivity in patients treated for unruptured intracranial aneurysms: A one-year transcranial Doppler and acetazolamide follow-up study. *BioMed Research International*. 2018;**2018**:1-9

[156] Rordorf G, Bellon RJ, Budzik RE Jr, et al. Silent thromboembolic events associated with the treatment of unruptured cerebral aneurysms by use of Guglielmi detachable coils:

Prospective study applying diffusion-weighted imaging. *American Journal of Neuroradiology*. 2001;**22**:5-10

[157] Matsukawa H, Kamiyama H, Miyazaki T, et al. Impacts of a size ratio on outcome in patients with surgically treated unruptured nondissecting anterior cerebral artery aneurysms. *World Neurosurgery*. 2018;**111**:e250-e260

[158] van der Jagt M, van Rooij WJJ, Müller MC, et al. Induced hypertension for delayed cerebral ischemia after aneurysmal subarachnoid hemorrhage. *Stroke*. 2017;**49**(1):76-83

[159] Suzuki M, Yoneda H, Ishihara H, et al. Adverse events after unruptured cerebral aneurysm treatment: A single-center experience with clipping/coil embolization combined units. *Journal of Stroke and Cerebrovascular Diseases*. 2015;**24**(1):223-231

[160] Kwun BD, Ahn JS, Park JC, Park W, Sheen JJ. Microsurgical treatment strategy for large and giant aneurysms of the internal carotid artery. *Clinical Neurology and Neurosurgery*. 2018;**177**:54-62

[161] Asaid M, O'Neill AH, Bervini D, Chandra RV, Lai LT. Unruptured paraclinoid aneurysm treatment effects on visual function: Systematic review and meta-analysis. *World Neurosurgery*. 2017;**106**:322-330. DOI: 10.1016/j.wneu.2017.06.135

[162] Tabani H, Safaee MM, Kamide T, Burkhardt J-K, Lawton MT. Microsurgical clipping of ophthalmic artery aneurysms: Surgical results and visual outcomes with 208 aneurysms. *Journal of Neurosurgery*. 2018:1-11

[163] Nanda A, Patra DP, Bir SC, Maiti TK, Kalakoti P, Bollam P. Microsurgical clipping of unruptured intracranial aneurysms: A single surgeon's experience over 16 years. *World Neurosurgery*. 2017;**100**:85-99

[164] Jeon HJ, Kim SY, Park KY, Lee JW, Huh SK. Ideal clipping methods for unruptured middle cerebral artery bifurcation aneurysms based on aneurysmal neck classification. *Neurosurgical Review*. 2016;**39**(2):215-224

[165] Nanda A, Javalkar V. Microneurosurgical management of ophthalmic segment of the internal carotid artery aneurysms: Single-surgeon operative experience from Louisiana State University, Shreveport. *Neurosurgery*. 2011;**68**(2):355-370 [discussion 370-1]

[166] Tsyben A, Paldor I, Laidlaw J. Cerebral vasospasm and delayed ischaemic deficit following elective aneurysm clipping. *Journal of Clinical Neuroscience*. 2016;**34**:33-38

[167] Kwon MY, Kim CH, Lee CY. Predicting factors of chronic subdural hematoma following surgical clipping in unruptured and ruptured intracranial aneurysm. *Journal of Korean Neurosurgical Association*. 2016;**59**(5):458-465

IntechOpen