

We are IntechOpen, the world's leading publisher of Open Access books Built by scientists, for scientists

6,900

Open access books available

186,000

International authors and editors

200M

Downloads

Our authors are among the

154

Countries delivered to

TOP 1%

most cited scientists

12.2%

Contributors from top 500 universities



WEB OF SCIENCE™

Selection of our books indexed in the Book Citation Index
in Web of Science™ Core Collection (BKCI)

Interested in publishing with us?
Contact book.department@intechopen.com

Numbers displayed above are based on latest data collected.
For more information visit www.intechopen.com



The C-Shaped Root Canal

Jesús Alejandro Quiñones Pedraza

Abstract

A thorough understanding of root canal anatomy is of paramount importance in the field of dentistry. The C-shaped root canal is an anatomical variation occurring mostly in mandibular second molars. In a transverse section, the shape of this canal is observed as the letter C. The presence of a fin or web connecting the individual root canals is another anatomic feature. Due to its complex anatomy, different classifications have been proposed through the years for a better comprehension. In endodontic literature, the C-shaped root canal has been of high interest and its prevalence is reported in different regions of the world. Additionally, its endodontic management has been widely described and analyzed.

Keywords: C-shaped root canal, anatomy, anatomical variation, canal configuration, human teeth

1. Introduction

The C-shaped root canal is considered an anatomical variation in human teeth [1] and was firstly documented in endodontic literature by Cooke and Cox in 1979 [2]. This anatomical variation has been widely studied. Additionally, several case reports have described its endodontic management [3–5].

The main cause of a C-shaped root is due to the failure of the Hertwig's epithelial root seath to fuse on the lingual or buccal root surface [1]. The roots of human molars with C-shaped canals may be conical and fused. For these characteristics, studies suggested that C-shaped root canals could be identified based on preoperative radiographs [6, 7]. However, not all conical roots have a C-shaped canal and various reports stated that a C-shaped root canal is not easily seen using only radiographs [6]. On the other hand, additional reports have demonstrated that a

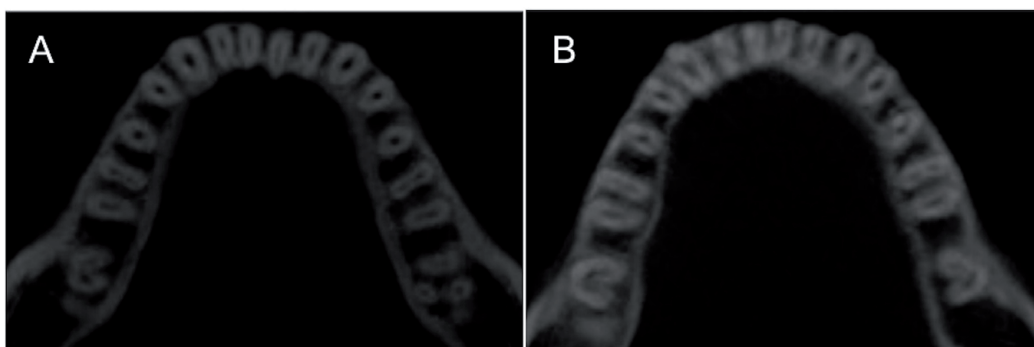


Figure 1.

(A) Unilateral C-shaped root canal in mandibular second molar; (B) bilateral C-shaped root canal in mandibular second molar.

C-shaped canal may be bilateral [8] (i.e., when it is present on one side, it can also be present in the contralateral tooth) (**Figure 1**).

The C-shaped root canal has been found in mandibular and maxillary molars [9, 10], mandibular premolars [11], and even in some incisors [12]. However, it is most commonly present in mandibular second molars [3]. As other anatomical variations, its prevalence has been associated with ethnicity. Interestingly, the prevalence of this canal in Asian populations has been higher than other populations [13].

2. Classification

Different techniques have been used to analyze the morphology of C-shaped root canals [14, 15]. In a transverse section of a tooth with this morphology, the shape of the canal is observed as the letter C (**Figure 2**) and different patterns may be present along the canal. The presence of fins connecting the individual root canals is other anatomical feature [1]. Likewise, the shape of the letter C may be interrupted and observed as separate canals [16]; for this reason, different anatomical classifications have been proposed through the years for a better understanding [17, 18].

Although there are different classifications, the following [18] has been commonly cited and well accepted by clinicians (**Figure 3**):

- Category I (C1): the shape was an uninterrupted “C” with no separation or division.
- Category II (C2): the canal shape resembled a semicolumn resulting from a discontinuation of the “C” outline, but either angle alpha or beta was no less than 60°.
- Category III (C3): two or three separated canals and both angles, alpha and beta, were less than 60°.
- Category IV (C4): only one round or oval in that cross-section.
- Category V (C5): no canal lumen could be observed (which was usually seen near the apex only).

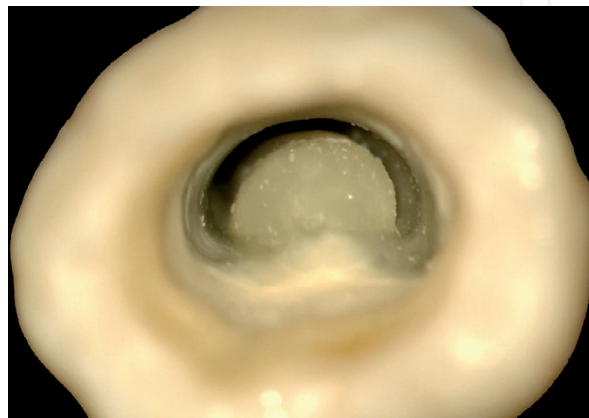


Figure 2.
C-shaped root canal, the shape of the canal is observed as the letter “C.”

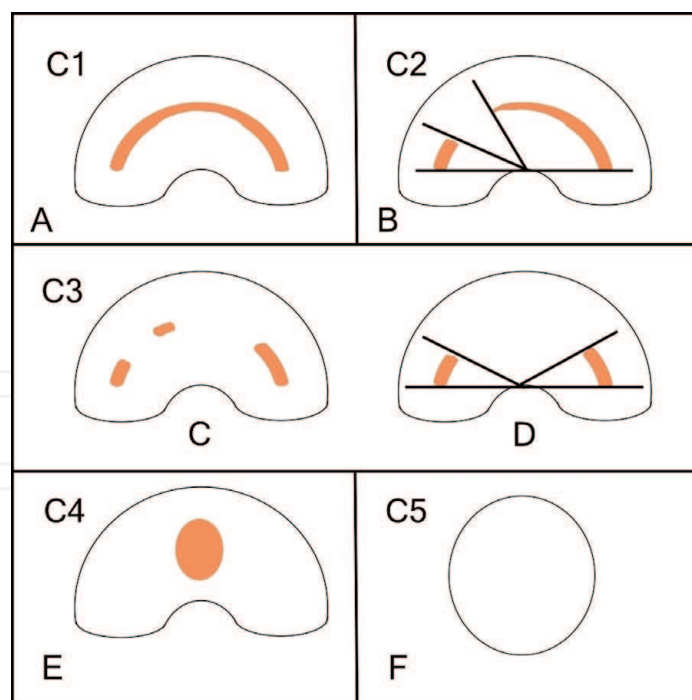


Figure 3.
 This representative illustration explains the classification of C-shaped root canal. (A) Category I; (B) category II; (C) and (D) category III; (E) category IV and (F) category V.

3. Endodontic management

In the field of dentistry, the C-shaped root canal has been of high interest, especially in endodontics. Lack of knowledge regarding root canal anatomy may lead to deficient endodontic treatments [19]. Irregular areas in a C-shaped canal can keep remnants of soft tissue, debris, and infected tissue or may be a source of bleeding during a root canal treatment [20, 21]. Therefore, root canal treatments in these cases may require specific skills.

In 1979, the first case reports of C-shaped root canals were documented [2]. Clinical images were presented where the C shape was evident in mandibular and maxillary molars. Since then, numerous case reports have described their clinical management [22].

The chemomechanical preparation and obturation of C-shaped canals have been challenging in some cases [23]. Sodium hypochlorite has been the most used endodontic irrigant because of its antimicrobial properties and tissue-dissolving capabilities [24]. Obturation techniques with warm condensation have been indicated in some cases of C-shaped root canals [25]. Likewise, the use of manual, rotary, and reciprocating files has resulted effective in mechanical preparation of teeth with aberrant anatomies [26].

The disinfection process is affected for isthmuses and other irregularities. Careful exploration with a small, precurved file may be helpful to locate additional canals. Although it is not possible to carry out an appropriate negotiation in all the canals, the penetration of sodium hypochlorite with ultrasonics may allow an effective disinfection process [27].

4. Conclusions

A thorough understanding of root canal anatomy is of paramount importance in the field of dentistry. Variations in the number of roots and root canal system

anatomy are not uncommon in human teeth. The C-shaped root canal represents an important and challenging anatomical variation. Likewise, knowledge of the different morphologies of C-shaped root canals can help avoid complications during endodontic treatments.

Acknowledgements

The author denies any conflict of interest related to this study.


Author details

Jesús Alejandro Quiñones Pedraza

Department of Endodontics, Intracanal, Monterrey, Nuevo León, México

*Address all correspondence to: aqp.endo@gmail.com

IntechOpen

© 2019 The Author(s). Licensee IntechOpen. This chapter is distributed under the terms of the Creative Commons Attribution License (<http://creativecommons.org/licenses/by/3.0>), which permits unrestricted use, distribution, and reproduction in any medium, provided the original work is properly cited. 

References

- [1] Jafarzadeh H, Wu YN. The C-shaped root canal configuration: A review. *Journal of Endodontics*. 2007;**33**:517-523
- [2] Cooke HG 3rd, Cox FL. C-shaped canal configurations in mandibular molars. *Journal of the American Dental Association*. 1979;**99**:836-839
- [3] Kato A, Ziegler A, Higuchi K, Nakamura H, Ohno N. Aetiology, incidence and morphology of the C-shaped root canal system and its impact on clinical endodontics. *International Endodontic Journal*. 2014;**47**:1012-1033
- [4] Martins JN, Quaresma S, Quaresma MC, Frisbie Teel J. C-shaped maxillary permanent first molar: A case report and literature review. *Journal of Endodontics*. 2013;**39**:1649-1653
- [5] Zheng Q, Zhang L, Zhou X, Wang Q, Wang Y, Tang L, et al. C-shaped root canal system in mandibular second molars in a chinese population evaluated by cone-beam computed tomography. *International Endodontic Journal*. 2011;**44**:857-862
- [6] Sinanoglu A, Helvacioğlu-Yigit D. Analysis of C-shaped canals by panoramic radiography and cone-beam computed tomography: Root type specificity by longitudinal distribution. *Journal of Endodontics*. 2014;**40**:917-921
- [7] Fan B, Cheung GS, Fan M, Gutman JL, Fan W. C-shaped canal system in mandibular second molars: Part II-radiographic features. *Journal of Endodontics*. 2004;**30**:904-908
- [8] Dankner E, Friedman S, Stabholz A. Bilateral C shape configuration in maxillary first molars. *Journal of Endodontics*. 1990;**16**:601-603
- [9] Martins JN, Mata A, Marques D, Anderson C, Caramês J. Prevalence and characteristics of the maxillary C-shaped molar. *Journal of Endodontics*. 2016;**42**:383-389
- [10] Weine FS. The C-shaped mandibular second molar: Incidence and other considerations. *Journal of Endodontics*. 1998;**24**:372-375
- [11] Martins JNR, Francisco H, Ordinola-Zapata R. Prevalence of C-shaped configurations in the mandibular first and second premolars: A cone-beam computed tomographic in vivo study. *Journal of Endodontics*. 2017;**43**:890-895
- [12] Boveda C, Fajardo M, Millan B. Root canal treatment of an invaginated maxillary lateral incisor with a C-shaped canal. *Quintessence International*. 1999;**30**:707-711
- [13] von Zuben M, Martins JNR, Berti L, Cassim I, Flynn D, Gonzalez JA, et al. Worldwide prevalence of mandibular second molar C-shaped morphologies evaluated by cone-beam computed tomography. *Journal of Endodontics*. 2017;**43**:1442-1447
- [14] Helvacioğlu-Yigit D, Sinanoglu A. Use of cone-beam computed tomography to evaluate C-shaped root canal systems in mandibular second molars in a Turkish subpopulation: A retrospective study. *International Endodontic Journal*. 2013;**46**:1032-1038
- [15] Seo MS, Park DS. C-shaped root canals of mandibular second molars in Korean population: Clinical observation and in vitro analysis. *International Endodontic Journal*. 2004;**37**:139-144
- [16] Amoroso-Silva PA, Ordinola-Zapata R, Duarte MA, Gutman JL, del Carpio-Perochena A, Bramante CM, et al. Micro-computed tomographic analysis of mandibular second molars with C-shaped root canals. *Journal of Endodontics*. 2015;**41**:890-895

- [17] Melton DC, Krell KV, Fuller MW. Anatomical and histological features of C-shaped canals in mandibular second molars. *Journal of Endodontics*. 1991;**17**:384-388
- [18] Fan B, Cheung GS, Fan M, Gutmann JL, Bian Z. C-shaped canal system in mandibular second molars: Part I-anatomical features. *Journal of Endodontics*. 2004;**30**:899-903
- [19] Nair PN. On the causes of persistent apical periodontitis: A review. *International Endodontic Journal*. 2006;**39**:249-281
- [20] Ordinola-Zapata R, Bramante CM, de Moraes IG. Analysis of the gutta-percha filled area in C-shaped mandibular molars obturated with modified micro-seal technique. *International Endodontic Journal*. 2009;**42**:186-197
- [21] Gok T, Capar ID, Akcay I, Keles A. Evaluation of different techniques for filling simulated C-shaped canals of 3-dimensional printed resin teeth. *Journal of Endodontics*. 2017;**43**:1559-1564
- [22] Ring J, Ring KC. Rare root canal configuration of mandibular second premolar using cone-beam computed tomographic scanning. *Journal of Endodontics*. 2017;**43**:1897-1900
- [23] Walid N. The use of two pluggers for the obturation of an uncommon C-shaped canal. *Journal of Endodontics*. 2000;**26**:422-424
- [24] Zhender M. Root canal irrigants. *Journal of Endodontics*. 2006;**32**:389-398
- [25] Liewehr FR, Kulild JC, Primack PD. Obturation of a C-shaped canal using an improved method of a warm lateral condensation. *Journal of Endodontics*. 1993;**19**:474-477
- [26] Solomonov M, Paqué F, Fan B, Eliat Y, Berman LH. The challenge of C-shaped canal systems: A comparative study of the self-adjusting file and protaper. *Journal of Endodontics*. 2012;**38**:209-214
- [27] Fan B, Min Y, Lu G, Yang J, Cheung GSP, Gutman JL. Negotiation of C-shaped canal systems in mandibular second molars. *Journal of Endodontics*. 2009;**35**:1003-1008