

# We are IntechOpen, the world's leading publisher of Open Access books Built by scientists, for scientists

6,900

Open access books available

185,000

International authors and editors

200M

Downloads

Our authors are among the

154

Countries delivered to

TOP 1%

most cited scientists

12.2%

Contributors from top 500 universities



WEB OF SCIENCE™

Selection of our books indexed in the Book Citation Index  
in Web of Science™ Core Collection (BKCI)

Interested in publishing with us?  
Contact [book.department@intechopen.com](mailto:book.department@intechopen.com)

Numbers displayed above are based on latest data collected.  
For more information visit [www.intechopen.com](http://www.intechopen.com)



# Role of Medical Therapy in Chronic Mitral Regurgitation

*Ruchika Meel*

## Abstract

Mitral regurgitation is one of the most commonly encountered valvular heart diseases in both the developing and the developed world. From various studies, it is known that chronic mitral regurgitation is associated with progressive left ventricular dysfunction, and eventually death if left untreated. This disease has a long silent period before symptoms manifest. During this latent period, left ventricular function progressively deteriorates and results in poor outcomes for patients even if surgery is performed. A few studies have evaluated the role of medical therapy in patients with chronic mitral regurgitation. This chapter will provide an overview of the use of medical therapy in chronic mitral regurgitation.

**Keywords:** chronic mitral regurgitation, medical therapy

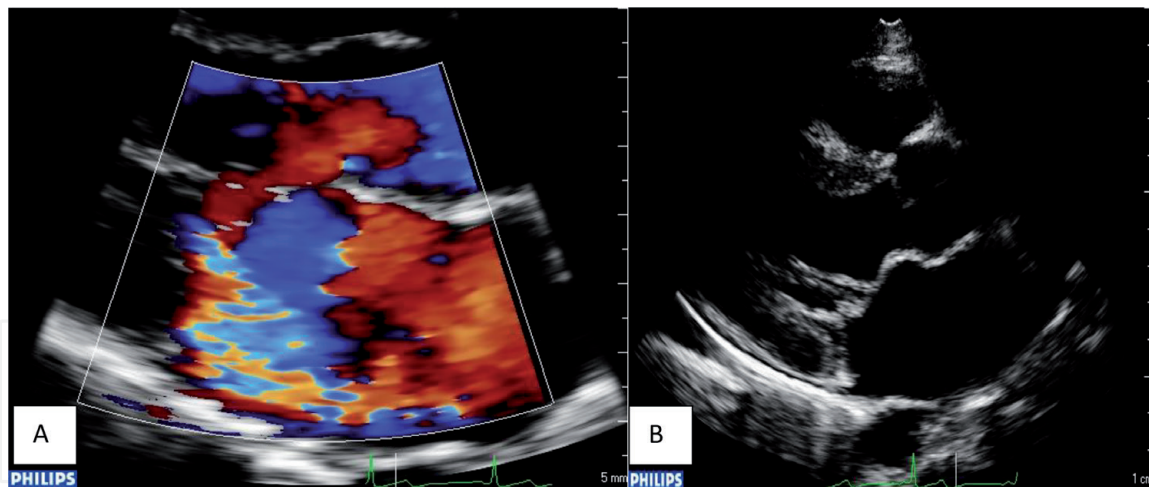
## 1. Introduction

In heart failure (HF), irrespective of aetiology, there is activation of the sympathetic nervous system and the renin angiotensin system that initially serves as compensatory mechanism to maintain the falling cardiac output through retention of sodium and water, peripheral arterial vasoconstriction and increased cardiac contractility [1–3]. However, long term stimulation of these systems has a deleterious effect and results in cardiac remodelling and eventually irreversible HF in the absence of therapy [2, 4]. In HF due to chronic mitral regurgitation (MR) the aforementioned mechanisms are activated and over time result in apoptosis, necrosis and myocyte slippage and left ventricular (LV) remodelling and dilatation from loss of interstitial collagen [3]. There are a number of studies that have evaluated the effects of drugs in degenerative MR. Most of these involved beta blockers or vasodilators. The pathophysiologic basis for their use was to prevent the deleterious effect of sympathetic nervous system in MR, and medical therapy decreased afterload and LV wall stress, thus preventing deleterious remodelling [5].

In this review chapter a brief overview of aetiology and pathophysiology of MR will be provided, followed by the current perspective regarding the value of medical therapy in chronic MR will be discussed.

## 2. Definition and aetiology of mitral regurgitation

Chronic MR is a result of abnormality of the one or more of the components of the mitral valve apparatus [3, 6]. Mitral regurgitation can be a result of abnormality of mitral leaflet, chordae tendineae, papillary muscles and annulus. It can be



**Figure 1.**

(A) Parasternal long-axis view depicting an eccentric anteriorly directed mitral regurgitation jet secondary to restricted posterior mitral leaflet motion. (B) Parasternal long-axis view depicting a contemporary patient with established rheumatic heart disease; thickened shortened chordae, restricted posterior mitral leaflet [7].

primary or secondary. Primary MR is confined to de novo abnormality of the mitral leaflet itself, whereas secondary MR is as a result of another disease process usually involving the LV, which results in a regurgitant mitral valve. Mitral regurgitation results in volume overload of the LV and culminates in left ventricular failure if left untreated.

There are numerous aetiologies of mitral regurgitation [6]. The common cause of MR in the developed world is due to degenerative disease and in the developing world MR is due to rheumatic heart disease (**Figure 1**). Other causes of MR include: infective endocarditis, trauma, drugs, congenital heart disease and annular calcification. Secondary mitral regurgitation is due to coronary artery disease, cardiomyopathies (dilated, hypertrophic cardiomyopathy) and right ventricular pacing.

### 3. Pathophysiology of chronic mitral regurgitation

The amount of blood regurgitating into the left atrium depends on the size of the regurgitant orifice and the pressure gradient between the LV and the left atrium [3]. The regurgitant orifice and the gradient between the LV and the left atrium are not static. The pressure gradient between the two chambers is dependent on the peripheral vascular resistance. The mitral annulus is a dynamic structure and thus any change in the preload, afterload, and contractility alters the size of the annulus due to alteration the LV size. Therefore, when the afterload, preload and contractility decrease, the size of the mitral annulus decreases and so does the regurgitant orifice. Vasodilators, inotropes and diuretics tend to decrease the size of the LV, thus decreasing the mitral annulus size and the area of regurgitant orifice and hence the regurgitant volume. Conversely, any condition that increases the size of the LV increases the mitral annulus size and size of the regurgitant orifice. Further, in addition to magnitude of the pressure gradient difference the duration of the gradient has an effect on volume of regurgitation [8].

Thus, in summary the regurgitant volume can be estimated by the following formulae [9]:

$$\text{Mitral Regurgitant Volume} = \text{Mitral Regurgitant Orifice Area} \times \text{constant} \times \text{Duration of pressure gradient} \times \text{square root (LV Pressure - Left Atrial Pressure)}$$

By altering the LV and left atrial pressure gradient and the orifice size various drugs can decrease or increase the mitral regurgitant volume.

Chronic MR is characterised by a compensated, transitional and decompensated stage [3, 10]. The compensated stage is characterised by LV remodelling. During this stage there is preserved ejection fraction as a result of eccentric ventricular hypertrophy accompanied by an elevated end diastolic volume. There is laying down of sarcomere in series and a shift in pressure-volume curve to the right with a larger volume for any given pressure. The transition phase is characterised by a decline in LV ejection fraction, the regurgitant volume and an increase in the afterload and there is a decrease in myocardial contractility. If untreated, the patient progresses into the decompensated state characterised by neurohormonal activation. There is increased LV stiffness with an increase in end-diastolic and end-systolic volume, preload and afterload with a decline in ejection fraction and stroke volume.

The compensated and the transition phase present opportunity for surgical intervention before the decompensated phase sets in and irreversible myocardial damages ensue. Current valvular heart disease guidelines recommend use of medical therapy for heart failure in patients with mitral regurgitation [11]. Medical therapy in the form of vasodilators and diuretics can be used in patients who are in decompensated phase and are at a high risk for surgery, and in the compensated phase where there is no indication for surgery. In the compensated phase the use of vasodilators aims to decrease the afterload, as it may help delay time to surgery [12].

#### **4. Medical therapy in chronic mitral regurgitation**

In chronic MR the persistent volume overload results in activation of compensatory mechanisms which include activation of sympathetic nervous system-renin angiotensin aldosterone system, the Frank-Starling mechanism and eccentric hypertrophy [3, 13]. Over the long-term, these compensatory mechanisms are deleterious and culminate in myocardial dysfunction and failure. These pathways have provided the rationale for benefit of medical therapy in MR. The following agents have been studied in chronic MR:

1. Vasodilators-angiotensin converting enzyme inhibitors (ACEI), angiotensin receptor blockers (ARB), hydralazine
2. Beta-blockers
3. Aldosterone receptor blockers
4. Combination anti-remodelling therapy

##### **4.1 Vasodilators in chronic mitral regurgitation**

Angiotensin converting enzyme inhibitors (ACEIs) and angiotensin receptor blockers (ARBs) reduce the severity of MR and hence HF symptoms by decreasing the afterload and potentially reversing the remodelling process. The decrease in predominantly peripheral vascular resistance results primarily in decrease in the size of the LV and thus size of the mitral annulus and that of the regurgitant orifice [14–16].

ACEIs have been used in the treatment of systolic HF with significant reductions in morbidity and mortality [17]. In the context of MR, benazepril was used in dogs with moderate to severe MR and showed improved survival [18]. Wisenbaugh et al. studied the effects of captopril in 32 patients with severe isolated MR over a 6-month

period, and found no difference in LV diameters or ejection fraction when compared to placebo [19]. In a trial on humans assessing a combined population of patients with moderate to severe aortic regurgitation and MR, a significant reduction in regurgitant fraction, LV end-systolic and end diastolic volumes and LV mass, was noted when quinapril was used [20]. One study looked at the use of lisinopril in patients with chronic moderate MR with preserved LV ejection fraction and without symptoms. Twenty-three patients were randomised to receive lisinopril or placebo for a period of 12 months. A decrease in regurgitant fraction was noted in the group on lisinopril compared to the placebo arm without a change in left atrial or LV size [21].

In a paediatric case-control study of patients with moderate to severe MR the effect of ACEI on LV size and function was small after a follow-up period of 1 month to 1 year [22].

ARBs seem to produce a similar beneficial effect. In a, small study on the use of losartan for the treatment of MR, a modest but variable improvement in the severity of MR was noted. Specifically, the regurgitant volume and the effective regurgitant orifice decreased and the effect was durable for 1 month [15]. Another trial assessing moderate degenerative and rheumatic MR also found a beneficial effect with losartan over a 6-week period with regards to MR severity, LA size, and LV function [23].

Irbesartan was tested in an animal study. In this study irbesartan was administered to animals with new onset MR for a duration of 3 months. It reduced peripheral vascular resistance in the study group compared to group that received no therapy. However, no effect on LV dimensions was noted [24].

Hydralazine and lisinopril in combination with isosorbide dinitrate have been studied in patients with HF complicated by secondary MR [25, 26]. Hydralazine was tested in a small study of 15 patients with HF and MR, it should a variable response with half the patients showing no or minimal improvement over a follow-up period of 13 months. A second study looked at the benefit of lisinopril and isosorbide dinitrate in patients with HF and MR. This study showed an overall improvement in symptoms, hospitalisations due to HF and in peak oxygen consumption. In terms of reduction in MR severity and LV size, the response was variable.

It is important to note the aetiology of MR when using drugs that venodilate. Venodilators tend to worsen MR in patients with a fixed orifice such as rheumatic heart disease. In these patients venodilation results in a decrease in pulmonary venous pressure and hence a decrease in left atrial pressure, which results in tendency of the blood to follow the path of least resistance, that is, from LV into the left atrium. A reduction in just the systemic vascular resistance as in patients with rheumatic MR and co-morbidity of hypertension results in decrease in MR severity [26].

## **4.2 Beta blockers in chronic mitral regurgitation**

The adrenergic system becomes activated at an early stage in patients with mitral regurgitation [27]. It acts as a support mechanism to maintain the contractility and cardiac output in MR. However, catecholamines are deleterious overlong term. Increased catecholamines induce myocyte apoptosis [28]. Hence, beta blockers are beneficial by preventing cardiac myocyte death due to excessive sympathetic activity.

Beta-blockade has demonstrated efficacy in reducing mortality in patients with cardiac failure due to non-valvular causes [17]. In canine models with chronic experimental MR chronic beta-blocker therapy improves LV function [13]. A pilot study involving patients with moderate to severe MR on beta-blocker therapy (metoprolol) was conducted over a 2-week period. Cardiac magnetic resonance imaging was used

to follow-up this cohort. No reduction in regurgitant volume was demonstrated, however, LV work was reduced by beta-blocker therapy [29]. A larger study was therefore proposed to assess the effect of beta-blockers on LV function and symptoms due to MR. A subsequent trial was published, involving patients with moderate to severe, degenerative MR on beta-blocker therapy, (metoprolol) over a 2-year follow-up. LV function was assessed using cardiac magnetic resonance imaging. Improvements were found in LV ejection fraction and LV early diastolic filling rate. No change in LV end-diastolic volume or LV end-systolic volume was noted [30].

### **4.3 Aldosterone receptor antagonist in chronic mitral regurgitation**

Aldosterone play an important role in HF progression [31]. In HF there is a decline in cardiac output which results in the activation of neurohormonal system and the renin angiotensin aldosterone pathway. The increased level of aldosterone stimulates inflammation and cardiac fibrosis. This results in pathologic cardiac remodelling.

Spironolactone has been evaluated in the context of systolic HF resulting in favourable LV remodelling and a decline in morbidity and mortality through aldosterone antagonism [17, 32]. The mortality reduction in HF was attributed to a decrease in sudden death and progression of HF. No human trials with spironolactone in MR have been noted in the literature. In dogs however, a study investigating spironolactone in moderate to severe MR resulted in a significant reduction (55%) in a composite end-point of cardiac-related death, euthanasia, or severe worsening of MR [33].

### **4.4 Combination anti-remodelling therapy in chronic mitral regurgitation**

There is proven mortality and morbidity benefit of combination anti-remodelling therapy in systolic HF as a result of ischaemia and cardiomyopathies [17, 34, 35]. Guidelines on valvular heart disease recommend medical therapy for HF (EF < 50%) in chronic MR (class IIa, level of evidence B) [36]. However, there are no randomised controlled studies on effects of combination therapy in HF secondary to MR. Recently, in a small observational study Meel et al. showed that combination anti-remodelling therapy may be beneficial for HF secondary to chronic rheumatic MR with no HF related admissions or deaths, and no deterioration in echocardiographic parameters of ventricular size and function [37].

## **5. Conclusion**

Most of above-mentioned trials were small studies involving vasodilators such as ACEIs and beta-blockers in degenerative MR and have been inconclusive. There is limited data pertaining to role of medical therapy in rheumatic MR. In general, LV dysfunction secondary to primary MR tends to respond poorly compared to LV dysfunction complicated by secondary MR. Currently there is no role of medical therapy in asymptomatic patients with chronic MR and preserved LV systolic function. Larger studies are needed to confirm benefit of medical therapy in chronic MR.

## **Conflicts of interest**

The author has no conflicts of interest.

## **Funding**

The author is the recipient of post-doctoral Carnegie Fellowship award.

## **Disclosures**

Parts of this manuscript are a reproduction of author's own work on the subject of mitral regurgitation.

## **Author details**

Ruchika Meel

Division of Cardiology, Department of Internal Medicine, University of the Witwatersrand, Johannesburg, Chris Hani Baragwanath Hospital, Johannesburg, South Africa

\*Address all correspondence to: [ruchikameel@gmail.com](mailto:ruchikameel@gmail.com)

## **IntechOpen**

© 2019 The Author(s). Licensee IntechOpen. This chapter is distributed under the terms of the Creative Commons Attribution License (<http://creativecommons.org/licenses/by/3.0>), which permits unrestricted use, distribution, and reproduction in any medium, provided the original work is properly cited. 

## References

- [1] Hilfiker-Kleiner D, Landmesser U, Drexler H. Molecular mechanisms in heart failure focus on cardiac hypertrophy, inflammation, angiogenesis, and apoptosis. *Journal of the American College of Cardiology*. 2006;**48**:A56-A66
- [2] Cohn J, Ferrari R, Sharpe N. Cardiac remodeling—Concepts and clinical implications: A consensus paper from an international forum on cardiac remodeling. *Journal of the American College of Cardiology*. 2000;**35**:569-582
- [3] Bonow RO, Mann DL, Zipes DP, Libby P. Braunwald's Heart Disease. A Textbook of Cardiovascular Medicine. Vol. 9. Philadelphia: Elsevier Saunders; 2012
- [4] Casaclang-Verzosa G, Gersh B, Tsang T. Structural and functional remodeling of the left atrium. Clinical and therapeutic implications for atrial fibrillation. *Journal of the American College of Cardiology*. 2008;**51**:1-11
- [5] Carabello BA. The current therapy for mitral regurgitation. *Journal of the American College of Cardiology*. 2008;**52**:319-326
- [6] Gaasch WH, Otto CM. Pathophysiology of Chronic Mitral Regurgitation. In: UpToDate, Post TW, editors. Waltham, MA: UpToDate; 2019
- [7] Meel R et al. The changing spectrum of rheumatic mitral regurgitation in Soweto, South Africa. *Cardiovascular Journal of Africa*. 2017;**28**:215-220
- [8] Topilsky Y, Michelena H, Bichara V, et al. Mitral valve prolapse with mid-late systolic mitral regurgitation: Pitfalls of evaluation and clinical outcome compared with holosystolic regurgitation. *Circulation*. 2012;**125**:1643
- [9] Gaasch WH, Aurigemma GP. Inhibition of the renin-angiotensin system and the left ventricular adaptation to mitral regurgitation. *Journal of the American College of Cardiology*. 2002;**39**:1380
- [10] Gaasch WH, Meyer TE. Left ventricular response to mitral regurgitation: Implications for management. *Circulation*. 2008;**118**:2298-2303
- [11] Baumgartner H, Falk V, Bax JJ, De Bonis M, et al. ESC/EACTS guidelines for the management of valvular heart disease. *European Heart Journal*. 2017;**38**:2739-2791
- [12] Gaasch WH, Otto CM. Vasodilator Therapy in Chronic Mitral Regurgitation. In: UpToDate, Post TW, editors. Waltham, MA: UpToDate; 2018
- [13] Tsutsui H, Spinale FG, Nagatsu M, et al. Effects of chronic beta-adrenergic blockade on the left ventricular and cardiocyte abnormalities of chronic canine mitral regurgitation. *The Journal of Clinical Investigation*. 1994;**93**:2639-2648
- [14] Levine HJ, Gaasch WH. Vasoactive drugs in chronic regurgitant lesions of the mitral and aortic valves. *Journal of the American College of Cardiology*. 1996;**28**:1083
- [15] Dujardin KS, Enriquez-Sarano M, Bailey KR, et al. Effect of losartan on degree of mitral regurgitation quantified by echocardiography. *The American Journal of Cardiology*. 2001;**87**:570
- [16] Rosario LB, Stevenson LW, Solomon SD, et al. The mechanism of decrease in dynamic mitral regurgitation during heart failure treatment: Importance of reduction in the regurgitant orifice size. *Journal of the American College of Cardiology*. 1998;**32**:1819

- [17] Yancy CW, Jessup M, Bozkurt B, et al. ACCF/AHA guideline for the management of heart failure: A report of the American College of Cardiology Foundation/American Heart Association task force on practice guidelines. *Circulation*. 2013;**128**:240-327
- [18] Kittleson M, Rishniw M, Pion P, et al. Effect of benazepril on survival and cardiac events in dogs with asymptomatic mitral valve disease: A retrospective study of 141 cases. *Journal of Veterinary Internal Medicine*. 2009;**23**:953-954
- [19] Wisenbaugh T, Sinovich V, Dullabh A, et al. Six month pilot study of captopril for mildly symptomatic, severe isolated mitral and isolated aortic regurgitation. *The Journal of Heart Valve Disease*. 1994;**3**:197-204
- [20] Schön HR, Schröter G, Barthel P, et al. Quinapril therapy in patients with chronic mitral regurgitation. *The Journal of Heart Valve Disease*. 1994;**3**:303-312
- [21] Marcotte F, Honos GN, Walling AD, et al. Effect of angiotensin-converting enzyme inhibitor therapy in mitral regurgitation with normal left ventricular function. *The Canadian Journal of Cardiology*. 1997;**13**:479
- [22] Knirsch W, Tlach L, Stambach D, et al. Angiotensin-converting enzyme inhibitors in pediatric patients with mitral valve regurgitation—Case-control study and review of the literature. *Congenital Heart Disease*. 2010;**5**:278-284
- [23] Sekuri C, Utuk O, Bayturan O, et al. Effect of losartan on exercise tolerance and echocardiographic parameters in patients with mitral regurgitation. *Journal of the Renin-Angiotensin-Aldosterone System*. 2008;**9**:107-111
- [24] Perry GJ, Wei CC, Hanks GH, et al. Angiotensin II receptor blockade does not improve left ventricular function and remodeling in subacute mitral regurgitation in the dog. *Journal of the American College of Cardiology*. 2002;**39**:1374
- [25] Greenberg BH, DeMots H, Murphy E, et al. Arterial dilators in mitral regurgitation: Effects on rest and exercise hemodynamics and long-term clinical follow-up. *Circulation*. 1982;**65**:181
- [26] Levine AB, Muller C, Levine TB. Effects of high-dose lisinopril-isosorbide dinitrate on severe mitral regurgitation and heart failure remodeling. *The American Journal of Cardiology*. 1998;**82**:1299
- [27] Carabello BA. Beta-blockade for mitral regurgitation. Could the management of valvular heart disease actually be moving into the 21st century? *Journal of the American College of Cardiology*. 2012;**60**:839-840
- [28] Amin P, Singh M, Singh K. Adrenergic receptor-stimulated cardiac myocyte apoptosis: Role of 1 integrins. *Journal of Signal Transduction*. 2011;**2011**. Article ID: 179057
- [29] Stewart S, Wilkinson W, Hansen C, et al. Predominance of heart failure in the heart of Soweto study cohort: Emerging challenges for Urban African communities. *Circulation*. 2008;**118**:2360-2367
- [30] Ahmed M, Aban I, Lloyd S, et al. A randomized controlled phase IIb trial of beta 1-receptor blockade for chronic degenerative mitral regurgitation. *Journal of the American College of Cardiology*. 2012;**60**:833-838
- [31] He BJ, Anderson ME. Aldosterone and cardiovascular disease: The heart of the matter. *Trends in Endocrinology and Metabolism*. 2013;**24**:21-30
- [32] Soberman JE, Weber KT. Spironolactone in congestive heart

failure. *Current Hypertension Reports*.  
2000;2:451-456

[33] Bernay F, Bland J, Häggström J, et al. Efficacy of spironolactone on survival in dogs with naturally occurring mitral regurgitation caused by myxomatous mitral valve disease. *Journal of Veterinary Internal Medicine*. 2010;24:331-341

[34] Merlo M, Pyxaras S, Pinamonti B, et al. Prevalence and prognostic significance of left ventricular reverse remodeling in dilated cardiomyopathy receiving tailored medical treatment. *Journal of the American College of Cardiology*. 2011;57:1468-1476

[35] Cicoira M, Zanolli L, Rossi A, et al. Long-term, dose-dependent effects of spironolactone on left ventricular function and exercise tolerance in patients with chronic heart failure. *Journal of the American College of Cardiology*. 2012;40:304-310

[36] Nishimura RA, Otto CM, Bonow RO, et al. AHA/ACC guideline for the management of patients with valvular heart disease: A report of the American College of Cardiology/American Heart Association task force on practice guidelines. *Journal of the American College of Cardiology*. 2014;63:57-185

[37] Meel R, Peters F, Libhaber E, et al. Is there a role for combination anti-remodelling therapy for heart failure secondary to chronic rheumatic mitral regurgitation? *Cardiovascular Journal of Africa*. 2017;28:280