

# We are IntechOpen, the world's leading publisher of Open Access books Built by scientists, for scientists

6,900

Open access books available

186,000

International authors and editors

200M

Downloads

Our authors are among the

154

Countries delivered to

TOP 1%

most cited scientists

12.2%

Contributors from top 500 universities



WEB OF SCIENCE™

Selection of our books indexed in the Book Citation Index  
in Web of Science™ Core Collection (BKCI)

Interested in publishing with us?  
Contact [book.department@intechopen.com](mailto:book.department@intechopen.com)

Numbers displayed above are based on latest data collected.  
For more information visit [www.intechopen.com](http://www.intechopen.com)



# MR-Guided Laser Interstitial Thermal Therapy for Treatment of Brain Tumors

*Alexa Semonche, Evan Luther, Katherine Berry, Ashish Shah, Daniel Eichberg, Long Di, Michael Kader and Michael E. Ivan*

## Abstract

Minimally invasive technologies for intracranial lesions are a rapidly growing area of surgical neuro-oncology. Magnetic resonance (MR)-guided laser interstitial thermal therapy (LITT) is novel adjunctive therapy for patients who are poor candidates for open surgical resection. Recent developments in modern stereotaxy, fiber optics, and MR thermography imaging have improved the safety profile of LITT, enabling its emergence as an attractive alternative adjunct therapy for intracranial lesions which are deep-seated, refractory to standard therapies, or in patients with multiple comorbidities. In this chapter, we review the technological principles underlying LITT and provide a comprehensive, up-to-date summary of the evidence regarding the indications, outcomes, and limitations of LITT for a diverse array of intracranial tumors, including dural-based lesions, metastases, gliomas, and radiation necrosis.

**Keywords:** LITT, laser, glioma, glioblastoma, astrocytoma, ablation

## 1. Introduction

### 1.1 LITT surgical procedure and current commercial platforms

LITT is a minimally invasive neurosurgical technique that delivers focused thermal energy from a laser light source via a fiber optic ensheathed in a catheter targeted to an intracranial lesion under stereotactic neuronavigation [1–6]. Currently, there are two Food and Drug Administration (FDA)-approved LITT platforms available for use in the United States: the Visualase Thermal Therapy System (Medtronic, Inc.; approved in 2009) and the Neuroblate Laser Ablation System (Monteris, Inc.; approved in 2007).

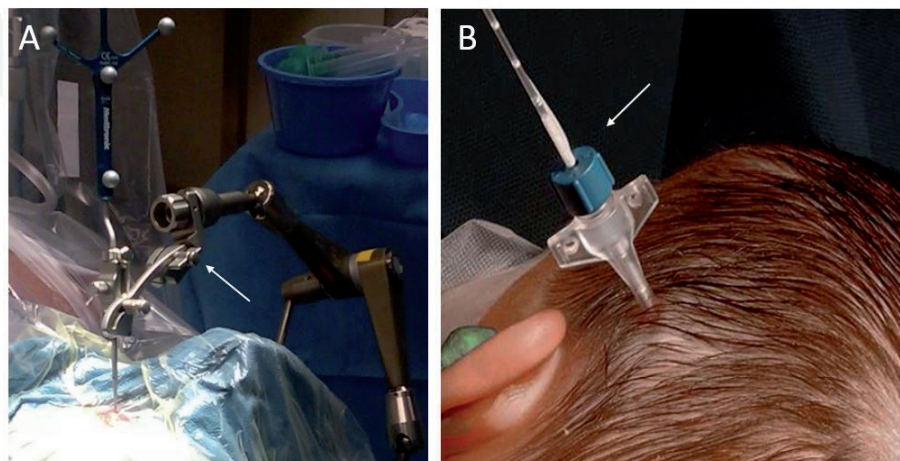
The Visualase and Neuroblate LITT platforms share similar components and a standardized general workflow. The patient is first induced under general anesthesia or monitored anesthesia care (MAC). The trajectory for stereotactic placement of the laser catheter is planned using standard neuronavigation technology with preoperative T1-weighted gadolinium enhanced magnetic resonance imaging (MRI) studies. The trajectory should be planned so that the catheter traverses the longest axis of the lesion without risking injury to any critical

structures. Stereotactic registration of the laser catheter and trajectory planning can be performed using either a traditional headframe or frameless setup. Frameless stereotaxy requires an additional computed-tomography (CT) with fiducial markers, which is then merged with the pre-operative MRI for registration with neuronavigation.

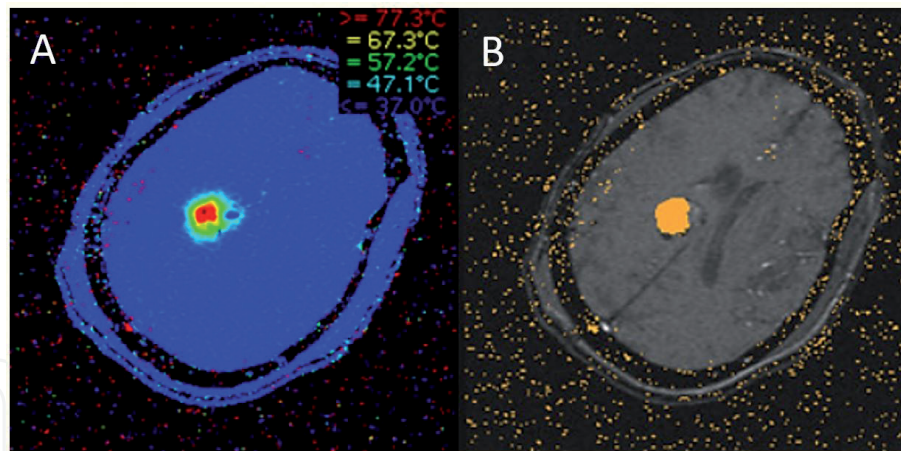
Following stereotactic registration, a Precision Aiming Device (PAD) is aligned over the planned skull entry site using neuronavigation. A single 4 mm skin incision and burr hole is made over the entry point. The surgeon may elect to perform a concurrent needle biopsy for histopathological diagnosis. After this, a reducing cannula followed by the laser catheter is inserted through this burr hole using the PAD to ensure proper entry angle to follow the planned trajectory. Once the laser applicator probe's position is fixed using a plastic anchor bolt embedded in the skull, the patient is transferred, under anesthesia, to a MRI suite. Care is taken to prevent contamination in the operating room until T2 weighted MRI confirms the correct placement of the laser fiber. Then, near-infrared laser light (980 nm in the Visualase, system, 1064 nm in the Neuroblate system) is delivered through the fiber optic cable within the applicator probe to the target lesion. Following LITT treatment, the catheter is removed and the stab incision is closed with absorbable sutures. An example of the Visualase LITT catheter after stereotactic placement is shown in **Figure 1**.

The delivery of thermal energy to the intracranial target is controlled by several mechanisms. The fiber optic laser catheter is encased in a cooling sheath, through which cooled saline (in the Visualase system) or a CO<sub>2</sub> gas (in the Neuroblate system) is circulated. This mechanism prevents the heating of brain parenchyma along the catheter path so that thermal damage is restricted to the region surrounding the distal tip [7]. At the distal tip, the distribution of laser light to surrounding target tissue is controlled via a diffusing tip to produce a spherical zone of ablation centered at the tip. Available only in the NeuroBlate system, laser light can be delivered through a small aperture along the lateral surface of the distal catheter to provide a cone-shaped region of directional ablation.

Finally, real-time MR thermography is performed concurrently with laser ablation to generate a thermal damage estimate (TDE) heat map, i.e., a color-coded visual representation of cumulative thermal damage to structures on a T2-weighted MRI (**Figure 2**).



**Figure 1.**  
(A) Intraoperative setup showing precision aiming device (PAD) (white arrow) and stealth neuronavigation wand (Medtronic, Inc.) to set laser catheter trajectory. (B) MRI-compatible laser catheter and plastic bone anchor after stereotactic PAD-assisted intracranial placement.



**Figure 2.**  
 (A) Real-time MR thermography provides a continuously updated heat map with concentric temperature zones. (B) Thermal damage estimate (TDE) mapping for LITT. Orange pixels estimate a zone of ablation based on a user-set threshold for sufficient ablation temperature (typically  $50^{\circ}\text{C}$ ).

A computer workstation has software that allows the user to adjust laser output parameters and deliver laser energy in a series of doses until the TDE map covers the total area of the target. This is typically achieved with 10–15 W doses of laser light delivered in 30s–3 minutes intervals for a total of 10–30 minutes. The user also sets minimum and maximum temperature threshold markers on MR images defining the boundaries of the lesion. Minimum temperature markers ensure that temperatures sufficient for ablation are achieved within the target lesion volume ( $50$ – $90^{\circ}\text{C}$ ), while maximum temperature thresholds ensure that off-target regions do not reach damaging temperatures [8]. Surpassing the maximum temperature threshold triggers automatic system shutoff [9]. The majority of patients have a hospital stay less than 48 hours following LITT [8–11].

Post-operative T1-weighted gadolinium enhanced MRI is typically obtained on day one following LITT, 1–3 months post-operatively, and then at longer follow-up intervals depending on clinical status. There is a typical radiographic increase in size of the ablated lesion in the acute period following LITT, peaking around 3–4 days and reaching a 45% increase in cross-sectional area corresponding to a 75% increase in volume [12, 13]. The initial increase in size seen within the first 24 hours post-op likely represents the tendency to “over-ablate” lesions and is secondary to perilesional edema that is difficult to differentiate radiographically. A significant amount of size variability is also seen in these newly ablated lesions and is attributed to multiple factors including heterogeneous gadolinium dispersion during the ablation process, heterogeneous disruption of vascular integrity, and the “extreme” variability in the amount of edema surrounding the lesion. These findings clearly lead to imaging heterogeneity and suggest that an accurate measurement of the lesion would be difficult to obtain in the first 24 hours post-LITT. Therefore, it has been suggested that MRI is more accurate at determining LITT ablation size and shape at 24 hours post-ablation rather than immediately post-LITT.

On T1-weighted gadolinium enhanced MRI, the thermal ablation zone has a thin enhancing rim with potential surrounding edema and enhancing residual blood products/protein coagulation [8]. Residual tumor remaining after subtotal ablation can be detected on this first post-operative scan. The extent of ablation can be determined by comparing volumetric analysis of the ablation zone post-operatively to the volume of the lesion on the pre-operative MRI, as described previously [14].



## 2. Current applications of LITT in neuro-oncology

### 2.1 Patient selection

LITT offers a minimally-invasive cytoreductive therapy for patients with surgically-inaccessible or treatment-refractory tumors who would likely not benefit from open surgical resection. Selection of appropriate cases for LITT is of primary concern. Over the past two decades, the first institutional experiences with LITT using MR thermography and modern stereotactic targeting were published, demonstrating both representative successes and complications associated with the procedure, including post-operative symptomatic edema, neurological deficit, and hemorrhage [4, 8, 15]. These results signaled the need to refine patient selection criteria to maximize changes of treatment success while minimizing risk of complications. From these initial studies in addition to our own institutional experiences [14, 16–18], we can summarize the following indications for LITT:

1. Anatomic location permits a reasonable expectation of an 80% ablation in order to confer a significant survival benefit [16, 19–21].
2. Lesion location is inaccessible via conventional open surgery (e.g., lesions located adjacent to deep structures such as the basal ganglia, thalamus, splenium, etc., in eloquent motor or speech areas, or near critical neurovascular structures).
3. Lesions have failed previous treatments (i.e., previous craniotomy or radiation).
4. Patients have medical comorbidities, low pre-operative functional status, or history of previous craniotomy/radiation therapy who are unable to tolerate prolonged anesthesia, blood loss, or who are at high risk of surgical morbidity and impaired wound healing.
5. Pediatrics: although cases must be carefully selected, there are currently no changes in protocol for the use of LITT in pediatric neurosurgery.

Additionally, we can summarize the following restrictions to best avoid procedural complications:

1. Functional status: patients should still have a pre-operative functional status appropriate for a minimally-invasive surgical procedure under anesthesia; in our institutional experience, patients are eligible if they have a Karnofsky Performance Score (KPS) of at least 70.
2. Lesion size: LITT should be limited to lesions with <3 cm diameter in any dimension. This size restriction stems from Jethwa et al., who reported the case of patient with a large (>3 cm) lesion treated with LITT who later underwent hemispherectomy for medically-refractory post-ablation edema [8]. The <3 cm guideline also reduces risk of damage to critical brain regions.
3. LITT trajectory: careful precautions must be made while choosing a trajectory to avoid critical neurovascular structures. In some cases, passing through virgin white matter should take priority over creating the shorter trajectory if the shortest trajectory involves eloquent tissue.

In the following sections we review the current state of LITT for treatment for a variety of intracranial tumors.

## 2.2 Glioma

Recent studies have shown that greater extent of surgical resection improves progression-free and overall survival in high-grade gliomas (HGGs) [22, 23]. Although HGGs inevitably recur, some patients may not be able to undergo conventional open surgical resection due to medical comorbidities, inability to tolerate general anesthesia, or have surgically inaccessible tumor locations. In addition, risk of neurological morbidity increases with repeat craniotomy and previous radiation therapy increases risk of impaired wound healing and radiation necrosis or secondary tumor formation [24]. Up to 40% of GBM tumors are considered surgically “unresectable” based on either their location in deep or eloquent brain regions or their proximity to critical neurovascular structures [14, 25]. For these patients, laser interstitial thermal therapy (LITT) provides an alternative option for cytoreductive therapy.

The first case series reporting the use of LITT in gliomas was published in 1990 by Sugiyama et al., which described the successful total ablation of five deep-seated gliomas. This has been followed by several larger case series for both recurrent and newly-diagnosed glioblastoma multiforme (GBM) [8, 10, 11, 15, 26–30]. In these series, median recurrence-free survival ranged from 1.5 to 14.3 months and overall survival ranged from 6.9 to 16 months. These reports are consistent with estimated median survival of 14.8 and 6 months for newly-diagnosed and recurrent gliomas under standard therapy, respectively [31]. Our institutional data for deep-seated (at least 2 cm from dura) newly diagnosed gliomas further evidenced the procedural safety and efficacy in 7 patients, with a median progression-free survival of 14.3 months and 85% patients remaining alive at 14 months follow-up. As such, LITT is an emerging safe adjuvant therapy for gliomas that are considered surgically inaccessible. A recent meta-analysis reported an overall survival of nearly 14 months (range: 0.1–23 months) for patients treated with LITT and adjuvant chemoradiation, which was comparable to reported outcomes after standard treatment (gross total resection and adjuvant chemoradiation) [16, 32–34].

## 2.3 Dural-based lesions

Although evidence is more limited for dural-based lesions, the published studies to date support the safety and efficacy of LITT for these lesions. An initial case series by Ivan et al. reported outcomes in 5 patients with 3 recurrent low-grade meningiomas, 1 grade III malignant meningioma, and 1 solitary fibrous tumor. Ivan et al. report an average extent of ablation of 80% and a local control rate of 60% at a mean follow-up of 59.3 weeks. The procedure was well-tolerated in these patients with no complications reported [18]. Only one other case series of three patients has been reported [35]. Two patients had grade III anaplastic meningiomas while the third had a low-grade lesion. The authors report an average extent of ablation of 75% with 2 of 3 lesions recurring by 9 weeks. One patient experienced transient hemiparesis with dysarthria, which resolved.

In comparison to other reports of LITT for intracranial lesions, these studies report lower extent of ablation rates, which may be attributable to tissue consistency. In these studies, the presence of a grade III malignant meningioma complicates the picture regarding the efficacy of LITT for dural-based lesions. Nonetheless, the procedure is generally well-tolerated, justifying further investigation into its utility for these lesions.

## 2.4 Brain metastases

LITT is a promising adjuvant therapy for recurrent brain metastases refractory to stereotactic radiosurgery (SRS). The first case series of LITT for brain metastases was reported by Carpentier et al. [41]. A subsequent Phase I clinical trial by the same authors, published in 2011, reported 6-month local control rates of 60 and 85% for partially and fully-ablated metastatic tumors, respectively [36]. In 2016, Ali et al. identified an 80% extent of ablation threshold, below which all cases eventually recurred [37]. Similarly, Ahluwalia et al. reported a 0% recurrence rate in 100% ablated lesions [38]. A recent systematic review found that reports of median overall survival after LITT for metastases ranged from 5.8 to 19.8 months [39]. Across studies, the most commonly reported complications were temporary neurologic deficit due to unintentional thermal ablation of eloquent structures, followed by hemorrhage. Although a 1–3 day period of post-operative edema on T2 FLAIR MRI sequences frequently occurs post-ablation, this typically resolves. In four rare instances of malignant edema requiring hemicraniectomy, the lesion volumes were far greater than 3 cm in diameter [39]. These recent studies support that LITT is safe and effective in cases where 80–100% lesional ablation can be achieved.

## 2.5 Radiation necrosis

LITT was first described for radiation necrosis (RN) by Rahmathulla et al. [40]. In this report, a single patient presented with progressive dysphagia following radiosurgery for brain metastasis almost 2 years prior. Because the symptoms did not respond to medical management with steroids, he was treated with LITT. Following LITT, he achieved steroid independence [40]. This study was followed by larger single-center retrospective case series which reported use of LITT for radiation necrosis with initial diagnoses of glioma or metastases. In these studies <50% of patients achieved steroid freedom, and up to 20% of patients required open craniotomy for surgical resection in the months following LITT [38]. In a study of LITT for radiation necrosis or post-radiosurgery recurrent metastasis, Rao et al., reported a median progression-free survival of 37 weeks with only 2 recurrences in 15 patients [5]. The authors concluded that LITT is a safe, well-tolerated procedure for patients with radiation necrosis or metastatic recurrence.

Our institutional experience with 20 patients with biopsy-proven RN between 2015 and 2018 also supports these conclusions (unpublished data). At 1 year follow-up, 80% of patients remained recurrence free, with a median progression-free survival of 12.3 and 24.4 months overall survival. No permanent complications occurred (unpublished data).

Overall evidence supports LITT as a safe procedure for radiation necrosis that is medically refractory or surgically inaccessible. In these patients, steroid freedom as well as progression-free and overall survival are important clinical outcomes.

## 3. Illustrative case series

Here we present four cases of patients treated by the department of surgical neuro-oncology at the University of Miami illustrating the use of LITT for gliomas, dural-based lesions, brain metastases, and radiation necrosis.

### 3.1 Case 1: recurrent glioma

A 37-year-old female with previous history of left frontoparietal craniotomy and chemoradiation for high-grade glioma 2 years prior presented with progressive

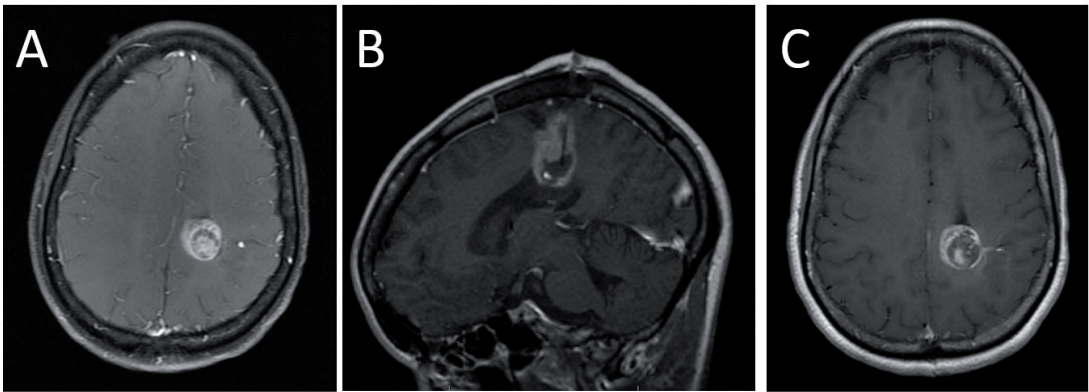
enhancement on surveillance MRI suggesting recurrence (**Figure 3A**). The patient was recommended LITT due to the lesion's proximity to the left motor strip. The lesion was ablated according to the following parameters:

1. Test dose at 3 W for 30 seconds to confirm location of catheter tip on MR thermography.
2. Increase in laser power to 50% maximum power for up to 3 minutes.
3. Increase in laser power at 20% maximum intervals for 30 seconds—1.5 minutes in series until maximal ablation zone is achieved (**Figure 3B**).

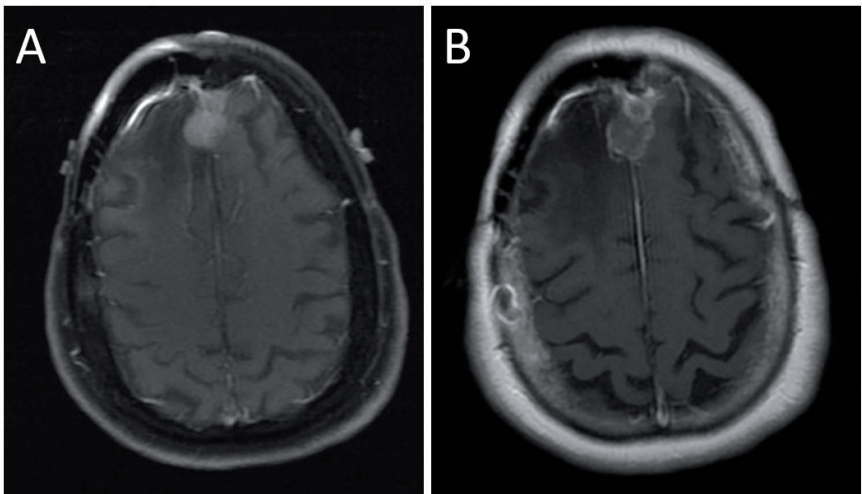
The patient recovered without complications. Although some residual tumor was present on postoperative imaging (**Figure 3C**), the patient remained recurrence free for 24.3 weeks with an overall survival of 1 year.

### 3.2 Case 2: meningioma

A 65-year-old female with previous history of craniotomy for resection of a right parafalcine meningioma and subsequent craniectomy for a wound infection



**Figure 3.**  
(A) A 37-year-old female with periventricular ring-enhancing mass abutting the left motor strip on axial T1-weighted MRI with contrast. (B) Intraoperative sagittal MRI showing laser catheter trajectory. (C) Immediate post-operative axial T1-weighted MRI with contrast demonstrating near-total lesional ablation.



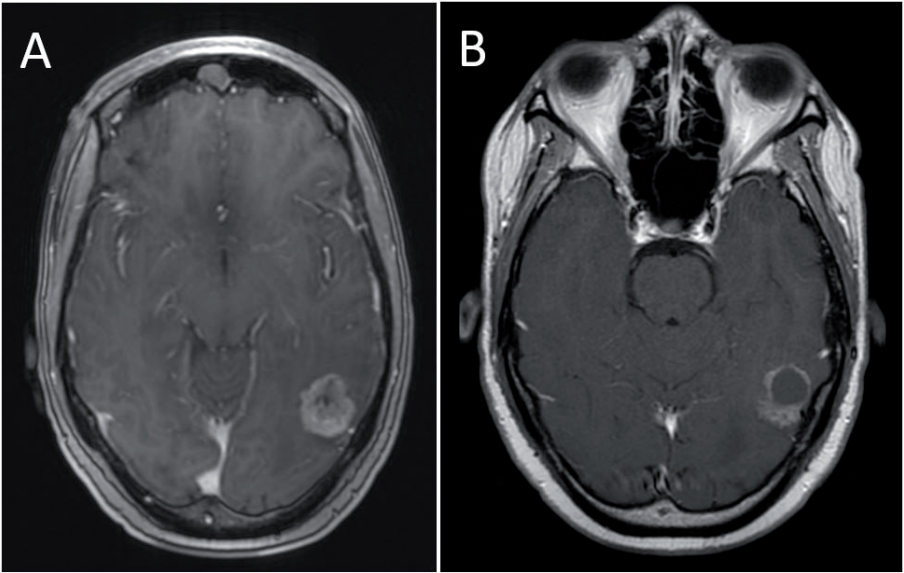
**Figure 4.**  
(A) Pre-operative T1-weighted MRI with contrast showing recurrence of right parafalcine meningioma. (B) Post-operative T1-weighted MRI with contrast showing near-total lesional ablation.



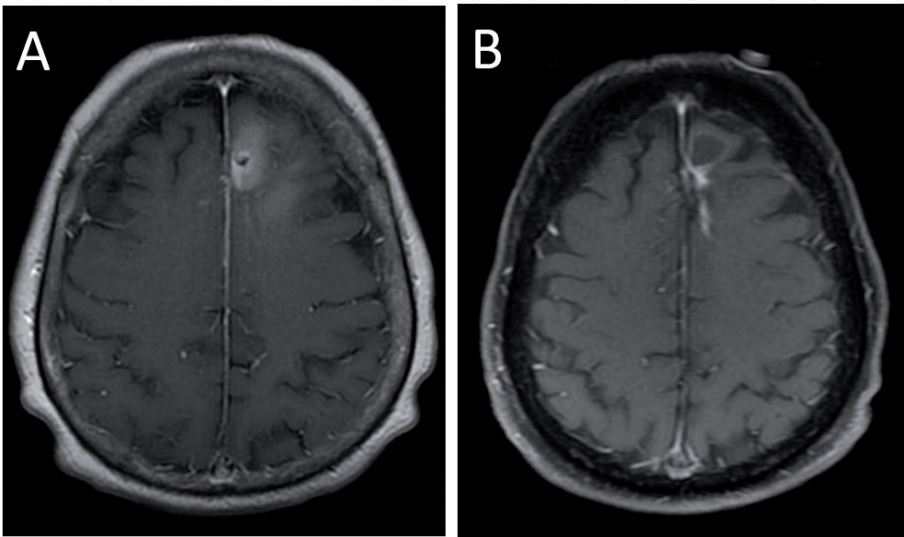
at an outside institution presented with progressive lesion regrowth over several MRI studies (**Figure 4A**). Because of her complicated surgical history, she was recommended LITT. Postoperative MRI imaging showed 97% extent of ablation (**Figure 4B**) and the patient recovered without complications. Patient remained recurrence free until non-neurologic death 4 years later.

3.3 Case 3: metastasis

A 31-year-old female with past medical history of metastatic breast cancer previously treated with whole brain radiation and stereotactic radiation for five intracranial metastatic lesions. She presented with headaches photophobia, dizziness, and fatigue. T1-weighted gadolinium enhanced MRI showed interval growth of one lesion in the right parietal lobe. Due to her extensive previous radiation history and the proximity of the lesion to the receptive speech area of the posterior left temporal lobe, the patient was treated with LITT, achieving near-total



**Figure 5.**  
(A) A 31-year-old female patient with recurrent metastatic breast cancer adjacent to the receptive speech area of the posterior temporal lobe. (B) Post-LITT procedure T1-weighted MRI shows lesional ablation.



**Figure 6.**  
(A) A 69-year-old female patient with progressive enhancement after treatment of metastatic lung adenocarcinoma. (B) Post-LITT procedure T1-weighted MRI with contrast shows successful lesion ablation.

ablation (**Figure 5B**). Patient remained recurrence free until last follow-up at 16 months post-procedure.

### 3.4 Case 4: radiation necrosis

A 69-year-old woman with history of metastatic lung adenocarcinoma previously treated with open surgical resection and stereotactic radiosurgery presented with asymptomatic progressive enhancement on surveillance MRI (**Figure 6A**). Because of her treatment history, the patient elected to undergo LITT. Patient recovered without complications and remained recurrence free at last follow-up, over 1 year after LITT (**Figure 6B**). Intraoperative needle biopsy performed prior to laser catheter placement confirmed diagnosis of radiation necrosis.

## 4. Discussion

### 4.1 Current role of LITT in neurosurgery

Technological advances in MR thermography and stereotactic surgery over the past two decades have facilitated the development of commercial LITT platforms. Evidence from both prospective and retrospective studies show that LITT is a safe alternative for cytoreduction in a wide variety of intracranial lesions, including metastases, radiation necrosis, dural-based lesions, and gliomas.

The advantage of LITT in treating intracranial lesions include:

1. Cytoreductive therapy in poor open-surgical candidates: a minimally invasive approach through a single burr hole reduces the risk of morbidity associated with craniotomy for surgical resection. This is especially relevant for patients who previously underwent open craniotomy or maximal radiotherapy, who are at higher risk of neurological sequelae and wound infection with repeat craniotomy [21, 24] or in patients with tumors in deep or eloquent regions of brain that would otherwise be considered surgically inaccessible.
2. Short procedure time: LITT has a shorter procedure time compared to open craniotomy. With shorter recovery times, LITT does not interrupt chemotherapy or other adjuvant therapy [10, 17].
3. Potential for repeated use: unlike stereotactic radiosurgery, LITT can be repeatedly applied and can thus be used as a salvage therapy in treatment-refractory tumors while avoiding the increased risk of secondary malignancy or radiation necrosis associated with ionizing radiation [7, 16].

Patient selection is of critical importance to ensure safe and effective use of LITT. To summarize, lesions should be <3 cm in diameter, in a region that can be accessed via a linear laser catheter trajectory without injury to critical structures and in patients who are able to tolerate a minimally-invasive surgical procedure under anesthesia. In addition, the lesion should have identifiable margins such that at least 80% of the target area can be feasibly ablated with a roughly-spherical ablation zone.

### 4.2 Limitations of LITT

Limitations of LITT include complications; the most common adverse events include intracranial hemorrhage and transient neurological deficit [10, 39, 41].

Intracranial hemorrhage may be secondary to laser catheter misplacement, off-target thermal ablation, or (in the case of brain metastases) an underlying patient coagulopathy [8, 39, 42]. This risk can be reduced with preoperative neuroimaging (e.g., computed tomography angiogram (CTA)) to better inform laser trajectory planning. Estimates of hemorrhage range from 0.98 to 14.2% of cases [39, 42].

Permanent neurological deficits are rare [42], but transient neurological deficits have been reported to occur in up to 35% of patients [39, 42]. Examples of commonly reported neurological deficits include weakness, hemianopsia, seizures, and dysphagia are often attributed to direct thermal injury to functional brain areas or cerebral edema. Cerebral edema is frequently observed in the immediate post-operative period following LITT, but is unlikely to cause permanent neurological deficits and may be controlled with a short course of steroids. Treatment of large (>3 cm) or use of multiple laser probes or laser trajectories is associated with a higher risk of significant cerebral edema [43].

Rare (<5% of all cases) complications include permanent neurological deficit, malignant cerebral edema requiring hemicraniectomy, infection (e.g., ventriculitis, meningitis, or brain abscess), diabetes insipidus, hyponatremia, and intracranial hypertension. There are only two recorded deaths attributed to LITT in the literature, from postoperative meningitis and intracranial hemorrhage, respectively [44].

Another limitation of LITT is that it is only appropriate for certain patients. As discussed previously, previous treatment history, baseline neurological functional status, and anticipated extent of ablation are also factors that limit use of LITT to selected patients.

### **4.3 Future directions**

Recent studies have focused on expanding the selection criteria for LITT, for example by staging the treatment of larger (>3 cm) lesions and application to other tumors, such as pediatric tuberous sclerosis and hypothalamic hamartomas [45]. In addition, the application of computer algorithms to better predict laser ablation dynamics may further improve the procedural safety profile [46].

Another body of research is investigating the secondary effects of LITT, including blood–brain barrier (BBB) disruption, which may offer a window of opportunity for enhanced delivery of chemotherapy [47, 48]. Other studies are investigating the potential immunostimulatory effects of LITT [49, 50]. In this sense, LITT could both ablate and facilitate a future antitumor immune response [51].

Finally, future investigations will require prospective, randomized-controlled trials to evaluate the clinical outcomes of LITT compared to other salvage therapies, such as repeat craniotomy or radiosurgery.

## **5. Conclusion**

In this chapter we reviewed the current evidence regarding safety and efficacy of LITT for four types of intracranial lesions: gliomas, metastases, dural-based lesions, and radiation necrosis. Although future randomized controlled trials are necessary to compare clinical outcomes, the evidence so far supports LITT as a safe and viable minimally-invasive approach to cytoreduction in patients with gliomas that are poor open surgical candidates.

## **Acknowledgements**

The authors have no source of financial support to report.

## Conflict of interest

Michael Ivan is a consultant for Medtronic. The other authors have no financial, personal, or institutional interests in any of the materials, devices, or drugs described in this article. Laser Ablation is only an Food and Drug Administration approved procedure for the ablation of soft tissue.

## Author details

Alexa Semonche, Evan Luther, Katherine Berry, Ashish Shah, Daniel Eichberg, Long Di, Michael Kader and Michael E. Ivan\*  
Department of Neurological Surgery, University of Miami Miller School of Medicine, Sylvester Comprehensive Cancer Center, Miami, United States

\*Address all correspondence to: [mivan@med.miami.edu](mailto:mivan@med.miami.edu)

## IntechOpen

© 2019 The Author(s). Licensee IntechOpen. This chapter is distributed under the terms of the Creative Commons Attribution License (<http://creativecommons.org/licenses/by/3.0>), which permits unrestricted use, distribution, and reproduction in any medium, provided the original work is properly cited. 



## References

- [1] Ascher PW, Justich E, Schrottner O. A new surgical but less invasive treatment of central brain tumours preliminary report. *Acta Neurochirurgica. Supplementum* (Wien). 1991;**52**:78-80
- [2] Bettag M, Ulrich F, Schober R, Furst G, Langen KJ, Sabel M, et al. Stereotactic laser therapy in cerebral gliomas. *Acta Neurochirurgica. Supplementum* (Wien). 1991;**52**:81-83
- [3] McNichols RJ, Gowda A, Kangasniemi M, Bankson JA, Price RE, Hazle JD. MR thermometry-based feedback control of laser interstitial thermal therapy at 980 nm. *Lasers in Surgery and Medicine*. 2004;**34**(1):48-55
- [4] Patel NV, Jethwa PR, Barrese JC, Hargreaves EL, Danish SF. Volumetric trends associated with MRI-guided laser-induced thermal therapy (LITT) for intracranial tumors. *Lasers in Surgery and Medicine*. 2013;**45**(6):362-369
- [5] Rao MS, Hargreaves EL, Khan AJ, Haffty BG, Danish SF. Magnetic resonance-guided laser ablation improves local control for postradiosurgery recurrence and/or radiation necrosis. *Neurosurgery*. 2014;**74**(6):658-667. Discussion 67
- [6] Schober R, Bettag M, Sabel M, Ulrich F, Hessel S. Fine structure of zonal changes in experimental Nd:YAG laser-induced interstitial hyperthermia. *Lasers in Surgery and Medicine*. 1993;**13**(2):234-241
- [7] Patel NV, Mian M, Stafford RJ, Nahed BV, Willie JT, Gross RE, et al. Laser interstitial thermal therapy technology, physics of magnetic resonance imaging thermometry, and technical considerations for proper catheter placement during magnetic resonance imaging-guided laser interstitial thermal therapy. *Neurosurgery*. 2016;**79**(Suppl 1):S8-S16
- [8] Jethwa PR, Barrese JC, Gowda A, Shetty A, Danish SF. Magnetic resonance thermometry-guided laser-induced thermal therapy for intracranial neoplasms: Initial experience. *Neurosurgery. 2012;71(1 Suppl Operative)*:133-44, 144-5
- [9] Medvid R, Ruiz A, Komotar RJ, Jagid JR, Ivan ME, Quencer RM, et al. Current applications of MRI-guided laser interstitial thermal therapy in the treatment of brain neoplasms and epilepsy: A radiologic and neurosurgical overview. *American Journal of Neuroradiology (AJNR)*. 2015;**36**(11):1998-2006
- [10] Carpentier A, Chauvet D, Reina V, Beccaria K, Leclercq D, McNichols RJ, et al. MR-guided laser-induced thermal therapy (LITT) for recurrent glioblastomas. *Lasers in Surgery and Medicine*. 2012;**44**(5):361-368
- [11] Sloan AE, Ahluwalia MS, Valerio-Pascua J, Manjila S, Torchia MG, Jones SE, et al. Results of the neuroplate system first-in-humans phase I clinical trial for recurrent glioblastoma: Clinical article. *Journal of Neurosurgery*. 2013;**118**(6):1202-1219
- [12] Nathoo N, Toms SA, Barnett GH. Metastases to the brain: Current management perspectives. *Expert Review of Neurotherapeutics*. 2004;**4**(4):633-640
- [13] Schwabe B, Kahn T, Harth T, Ulrich F, Schwarzmaier HJ. Laser-induced thermal lesions in the human brain: Short- and long-term appearance on MRI. *Journal of Computer Assisted Tomography*. 1997;**21**(5):818-825
- [14] Eichberg D, VanDenBerg R, Komotar RJ, Ivan ME. Quantitative

volumetric analysis following magnetic resonance-guided laser interstitial thermal ablation of cerebellar metastases. *World Neurosurgery*. 2018;**110**:e755-e765

[15] Schwarzmaier HJ, Eickmeyer F, von Tempelhoff W, Fiedler VU, Niehoff H, Ulrich SD, et al. MR-guided laser irradiation of recurrent glioblastomas. *Journal of Magnetic Resonance Imaging*. 2005;**22**(6):799-803

[16] Ivan ME, Mohammadi AM, De Deugd N, Reyes J, Rodriguez G, Shah A, et al. Laser ablation of newly diagnosed malignant gliomas: A meta-analysis. *Neurosurgery*. 2016;**79**(Suppl 1):S17-S23

[17] Diaz R, Ivan ME, Hanft S, Vanni S, Manzano G, Jagid J, et al. Laser interstitial thermal therapy: Lighting the way to a new treatment option in neurosurgery. *Neurosurgery*. 2016;**79**(Suppl 1):S3-S7

[18] Ivan ME, Diaz RJ, Berger MH, Basil GW, Osiason DA, Plate T, et al. Magnetic resonance-guided laser ablation for the treatment of recurrent Dural-based lesions: A series of five cases. *World Neurosurgery*. 2017;**98**:162-170

[19] Chaudhry NS, Shah AH, Ferraro N, Snelling BM, Bregy A, Madhavan K, et al. Predictors of long-term survival in patients with glioblastoma multiforme: Advancements from the last quarter century. *Cancer Investigation*. 2013;**31**(5):287-308

[20] Oppenlander ME, Wolf AB, Snyder LA, Bina R, Wilson JR, Coons SW, et al. An extent of resection threshold for recurrent glioblastoma and its risk for neurological morbidity. *Journal of Neurosurgery*. 2014;**120**(4):846-853

[21] Laws ER, Parney IF, Huang W, Anderson F, Morris AM, Asher A, et al. Survival following surgery and prognostic factors for recently

diagnosed malignant glioma: Data from the glioma outcomes project. *Journal of Neurosurgery*. 2003;**99**(3):467-473

[22] Brown TJ, Brennan MC, Li M, Church EW, Brandmeir NJ, Rakszawski KL, et al. Association of the extent of resection with survival in glioblastoma: A systematic review and meta-analysis. *JAMA Oncology*. 2016;**2**(11):1460-1469

[23] Sanai N, Polley MY, McDermott MW, Parsa AT, Berger MS. An extent of resection threshold for newly diagnosed glioblastomas. *Journal of Neurosurgery*. 2011;**115**(1):3-8

[24] Chang SM, Parney IF, McDermott M, Barker FG, Schmidt MH, Huang W, et al. Perioperative complications and neurological outcomes of first and second craniotomies among patients enrolled in the glioma outcome project. *Journal of Neurosurgery*. 2003;**98**(6):1175-1181

[25] Fazeny-Dorner B, Wenzel C, Veitl M, Piribauer M, Rossler K, Dieckmann K, et al. Survival and prognostic factors of patients with unresectable glioblastoma multiforme. *Anti-Cancer Drugs*. 2003;**14**(4):305-312

[26] Schwarzmaier HJ, Eickmeyer F, von Tempelhoff W, Fiedler VU, Niehoff H, Ulrich SD, et al. MR-guided laser-induced interstitial thermotherapy of recurrent glioblastoma multiforme: Preliminary results in 16 patients. *European Journal of Radiology*. 2006;**59**(2):208-215

[27] Hawasli AH, Bagade S, Shimony JS, Miller-Thomas M, Leuthardt EC. Magnetic resonance imaging-guided focused laser interstitial thermal therapy for intracranial lesions: Single-institution series. *Neurosurgery*. 2013;**73**(6):1007-1017

[28] Mohammadi AM, Schroeder JL. Laser interstitial thermal therapy

in treatment of brain tumors—The neuroblate system. *Expert Review of Medical Devices*. 2014;**11**(2):109-119

[29] Kamath AA, Friedman DD, Akbari SHA, Kim AH, Tao Y, Luo J, et al. Glioblastoma treated with magnetic resonance imaging-guided laser interstitial thermal therapy: Safety, efficacy, and outcomes. *Neurosurgery*. 2019;**84**(4):836-843

[30] Shah AH, Burks JD, Buttrick SS, Debs L, Ivan ME, Komotar RJ. Laser interstitial thermal therapy as a primary treatment for deep inaccessible gliomas. *Neurosurgery*. 2019;**84**(3):768-777

[31] Stupp R, Mason WP, van den Bent MJ, Weller M, Fisher B, Taphoorn MJ, et al. Radiotherapy plus concomitant and adjuvant temozolomide for glioblastoma. *The New England Journal of Medicine*. 2005;**352**(10):987-996

[32] Stupp R, Hegi ME, Mason WP, van den Bent MJ, Taphoorn MJ, Janzer RC, et al. Effects of radiotherapy with concomitant and adjuvant temozolomide versus radiotherapy alone on survival in glioblastoma in a randomised phase III study: 5-year analysis of the EORTC-NCIC trial. *The Lancet Oncology*. 2009;**10**(5):459-466

[33] Allahdini F, Amirjamshidi A, Reza-Zarei M, Abdollahi M. Evaluating the prognostic factors effective on the outcome of patients with glioblastoma multiformis: Does maximal resection of the tumor lengthen the median survival? *World Neurosurgery*. 2010;**73**(2):128-134. Discussion e16

[34] Lacroix M, Abi-Said D, Fournier DR, Gokaslan ZL, Shi W, DeMonte F, et al. A multivariate analysis of 416 patients with glioblastoma multiforme: Prognosis, extent of resection, and survival. *Journal of Neurosurgery*. 2001;**95**(2):190-198

[35] Rammo R, Scarpace L, Nagaraja T, Lee I. MR-guided laser interstitial thermal therapy in the treatment of recurrent intracranial meningiomas. *Lasers in Surgery and Medicine*. 2019;**51**(3):245-250

[36] Carpentier A, McNichols RJ, Stafford RJ, Guichard JP, Reizine D, Delaloge S, et al. Laser thermal therapy: Real-time MRI-guided and computer-controlled procedures for metastatic brain tumors. *Lasers in Surgery and Medicine*. 2011;**43**(10):943-950

[37] Ali MA, Carroll KT, Rennert RC, Hamelin T, Chang L, Lemkuil BP, et al. Stereotactic laser ablation as treatment for brain metastases that recur after stereotactic radiosurgery: A multiinstitutional experience. *Neurosurgical Focus*. 2016;**41**(4):E11

[38] Ahluwalia M, Barnett GH, Deng D, Tatter SB, Laxton AW, Mohammadi AM, et al. Laser ablation after stereotactic radiosurgery: A multicenter prospective study in patients with metastatic brain tumors and radiation necrosis. *Journal of Neurosurgery*. 2018;**130**(3):804-811

[39] Alattar AA, Bartek J Jr, Chiang VL, Mohammadi AM, Barnett GH, Sloan A, et al. Stereotactic laser ablation as treatment for brain metastases recurring after stereotactic radiosurgery: A systematic literature review. *World Neurosurgery*. 2019;**S1878-8750**(19)31195-7

[40] Rahmathulla G, Recinos PF, Valerio JE, Chao S, Barnett GH. Laser interstitial thermal therapy for focal cerebral radiation necrosis: A case report and literature review. *Stereotactic and Functional Neurosurgery*. 2012;**90**(3):192-200

[41] Carpentier A, McNichols RJ, Stafford RJ, Itzcovitz J, Guichard JP, Reizine D, et al. Real-time magnetic resonance-guided laser thermal therapy for focal metastatic brain

tumors. Neurosurgery. 2008;**63**(Suppl 1):ONS21-ONS28. Discussion ONS8-9

[42] Pruitt R, Gamble A, Black K, Schulder M, Mehta AD. Complication avoidance in laser interstitial thermal therapy: Lessons learned. *Journal of Neurosurgery*. 2017;**126**(4):1238-1245

[43] Ashraf O, Patel NV, Hanft S, Danish SF. Laser-induced thermal therapy in neuro-oncology: A review. *World Neurosurgery*. 2018;**112**:166-177

[44] Mohammadi AM, Hawasli AH, Rodriguez A, Schroeder JL, Laxton AW, Elson P, et al. The role of laser interstitial thermal therapy in enhancing progression-free survival of difficult-to-access high-grade gliomas: A multicenter study. *Cancer Medicine*. 2014;**3**(4):971-979

[45] Xu DS, Chen T, Hlubek RJ, Bristol RE, Smith KA, Ponce FA, et al. Magnetic resonance imaging-guided laser interstitial thermal therapy for the treatment of hypothalamic hamartomas: A retrospective review. *Neurosurgery*. 2018;**83**(6):1183-1192

[46] Jermakowicz WJ, Mahavadi AK, Cajigas I, Dan L, Guerra S, Farooq G, et al. Predictive modeling of brain tumor laser ablation dynamics. *Journal of Neuro-Oncology*. 2019;**144**(1):193-203

[47] Sabel M, Rommel F, Kondakci M, Gorol M, Willers R, Bilzer T. Locoregional opening of the rodent blood-brain barrier for paclitaxel using Nd:YAG laser-induced thermo therapy: A new concept of adjuvant glioma therapy? *Lasers in Surgery and Medicine*. 2003;**33**(2):75-80

[48] Leuthardt EC, Duan C, Kim MJ, Campian JL, Kim AH, Miller-Thomas MM, et al. Hyperthermic laser ablation of recurrent glioblastoma leads to temporary disruption of the peritumoral blood brain barrier. *PLoS One*. 2016;**11**(2):e0148613

[49] Vogl TJ, Straub R, Eichler K, Woitaschek D, Mack MG. Malignant liver tumors treated with MR imaging-guided laser-induced thermotherapy: Experience with complications in 899 patients (2,520 lesions). *Radiology*. 2002;**225**(2):367-377

[50] Ivarsson K, Myllymaki L, Jansner K, Stenram U, Tranberg KG. Resistance to tumour challenge after tumour laser thermotherapy is associated with a cellular immune response. *British Journal of Cancer*. 2005;**93**(4):435-440

[51] Axelsson A, Pantaleone C, Astrom S. Initial findings of immunostimulating interstitial laser thermotherapy of solid tumors. *Journal for Clinical Studies*. 2017;**9**:28-31