

We are IntechOpen, the world's leading publisher of Open Access books Built by scientists, for scientists

6,900

Open access books available

186,000

International authors and editors

200M

Downloads

Our authors are among the

154

Countries delivered to

TOP 1%

most cited scientists

12.2%

Contributors from top 500 universities



WEB OF SCIENCE™

Selection of our books indexed in the Book Citation Index
in Web of Science™ Core Collection (BKCI)

Interested in publishing with us?
Contact book.department@intechopen.com

Numbers displayed above are based on latest data collected.
For more information visit www.intechopen.com



Endoscopic Aspects of *Helicobacter pylori* Gastritis in Children

Felicia Galoş, Cătălin Boboc, Gabriela Năstase,
Anca Orzan, Cristina Coldea, Mălina Anghel and
Mihaela Bălgrădean

Additional information is available at the end of the chapter

<http://dx.doi.org/10.5772/intechopen.81437>

Abstract

The current gold standard for the detection of *Helicobacter pylori* in children remains upper endoscopy plus mucosal biopsies. Endoscopy has the advantage of being able to detect complications of *Helicobacter pylori* infection and to rule out other upper gastro-intestinal pathologies. An additional advantage of endoscopy with gastric biopsy is that it allows physicians to obtain mucosa for urease testing, histological examination and bacterial culture. In children, there is a high correlation between antral nodularity at endoscopy and the presence of *Helicobacter pylori* infection. The authors have proposed to investigate the correlations between macroscopic aspects during endoscopy and histological findings, in order to identify those endoscopic and histopathological features that can help the clinician in clinical practice.

Keywords: *Helicobacter pylori*, children, gastritis, endoscopic aspects

1. Introduction

Helicobacter pylori (*H. pylori*) infection is acquired in childhood and remains an important cause of peptic ulcer disease (PUD) and gastric cancer. In comparison with adults, children and adolescents, however, infrequently develop these complications [1].

It is now well accepted that PUD, the most common stomach disease, is an infectious disease, and all consensus conferences agree that the causative agent, *H. pylori*, must be treated with antibiotics [2].

The public health importance of *H. pylori* discovery, in 1982, and its role in stomach disease was recognized in 2005 with the attribution of the Nobel Prize in Medicine to Barry Marshall and Robin Warren. *H. pylori* was classified as a class I human carcinogen by World Health Organization in 1994.

Numerous diagnostic tests are available for detecting *H. pylori* infection: invasive techniques, which means endoscopy with biopsies for a rapid urease test (RUT), histology, culture and non-invasive techniques, such as serology, ^{13}C -Urea breath test (^{13}C -UBT), and the stool antigen test. There is no single method to detect *H. pylori* infection reliably and accurately. The choice of the diagnostic method depends on patients' age and complaints, technical difficulty level, costs and extensive accessibility in hospitals.

The same diagnostic methods used for adults can be used for children. However, *H. pylori* infection has certain particularities in children which have implications for diagnostic testing. *H. pylori* infection may slowly establish itself, so it is possible, in rare instances, to find the bacteria without traces of inflammation. At endoscopy, antral nodularity is common [2]. Histology provides an excellent diagnostic accuracy, allowing for the detection of the bacteria as well as for the grading of gastritis. The sensitivity and specificity of histology for the diagnosis depends on clinical settings, density of colonization and on pathologist's experience [3].

2. Material and methods

2.1. Patients

This was a prospective, single center study (in Maria Sklodowska Curie Children's Emergency Hospital Bucharest, Romania) that evaluated consecutive children referred by their physicians for upper endoscopy because of dyspepsia. They were all screened for *H. pylori* and had a positive stool antigen test.

Demographic characteristics and family history of each patient were collected through a questionnaire, which was completed by parents or by patients depending on the age of the child. Demographic data included patients' age, gender, and residency (urban or country area). Information on patient's history of *H. pylori* infection as well as on previous therapies was obtained. History of siblings or parents infection was also assessed. Patients were asked about the time of onset and duration of gastrointestinal symptoms, use of proton pump inhibitors, H_2 receptors antagonists, non steroidal anti-inflammatory drugs or steroidal drugs. Smoking status and alcohol consumption was determined as well.

Excluding criteria were: use of proton pump inhibitors or H_2 receptors antagonists and antibiotics as well as non steroidal anti inflammatory drugs or steroidal therapy 2 weeks before the beginning of the study, history of intestinal surgery (except for polypectomy and appendectomy), concomitant severe disease (heart, lungs, kidneys and endocrine diseases), and smoking and alcohol consumption.

The study was approved by Ethics Committee.

2.2. Endoscopy

All patients underwent endoscopy with biopsy specimens for histology (one for the antrum, one for the corpus). One sample from the antrum was used for rapid urease test. Two additional biopsies were taken from the antrum for bacterial culture. The samples were placed in separate vials, previously identified, containing the appropriate medium for each test.

This procedure was performed in patients with a minimum of 10 hours of fasting, under general anesthesia or conscious sedation. Vital signs were continuously monitored for the entire procedure.

Written informed consent was obtained from the parent or tutor of each child included in the study.

2.3. Histology

A biopsy of gastric body and antrum were fixed in a solution of formaldehyde 10%. Subsequently, the gastric mucosa samples were processed, following the usual steps of dehydration and paraffin embedding.

Two stains were used for histological study: hematoxylin eosin and Giemsa. Hematoxylin eosin stain was used to evaluate inflammatory cells and *H. pylori*. Giemsa stain was needed when hematoxylin eosin stain failed to identify the bacterium. The Giemsa stain is the preferred stain for detecting *H. pylori* because of its technical simplicity, high sensitivity and low cost.

Gastritis was graded according to the Sydney System [6] that assesses the severity of inflammation, the level of activity (the degree of polymorph neutrophil inflammation), and the presence of atrophy and of intestinal metaplasia on a scale from 0 to 3.

In accordance with the Sydney System, the density of *H. pylori* infection was also semi quantitatively classified on a scale from 0 to 3 (mild, moderate, and marked).

H. pylori was recognized in the histological section appearing as a short curved or spiral bacillus resting on the epithelial surface or in the mucus layer.

2.4. Bacterial culture

The biopsy specimens collected for bacterial culture were transported in commercial selective transport *H. pylori* medium, Portagerm pylori (BioMérieux SA, Marcy l'Etoile, France), and were inoculated after a few hours onto selective medium Pylori Agar (BioMérieux Italia). The plates were incubated under microaerobic condition at 37° for 72 h. Once incubated, the colonies resembling *H. pylori* were identified by Gram stain and by oxidase, catalase and urease tests. Suspensions from the primary plates were prepared in sterile solution to perform an E-test on Pylori Agar. An agar plate was streaked in three directions with a swab dipped into each bacterial suspension to produce a lawn of growth, an E-Test strip (E-Test; AB Bio disk, Solna, Sweden) was placed each onto separate plate, which was immediately incubated

in a microaerobic atmosphere at 37°C for 72 h. Isolated strains were tested for amoxicillin, clarithromycin, metronidazole, and levofloxacin resistance following the recommendations of the European Committee on Antimicrobial Susceptibility Testing.

2.5. Statistical analysis

The data was collected and analyzed with Microsoft Excel 2013 and PSPP version 1.0.1. Continuous variables with a normal distribution were expressed as a mean with standard derivation (SD) and continuous variables with a non-normal distribution as median with interquartile range (IQR). Differences between groups were analyzed using Student t-test and Mann-Whitney U test for continuous variables, and Fisher's exact test for categorical variables. A p value <0.05 was considered statistically significant for all the analyzed parameters.

3. Results

Of the 38 patients who underwent upper endoscopy with biopsies by protocol (**Figure 1**), nine were excluded because of negative results in both culture and histology.

In the study, the culture and histology examination findings were accepted as "gold standard". The detection of *H. pylori* in at least one of the two tests was accepted as *H. pylori* positivity. Negative results in both culture and histology were accepted as *H. pylori* negativity.

Twenty-nine cases (76.31%) were included in the final analyses, 19 females (65.51%) and the 10 males (34.49%). The ages were between 3 years and 7 months and 17 years and 8 months (mean age 13.5 ± 4.53 years).

Four patients had a family history of peptic ulcer disease. In 15 children the duration of symptoms was more than 6 months and 12 patients were previously treated for *H. pylori* (**Table 1**).

The mean duration of the period between the onset of symptoms and the effective diagnosis in patients with a family history of upper gastrointestinal diseases was 3.75 ± 3.69 and 8.66 ± 5.42 months in those with negative family history ($p = 0.17$). A family history of gastric or duodenal ulcer did not significantly alter the length of time between the onset of symptoms and the diagnosis according to our statistical results, which, however, may have been influenced by the restricted number of patients in our study population.

Twelve patients had previous therapies. The median age of patients who were previously treated was 14.5 ± 3.74 and 13 ± 4.71 years old of those without any anterior therapy ($p = 0.2$).

The most common finding identified at endoscopy was macroscopic nodular antral gastritis, which was present in 22 patients (75.86%) (**Figure 2**). Among these, 10 had additional associated macroscopic lesions: 8 presented with nodular gastritis of gastric body, 1 with bulbitis, and one with esophagitis. Endoscopy showed antral hyperemia in 4 cases and a normal mucosal aspect in other 3 cases (**Table 2**).

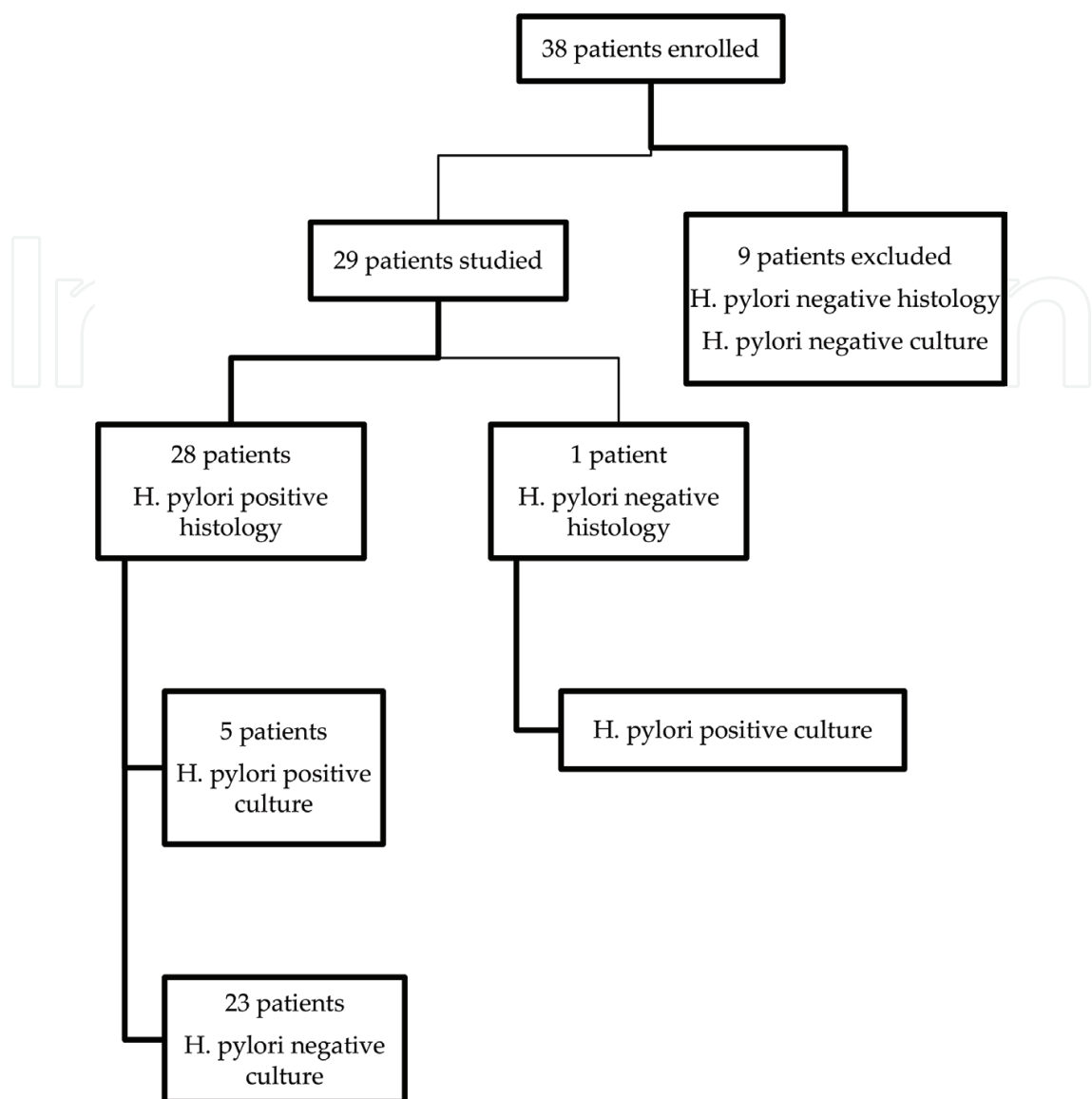


Figure 1. Flow chart of the study.

| | |
|---|-----------------|
| Mean age \pm SD, years | 13.5 \pm 4.47 |
| Male/female | 10/29 |
| Familial history for <i>H. pylori</i> infection | 4/29 |
| Peptic ulcer/non ulcer dyspepsia | 1/28 |
| Previous therapy | 12/29 |

Table 1. Clinical and demographical characteristics of the patients.

We tried to find out if there was a significant difference in the severity of endoscopic findings between patients who received previous therapy and those who did not. Among the 12 previously treated patients, 7 (58.33%) presented with macroscopic nodular antral gastritis,

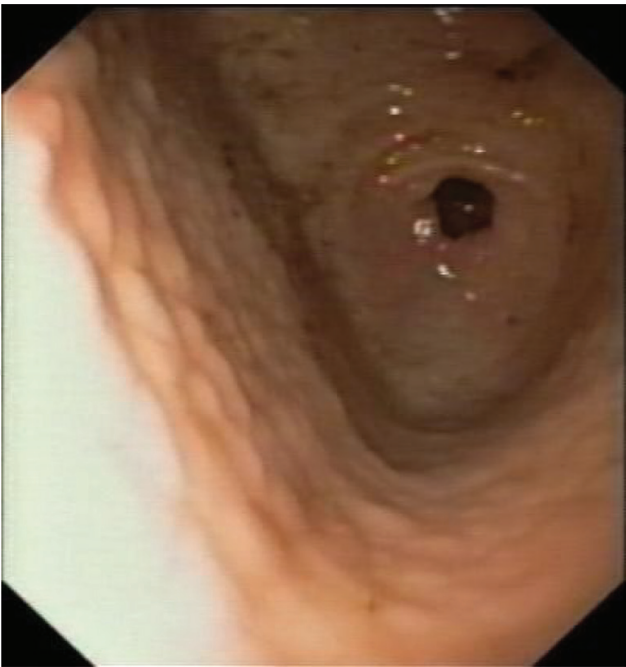

Figure 2. Endoscopic aspect of *Helicobacter pylori* gastritis in children (macroscopic nodular antral gastritis).

| Endoscopic features | n (%) |
|---|-------------|
| Macroscopic nodular antral gastritis | 22 (75.86%) |
| Nodular antral gastritis (only) | 12 |
| Nodular gastritis of corpus (with) | 8 |
| Erosive bulbitis (with) | 1 |
| Esophagitis (with) | 1 |
| Antral hyperemia without macroscopic nodularity | 4 (13.79%) |
| Normal | 3 (10.34) |
| Total | 29 (100%) |

Table 2. Endoscopic features associated to *Helicobacter pylori* infection.

2 (16.67%) with antral hyperemia and 3 (25%) showed a normal mucosal aspect. In patients who were not previously treated, we observed macroscopic nodular antral gastritis in 15 cases (88.24%), antral hyperemia in 2 cases (11.76%) while a normal appearance of gastric mucosa was never detected (**Table 3**). There was not a statistically significant association between the severity of mucosal damage at endoscopy and the existence of a previous therapy against the infection ($p = 0.06$).

In our study, bleeding was the presenting symptom in 4 children; three of them had pan gastritis, and one had nodular gastritis and esophagitis.

| Endoscopic features | <i>H. pylori</i> infection without anterior therapies, n (%) | <i>H. pylori</i> infection with anterior therapies, n (%) |
|---|--|---|
| Macroscopic nodular antral gastritis | 15 (88.24) | 7 (58.33%) |
| Nodular antral gastritis (only) | 8 | 4 |
| Nodular gastritis of corpus (with) | 6 | 2 |
| Erosive bulbitis (with) | 0 | 1 |
| Esophagitis (with) | 1 | 2 (16.67%) |
| Antral hyperemia without macroscopic nodularity | 2 (11.76) | 3 (25.0%) |
| Normal | 0 | 12 (100%) |
| Total | 17 (100) | |

Table 3. Endoscopic features associated to *Helicobacter pylori* infection: without anterior therapies versus with anterior therapies.

4. Discussion

There is a clear association between *H. pylori* and gastritis, gastric ulcer, and duodenal ulcers. Studies have shown that this pathogen causes mucosa-associated lymphoid tissue (MALT) lymphoma in both children and adults. In fact, when the organism is eradicated, extra gastric metastases or sites of MALT lymphoma resolve [4].

The finding of *H. pylori*-associated gastritis without duodenal or gastric mucosal lesions puts the pediatric gastroenterologist in a dilemma on recommending eradication treatment. *H. pylori*-associated gastritis without PUD rarely gives rise of symptoms or progresses to severe complications of the disease during childhood [5]. The risk of *H. pylori*- associated cancer or MALT-lymphoma during childhood is extremely low in Europe and North America. Ohno reported two cases in Japanese children, a 14-year-old boy and another 6-year-old boy with MALT and *H. pylori* infection [5]. The lower risk of complications in children may be in part explained by a different immune response against the infection. In comparison with adults, gastric biopsies obtained from children infected with *H. pylori* show a lower degree of inflammation. In addition, a higher number of immunosuppressive regulatory T cells and a more prominent IL-10 mediated anti-inflammatory response have been detected in pediatric patients [1].

During childhood, *H. pylori* is associated with antral predominant gastritis and duodenal ulcers [6].

In our study, the most frequent lesion identified by endoscopy was macroscopic antral nodular gastritis, which was present in 22 patients (78.86%). This high frequency is in accordance with a retrospective study from Japan that also found out a marked prevalence of nodular antral gastritis associated with *H. pylori* infection (98.5%) [7]. A nodular antral gastritis frequency of 82.53% was also reported by a Turkish study conducted in adults and adolescents

[8]. In a pediatric polish study, the sensitivity of antral nodularity associated with *H. pylori* was 91.6%, and the specificity was 91% [9]. A slightly lower value of specificity of antral nodularity, similar to our results (75.86%), was detected by several authors and ranged from 64 to 85.2%. Higher specificity was found by others [7–9].

Although the mechanisms underlying nodular gastritis in children is not clear yet, it is thought that lymphoid follicles with germinal center form nodules on gastric mucosa or that inflammatory reaction generated by *H. pylori* infection results in an exaggerated appearance of a normal gastric mucosa [10].

In a 14-year-old boy we observed erosions at endoscopy. The frequency of these lesions in our study (3.45%) is similar to the one measured by another study conducted in Italy (3.40%) [11].

A prospective study, carried out during 1-month simultaneously in 19 centers among 14 European countries, showed a frequency of 8.1% of ulcers and/or erosions in children, occurring mainly in the second decade of life, but *H. pylori* infection and toxic gastric medications were less frequently implicated than expected in their development. On a total of 56 children with ulcers or erosions, *H. pylori* was present in 15 patients (27%), 8 used NSAIDs, 5 were treated with steroids, 5 with immune-suppressive drugs, 6 with antibiotics, 1 with antacids, 6 with H₂ blockers and 8 with proton pump inhibitors (more than one risk factor was detected in 32 of 56 children) [12].

For years, reports have noted an association between peptic ulcer disease and families with a strong history of upper gastrointestinal tract disease, in particular between gastric and duodenal ulcers. Family history of gastric cancer is an important component in the diagnosis and management of *H. pylori* infection in children. Children with a mother or a father with gastric cancer are considered to be at very high risk owing to shared genetic characteristics, environmental factors, and virulence features of the infecting strain of *H. pylori* [4].

In countries with an elevated risk for gastric cancer, however, eradicating *H. pylori* in childhood could be more effective in preventing gastric atrophy, and ultimately, cancer development [13]. It still remains to be determined whether *H. pylori*-infected children with gastric atrophy are at increased risk for gastric cancer [14].

Recently, a decreasing proportion of *H. pylori*-positive peptic ulcers in adults has been observed, along with a decrease in the prevalence of infection, while, on the other hand, an increasing number of patients that use non-steroidal anti-inflammatory drugs (NSAIDs) has been noted [7, 15]. Regarding children, there are a few available data in the literature that investigate the trend of *H. pylori* prevalence in peptic ulcer [16].

In our study, four patients had a family history of *H. pylori* infection, none of gastric cancer, two of peptic ulcer, and two of *H. pylori* chronic gastritis. In this situation, the period of the onset of symptoms and to presentation to the doctor was less than 3 months, so that the average duration of symptoms are 3.75 ± 3.69 months in comparison with 8.66 ± 5.42 months for those without family history for gastric or duodenal ulcers. Influence of family history for upper gastrointestinal tract diseases to the period of the onset of symptoms and diagnosis, can be explained by the consciousness of the disease and the risks than derive from it.

The sex difference between the *H. pylori*-positive and *H. pylori*-negative group is also of great interest. We found female preponderance in the study group (65.51%), similarly with another report in our geographic area (78.49%) [17].

Studies have unanimously shown a male preponderance for peptic ulcer disease in children. It is still not known why primary peptic ulcers predominantly develop in infected male children. Epidemiological studies do not suggest any sex predilection in *H. pylori* infection [16].

Median age for patients with previous therapies was 14.5 ± 3.74 years, comparative with 13 ± 4.71 years for patients without previous therapies, results or else expected. We do not have data to express if it is failure of antimicrobial therapy or reinfection. 1/12 patient with previous therapies had family history of peptic ulcer disease. We do not investigate all the family member of each child, and therefore we do not know the real status of *H. pylori* infection. Familial history for gastrointestinal disease was collected for interview. Magistà et al. [18] identified two variables by logistic regression analysis as predictors of *H. pylori* reinfection: age of primary infection and having an infected sibling. Multivariable analysis revealed that only age at primary infection correlates with an increased risk of reinfection [18].

In patients with anterior therapies, the endoscopic features were less serious than in those without any previous treatment. All three patients with normal endoscopic mucosa were anteriorly treated. These results suggest that children might become “tolerant” to the bacterium or that the growing child is more resistant to *H. pylori*-induced lesions. The evidence that *H. pylori* infection in children coexist with normal gastric mucosa was reported in a percent comparable with our results (11%) [19]. This is the reason for which we strongly recommend to take biopsies at least for histological exam in children and adolescents, even if a normal appearance of mucosa is observed during endoscopy.

The ability of *H. pylori* to manipulate the immune response (activation or inactivation of Toll-like receptors dependent response) may be responsible for bacterial survival and a mild course of infection in children [20].

5. Conclusions

The main endoscopic feature found in our study was macroscopic nodular antral gastritis, in 75.86%. In 10.34% of cases the endoscopic aspect of mucosa was normal. All patients with normal endoscopic mucosa were previously treated. These results suggest that children might become “tolerant” to the bacterium or that the growing child is more resistant to *H. pylori*-induced lesions.

Acknowledgements

The authors thank Dr. Augustina Enculescu for her histological support.

Conflict of interest

None declared.

Author details

Felicia Galoș^{1,2*}, Cătălin Boboc^{2,†}, Gabriela Năstase², Anca Orzan^{1,2}, Cristina Coldea^{1,2}, Mălina Anghel² and Mihaela Bălgrădean^{1,2}

*Address all correspondence to: felicia_galos@yahoo.com

1 University of Medicine and Pharmacy Carol Davila, Bucharest, Romania

2 Maria Sklodowska Curie Children's Emergency Hospital, Bucharest, Romania

† These two authors contributed equally to this work.

References

- [1] Jones NL, Koletzko S, Goodman K, Bontems P, Cadranet S, Casswall T, et al. Joint ESPGHAN/NASPGHAN guidelines for the management of *H. pylori* infection in children and adolescents (update 2016). *JPGN*. 2017;**64**:991-1003. DOI: 10.1097/MPG.0000000000001594
- [2] Mégraud F, Lehours P. *Helicobacter pylori* detection and antimicrobial susceptibility testing. *Clinical Microbiology Reviews*. 2007;**20**:280-322. DOI: 10.1128/CMR.00033-06
- [3] Ricci C, Holton J, Vaira D. Diagnosis of *Helicobacter pylori*: Invasive and non-invasive tests. *Best Practice & Research. Clinical Gastroenterology*. 2007;**21**:299-313. DOI: 10.1016/j.bpg.2006.11.002
- [4] Gold BD, Gilger MA, Czinn S. New diagnostic strategies for detection of *Helicobacter pylori* infection in paediatric patients. *Gastroenterology & Hepatology*. 2014;**10**(12 Suppl 7): 1-18. DOI: 05US14EBP1368
- [5] Sierra MS, Hastings EV, Goodman KJ. What do we know about benefits of *H. pylori* treatment in childhood? *Gut Microbes*. 2013;**4**:549-567. DOI: 10.4161/gmic.27000
- [6] Pacifico L, Anania C, Osborn JF, Feraro F, Chiesa C. Consequences of *Helicobacter pylori* infection in children. *World Journal of Gastroenterology*. 2010;**16**(41):5181-5194. DOI: 10.3748/wjg.v16.i41.5181
- [7] Kato S, Nishino Y, Ozawa K, Konno M, Maisawa S, Toyoda S, et al. The prevalence of *Helicobacter pylori* in Japanese children with gastritis or peptic ulcer disease. *Journal of Gastroenterology*. 2004;**39**(8):734-738. DOI: 10.1007/s00535-004-1381-2

- [8] Cosgun Y, Yildirim A, Yucel M, Karakoc AE, Koca G, Gonultas A, et al. Evaluation of invasive and noninvasive methods for the diagnosis of *Helicobacter pylori* infection. Asian Pacific Journal of Cancer Prevention. 2016;**12**:5265-5272. DOI: 10.22034/APJCP.2016.17.12.5265
- [9] Łazowska-Przeorek I, Kotowska M, Banasiuk M, Karolewska-Bochenek K, Banaszkiewicz A, Gawronska A, et al. Value of antral nodularity for the diagnosis of *Helicobacter pylori* infection in children. Medical Science Monitor. 2015;**21**:1827-1830. DOI: 10.12659/MSM.893467
- [10] Yang HR. Update on the diagnosis of *Helicobacter pylori* infection in children: What are the differences between adults and children? Pediatric Gastroenterology, Hepatology & Nutrition. 2016;**19**(2):96-103. DOI: 10.5223/pghn.2016.19.2.96
- [11] Odera G, Mura S, Valori A, Brustia R. Idiopathic peptic ulcers in children. JPGN. 2009;**48**(3):268-270
- [12] Kalach N, Bontems P, Koletzko S, Mourad-Baars P, Shcherbakov P, Celinska-Cedro D, et al. Frequency and risk factors of gastric and duodenal ulcers or erosions in children: A prospective 1-month European multicenter study. European Journal of Gastroenterology & Hepatology. 2010;**22**(10):1174-1181. DOI: 10.1097/MEG.0b13e32833d36de
- [13] Kato S, Kikuchi S, Nakajima S. When does gastric atrophy develop in Japanese children? *Helicobacter*. 2008;**13**(4):278-281. DOI: 10.1111/j.1523-5378.2008.00611.x.
- [14] Kato S, Nakajima S, Nishino Y, Ozawa K, Minoura T, Konno M, et al. Association between gastric atrophy and *Helicobacter pylori* infection in Japanese children: A retrospective multicenter study. Digestive Diseases and Sciences. 2006;**51**(1):99-104. DOI: 10.1007/s10620-006-3091-5
- [15] Arents N, Thijs JC, van Zwet AA, Kleibeuker JH. Does the declining prevalence of *Helicobacter pylori* unmask patients with idiopathic peptic ulcer disease? Trends over an 8 years period. European Journal of Gastroenterology & Hepatology. 2004;**16**:779-783. DOI: 10.1097/01.meg.0000108367.19243.73
- [16] Tam YH, Lee KH, To KF, Chan KW, Cheung ST. *Helicobacter pylori* positive versus *Helicobacter pylori* negative idiopathic peptic ulcers in children with their long-term outcomes. JPGN. 2009;**48**(3):299-305
- [17] Mărginean CO, Cotoi OS, Pitea AM, Mocanu S, Mărginean C. Assessment of the relationship between *Helicobacter pylori* infection, endoscopic appearance and histological changes of the gastric mucosa in children with gastritis (a single center experience). Romanian Journal of Morphology and Embryology. 2013;**54**(3):709-715
- [18] Magistà AM, Ierardi E, Castellaneta S, Miniello VL, Lionetti E, Francavilla A, et al. *Helicobacter* status and symptoms assessment two years after eradication in pediatric patients from a high prevalence area. JPGN. 2005;**40**:312-318

- [19] Nardone G, Staibano S, Rocco A, Mezza E, Balzano T, Salvatore G, et al. Effect of *Helicobacter pylori* on gastric cell proliferation and genomic stability in a paediatric population of southern Italy. *Digestive and Liver Disease*. 2001;**33**:743-749. DOI: 10.1016/S1590-8658(01)80690-3
- [20] Michalkiewicz J, Helmin-Basa A, Grzywa R, Czerwionka-Szaflarska M, Szaflarska-Poplawaska A, Mierzwa G, et al. Innate immunity components and cytokines in gastric mucosa in children with *Helicobacter pylori* infection. In: *Mediators of Inflammation*. Hindawi Publishing Corporation; 2015. DOI: 10.1155/2015/176726