

We are IntechOpen, the world's leading publisher of Open Access books Built by scientists, for scientists

6,900

Open access books available

186,000

International authors and editors

200M

Downloads

Our authors are among the

154

Countries delivered to

TOP 1%

most cited scientists

12.2%

Contributors from top 500 universities



WEB OF SCIENCE™

Selection of our books indexed in the Book Citation Index
in Web of Science™ Core Collection (BKCI)

Interested in publishing with us?
Contact book.department@intechopen.com

Numbers displayed above are based on latest data collected.
For more information visit www.intechopen.com



Pathology of Nonneoplastic Lesions of the Vocal Folds

Nil Çomunoğlu, Şebnem Batur and Ayşe Mine Önenerk

Abstract

Nonneoplastic vocal fold lesions are common that can cause hoarseness and voice change. Reactive lesions of Reinke's space can be observed in all ages and genders and comprise the majority of the benign nonneoplastic vocal fold lesions. Although clinically different terms are used to define reactive lesions of Reinke's space, they share the same histopathologic features. In order to differentiate vocal fold polyp and nodule and Reinke's edema, clinical findings should be considered. Epithelial changes such as pseudoepitheliomatous and verrucous hyperplasia may cause diagnostic challenge due to resemblance of squamous cell carcinoma. Evaluation of the invasion border and cellular atypia may aid in correct diagnosis.

Keywords: vocal fold nodule, vocal fold polyp, Reinke's edema, contact ulcer, keratosis

1. Introduction

The vocal folds, also known as vocal cords, extend through the laryngeal cavity bilaterally and are primarily responsible for voice production. The thyroarytenoid muscle, deep lamina propria, intermediate lamina propria, superficial lamina propria, and squamous epithelium comprise the vocal folds [1–3]. The superficial lamina propria, which is also called Reinke's space, consists of loose fibrous or elastic components and provides a gelatinous surface for vocal folds to vibrate upon. The deep and superficial lamina propria forms the vocal ligament. Madruga et al. demonstrated that type I collagen is abundant in the superficial lamina propria which forms a narrow band. The intermediate lamina propria essentially contains type III collagen, and the deep lamina propria is rich from both type I and type III collagen [4].

In a study of Chandramouli et al., nonneoplastic lesions of the larynx comprise 80% of the benign lesions diagnosed [5]. The etiology of the nonneoplastic vocal fold lesions is usually multifactorial, including phonotrauma (excessive loudness and cough, excess tension while speaking or singing, etc.), laryngeal trauma (endotracheal intubation), hypothyroidism, cigarette smoking, alcohol abuse, and gastroesophageal reflux (GERD) [6–10].

2. Exudative lesions of Reinke's space

Vocal fold nodules and polyps and Reinke's edema are exudative vascular-stromal lesions involving Reinke's space. The similarities and distinct features of these lesions have long been studied [11]. Although some discriminating features have

been emphasized, most of the literature concludes that these lesions share the same histopathologic features which prevent a definitive diagnosis [11, 12].

2.1 Reinke's edema

Reinke's edema is one of the most common causes of hoarseness and approximately comprises 10% of the laryngeal pathologies [13, 14]. It is the result of fluid accumulation in Reinke's space that lies beneath the surface epithelium of the true vocal cords [13]. Smoking, vocal abuse, upper respiratory tract infection, and gastroesophageal reflux (GERD) have been associated with Reinke's edema [13, 15–17]. Marcotullio revealed that the occurrence and recurrence of Reinke's edema depend on the number of cigarettes daily used [15]. Zeitels et al. showed that increased subglottic aerodynamic driving pressure is the underlying mechanism of edema [18]. It has been hypothesized that vocal hyperfunction along with the underlying conditions such as reflux, smoking, etc. is more prone to Reinke's edema [13]. Vecerina et al. classified Reinke's edema into transparent and livid type [19]. Hypothyroidism is stated not to be related with Reinke's edema [13, 20–22]. Majority of the patients are adults (aged between 20 and 60 years). Most of the patients experience Reinke's edema unilaterally (74%). Only a small group of the patients has bilateral edema (26%) [13].

Most of the time, serous fluid is observed upon incision in macroscopic evaluation. However, if the condition persists longer, a jellylike fluid can be seen [13]. Patients are treated with vocal rehabilitation and surgery after eliminating the underlying conditions. Cessation of cigarette smoking is an important factor in long-term treatment [23, 24]. Histopathologic features include subepithelial edema and expansion of the intercellular space, especially the basal membrane. Few blood vessels can be observed [25]. The overlying epithelium is normal most of the time [13]. Duflo et al. showed that antioxidant gene expression is increased in Reinke's edema compared to the vocal fold polyps [26]. In addition, Branski et al. demonstrated that heme oxygenase is increased in vocal fold fibroblasts [27]. Collagen and elastin fiber configuration alterations are demonstrated in Reinke's edema [28, 29]. Dikker et al.'s stated that increased fibrin, hemorrhage, and thickening of the basement membrane are related with Reinke's edema [30].

2.2 Vocal fold nodule and polyp

Vocal fold nodules and polyps are polypoid lesions of the vocal folds sharing the same histopathologic features. They are usually differentiated by clinical findings. A polypoid lesion larger than 3 mm is often regarded as a polyp, whereas smaller lesions are classified as a nodule [31]. Vocal fold nodules are usually bilateral lesions involving anterior or middle vocal fold and located superficially to the free edge of the vocal fold [32]. They are slightly more common in women and in young age [10, 33]. Vocal polyps occur more commonly at the anterior portion of the vocal fold, and in more than 90% of the patients, they are unilateral [31]. There is no age and gender predilection for vocal polyps. Vocal abuse is the leading etiologic factor for vocal fold nodules and polyps; singers, lecturers, and coaches are more prone to developing these lesions due to excessive and loud voice use [6, 10]. Infection, hypothyroidism, GERD, cigarette smoking, and allergy are the other frequent causes [7–9, 34]. Patients present with hoarseness and change in voice quality.

Grossly, vocal cord polyps and nodules present as sessile or polypoid lesions with nodules presenting as few millimeters and polyps up to few centimeters in size [5]. They can be white or bright red, and their consistency varies from firm to soft with a mucoid or glistening cut surface [32].

Although previous studies have attempted to identify histopathologic features which may aid in the differential diagnosis, it is now widely accepted that vocal fold nodules/polyps cannot be differentiated on the histopathologic basis [11, 31, 32, 35]. Epithelial hyperplasia, basement membrane thickening, edema, and vascular proliferation can be seen both in nodules/polyps and Reinke's edema [25, 31, 36]. Ancillary studies such as Verhoeff-van Gieson, Masson trichrome, and Alcian blue did not reveal any difference among these entities [31].

Histopathology represents primarily the extent of the vascular damage and the temporal stage of the lesion [37]. Vocal abuse causes vascular injury and increased vascular permeability. If the damage is minimal, then increased permeability causes only edema, and the microscopic evaluation reveals hypocellular myxoid stroma which is defined as edematous myxoid-type vocal fold nodule/polyp according to some authors (**Figure 1**). When this lesion is not removed or resolved, it undergoes fibrosis, and fibrous-type polyp/nodule evolves. Oval and spindle cells are observed embedded in a fibrous stroma (**Figure 2**). Rarely atypical cells can be detected in this type which is not related with an aggressive behavior [36, 38, 39]. However, if the vascular injury is severe enough for fibrin escape to the subepithelium and interstitium at the beginning of the injury, then hyaline-type polyp/nodule occurs which is characterized by a hypocellular/acellular eosinophilic stroma. By the time capillary proliferation occurs, it progresses to a vascular-type nodule/polyp. This subtype shows ectatic vascular channels in a hypocellular stroma (**Figure 3**). Although, these classification and staging are helpful in understanding the

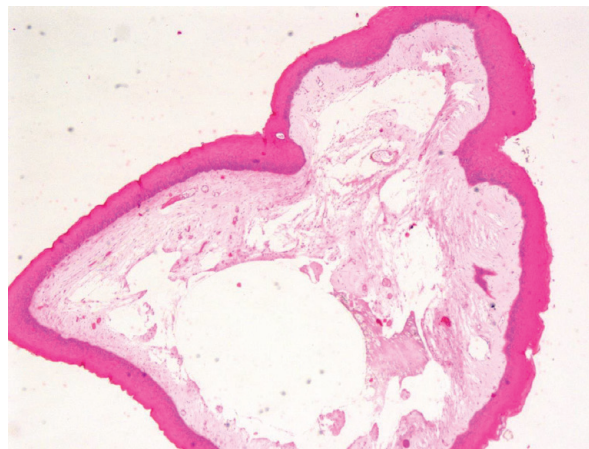


Figure 1.
Polyp with hypocellular myxoid stroma (H&E, ×100).

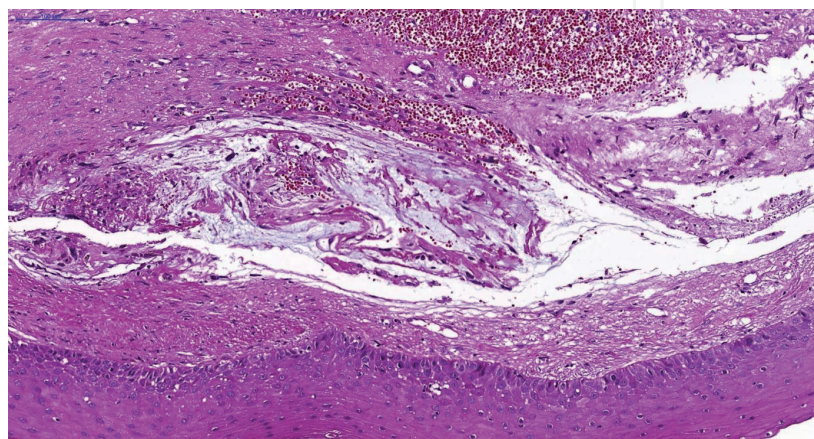


Figure 2.
Polyp stroma appears fibrotic, and spindle cells can be observed embedded within the stroma (H&E, ×200).

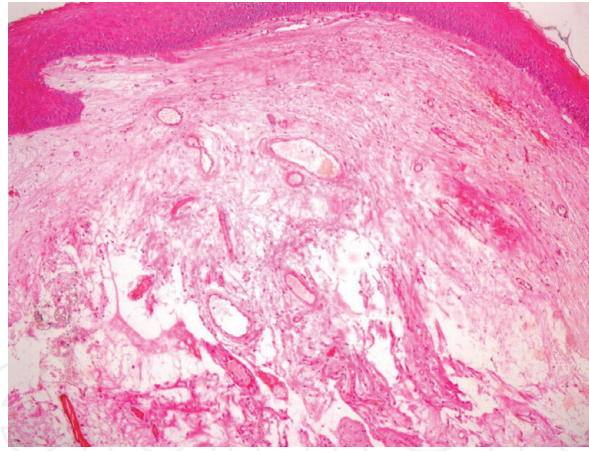


Figure 3.
Polyp stroma shows ectatic vasculature with a hypocellular stroma (H&E, ×200).

histopathologic spectrum, it is clinically insignificant. In addition, mixed features are seen in a single lesion most of the time. The overlying squamous epithelium may be normal, atrophic, or hypertrophic, and keratosis can be seen.

Differential diagnosis includes amyloidosis, myxoma, and contact ulcer. Differentiation of hyaline-type vocal fold nodule/polyp from amyloidosis can be made by observing the distribution of eosinophilic material carefully. In hyaline-type nodule/polyp, it is more homogenous, whereas in amyloidosis there is perivascular and periglandular accentuation of the deposit. Histochemical stains like Congo red and crystal violet can be helpful in identifying the nature of the amorphous material. Myxoma has been rarely reported in the larynx, and it has characteristic stellate spindle cells embedded in an avascular, basophilic, gelatinous-like matrix [40, 41]. Contact ulcer has an ulcerated and fibrin-coated surface and usually involves the posterior portion of the vocal folds.

Surgery has a limited value for these lesions as they are reactive changes to an underlying injurious condition which must be managed. Not surprisingly, voice therapy may result in resolution in most of the patients [42, 43]. Also, treatment of the exact underlying condition such as hypothyroidism can be helpful in the treatment of vocal fold polyps/nodules.

3. Contact ulcer

Contact ulcer is an ulcerated granulation tissue due to vocal abuse, endotracheal intubation, and GERD. Men are more commonly affected than women except that postintubation-related ulcers are more common in female patients. Clinically patients present with hoarseness, cough, dysphonia, habitual coughing, and throat cleaning [44].

Contact ulcers are generally bilateral (“kissing ulcer”) and involve the posterior part of the vocal fold. Grossly they present as an ulcerated, tan-white to erythematous polypoid lesion up to 3 cm in diameter. Microscopic evaluation reveals ulceration underlying a fibrin and/or fibrinoid necrosis and capillary proliferation that is oriented perpendicularly to the mucosal surface (**Figure 4**). Central and base part of the lesion contains hemosiderin-laden macrophages. Usually a dense inflammatory infiltration accompanies. Re-epithelization, mucosal hyperplasia, and fibroblastic proliferation can be observed in chronic phase of the lesion [45].

Clinicopathologic correlation is important in the correct diagnosis as histopathologic features are somewhat nonspecific. Differential diagnosis includes vascular-type vocal cord polyp/nodule, Kaposi sarcoma, Wegener granulomatosis, and

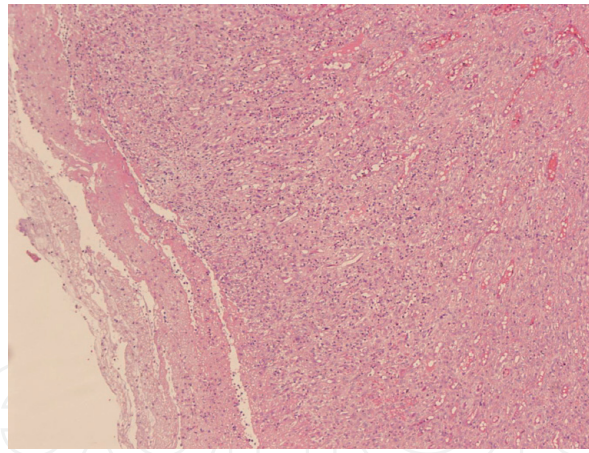


Figure 4.
Ulceration, necrosis, and granulation tissue formation. Capillaries oriented perpendicular to surface (H&E, ×200).

infectious agents. Wegener granulomatosis can be differentiated from contact ulcer with features of vasculitis and necrotizing granulomas. Also, laboratory findings, such as cytoplasmic antineutrophil cytoplasmic antibody (c-ANCA) positivity, support a diagnosis of Wegener granulomatosis over contact ulcer. Kaposi sarcoma may rarely involve the larynx, and histopathologic evaluation reveals spindle cells with intracellular spheroid hyaline globules forming slit-like spaces and anastomosing vascular channels. Immunohistochemical staining with human herpes virus 8 (HHV8) reliably confirms the diagnosis as Kaposi sarcoma.

Like vocal polyps/nodules, contact ulcer is treated with voice therapy, anti-GERD medication, and behavioral modifications in order to decrease habitual coughing and throat clearing [44].

4. Amyloidosis

Amyloidosis is the deposition of an extracellular, acellular, fibrillar, and amorphous material in various sites of the body. It can be primary (associated with plasma cell neoplasms) or secondary (associated with chronic systemic diseases such as familial Mediterranean fever, rheumatoid arthritis, etc.). Primary amyloidosis can be classified as systemic or localized. The larynx is the most common site for localized amyloidosis [46, 47]. It may also be associated with “mucosa-associated lymphoid tissue” (MALT) lymphoma or a neuroendocrine tumor. Laryngeal amyloidosis generally affects adults at the sixth decade. Patients present with hoarseness and voice changes because of mass effect [45]. Grossly it presents as a firm polypoid lesion up to 4 cm covered by normal-appearing mucosa. Cut surface may be firm and starch-like and gray or yellow-orange in color. Localized laryngeal amyloidosis can involve the larynx diffusely or present as a nodule. Microscopic examination reveals diffuse subepithelial or discrete nodular lesion consisting of amorphous, fibrillary, and hyaline-like eosinophilic substance deposition. Usually the distribution of the deposition is more pronounced in perivascular and periglandular areas. Lymphoplasmacytic infiltration and foreign body giant cells can be seen but usually sparse.

Differential diagnosis includes hyalinized-type vocal fold polyps/nodules and lipid proteinosis which are negative with Congo red and crystal violet. Most importantly as amyloid can be associated with multiple myeloma, laryngeal neuroendocrine tumors, and medullary thyroid carcinoma, a systemic evaluation of the patient is necessary.

If amyloidosis is limited to the larynx, patients are treated with surgical removal of the lesion. However, other treatment options will be applied if the patient has an underlying neoplastic condition or chronic inflammatory disease.

5. Cysts of the larynx

Nonneoplastic cysts of the larynx consist of laryngocele, saccular, and ductal cysts [48–50].

5.1 Laryngocele

Laryngeal ventricles are the spaces between the true and false vocal cords which extend upward and form the laryngeal saccule bilaterally. Laryngocele can be defined as a symptomatic dilation of the laryngeal saccule with air entrapment [51]. An important feature of laryngocele is that the lumen of the cyst communicates with the laryngeal cavity. Radiography reveals an air-filled cystic enlargement. They are usually unilateral, may occur over a wide age range, and are more frequent in males. Occupations such as glassblower or wind instrumentalists are at increased risk of developing laryngocele due to repetitive increase in intralaryngeal pressure. Patients present with hoarseness and foreign body or globus sensation.

Clinically it can be divided as internal, external, or combined. Internal laryngocele is confined to the endolarynx and presents as a supraglottic submucosal lesion. In contrast external laryngocele extends through the thyrohyoid membrane. However, in combined laryngocele, the cyst herniates through the thyrohyoid membrane and presents as an anterior neck mass [51–53]. Patients present with hoarseness, dyspnea, and chronic cough. In histopathologic examination, the respiratory epithelium is identified as the lining of the cyst wall.

Differential diagnosis includes other laryngeal cysts. However, laryngocele is the only air-filled cyst of this region and communicates with the laryngeal cavity—an important finding in differentiation.

Symptoms may resolve with the expulsion of trapped air from the cyst lumen. Treatment of laryngocele is simple excision or marsupialization of the cyst wall.

5.2 Saccular cyst

Saccular cyst is a mucin-filled cyst due to obstruction of the laryngeal saccule. It can be acquired or congenital [49, 50]. If it extends medially, it may obscure the anterior vocal fold. Lateral saccular cysts are similar to the external laryngoceles, herniated through the thyrohyoid membrane, and may present as a neck mass [37].

Saccular cysts are usually lined by respiratory-type epithelium. Squamous or oncocytic lining can be observed in some cases. Cyst lumen is filled with mucin or acute inflammatory exudate.

Differential diagnosis includes laryngocele and thyroglossal ductus cyst. It is differentiated from laryngocele by mucin content, and it does not communicate with the laryngeal cavity. It is difficult to discriminate a thyroglossal cyst from a saccular cyst when it invades through the pre-epiglottic space and histopathologically lacks the thyroid tissue. When this is the situation, investigation of the anatomic localization of the cyst is a reliable finding in the differentiation of these cysts. Thyroglossal ductus cysts are related with the hyoid bone and located in the midline of the neck.

5.3 Ductal cysts (squamous, tonsillar, oncocytic)

Ductal cysts are the most common type of laryngeal cysts. Cyst lining epithelium can be squamous or oncocytic [49, 54] (**Figures 5 and 6**). When a squamous lined cyst is surrounded by lymphoid tissue, it is called a tonsillar cyst. Tonsillar cysts are more common in the vallecula which contains tonsillar remnants.

5.4 Other cysts

Rarely epidermal, dermoid, and branchial cleft cysts may occur in the endolarynx.

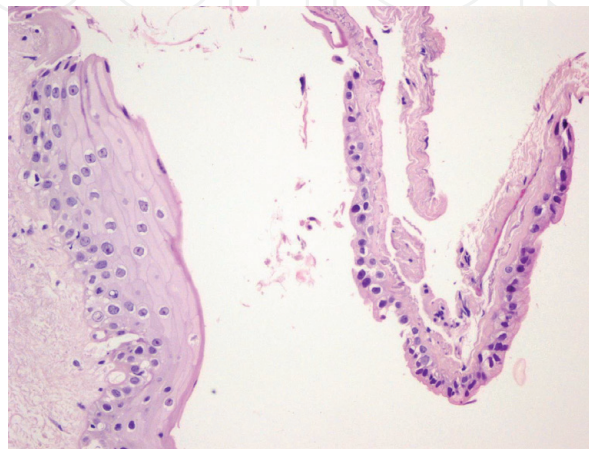


Figure 5.
The right side of the figure represents a squamous cell lined cyst. On the left cyst lining cells appear oncocytic (H&E, ×400).

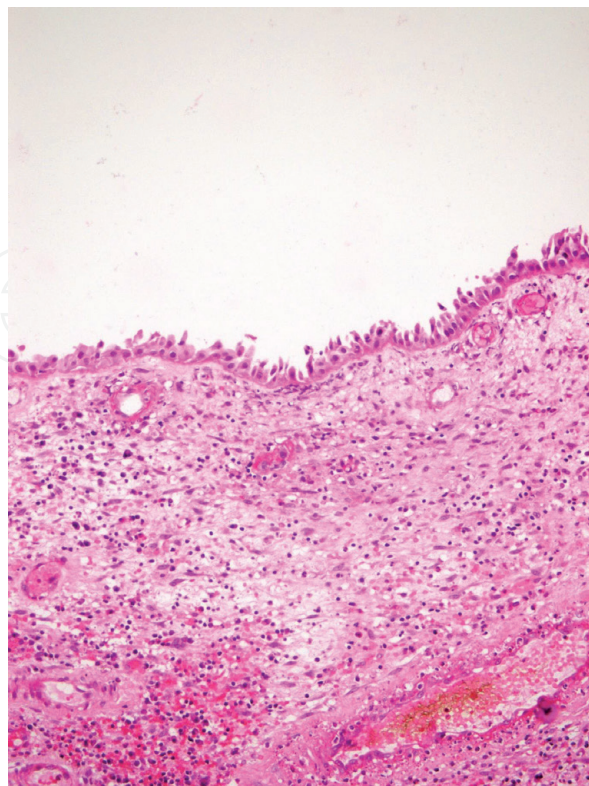


Figure 6.
Ductal cyst with lining oncocytic cells (H&E, ×400).

6. Hyperplastic lesions of the larynx

Hyperplastic lesions of the larynx are a result of a reparative process. Clinical terms such as leukoplakia (white plaque), erythroplakia (red plaque), erythroleukoplakia (red and white changes), or pachydermia (extensive thickening of the mucosa) are used to describe the lesion macroscopically, and they are not histologic entities [55].

Keratosis of the larynx is synonymously used with simple hyperplasia and squamous hyperplasia [56]. Singers and other occupations that lead to an individual to use his/her voice excessively and cigarette smokers are at risk of keratosis. Hoarseness is the leading complaint. Laryngoscopy identifies leukoplakia. Microscopic evaluation reveals a thickened squamous epithelium without cellular or architectural atypia [55]. Generally, a hyperkeratotic layer overlies the epithelium. Lesions with warty configuration are referred as verrucous keratosis [56, 57].

Pseudoepitheliomatous hyperplasia (PEH) is a reactive proliferation of the squamous epithelium which develops in response to infections, trauma, or neoplasia. Histologically these lesions are downward thickening of the epithelium (**Figure 7**). Due to a less well-defined epithelial stromal interface and the tendency of anastomosing epithelial tongues entrapping the submucosa, the lesion may mimic squamous cell carcinoma [58]. However, in PEH, the hyperplastic epithelium forms large bulbous projections, and basement membrane is always preserved.

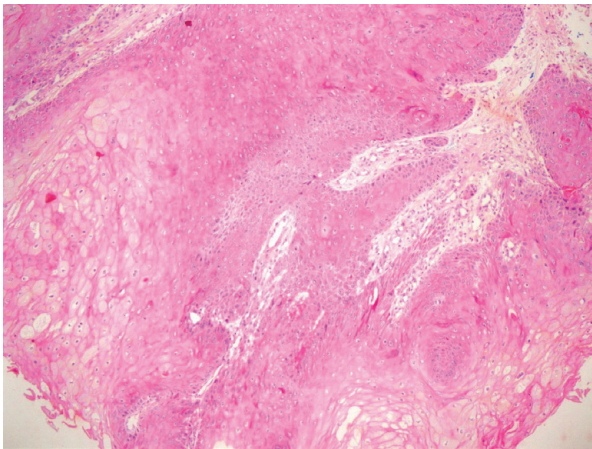


Figure 7.
Downward proliferation of benign appearing surface epithelium (H&E, ×200).

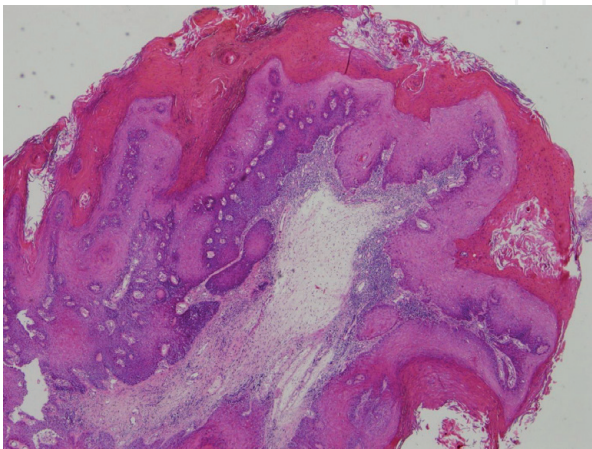


Figure 8.
Parakeratosis and verrucous hyperplasia of the surface epithelium (H&E, ×100).

Verrucous hyperplasia is a verrucous and keratotic form of squamous hyperplasia which may show varying degrees of cytological atypia (**Figure 8**). The presence of cellular atypia and a relatively regular epithelial-stromal border supports a diagnosis of verrucous hyperplasia over verrucous squamous cell cancer (SCC) [59].

7. Conclusions

Voice change or hoarseness of voice and nonneoplastic vocal fold lesions lead to a high percentage of vocal fold biopsies. Both clinical and histopathologic features should be considered in order to differentiate lesions involving Reinke's space and also hyperplastic epithelial lesions from squamous cell carcinoma.

Author details

Nil Çomunoğlu^{1*}, Şebnem Batur¹ and Ayşe Mine Önenerk²

1 Pathology Department, Istanbul University Cerrahpasa, Cerrahpasa Medical Faculty, Istanbul, Turkey

2 Pathology Department, Karaman State Hospital, Karaman, Turkey

*Address all correspondence to: nilcomunoglu@gmail.com

IntechOpen

© 2019 The Author(s). Licensee IntechOpen. This chapter is distributed under the terms of the Creative Commons Attribution License (<http://creativecommons.org/licenses/by/3.0>), which permits unrestricted use, distribution, and reproduction in any medium, provided the original work is properly cited. 

References

- [1] Thiabeault SL. Advances in our understanding of the Reinke space. *Current Opinion in Otolaryngology & Head and Neck Surgery*. 2005;**13**:148-151
- [2] Volic SV, Klapan I, Seiwerth S, Ibrahimasic T. Extracellular matrix of Reinke's space in some pathological conditions. *Acta Oto-Laryngologica*. 2004;**124**:505-508
- [3] Claassen H, Werner JA. Fibre differentiation of the human laryngeal muscles using the inhibition reactivation myofibrillar ATPase technique. *Anatomy and Embryology (Berlin)*. 1992;**186**:341-346
- [4] Madruga de Melo EC, Lemos M, Aragão Ximenes Filho J, Sennes LU, Nascimento Saldiva PH, Tsuji DH. Distribution of collagen in the lamina propria of the human vocal fold. *The Laryngoscope*. 2003;**113**:2187-2191
- [5] Chandramouli MP, Sengottuvelu P, Vivek B. Non-malignant lesions of larynx—Our experience. *IOSR Journal of Dental and Medical Sciences (IOSR-JDMS)*. 2018;**17**(2):54-57
- [6] Bastian RW, Thomas JP. Do talkativeness and vocal loudness correlate with laryngeal pathology? A study of the vocal overdoer/underdoer continuum. *Journal of Voice*. 2016;**30**(5):557-562. DOI: 10.1016/j.jvoice.2015.06.012
- [7] Chung JH, Tae K, Lee YS, Jeong JH, Cho SH, Kim KR, et al. The significance of laryngopharyngeal reflux in benign vocal mucosal lesions. *Otolaryngology and Head and Neck Surgery*. 2009;**141**:369-373
- [8] Karkos PD, McCormick M. The etiology of vocal fold nodules in adults. *Current Opinion in Otolaryngology & Head and Neck Surgery*. 2009;**17**(6):420-423. DOI: 10.1097/MOO.0b013e328331a7f8
- [9] Lechien JR, Saussez S, Nacci A, Barillari MR, Rodriguez A, Le Bon SD, et al. Association between laryngopharyngeal reflux and benign vocal fold lesions: A systematic review. *The Laryngoscope*. 2019;**129**(9):329-341
- [10] Smolander S, Huttunen K. Voice problems experienced by Finnish comprehensive school teachers and realization of occupational health care. *Logopedics, Phoniatrics, Vocology*. 2006;**31**(4):166-171
- [11] Hantzakos A, Remacle M, Dikkers FG, Degols JC, Delos M, Friedrich G, et al. Exudative lesions of Reinke's space: A terminology proposal. *European Archives of Oto-Rhino-Laryngology*. 2009;**266**(6):869-878. DOI: 10.1007/s00405-008-0863-x
- [12] Oates J, Winkworth A. Current knowledge, controversies and future directions in hyperfunctional voice disorders. *International Journal of Speech-Language Pathology*. 2008;**10**(4):267-277
- [13] Goswami S, Patra TK. A clinico-pathological study of Reinke's oedema. *Indian Journal of Otolaryngology and Head and Neck Surgery*. 2003;**55**(3):160-165. DOI: 10.1007/BF02991943
- [14] Fritzell B, Sundberg J, Strange-Ebbesen A. Pitch change after stripping oedematous vocal folds. *Folia Phoniatica et Logopaedica*. 1982;**34**:29-32
- [15] Marcotullio D, Magliulo G, Pezone T. Reinke's edema and risk factors: Clinical and histopathologic aspects. *American Journal of Otolaryngology*. 2002;**23**:81-84
- [16] Myerson MC. Smoker's larynx: A clinical pathological entity. *The Annals of Otology, Rhinology, and Laryngology*. 1950;**59**:541-546

- [17] Koufman JA. Gastroesophageal reflux and voice disorders. In: Rubin JS, Sataloff RS, Korovin GS, Gould WJ, editors. *Diagnosis and Treatment of Voice Disorders*. New York: Igaku-Shoin; 1995. pp. 161-175
- [18] Zeitels SM, Hillman RE, Bunting GW, Vaughn T. Reinke's edema: Phonatory mechanisms and management strategies. *The Annals of Otolaryngology, Rhinology, and Laryngology*. 1997;**106**:533-543
- [19] Vecerina VS, Klrincic N, Markov D. Some morphological. Histological, cytological and histochemical aspects of Reinke's oedema. *Acta Oto-Laryngologica*. 1996;**116**:322-324
- [20] Lindeberg H, Felding JU, Sogaard H, Ilium P. Reinke's oedema and thyroid function: A prospective study in 43 patients. *Clinical Otolaryngology*. 1987;**12**(6):417-420
- [21] Wedrychowicz B, Nijander D, Betkowski A, Jastrzebski J. Reinke's edema and thyroid hypofunction. *Otolaryngology*. 1992;**46**(6):538-542
- [22] White A, Sire DW, Maran AG. Reinke's oedema and thyroid function. *The Journal of Laryngology and Otolaryngology*. 1991;**105**(4):291-292
- [23] Zalesska-Krecicka M, Krecicki T, Cyganek P. A clinical study of Reinke's edema. *Otolaryngologia Polska*. 1994;**47**(2):153-157
- [24] Hojslet EE, Moesgaard-Nielsen V, Karlslose M. Smoking cessation in chronic Reinke's oedema. *The Journal of Laryngology and Otolaryngology*. 1990;**104**:626-628
- [25] Dikkers FG, Nikkels PG. Lamina propria of the mucosa of benign lesions of the vocal folds. *The Laryngoscope*. 1999;**109**:1684-1689
- [26] Duflo SM, Thibeault SL, Li W, Smith ME, Schade G, Hess MM. Differential gene expression profiling of vocal fold polyps and Reinke's edema by complementary DNA microarray. *The Annals of Otolaryngology, Rhinology, and Laryngology*. 2006;**115**:703-714
- [27] Branski RC, Barbieri SS, Weksler BB, et al. The effects of transforming growth factor-beta1 on human vocal fold fibroblasts. *The Annals of Otolaryngology, Rhinology, and Laryngology*. 2009;**118**:218-226
- [28] Sakae FA, Imamura MD, Sennes L, Mauad T, Saldiva P, Tsuji DH. Disarrangement of collagen fibers in Reinke's edema. *The Laryngoscope*. 2008;**118**:1500-1503
- [29] Sakae FA, Imamura R, Sennes LU, Tsuji DH, Mauad T, Saldiva PH. Elastic fibers in Reinke's edema. *The Annals of Otolaryngology, Rhinology, and Laryngology*. 2010;**119**(9):609-614
- [30] Dikkers FG, Nikkels PG. Benign lesions of the vocal folds: Histopathology and phonotrauma. *The Annals of Otolaryngology, Rhinology, and Laryngology*. 1995;**104**:698-703
- [31] Wallis L, Jackson-Menaldi C, Holland W, Giraldo A. Vocal fold nodule vs vocal fold polyp: Answer from surgical pathologist and voice pathologist point of view. *Journal of Voice*. 2004;**18**(1):125-129
- [32] Bohlender J. Diagnostic and therapeutic pitfalls in benign vocal fold diseases. *GMS Current Topics in Otorhinolaryngology-Head and Neck Surgery*. 2013;**13**(12):Doc1
- [33] Mudd P, Noelke C. Vocal fold nodules in children. *Current Opinion in Otolaryngology & Head and Neck Surgery*. 2018;**26**(6):426-430. DOI: 10.1097/MOO.0000000000000496
- [34] Martins RH, Defaveri J, Domingues MA, de Albuquerque e Silva R.

Vocal polyps: Clinical, morphological and immunohistochemical aspects. *Journal of Voice*. 2011;**25**(1):98-106. DOI: 10.1016/j.jvoice.2009.05.002

[35] Cipriani NA, Martin DE, Corey JP, Portugal L, Caballero N, Lester R, et al. The clinicopathologic spectrum of benign mass lesions of the vocal fold due to vocal abuse. *International Journal of Surgical Pathology*. 2011;**19**(5):583-587. DOI: 10.1177/1066896911411480

[36] Loire R, Bouchayer M, Cornut G, Bastian RW. Pathology of benign vocal fold lesions. *Ear, Nose, & Throat Journal*. 1988;**67**(5):357-358. 360-2

[37] Barnes L. Diseases of the larynx, hypopharynx, and trachea. In: *Surgical Pathology of the Head and Neck*. 2nd ed. New York, Basel: Marcel Dekker; 2001. pp. 109-119

[38] Batsakis J. Stromal cell atypia in sinonasal polyposis. *The Annals of Otolaryngology, Rhinology, and Laryngology*. 1986;**321-322**(13):95

[39] Compagno J, Hyams V, Lepore M. Nasal polyposis with stromal atypia. Review of follow-up study of 14 cases. *Archives of Pathology & Laboratory Medicine*. 1976;**100**:224-226

[40] Panda S, Kumar R, Gopinath VR, Sagar P. Head and neck myxoma presenting as isolated laryngeal polyp. *Case Reports in Otolaryngology*. 2018;6868737

[41] Val-Bernal JF, Martino M, Longarela MY. Cellular myxoma of the vocal cord: A case report and review of the literature. *Turkish Journal of Pathology*. 2017;**13**:1-5. DOI: 10.5146/tjpath.2017.01417

[42] Hosoya M, Kobayashi R, Ishii T, Senarita M, Kuroda H, Misawa H, et al. Vocal hygiene education program reduces surgical interventions for

benign vocal fold lesions: A randomized controlled trial. *The Laryngoscope*. 2018;**128**(11):2593-2599. DOI: 10.1002/lary.27415

[43] Mansuri B, Tohidast SA, Soltaninejad N, Kamali M, Ghelichi L, Azimi H. Nonmedical treatments of vocal fold nodules: A systematic review. *Journal of Voice*. 2018;**32**(5):609-620. DOI: 10.1016/j.jvoice.2017.08.023

[44] Emami AJ, Morrison M, Rammage L, Bosch D. Treatment of laryngeal contact ulcers and granulomas: A 12-year retrospective analysis. *Journal of Voice*. 1999;**13**(4):612-617

[45] Thompson LDR. Non-neoplastic lesions of the larynx, hypopharynx, and trachea. In: Thompson LDR, Goldblum JR, editors. *Head and Neck Pathology*. 2nd ed. Philadelphia: Elsevier; 2013. pp. P107-P127

[46] Godbersen GS, Leh JF, Hansmann ML, Rudert H, Linke RP. Organ-limited laryngeal amyloid deposits: Clinical, morphological, and immunohistochemical results of five cases. *The Annals of Otolaryngology, Rhinology, and Laryngology*. 1992;**101**(9):770-775

[47] Berg AM, Troxler RF, Grillone G, Kasznica J, Kane K, Cohen AS, et al. Localized amyloidosis of the larynx: Evidence for light chain composition. *The Annals of Otolaryngology, Rhinology, and Laryngology*. 1993;**102**(11):884-889

[48] Canalis RF, Maxwell DS, Hemenway WG. Laryngocele—An updated review. *The Journal of Otolaryngology*. 1977;**6**(3):191-199

[49] DeSanto LW, Devine KD, Weiland LH. Cysts of the larynx—Classification. *The Laryngoscope*. 2015;**125**(12):2629. DOI: 10.1002/lary.25563

[50] Holinger LD, Barnes DR, Smid LJ, Holinger PH. Laryngocele and saccular cysts. *The Annals of Otology, Rhinology, and Laryngology*. 1978; **87**(5 Pt 1):675-685

[51] Mobashir MK, Basha WM, Mohamed AE, Hassaan M, Anany AM. Laryngoceles: Concepts of diagnosis and management. *Ear, Nose, & Throat Journal*. 2017; **96**(3):133-138

[52] Szwarc BJ, Kashima HK. Endoscopic management of a combined laryngocele. *The Annals of Otology, Rhinology, and Laryngology*. 1997; **106**:556-559

[53] Nazaroglu H, Ozates M, Uyar A, et al. Laryngopyocele: Signs on computed tomography. *European Journal of Radiology*. 2000; **33**(1):63-65

[54] Newman BH, Taxy JB, Laker HI. Laryngeal cysts in adults: A clinicopathologic study of 20 cases. *American Journal of Clinical Pathology*. 1984; **81**(6):715-720

[55] Ferlito A, Devaney KO, Woolgar JA, Slootweg PJ, Paleri V, Takes RP, et al. Squamous epithelial changes of the larynx: Diagnosis and therapy. *Head & Neck*. 2012; **34**(12):1810-1816. DOI: 10.1002/hed.21862

[56] Rosai J. *Larynx and Trachea. Surgical Pathology*. 10th ed. Philadelphia: Elsevier; 2011. pp. 320-323

[57] Goodman ML. Keratosis (Leukoplakia) of the larynx. *Otolaryngol Clinics of North America*. 1984; **17**:179-183

[58] Gnepp DR. *Diagnostic Surgical Pathology of the Head and Neck*. 2nd ed. Philadelphia: Saunders Elsevier; 2009

[59] Stelow E. Larynx. In: Mills SE, editor. *Diagnostic Surgical Pathology*. 6th ed. Philadelphia: Wolters Kluwer; 2015. pp. P995-P1002