

We are IntechOpen, the world's leading publisher of Open Access books Built by scientists, for scientists

6,900

Open access books available

185,000

International authors and editors

200M

Downloads

Our authors are among the

154

Countries delivered to

TOP 1%

most cited scientists

12.2%

Contributors from top 500 universities



WEB OF SCIENCE™

Selection of our books indexed in the Book Citation Index
in Web of Science™ Core Collection (BKCI)

Interested in publishing with us?
Contact book.department@intechopen.com

Numbers displayed above are based on latest data collected.
For more information visit www.intechopen.com



Application of Negative Pressure Wound Therapy on Closed Incisions

*Chitang J. Joshi, Ji-Cheng Hsieh, Abbas Hassan
and Robert D. Galiano*

Abstract

Negative pressure wound therapy (NPWT) is widely used for chronic and acute open wounds, with clinically proven benefits of faster wound healing by promoting granulation tissue growth and increased perfusion and facilitating epithelialization and contraction. Improved outcomes on open wounds prompted the application of NPWT on closed surgical incisions. The application of NPWT, in the immediate postoperative period, reduces surgical site infections (SSIs) and wound dehiscence by 50% in high-risk patients. The negative pressure reduces wound edema and improves local perfusion and lymphatic flow, thereby minimizing hematoma and seroma rates. The improved perfusion and oxygenation facilitate quicker wound healing as well as minimize ischemic complications like flap necrosis. Recent literature supports enhanced wound healing and superior scar appearance as well as improved wound maturity, evidenced by 50% more force required to pull apart a sutured incision. Improved outcomes of incisional NPWT are reported from various surgical procedures on abdominal, breast, orthopedic, vascular, cardiac, and plastic surgeries. Further clinical studies and cost-benefit analysis are needed to recommend routine postoperative use of incisional NPWT in high-risk and low-risk patient population.

Keywords: negative pressure wound therapy, incisional NPWT, closed incision NPWT, wound healing, wound dehiscence, surgical site infections

1. Introduction

The concept of negative pressure wound therapy (NPWT) was pioneered in 1997 by Morykwas, applying vacuum-assisted closure (VAC) on a pig wound model. Morykwas' initial methodology involved packing the wound with foam, covering and sealing with an adhesive drape, and applying 125 mm Hg of negative pressure either continuously or intermittently [1]. The rudimentary NPWT led to increased blood flow, granulation tissue, and flap survival, with decreased bacterial growth [1].

NPWT refers to wound healing technology consisting of three major parts: a wound dressing, covers, and a pump [2]. Wound dressing aids in transferring pressure from the pump to the wound itself, and modern NPWT typically utilizes reticulated open-pore polyurethane foam, intended to equalize the negative

pressure across the entire wound surface [2]. The cover creates an airtight seal over an open wound, and the pump applies the negative pressure [2, 3].

There are four major types of NPWT [4]. The first is a large, battery-powered NPWT in the acute inpatient setting, while the second is a portable, battery-powered NPWT designed for outpatient use, but cannot be purchased over the counter and tends to be noisy [4]. The third type is a longer-lasting battery-powered NPWT that can be purchased over the counter and is designed to last 7 days and subsequently discarded, while altered models designed for inpatient use that include additional functions, such as negative pressure wound therapy with instillation-dwelling (NPWTi-d) and incisional negative pressure wound therapy (iNPWT), are the last [4].

1.1 Mechanism of action

By drawing fluid out of the wound, negative pressure increases blood flow, decreases the bacterial burden, cleans the wound, reduces local edema, and removes soluble inflammatory mediators that may delay wound healing [2–4]. It has been postulated that NPWT draws antibiotics into the wound, but evidence is lacking [2]. The application of pressure applies forces to the wound, exerting effects macroscopically, through macrodeformation, as well as microscopically, through microdeformation [2, 5]. Naturally, negative pressure on a sealed wound draws the wound edges together [2]. However, it is important to note that the effect is reliant upon tissue parameters such as elasticity and tension, and the strength of the negative pressure does not seem to affect the amount of macrodeformation that occurs [2].

With NPWT, 5–20% of the wound surface experiences tissue stress, and by using a reticulated wound dressing, the action of drawing the wound bed into each pore via negative pressure constitutes the microdeformation that promotes tissue healing processes: increases in cell proliferation, angiogenesis, granulation tissue formation, and epithelialization and decreases in inflammation [2, 5]. NPWT has the potential to grow granulation tissue over exposed bone, tendon, or devices [4]. Specifically, NPWT increases the concentration of VEGF, TGF-beta, FGF-2, PDGF, and IL-8 in the wound, with IL-10 increasing in the body, and decreased concentrations of TNF-alpha, IL-1 beta, and matrix metalloproteases (MMPs) [2]. In patients with type-2 diabetes, the pro-angiogenic and pro-epithelization proteins GDNF family receptor alpha-2 (GFRA2), which complement C1q binding protein (C1QBP), RAB35, and synaptic inositol 1,4,5-triphosphate 5-phosphatase 1 (SYNJ1), were increased [2].

2. NPWT

2.1 Early indications and need for NPWT

Traditional NPWT has been utilized for chronic and acute open wounds and has become a mainstay of wound management [4, 6, 7].

Indications for NPWT are as follows [5, 8]:

- Acute, chronic, and dehisced surgical wounds
- Diabetic, pressure, and venous leg ulcers
- Open abdominal wounds

- Fasciotomies
- Split-thickness skin graft (STSG) recipient sites
- Flaps
- Partial-thickness burns

Contraindications of NPWT include fistulas, malignancy, osteomyelitis, or infection, and NPWT should never be applied over exposed critical anatomic structures or in wounds with necrotic tissue [4, 5]. Despite the benefits of NPWT, there are several key reminders to remember in order for treatment to be effective. The cover and drainage tube must be assessed carefully as loss of seal or fluid buildup in the tube can lead to skin loss or maceration [5]. It is also important to monitor the pump to minimize the risk of exsanguination.

There is significant variability regarding the application of NPWT that depends on wound characteristics [2, 5]. The wound packing can be foam or gauze [2]. The pump may be mechanically or electrically driven [2]. The strength of negative pressure can vary from -50 mm Hg to -150 mm Hg [2]. The pattern of negative pressure application can be intermittent, continuous, or variable, with a continuous pattern the most common [2]. Selection of parameters is typically at the physician's discretion, but a recommended pressure is 125 mm Hg applied in a pattern alternating between a 5-minute negative pressure and a 2-minute suction [4, 5]. Although studies suggest intermittent NPWT is the most effective pattern in inducing granulation tissue formation and increasing blood flow, it also increases pain for the patient [4, 5]. As a result, continuous pressure is often used for painful wounds, as well as wounds with overlying skin grafts, and particularly edematous wounds [5]. Beyond wound outcomes, NPWT reduces the number of dressing changes, healthcare labor, time spent in the hospital, and costs, and this is most demonstrated in portable NPWT, which allows treatment to be done at home [5, 9].

2.2 Current applications

Beyond its indications listed previously, the use of NPWT has been expanding into newer wound types, including tunneling wounds and avascular tissue, and new published case series have demonstrated the use of NPWT in wounds such as necrotizing fasciitis [4, 5, 10]. Alterations to traditional NPWT led to negative wound pressure therapy with installation (NPWT-i) and incisional negative pressure wound therapy (iNPWT), the latter of which is utilized on closed wounds.

3. Incisional NPWT

Incisional NPWT (iNPWT) has been used since 2006, as an adjunct treatment to augment wound healing and prevent surgical site infections (SSI) and wound complications.

3.1 Evolution and development

Surgical incisions are a break in the skin and its defenses in avoiding translocation of infectious pathogens into the deeper tissues. It's imperative to cover and isolate these incisions by a sterile protective dressing in the sterile environment of the operating room. Advances in these sterile protective dressings have taken place over

decades and, in the present form, are made up of a nonadherent, antimicrobial-containing dressing covered with sterile gauze or abdominal pads, which are held in place by tapes or transparent film.

In the 1990s, NPWT demonstrated promising results in the management of acute and chronic open wounds, and Argenta and Morykwas proposed improved perfusion and wound contraction, which had a profoundly positive effect on the success of wound healing [1].

Gomoll et al., in 2006, pioneered the idea of incisional NPWT and described the application of NPWT on 35 orthopedic trauma patients, considered high-risk for infections [11]. A permeable nonadherent dressing was applied over the incision and covered with standard VAC sponge cut into 1-inch wide strips and then sealed with conventional VAC adhesive material. The negative pressure was maintained for 3 days, and patients were followed up for SSI for a minimum of 3 weeks. None of these 35 patients reported infections, which led to heightened interest in application of NPWT for surgical incisions.

3.2 Mechanism of action

Efficacy of NPWT depends on a number of factors, namely, foam width, foam thickness, magnitude of negative pressure, and its duration and frequency.

To achieve reproducible and standardized results, the NPWT dressing includes a skin interface layer, which is directly placed over the incision site, over which reticulated foam dressing is secured with occlusive drape. The VAC pump along with the canister is then connected via tubes attached through the foam dressing and secured underneath the occlusive drape to maintain an airtight seal. It's imperative to secure and maintain an airtight seal, in order to achieve efficacy and prevent complications like maceration of peri-wound skin.

Several studies and trials have proposed these mechanisms of iNPWT (**Figure 1**):

- Physical barrier to external contamination
- Microdeformation of the wound edges and release of local growth factors
- Approximation of wound edges and minimizing lateral tension and dead space
- Fluid egress and exudate removal

The negative pressure is commonly used *continuously* within a range of -75 mm of Hg to -125 mm of Hg . Although a faster rate of granulation is seen with interrupted pressure, the associated drastic changes in the foam contraction and expansion often render it more painful and impractical for use.

Another alternative, to bridge the gap between continuous and interrupted pressure, is *variable pressure*. It combines the benefit of interrupted pressure and faster granulation tissue growth with gradual and smaller deviations in pressure, in an attempt to minimize pain.

The role of foam width and thickness is important, as it's proportional to the lateral tension attenuation, as described later in the chapter. Hence, a standard foam width of 60 mm is recommended. Cutting thin strips of the foam and using as a construction dressing are also discouraged, as it limits the efficacy and benefits of the iNPWT.

The optimum negative pressure has been a debatable aspect of NPWT. A lot of research focused on negative pressure of -80 mm Hg with positive results, followed

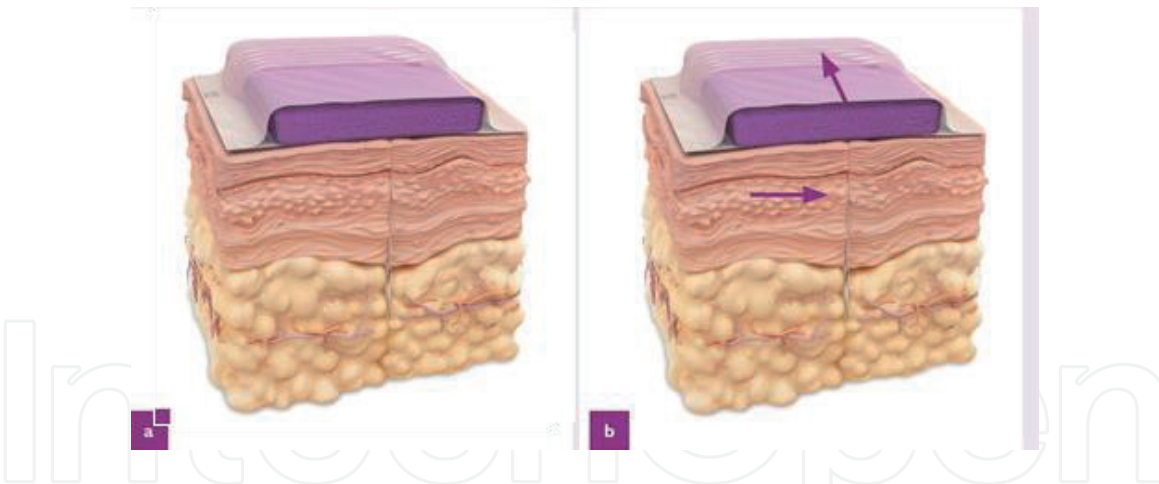


Figure 1. Cross-sectional depiction of an incision closed with sutures without incisional NPWT (a). Application of incisional NPWT decreases lateral tissue tension and increases incisional apposition (b), reducing dead space. The applied pressure causes microdeformation and release of local growth factors, promoting healing of the surgical incision (reprinted with permission from Ref. [36]).

by a paper published by Morykwas et al., using -125 mm Hg. The results of this trial were promising as it demonstrated improved healing and granulation as compared to the earlier results published by the same team and others. Recent literature and guidelines recommend a pressure of -125 mm Hg; however, pressures ranging from -80 , -100 , and -125 mm Hg have been employed, and encouraging results have been published.

Application of iNPWT on perineal wounds, following abdominoperineal resection (APR) for colonic and anal lesions, demonstrated improved wound healing and reduced complications and infection rates, while using pressure of -80 mm Hg. The increase in negative pressure beyond -125 mm Hg does not demonstrate improved wound outcomes, either in open or closed wounds.

As the uses and application of the NPWT system develop for closed incision surgical wounds, results of various large-scale clinical trials would emerge, and further modifications would evolve to maximize the clinical benefits of this promising therapeutic modality for postoperative surgical wounds.

3.3 Advantages of iNPWT

Several studies have described the benefits of incisional NPWT (iNPWT) in general, colorectal, cardiac, vascular, plastic, and orthopedic surgeries. These benefits have been classified as immediate, intermediate, and long-term effects and result from the sterile isolation of the incision; mechanical stabilization and reduction in the tensile forces; obliteration of dead space; reduction of local edema, hematoma, and seroma; and increased perfusion and lymphatic flow.

Nam et al. proposed benefits of iNPWT [12], as

- Immediate effects
 - Protection of incision from external contamination
 - Decreased lateral tension on the incision
 - Increased appositional strength
 - Normalized stress distribution

- Increased skin perfusion
- Intermediate effects
 - Decreased edema
 - Decreased hematoma/seroma formation
 - Increased lymphatic flow
- Long-term effects
 - Improved Incision quality
 - Mechanical strength
 - Histology
 - Gene expression

3.3.1 Prevention of external contamination and surgical site infections

Surgical site infections (SSIs) result in significant morbidity and increased healthcare costs, accounting for 21.8% of the 721,800 healthcare-associated infections recorded annually in the United States [13].

SSIs are estimated to increase average hospital stay by 9.6 days, resulting in an added cost of \$38,656 and around \$10 billion in direct and indirect costs annually [14].

With emphasis on lowering healthcare costs and advancing quality of care, SSIs pose a major physical, psychological, and economic burden.

Incisional NPWT immediately provides protection and isolation of the incision from external contamination. Multiple studies in trauma surgery, general surgery, and plastic surgery have attributed decreased local edema, fluid egress, lower hematoma/seroma rates, lower time to healing, and improved genomic profile, in terms of reduction of pro-inflammatory cytokines and chemokines in surgical incisions covered with NPWT. An international expert panel in 2017 recommended ciNPWT for patients at high risk for surgical site complications [15]. Notable high-risk features include diabetes, ASA score ≥ 3 , obesity (BMI ≥ 30 kg/m²), tobacco use, hypoalbuminemia, corticosteroid use, high-tension wounds and revision surgery.

Multiple studies across different specialties reported a threefold to fivefold reduction in the surgical site infection risk, following the use of ciNPWT [16–18].

Notably, Grauhan and team reported findings of a prospective study of 150 obese patients who underwent cardiac surgery via a median sternotomy. A significant reduction of fourfold in the incidence of wound infection was seen in the iNPWT group compared to conventional dressings, at 1 week of surgery [19]. Similar findings were reported by Matatov in groin infections covered with iNPWT, after vascular procedures (6 vs. 30%, $p = 0.0011$) [20]. Bonds described a reduction in the rate of SSIs in the iNPWT group, after open colectomy (12.5 vs. 29.3%, $p < 0.05$) [21].

Contrastingly, a study analyzing 398 patients concluded incisional NPWT improved short-term wound complications but had no effect on long-term infection rate following knee and hip arthroplasty. A higher proportion of iNPWT patients reported wound drainage at day 7, though similar increase was not seen at different

time intervals. This study is the largest RCT comparing outcomes of NPWT dressing in elective lower extremity arthroplasty and supporting improved soft tissue healing response and lower wound-related complications, but no effect on the risk of late superficial or deep infections [22].

Evidence supporting the use of iNPWT in hand and spine surgery is new and fewer. SSIs occur in 0.4–20% of patients undergoing spine surgery and contribute to increased morbidity, hospitalization, and costs [23–26]. Various treatment modalities such as drains, copious irrigation, and prophylactic antibiotics are employed. Adogwa et al. reported a 30% reduction in wound infection rate and 50% reduction in wound dehiscence rates in patients after long-segment thoracolumbar spine fusion and suggested ciNPWT as a safe and effective means of wound management for high-risk spine incisions.

Recent literature suggests incisional NPWT as a safe and effective method in preventing SSIs and wound complications in high-risk patients.

3.3.2 Cost analysis of iNPWT

As modern healthcare strives to deliver quality and efficient yet cost-effective care, continued efforts are warranted to evaluate economic viability of NPWT use and its application in various specialties.

An estimated cost of \$100 per day was associated with the use of the PREVENA (V.A.C therapy, KCI, San Antonio, TX) system, which showed significant reduction in SSI risk [27]. With a typical use of 5–7 days, cost of ciNPWT is estimated around \$500–700. When used in high-risk populations and higher-cost wound management modality, such additional costs of the NPWT system are validated, as they lead to overall reduction in total healthcare expenditure. SSIs prolong hospital stay, on an average of 9 days, and are associated with an increase in costs up to \$20,000 [28].

When compared with indirect costs associated with treatment of wound dehiscence and complications, and direct costs such as daily dressing changes, the economic viability of the iNPWT system in high-risk population seems justified. Chopra et al. found an estimated cost saving of \$1456 with ciNPWT use in abdominal wall surgeries. Raymund Horch and his team proposed a cost saving of \$163 in obese patients and \$203 in morbidly obese patients employing iNPWT in post-bariatric patients undergoing abdominal and thigh dermolipectomy. The authors determined that a 28 and 25% reduction in SSIs' rate in the obese and morbidly obese patients, respectively, was needed to achieve cost savings with iNPWT. Lewis et al. proposed cost savings with iNPWT if wound complications are reduced by one-third in patients undergoing laparotomy for gynecological malignancies [29]. Further evaluation of the applicability of the NPWT system and its costs is warranted in diverse patient population (high vs. low risk), healthcare setups (inpatient vs. at-home), and specialties.

3.3.3 Wound healing

NPWT has been applied successfully as a therapeutic modality to treat open wounds for decades, which led to heightened interest in the scientific community to use it over closed wounds, incisions, and skin grafts. Many trials and studies have proposed the following mechanisms of incisional NPWT:

- Foam dressing protects wound from external mechanical stress.
- Decrease wound tension and tensile forces in deeper dermal layers.

- Continuous removal of exudate and fluids.
- Decrease local edema improving physiologic adaptation of the wound.
- Increase in local perfusion, oxygenation, and lymphatic flow.
- Decrease hematoma/seroma rates.
- Decrease in time-to-heal duration.

On a molecular level, iNPWT has been hypothesized to remove toxic inflammatory mediators and increase the concentration of local tissue growth factors, via microdeformation [30].

An immediate benefit of the iNPWT is the foam dressing that protects the incision/wound from external contamination as well as its ability to minimize the lateral tension around the suture line by 50%. It also normalizes tensile forces in the deep dermal tissue to decrease dead space, which aids in wound healing and reduced seroma/hematoma rates. In wound mechanics, study conducted on an incision made on silicon surface found when iNPWT was applied, 51% more force was required to pull apart a sutured incision, and 43% more force was required to pull apart a stapled incision than non-iNPWT-treated incisions. An interesting correlation was the proportional association between the width of the foam dressing and the force required to pull the incision apart. The study concluded that a foam width of 60 mm is required to increase the tensile strength of the incision.

Studies on earlier techniques of NPWT discouraged the construction method (dressing of the incision by cutting foam into thin strips) as it likely decreased the positive effect of reduced lateral tension on the incision [1].

Early application of iNPWT on pig wound model demonstrated improved healing in terms of mechanical, histomorphometric, and gene expression properties. These incisions showed significantly improved mechanical properties (strain energy density, peak strain) and a narrower scar, extending in the deep dermis [31].

Long-term genomic analysis on surgical wounds reveals pro-inflammatory chemokine and cytokine signals in conventional dressing (sterile absorbent abdominal dressing)-treated incisions compared to iNPWT-treated incisions. Thus, the latter seemed superior in wound strength and wound maturity compared to conventional dressing-covered incisions [31].

Early application of iNPWT promotes fluid egress and continuous removal of exudates. This leads to reduction in local edema, reduced hematoma/seroma rates, improved time to hematoma resolution, decreased time to wound healing, and with split-thickness skin grafts (STSG), improved survival with NPWT [12]. When used with grafts and skin substitutes, the fluid egress with iNPWT minimizes shear stress and provides tight apposition to the underlying recipient wound bed, which promotes incorporation of the graft or skin substitutes and reepithelialization of graft interstices [32–34]. Maruccia et al. described faster healing, fewer dressing changes, and quicker maturity of mesh skin grafts when combined with NPWT. This combined treatment provides higher integration, better immobilization of the graft, expulsion of fluids, and a moist clean wound bed [35].

The reduction in local edema and removal of fluids in sites such as the abdomen and breast help in reducing the need for postoperative drainage. There is renewed interest in analyzing results to conclude reduced need and duration for postoperative drains. Several studies in general surgery, plastic surgery, and orthopedic surgery have demonstrated reduced drainage with iNPWT-covered incisions. Raymund Horch and his team, in 2014, demonstrated the benefits of iNPWT in

a post-bariatric patient population undergoing dermolipectomy of the abdomen and who presented with reduced exudate formation, earlier drain removal, and decreased length of hospitalization [36].

3.3.4 Pain relief

Pain relief with iNPWT has been reported rarely, as very few studies have focused on reporting pain scores with this modality. Maruccia et al., in 2016, reported a statistically significant reduction in pain scores and wound area in skin graft patients. This could be explained by faster healing and improved uptake of the graft, along with less frequent need for dressing changes [35].

3.3.5 Scar appearance

Recent literature shows *scar appearance* improvement with the iNPWT system, across various incision sites. Keeney et al., in 2018, reported a trend toward better outcomes and improved scar appearance in total knee arthroplasty (TKA) patients [22]. Similar improvements have been reported with breast, abdominal, and lower and upper extremity incisions too. This is explained by faster wound healing, decreased time-to-heal time, reduced wound area and lateral tension, and reduced scarring in the deep dermal layers. Optimization in wound healing and avoidance of complications, such as wound dehiscence and hematoma/seroma formation, reduce secondary scarring and augurs well for improved scar appearance.

3.3.6 Perfusion and oxygen saturation

An important aspect of iNPWT is its ability to alter *microcirculation and improve tissue perfusion and oxygen saturation*, in the immediate, intermediate, and long-term analysis of surgical wounds. The purported mechanisms of action are microdeformation of wound and increased neo-angiogenesis via release of local growth factors [37]. Improved perfusion is demonstrated in the cutaneous arterioles (along the skin edges) as well as the deeper tissues, as evidenced by Atkins et al., in peri-sternal perfusion after cardiac surgery via median sternotomy. The iNPWT was also able to compensate for the reduced perfusion rendered by mammary artery harvesting in these patients. In a study published in 2014, Raymund Horch and his team demonstrated improved SaO₂ and blood flow at all time intervals, over abdomen and thigh wounds in post-bariatric surgery patients undergoing dermolipectomy. This was recorded by placing sensors and O₂C probe over the abdominal skin and thighs [36].

Timmers et al. found a fivefold increase in perfusion, assessed with Doppler probes, after application of NPWT over the forearms of healthy volunteers [38].

In a study on iNPWT published in 2016 from the University of Chicago, comprising of 228 patients undergoing immediate expander-based breast reconstruction (study and control groups of 45 and 183, respectively), it was concluded that the application of iNPWT significantly decreased the rate of major mastectomy flap necrosis rate (requiring operative intervention), overall mastectomy flap necrosis rates, and overall complication rates [39].

3.3.7 Lymphatic flow

An important supplement to the improved perfusion is *increased lymphatic flow* around the incision. Lymphatic flow increments aid in reducing hematoma

and seroma rates, which are estimated to be reduced by 50–63% with the use of iNPWT. The importance of increased lymphatic flow on reducing seroma/hematoma rates is evidenced by the porcine model study described by Kilpadi and Cunningham, in which significant reduction of hematoma and seroma occurs without fluid collection in the canister [40].

Kilpadi and Cunningham reported 63% reduced hematoma/seroma rates with iNPWT and injected isotope-labeled nanospheres in the subcutaneous tissue to discover their highest concentration in lymph nodes closest to, draining the incision site [40]. Recent literature is overwhelmingly in favor of reduced seroma/hematoma rates, across various surgical procedures covering different surgical specialties and incision sites. To name a few, iNPWT and reduced seroma/hematoma have been demonstrated at flap donor sites, like scapular and latissimus dorsi free flap harvest sites, total hip and knee arthroplasty, over abdominal (e.g., cesarean, laparotomy, and abdominoplasty), thoracic incisions (e.g., sternotomy), breast incisions (expander-based and autologous reconstruction), lower extremity (trauma and fractures), and groin incisions (vascular procedures involving femoral vessels) [40–43].

3.3.8 Hospital stay

Reduced hospital stay with iNPWT use has been demonstrated extensively, via reduced time-to-heal duration, as well as decreased SSI and wound dehiscence and complication rates. A recent systematic review on abdomen procedures estimates reduction of ICU stay but required more extensive clinical RCT and research [44]. Though, it's difficult to quantify this reduction in hospital stay across various procedures, NPWT as an incision management tool has been demonstrated to optimize and accentuate the wound healing process.

3.3.9 Readmission and reoperation rates

These rates have been assessed in a recent meta-analysis comparing efficacy of NPWT in high-risk patients undergoing abdominal wall reconstruction. Both outcomes were low in the iNPWT group as compared to control [9 vs. 14% and 3 vs. 14%, respectively; RR = 0.68 CI (0.46–0.99)].

3.3.10 Wound dehiscence and complication

Wound dehiscence and complications are lowered with the use of iNPWT and its aforementioned benefits. Recent literature estimates a reduction of ~50% reduction in wound dehiscence rates, across various surgical specialties [23, 45–50].

The proposed mechanism of improved wound healing, increased perfusion, decreased infection rates, decreased hematoma/seroma rates, decreased lateral and deep wound tension, improved wound maturity, and strength and obliteration of dead space augurs well for low wound dehiscence and complication rate.

Besides the cost-benefit analysis, an incision management tool with these benefits and improved scar appearance definitely requires further clinical trials and recommendations for use, especially in high-risk patients.

3.4 Complications and risks of iNPWT

Interest in the use of iNPWT has been peaking in the last few years as favorable outcomes seem promising and with easy adaptability and application of at-home single-use canister-based NPWT. This single-use NPWT can be used for

7 days and improves patient acceptability and compliance. A lot of research has been invested in the safety of these systems and to identify complications impeding its widespread use.

The risk of hemorrhage, especially in patients on anticoagulants and with clotting disorders, has been described with the use of iNPWT. Any evidence of fistulas or communication to visceral cavities needs further imaging and management before the application of negative pressure. Allergic reaction to the dressings is a contraindication to the use of iNPWT. Minor skin irritation and ecchymosis are the most frequently encountered complications.

4. Clinical applications of incisional NPWT

The earliest description of the use of negative pressure in wound healing was in the management of soft tissue injury associated with open fractures. The beneficial outcomes seen in various animal models spurred the development of a wide range of clinical indications including abdominal, breast, orthopedic, vascular, cardiac, and plastic surgeries (e.g., skin graft, burns, muscle flap) [51].

4.1 Abdominal wounds

The use of incisional NPWT in high-risk patients undergoing abdominal surgeries decreased wound complications such as surgical site infections and wound healing complications. The primary goals of incisional NPWT wound management include active removal of exudates, estimation of third-space fluid loss, and avoidance of mechanical contamination of the abdominal viscera [51].

With the help of the dressing, NPWT applies negative pressure uniformly, thus promoting healing by reducing edema, approximating the wound, and removing infectious material and exudates [52].

Some studies showed that NPWT improves the removal of abdominal fluid, which helps in early fascial closure. The removal of fluids is especially beneficial in reducing inflammatory responses that may occur [53, 54]. This is supported by the septic/hemorrhagic shock porcine model, which showed that NPWT efficacy was partially due to a reduction in the anti-inflammatory response [55].

On a recent comparative study on incisional NPWT and conventional dressing following abdominal wall reconstruction, the authors demonstrated a statically significant reduction in the incidence of skin dehiscence and overall wound complications in the incisional NPWT group compared with the conventional dressing group [30].

In a study comparing the rates of SSI of patients who underwent surgery for pancreatic, colorectal, or peritoneal surface malignancies between incisional NPWT and conventional dressings, the incidence of SSI was significantly lower in the incisional NPWT group than the conventional group [56].

The use of incisional NPWT as an effective prophylactic tool has been examined in studies from various surgical specialties. The results show that its use facilitates healing of incisional wounds and reduces the incidence of wound healing disorders [57].

4.2 Breast surgery

Breast reconstruction using the expander-/implant-based breast reconstruction is usually performed after mastectomy and plays a crucial role in psychosocial and oncological outcomes in breast cancer patients.

One of the most common and significant complications in the immediate expander-based breast reconstruction is mastectomy flap necrosis, which has been reported to occur in up to 30% of the patients [58]. Authors of a recent study evaluated the incidence of mastectomy flap necrosis in patients with incisional NPWT after immediate expander-based breast reconstruction compared with the incidence in patients with conventional dressing.

The incisional NPWT group had a lower overall complication rate, overall mastectomy flap necrosis rate, and major mastectomy flap necrosis than the conventional dressing group [59].

Besides oncological breast surgery, the use of incisional NPWT was also assessed in a multicenter study on reduction mammoplasty. The results have shown that incisional NPWT applied to closed incision appeared to be most effective on dehiscence in the higher BMI categories and benefit most in preventing complications in the higher tissue resection weight categories [60] (**Figure 2**). The results thus suggest applying incisional NPWT devices in reduction mammoplasty where the BMI is over 25 or resection weight is above 500 mg [60] (**Figure 3**).

The safety and efficacy of incisional NPWT in elderly patients undergoing breast surgery were studied previously. The results of the study suggest that the rates of infections and surgical site events (SSE) were lower with the use of incisional NPWT. The use of incisional NPWT is thus highly recommended in elderly patients, who have significant increased risk of developing SSE when compared with younger patients [61]. Other studies have concluded that incisional NPWT applied to closed surgical incisions on healthy patients after breast reduction surgery prevented postsurgical wound complications significantly [62].

4.3 Orthopedics

Complications related to high-risk lower extremity fractures such as calcaneal, pilon, and tibial plateau are particularly common. Common complications include infection and wound healing problems. In a prospective randomized multicenter clinical trial evaluating the use of NPWT after calcaneus, pilon, or tibial fractures, the authors have found a significant reduction of infection in the NPWT group [48]. The beneficial effects of NPWT on wounds after total ankle replacement or calcaneus fractures were recognized in a study that showed decreased total time required to achieve complete healing, decreased risk of infections, and decreased pain and swelling [63]. Several retrospective studies showed positive effects of incisional NPWT on wounds after open reduction and internal fixation of acetabular fractures. The NPWT group showed reduced rates of wound dehiscence, deep wound infections, and infection rates [64, 65].

A prospective randomized clinical study examined the wounds of patients after total hip arthroplasty using ultrasound examination to evaluate for the development of potential seroma, a possible risk factor for wound infections. The study showed a significant reduction in the seroma size when compared to standard wound dressing and positive effects on wound healing and complication rate [42].

4.4 Cardiac surgery

Despite the use of prophylactic antibiotics, the increasing incidence of post-operative sternal wound infections continues to be a serious problem after surgical cardiac procedures. Sternal wound infections are associated with additional expenses, increased length of stay in the hospital, increased mortality during the first year, and a significant reduction in quality of life [66].

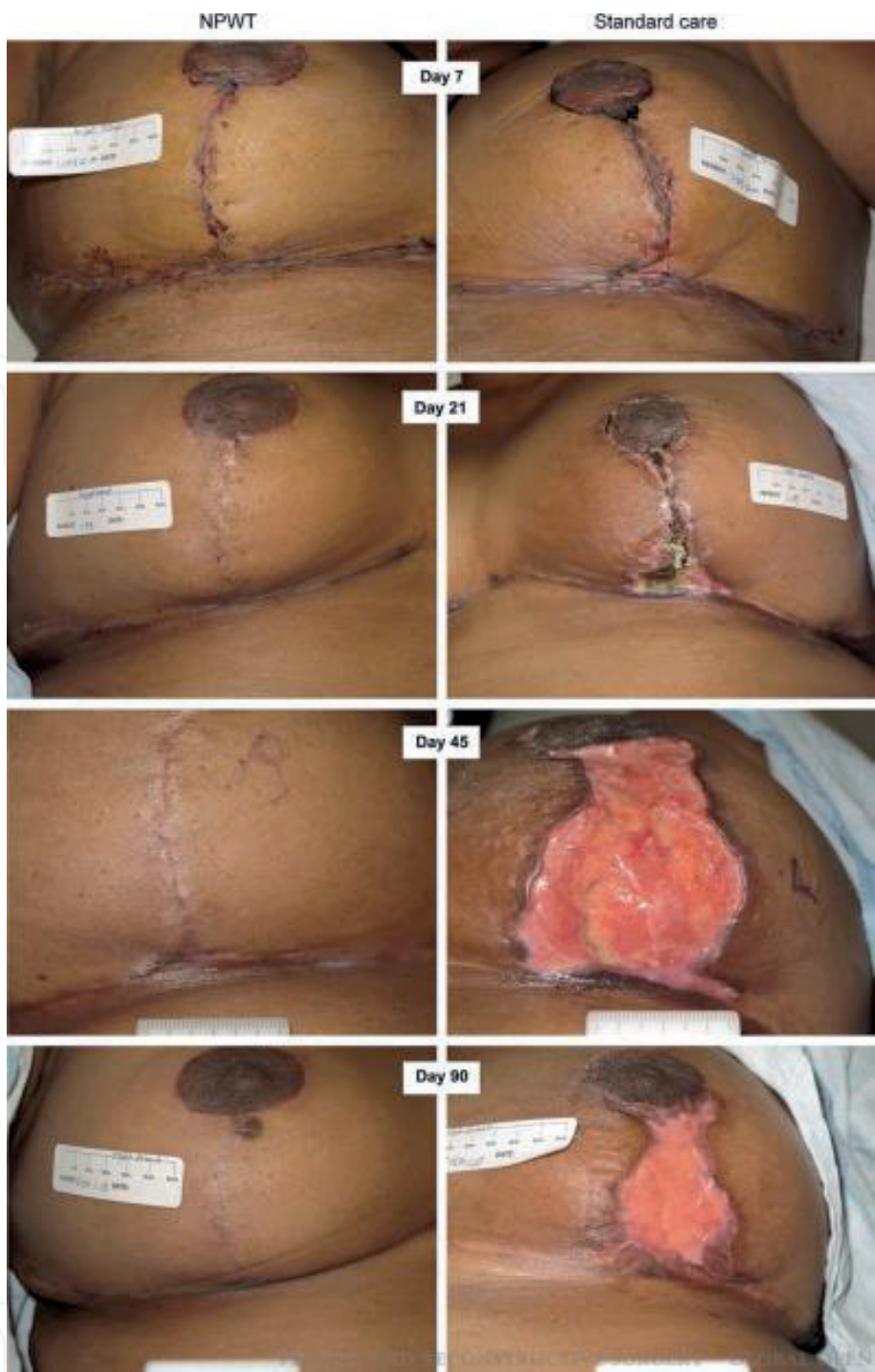

Figure 2.
Progression of incisions in patient treated with iNPWT and standard wound care after bilateral reduction mammoplasty. Wound complications and dehiscence are reduced with iNPWT (reprinted with permission from Ref. [60]).

Risk factors that increase the risk of sternal wound infections include smoking, diabetes, increasing number of grafts, peripheral vascular disease, chronic pulmonary disease, obesity, increased duration of mechanical ventilation, preoperative malnutrition, and harvesting of bilateral internal mammary arteries [67].

The use of incisional NPWT on sternal surgical incisions in patients with multiple comorbidities and consequently a high risk for wound complications was evaluated. Results have shown no wound complications in this high-risk group of patients at least 30 days after surgery and complete wound and surrounding skin healing with the absence of skin lesion due to negative pressure after removal of the dressing [68]. Results from another study also concluded that applying incisional

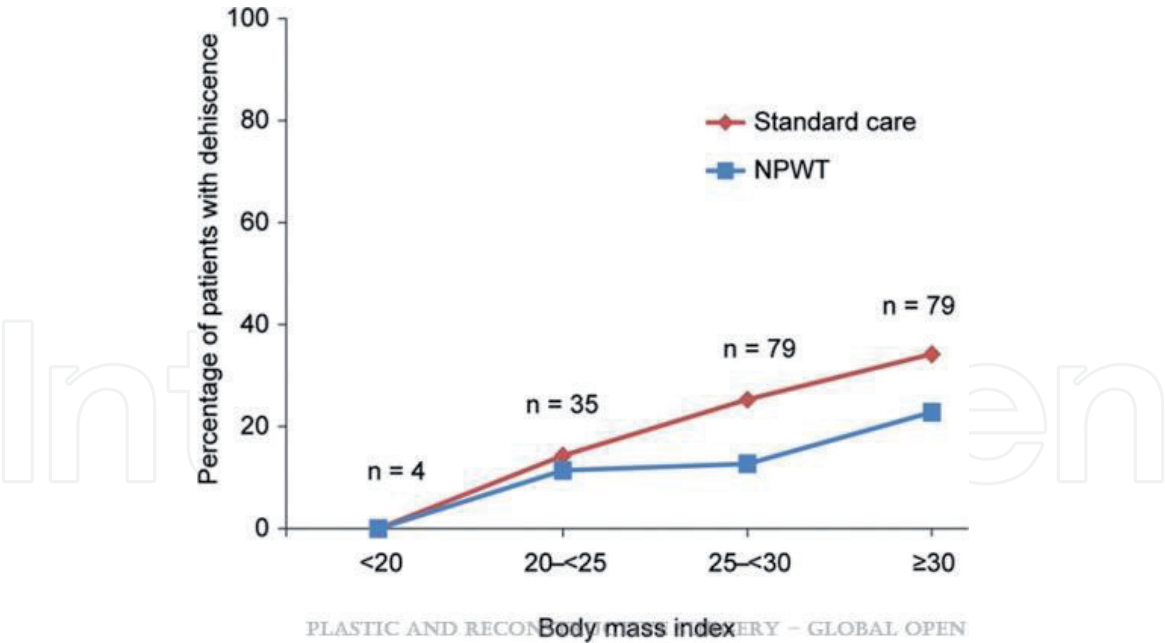


Figure 3. Relation of body mass index (BMI) on wound dehiscence rates in patients undergoing reduction mammoplasty. The NPWT group shows lower wound dehiscence rates than standard wound care (reprinted with permission from Ref. [60]).

NPWT over clean, closed incisions for the first 6–7 postoperative days reduced the likelihood of postoperative wound infections after median sternotomy not only in high-risk patients but also in a comprehensive patient population [45].

4.5 Vascular surgery

Vascular surgical site infections (SSI) occur as a result of perioperative events that lead to the colonization of the wound and underlying graft with bacterial species. Patients undergoing vascular procedures are at an increased risk of developing an SSI of up to 5% of clean procedures and 30% of clean-contaminated procedures [69]. Severe complications that arise after vascular surgery including leg amputation and death prompted the use of incisional NPWT postoperatively to prevent complications associated with such surgeries. Results of different studies have shown a potential reduction in wound complications and no observed increase in hemorrhage in high-risk patients with severe comorbidities undergoing vascular surgeries [70].

Recent retrospective study on lower leg fasciotomy supports faster wound closure and daily wound size reduction, fewer dressing changes, and shorter hospital stay with NPWT. These factors contribute to significant reduction in surgical site infections, from 30 per cent with standard wound care to 6 per cent with closed incisional NPWT [71].

4.6 Plastic surgery

In plastic surgery, the use of NPWT is particularly important in patients who experienced complications associated with skin graft rejection and its associated partial necrosis. It's also used after excision of large scalp flaps due to injuries and lack of opportunities to cover it with the patient's own skin. NPWT resulted in faster healing and granulation of wounds and a reduction of the overall size [72]. The use of NPWT in large wound surfaces with large amounts of mucus, observed in skin burns, resulted in a significant acceleration in the time taken for patients' healing and rehabilitation. Additional outcomes included wounds that healed better, fewer

infection rates, and more elastic tissue preservation [73]. Results from a multicenter, prospective randomized controlled, within-patient study involving our center and senior author (RDG) provided high-level evidence supporting significantly reduced wound complications following application of iNPWT in susceptible patients [60].

5. Conclusion

Advances in surgical and sterilization techniques have largely mitigated risk of wound complications and SSI rates; however, these complications till date pose a major physical, financial, and psychological challenge in the postoperative phase of treatment. Incisional NPWT presents a promising treatment modality for surgical wounds and incisions, with its proposed benefits in reducing infections, preventing wound dehiscence and optimizing wound healing and scarring. Randomized controlled trials and further clinical research are warranted to develop guidelines to the safe, effective, and routine use of iNPWT. However, in the present economic model of healthcare, efficacy of a treatment modality alone does not justify its use, and a large-scale cost-benefit analysis is warranted to rationalize its use in high-risk and low-risk postoperative patients.

Acknowledgements

The authors would like to thank Abbas Hassan, Rou Wan, and Dr. Jing Liu for their valuable inputs and contribution.

Conflict of interest

The authors declare no conflict of interest.

Notes/thanks

The first author CJJ would like to immensely thank senior author RDG for his unending support, guidance, and inspiration to strive to be perfect.

Author details

Chitang J. Joshi, Ji-Cheng Hsieh, Abbas Hassan and Robert D. Galiano*
Department of Plastic and Reconstructive Surgery, Feinberg School of Medicine,
Northwestern University, Chicago, IL, United States

*Address all correspondence to: rgaliano@nm.org

IntechOpen

© 2019 The Author(s). Licensee IntechOpen. This chapter is distributed under the terms of the Creative Commons Attribution License (<http://creativecommons.org/licenses/by/3.0>), which permits unrestricted use, distribution, and reproduction in any medium, provided the original work is properly cited. 

References

- [1] Argenta LC, Morykwas MJ. Vacuum-assisted closure: A new method for wound control and treatment. Clinical experience. *Annals of Plastic Surgery*. 1997;**38**(6):563-576
- [2] Borys S, Ludwig-Slomczynska AH, Seweryn M, et al. Negative pressure wound therapy in the treatment of diabetic foot ulcers may be mediated through differential gene expression. *Acta Diabetologica*. 2019;**56**(1):115-120. DOI: 10.1007/s00592-018-1223-y
- [3] Condé-Green A, Chung TWL, Holton LH, Hui-Chou HG, Zhu Y, Wang HD, et al. Incisional negative-pressure wound therapy versus conventional dressings following abdominal wall reconstruction: A comparative study. *Annals of Plastic Surgery*. 2013;**71**(4):394-397
- [4] Jaffe L, Wu SC. Dressings, topical therapy, and negative pressure wound therapy. *Clinics in Podiatric Medicine and Surgery*. 2019;**36**:397-411. DOI: 10.1016/j.cpm.2019.02.005
- [5] Rosenbaum AJ, Banerjee S, Rezak KM, Uhl RL. Advances in wound management. *Journal of the American Academy of Orthopaedic Surgeons*. 2018;**26**(23):833-843
- [6] Sahebally SM, McKevitt K, Stephens I, et al. Negative pressure wound therapy for closed laparotomy incisions in general and colorectal surgery: A systematic review and meta-analysis. *JAMA Surgery*. 2018;**153**(11):e183467
- [7] Javed AA, Teinor J, Wright M, et al. Negative pressure wound therapy for surgical-site infections: A randomized trial. *Annals of Surgery*. 2018;**269**(6):1034-1040
- [8] Yao M, Fabbi M, Hayashi H, et al. A retrospective cohort study evaluating efficacy in high-risk patients with chronic lower extremity ulcers treated with negative pressure wound therapy. *International Wound Journal*. 2014;**11**(5):483-488
- [9] Shine J, Efanov JI, Paek L, Coeugnet É, Danino MA, Izadpanah A. Negative pressure wound therapy as a definitive treatment for upper extremity wound defects: A systematic review. *International Wound Journal*. 2019;**16**(4):960-967. DOI: 10.1111/iwj.13128
- [10] Reider K, McElroy E, Lemay S. The use of negative pressure with instillation and dwell for the treatment of necrotizing fasciitis. *Cureus*. 2018;**10**(10):e3515. DOI: 10.7759/cureus.3515
- [11] Gomoll AH, Lin A, Harris MB. Incisional vacuum-assisted closure therapy. *Journal of Orthopaedic Trauma*. 2006;**20**(10):705-709
- [12] Nam D, Sereshon RA, Levine BR, Della Valle CJ. The use of closed incision negative-pressure wound therapy in orthopaedic surgery. *Journal of the American Academy of Orthopaedic Surgeons*. 2018;**26**(9):295-302
- [13] Magill SS, Edwards JR, Bamberg W, et al. Emerging infections program healthcare-associated infections and antimicrobial use prevalence survey team: Multistate point-prevalence survey of health care-associated infections. *The New England Journal of Medicine*. 2014;**370**(13):1198-1208
- [14] Shepard J, Ward W, Milstone A, et al. 16. Financial impact of surgical site infections on hospitals: The hospital management perspective. *JAMA Surgery*. 2013;**148**(10):907-914
- [15] Willy C, Agarwal A, Andersen CA, et al. Closed incision negative pressure therapy: International multidisciplinary consensus recommendations.

International Wound Journal.
 2017;**14**(2):385-398

[16] Cooper HJ, Bas MA. Closed-incision negative-pressure therapy versus anti-microbial dressings after revision hip and knee surgery: A comparative study. *The Journal of Arthroplasty*. 2016;**31**:1047e52

[17] Karlakki SL, Hamad AK, Whittall C, Graham NM, Banerjee RD, Kuiper JH. Incisional negative pressure wound therapy dressings (iNPWTd) in routine primary hip and knee arthroplasties: A randomised controlled trial. *Bone & Joint Research*. 2016;**5**:328e37

[18] Redfern RE, Cameron-Ruetz C, O'Drobinak SK, Chen JT, Beer KJ. Closed incision negative pressure therapy effects on postoperative infection and surgical site complication after total hip and knee arthroplasty. *The Journal of Arthroplasty*. 2017;**32**:3333e9

[19] Grauhan O, Navasardyan A, Hofmann M, Müller P, Stein J, Hetzer R. Prevention of poststernotomy wound infections in obese patients by negative pressure wound therapy. *The Journal of Thoracic and Cardiovascular Surgery*. 2013;**145**(5):1387-1392

[20] Matatov T, Reddy KN, Doucet LD, Zhao CX, Zhang WW. Experience with a new negative pressure incision management system in prevention of groin wound infection in vascular surgery patients. *Journal of Vascular Surgery*. 2013;**57**(3):791-795

[21] Bonds AM, Novick TK, Dietert JB, Araghizadeh FY, Olson CH. Incisional negative pressure wound therapy significantly reduces surgical site infection in open colorectal surgery. *Diseases of the Colon and Rectum*. 2013;**56**(12):1403-1408

[22] Keeney JA, Cook JL, Clawson SW, Aggarwal A, Stannard JP. Incisional negative pressure wound therapy devices improve short-term wound

complications, but not long-term infection rate following hip and knee arthroplasty. *The Journal of Arthroplasty*. 2019;**34**:723-728

[23] Adogwa O, Fatemi P, Perez E, et al. Negative pressure wound therapy reduces incidence of postoperative wound infection and dehiscence after long-segment thoracolumbar spinal fusion: A single institutional experience. *The Spine Journal*. 2014;**14**(12):2911-2917

[24] Ousey KJ, Atkinson RA, Williamson JB, Lui S. Negative pressure wound therapy (NPWT) for spinal wounds: A systematic review. *The Spine Journal*. 2013;**13**(10):1393-1405

[25] Jones GA, Butler J, Lieberman I, Schlenk R. Negative-pressure wound therapy in the treatment of complex postoperative spinal wound infections: Complications and lessons learned using vacuum-assisted closure. *Journal of Neurosurgery. Spine*. 2007;**6**(5):407-411

[26] Ploumis A, Mehbod AA, Dressel TD, Dykes DC, Transfeldt EE, Lonstein JE. Therapy of spinal wound infections using vacuum-assisted wound closure: Risk factors leading to resistance to treatment. *Journal of Spinal Disorders & Techniques*. 2008;**21**(5):320-323

[27] Kim JJ, Franczyk M, Gottlieb LJ, Song DH. Cost-effective alternative for negative-pressure wound therapy. *Plastic and Reconstructive Surgery. Global Open*. 2017;**5**:e1211

[28] deLissovoy G, Fraeman K, Hutchins V, Murphy D, Song D, Vaughn BB. Surgical site infection: Incidence and impact on hospital utilization and treatment costs. *American Journal of Infection Control*. 2009;**37**:387-397

[29] Lewis LS, Convery PA, Bolac CS, et al. Cost of care using prophylactic

negative pressure wound vacuum on closed laparotomy incisions. *Gynecologic Oncology*. 2014;**132**(3):684-689

[30] Tran BN, Johnson AR, Shen C, Lee BT, Lee ES. Closed-incision negative-pressure therapy efficacy in abdominal wall reconstruction in high-risk patients: A meta-analysis. *The Journal of Surgical Research*. 2019;**241**:63-71

[31] Kilpadi DV, Lessing C, Derrick K. Healed porcine incisions previously treated with a surgical incision management system: Mechanical, histomorphometric, and gene expression properties. *Aesthetic Plastic Surgery*. 2014;**38**(4):767-778

[32] Dadaci M, Isci ET, Ince B, et al. Negative pressure wound therapy in the early period after hand and forearm replantation: Is it safe? *Journal of Wound Care*. 2016;**25**(6):350-355

[33] Lesiak AC, Shafritz AB. Negative-pressure wound therapy. *The Journal of Hand Surgery*. 2013;**38**(9):1828-1832

[34] Watt AJ, Friedrich JB, Huang JI. Advances in treating skin defects of the hand: Skin substitutes and negative-pressure wound therapy. *Hand Clinics*. 2012;**28**(4):519-528

[35] Maruccia M, Onesti MG, Sorvillo V, Albano A, Dessy LA, Carlesimo B, et al. An alternative treatment strategy for complicated chronic wounds: Negative pressure therapy over mesh skin graft. *BioMed Research International*. 2017;**2017**:7. DOI: 10.1155/2017/83952

[36] Horch RE. Incisional negative pressure wound therapy for high-risk wounds. *Journal of Wound Care*. 2015;**24**(4 Suppl):21-28

[37] Orgill DP, Bayer LR. Update on negative-pressure wound therapy.

Plastic and Reconstructive Surgery. 2011;**127**(Suppl 1):105S-115S

[38] Timmers MS, Le Cessie S, Banwell P, Jukema GN. The effects of varying degrees of pressure delivered by negative-pressure wound therapy on skin perfusion. *Annals of Plastic Surgery*. 2005;**55**(6):665-671

[39] Ooi AS, Song DH. Discussion: Does the use of incisional negative-pressure wound therapy prevent mastectomy flap necrosis in immediate expander-based breast reconstruction? *Plastic and Reconstructive Surgery*. 2016;**138**(3):567-569

[40] Kilpadi DV, Cunningham MR. Evaluation of closed incision management with negative pressure wound therapy (CIM): Hematoma/seroma and involvement of the lymphatic system. *Wound Repair and Regeneration*. 2011;**19**(5):588-596

[41] Schmedes GW, Banks CA, Malin BT, et al. Massive flap donor sites and the role of negative pressure wound therapy. *Otolaryngology and Head and Neck Surgery*. 2012;**147**(6):1049-1053

[42] Pachowsky M, Gusinde J, Klein A, et al. Negative pressure wound therapy to prevent seromas and treat surgical incisions after total hip arthroplasty. *International Orthopaedics*. 2012;**36**(4):719-722

[43] Mark KS, Alger L, Terplan M. Incisional negative pressure therapy to prevent wound complications following cesarean section in morbidly obese women: A pilot study. *Surgical Innovation*. 2013;**21**(4):345-349

[44] Cirotchi R, Birindelli A, Biffi WL, Mutaftchiyski V, Popivanov G, Chiara O, et al. What is the effectiveness of the negative pressure wound therapy (NPWT) in patients treated with open abdomen technique? A systematic review and meta-analysis. *The Journal*

of Trauma and Acute Care Surgery. 2016;**81**(3):575-584

[45] Grauhan O, Navasardyan A, Tutkun B, Hennig F, Müller P, Hummel M, et al. Effect of surgical incision management on wound infections in a poststernotomy patient population. *International Wound Journal*. 2014;**11**(Suppl. 1):6-9

[46] Dohmen PM, Misfeld M, Borger MA, Mohr FW. Closed incision management with negative pressure wound therapy. *Expert Review of Medical Devices*. 2014;**11**(4):395-402

[47] Karlakki S, Brem M, Giannini S, et al. Negative pressure wound therapy for management of the surgical incision in orthopaedic surgery: A review of evidence and mechanisms for an emerging indication. *Bone & Joint Research*. 2013;**2**(12):276-284

[48] Stannard JP, Volgas DA, McGwin G 3rd, et al. Incisional negative pressure wound therapy after high-risk lower extremity fractures. *Journal of Orthopaedic Trauma*. 2012;**26**(1):37-42

[49] Stannard JP, Gabriel A, Lehner B. Use of negative pressure wound therapy over clean, closed surgical incisions. *International Wound Journal*. 2012;**9**(Suppl. 1):32-39

[50] Atkins BZ, Wooten MK, Kistler J, et al. Does negative pressure wound therapy have a role in preventing poststernotomy wound complications? *Surgical Innovation*. 2009;**16**(2):140-146

[51] Bovill E, Banwell PE, Teot L, Eriksson E, Song C, Mahoney J, et al. Topical negative pressure wound therapy: A review of its role and guidelines for its use in the management of acute wounds. *International Wound Journal*. 2008;**5**(4):511-529

[52] Lindstedt S, Malmsjö M, Hansson J, Hlebowicz J, Ingemansson R. Pressure transduction and fluid evacuation during conventional negative pressure wound therapy of the open abdomen and NPWT using a protective disc over the intestines. *BMC Surgery*. 2012;**12**(1):4

[53] Kaplan M, Banwell P, Orgill DP, Ivatury RR, Demetriades D, Moore FA, et al. Guidelines for the management of the open abdomen. *Wounds-A Compendium of Clinical Research and Practice*. 2005;**17**:1-24

[54] Franklin ME, Alvarez A, Russek K. Negative pressure therapy: A viable option for general surgical management of the open abdomen. *Surgical Innovation*. 2012;**19**(4):353-363

[55] Kubiak BD, Albert SP, Gatto LA, Snyder KP, Maier KG, Vieau CJ, et al. Peritoneal negative pressure therapy prevents multiple organ injury in a chronic porcine sepsis and ischemia/reperfusion model. *Shock*. 2010;**34**(5):525-534

[56] Blackham AU, Farrah JP, McCoy TP, Schmidt BS, Shen P. Prevention of surgical site infections in high-risk patients with laparotomy incisions using negative-pressure therapy. *The American Journal of Surgery*. 2013;**205**(6):647-654

[57] Wiegering A, Dietz UA, Corteville C, Plaßmeier L, Jurowich C, Germer CT, et al. Impact of incisional negative pressure wound therapy on perineal wound healing after abdominoperineal rectum extirpation. *International Journal of Colorectal Disease*. 2017;**32**(2):291-293

[58] Moyer HR, Losken A. Predicting mastectomy skin flap necrosis with indocyanine green angiography: The gray area defined. *Plastic and Reconstructive Surgery*. 2012;**129**(5):1043-1048

- [59] Kim DY, Park SJ, Bang SI, Mun GH, Pyon JK. Does the use of incisional negative-pressure wound therapy prevent mastectomy flap necrosis in immediate expander-based breast reconstruction? *Plastic and Reconstructive Surgery*. 2016;**138**(3):558-566
- [60] Galiano RD, Hudson D, Shin J, van der Hulst R, Tanaydin V, Djohan R, et al. Incisional negative pressure wound therapy for prevention of wound healing complications following reduction mammoplasty. *Plastic and Reconstructive Surgery—Global Open*. 2018;**6**(1):e1560
- [61] Pellino G, Sciaudone G, Candilio G, De Fatico GS, Landino I, Della Corte A, et al. Preventive NPWT over closed incisions in general surgery: Does age matter? *International Journal of Surgery*. 2014;**12**:S64-S68
- [62] Tanaydin V, Beugels J, Andriessen A, Sawor JH, Van der Hulst RR. Randomized controlled study comparing disposable negative-pressure wound therapy with standard care in bilateral breast reduction mammoplasty evaluating surgical site complications and scar quality. *Aesthetic Plastic Surgery*. 2018;**42**(4):927-935
- [63] DeCarbo WT, Hyer CF. Negative-pressure wound therapy applied to high-risk surgical incisions. *The Journal of Foot and Ankle Surgery*. 2010;**49**(3):299-300
- [64] Reddix JR, Tyler HK, Kulp B, Webb LX. Incisional vacuum-assisted wound closure in morbidly obese patients undergoing acetabular fracture surgery. *American Journal of Orthopedics*. 2009;**38**(9):446-449
- [65] Reddix JR, Leng XI, Woodall J, Jackson B, Dedmond B, Webb LX. The effect of incisional negative pressure therapy on wound complications after acetabular fracture surgery. *Journal of Surgical Orthopaedic Advances*. 2010;**19**(2):91-97
- [66] Hollenbeak CS, Murphy DM, Koenig S, Woodward RS, Dunagan WC, Fraser VJ. The clinical and economic impact of deep chest surgical site infections following coronary artery bypass graft surgery. *Chest*. 2000;**118**(2):397-402
- [67] Lu JC, Grayson AD, Jha P, Srinivasan AK, Fabri BM. Risk factors for sternal wound infection and mid-term survival following coronary artery bypass surgery. *European Journal of Cardio-Thoracic Surgery*. 2003;**23**(6):943-949
- [68] Colli A. First experience with a new negative pressure incision management system on surgical incisions after cardiac surgery in high risk patients. *Journal of Cardiothoracic Surgery*. 2011;**6**(1):160
- [69] Mangram AJ, Horan TC, Pearson ML, Silver LC, Jarvis WR, Hospital Infection Control Practices Advisory Committee. Guideline for prevention of surgical site infection, 1999. *Infection Control and Hospital Epidemiology*. 1999;**20**(4):247-280
- [70] Weir G. The use of a surgical incision management system on vascular surgery incisions: A pilot study. *International Wound Journal*. 2014;**11**(s1):10-12
- [71] Acosta S, Björck M, Wanhainen A. Negative-pressure wound therapy for prevention and treatment of surgical-site infections after vascular surgery. *The British Journal of Surgery*. 2017;**104**(2):e75-e84
- [72] Gupta S. Optimal use of negative pressure wound therapy for skin grafts. *International Wound Journal*. 2012;**9**:40-47

[73] Bloemen MC, van der Wal MB, Verhaegen PD, Nieuwenhuis MK, van Baar ME, van Zuijlen PP, et al. Clinical effectiveness of dermal substitution in burns by topical negative pressure: A multicenter randomized controlled trial. *Wound Repair and Regeneration*. 2012;**20**(6):797-805

IntechOpen

IntechOpen