We are IntechOpen, the world's leading publisher of Open Access books Built by scientists, for scientists

6,900
Open access books available

185,000
International authors and editors

200M
Downloads

Our authors are among the

154
Countries delivered to

TOP 1%
most cited scientists

12.2%
Contributors from top 500 universities

WEB OF SCIENCE™

Selection of our books indexed in the Book Citation Index in Web of Science™ Core Collection (BKCI)

Interested in publishing with us?
Contact book.department@intechopen.com

Numbers displayed above are based on latest data collected.
For more information visit www.intechopen.com

Chapter

Systemic Sclerosis Mimics

Ondřej Kodet and Sabína Oreská

Abstract

Many clinical conditions are presenting with sclerosis of the skin and with tissue fibrosis. These conditions may be confused with systemic sclerosis (SSc, scleroderma). These diseases and disabilities are generally referred to as systemic sclerosis mimics or scleroderma-like syndromes. These disorders have very different etiologies and often an unclear pathogenetic mechanism. Distinct clinical characteristics, skin histology, and disease associations may allow distinguishing these conditions from systemic sclerosis and from each other. A histopathological examination with clinicopathological correlation for diagnosis is important to spare the patients from ineffective treatments and inadequate management. In this chapter, we discussed localized scleroderma, lichen sclerosus, nephrogenic systemic fibrosis, eosinophilic fasciitis, scleromyxedema, and scleredema. These are often detected in the primary care setting and referred to rheumatologists for further evaluation. Rheumatologists, or preferably in collaboration with a dermatologist, must be able to promptly recognize them to provide valuable prognostic information and appropriate treatment options for affected patients.

Keywords: localized scleroderma, lichen sclerosus, eosinophilic fasciitis, nephrogenic systemic fibrosis, scleromyxedema, scleredema

1. Introduction

In this chapter, we discuss the groups of disorders classified as systemic sclerosis mimics. Localized and sometimes generalized skin stiffness is typical for this group of diseases. However, quite incongruous pathogenesis, underlying disease mechanisms and distinct organ involvement are significantly different in these conditions. This chapter describes the pathogenesis, clinical manifestation, histopathology findings, and therapeutic possibilities of the most common diseases that may cause difficulties in the differential diagnosis of systemic sclerosis.

2. Localized scleroderma, morphea

2.1 Introduction

Localized scleroderma is a clinically distinct inflammatory disease, primarily of the dermis and also subcutaneous fat [1]. The inflammation leads to scar-like sclerosis. Inflammatory infiltrates and changes of small vessels are similar in morphea and systemic sclerosis (SSc), but morphea has more asymmetric or linear skin localization and distribution than SSc, which has symmetrical distribution. Generalized morphea can prevent and mimic diffuse cutaneous SSc, but this clinical variant does not have Raynaud's phenomenon, digital sclerosis and lung, and

gastrointestinal tract manifestation of the disease. Morphea is responsible for the morbidity of the patient such as skin tightness, joint mobility reduction leading to contractures, growth retardation, and pain [1–3].

2.2 Epidemiology

Morphea typically develops in adults, although morphea can occur at any age. The incidence of morphea is 3 per 100,000 people, and the prevalence of morphea increases with age. The mean age of disease onset is 45 years. Morphea is more prevalent in women than in men (2.6:1), except linear morphea, which has no gender preference [2–4].

2.3 Pathogenesis

The cause of the disease is unknown. Coexistence of various forms of scleroderma and the rare possibility of progression of localized scleroderma into SSc indicate that both types represent different manifestations of the same pathological process. Pathogenesis may be due to participation of environmental influences, immunological disorders, and infections, e.g., association with *Borrelia burgdorferi* [3]. Sclerosis of the skin is induced by vascular damage, activated T cells, and accented connective tissue production by dermal fibroblasts. Vascular changes represent a reduction in the number of capillaries. Enhanced production of collagen and other extracellular matrix proteins and components is induced by T-cell-derived cytokines, interleukin 4 (IL-4), IL-13, and transforming growth factor beta (TGF-β) [3, 5, 6].

2.4 Clinical features

Morphea can be divided into several clinical groups: plaque-type morphea, linear morphea, generalized morphea, deep morphea, nodular morphea, and guttate morphea. Patient with morphea does not have involvement of internal organs and Raynaud's phenomenon. Some patients may have involvement of muscles, tendons, and joints or neurological or ophthalmological symptoms which depend more likely on anatomical site, e.g., in a patient with linear morphea [2].

2.5 Plaque-type morphea, circumscribed morphea

Plaque-type morphea is the most common variant, characterized by a slightly elevated, edematous, erythematous, or violaceous and livid plaque with oval to round or centrifugal distribution (**Figure 1**). The developmental stage of the disease may influence the clinical features: (i) inflammatory, (ii) sclerotic, and (iii) atrophic [1, 2].

Figure 1.
Plaque-type morphea, lesion on the right side of the trunk. Plaques are surrounded by a dark red rim on the periphery with a yellowish white color center of the lesion as a result of the increasing deposition of connective tissue.

Figure 2.
Guttate morphea, multiple nummular lesions on the right thigh.

In the inflammatory phase, these are delimited striated skin plaques with the accentuated surface by skin pores, which resemble "orange peel" due to the edema of the corium expanding the follicular orifice. Plaques are surrounded by a violaceous rim on the periphery, indicating the active inflammatory stage of the disease. A yellowish-white color develops in the center of the lesion as a result of the increasing deposit of connective tissue [3]. In the sclerotic phase, the inflammatory border is absent. The skin of the lesion is smooth, shiny, and difficult or unable to be shaken. In the final (atrophic) phase, induration disappears; the plaques are soft, slightly sloping for skin and subcutaneous atrophy, and mostly gray-brown pigmented. Circumscribed morphea usually presents as single or multiple skin lesions. It is generally asymptomatic, but the central portion of the progressing lesion starts to get rigid and may be slightly painful [2, 3].

A different manifestation of morphea can be present. Guttate morphea presents as multiple rather superficial and nummular plaques (**Figure 2**).

Deep morphea represents sclerosis that affects the primarily deep parts of the dermis and subcutaneous fat (**Figure 3**).

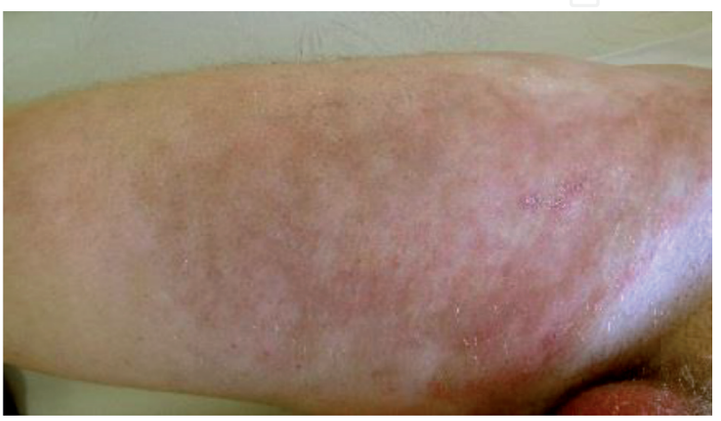

Figure 3.
Deep morphea, the affection of the front of the right thigh, mapping distribution of erythematous and whitish parts with visible scarring.

2.6 Linear morphea

Linear morphea is similar in the clinical feature to circumscribed morphea but with a linear distribution. Linear morphea initially starts as a linear erythematous streak or harmless lesion that later forms a scar-like band (**Figure 4**).

This scar-like band significantly impairs the mobility of the affected limb. Linear morphea can affect the underlying fascia, the muscle, and tendons. Linear morphea that transcends joints can significantly reduce movement and lead to developmental limb defects in children. Rarely, it can form bizarre configurations when copying Blaschko's lines [1, 3, 7].

2.7 "En coup de sabre"

The "en coup de sabre" represents a linear type of morphea of the head. This morphea is unilateral and extends from the forehead into the frontal scalp (**Figure 5**).

It usually starts as a small plaque with the surrounding inflammatory erythematous rim. Parry-Romberg syndrome is a rare variant of linear morphea of the forehead and scalp, with progressive loss of subcutaneous fat, with a smaller share of sclerosis [3, 8, 9].

Figure 4.
Linear morphea, linear distribution of plaques, leading to atrophic changes in the affected limb.

Figure 5.
"En coup de sabre" as linear morphea of the head. Linear scarring lesion on the forehead with an erythematous rim spreading to the scalp.

2.8 Generalized morphea

Generalized morphea begins as multiple plaque-type morphea on the trunk. This clinical variant is defined by the presence of ≥4 plaques involving at least two different anatomic sites (**Figure 6**).

In contrast to systemic sclerosis, generalized morphea does not present with sclerosis primarily involving acral skin or sclerodactyly, but this anatomical site can also be affected [10]. Apart from the skin, generalized morphea can also affect the subcutis and fascia, and be accompanied by slight changes in internal organs (especially the gastrointestinal tract and lungs) and the formation of joint contractures with mostly secondary joint involvement and movement limitation [11, 12]. Carapace-like tightening of the chest, can reduce breathing and cause swallowing difficulties.

2.9 Laboratory findings

Laboratory abnormalities are typically associated with generalized and linear morphea, but some patients with morphea have elevated antinuclear antibody (ANA). Reported rates of ANA positivity among patients with morphea range from 18 to 68%. Other autoantibodies that are detected less frequently than ANA in patients with morphea include anti-single-stranded DNA (ssDNA), anti-double-stranded DNA (dsDNA), antihistone, anti-topoisomerase IIα, antiphospholipid, and rheumatoid factor [1, 13].

2.10 Histopathology

The histopathological findings depend on the stage of the disease and area where the biopsy was taken (inflammatory border or central sclerotic lesion). Biopsy specimens for histology must include subcutaneous fat (**Figure 7**).

Biopsies performed from inflammatory lesions demonstrate an interstitial and perivascular inflammatory cell infiltrate composed primarily of $CD4^+$ T

Figure 6.
Generalized morphea begins as multiple-plaque-type morphea on the abdomen, circularly affecting breasts and the neck. In the margins, lesions are with a rim of erythema, indicating the inflammatory stage of the disease.

Figure 7.
Deep skin biopsy to subcutaneous fat after formaldehyde fixation.

cells, eosinophils, plasma cells, and mast cells. Inflammation may extend into the subcutaneous tissues. Furthermore, tissue edema, enlarged tortuous vessels, and thickened collagen bundles may be observed. Biopsy from a sclerotic lesion

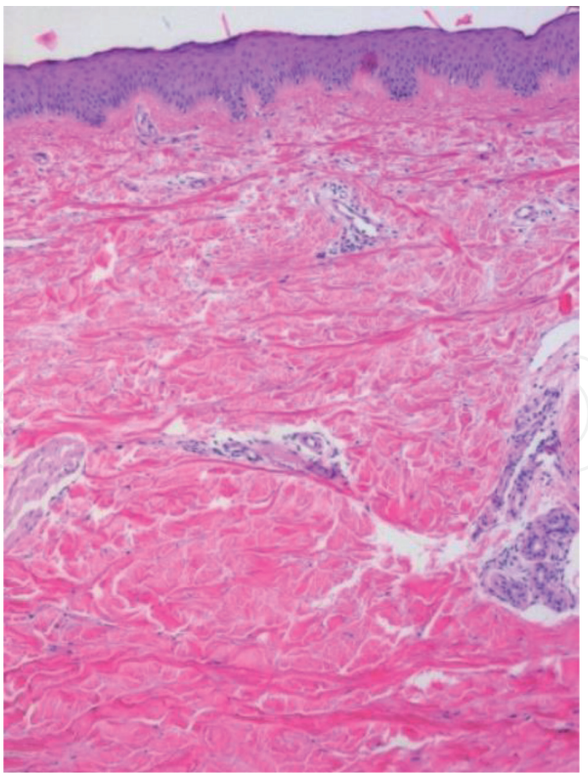

Figure 8.
Biopsy from a sclerotic lesion demonstrates homogenization of the papillary dermis and thickened collagen bundles extending into the reticular dermis.

demonstrates homogenization of the papillary dermis and thickened collagen bundles extending into the reticular dermis or beyond (**Figure 8**). In biopsy from deep morphea, the deep reticular dermis, subcutis, and fascia show sclerotic changes [14].

2.11 Differential diagnosis

A number of other disorders can present with clinical features that resemble morphea. Generalized morphea is necessary to distinguish from systemic sclerosis or scleredema diabeticorum. In addition to the skin sclerosis, systemic sclerosis generally begins with the Raynaud's phenomenon, and patients commonly exhibit initial puffiness and eventual sclerosis in the fingertips (sclerodactyly), usually accompanied by nail fold capillary changes. These changes are absent in patients with morphea. The differential diagnosis of plaque-type morphea includes lichen sclerosus, morpheaform basal cell carcinoma, and postirradiation morphea. Furthermore, we need to think of lipodermatosclerosis as fibrosing panniculitis with typical localization on the lower extremities or eosinophilic fasciitis. In some cases of limb involvement, pretibial myxedema or Lyme disease (acrodermatitis atrophicans) must be excluded [1, 13, 14].

2.12 Treatment

A variety of treatment options are available for patients with active lesions of morphea; however, evidence in support and success of these therapeutics modalities is limited. The expected outcome of successful therapy for morphea is not a complete healing or normal skin texture. In patients with progressive disease, successful treatment presents stopping the formation of new lesions and limiting the spreading of the disease [1, 15].

2.13 Topical and intralesional treatment

Topical therapies are unlikely to be effective for the disease involving the subcutis or deeper tissues and are not useful for preventing the development of new lesions in patients with rapidly progressive disease. Topical tacrolimus as tacrolimus 0.1% ointment may be effective for active, inflammatory morphea [16]. High potency topical and intralesional corticosteroids are widely used for the treatment of morphea; however, no formal studies have documented their efficacy. Topical vitamin D—vitamin D as topical calcipotriene 0.005% ointment—may inhibit effects on fibroblast proliferation, collagen synthesis, and T-cell activation. In some clinical studies, an improvement on this therapy was noted in limited numbers of patients [15, 17].

Imiquimod is a topical immunomodulator that induces interferon-gamma, a cytokine that inhibits TGF-beta and the production of extracellular matrix proteins. Imiquimod also downregulates the profibrotic cytokine IL-4. Limited data suggest that imiquimod is effective in some patients with plaque-type morphea [18].

It is possible to use phototherapy in patients with sclerotic diseases like morphea. Longer wavelengths of light as ultraviolet A (UVA) (320–400 nm) are capable of greater depth of penetration into the skin, and most studies of UV phototherapy in sclerotic skin disease have focused on the use of UVA light (320–400 nm). Fewer data are available on the use of PUVA therapy (a combination of UVA and topical or oral use of psoralens) and ultraviolet B (UVB) light (290–320 nm). Phototherapy is unlikely to be effective for morphea with deep involvement (subcutis, fascia, or muscle) and should not be considered as primary therapy alone [19].

2.14 Systemic treatment

Patients with the progressive disease require systemic therapy with methotrexate or corticosteroids. Methotrexate is the most appropriate systemic therapy for morphea. In patients with acute generalized or rapidly progressive disease, we combine treatment with systemic corticosteroids. Methotrexate is typically given for at least 6–12 months with a weekly dose of 15–25 mg. The systemic corticosteroids are usually tapered and discontinued after 3–4 months or pulse intravenous therapy is used instead (500–1000 mg of intravenous methylprednisolone sodium succinate for 3 consecutive days/month) [15, 20].

3. Morpheaform inflammatory syndromes/conditions

Some diseases and disorders with acrosclerosis and Raynaud's phenomenon have a clinical presentation similar to localized scleroderma. The etiology of these disorders is diverse and includes, e.g., secondary sclerosis after exposition to bleomycin, vinyl chloride, L-tryptophan, or toxic oils. Sclerosis can also be induced by endogenous metabolites, by x-irradiation, or during chronic graft-versus-host disease (GVHD) (**Figure 9**). Morphea-like lesion, eosinophilic fasciitis, and lichen sclerosus can also be observed in these patients [21].

3.1 Lipodermatosclerosis

3.1.1 Introduction

Typical changes associated with chronic venous insufficiency include erythema, induration, and hemosiderin pigmentary changes. But a variety of clinical

Figure 9.
Morphea-like lesion in a patient with GVHD. Post-inflammatory hyperpigmentation with whitish areas of sclerotic skin affecting the left thigh.

appearances and histopathologic findings also include sclerosis, or sclerosing panniculitis. The various manifestations of this panniculitis have been consolidated under the heading of lipodermatosclerosis or sclerosing panniculitis [22].

Lipodermatosclerosis typically manifests in patients, usually in women over the age of 40 years with chronic venous insufficiency as a result of chronic hypoxia. Venous hypertension leads to a compromised ability to reduce foot vein pressure during exercise. This change results in increased capillary permeability, with leakage of fibrinogen, with subsequent polymerization leading to formation of fibrin plaques around vessels. There may also be an abnormal regulation of angiogenesis in a patient with lipodermatosclerosis. For example, increased expression of vascular endothelial growth factor receptor 1 (VEGFR-1) can be a result of VEGF-mediated angiogenesis. Another factors may include local stimulation of collagen and obesity [23, 24].

3.1.2 Clinical features

Sclerosis affects the acral parts of the lower limbs symmetrically. The acute and progressive phase of lipodermatosclerosis presents with pain, erythema, and the formation of induration on the affected area of lower limbs. In the chronic phase, sclerosis of the dermis and subcutis is typically present, and sclerosis results in induration that is more sharply demarcated from the adjacent normal skin (**Figure 10**). Other gravity dependent sites such as the lower aspect of the abdominal pannus can also develop lipodermatosclerosis. At this point, the changes are relatively diffuse. Hyperpigmentation due to hemosiderin deposition or chronic ulceration of the lower limbs may also be present [22].

Figure 10.
Lipodermatosclerosis in a patient with chronic venous insufficiency. In this case erythema and sclerotic whitish induration on the medial part of the shank with the border of hemosiderin pigmentary changes are present.

3.1.3 Histopathology

Early lesions show mid-lobular panniculitis, a lymphocytic infiltrate in the septa, variable degrees of capillary congestion, and extravasation of erythrocytes with hemosiderin deposition. Chronic lesions show septal sclerosis and membranocytic change with a marked reduction in inflammation or lymphocytic infiltrate [25, 26].

3.1.4 Differential diagnosis

In differential diagnosis, it is necessary to distinguish inflammatory changes such as cellulitis and erysipelas but also erythema nodosum or erythema induratum. As induration develops and progresses, differentiation from morphea and scleromyxedema may be necessary. In morphea, subcutaneous involvement is predominantly septal, and lipophagic and lipodystrophic changes are not typically present [22, 25].

3.1.5 Treatment

Leg elevation and consistent compression therapy are crucial for the treatment of lipodermatosclerosis. Traditional anti-inflammatory therapies are usually ineffective, but topical or intralesional corticosteroids (e.g., triamcinolone 5–10 mg/cc) may bring relief and improvement with compression therapy [27].

3.2 Injection of vitamin K

Oil-soluble injection of vitamin K may be responsible for the eosinophilic reaction of the deep part of the dermis and subcutaneous fat, which may resemble localized eosinophilic fasciitis with similar clinical manifestation as deep morphea. This inflammation can result in dermal and subcutaneous atrophy [28].

3.3 Vaccination-associated morphea

Circumscribed morphea and deep morphea have been described after intramuscular injections of different types of vaccines. The etiology and antigens responsible for this type of inflammation have not been reliably elucidated [29].

Figure 11.
Morphea-like lesion in a patient after x-irradiation for breast carcinoma. The erythematous and sclerodermic lesion on the right breast.

3.4 Paraffin and silicone injections or silicone implants

The leak of silicone from implants and silicone or paraffin injection after reconstructive or plastic surgery induce chronic inflammation that results in localized morphea-like lesion. The contribution to the induction of SSc, eosinophilic fasciitis, or mixed connective tissue disease has also been discussed [30].

3.5 Porphyrias

Porphyria cutanea tarda can lead to a morphea-like lesion and scarring in the chronic sun (UV)-exposed sites, such as the face, scalp, dorsal part of the hands, and upper part of the chest [31].

3.6 Radiation-induced morphea

X-irradiation can induce sclerotic, chronic erythematous, and secondary pigmented lesions typically in a patient after irradiation of the chest and axillary region for breast carcinoma (**Figure 11**). The morphea-like lesions can start several years after radiation [32].

3.7 Differential diagnosis

The differential diagnosis is summarized in this paragraph, but the most important entity in the differential diagnosis of SSc or localized scleroderma is lichen sclerosus et atrophicus and scleromyxedema. Absence of overall symptoms and organ involvement is crucial [21].

4. Lichen sclerosus

Lichen sclerosus et atrophicus is an inflammatory disease, primarily of the superficial dermis or mucosa, which leads to white scar-like atrophy. Extragenital lichen sclerosus may itch and be cosmetically annoying. Genital lichen sclerosus causes dryness and persistent pruritus. Genital lichen leads to progressive atrophy, and functional impairment, which significantly reduces the quality of life.

4.1 Epidemiology

Prevalence of lichen sclerosus is unknown. This chronic disease occurs at all ages with a similar incidence in all races. The ratio of occurrence in men and women varies considerably, but in both sexes, the most affected area is the anogenital region (about 85% of patients, in women usually as a vulvar disease) [33, 34].

4.2 Pathogenesis

Association with the MHC class II antigen HLA-DQ7 was observed, but the specific genetic predisposition is unknown. Unspecific inflammation seems to be essential for the initiation and also the progression of lichen sclerosus. Autoantibodies such as those against the extracellular matrix protein 1 (ECM-1) were found in 80% of patients with lichen sclerosus. Moreover, in female patients with lichen sclerosus, there is a higher prevalence of autoimmune diseases (especially autoimmune thyroid disease) and ANA positivity than in male patients with lichen sclerosus [34–36].

4.3 Clinical features

Lichen sclerosus manifests by polygonal, bluish-white, shiny, slightly elevated maculopapules with a pointed follicular bounds of hyperkeratoses, which may be solitary or in groups. This skin lesion can be bounded with an area of erythema. The solitary lesion enlarges to plaques and to the scar-like lesion with a rough surface and skin atrophy (**Figure 12**).

More rarely, blistering with possible hemorrhagic content can be present (**Figure 13**). Extragenital predilection sites include supraclavicular localization, under the breasts, cubit, groin, loose wrist, and cross. Symptoms of extragenital lichen sclerosus are dryness and pruritus.

However, lichen sclerosus most frequently affects the anogenital region. In women, it typically affects the vulva and the perianal localization in figure-of-eight configuration (**Figure 14**). Genital lichen sclerosus begins as slightly elevated lesion of erythema, sometimes with erosions. During the chronic stage of the disease, the skin becomes shiny, sclerotic, and also hypopigmented. The scarring may affect the clitoris and labia, and disability may be significant or even make the sexual intercourse impossible. Although the disease may be symptom-free, it frequently causes severe pruritus and pain is a typical symptom. Another symptom may be dysuria or pain upon defecation [34, 37].

Figure 12.
Extragenital lichen sclerosus, slightly elevated plaque with scar-like presentation, with a whitish erythematous rim and skin atrophy.

Figure 13.
Extragenital lichen sclerosus, whitish plaque with blisters and crusts. Blisters resemble hemorrhagic-like content.

Figure 14.
Genital lichen sclerosus affects the labia minora, clitoris, and vulval vestibule. Whitish and erythematous plaques are also present in the labia majora, the perineum, and the perianal region.

4.4 Histopathology

Lichen sclerosus has a specific histopathological pattern. Initially, superficial dermal edema is associated with a band-like lymphocytic infiltrate. The epidermis is thinned and atrophic, with orthohyperkeratosis and vacuolar degeneration of the basal layer. Hyperkeratosis is especially pronounced at follicular openings and may lead to plugging. Vacuolar degeneration of the basal layer and flattening of the rete ridges predispose to the development of blisters, which may become hemorrhagic. The most important changes are found in the superficial dermis with the presence of homogenized collagen (**Figure 15**). Loss of elastic fibers is typical for lichen sclerosus and is not observed in morphea [38–40].

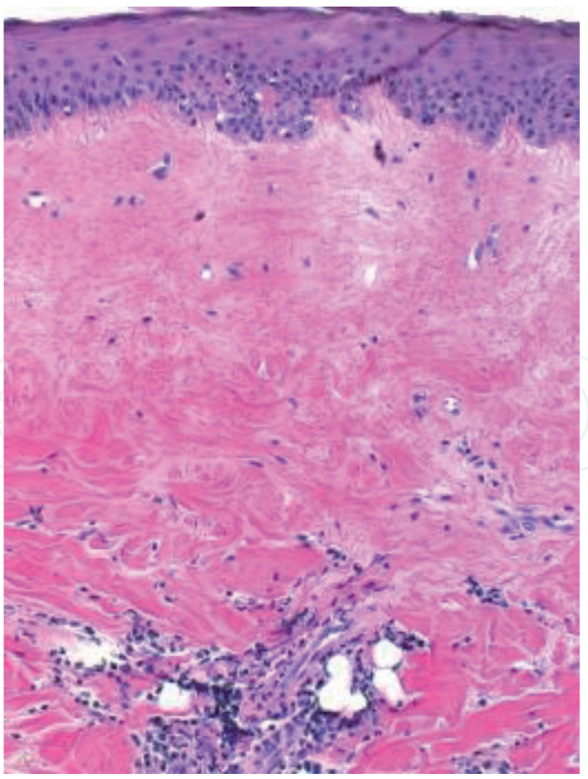

Figure 15.
Skin biopsy of extragenital lichen sclerosus where atrophic thinned epidermis and mild vacuolar degeneration of the basal layer are present. In the superficial dermis, homogenized collagen with perivascular lymphocytic infiltrates can be found.

4.5 Differential diagnosis

The differential diagnosis of extragenital lichen sclerosus includes morphea, vitiligo, tinea versicolor, anetoderma, or cutaneous lymphoma. In the case of genital lichen sclerosus, erosive lichen planus and erythroplasia of Queyrat must be considered.

Sometimes it is not possible to distinguish morphea from lichen because clinical and especially histopathological findings of both diseases can also be present in one patient or one biopsy [34].

4.6 Treatment

Topical medications, phototherapy, and systemic therapy have been used for the treatment of lichen sclerosus. The effect of topical corticosteroids was reported especially in genital lichen sclerosus, but mitigation has also been demonstrated in extragenital lichen. Effect of topical corticosteroid therapy has been reported in randomized treatment and retrospective studies. Phototherapy is preferred second-line treatment for patients with limited disease that cannot be effectively treated with topical corticosteroids. An alternative to topical corticosteroids is the use of calcineurin inhibitors pimecrolimus and tacrolimus despite concerns of possible increase of development of squamous cell carcinoma or reactivation of HPV [15, 37, 41].

The use of systemic therapy is limited to a small group of patients with progressive worsening of extragenital lichen sclerosus that failed to respond to a potent topical corticosteroid and phototherapy. For systemic therapy, methotrexate (15–20 mg/week) and systemic corticosteroids (1 g of intravenous methylprednisolone sodium succinate for 3 consecutive days/month) can be used [42].

5. Eosinophilic fasciitis

Eosinophilic fasciitis is a relatively recently described disease, characterized by fibrosing induration of the extremities and peripheral eosinophilia. In many patients strenuous physical activity precedes the development of this condition.

5.1 Clinical feature

Initial clinical manifestation includes painful edema of the extremities, which progresses to fibrosis and pseudo-inflammatory appearance (**Figure 16**). The manifestation of the disease is typically symmetrical on extremities without involvement of the hands, feet, and face [43].

Laboratory findings include elevation of ESR, hypergammaglobulinemia and peripheral eosinophilia which can be present in the early phase of the disease. ANA titer and complement level are usually normal. Pancytopenia, anemia, thrombocytopenia, myeloproliferative disorders, and monoclonal gammopathy have been reported in association with eosinophilic fasciitis. The diagnosis of eosinophilic fasciitis is established via fascial biopsy and/or by MRI [44].

5.2 Histopathology

Histologically eosinophils and mast cells are present, and dermal fibrosis with patchy infiltrates composed of lymphocytes and plasma cells are also present. In deep biopsy thickening of the fascia is typical, which may be 10–50 times the normal width [44].

5.3 Treatment

Once the diagnosis of eosinophilic fasciitis is established via fascial biopsy and/or MRI, prompt treatment is essential to preserve mobility and function and prevent joint contractures. Prompt therapy with oral corticosteroids (e.g., prednisone 1–2 mg/kg daily) is usually necessary for reduction or cessation of rapid disease progression and as prevention of mobility reduction and development of joint contractures. The response is typically noted within the first few weeks, and clinical improvement may be seen over several months. Alternatively, hydroxychloroquine, cyclosporine, dapsone, methotrexate, PUVA, or infliximab may be used alone or in combination with prednisone. Phototherapy as UVA1 can also be beneficial [45].

Figure 16.
Eosinophilic fasciitis with initial clinical manifestation of progressive fibrotic changes with pseudo-inflammatory appearance.

6. Nephrogenic systemic fibrosis

Nephrogenic systemic fibrosis is most often observed in middle-aged adults but has also been described in children and elderly patients. There is no gender or race predilection. Renal dysfunction and exposure to gadolinium-based contrast medium play a crucial role in the pathogenesis. Although the context use of the gadolinium in a patient with renal dysfunction is irrefutable, the mechanisms of fibrosis are still unknown [46, 47].

6.1 Clinical features

This disorder presents with large and thick, indurated plaques distributed symmetrically on the extremities and trunk. The skin lesions are irregular and erythematous with a tendency to develop hyperpigmentation. The manifestation on the extremities often results in joint contractures. The condition is frequently associated with considerable pain and loss of mobility. Extracutaneous manifestations include yellow scleral plaques and systemic fibrosis with involvement of the heart, lungs, and also skeletal muscles [48, 49].

6.2 Histopathology

A deep biopsy is necessary for diagnosis. Histologic features include increased dermal fibroblast-like cells with positivity for CD34 and procollagen I. Haphazard arrangement of thickened collagen bundles is also present. Furthermore, vascular proliferation and mucin deposition may also be present.

6.3 Treatment

Nephrogenic systemic fibrosis is refractory to treatment with corticosteroids and other immunosuppressive drugs. There have only been case reports of improvement with imatinib, rapamycin, phototherapy UVA1, PUVA, or plasmapheresis. Improvement in renal function after renal transplantation may improve this type of fibrosis [49].

7. Stiff skin syndrome

This dysfunction may be hereditary as a congenital disorder or acquired during early childhood. Familiar hereditary subtype is caused by heterozygosity for a mutation in the gene that encodes fibrillin-1 (FBN1). Dysfunction of this gene results in the production of giant collagen fibrils in the affected fascia [50].

7.1 Clinical features

Stiff skin syndrome is characterized by "rock hard" induration and thickening of the skin and subcutaneous tissues. Typical manifestation is on the buttocks and thighs with mild hypertrichosis without affecting the inguinal folds. This disorder does not affect the hands and feet. The condition is stable or slowly progressive, and abnormalities of internal organs are not typically observed. In differential diagnosis the disease may resemble scleredema, deep morphea, or linear scleroderma [51].

7.2 Histopathology

Histologically, significant thickness of fascia with deposition of hyaline without an associated inflammatory infiltrate can be found. Thickened collagen bundles and mucin deposition may be present in the dermis. The epidermis and papillary dermis are mostly without any pathologies [52].

7.3 Treatment

Treatment of stiff skin syndrome is very difficult, and no effective treatments have been reported. Physical therapy and regimen measures for the patient can help to prevent progressive joint contractures and immobility [51, 52].

8. Scleromyxedema

Scleromyxedema is a chronic idiopathic disorder characterized by papules and lesion of induration with dermal mucin deposition and with an increase of dermal collagen resulting in skin sclerosis. Many patients with scleromyxedema have monoclonal gammopathy, with systemic or lethal manifestations. Scleromyxedema represents a generalized variant that needs to be distinguished from localized lichen myxedematosus (variant without sclerosis and paraproteinemia) [53].

8.1 Pathogenesis

The exact pathogenesis of scleromyxedema is unknown, typically affecting middle-aged adults of both sexes equally. The role of the associated monoclonal gammopathy remains a matter of debate, because, for example, paraprotein levels do not correlate with progression of the disease. But clinical remission of scleromyxedema, during the reduction of paraprotein, that follows after autologous hematopoietic stem cell transplantation was described [53, 54].

8.2 Clinical features

In the clinical manifestation of scleromyxedema, typically widespread and symmetrically firm, waxy, and closely aligned papules are present (**Figure 17**).

Figure 17.
Scleromyxedema. Numerous skin-colored papules of the neck.

Predilection localizations include the head and neck, upper trunk, forearms, and thighs and the proximal parts of fingers. The surrounding skin is shiny with sclerodermoid appearance. Deep longitudinal furrowing is typically involved on the glabella. Strong and rigid infiltrates of the face can result in the face of a lionlike face. As the condition progresses, erythematous and infiltrated plaques may be present with skin stiffening, sclerodactyly, and decreased motility of the mouth and joints.

Scleromyxedema is almost always associated with paraproteinemia. The monoclonal gammopathy is usually IgG and the light chains are more commonly lambda. Patients with scleromyxedema can have a number of internal manifestations, such as dysphagia, proximal muscle weakness due to myositis, peripheral neuropathy, arthropathies, carpal tunnel syndrome, restrictive or obstructive lung disease, and also scleroderma-like renal disease [54].

8.3 Histopathology

Scleromyxedema is characterized by diffuse deposits of mucin in the upper and middle part of the reticular dermis, increase in collagen deposition in the reticular dermis, and significant proliferation of irregularly distributed fibroblasts. Mucin may fill the walls of myocardial blood vessels as well as vessels of the kidney, the pancreas, adrenal glands, nerves, or lymph nodes [55].

8.4 Differential diagnosis

The primary differential diagnosis of scleromyxedema includes systemic sclerosis and scleredema. Other conditions in differential diagnosis with possible presence of mucin in the biopsy include nephrogenic systemic sclerosis. Differential diagnosis of leonine facies includes, for example, lepromatous changes, leishmaniasis, cutaneous lymphoma (T cell, rarely B cell), an actinic reticuloid as chronic actinic dermatitis, systemic amyloidosis, nodular mastocytosis, or sarcoidosis [53].

8.5 Treatment

Recommendations are still based on case reports and open-label small case series. Many chemotherapeutics, primarily melphalan, cyclophosphamide, methotrexate, or chlorambucil, have been tried, with no better results but with the risk of significant side effects. IVIg, alone or in combination with systemic medications such as thalidomide or systemic corticosteroids, may be administered as first-line therapy for cutaneous involvement and also systemic manifestations, including the dermatoneurological syndrome. Additional therapies include PUVA, UVA1, systemic retinoids, cyclosporine, electron beam radiation, plasmapheresis, and extracorporeal photochemotherapy with variable and unpredictable results [56].

9. Scleredema adultorum of Buschke

Scleredema is typically symmetrical diffuse induration and sclerosis of the upper part of the body especially of the trunk due to thickened dermis with mucin deposition and with relationship to diabetes mellitus.

9.1 Pathogenesis

Scleredema is a relatively unusual and rare disease that affects patients of all races. The typical form that is associated with diabetes mellitus is more prevalent in

men, while other forms are seen more commonly in women. Irreversible glycosylation of collagen and resistance to degradation lead to an accumulation of collagen deposition. Furthermore, stimulation by insulin, microvascular changes and damage, and hypoxia during diabetes mellitus may increase the synthesis of collagen and mucin which result in a dermal deposition of collagen [57].

9.2 Clinical features

Scleredema adultorum may be divided into three clinical types of scleredema. The first type affects primarily children and middle-aged women. It is preceded by fever, malaise, and an infection (usually streptococcal) of the upper or lower respiratory tract. The localization of this type is the cervicofacial region with extension to the trunk and proximal upper limbs. The cervicofacial region typically affects the perioral localization with difficult opening of the mouth and hindered swallowing. This type usually resolves spontaneously. The second type shares the same clinical features as the first but with very slow manifestation and is more commonly associated with a monoclonal gammopathy [58].

The third type typically affects obese middle-aged men with insulin-dependent diabetes (scleredema diabeticorum). Sclerosis usually starts very slowly and the involvement is persistent. Affected skin is usually erythematous and indurated with typical localization of the posterior region of the neck and the back (**Figure 18**). The affected skin has peau d'orange appearance. In all three forms, systemic manifestations such as serositis, myositis, dysarthria, dysphagia, parotitis, and ocular and cardiac abnormalities may be present [57–59].

9.3 Histopathology

The main histopathological feature is the thickening of the reticular dermis, with atypical large collagen bundles. Mucin deposition is also present among separated collagen bundles. There is no increase in the number of fibroblasts, but the elastic fibers are significantly reduced in number. Mucin is also accumulated in the skeletal muscle and in the heart.

Figure 18.
Scleredema adultorum with typical localization of the posterior region of the neck and the back with affected erythematous and indurated skin.

9.4 Treatment

Scleredema which is associated with streptococcal infections is self-limited, thus no therapy is needed. Therapy of scleredema associated with diabetes or a monoclonal gammopathy is more difficult, and no specific treatment is available. Phototherapy as UVA1 or PUVA is the first-line therapy. Systemic and intralesional corticosteroids, intralesional hyaluronidase, antibiotics, methotrexate, cyclosporine, pulse therapy with cyclophosphamide plus oral corticosteroids, tamoxifen, and allopurinol have all been tried, with variable results [58, 59].

10. Endocrine disorders

Some endocrine disorders like diabetes mellitus and hypothyroidism can be accompanied with skin induration and sclerotic changes and may thus be a diagnostic problem for both systemic sclerosis and its localized forms. Endocrine disorders include sclerodactyly as "diabetic cheiroarthropathy" and myxedema in hypothyroidism.

10.1 Diabetic cheiroarthropathy

Diabetes mellitus is associated with a wide variety of rheumatologic manifestations which can significantly affect a patient's quality of life. One of these manifestations includes diabetic cheiroarthropathy which is associated with type I diabetes. Diabetic cheiroarthropathy affects typically the hands. It is postulated to result from increased glycosylation of collagen in the skin and is associated with retinopathy, nephropathy, and duration of the diabetes [60, 61].

10.1.1 Clinical features

Clinical features include thickened skin and limited joint mobility of the hands and fingers, leading to flexion contractures and an inability to approximate the palmar surfaces of the hands and fingers. Sometimes ischemic ulceration and calcinosis cutis can be present.

Treatment relies primarily on glycemic control and on nonsteroidal anti-inflammatory drugs and physical therapy with physiotherapy. With improved glycemic control, the symptoms and signs can be ameliorated and complete reversal is possible [61].

10.2 Mucinoses associated with thyroid dysfunction

Pretibial myxedema is characterized by cutaneous induration of the shins due to mucin deposition. It is often associated with hyperthyroidism most commonly due to Graves' disease. Localized myxedema with goiter, exophthalmos, and thyroid acropachy are typical signs of Graves' disease. Pretibial myxedema is found in 1–5% of patients with Graves' disease and in up to 25% of those with exophthalmos [62].

10.2.1 Localized myxedema

10.2.1.1 Clinical features

Localized myxedema presents as erythematous, yellowish or skin-colored waxy induration in a form of a nodulus or plaques. Typical localizations include ventral or

Figure 19.
Pretibial myxedema presents as erythematous waxy induration and nodulus on the ventral part of the shank.

anterolateral parts of the lower legs or the feet (**Figure 19**). In early phases localized myxedema can also present as a diffuse non-pitting edema of the shins or feet that evolves into lymphedema. Even more rarely, localized myxedema affects the face, shoulders, upper extremities, the lower abdomen, scars, or donor graft sites. Large plaques are often painful and pruritic. When present, hypertrichosis and hyperhidrosis are confined to the pretibial myxedematous skin [63, 64].

10.2.1.2 Treatment

First-line therapy such as topical corticosteroids or their application under occlusive dressings can be used. In some cases intralesional injection of corticosteroids can be effective. In a patient with lymphedema, medical treatments including IVIg, rituximab, plasmapheresis, and their combination with surgical treatment may have some benefit [63, 65].

10.2.2 Generalized myxedema

Generalized myxedema is a manifestation of hypothyroidism where mucin is deposited in the dermis, leading to waxiness of the skin. This condition is caused by a quantitative or functional deficiency of thyroxine. Impaired degradation of mucin and/or increased synthesis is suggested as the main cause.

10.2.2.1 Clinical features

The typical skin is pale, cool, waxy, and dry. Anhidrosis as an absence of sweating may lead to ichthyosis or eczema "craquelé." Hair and nails are dry and diffuse

non-scaring alopecia is also common. A yellowish hyperkeratosis of the palms may be present. Sometimes purpura on the extremities and skin xanthomas may be observed [66].

10.2.2.2 Treatment

Early treatment of hypothyroidism is crucial for reduction or cessation of skin involvement and overall symptoms of the disease.

11. Amyloidosis

The cutaneous amyloidosis represents a heterogeneous group of conditions in which amyloid, as a fibrillar material that can result from the pathological degradation of various proteins, is deposited in the skin. In primary cutaneous amyloidosis, the deposits are derived from keratin (macular, lichen, biphasic) or immunoglobulin light chains (nodular) [67].

The specific cutaneous lesions of primary systemic amyloidosis are waxy, translucent, or purpuric papules, nodules, and plaques. Amyloid infiltration of the skin may produce thickening and stiffness. Typical localization may be on the limbs but sometimes also on the trunk. This is characteristic of AL amyloid, due to a plasma cell disorder in hematological malignancies. Primary systemic amyloidosis is due to a plasma cell dyscrasia, while secondary systemic amyloidosis arises from chronic inflammatory conditions such as rheumatoid arthritis or in the setting of chronic infections [67, 68].

Skin biopsy reveals accumulation of amyloid with characteristic staining (Congo red) properties under polarizing microscopic examination. Immunofixation of serum or urine is necessary for unambiguous identification of a monoclonal component [69].

Treatment of all forms of amyloidosis is challenging; although the primary cutaneous forms are not life-threatening, primary systemic amyloidosis can carry a poor prognosis for a patient [70].

12. Conclusion

Systemic sclerosis mimics include a variety of diseases that may resemble systemic connective tissue diseases such as SSc. Above all, the most common diseases are discussed in this chapter.

The basis of proper diagnosis and treatment is the interdisciplinary collaboration of rheumatology and dermatology with the possibility of biopsy tissue collection and histological verification of the disease.

A carefully performed clinical history and physical examination may distinguish these scleroderma mimic syndromes from systemic sclerosis (SSc, scleroderma) and from each other. The distribution and the quality/texture of skin involvement (in SSc typically: sclerodactyly, puffy fingers, ischemic defects/pitting scars/digital ulcers/gangrenes, telangiectasias, calcinosis), the presence of Raynaud's phenomenon (typically signs of a secondary Raynaud's phenomenon such as onset after the age of 40, asymmetry, thumb involvement, ischemic pain, history of symptoms <3 years, worsening attacks) or abnormal nail fold capillary microscopy (characteristic scleroderma patterns in SSc), the presence and type of associated systemic manifestations (typical organ involvement characteristic for SSc), and the association with particular concurrent diseases or specific laboratory parameters (SSc-specific autoantibodies such as anti-topoisomerase I, anti-centromere, anti-RNA-polymerase III) can be of substantial help in refining the diagnosis.

In some cases, a full-thickness skin biopsy is helpful to confirm the clinical suspicion. Effective therapies are available for some of these conditions, whereas others are more refractory. For this reason, a prompt diagnosis is important to guide treatment decisions wisely, to spare the patients from ineffective treatments, to facilitate appropriate diagnostic evaluations, and to allow for accurate determination of prognosis [71].

Acknowledgements

This chapter was supported by NV18-01-00161 A, MHCR 023728 and GAUK 312218.

Author details

Ondřej Kodet[1,2,3]* and Sabína Oreská[4]

1 Department of Dermatology and Venereology, First Faculty of Medicine, Charles University, Prague, Czech Republic

2 Institute of Anatomy, First Faculty of Medicine, Charles University, Prague, Czech Republic

3 BIOCEV, First Faculty of Medicine, Charles University, Vestec, Czech Republic

4 Institute of Rheumatology, Department of Rheumatology, First Faculty of Medicine, Charles University, Prague, Czech Republic

*Address all correspondence to: ondrej.kodet@vfn.cz

IntechOpen

© 2019 The Author(s). Licensee IntechOpen. This chapter is distributed under the terms of the Creative Commons Attribution License (http://creativecommons.org/licenses/by/3.0), which permits unrestricted use, distribution, and reproduction in any medium, provided the original work is properly cited.

References

[1] Sehgal VN, Srivastava G, Aggarwal AK, Behl PN, Choudhary M, Bajaj P. Localized scleroderma/morphea. International Journal of Dermatology. 2002;**41**(8):467-475

[2] Gabrielli A, Avvedimento EV, Krieg T. Scleroderma. The New England Journal of Medicine. 2009;**360**(19):1989-2003

[3] Fett N, Werth VP. Update on morphea: Part I. Epidemiology, clinical presentation, and pathogenesis. Journal of the American Academy of Dermatology. 2011;**64**(2):217-228; quiz 29-30

[4] Peterson LS, Nelson AM, Su WP, Mason T, O'Fallon WM, Gabriel SE. The epidemiology of morphea (localized scleroderma) in Olmsted County 1960-1993. The Journal of Rheumatology. 1997;**24**(1):73-80

[5] Badea I, Taylor M, Rosenberg A, Foldvari M. Pathogenesis and therapeutic approaches for improved topical treatment in localized scleroderma and systemic sclerosis. Rheumatology (Oxford, England). 2009;**48**(3):213-221

[6] Yamane K, Ihn H, Kubo M, Yazawa N, Kikuchi K, Soma Y, et al. Increased serum levels of soluble vascular cell adhesion molecule 1 and E-selectin in patients with localized scleroderma. Journal of the American Academy of Dermatology. 2000;**42**(1 Pt 1):64-69

[7] Weibel L, Harper JI. Linear morphoea follows Blaschko's lines. The British Journal of Dermatology. 2008;**159**(1):175-181

[8] Niklander S, Marin C, Martinez R, Esguep A. Morphea "en coup de sabre": An unusual oral presentation. Journal of Clinical and Experimental Dentistry. 2017;**9**(2):e315-e3e8

[9] Tollefson MM, Witman PM. En coup de sabre morphea and Parry-Romberg syndrome: A retrospective review of 54 patients. Journal of the American Academy of Dermatology. 2007;**56**(2):257-263

[10] Sato T, Goto M, Takeo N, Hatano Y. Case of generalized morphea with the manifestation of diffuse systemic cutaneous sclerosis without sclerodactyly. The Journal of Dermatology. 2018;**45**(5):e100-e1e1

[11] Adamska U, Slinko A, Bialecka A, Mecinska-Jundzill K, Adamski P, Czajkowski R. Unilateral generalized morphea: A case report and literature review. Postępy dermatologii i alergologii. 2018;**35**(4):425-428

[12] Cantisani C, Miraglia E, Richetta AG, Mattozzi C, Calvieri S. Generalized morphea successfully treated with tacrolimus 0.1% ointment. Journal of Drugs in Dermatology. 2013;**12**(1):14-15

[13] Marzano AV, Menni S, Parodi A, Borghi A, Fuligni A, Fabbri P, et al. Localized scleroderma in adults and children. Clinical and laboratory investigations on 239 cases. European Journal of Dermatology. 2003;**13**(2):171-176

[14] Walker D, Susa JS, Currimbhoy S, Jacobe H. Histopathological changes in morphea and their clinical correlates: Results from the Morphea in Adults and Children Cohort V. Journal of the American Academy of Dermatology. 2017;**76**(6):1124-1130

[15] Zwischenberger BA, Jacobe HT. A systematic review of morphea treatments and therapeutic algorithm. Journal of the American Academy of Dermatology. 2011;**65**(5):925-941

[16] Stefanaki C, Stefanaki K, Kontochristopoulos G, Antoniou C, Stratigos A, Nicolaidou E, et al. Topical tacrolimus 0.1% ointment in the treatment of localized scleroderma. An open label clinical and histological study. The Journal of Dermatology. 2008;**35**(11):712-718

[17] Caca-Biljanovska NG, Vlckova-Laskoska MT, Dervendi DV, Pesic NP, Laskoski DS. Treatment of generalized morphea with oral 1,25-dihydroxyvitamin D3. Advances in Experimental Medicine and Biology. 1999;**455**:299-304

[18] Dytoc M, Wat H, Cheung-Lee M, Sawyer D, Ackerman T, Fiorillo L. Evaluation of the efficacy and safety of topical imiquimod 5% for plaque-type morphea: A multicenter, prospective, vehicle-controlled trial. Journal of Cutaneous Medicine and Surgery. 2015;**19**(2):132-139

[19] Kroft EB, Berkhof NJ, van de Kerkhof PC, Gerritsen RM, de Jong EM. Ultraviolet A phototherapy for sclerotic skin diseases: A systematic review. Journal of the American Academy of Dermatology. 2008;**59**(6):1017-1030

[20] Kreuter A, Gambichler T, Breuckmann F, Rotterdam S, Freitag M, Stuecker M, et al. Pulsed high-dose corticosteroids combined with low-dose methotrexate in severe localized scleroderma. Archives of Dermatology. 2005;**141**(7):847-852

[21] Ferreli C, Gasparini G, Parodi A, Cozzani E, Rongioletti F, Atzori L. Cutaneous manifestations of scleroderma and scleroderma-like disorders: A comprehensive review. Clinical Reviews in Allergy and Immunology. 2017;**53**(3):306-336

[22] Kirsner RS, Pardes JB, Eaglstein WH, Falanga V. The clinical spectrum of lipodermatosclerosis. Journal of the American Academy of Dermatology. 1993;**28**(4):623-627

[23] Stacey MC, Burnand KG, Bhogal BS, Black MM. Pericapillary fibrin deposits and skin hypoxia precede the changes of lipodermatosclerosis in limbs at increased risk of developing a venous ulcer. Cardiovascular Surgery. 2000;**8**(5):372-380

[24] Herouy Y, Kreis S, Mueller T, Duerk T, Martiny-Baron G, Reusch P, et al. Inhibition of angiogenesis in lipodermatosclerosis: Implication for venous ulcer formation. International Journal of Molecular Medicine. 2009;**24**(5):645-651

[25] Huang TM, Lee JY. Lipodermatosclerosis: A clinicopathologic study of 17 cases and differential diagnosis from erythema nodosum. Journal of Cutaneous Pathology. 2009;**36**(4):453-460

[26] Choonhakarn C, Chaowattanapanit S, Julanon N. Lipodermatosclerosis: A clinicopathologic correlation. International Journal of Dermatology. 2016;**55**(3):303-308

[27] Suehiro K, Morikage N, Harada T, Samura M, Nagase T, Mizoguchi T, et al. Compression therapy using bandages successfully manages acute or subacute lipodermatosclerosis. Annals of Vascular Diseases. 2019;**12**(1):77-79

[28] Bourrat E, Moraillon I, Vignon-Pennamen MD, Fraitag S, Cavelier-Balloy B, Cordoliani F, et al. Scleroderma-like patch on the thigh in infants after vitamin K injection at birth: Six observations. Annales de Dermatologie et de Vénéréologie. 1996;**123**(10):634-638

[29] Torrelo A, Suarez J, Colmenero I, Azorin D, Perera A, Zambrano A. Deep morphea after vaccination in two

young children. Pediatric Dermatology. 2006;**23**(5):484-487

[30] Slimani S, Ben Ammar A, Ladjouze-Rezig A. Connective tissue diseases after heavy exposure to silica: A report of nine cases in stonemasons. Clinical Rheumatology. 2010;**29**(5):531-533

[31] Zemtsov R, Zemtsov A. Porphyria cutanea tarda presenting as scleroderma. Cutis. 2010;**85**(4):203-205

[32] Partl R, Regitnig P, Tauber G, Potscher M, Bjelic-Radisic V, Kapp KS. Radiation-induced morphea-a rare but severe late effect of adjuvant breast irradiation: Case report and review of the literature. Strahlentherapie und Onkologie. 2018;**194**(11):1060-1065

[33] Perez-Lopez FR, Vieira-Baptista P. Lichen sclerosus in women: A review. Climacteric. 2017;**20**(4):339-347

[34] Dalziel K, Shaw S. Lichen sclerosus. BMJ. 2010;**340**:c731

[35] Kreuter A, Wischnewski J, Terras S, Altmeyer P, Stucker M, Gambichler T. Coexistence of lichen sclerosus and morphea: A retrospective analysis of 472 patients with localized scleroderma from a German tertiary referral center. Journal of the American Academy of Dermatology. 2012;**67**(6):1157-1162

[36] Oyama N, Chan I, Neill SM, Hamada T, South AP, Wessagowit V, et al. Autoantibodies to extracellular matrix protein 1 in lichen sclerosus. Lancet. 2003;**362**(9378):118-123

[37] Bunker CB. EDF lichen sclerosus guideline. Journal of the European Academy of Dermatology and Venereology. 2017;**31**(2):e97-ee8

[38] Wang JB, Yan H, Yang HY, Si JY, Jia LP, Li K, et al. Histopathological and ultrastructural changes of lichen sclerosus et atrophicus on the vulva. Chinese Medical Journal. 1991;**104**(10):868-871

[39] Staricco RG. Lichen striatus: A study of fifteen new cases with special emphasis on the histopathological changes and a review of the literature. A.M.A. Archives of Dermatology. 1959;**79**(3):311-324

[40] Singh L, Sengar M, Goyal S, Mansi M, Khurana N, Mohta A. Childhood phimosis secondary to lichen sclerosus: Is there a spatial pattern of histopathological changes? The American Journal of Dermatopathology. 2018;**40**(11):824-828

[41] Kai A, Lewis F. Long-term use of an ultrapotent topical steroid for the treatment of vulval lichen sclerosus is safe. Journal of Obstetrics and Gynaecology. 2016;**36**(2):276-277

[42] van der Avoort IA, Tiemes DE, van Rossum MM, van der Vleuten CJ, Massuger LF, de Hullu JA. Lichen sclerosus: Treatment and follow-up at the departments of gynaecology and dermatology. Journal of Lower Genital Tract Disease. 2010;**14**(2):118-123

[43] Lakhanpal S, Ginsburg WW, Michet CJ, Doyle JA, Moore SB. Eosinophilic fasciitis: Clinical spectrum and therapeutic response in 52 cases. Seminars in Arthritis and Rheumatism. 1988;**17**(4):221-231

[44] Onajin O, Wieland CN, Peters MS, Lohse CM, Lehman JS. Clinicopathologic and immunophenotypic features of eosinophilic fasciitis and morphea profunda: A comparative study of 27 cases. Journal of the American Academy of Dermatology. 2018;**78**(1):121-128

[45] Mazori DR, Femia AN, Vleugels RA. Eosinophilic fasciitis: An updated review on diagnosis and

treatment. Current Rheumatology Reports. 2017;**19**(12):74

[46] Smorodinsky E, Ansdell DS, Foster ZW, Mazhar SM, Cruite I, Wolfson T, et al. Risk of nephrogenic systemic fibrosis is low in patients with chronic liver disease exposed to gadolinium-based contrast agents. Journal of Magnetic Resonance Imaging. 2015;**41**(5):1259-1267

[47] Bruce R, Wentland AL, Haemel AK, Garrett RW, Sadowski DR, Djamali A, et al. Incidence of nephrogenic systemic fibrosis using gadobenate dimeglumine in 1423 patients with renal insufficiency compared with gadodiamide. Investigative Radiology. 2016;**51**(11):701-705

[48] Thomsen HS. Nephrogenic systemic fibrosis: A serious adverse reaction to gadolinium—1997-2006-2016. Part 1. Acta Radiologica. 2016;**57**(5):515-520

[49] Thomsen HS. Nephrogenic systemic fibrosis: A serious adverse reaction to gadolinium—1997-2006-2016. Part 2. Acta Radiologica. 2016;**57**(6):643-648

[50] Deng X, Chen F, Song Z, Yan H, You Y, Zhong B, et al. Four new cases of stiff skin syndrome with unusual presentations. Journal of the European Academy of Dermatology and Venereology. 2016;**30**(1):163-165

[51] Geng S, Lei X, Toyohara JP, Zhan P, Wang J, Tan S. Stiff skin syndrome. Journal of the European Academy of Dermatology and Venereology. 2006;**20**(6):729-732

[52] Guiducci S, Distler JH, Milia AF, Miniati I, Rogai V, Manetti M, et al. Stiff skin syndrome: Evidence for an inflammation-independent fibrosis? Rheumatology (Oxford, England). 2009;**48**(7):849-852

[53] Aoki M, Matsushita S, Kawai K, Kanekura T. Scleromyxedema clinically resembling to scleroderma. Indian Journal of Dermatology. 2016;**61**(1):127

[54] Nofal A, Amer H, Nofal E. Scleromyxedema without paraproteinemia. International Journal of Dermatology. 2016;**55**(7):e418-e419

[55] Rongioletti F, Rebora A. Cutaneous mucinoses: Microscopic criteria for diagnosis. The American Journal of Dermatopathology. 2001;**23**(3):257-267

[56] Saniee S, Davarnia G. Scleromyxedema without paraproteinemia: Treatment with thalidomide and prednisolone. Case Reports in Dermatology. 2016;**8**(3):327-332

[57] Meguerditchian C, Jacquet P, Beliard S, Benderitter T, Valero R, Carsuzza F, et al. Scleredema adultorum of Buschke: An under recognized skin complication of diabetes. Diabetes & Metabolism. 2006;**32**(5 Pt 1):481-484

[58] Kreuter A. Scleredema adultorum: Clinical presentation, diagnostic workup, differential diagnosis, treatment option. Hautarzt. 2018;**69**(11):908-915

[59] Cohn BA, Wheeler CE Jr, Briggaman RA. Scleredema adultorum of Buschke and diabetes mellitus. Archives of Dermatology. 1970;**101**(1):27-35

[60] Cherqaoui R, McKenzie S, Nunlee-Bland G. Diabetic cheiroarthropathy: A case report and review of the literature. Case Reports in Endocrinology. 2013;**2013**:257028

[61] Hider SL, Roy DK, Augustine T, Parrott N, Bruce IN. Resolution of diabetic cheiroarthropathy after pancreatic transplantation. Diabetes Care. 2004;**27**(9):2279-2280

[62] Fatourechi V. Thyroid dermopathy and acropachy. Best Practice &

Research. Clinical Endocrinology & Metabolism. 2012;**26**(4):553-565

[63] Brinster NK, Garrett AB, Kostopoulos TC. Localized myxedema of thyroid disease. Journal of the American Academy of Dermatology. 2013;**68**(6):e189-e190

[64] Katsambas A, Pantazi V, Giannakopoulou H, Potouridou I. Localized myxedema in Grave's disease confined to the toes. International Journal of Dermatology. 2000;**39**(12):953-954

[65] Dhaille F, Dadban A, Meziane L, Fessier C, Colta L, Lok C, et al. Elephantiasic pretibial myxoedema with upper-limb involvement, treated with low-dose intravenous immunoglobulins. Clinical and Experimental Dermatology. 2012;**37**(3):307-308

[66] Burman KD, McKinley-Grant L. Dermatologic aspects of thyroid disease. Clinics in Dermatology. 2006;**24**(4):247-255

[67] Palladini G, Merlini G. Systemic amyloidoses: What an internist should know. European Journal of Internal Medicine. 2013;**24**(8):729-739

[68] Schreml S, Szeimies RM, Vogt T, Landthaler M, Schroeder J, Babilas P. Cutaneous amyloidoses and systemic amyloidoses with cutaneous involvement. European Journal of Dermatology. 2010;**20**(2):152-160

[69] Nilsson KP, Ikenberg K, Aslund A, Fransson S, Konradsson P, Rocken C, et al. Structural typing of systemic amyloidoses by luminescent-conjugated polymer spectroscopy. The American Journal of Pathology. 2010;**176**(2):563-574

[70] Dember LM. Emerging treatment approaches for the systemic amyloidoses. Kidney International. 2005;**68**(3):1377-1390

[71] Varga J, Denton C, Wigley F, Allanore Y, Kuwana M. Scleroderma. 2nd ed. Cham: Springer International Publishing; 2017