

We are IntechOpen, the world's leading publisher of Open Access books Built by scientists, for scientists

6,900

Open access books available

185,000

International authors and editors

200M

Downloads

Our authors are among the

154

Countries delivered to

TOP 1%

most cited scientists

12.2%

Contributors from top 500 universities



WEB OF SCIENCE™

Selection of our books indexed in the Book Citation Index
in Web of Science™ Core Collection (BKCI)

Interested in publishing with us?
Contact book.department@intechopen.com

Numbers displayed above are based on latest data collected.
For more information visit www.intechopen.com



Stents in Gastrointestinal Diseases

*Eduardo Aimore Bonin, Bruno Verschoor,
Fernanda Hoffmann Silva, Kelly Cristina Vieira
and Susan Kakitani Takata*

Abstract

Stent is a medical device originally designed for recanalization and/or sealing of any obstructing or leaking lesion. In gastroenterology, it has a major role in recanalization of gastrointestinal (GI) tumors and postoperative leak sealing. Among several materials and models used in stent manufacturing, self-expandable metallic stents (SEMS) are the most common used stents. Over the years, SEMS has evolved into a standard of care medical device in several oncological conditions, such as advanced esophageal cancer. Other potential applications are drug-eluting devices, scar tissue modeling for benign conditions, and GI tract drainage/anastomosis. The aim of this chapter is to review the most common GI stent models and its indications in gastrointestinal diseases.

Keywords: stent, gastroenterology, endoscopy

1. Introduction

Stent is an artificial tube graft defined as “a short narrow metal or plastic tube often in the form of a mesh that is inserted into the lumen of an anatomical vessel (such as an artery or a bile duct) especially to keep a previously blocked passageway open” [1]. Stenting is a medical procedure for placing a stent. It should be differentiated from shunting, when a tube conduit is used for allowing flow between two previous unconnected structures. Splint refers to a rod- or a cast-like shell device placed outside any desired organ to make it stable. An **endoprosthesis** refers to a stent inserted into the lumen (endoluminal), which can be inside the gastrointestinal (GI) visceral tract (esophagus, stomach, duodenum, intestinal, colorectal), or into a blood or biliary vessel (endovascular or endobiliary, respectively).

The term stent is an eponym of a British dentist, Charles T. Stent (1807–1885), who developed a compound originally used for dental impressions [2]. He developed a formula made of gutta-percha, a natural latex produced from tropical trees native to Southeast Asia and Northern Australia. The etymological origin of “stent” as a term in surgery started with Dr. Johannes F. Esser in 1917, which used Stent’s dental compound as a mold for bridging skin grafts [2]. The term stent became popular among surgeons for such applications and was then later used to define any surgical mold for bridging tissues until a healing process has taken place, as in 1954, when a polyethylene tube was described by Drs. Remine and Grindlay as “to act as a stent for the anastomosis” in experimental biliary surgery [2].

In gastroenterology, **gastrointestinal stents** have been originally used to treat obstructed cancer in the GI tract. From early modern medicine in the nineteenth century until nowadays, GI tract cancer or luminal palliation has always been a huge challenge for surgeons and physicians. In esophageal cancer, for example, nonsurgical attempts to relieve dysphagia and starvation from the early to mid-1800s were esophageal dilatation or placement of an esophageal gumlike, rubber-made tube. The esophageal tube was passed through the mouth or nose across the tumor, acting as a feeding tube, with no effect on dysphagia [3]. These early esophageal tubes ultimately gave place to flexible polyethylene or silicone nasogastric feeding tubes used today. It was a matter of time for physicians to come out with a solution involving an artificial tube that could fit across the tumor and relieve dysphagia. **The first successful esophageal stenting procedure** has been credited to Sir Charters James Symonds in 1885 [4], who developed an esophageal semirigid tube with a funnel attached to a silk suture to treat malignant esophageal tumors. This tube was orally and blindly inserted, and the suture was brought out from the mouth and attached to the patient's ear. Later in the 1920s–1930s, a stent introducer over a guide-wire technique was developed to increase safety and facilitate stent insertion. After further technical developments with the aid of a flexible endoscope, several materials were used to increase softness. Gumlike or black rubber tubes gave place to tubes made of latex or silicone (the Celestin or Atkinson esophageal tube) or also polyvinyl, which all became popular in the 1960s–1980s [5]. Although being the best palliation measure at that time, avoiding surgery, these tubes were associated to high-risk complications, such as esophageal perforation. As they were semirigid, their passage through a narrow friable lumen required prior dilatation. To overcome this problem, a self-expandable tube would be the solution. **The first self-expandable metal stent (SEMS) models** were stainless steel coil springs [5]. Their design was similar to endovascular stent models produced in the 1980s. For being developed for gastrointestinal (GI) tract use, they were inserted orally using an introducer and a fixation thread to tie them down into a compressed shape around an introducer or a gastroscope. Once positioned across the tumor, the stent was released to expand to its original shape using a novel feature that is producing significantly more radial force expansion instead of mostly axial. These stents became popular compared to their rigid plastic stent counterparts, especially after a first randomized study favoring SEMS over semirigid plastic stents for esophageal cancer [6]. Although being more expensive, they resulted in a higher cost-effectiveness due to their lower complication rates, lower hospitalization rate, and lower mortality. These stents gained significant improvement in design over time: a mesh-like stent to increase flexibility, while retaining a good radial expansion, a longer body, and a proximal flare at its end to prevent migration, and a synthetic covering film to prevent tumor ingrowth.

The third-generation SEMS were made of nitinol (an acronym for nickel titanium Naval Ordnance Laboratories) [5], a so-called memory-shape alloy; once deformed it returns to its pre-deformed shape when heated. This results in a more flexible stent that can fit into a reduced caliber introducer/delivery system. Their first models had a higher foreshortening (25–40%) and a lower radial expansion compared to prior stainless steel models. As they gained later refinements in stent design and metal alloy, these stents are capable of being passed through a working channel of an endoscope to reach deeper parts of the gastrointestinal tract, reaching, for example, the proximal biliary tree, pancreatic duct, and proximal colon. Apart from other models made of self-expandable plastic or biodegradable material, nowadays SEMS remains the standard of care in most gastrointestinal stent applications.

2. Stent types

There are several different gastrointestinal stent shapes and materials (Figure 1), and there is no ideal stent type to date to fit all expectations.

Each distinguished shape and material have several physical properties, which enable a distinct function, ultimately influencing clinical outcome and stent choice (Figure 2) [7].

A **laser-cut stent** is a seamless metal tube (i.e., nitinol) being cut into several mesh stent patterns, which differs from a **handmade woven, wire-braided or**




Figure 1.
A typical self-expandable metal stent. One is an uncovered colonic enteral stent (a) and another is a partially covered (silicone covering) esophageal stent (b). Its proximal flange has a larger caliber than its body, to ensure anchoring and prevent migration. Also, a curved wire flange instead of sharp struts is designed to prevent stent piercing into tissue. Picture from Eduardo A. Bonin.




Figure 2.
Self-expandable stents, one totally made of plastic (silicone) (a), no longer commercially available for the gastrointestinal tract. The other is a multi-wire braided-type metal (nitinol), uncovered stent (b). Note the “kinking effect” of the plastic stent when compressed (a), where the metal stent remains patent, with some foreshortening. Picture from Eduardo A. Bonin.

knitted stent configuration (**Figure 2**). A laser-cut stent has higher radial force and a lower foreshortening property, thus being more predictable when deployed. This can be useful in a straight narrow short lumen such as the biliary tree, a coronary vessel, or the bronchial tree [8]. They also have a higher radial force and higher longitudinal force. For some laser-cut stents with pointed struts at its distal end, longitudinal force might induce tissue reaction from direct piercing [8]. Wire-braided or knitted stents are more flexible and have a greater conformability (less “kinking effect”) when deployed (**Figure 2**). They also allow placing another stent across its mesh, as required in some specific anatomic structures such as the biliary tree.

The most common stent types used in gastroenterology are made of semi-rigid, plastic tubes (polyethylene) or SEMS (nitinol or stainless steel mesh). **Semirigid plastic tube stents** are currently being used exclusively in the biliary tree and the pancreas [9]. They are commonly made of polyethylene, a softer plastic with a better molding capability compared to polyurethane. They remain a first-line and cost-effective method compared to fully covered SEMS in most biliopancreatic benign conditions (biliary stricture, fistula) with a lower migration rate, however having higher occlusion rates. Fully covered SEMS are currently being investigated for refractory benign biliary strictures (**Table 5**). Semirigid, plastic tubes are no longer used in the gastrointestinal tract (esophagus, stomach, or colorectal).

A typical **SEMS** design has a cylinder-shape body part, which is used to cover or seal the desired area, and a flare (funnel-like shape) at one or both extremities (**Figure 1**). Self-expandable plastic stents (SEPS) are another version of SEMS in terms of material used. SEMS can be found as uncovered or partially and totally covered using a synthetic covering film such as polyethylene or silicone (**Figure 1**).

Biodegradable stents and drug-eluting stents are other models under investigation. **Biodegradable stents** are made of biodegradable material (i.e., polyesters, polycarbonates, bacterial-derived polymers, and corrodible metals), mostly used in coronary artery disease. In gastroenterology, these stents are particularly useful in benign conditions, where a metallic stent would be incorporated to tissue over time, becoming very difficult to remove once achieving a stable luminal patency. Several models have been tested in clinical trials, and none has proved a consistent clinical result in terms of luminal patency. **Drug-eluting stents** are capable of maintaining patency not only from radial expansion but also from drug delivery directly to tissue, reducing its occlusion rates. These stents are very popular in cardiology, where they are superior to traditional bare stents to prevent coronary artery re-occlusion from endothelial intimal proliferation. In gastroenterology, they have been used in malignant disease to prevent tumor ingrowth and overgrowth. Despite the use of covered SEMS, its synthetic covering membrane is destroyed over time by hydrolysis and oxidation from gastrointestinal contents. Chemotherapeutic antitumoral agents, such as paclitaxel, have been initially tested with no proven benefit over the standard fully covered SEMS. For hydrophilic agents such as gemcitabine, a slow-release surface-stabilizing substance pullulan acetate has been added to increase optimal local drug release. Five-fluorouracil (5-FU) has also been tested as an antiproliferative agent for local tumor control in esophageal and biliopancreatic cancer [10]. Although promising, most of these stents are still in the experimental field, with scarce clinical experience. One major concern about these stents is local drug delivery causing injury to adjacent tissue and distant organ toxicity due to systemic exposure. Setting an appropriate drug concentration and release will enable an optimal local drug distribution to reach the desired effect.

3. A typical SEMS placement procedure in the gastrointestinal tract

A gastrointestinal stenting procedure usually requires the aid of an endoscope under radiological (fluoroscopy) guidance or at least one of these techniques. The procedure can be performed even in high-risk patients, with or without general anesthesia. Stent placement requires a special training and is reserved for interventional radiologists or interventional endoscopy gastroenterologists or surgeons. For SEMS placement there is an introducer system, in which the stent is compressed against a guiding catheter using an outer catheter sheath (**Figure 3**) or a thread suture (older models).

The procedure always requires a guide wire, with stiffness enough to avoid kinking, especially for passing a bulky fully covered large SEMS. For such stents a dilation procedure may be required using the smallest caliber dilation possible to avoid perforation. Fortunately, introducer systems are becoming thinner over time to facilitate insertion. Those are commonly used for intestinal and biliary stents. The stent and introducer system (**Figure 3**) is advanced over the guide wire and placed across the desired area. The stent is then deployed pulling back the outer catheter sheath (or advancing the outer catheter sheath, for a few models), under endoscopic or radiological guidance. The over-the-wire (OTW) technique refers to placing a stent over a guide wire having an endoscope alongside to ensure proper placement, with or without radiological guidance. The through-the-scope (TTS) technique refers to placing the stent over a guide wire using the working channel of an endoscope (**Figure 3**). Alternatively, one may compress the stent over an endoscope using sutures and release it at difficult-to-reach proximal portions of the gastrointestinal tract (over-the-scope technique) [11]. Technical issues can be related to a poor preclinical evaluation, lack of patient information consent, wrong stent choice, and lack of accessories/logistics [12].




Figure 3. A typical catheter-based self-expandable metal stent (SEMS) delivery system. The outer catheter has been pulled back to open the stent (white arrow). This can be done under radiological or endoscopic guidance. Note the SEMS being partially deployed (yellow arrow). The blue arrow depicts the proximal part of the delivery system, which is facing the distal flange of the SEMS (for duodenal and esophageal models). Note some foreshortening of the SEMS while being deployed (distance between the yellow and blue arrows). For biliary and colonic stents, the proximal flange is facing the proximal part of the catheter delivery system. Picture from Eduardo A. Bonin.

4. Stent-related issues

Nowadays, a huge effort in stent design is to overcome the most common stent-related issues: migration, stent-related perforation, and stent occlusion.

Anchoring measures to prevent stent migration: the most popular anchoring measure is having a flange at its proximal end to anchor it against a more elastic, healthy GI tract wall proximal to the tumor. Using a barbed proximal end, similar as found in plastic tube stents, has the same principle. An **uncovered stent** (Figure 1) has a lower migration rate compared to a covered stent because it becomes fixed and embedded to tissue over time due to pressure necrosis. However, this poses a special problem for removing it, which is required in benign conditions. **Partially covered stents** (Figure 1) are stents covered only at the body of the stent, leaving its proximal end to embed into tissue. They are very popular for malignant esophageal and biliopancreatic cancer, but again, there is a problem in removing the stent when used in benign conditions. Other measures are stent fixation using an endoscopic clip (Figure 5) or using an endoscopic suturing device [13] or passing a temporary suture thread at its proximal end, coming out from a nostril and fixated at the ear (Figure 4). A double-layer stent (a fully covered stent with an outer uncovered mesh layer) has also been proposed (Figure 4). Lumen-apposing stents are fully covered SEMS with a larger flange that allows transluminal drainage procedures (Figure 8).

Stent-related perforation occurs due to gastrointestinal wall pressure necrosis due to stent compression, usually occurring at the stent's distal end. Perforation can be devastating and is more likely to occur when there is more angulation (surgically altered anatomy or the colon). More flexible and longer stents are less likely to have this issue, having in mind to avoid placing a short and/or more rigid or self-expandable plastic stent at any sharp angulation.

Stent occlusion may occur from tumor ingrowth or overgrowth and/or accumulation of debris and bacterial biofilm deposit. Tumor overgrowth corresponds to

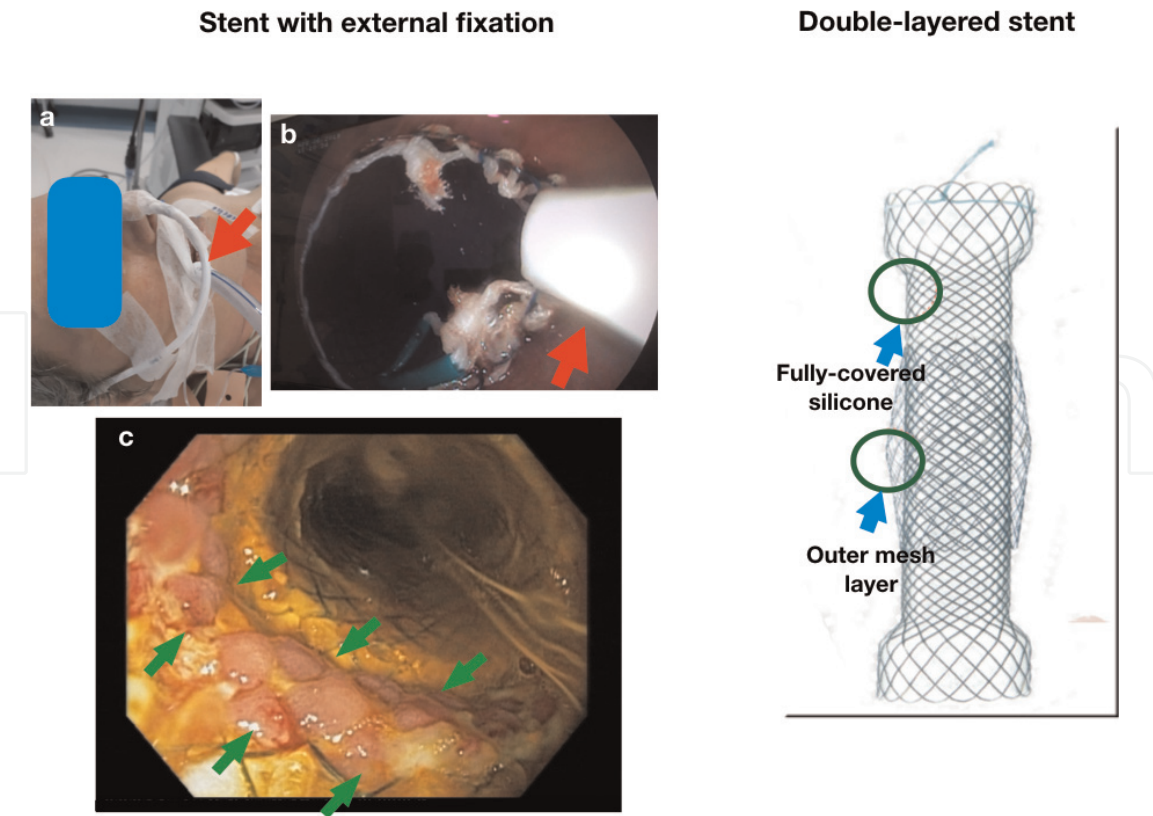


Figure 4. Anchoring methods for stenting. A suture thread passed at the proximal flange can be used to anchor the stent at the level of the nostril (a, b, c, red arrows). Using a near-fully covered stent with a short uncovered line at the proximal flange allows ingrowth of granulating tissue to prevent migration (c, green arrows). A double-layer stent is a fully covered stent with an outer mesh layer to prevent migration (picture modified from www.stent.net.com).

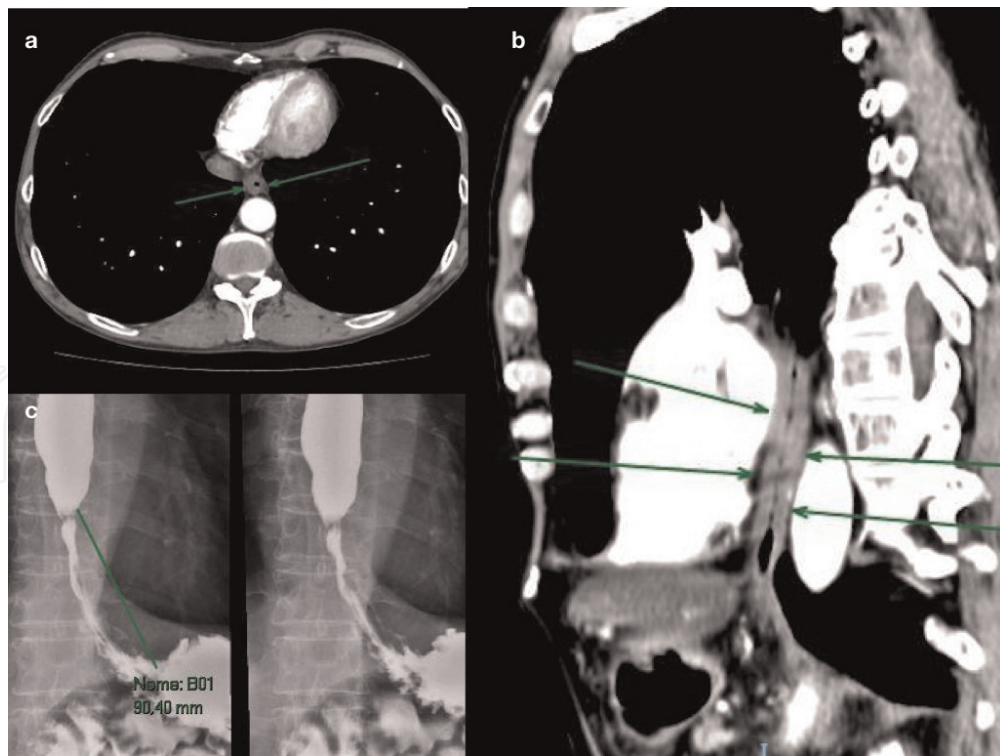


Figure 5.
 A 65-year-old male with advanced mid-distal esophageal cancer treated with chemoradiation. He developed a liver metastasis and an extensive esophageal stenosis (a–c), refractory to dilatation. Because of dysphagia and an ongoing, non-curable disease, it was decided for esophageal stenting. Picture from Eduardo A. Bonin.

tumor growth at any of both ends of a stent. This is avoided by covering the tumor at least 2 cm away from any of both ends. Tumor ingrowth corresponds to tumor growing within the stent mesh. This has been largely supervised using a covering film (silicone, polyethylene, polyvinyl). Larger caliber stents and stents with a good radius force expansion are associated to a larger fluid flow, thus a lower risk of occlusion.

5. Stents in gastrointestinal diseases

In clinical practice, stents are being used for **gastrointestinal tract tumor palliation** (luminal patency maintenance, luminal recanalization, tunneling), **gastrointestinal bleeding** (luminal vessel compression), **gastrointestinal perforation or leak sealing** (gastrointestinal fistula sealing), and **gastrointestinal bypass or anastomosis** (gastrointestinal transluminal drainage).

For each stent application, there are several technical and clinical issues to be assessed. **Technical success** refers to a successful stent deployment across the GI tract for a specific function (tumor palliation, compression, or anastomosis). Generally speaking, a successfully deployed stent should remain in the desired position and ideally expanded to its full radial force until up to 48 hours after deployment. **Clinical success** refers to achieving a desired clinical endpoint (i.e., relief of dysphagia, biliary decompression, fistula sealing) from the first 3–30 days (early) or 3 months and beyond (later) after stent deployment. A **bridging stent** refers to a stent used as a temporary measure for GI tract decompression, as in obstructed colon cancer patients to avoid colostomy. Since stents are commonly used for palliation of end-of-life cancer patients, **quality of life** is also a major concern. **Cost-effectiveness** refers to evaluation of cost of the device and procedure, complication, hospitalization, and mortality rates compared to other available

Level of evidence	
A. High-quality evidence	Further research is unlikely to change our confidence in the estimate of effect. Consistent evidence from RCTs without important limitations or exceptionally strong evidence from observational studies
B. Moderate-quality evidence	Further research is likely to have an important impact on our confidence in the estimate of effect and may change the estimate. Evidence from RCTs with important limitations (inconsistent results, methodological flaws, indirect, or imprecise) or very strong evidence from observational studies
C. Low-quality evidence	Further research is very likely to have an important impact on our confidence in the estimate of effect and is likely to change the estimate. Evidence for at least one critical outcome from observational studies, case series, or RCTs with serious flaws, indirect evidence, or expert consensus
Strength of recommendation	
1. Strong recommendation	Recommendation can apply to most patients in most circumstances.
2. Weak recommendation	The best action may differ depending on the circumstances or patient or society values. Other alternatives may be equally reasonable

RCT, randomized controlled trial.

Table 1.
Level of evidence and strength of recommendation (extracted from [14]).

techniques in terms of clinical success and quality of life. SEMS are often more cost-effective than traditional or laparoscopic surgery for palliation of cancer in high-risk patients.

GI stenting is one of many nonsurgical methods to achieve palliation of gastro-intestinal cancer. Stents are more popular compared to other technologies for upper GI luminal recanalization/tunneling-ablation such as Nd:YAG laser ablation, argon plasma coagulation, or brachytherapy because it is the first-line recommended method [14] and it is an affordable single device with high technical success rates (approaching 90%) and no need for specific or expensive, dedicated equipment. For its widespread use, it is the most common nonsurgical palliation technique used for GI tract cancer worldwide. There are several recommendation guidelines for GI stenting from Western and Eastern surgical and gastrointestinal endoscopy societies based on evidence medicine (**Table 1**) [14]. For this present chapter, we have selected the most recently published guidelines.

6. Indications

6.1 Gastrointestinal cancer

Stenting is a first-line approach to esophageal cancer palliation [15] (**Table 2, Figures 5 and 6**).

Initial historical attempts to relieve dysphagia and alleviate starvation were esophageal dilatation and the use of an esophageal catheter-like tube. This first measure is temporary, unsuccessful over time due to tumor growth and associated to high risk of perforation. It can be still used as an initial approach in areas with no access to more advanced resources. The main, absolute indication for esophageal stenting is tracheoesophageal cancer fistula. Esophageal dysphagia is another major indication; however, it has been balanced with esophageal brachytherapy, when available. Esophageal stenting leads to a better quality of life mainly because of

1. Placement of partially or fully covered self-expandable metal stents (SEMS) is recommended for palliative treatment of malignant dysphagia over laser therapy, photodynamic therapy, and esophageal bypass (strong recommendation, high-quality evidence)
2. For patients with longer life expectancy, brachytherapy is recommended as a valid alternative or in addition to stenting in esophageal cancer patients with malignant dysphagia. Brachytherapy may provide a survival advantage and possibly a better quality of life compared to SEMS placement alone (strong recommendation, high-quality evidence)
3. SEMS placement is recommended as the preferred treatment for sealing malignant tracheoesophageal or bronchoesophageal fistula (strong recommendation, low-quality evidence)
4. The use of concurrent external radiotherapy and esophageal stent treatment is not recommended. SEMS placement is also not recommended as a bridge to surgery or prior to preoperative chemoradiotherapy. It is associated with a high incidence of adverse events, and alternative satisfactory options such as placement of a feeding tube are available (strong recommendation, low-quality evidence)

Table 2.
Recommendations for stenting in esophageal cancer (modified from [15]).

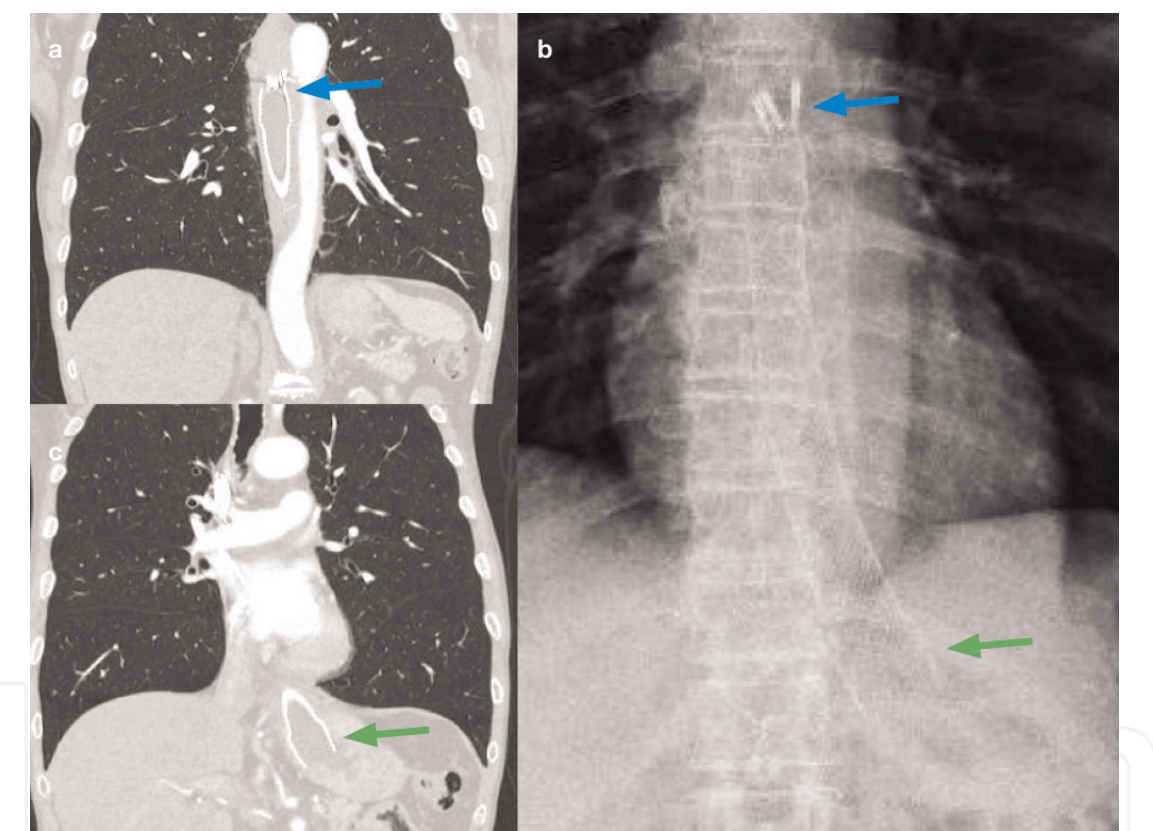


Figure 6.
The same patient as in Figure 5. A 23 mm/12 cm partially covered self-expandable metal stent was placed covering the stenosis. The stent migrated distally 2 days after the procedure, which required repositioning. The stent was then fixed with clips at its proximal end (a, b, blue arrows). The patient resumed oral diet, and the stent remained in place, with its distal end at the level of the cardia (b, c, green arrows). Picture from Eduardo A. Bonin.

relief of dysphagia. It also helps in patient’s nutritional condition, but this should not be highly expected. The clinical success rates for dysphagia are 80–95%, with a median duration of esophageal stent patency being reported as 94% at 4 weeks, 78% at 3 months, and 67% at 6 months [16]. Recurrent obstruction occurs in 30% of patients, and migration rate is more common for covered stents (10–25%) than uncovered stents (2–5%). Stent placement can be considered as a temporary/bridge measure for those who have severe dysphagia before radio- or chemotherapy (neoadjuvant therapy). However, the stent has to be removed after a few weeks,

and a high migration risk is expected once the tumor responds and reduces its size from treatment. Thus, the cost-benefit of a bridging stent for esophageal cancer remains controversial. Several **anti-reflux in-stent valve mechanisms** have been used for preventing gastroesophageal reflux in distal esophageal tumors; however, it seems not to add any advantage over standard esophageal SEMS [17].

Chemotherapy and radiotherapy have evolved over the years into better quality of life scores in palliation of esophageal cancer patients, since many of them are spared from dysphagia for several months on the course of disease. The correct timing for esophageal stent insertion is crucial for a better clinical outcome. It is usually considered when there is an ongoing disease and dysphagia despite optimal previous chemotherapy and radiotherapy treatment. Esophageal stenting with SEMS is superior to any other surgical palliation method for any given patient. It is also superior to gastrostomy for nutritional therapy in advanced cancer patients. Combinations of brachytherapy with SEMS are an interesting approach due to a reduced requirement for re-interventions [18].

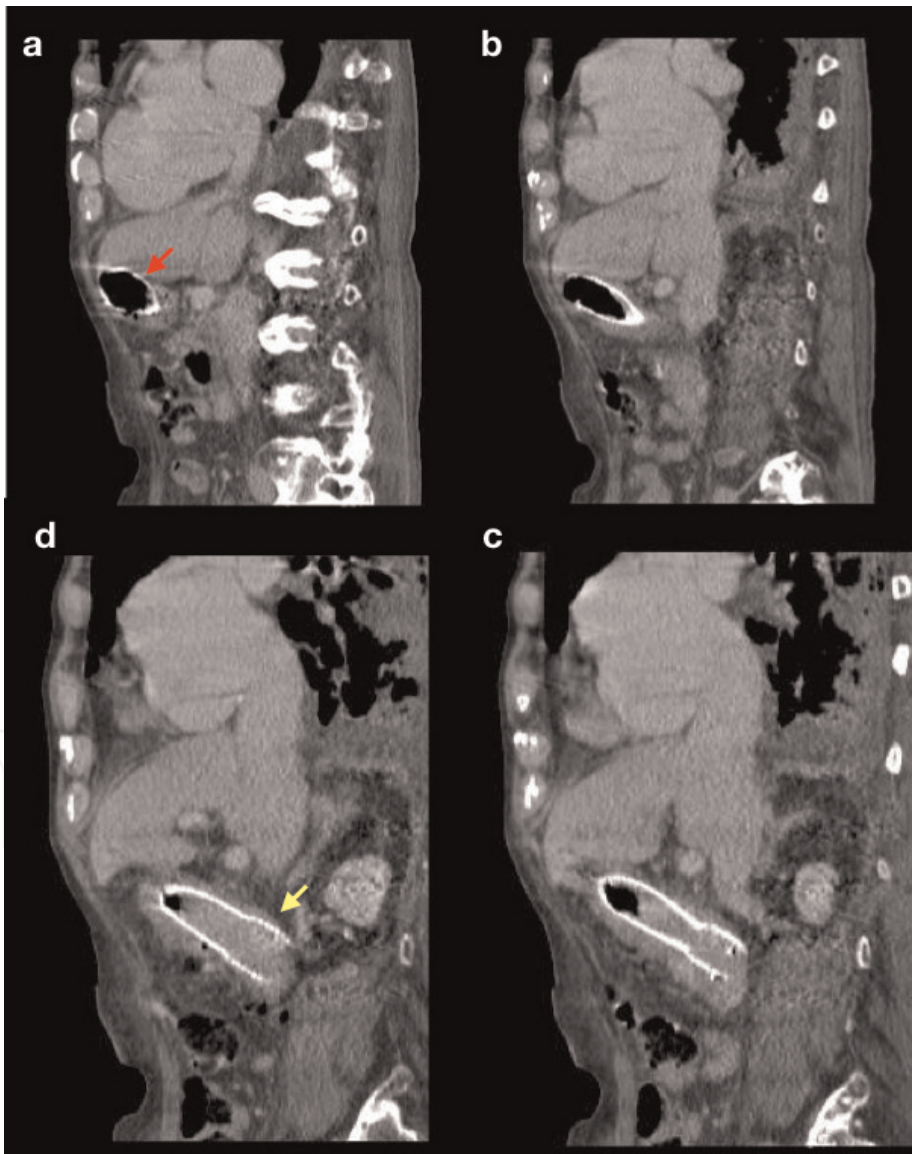


Figure 7. A 90-year-old male with gastric outlet obstruction due to advanced gastric (antral) cancer. He was not clinically fit for a surgical intervention. A duodenal stent was inserted endoscopically. He was able to eat per mouth until he deceased 6 months later because of advanced cancer and pneumonia. The red arrow depicts the proximal flange, located at the antrum (a, b). The distal flange is at the duodenum (c, d, yellow arrow). Picture from Eduardo A. Bonin.

Gastroduodenal outlet obstruction (GOO) may rise from a locally advanced gastric, duodenal, or pancreatic cancer. It occurs in up to 20% of pancreatic cancer patients and is associated to recurrent vomiting, severe weight loss, and malnutrition. This condition is associated to a poor prognosis, with a 3–4 month average life expectancy. Stent placement should be considered for palliation of such patients, especially those who are not fit for surgery or have metastatic cancer (**Figure 7**).

Patients with pancreatic cancer and a larger life expectancy have always the option for a surgical bypass, which nowadays is achieved using minimally invasive laparoscopic techniques. Surgical bypass appears to offer a longer luminal patency compared to stents for patients with GOO with a life expectation of more than 2 months [19]. Patients with locally advanced gastric cancer who are fit for surgery can be considered for gastric resection (partial gastrectomy) as a palliation method [20], since it treats the obstruction and also reduces the chance of tumor bleeding. Although peritoneal disease (carcinomatosis) is considered a relative contraindication to SEMS placement for GOO given the risk of multifocal obstruction, this procedure seems reasonable in such advanced gastric cancer patients [21].

For malignant biliopancreatic diseases, SEMS are preferred over traditional plastic tube stents due to its better cost-effectiveness (lower occlusion rates) [22]. This applies to biliary obstruction in pancreatic cancer and biliary tract cancer. Apart from some evidence-based recommendations [23] (**Table 3**), there are several other clinical aspects in biliary and pancreatic stenting that are beyond the scope of this book chapter.

In **colorectal cancer, acute colonic obstruction** represents a major complication, since it requires prompt intervention because of the risk of colonic necrosis and perforation. It is the primary symptom for 10–30% of patients with colorectal cancer. Others may develop colonic obstruction under their course of any nonsurgical adjuvant therapy. Emergency surgery for an acute obstructed colonic cancer is associated with a morbidity rate of 32–64% and mortality rate of 15–34% [24].

1. Routine preoperative biliary drainage is not recommended in patients with malignant extrahepatic biliary obstruction; preoperative biliary drainage should be reserved for patients with cholangitis, severe symptomatic jaundice (e.g., intense pruritus), or delayed surgery or before neoadjuvant chemotherapy in jaundiced patients (strong recommendation, moderate-quality evidence)
2. Endoscopic placement of a 10 mm diameter self-expandable metal stent (SEMS) is recommended for preoperative biliary drainage of malignant extrahepatic biliary obstruction (strong recommendation, moderate-quality evidence)
3. SEMS insertion is recommended for palliative drainage of extrahepatic malignant biliary obstruction (strong recommendation, high-quality evidence)
4. Insertion of uncovered SEMS is not recommended for the drainage of extrahepatic biliary obstruction of unconfirmed etiology (strong recommendation, low-quality evidence)
5. Routine preoperative biliary drainage is not recommended in patients with malignant hilar obstruction (weak recommendation, low-quality evidence)
6. Uncovered SEMS is recommended for palliative drainage of malignant hilar obstruction (strong recommendation, moderate-quality evidence)
7. Temporary insertion of multiple plastic stents or of a fully covered SEMS is recommended for treatment of benign biliary strictures (strong recommendation, moderate-quality evidence)
8. Endoscopic placement of plastic stent(s) is recommended to treat bile duct leaks that are not due to transection of the common bile duct or common hepatic duct (strong recommendation, moderate-quality evidence)

Table 3.
Recommendations for stenting in biliopancreatic diseases (modified from [23]).

1. Prophylactic colonic stent placement is not recommended. Colonic stenting should be reserved for patients with clinical symptoms and imaging evidence of malignant large-bowel obstruction, without signs of perforation (strong recommendation, low-quality evidence)
2. Colonic SEMS placement as a bridge to elective surgery is not recommended as a standard treatment of symptomatic left-sided malignant colonic obstruction (strong recommendation, high-quality evidence)
3. For patients with potentially curable but obstructing left-sided colonic cancer, stent placement may be considered as an alternative to emergency surgery in those who have an increased risk of postoperative mortality, i.e., American Society of Anesthesiologists (ASA) physical status \geq III and/or age > 70 years (weak recommendation, low-quality evidence)
4. SEMS placement is recommended as the preferred treatment for palliation of malignant colonic obstruction (strong recommendation, high-quality evidence), except in patients treated or considered for treatment with antiangiogenic drugs (e.g., bevacizumab) (strong recommendation, low-quality evidence)

Table 4.
Recommendations for stenting in colorectal cancer (modified from [26]).

Stenting of obstructed colon cancer is mainly used for palliation in advanced left-sided high-risk colonic cancer patients (**Table 4**) [25, 26], since it avoids a definitive stoma, with a potential increase in quality of life. It can also be used as an alternative temporary decompression measure as a bridge before surgical resection, as it may prevent the need of a stoma (colostomy) in 30–40% of cases. However, there are some concerns regarding its safety and long-term oncological issues [27]. Colonic stenting is associated to technical and clinical success rate approaching 90%. It has an overall adverse event rate of up to 25% (perforation, migration, colonic decompression failure as major events, pain as minor event). Patients at higher risk of major events have strictures longer than 4 cm and complete obstruction. A colonic decompression failure may require urgent surgery. Perforation is another feared complication, with an estimated rate of 9.5%. Stent migration usually occurs within a week after placement at a rate of 10% of patients when used as a bridge to surgery, whereas stent occlusion occurs in 10% of palliative patients [27], usually 3–6 months after placement (tumor growth). Covered stents are solely used in benign conditions, with a migration rate reaching up to 90% within 1–3 weeks after placement [25].

7. Benign gastrointestinal tract conditions

7.1 Gastrointestinal strictures, fistulas, and bleeding tamponade

Benign GI tract strictures usually occur from previous surgery (anastomotic) or post-radiotherapy. Caustic chemically induced esophageal strictures are fortunately becoming more rare due to chemical commercial restrictions. Recalcitrant gastrointestinal strictures remain a huge clinical challenge, since results are not consistent and no single therapy has been proven uniformly efficacious. Gastrointestinal stenting has emerged as an alternative therapy for benign stricture treatment, and a fully covered SEMS has been regarded the stent of choice, preferably using a fixation method (**Table 5**) [28].

Gastrointestinal perforation and fistula management have evolved dramatically over the last 15 years toward a noninvasive endoscopic treatment. Gastrointestinal perforation or laceration usually refers to any gastrointestinal full-thickness wall opening that can occur during a therapeutic endoscopic procedure [29] or spontaneously from intense vomiting (Boerhaave syndrome) or gut wall necrosis

1. SEMS is not recommended as first-line therapy for the management of benign esophageal strictures because of the potential for adverse events, the availability of alternative therapies, and costs (strong recommendation, low-quality evidence)
2. Temporary placement of SEMS should be considered as therapy for refractory benign esophageal strictures (weak recommendation, moderate-quality evidence). Stents should usually be removed at a maximum of 3 months (strong recommendation, low-quality evidence)
3. Fully covered SEMS are preferred over partially covered SEMS for the treatment of refractory benign esophageal strictures, because of their lack of embedment and ease of removability (weak recommendation, low-quality evidence)
4. For the removal of partially covered esophageal SEMS that are embedded, the stent-in-stent technique is recommended (strong recommendation, low-quality evidence)
5. Temporary stent placement can be considered for treating esophageal leaks, fistulas, and perforations. The optimal stenting duration remains unclear and should be individualized (strong recommendation, low-quality evidence)
6. Placement of a SEMS is recommended for the treatment of esophageal variceal bleeding refractory to medical, endoscopic, and/or radiological therapy or as initial therapy for patients with massive esophageal variceal bleeding (strong recommendation, moderate-quality evidence)

Table 5.
Recommendations for stenting for benign disease (modified from [15]).

following an intense inflammatory process [30]. Gastrointestinal leakage may also occur postoperatively after a given gastrointestinal anastomosis. Any of these situations may lead to gastrointestinal fluid leak/extravasation and consequent abdominal cavity contamination, leading to an established communication (fistula) of the afflicted organ to the abdominal cavity or to other GI tract compartments or the skin. Gastrointestinal stenting may aid as a sealing procedure to avoid gastrointestinal content leakage and also to maintain luminal patency, reducing any pressure from an unexpected gastrointestinal anastomotic stricture (**Table 5**).

Gastroesophageal varices are mostly found in cirrhotic patients. Other causes include **Schistosoma** infection and portal vein thrombosis from other causes excluding cirrhosis. They may lead to massive bleeding with a high-rate mortality. Variceal band ligation and endoscopic injection therapy are the treatment of choice for ongoing acute variceal bleeding despite medical management. However, patients with massive refractory bleeding and coagulation impairment (usually due to cirrhosis) may require a life-saving tamponade measure, usually done using an esophagogastric balloon device (Sengstaken-Blakemore tube). This device requires a highly compromised team to take care of the balloon device tube and is very uncomfortable for an awoken patient. It also leads to complications such as mucosal ischemic injury. Stenting has emerged as an alternative effective temporary tamponade measure for such bleeding cases until a definitive treatment can be applied (**Table 5**).

8. Other indications

8.1 Gastrointestinal bypass/drainage/anastomosis

Transgastric pancreatic fluid collection drainage (cystogastrostomy drainage) has been for at least 20 years the most popular representative of a typical transmural endoscopic drainage procedure (**Figure 8**). Until 5 years ago, no one would assume a gastrointestinal anastomosis being performed totally under endoscopic technique in the clinical setting, until a novel lumen-apposing self-expandable metal stent (LAMS) has been developed.

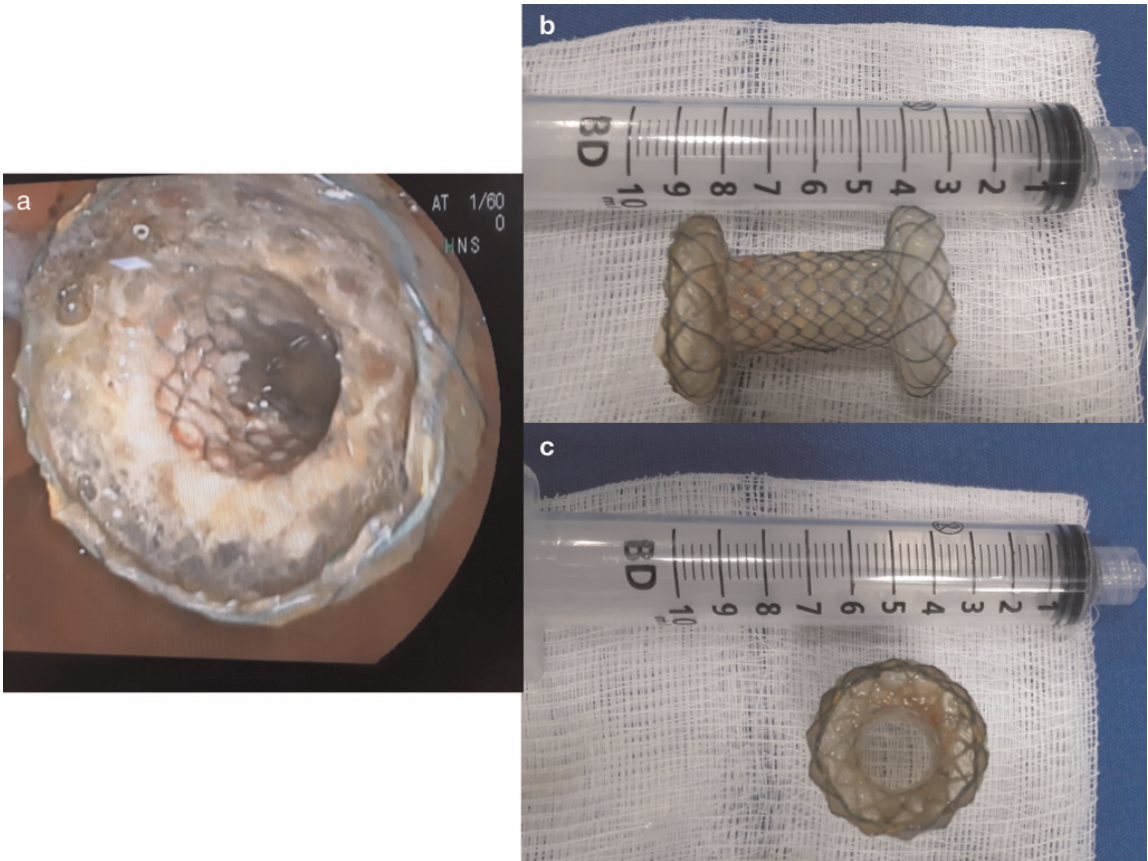


Figure 8. Lumen-apposing self-expandable metal stent used for transgastric drainage of a walled of pancreatic necrosis. (a) Four weeks after transgastric endoscopic necrosectomy, the resulting cavity has been replaced by granulating tissue. The stent was then removed. The stent has large flanges to avoid migration (b) and a 14 mm lumen to allow endoscope insertion (c). Picture from Eduardo A. Bonin.

This totally covered, dumbbell-shape self-expandable metal stent has been used for gastrointestinal (gastrojejunal) and bilioenteric (cholecysto-gastric, choledoco-duodenal) anastomosis in clinical practice with promising results [31]. A recent case control retrospective trial has demonstrated its role compared to traditional endoscopic stenting in managing gastric outlet obstruction from malignant and benign conditions [32].

9. Summary

Gastrointestinal stenting is a procedure associated to a high safety and technical success profile, and its clinical indications have surpassed its original use, esophageal cancer. Self-expandable metal stent placement is the preferred nonsurgical method for biliopancreatic and upper and lower gastrointestinal tract cancer palliation. Stenting is also being used for several other indications, such as benign gastrointestinal stricture treatment, gastrointestinal fistula management, variceal bleeding arrest, and gastrointestinal bypass or drainage. Several efforts have been made to overcome its three remaining clinical major issues: stent occlusion, stent migration, and stent-related perforation.

IntechOpen

IntechOpen

Author details

Eduardo Aimore Bonin*, Bruno Verschoor, Fernanda Hoffmann Silva,
Kelly Cristina Vieira and Susan Kakitani Takata
Hospital Erasto Gaertner, Curitiba, Paraná, Brazil

*Address all correspondence to: eabonin@gmail.com

IntechOpen

© 2019 The Author(s). Licensee IntechOpen. This chapter is distributed under the terms of the Creative Commons Attribution License (<http://creativecommons.org/licenses/by/3.0>), which permits unrestricted use, distribution, and reproduction in any medium, provided the original work is properly cited. 

References

- [1] Available from: <https://www.merriam-webster.com/dictionary/stent#h1m> [Accessed: April 30, 2019]
- [2] Roguin A. Stent: The man and word behind the coronary metal prosthesis. *Circulation Cardiovascular Interventions*. 2011;4(2):206-209
- [3] Girardet RE, Ransdell HT Jr, Wheat MW Jr. Palliative intubation in the management of esophageal carcinoma. *The Annals of Thoracic Surgery*. 1974;18(4):417-430
- [4] Symonds CJ. The treatment of malignant stricture of the oesophagus by tubage or permanent catheterism. *British Medical Journal*. 1887;1(1373):870-873
- [5] Irani S, Kozarek RA. History of GI stenting: Rigid prostheses in the esophagus. In: Kozarek RA, Baron TH, Song HY, editors. *Self-Expandable Stents in the GI Tract*. New York, USA: Springer; 2013. pp. 3-15. ISBN 978-1-4614-3745-1
- [6] Knyrim K, Wagner HJ, Bethge N, Keymling M, Vakil N. A controlled trial of an expansile metal stent for palliation of esophageal obstruction due to inoperable cancer. *The New England Journal of Medicine*. 1993;329(18):1302-1307
- [7] Thiebes AL, McGrath DJ, Kelly N, Sweeney CA, Kurtenbach K, Gesché VN, et al. Comparison of covered laser-cut and braided respiratory stents: From bench to pre-clinical testing. *Annals of Biomedical Engineering*. 2019;47(8):1738-1747
- [8] Domingo S, Puértolas S, Gracia-Villa L, Puértolas JA. Mechanical comparative analysis of stents for colorectal obstruction. *Minimally Invasive Therapy & Allied Technologies*. 2007;16(2):126-136
- [9] Mangiavillano B, Pagano N, Baron TH, Arena M, Iabichino G, Consolo P, et al. Biliary and pancreatic stenting: Devices and insertion techniques in therapeutic endoscopic retrograde cholangiopancreatography and endoscopic ultrasonography. *World Journal of Gastrointestinal Endoscopy*. 2016;8(3):143-156
- [10] Shatzel J, Kim J, Sampath K, Syed S, Saad J, Hussain ZH, et al. Drug eluting biliary stents to decrease stent failure rates: A review of the literature. *World Journal of Gastrointestinal Endoscopy*. 2016;8(2):77-85. DOI: 10.4253/wjge.v8.i2.77
- [11] Samadder NJ, Bonin EA, Buttar NS, Baron TH, Gostout CJ, Topazian MD, et al. Placement of a covered stent for palliation of a cavitated colon cancer by using a novel over-the-scope technique (with video). *Gastrointestinal Endoscopy*. 2012;76(6):1275-1277
- [12] Veld JV, Fockens P, van Hooft JE. Mistakes in enteral stenting and how to avoid them. *UEG Education*. 2019;19:5-8
- [13] Fujii LL, Bonin EA, Baron TH, Gostout CJ, Wong Kee Song LM. Utility of an endoscopic suturing system for prevention of covered luminal stent migration in the upper GI tract. *Gastrointestinal Endoscopy*. 2013;78(5):787-793
- [14] Jee SR, Cho JY, Kim KH, Kim SG, Cho JH, The Stent Study Group of the Korean Society of Gastrointestinal Endoscopy. Evidence-based recommendations on upper gastrointestinal tract stenting: A report from the Stent Study Group of the Korean Society of Gastrointestinal

Endoscopy. Clinical Endoscopy. 2013; **46**(4):342-354

[15] Spaander MC, Baron TH, Siersema PD, Fuccio L, Schumacher B, Escorsell À, et al. Esophageal stenting for benign and malignant disease: European Society of Gastrointestinal Endoscopy (ESGE) clinical guideline. Endoscopy. 2016;**48**(10):939-948

[16] Kang HW, Kim SG. Upper gastrointestinal stent insertion in malignant and benign disorders. Clinical Endoscopy. 2015;**48**(3):187-193

[17] Pandit S, Samant H, Morris J, Alexander SJ. Efficacy and safety of standard and anti-reflux self-expanding metal stent: A systematic review and meta-analysis of randomized controlled trials. World Journal of Gastrointestinal Endoscopy. 2019;**11**(4):271-280

[18] Dai Y, Li C, Xie Y, Liu X, Zhang J, Zhou J, et al. Interventions for dysphagia in oesophageal cancer. Cochrane Database of Systematic Reviews. 2014;**10**:CD005048

[19] Jeurnink SM, Steyerberg EW, van Hooft JE, van Eijck CH, Schwartz MP, Vleggaar FP, et al. Surgical gastrojejunostomy or endoscopic stent placement for the palliation of malignant gastric outlet obstruction (SUSTENT study): A multicenter randomized trial. Gastrointestinal Endoscopy. 2010;**71**(3):490-499

[20] No JH, Kim SW, Lim CH, Kim JS, Cho YK, Park JM, et al. Long-term outcome of palliative therapy for gastric outlet obstruction caused by unresectable gastric cancer in patients with good performance status: Endoscopic stenting versus surgery. Gastrointestinal Endoscopy. 2013;**78**(1): 55-62

[21] Mendelsohn RB, Gerdes H, Markowitz AJ, DiMaio CJ,

Schattner MA. Carcinomatosis is not a contraindication to enteral stenting in selected patients with malignant gastric outlet obstruction. Gastrointestinal Endoscopy. 2011;**73**(6):1135-1140

[22] Bonin EA, Baron TH. Preoperative biliary stents in pancreatic cancer. Journal of Hepato-Biliary-Pancreatic Sciences. 2011;**18**(5):621-629

[23] Dumonceau JM, Tringali A, Papanikolaou IS, Blero D, Mangiavillano B, Schmidt A, et al. Endoscopic biliary stenting: Indications, choice of stents, and results: European Society of Gastrointestinal Endoscopy (ESGE) clinical guideline—Updated October 2017. Endoscopy. 2018;**50**(9): 910-930

[24] Arezzo A, Passera R, Lo Secco G, Verra M, Bonino MA, Targarona E, et al. Stent as bridge to surgery for left-sided malignant colonic obstruction reduces adverse events and stoma rate compared with emergency surgery: Results of a systematic review and meta-analysis of randomized controlled trials. Gastrointestinal Endoscopy. 2017;**86**: 416-426

[25] Bonin EA, Baron TH. Update on the indications and use of colonic stents. Current Gastroenterology Reports. 2010;**12**(5):374-382

[26] van Hooft JE, van Halsema EE, Vanbiervliet G, Beets-Tan RG, DeWitt JM, Donnellan F, et al. Self-expandable metal stents for obstructing colonic and extracolonic cancer: Clinical guideline. Endoscopy. 2014;**46**(11): 990-1053

[27] Ribeiro IB, de Moura DTH, Thompson CC, de Moura EGH. Acute abdominal obstruction: Colon stent or emergency surgery? An evidence-based review. World Journal of Gastrointestinal Endoscopy. 2019;**11**(3): 193-208

[28] Ngamruengphong S, Sharaiha R, Sethi A, Siddiqui A, DiMaio CJ, Gonzalez S, et al. Fully-covered metal stents with endoscopic suturing vs. partially-covered metal stents for benign upper gastrointestinal diseases: A comparative study. *Endoscopy International Open*. 2018;**6**(2): E217-E223

[29] Rao AS, LeRoy AJ, Bonin EA, Sweetser SR, Baron TH. Novel technique for placement of overlapping self-expandable metal stents to close a massive pancreatitis-induced duodenal fistula. *Endoscopy*. 2012;**44**(Suppl 2 UCTN):E163-E164

[30] Hadj Amor WB, Bonin EA, Vitton V, Desjeux A, Grimaud JC, Barthet M. Successful endoscopic management of large upper gastrointestinal perforations following EMR using over-the-scope clipping combined with stenting. *Endoscopy*. 2012;**44**(Suppl 2 UCTN):E277

[31] Lee HS, Chung MJ. Past, present, and future of gastrointestinal stents: New endoscopic ultrasonography-guided metal stents and future developments. *Clinical Endoscopy*. 2016;**49**(2):131-138

[32] Chen YI, Itoi T, Baron TH, Nieto J, Haito-Chavez Y, Grimm IS, et al. EUS-guided gastroenterostomy is comparable to enteral stenting with fewer re-interventions in malignant gastric outlet obstruction. *Surgical Endoscopy*. 2017; **31**(7):2946-2952