

We are IntechOpen, the world's leading publisher of Open Access books Built by scientists, for scientists

6,900

Open access books available

185,000

International authors and editors

200M

Downloads

Our authors are among the

154

Countries delivered to

TOP 1%

most cited scientists

12.2%

Contributors from top 500 universities



WEB OF SCIENCE™

Selection of our books indexed in the Book Citation Index
in Web of Science™ Core Collection (BKCI)

Interested in publishing with us?
Contact book.department@intechopen.com

Numbers displayed above are based on latest data collected.
For more information visit www.intechopen.com



Marginal Bone Changes around Dental Implants after LIPUS Application: CBCT Study

Elaf Akram Abdulhameed, Marzuki Omar and A.R. Samsudin

Abstract

To assess the effect of LIPUS on marginal bone regeneration during insertion and following loading using CBCT scan imaging, a trial of RCT of 22 subjects needing dental implant was conducted. The participants were randomly allocated into 2 groups; both groups underwent similar two-stage implant surgery of one maxillary dental implant. The control group ($n = 11$) of the implant site was allowed to heal in a conventional way, while the intervention group ($n = 11$) was subjected to LIPUS therapy at the implant site (twice a week, 20-minute duration, from week 2 after stage I implant surgery and continued for 10 weeks). Similar ultrasound protocol was repeated 2 weeks after crown installation and again continued for another 10 weeks. The assessment of marginal bone loss around dental implants was carried out at three different views (coronal, sagittal, and axial) of the implant site immediately after surgery, 3 and 6 months later. Statistical analysis of ANOVA within and between two-group analysis that was applied followed by pairwise comparison with confidence interval adjustment showed that there is a significant difference among the groups ($p < 0.05$). The CBCT imaging (coronal view) values suggested that buccal bone regeneration around the dental implant has significantly increased during the early osseointegration period in the LIPUS-treated subjects than in the control group. LIPUS enhances bone formation in particular buccal bone plate around the dental implant as confirmed by the coronal view.

Keywords: LIPUS, coronal, sagittal, axial, osseointegration

1. Introduction

The introduction of osseointegration, in 1969, by Professor Per-Ingvar Brånemark, at the Institute of Applied Biotechnology, University of Goteborg, [1] opened new avenues in the dental implant treatment for the partially or fully edentulous patients [2]. Titanium endosseous implants are widely used successfully in association with this treatment modality. Various investigations proved this method to be superior for long-term prognosis for dental implant treatment [3, 4].

Osseointegration is a process of connecting structurally and functionally an ordered living bone with load-carrying implant [5]. When histologic features of the osseointegration were observed, functional ankylosis was found without any intrusion of connective or fibrous tissues between the implant surface and bone [6]. However, in some situations, osseointegration does not take place adequately and

at times leads to implant failure. Continuous investigations looking into implant's chemical and physical characteristics, structures, and the biological responses from the surrounding bone are being conducted to identify its cause.

Implant success depends upon successful osseointegration. Evaluation of the bone surrounding the implant is a common method for observing the implant prognosis [7–9]. Care of the bone that supports the implant is vital for the beneficial results of the implant treatment [10].

Various studies have shown that there were changes in the marginal bone level and loss of different amount of bone that occur mostly during the first year of dental implant placement [11–13]. Assessment of changes in marginal bone height is considered an important parameter in evaluating implant success [14, 15]. Excessive marginal bone loss after implant or following prosthesis may be seen in the first year. However, in the early phase of osseointegration, the process of bone healing is not well understood [16].

One of the etiological factors of marginal bone loss is the disruption of the periosteum and blood supply during flap elevation and placement of implant [17]. Some studies showed that less marginal bone loss was noticed when flapless technique is used as compared with full-thickness flap technique that showed more marginal bone loss during healing period [18–21].

Other studies showed that periosteum disruption not only affects marginal bone level but also has other effects on bone formation around the implant during the healing period that compromise the stability of the implant and delay healing [21, 22].

Previous studies [19, 23] reported that the decreased blood supply to the bone after periosteum elevation has the same effect of flapless technique on the level of marginal bone and bone formation rhythm.

Continuous bone resorption affects function and esthetic. There are several ways to restore and regenerate bone such as advocating bone grafting procedures, usage of growth factors, laser therapy in low levels, and therapeutic ultrasound.

Low-intensity pulsed ultrasound (LIPUS) stimulation is a classical therapeutic modality for bone regeneration. Its efficiency has been widely reported over the years. LIPUS stimulation can be used as a tool to enhance tooth and periodontal regeneration [24].

Della Rocca [25] in her study on the effect of LIPUS on bone regeneration on Wistar rats confirmed that LIPUS can consolidate fractures and reduce bone healing time. It is also shown that LIPUS enhances bone regeneration based on its angiogenic and osteogenic values both before and after dental implant placement [26, 27].

1.1 Ultrasound

1.1.1 History and development of ultrasound

Ultrasound has been discovered 50 years ago for therapeutic and diagnostic uses in the medical field. Ultrasound refers to the sound with frequency greater than that audible by the human ear. It is a mechanical compression-rarefaction wave that travels through the tissue, producing both thermal and nonthermal effects [28].

The thermal effects of ultrasound can increase the temperature of deep tissue with high collagen content to increase the extensibility of the tissue or to control pain. The nonthermal effects of ultrasound can alter cell membrane permeability, thus facilitating tissue healing and transdermal drug penetration. Therapeutic ultrasound may also facilitate calcium resorption. To achieve these treatment outcomes, appropriate frequency, intensity, duty cycle, and duration of ultrasound must be selected and applied.

In evaluating an ultrasound device for the clinical application, one should consider the appropriateness of the available heads and BNRs for the types of problems expected to be treated with the device [28].

1.1.2 Diagnostic uses of ultrasound

Transthoracic ultrasound (US) examination can be used for (1) chest wall lesions; (2) pleural lesions such as pleural effusion, pleural thickening, or pleural tumors; (3) peridiaphragmatic lesions; (4) peripheral pulmonary lesions which abut the pleura; (5) pulmonary lesions with an accessible US window; and (6) mediastinal tumors in contact with the chest wall [29–31].

On US, pleural effusion is characterized by an echo-free or hypo echoic space between the visceral and parietal pleurae that can change shape with respiration. On US, peripheral lung tumors appear as well-defined, homogeneous, hypo echoic, or echogenic nodules with posterior acoustic enhancement.

Diagnostic US is efficiently used for the visceral examinations, e.g., the liver, pancreas, kidneys, etc., at 3 MHz frequency. The neck, breast, and children are examined using a frequency of 5–7 MHz. The increase in the frequency in the ultrasound examination increases the visibility and discrimination of details of the image.

Diagnosis of benign or malignant growth in the uterus, fallopian tubes, and ovary is routinely made in the obstetrics using ultrasound. It is also used for the progressive assessment of pregnancy.

1.1.3 Therapeutic uses of ultrasound

1.1.3.1 Osteoradionecrosis

Harris [32] claimed that therapeutic ultrasound increases the blood supply and the deposition of new healthy callus replacing the necrotic bone. Therefore, therapeutic ultrasound can be used as conservative method of management of osteoradionecrosis of the mandible.

1.1.3.2 In vitro and in vivo bone regeneration

Ultrasound and some other physical factors stimulate the bone healing process by increasing the intracellular calcium levels. Deposition of intracellular calcium enhances the formation of bone [33]. In vivo and in vitro studies have shown that ultrasound treatment increases the activity of alkaline phosphatase in spontaneous and experimental fractures in rats and rabbits as compared with untreated animals [34–36].

Animal and clinical studies conducted in two phases by John et al. [37] reported that ultrasound-treated groups have increased formation of callus. Increased activity of the osteoblasts was observed cytologically in the ultrasound-treated group.

1.1.4 Ultrasound treatment setting parameters

General guidelines of parameters for ultrasound therapy are given for different clinical applications as follow [28]:

- **Duty cycle:** The proportion of the total treatment time that the ultrasound is on. This can be expressed as a percentage or a ratio: 20 or 1:5 duty cycle, that is, 20% of the time on and 80% of the time off.

- **Effective radiating area (ERA):** The area of the transducer that radiates ultrasound energy is known as ERA. ERA is smaller in comparison with the area of the treatment head.
- **Frequency:** Frequency is the measure of compression-refraction cycles per unit of time. It can be expressed in Hertz (Hz) or cycle per second. Frequency used for therapeutic purposes ranges from 1 to 3 MHz. Increment in the frequency decreases the concentration and depth of penetration of the ultrasound energy in the tissues.
- **Intensity:** Intensity demonstrates power per unit area of the sound head. It is expressed in watts per centimeter squared (W/cm^2). The recommended limit of the intensity for therapeutic purposes is $3 \text{ W}/\text{cm}^2$ by the World Health Organization.
- **Power:** It is the amount of aural energy per unit time. It is expressed in watts (W).
- **Pulsed ultrasound:** During the treatment, periodic or sporadic supply of ultrasound is known as pulsed ultrasound.
- **Spatial average intensity:** The average intensity of the ultrasound output over the area of the transducer.
- **Spatial average temporal average (SATA) intensity:** The spatial average intensity of the ultrasound averaged over the on time and the off time of the pulse.
- **Spatial average temporal peak (SATP) intensity:** The spatial average intensity of the ultrasound during the on time of the pulse. This is a measure of the amount of energy delivered to the tissue.

1.1.5 Mechanism of action of ultrasound therapy

Although the exact mechanism of LIPUS interaction with the viable tissues and stimulation of bone healing is still unclear, there are several studies that showed that LIPUS stimulates regeneration of the bone and decreases the osseointegration time and promotion of the quality of osseointegration [38].

The mechanism behind the effect of LIPUS on bone regeneration might start from the mechanotransduction pathways of LIPUS on bone wound healing which is considered a complex process as numerous cell types respond to this stimulus involving several pathways. Mechanotransduction refers to the processes through which cells sense and respond to mechanical stimuli by converting them to biochemical signals that elicit specific cellular responses [39]. Typically the mechanical stimulus gets filtered in the conveying medium before reaching the site of mechanotransduction. Cellular responses to mechanotransduction are variable and give rise to a variety of changes and sensations. From definition of mechanotransduction, LIPUS promotes activation of osteoblast and other necessary cells' function which are considered decisive elements in bone healing by increasing proliferation, migration, and differentiation of these cells and changing it from inactive phase to active cells. The cellular responses underlying this mechanism are termed mechanotransduction [40].

Ingber [41] demonstrated in his work that the integrins are the most important key in the transduction of the ultrasound signals with evolutionary conserved mechanoreceptors, are expressed by various cell types, and convert mechanical signal into biochemical response. This form of sensory transduction is responsible for a

number of senses and physiological processes in the body, including proprioception, touch, balance, and hearing. Mechanotransduction involves various signal transduction pathways, including the activation of ion channels and other mechanoreceptors in the membrane of the bone cell, resulting in gene regulation in the nucleus [42]. Identification and functional characterization of the mechanotransduction components may improve bone tissue engineering. In this process, a mechanically gated ion channel makes it possible for sound, pressure, or movement to cause a change in the excitability of specialized sensory cells and sensory neurons [43]. The stimulation of a mechanoreceptor causes mechanically sensitive ion channels to open and produce a transduction current that changes the membrane potential of the cell.

Padilla et al. [44] and Sato et al. [45] updated the information in this area of interest that the mechanotransduction pathways involved in cell responses include integrin/mitogen-activated protein kinase (MAPK) and other kinase signaling pathways, gap-junctional intercellular communication, upregulation and clustering of integrins, involvement of the COX-2/PGE2 and iNOS/NO pathways, and activation of mechanoreceptor. Along with the direct effect of ultrasound, sensitizing mechanosensitive receptors, channels of the cell and the indirect effect of acoustic streaming-governed-shear stress on the cell surface (**Figure 1**). Acoustic streaming, giving rise to a unidirectional bulk fluid movement, can improve the circulation of molecules within the extracellular matrix in the culture wall, or trigger fluid flow in vivo, and thereby increase the delivery of cytokines secreted by other cell participants or other essential nutrients, and remove cellular waste products [46]. Tang et al. [47] stressed with his co-worker that the transmembrane mechanoreceptors increased surface expression in rat primary osteoblasts (in vitro study) of $\alpha 2$, $\alpha 5$, $\beta 1$, and $\beta 3$ integrins and clustering of $\beta 1$ and $\beta 3$ integrins have been shown to be upregulated within 24 hours after 20-minute treatment with LIPUS. In the same cell type, but using continuous ultrasound exposure, enhanced expression of $\alpha 2$, $\alpha 5$, and $\beta 1$ integrins has also been reported and also showed upregulated expression [36]. After ultrasound exposure in mouse, osteoblasts isolated from long bones, gene expression was also significantly upregulated of $\alpha 2$, $\alpha 5$, and $\beta 1$ integrins, whereas Watabe et al. [48] revealed in his vitro study that only expression of $\alpha 5$ was enhanced in mouse mandibular and calvaria-derived osteoblasts stimulated with LIPUS. Zhou et al. [49] explained in his amazing work that inhibiting $\beta 1$ integrin by blocking antibody or RGD peptide in human primary skin fibroblasts led to restoring basal levels of DNA synthesis, which had been upregulated in response to ultrasound before.

Ren et al. [50] has reported that p38 MAPK kinase is crucial for LIPUS to induce and enhance differentiation of human periodontal ligament cells (HPDLC) which are similar to mesenchymal stem cells and can undergo osteogenic differentiation. Treatment of cells with the p38 inhibitor significantly reduced ALP activity, osteocalcin concentration, and matrix mineralization in response to LIPUS, compared to the control group, where no inhibitor was added [44]. Whitney et al. [51] also explained in his study that the LIPUS in continuous mode caused more intense phosphorylation of FAK, Src, p130Cas, CrkII, and Erk1/Erk2 in primary human chondrocyte culture, suggesting that this pathway is involved in US-induced mechanotransduction mechanism. However, several studies in mechanotransduction suggested that voltage-sensitive calcium channels (VSCCs) have been reported to be the key regulators of intracellular calcium signaling in osteoblasts for bone formation [40].

Most recently, Kang et al. [52] studied the effects of 20 minutes a day stimulation by a low-intensity ultrasound (1 MHz, 30 mW/cm² continuous sine wave) in combination with cyclic vibratory strain (1 Hz, 10% strain) on MC3T3-E1 cells in a 3D scaffold. The stimulation did not change the cell proliferation over a period of 10 days, but significantly upregulated several gene expressions—COL-I, OC, RUNX2, and OSX—indicating accelerated differentiation.

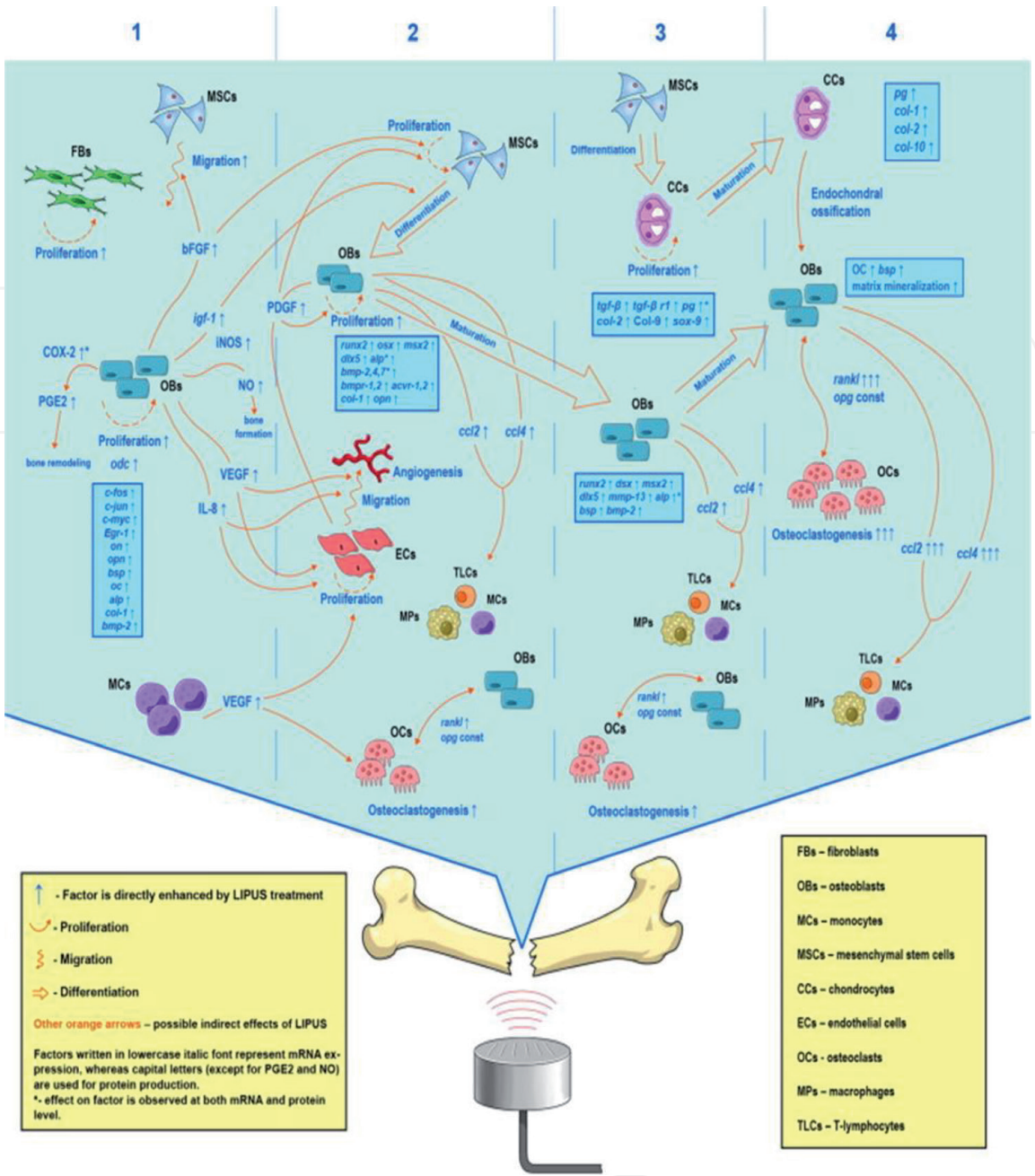


Figure 1. Summary of hypothetical LIPUS effects on bone cellular events in vitro data. The columns represent the four phases during in vivo endochondral bone fracture healing: phase 1, early events soon after the bone injury: hematoma formation, inflammation, and migration of osteogenic precursors; phase 2, angiogenesis, proliferation of mesenchymal stem cells (MSCs), and osteoblasts and osteogenic differentiation; phase 3, chondrogenesis and maturation of osteoblast; and phase 4, maturation of chondrocytes, woven bone formation, and remodeling [44].

The accessibility of the crucial factors to the compromised cells supports their viability and maintains the indispensable microenvironment in the healing fracture through the regulation of pH and oxygenation, which may be enhanced by the ultrasound treatment. A mechanism of improved oxygen and nutrient transport in response to ultrasound has been suggested by Pitt and Ross [53].

These studies suggest that LIPUS are able to enhance osteogenesis and angiogenesis in vivo and in vitro as was well documented by literature review that angiogenesis precedes osteogenesis process [54]. Angiogenesis is closely associated with osteogenesis where reciprocal interactions between endothelial and osteoblast cells play an important role in bone regeneration [55].

Angiogenesis has a key role in bone repair by not only facilitating the supply of oxygen and nutrients required for bone repair and the removal of waste products but also by providing conduits for the invasion of osteoblast and osteoclast

progenitors into the healing site [56]. Vascular endothelial growth factor (VEGF) is a potent and vital angiogenic cytokine. It is a specific mitogen for vascular endothelial cells (ECs) [57]. Shiraishi et al. [58] demonstrated in his vitro study that the application of LIPUS led to the upregulation of interleukin-8, basic fibroblast growth factor, vascular endothelial growth factor, and non-collagenous bone proteins, and the downregulation of osteoclasts resulted in bone regeneration. El-Bialy et al.'s [59] study in vivo has demonstrated that therapeutic LIPUS can promote bone repair and regeneration, accelerate bone fracture healing, and enhance osteogenesis at the distraction site on rabbits ultimately offering long-term benefits to patients.

1.1.6 Ultrasound in dentistry

Low-intensity pulsed ultrasound technique is used for the evaluation of bone growth in the permeable implant surface [60]. Pulsed ultrasound produces a pressure wave which serves as a noninvasive mechanical stimulus and promotes the growth at the site of injury. Amplitude of the pulse is kept as low as 0.3 mm showing no ill effects on the process of recovery. However, mechanism of cellular response produced by ultrasound is not well defined [61, 62]. Low-intensity pulsed ultrasound, which is used for only few minutes in routine, has shown beneficial role in the healing evidenced by experimental and clinical trials [62, 63].

The intensity of ultrasound used for soft tissue application ranges from 500 to 3000 mW/cm². Much of the clinical benefits from the ultrasound in physical therapy have been attributed to the controlled heating of the tissue. Because heating bone may also have significant deleterious effects, intensity used for bone application is much lower, in the range 30 mW/cm², which does not induce applicable heating of treated hard and soft tissues [64].

1.1.6.1 Applications of ultrasound in dentistry

1. Ultrasound is widely used for fracture detection in dentistry. Fractures of the nasal bone, orbital rim, maxilla, and mandible zygomatic arch are commonly detected by ultrasound. The position of the mandibular condyles is also located by ultrasound. To observe the healing fractures after surgery can be easily performed by ultrasound [66].
2. Focal disease or parotid lesions can be observed easily using an ultrasound.

2. Materials and methods

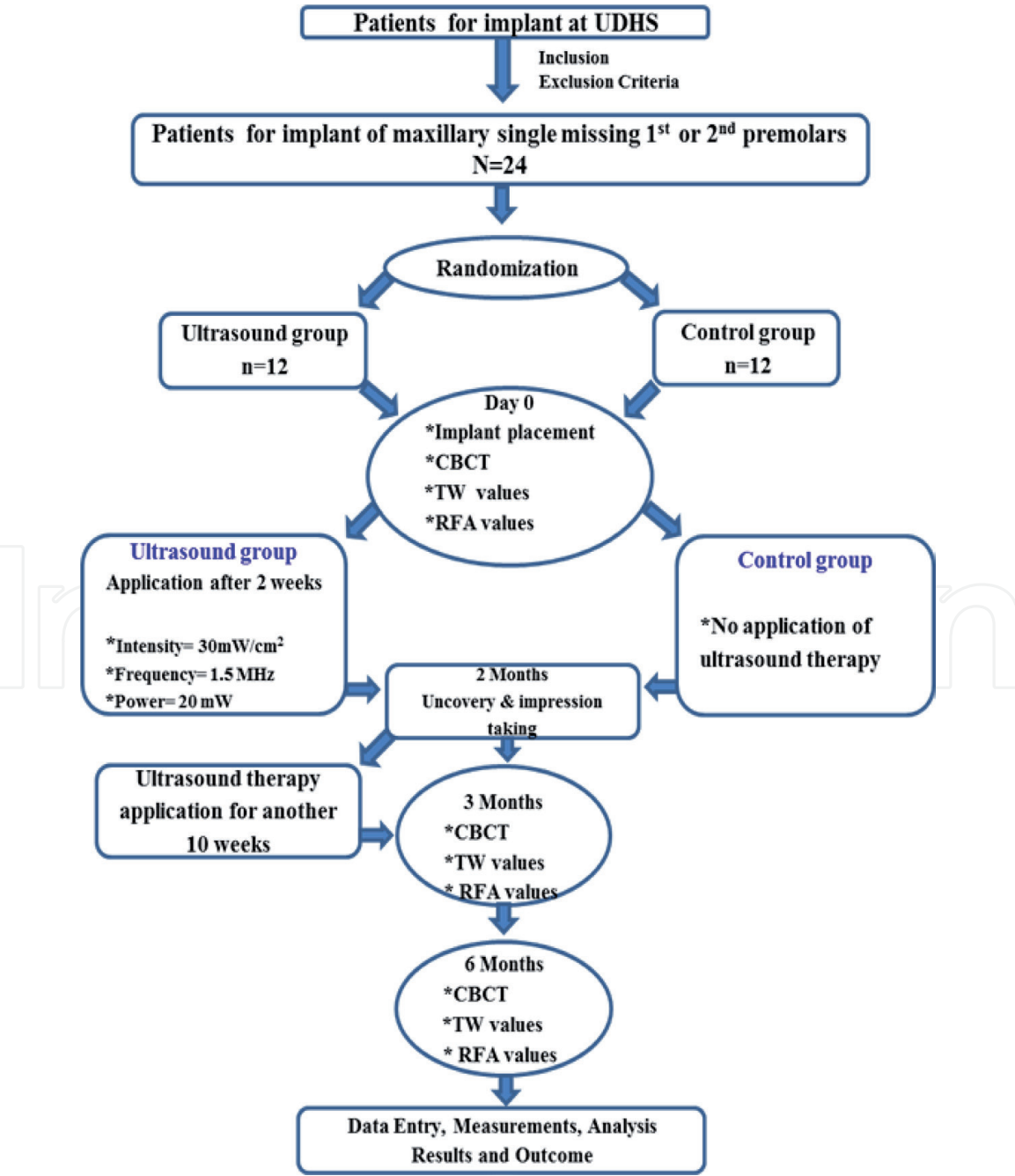
2.1 Study design

This study was a randomized controlled clinical trial (RCT) in which patients who visited the University Dental Hospital Sharjah (UDHS) for dental treatment and requested for oral rehabilitation of their missing teeth were selected for dental implant therapy. Those patients were examined in the oral surgery implant clinic and provided with new registration serial number. All the odd number patients were in the trial (ultrasound) group, and the even numbers were in the control group.

The aims and objectives of this study were to evaluate the effect of ultrasound therapy on osseointegration using clinical assessments, measurements of RFA values, and radiological assessments using linear measurement of marginal bone loss around the dental implant-supported prostheses using CBCT. The selected age groups were between 20 and 40 years old. All patients were recruited following specific criteria

of inclusion and exclusion. Patients of this study were divided into two groups, namely, ultrasound and control; each patient received one dental implant to replace single missing maxillary first or second premolar teeth. In the first trial group (ultrasound), the ultrasound therapy was applied twice a week for 20 minutes that commenced 2 weeks after stage I implant surgery and continued for 10 weeks. At 2 months, uncover and placement of gingival former for 10 days were carried on for all patients in both groups (ultrasound and control), then the impression taking was done for all patients, and installation of screw-retained porcelain to fused crown was performed 2 weeks later after the impression was taken. The same ultrasound therapy protocol was repeated 2 weeks after the crown installation for another 10 weeks. In the control group, patients were not subjected to application of ultrasound therapy. Clinical data collections composed of measurements of resonance frequency analysis (RFA) values using Osstell ISQ device and linear measurements of different variables using CBCT images taken immediately after the placement of the implant and during follow-up clinical examinations at 3 and 6 months postoperatively.

2.2 Flowchart



2.3 Clinical methods

2.3.1 Clinical assessment

Thorough medical and dental histories were taken from all patients presented in the study project. General clinical assessment of oral hygiene and gingival and periodontal health in terms of gingival color, contour, size, and consistency was documented. The height and width of the available bone around the potential site of the dental implant were assessed using a bone caliper.

2.3.2 Preoperative radiological screening assessment

An orthopantomogram (OPG) and intraoral periapical radiograph (IOPA) were taken preoperatively during patient selection and were kept in the patient's record; they gave an indication about the location and proximity of the vital structures and anatomical landmarks, bone quality, quantity and the presence of sufficient bone height and width in terms of mesiodistal dimension around the dental implant, absence of pathological lesions that may affect the outcome of dental implant success (periapical cysts, granulomas, osteomyelitis), and the angulation and position of the potential dental implant in relation to the adjacent teeth.

2.3.3 Operative techniques

All patients underwent two stages of implant surgeries. Stage I implant surgery was performed in which one SPI dental implant (THOMMEN Medical SPI ELEMENT MC INICELL) bone level type with a length of 9.5 mm and a diameter of 4 mm was positioned in the maxillary edentulous premolar area in each patient of the 22 sample size. A stage II implant surgery was carried on after 2 months of implant placement in which the dental implant had to be uncovered and impression was taken for crown installation.

2.3.3.1 Group I (ultrasound) group

1. The ultrasound group patients (n = 11) were then subjected to the application of low-intensity pulsed ultrasound 2 weeks following stage I implant surgery placement. The machine employed was Gymna Pulson® 330 Belgium (**Figure 2**). The intensity of ultrasound therapy used was 30 mW/cm² with a frequency of 1.5 MHz and temporal average power of 20 mW (**Table 1**). The therapy was delivered intraorally on the buccal part of the implant site for duration of 20 minutes twice a week starting 2 weeks after dental implant placement for the subsequent 10 weeks (**Figure 3**). At 2 months, uncover and placement of gingival former for 10 days were carried on, then the impression taking was done for all patients, and installation of screw-retained porcelain to fused crown was performed 2 weeks later after the impression was taken. The same ultrasound therapy protocol was repeated 2 weeks after the crown installation for another 10 weeks.
2. Clinical data collections composed of resonance frequency analysis (RFA) value measurements using Osstell ISQ device (**Figure 4**) and linear measurements of CBCT images at three different views were taken immediately after the placement of the implant and in the follow-up clinical examinations at 3 and 6 months postoperatively.



Figure 2.
The therapeutic ultrasound machine Gymna Pulson® 330 with intraoral probe and actual setting parameters on display.

Ultrasound frequency	1.5 MHz
Intensity (SATA)	30 mW/cm ²
Temporal average power	20 W

**Kerr et al. [65].*

Table 1.
Intraoral ultrasound device: technical specifications of the ultrasound signal.

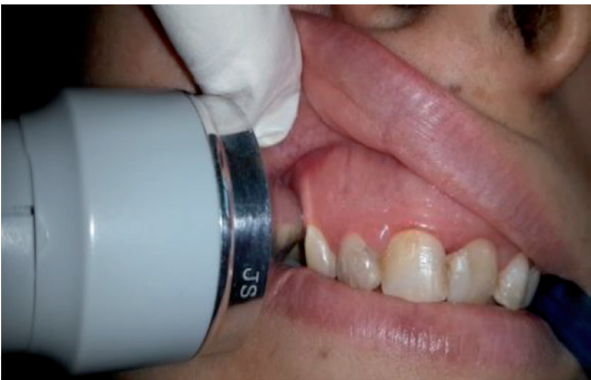

Figure 3.
Ultrasound therapy delivered using probe on the buccal aspect of the implant site.

2.3.3.2 Group II (control)

The control group patients (n = 11) were not subjected to the application of ultrasound therapy. Those patients went through two stages of implant placement surgery. At stage I implant surgery, the dental implant was placed to replace a single missing maxillary premolar tooth. Uncovery and impression were taken for the dental implant at stage II implant surgery, and supra-structure prosthetic construction comprising of screw-retained porcelain fused to metal crown was inserted at 2 months postoperatively. Clinical data collections composed of resonance frequency analysis (RFA) value measurements using Osstell ISQ device and linear measurements of CBCT images at three different views were taken immediately after the placement of the implant and in the follow-up clinical examinations at 3 and 6 months postoperatively.

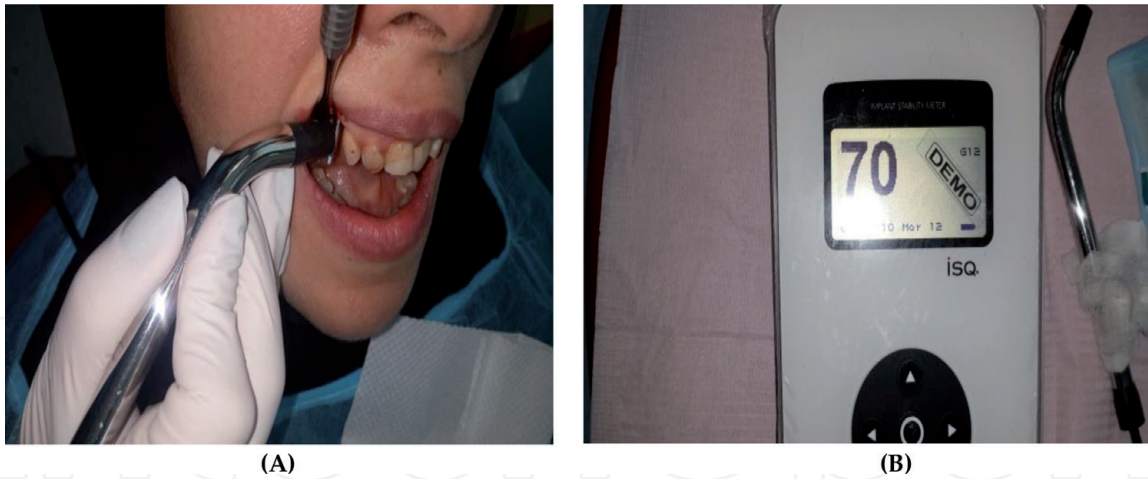

Figure 4.
RFA measurement procedure, the probe close to the SmartPeg™. (A) At bucco-palatal and mesio-distal directions, a value of 70 reveals as primary stability on the day of implant placement surgery (B).

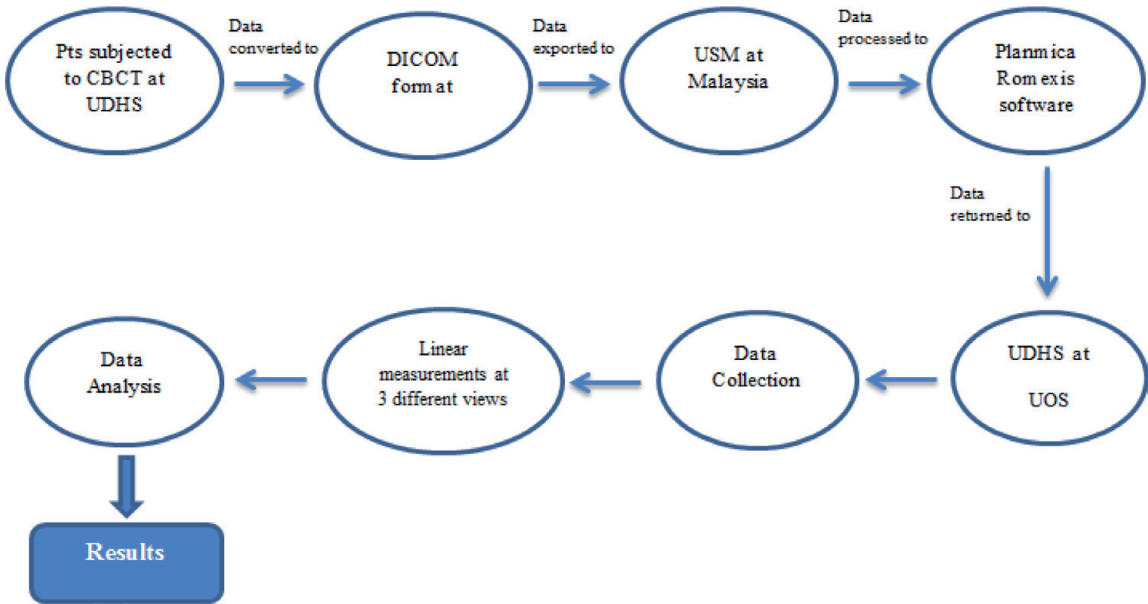


Figure 5.
Flowchart of steps for data transformation from UDHS to USM.

2.4 Data collection

The CBCT scan of each patient was carried out at the Radiographic Department, University Dental Hospital Sharjah, Sharjah, United Arab Emirates. All patients underwent computed tomography scans using GALILEOS; then, the data are converted to DICOM format in which they get exported to USM to be processed using Planmeca Promexis 3D software, and then the data returned to UDHS where data collection started (**Figure 5**).

The machine used produces X-rays in cone shape that centers on the X area of the detector. Its tube detector system can be rotated at 360° around the patient's head which exposes the patient for a series of images to be taken by GALILEOS/ Sirona Dental Systems Scan specifications summarized in **Table 2**.

The cone beam volumetric tomography (CBVT) X-ray unit used in this study was Planmeca ProMax 3D Max. It records the finest details of the patient's oral anatomy. It offers a maximum field view (Ø23 × 26 cm) which explores new possibilities in diagnostic radiology. It has an advanced imaging software system that increases its benefits.

Scanner name	GALILEOS Comfort ^{PLUS}
Manufacturer	Sirona Dental Systems GmbH, Bensheim, Germany
Detector type	Image intensifier (I.I.), Thales or Siemens
Focal spot size	0.5
Voltage kV	85
Current mA	10
Exposure time	14 seconds
Number of single exposures	200

Table 2.
Specifications of CBCT machine used in Dental clinic, UDHS.

CBVT technology is utilized in Planmeca ProMax 3D Max. It is an advanced, multipurpose, and active imaging machine. It can be utilized in various fields of dentistry that include maxillofacial surgery, implantology, endodontic, orthodontics, periodontics, and for the analysis of TMJ. The newly designed advanced ProMax has evolved into a classical 3D platform with CBVT.

Instead of a continuous beam, each volume is produced by throbbing the X-ray tube during the scanning. It reduces the dose as well as the rotational distortions during the scanning procedure. The total time required for scanning may be from 18 to 26 seconds. However, the exact exposure time may be only 3 seconds. Accurate and distortion-free image for 3D construction is produced by the ScI semiconductor flat panel. Correction for geometric magnification is not required for the images produced by Planmeca ProMax 3D Max.

To ensure immobilization of the patient during exposure, standard methods have been taken as follow:

1. Frankfort plane of the patient parallel to the floor.
2. Midsagittal plane perpendicular to the floor.
3. The patient was asked to bite on the bite block of the machine using the upper and lower incisors to standardize patient's position according to X-ray tube head rotation.

Lead apron was placed on each patient prior to exposure. All metallic objects (e.g., hairpins and earrings) and any intraoral removable prosthesis were removed.

3. Results

3.1 Radiological results using CBCT images

The orthopantomogram (OPG) was shown to be a useful tool for radiological screening of the patient during selection stage. Complex cases such as proximity to vital structures and inadequate bone height and width were excluded from the study. In the CBCT images obtained at day 0, there was adequate availability of bone height and width at the platform of dental implant for both groups. At 3 months, there was an increase of buccal plate thickness of 0.3–0.6 mm in the

ultrasound group compared to the control group. At 6 months, there was marginal bone loss around dental implant in the control group and marginal bone increase in height and width in the ultrasound group (**Figure 6A–E**).

3.2 Evaluation of marginal bone changes for both groups at different time intervals

CBCT images were obtained at day 0, 3, and 6 months follow-up. The marginal bone level was assessed and measured at three different views (coronal, sagittal, and axial) at time-point interval.

In the coronal view, there was an overgrowth of the bone width at corono-buccal and corono-palatal and less reduction of the bone height at apico-buccal and apico-palatal in the ultrasound group, but the bony tissue overgrowth was more pronounced at the buccal bone plate at 3 and 6 months rather than at the palatal bone plate. In the control group, the marginal bone loss was more in height and width than the in the ultrasound group (**Table 3**).

In the sagittal view, there was an overgrowth of the bone width at sagitto-mesial and sagitto-distal aspects of dental implants and less reduction of the bone height at apico-mesial and apico-distal in the ultrasound group, but the bony tissue overgrowth was more pronounced at the mesial bone plate at 3 and 6 months. In the control group, there was a reduction in the bone width and height from day 0 to 6 months (**Table 4**).

In the axial view, the bony tissue overgrowth was revealed more at the axio-buccal than axio-palatal at 3 and 6 months in the ultrasound group, while in the control group, there was marginal bone loss in all aspects of dental implant (**Table 5**).

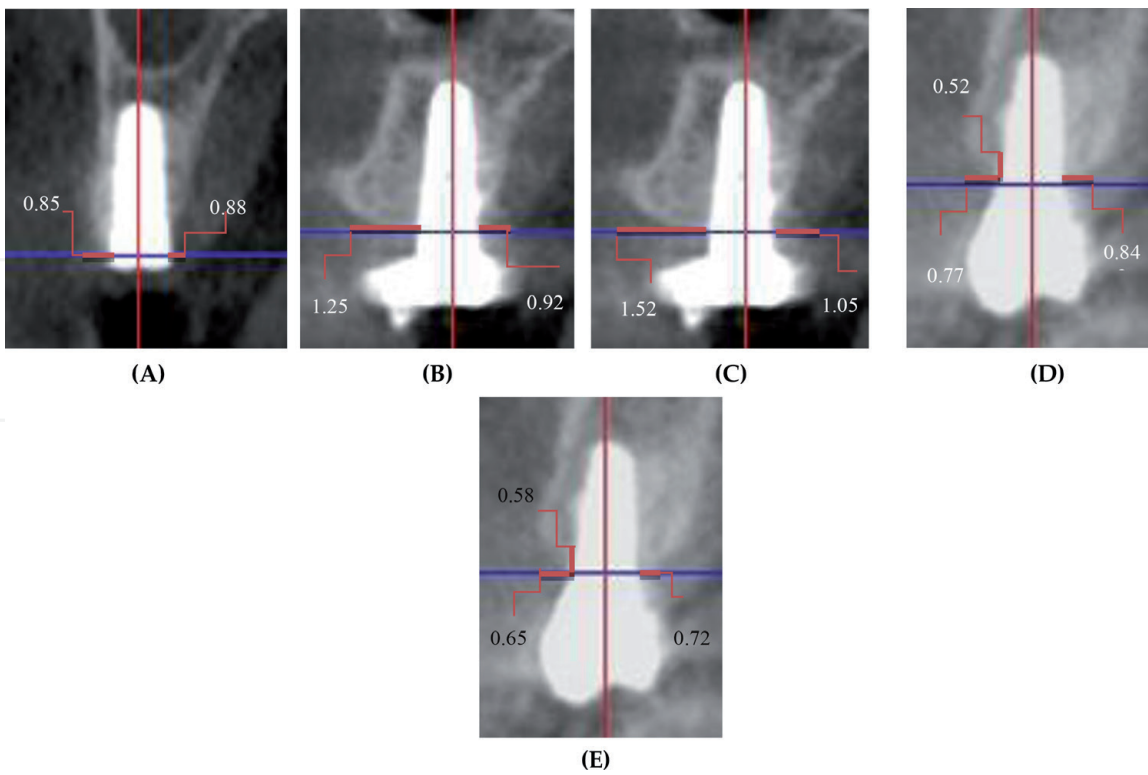


Figure 6. Representative CBCT images of marginal bone level in the coronal view. Both groups showed an adequate availability of bone height and width at day 0 (A). An overgrowth of buccal bone plate thickness observed in the ultrasound group at 3 and 6 months (B, C). Marginal bone loss around dental implant observed in the control group at 3 and 6 months (D, E).

Time		Ultrasound (n = 11)	Control (n = 11)
		Mean(SD)	Mean(SD)
Day 0	CB**	1.43 (0.24)	1.43 (0.50)
	CP#	1.44 (0.37)	1.42 (0.36)
3 months	CB	1.62 (0.36)	0.92 (0.25)
	CP	1.55 (0.34)	1.37 (0.26)
	AB†	1.20 (0.73)	1.20 (0.39)
	AP‡	0.89 (0.83)	0.87 (0.74)
6 months	CB	1.81 (0.41)	0.85 (0.30)
	CP	1.62 (0.22)	1.02 (0.34)
	AB	1.65 (0.73)	0.88 (0.29)
	AP	1.02 (0.62)	0.76 (0.53)

Day 0 readings for AB and AP are not shown since there are no parameters given.

**CB = corono-buccal

#CP = corono-palatal

†AB = apico-buccal

‡AP = apico-palatal

Table 3.
Descriptive statistics of linear measurements (mean, SD) of marginal bone changes between ultrasound and control groups in coronal view (values in millimeters).

Time		Ultrasound (n = 11)	Control (n = 11)
		Mean(SD)	Mean(SD)
Day 0	SM**	1.40 (0.30)	1.39 (0.41)
	SD#	1.41 (0.35)	1.38 (0.34)
3 months	SM	1.47 (0.39)	0.88 (0.26)
	SD	1.46 (0.20)	0.92 (0.25)
	AM†	0.89 (0.72)	0.83 (0.74)
	AD‡	0.87 (0.83)	0.84 (0.45)
6 months	SM	1.66 (0.57)	0.65 (0.29)
	SD	1.62 (0.23)	0.78 (0.30)
	AM	1.18 (0.73)	0.75 (0.32)
	AD	1.12 (0.60)	0.71 (0.40)

Day 0 readings for AM and AD are not shown since there are no parameters given.

**SM = sagitto-mesial

#SD = sagitto-distal

†AM = apico-mesial

‡AD = apico-distal.

Table 4.
Descriptive statistics of linear measurements (mean, SD) of marginal bone changes between ultrasound and control groups in sagittal view (values in millimeters).

Time		Ultrasound (n = 11)	Control (n = 11)
		Mean(SD)	Mean(SD)
Day 0	AM ^{**}	1.41 (0.31)	1.40 (0.44)
	AD [#]	1.42 (0.37)	1.40 (0.33)
	AB [†]	1.44 (0.37)	1.42 (0.52)
	AP [‡]	1.45 (0.47)	1.43 (0.36)
3 months	AM	1.52 (0.39)	0.87 (0.25)
	AD	1.48 (0.19)	0.89 (0.27)
	AB	1.60 (0.37)	0.90 (0.30)
	AP	1.53 (0.35)	1.35 (0.18)
6 months	AM	1.66 (0.57)	0.63 (0.30)
	AD	1.63 (0.21)	0.72 (0.30)
	AB	1.82 (0.41)	0.84 (0.22)
	AP	1.63 (0.21)	0.98 (0.34)

^{**}AM = axio-mesial
[#]AD = axio-distal
[†]AB = axio-buccal
[‡]AP = axio-palatal

Table 5.
Descriptive statistics of linear measurements (mean, SD) of marginal bone changes between ultrasound and control groups in axial view (values in millimeters).

3.3 Comparison of marginal bone changes within each group at three different views

In the coronal view, within the ultrasound group, there was statistically significant increase in the buccal and palatal bones' thickness (height and width) from day 0 to 3 months, day 0 and 6 months, and from 3 to 6 months as p value was less than 0.05, but it was more pronounced at the buccal bone plate, while in the control group, there was no statistically significant increase in bone thickness, and there was marginal bone loss at all aspects of 9° dental implant.

In the sagittal view, within the ultrasound group, there was statistically significant increase in the mesial and distal bones' thickness (height and width) from day 0 to month 3, day 0 and month 6, and from month 3 to month 6 as p value was less than 0.05, while in the control group, there was no statistically significant increase in bone thickness, and there was marginal bone loss at all aspects of dental implant.

In the axial view, within the ultrasound group, there was statistically significant increase in the buccal, palatal, mesial, and distal bones' thickness (height and width) from day 0 to 3 months, day 0 and 6 months, and from 3 months to month 6 as p value was less than 0.05, while in the control group, there was no statistically significant increase in bone thickness.

3.4 Comparison of marginal bone changes between two groups at three different views

In the coronal view, there was statistically significant increase in buccal and palatal bone width between two groups (ultrasound and control) at 3 and 6 months

as p value was less than 0.05. Thus, this increase in bone plate width is contributed to ultrasound therapy. There was no statistically significant increase in buccal and palatal bone height at 3 months between ultrasound and control groups, but there was statistically significant increase in buccal and palatal bone height at 6 months. Thus, this increase in bone plate height is contributed by ultrasound therapy.

In the sagittal view, there was statistically significant increase in mesial and distal bone plates' width between two groups (ultrasound and control) at 3 and 6 months as p value was less than 0.05. Thus, this increase in bone plate thickness is contributed by ultrasound therapy. There was no statistically significant increase in mesial and distal bone height at 3 months between ultrasound and control groups, but there was statistically significant increase in mesial and distal bone height at 6 months. Thus, this increase in bone plate height is contributed by ultrasound therapy.

In the axial view, there was statistically significant increase in buccal, palatal, mesial, and distal bone plates' width between two groups (ultrasound and control) at 3 and 6 months as p value was less than 0.05. Thus, this increase in bone plate thickness is contributed by ultrasound therapy.

4. Discussion

4.1 Introduction of marginal bone loss around dental implant

Marginal bone loss is considered to be an inevitable risk factor in implant therapy. The reduction in height and width of marginal bone level affects the success rate of implant treatment in terms of esthetic and function.

The majority of marginal bone loss occurs in the first year after implant placement [67]. Thus, the clinical crown-to-implant ratio rises with time to become more unfavorable as years go by. However, the etiology of long-term marginal bone loss or late implant failure seems to be of different origin and prone to peri-implantitis or occlusal overload [68]. It is important to consider multiple factors together in assessing implant failure rates as interactive effects may be observed in the establishment and maintenance of osseointegration [69, 70]. Thus, in the present study, attempts were made to control the relevant confounding variables (patient gender and age, implant location, implant diameter and neck design, insertion torque, insertion depth, and crown-to-implant ratios).

In this study project, we tried to measure the marginal bone level around the implant and its stability both at the time of implant placement and at the time of loading. For this reason we chose the 3- and 6-month intervals to examine the marginal bone level and implant stability after soft and hard tissue maturation and early bone remodeling [71].

Ultrasound is the generation of sound waves with a frequency above the limit of human audibility of 20 kHz that transfers mechanical energy into the tissues; it is used extensively in sports medicine and physiotherapy. Therapeutic ultrasound can induce angiogenic and bone morphogenetic factors and bone formation in vitro [72].

Dinno et al. [73] demonstrated that intensities of ultrasound of less than 100 mW/cm² spatial average and temporal average were nonthermal. Duarte [63] and Pilla et al. [74] reported that low-intensity ultrasound treatment in the range of 30–57 mW/cm² yielded minimal temperature changes when applied to the site of a bone fracture. Application of low-intensity pulsed ultrasound (30 mW/cm²) was considered to have little thermal effect.

4.2 Clinical evaluation of application of ultrasound therapy

All patients in the ultrasound group tolerated the ultrasound therapy very well. The therapy was conducted over 20 minutes comfortably without any rejection from the patients. The results showed that the ultrasound therapy with the intensity set at 30 mW/cm^2 generated minimum heat that did not cause discomfort for the patients. Furthermore, the color of the gingival soft tissue remains pink and did not change to erythematic state at the end of the procedure which further proves there was no inflammation and untoward tissue response following the therapy. Therefore, the pain symptoms from patients were minimal as shown by minimal need for analgesia, and healing of the soft tissue wound in the ultrasound group was excellent. These clinical findings demonstrate wide acceptance of patients toward postoperative ultrasound therapy. Kamath et al. [75] in his study on the effect of LIPUS on healing of femur fracture revealed that there was more significant callous formation at the early stage of femur fracture in the LIPUS group than in the control group. Therefore, even in other parts of the body like femur, there are good results when LIPUS is applied.

In view of the increasing use of high-intensity and low-frequency ultrasonic technology, in medicine and in surgery, better understanding of the benefits or side effects of US application is significant in order to establish appropriate clinical studies. LIPUS has disadvantages besides the advantages as mentioned. Erdogan and Esen [76] showed that the effects of ultrasound therapy on growing bones and brain tissues are unclear. Thus, its use in children and in skull bones should be avoided. Its use in sites with suspected neoplasia and acute infections is contraindicated because of possible accelerated disease progression. Patients should be evaluated for allergic reactions to the coupling gel, and patients with cardiac pacemakers should avoid ultrasound treatment because of possible interaction with the ultrasound signals specially when using US with both high-intensity and high-frequency waves.

Miller et al. [77] mentioned that the induced heat by US is the result of the absorption of US energy in biological tissue and the heat can be concentrated by focused beams until tissue is coagulated for the purpose of tissue ablation. Unlike ultrasound for medical imaging (which transmits ultrasonic waves and processes a returning echo to generate an image), therapeutic ultrasound is a one-way energy delivery that might cause harmful effect in a cumulative way into the tissue, which utilizes a crystal sound head to transmit acoustic waves at 1–3 MHz and at amplitude densities between 0.1 and 3 W/cm^2 [78]. US heating, which can lead to irreversible tissue changes, follows an inverse time-temperature relationship. Depending on the temperature gradients, the effects from ultrasound exposure can include mild heating, coagulative or liquefactive necrosis, tissue vaporization, or all three [77]. Angle et al. [79] demonstrated that the therapeutic ultrasound with frequencies varying between 0.5 and 1.5 MHz and intensities 30 – 200 mW/cm^2 is known to promote healing, bone deposition, and growth. Nevertheless, therapeutic ultrasound is proposed to deliver energy to deep tissue sites through ultrasonic waves, to produce increases in tissue temperature or nonthermal physiologic changes [78].

Ebadi et al. [80] explained that ultrasonic energy causes soft tissue molecules to vibrate from exposure to the acoustic wave. This increased molecular motion generates frictional heat, thus increasing tissue temperature. The thermal effects of ultrasound are proposed to increase collagen extensibility, increase nerve conduction velocity, alter local vascular perfusion, increase enzymatic activity, alter contractile activity of skeletal muscle, and increase nociceptive threshold [78].

However, in our study, the intensity of LIPUS used was 30 mW/cm^2 , and the duration of application was only for 20 minutes, and this treatment was commenced 2 weeks after the acute inflammatory phase has subsided. We

feel that this dosage of US therapy is harmless to the active cells in the healing wound which was in the proliferative phase. The dose recommended may be harmful to the cells in the healing wound because they are vulnerable to damage from heat generation or prolonged treatment duration. Therefore, although the mechanotransduction mechanism for cell stimulation following US therapy is an acceptable phenomenon, it may only work favorably within certain limitations of the delivered energy.

4.3 Evaluation of marginal bone level

CBCT images showed adequate availability of bone height and width at the dental implant platform at day 0 for both groups at the time of implant placement. In this study, results obtained using CBCT images were reliable for linear measurements of bone thickness in height and width for both ultrasound-treated group and control group. CBCT enables us to expose the patient to low radiation doses, giving more comfort, and it is an economical procedure [81]. At 3 months, there was an increase of the mean difference of buccal bone plate width of 0.19 mm in the ultrasound group compared to the control group. At 6 months, there was a mean difference marginal bone loss of 0.58 mm in width of the buccal bone plate around the dental implant platform in the control group, while there was 0.38 mm increase in the mean difference of buccal bone width in the ultrasound group. These findings were consistent with the previous study by Chen who investigated the effect of LIPUS on bone regeneration in the rat parietal bone defects [26]. In Chen study, the defects were analyzed with micro-CT (μ CT) and then histologically, which demonstrated new bone formation with the newly formed thick and matured bone compared to the one of the control group.

The justification of using LIPUS in this study is to accelerate the bone wound healing processes within the region of interest (ROI) which is the region replacing single missing maxillary premolar following trauma to the bone as implant placement surgery is considered to be a traumatic procedure even though the surgery is minimally invasive to the bone. Our aim in this study is to mimic what happened in natural tissue repair by inducing, triggering, and provocation of the cells related to bone formation by encouragement of mechanotransduction pathways involved in cell responses. These responses include integrin/mitogen-activated protein kinase (MAPK) and other kinase signaling pathways, gap-junctional intercellular communication, upregulation and clustering of integrins, involvement of the COX-2/PGE2 and iNOS/NO pathways, and activation of mechanoreceptor [44]. Mechanotransduction involves various signal transduction pathways, including the activation of ion channels and other mechanoreceptors in the membrane of the bone cell, resulting in gene regulation in the nucleus [42].

Based on time intensity and period of exposure of cells to waves of ultrasound, LIPUS can recruit mesenchymal stem cells from neighboring tissues and other sites in the body in attractive processes (chemotactic) with other biomedical pro-inflammatory mediators (growth factors) that are considered necessary in bone wound healing processes and trigger it from inactive form to active phase when LIPUS is used. This suggests that LIPUS is able to enhance osteogenesis and angiogenesis in vivo and in vitro as was well documented by literature review that angiogenesis precede osteogenesis process [54]. Angiogenesis is closely associated with osteogenesis where reciprocal interactions between endothelial and osteoblast cells play an important role in bone regeneration [55].

In our study, the marginal bone level was assessed and measured at three different views (coronal, sagittal, and axial) in which four points were located and

measured per implant site (corono-buccal, corono-palatal, apico-buccal, apico-palatal, sagitto-mesial, sagitto-distal, apico-mesial, apico-distal, axio-buccal, axio-palatal, axio-mesial, and axio-distal), respectively, and at three different time intervals postoperatively at day 0, 3, and 6 months. The results of this study showed an increase in buccal bone width from 1.43 mm at day 0 to 1.81 mm at 6 months which revealed that the mean difference of buccal bone plate width increased by 0.38 mm, while the palatal bone mean difference width was also increased by 0.18 mm at 6 months. In the sagittal view, there was an increase of mean difference of 0.26 mm at the mesial aspect of the dental implant at 6 months in the ultrasound group compared to the control group that had marginal bone loss from 1.43 mm at day 0 to 0.85 mm at 6 months at the buccal bone plate in the coronal view. The reason why the height and width of bone thickness had increased in the ultrasound compared to the control is that LIPUS can promote bone healing and repair by inducing osteogenesis and angiogenesis. Earlier work has shown that the therapeutic range of US stimulates bone formation, osteoblast proliferation, and the synthesis of angiogenic vascular endothelial growth factor (VEGF), basic fibroblast growth factor (FGF), and interleukin 8 [72, 82]. Ramli et al. [83] have proven that ultrasound should be considered to have angiogenic and osteogenic values in their in vivo study looking at ultrasound effects on angiogenesis using the chick chorioallantoic membrane. In vitro ultrasound has also been shown to upregulate the release of the osteogenic cytokine OPG and downregulate RANKL, the ligand of the receptor activator nuclear factor kappa B, which recruits and activates osteoclasts [83].

In this study, the transducer was applied on the buccal aspect of the dental implant very close to the buccal bone plate and showed clinically that at 1.5 MHz frequency, a penetration of up to 2 cm is possible, thus influencing the palatal plate. Ramli et al. [83] demonstrated that the traditional 1- to 3-MHz frequency of ultrasound therapy has a penetration of up to 2 cm. Doan et al. [72] reported that the best effect of therapeutic ultrasound on angiogenesis occurs with intensities between 15 and 30 mW/cm² and a frequency of 45 kHz, as the long wave machine has a theoretical advantage of penetrating tissues up to 10 cm.

Results of the control group showed increased loss of bone height from 1.20 mm at 3 months to 0.88 mm at 6 months at the apico-buccal aspect of the dental implant and increased marginal bone loss (MBL) in width from 1.43 mm at day 0 to 0.85 mm at 6 months as compared with LIPUS-treated group. It reveals that LIPUS has a positive effect on the healing of bone, and the loss of marginal bone in the control group was contributed by not using US therapy. This finding is consistent with those of [26, 84–86].

Angle et al. [79] explained in his vitro study, using rat bone marrow stromal cells that the LIPUS intensities below 30 mW/cm² are able to provoke phenotypic responses in bone cells. They cultured bone cells under defined conditions with intensities of 2, 15, and 30 mW/cm², compared them with the control group (0 mW/cm²), and then studied them at early (cell activation), middle (differentiation into osteogenic cells), and late (biological mineralization) stages of osteogenic differentiation. They concluded that LIPUS with intensities of 2, 15, and 30 mW/cm² showed a positive effect on osteogenic differentiation of rat bone marrow stromal cells in early stage compared with the control group. Monden et al. [87] also suggested that the injured bone may be treated with LIPUS, as LIPUS has the capability to induce the cellular as well as molecular pathways of bone healing. LIPUS treatment matures the newly formed bone in the cortical bone area producing bone differentiation markers, osteocalcin (OCN) and osteopontin (OPN), and reduces the depression by enhancing the periosteal cellular

differentiation. In vitro studies have shown that LIPUS leads to the increased expression of genes related to the bone formation. These genes include osteocalcin, aggrecan, bone sialoprotein, insulin-like growth factor-I, collagen types I and X, transforming growth factor beta, alkaline phosphatase, and runt-related gene-2 [88, 89].

Additionally, LIPUS treatment also promotes the synthesis of protein and uptake of calcium by osteoblasts. LIPUS treatment also plays an important role in the remodeling of the bone by stimulating the cyclooxygenase pathway. LIPUS increases the expression of COX-2 gene that promotes the synthesis of prostaglandin E2 (PGE2) in the osteoblasts [88, 89].

Huang et al. [90] concluded in his recent study in vitro that the LIPUS stimulates the expression of BMP-2 which means positive effects of LIPUS on osteogenesis. In vitro study by Sun et al. [91] showed that LIPUS upregulated osteoblasts and downregulated osteoclasts in the rat alveolar mononuclear cells. Lu et al. [92] explained that the mechanical signals from LIPUS could stimulate osteoblasts by means of gene expression and stimulated proteins that were translated by these genes causing activation of apoptotic genes and osteogenesis in acceleration of the tissue remodeling and expedite clinical outcomes as we have seen in our current study.

Iwanabe et al. [93] demonstrated in his recent study in vitro that the number of cells at 5 days after LIPUS exposure was significantly higher than that of the control, while that at 7 days was about 35% higher than that of the control. This means that LIPUS has the potential to be an effective agent in inducing migration, proliferation, and cell differentiation.

In vitro as well as in vivo studies, using animal models showed that LIPUS has stimulatory effect on cellular activity, release of cytokines, and bone healing [94]. Cell physiology is directly affected by LIPUS. It increases the uptake of calcium by the developing cartilage and bone cells in the culture. It also stimulates a large number of genes that help in the process of healing [62]. Barzelai et al. [95] reported that LIPUS not only modulates the expression of genes, but it also enhances the process of angiogenesis and increases the flow of blood at the site of fracture.

4.4 Clinical significance

- LIPUS may be utilized as treatment modality to save dental implant with questionable primary stability during stage I implant placement, with the aim of achieving adequate osseointegration and improving implant success.
- LIPUS can be recruited to promote and accelerate healing time particularly in patients with medical conditions such as diabetes mellitus and other diseases.
- The clinical results shown in this study confirmed that low-intensity pulsed ultrasound (LIPUS) presents low toxicity, noninvasiveness, and repeated applicability. The risk of thermal injury is unfounded.
- Application of LIPUS on dental implant wound at 2 weeks postoperative seems to be a favorable time when the acute inflammatory phase has subsided and the cellular proliferative phase has actively began.
- RFA gives clear image about the stability of the implant and the condition of the bone around implant.

5. Conclusion

5.1 Summary and conclusion

Animal experiments using LIPUS for healing of wounds have shown effective and favorable results with histological evidence. The effects of the ultrasound waves on the cell and molecular biology phenomena of wound healing have further confirmed the fundamental mechanisms underlying this interesting wound healing treatment modality. However, we still lack clinical studies in this field, and our study is one of the few clinical trials of the effect of ultrasound therapy on osseointegration and marginal bone loss around implant-supported prosthesis, which showed favorable results. We have compared and contrasted two groups of patients receiving implant therapy where the first group was given LIPUS during the early healing period and post loading as an additional treatment modality and the second group was allowed to heal in the conventional way. Comparative bone thickness measurements using CBCT images and implant stability measurements using RFA values showed consistently higher stability with an increase in bone thickness (height and width), and the ultrasound therapy group demonstrated much higher implant stability values than the control group.

The overall clinical results contribute to the following findings:

- LIPUS enhances bone formation around dental implants as confirmed by radiological investigations, RFA values, and pre and post prosthetic loading behaviors.
- LIPUS technique employed in this study promoted increased in buccal bone plate height and width much more than that occurred in the palatal side. This may be attributed to the design of the US delivery probe.
- With an increase in bone height and width, we expect a simultaneous increase in bone-implant contact that leads to higher osseointegration as evidenced by RFA values.

Acknowledgements

This work was supported by Research University Individual (RUI) grant, account no. 1001/PPSG/812207 from Universiti Sains Malaysia (USM).

Abbreviations

μCT	micro-CT
2-D	two dimensional
3-D	three dimensional
AB	apico-buccal
AD	apico-distal
ALP	alkaline phosphatase
AM	apico-mesial
AP	apico-palatal
BMP	bone morphogenetic proteins
CB	corono-buccal

CBCT	cone beam computed tomography
COX-2	cyclooxygenase-2
CP	corono-palatal
DBM	demineralized bone matrix
ECs	endothelia cells
Erk	extracellular signal-regulated kinase
et al.	and another people
FAK	focal adhesion kinase
FGF2	fibroblast growth factor-2
HPDLC	human periodontal ligament cells
iNOS/NO	inducible nitric oxide synthase
ISQ	implant stability quotient
MARK	mitogen-activated protein kinase
MBL	marginal bone loss
MSCs	mesenchymal stem cells
OCN	osteocalcin
OPN	osteopontin
OSX	osteoblast-specific transcription factor Osterix
PGE2	prostaglandin E2
RFA	resonance frequency analysis
ROI	region of interest
SD	sagitto-distal
SM	sagitto-mesial
UDHS	University Dental Hospital Sharjah
US	ultrasound
USM	Universiti Sains Malaysia
VEGF	vascular endothelial growth factor
VSCCs	voltage-sensitive calcium channels
β	beta

Author details

Elaf Akram Abdulhameed^{1,2*}, Marzuki Omar² and A.R. Samsudin¹

¹ Sharjah Institute for Medical Research, University of Sharjah, UAE

² University Science Malaysia (USM), Malaysia

*Address all correspondence to: elaf.alzubaidi@gmail.com

IntechOpen

© 2019 The Author(s). Licensee IntechOpen. This chapter is distributed under the terms of the Creative Commons Attribution License (<http://creativecommons.org/licenses/by/3.0>), which permits unrestricted use, distribution, and reproduction in any medium, provided the original work is properly cited. 

References

- [1] Jayesh RS, Dhinakarsamy V. Osseointegration. *Journal of Pharmacy and Bioallied Sciences*. 2015;7(1):226-232
- [2] Kishore K, Anne G, Mohan T, Kumar K, Dev J, Rakesh R, et al. Evaluation of crestal bone loss around two different implant systems supporting a mandibular overdenture-a clinical study. *Indian Journal of Dental Sciences*. 2014;6(2):001-004. ISSN: 0976-4003
- [3] Eriksson A. The long-term efficacy of currently used dental implants: A review and proposed criteria of success. *The International Journal of Oral and Maxillofacial Implants*. 1986;1:11-25
- [4] Jadhav R, Sabane A, Thareja A, Gandhi P. Dental implant in diabetic patients: Statement of facts. *Indian Journal of Oral Sciences*. 2015;6(2):47. DOI: 10.4103/0976-6944.162628
- [5] Mavrogenis A, Dimitriou R, Parvizi J, Babis G. Biology of implant osseointegration. *Journal of Musculoskeletal and Neuronal Interactions*. 2009;9(2):61-71
- [6] Parithimarkalaignan S, Padmanabhan TV. Osseointegration: An update. *Journal of Indian Prosthodontic Society*. 2013;13(1):2-6. DOI: 10.1007/s13191-013-0252-z
- [7] Fyhrie D. Summary—Measuring “bone quality”. *Journal of Musculoskeletal and Neuronal Interactions*. 2004;5(4):318-320
- [8] Ibrahim N, Parsa A, Hassan B, van der Stelt P, Wismeijer D. Diagnostic imaging of trabecular bone microstructure for oral implants: A literature review. *Dento Maxillo Facial Radiology*. 2013;42(3):20120075. DOI: 10.1259/dmfr.20120075
- [9] Sievänen H, Kannus P, Järvinen TL. Bone quality: An empty term. *PLoS Medicine*. 2007;4(3):e27. DOI: 10.1371/journal.pmed.0040027
- [10] Marcantonio C, Nicoli LG, Junior E, Zandim-Barcelos DL. Prevalence and possible risk factors of peri-implantitis: A concept review. *The Journal of Contemporary Dental Practice*. 2015;16(9):750-757
- [11] Åstrand P, Engquist B, Dahlgren S, Gröndahl K, Engquist E, Feldmann H. Astra Tech and Brånemark system implants: A 5-year prospective study of marginal bone reactions. *Clinical Oral Implants Research*. 2004;15(4):413-420
- [12] Enkling N, Johren P, Katsoulis J, Bayer S, Jervoe-Storm PM, Mericske-Stern R, et al. Influence of platform switching on bone-level alterations: A three-year randomized clinical trial. *Journal of Dental Research*. 2013;92(12 Suppl):139S-145S. DOI: 10.1177/0022034513504953
- [13] Tadi DP, Piniseti S, Gujjalapudi M, Kakaraparthi S, Kolasani B, Vadapalli SHB. Evaluation of initial stability and crestal bone loss in immediate implant placement: An in vivo study. *Journal of International Society of Preventive and Community Dentistry*. 2014;4(3):139-144
- [14] Nandal S, Ghalaut P, Shekhawat H. A radiological evaluation of marginal bone around dental implants: An in-vivo study. *National Journal of Maxillofacial Surgery*. 2014;5(2):126-137. DOI: 10.4103/0975-5950.154813
- [15] Salvi GE, Lang NP. Diagnostic parameters for monitoring peri-implant conditions. *The International Journal of Oral and Maxillofacial Implants*. 2004;19(7):116-127

- [16] Hof M, Pommer B, Zukic N, Vasak C, Lorenzoni M, Zechner W. Influence of prosthetic parameters on peri-implant bone resorption in the first year of loading: A multi-factorial analysis. *Clinical Implant Dentistry and Related Research*. 2015;17(1):183-191. DOI: 10.1111/cid.12153
- [17] Al-Juboori MJ, Ab Rahman S, Hassan A, Bin Ismail IH, Tawfiq OF. What is the effect of initial implant position on the crestal bone level in flap and flapless technique during healing period? *Journal of Periodontal and Implant Science*. 2013;43(4):153-159. DOI: 10.5051/jpis.2013.43.4.153
- [18] Al-Juboori M, Bin AS, Jassan A. Comparison of flapless and conventional flap and the effect on crestal bone resorption during a 12-week healing period. *Dental Implantology Update*. 2012;23(2):9-16
- [19] Becker W, Wikesjo UM, Sennerby L, Qahash M, Hujoel P, Goldstein M, et al. Histologic evaluation of implants following flapless and flapped surgery: A study in canines. *Journal of Periodontology*. 2006;77(10):1717-1722. DOI: 10.1902/jop.2006.060090
- [20] Gomez-Roman G. Influence of flap design on peri-implant interproximal crestal bone loss around single-tooth implants. *The International Journal of Oral and Maxillofacial Implants*. 2001;16(1):61-67
- [21] Jeong SM, Choi BH, Li J, Xuan F. Simultaneous flapless implant placement and peri-implant defect correction: An experimental pilot study in dogs. *Journal of Periodontology*. 2008;79(5):876-880. DOI: 10.1902/jop.2008.070539
- [22] Levin MP, Grower MF, Cutright DE, Getter L. The effects of length of surgery on healing of full and partial thickness flaps. *Journal of Oral Pathology and Medicine*. 1977;6(3):152-160
- [23] Ozan O, Turkyilmaz I, Yilmaz B. A preliminary report of patients treated with early loaded implants using computerized tomography-guided surgical stents: Flapless versus conventional flapped surgery. *Journal of Oral Rehabilitation*. 2007;34(11):835-840
- [24] Rego EB, Takata T, Tanne K, Tanaka E. Current status of low intensity pulsed ultrasound for dental purposes. *The Open Dentistry Journal*. 2012;6(1):220-225
- [25] Della Rocca GJ. The science of ultrasound therapy for fracture healing. *Indian journal of orthopaedics*. 2009;43(2):121-126
- [26] Chen K, Hao J, Noritake K, Yamashita Y, Kuroda S, Kasugai S. Effects of low intensity pulsed ultrasound stimulation on bone regeneration in rat parietal bone defect model. *Journal of Regenerative Medicine*. 2013;2(1):8-14
- [27] Tanzer M, Kantor S, Bobyn J. Enhancement of bone growth into porous intramedullary implants using non-invasive low intensity ultrasound. *Journal of Orthopaedic Research*. 2001;19(2):195-199
- [28] Cameron MH. *Physical Agents in Rehabilitation: From Research to Practice*. Vol. 4. China: Elsevier Health Sciences; 2013
- [29] Yang PC. Ultrasound-guided transthoracic biopsy of peripheral lung, pleural, and chest-wall lesions. *Journal of Thoracic Imaging*. 1997;12(4):272-284
- [30] Yang PC. Ultrasound-guided transthoracic biopsy of the chest. *Radiologic Clinics of North America*. 2000;38(2):323-343

- [31] Yang PC, Lee YC, Yu CJ, Chang DB, Wu HD, Lee LN, et al. Ultrasonographically guided biopsy of thoracic tumors. A comparison of large-bore cutting biopsy with fine-needle aspiration. *Cancer*. 1992;**69**(10):2553-2560
- [32] Harris M. The conservative management of osteoradionecrosis of the mandible with ultrasound therapy. *British Journal of Oral and Maxillofacial Surgery*. 1992;**30**(5):313-318
- [33] Nelson AB, Krispel CM, Sekirnjak C, du Lac S. Long-lasting increases in intrinsic excitability triggered by inhibition. *Neuron*. 2003;**40**(3):609-620
- [34] Leung K, Cheung W, Zhang C, Lee K, Lo H. Low intensity pulsed ultrasound stimulates osteogenic activity of human periosteal cells. *Clinical Orthopaedics and Related Research*. 2004;**418**:253-259
- [35] Yang KH, Parvizi J, Wang SJ, Lewallen DG, Kinnick RR, Greenleaf JF, et al. Exposure to low-intensity ultrasound increases aggrecan gene expression in a rat femur fracture model. *Journal of Orthopaedic Research*. 1996;**14**(5):802-809
- [36] Yang RS, Lin WL, Chen YZ, Tang CH, Huang TH, Lu BY, et al. Regulation by ultrasound treatment on the integrin expression and differentiation of osteoblasts. *Bone*. 2005;**36**(2):276-283
- [37] John P, Poulouse C, George B. Therapeutic ultrasound in fracture healing: The mechanism of osteoinduction. *Indian Journal of Orthopaedics*. 2008;**42**(4):444
- [38] Ustun Y, Erdogan O, Kurkcu M, Akova T, Damlar İ. Effects of low-intensity pulsed ultrasound on dental implant osseointegration: A preliminary report. *European Journal of Dentistry*. 2008;**2**:254-262
- [39] Gardinier JD, Majumdar S, Duncan RL, Wang L. Cyclic hydraulic pressure and fluid flow differentially modulate cytoskeleton re-organization in MC3T3 osteoblasts. *Cellular and Molecular Bioengineering*. 2009;**2**(1):133-143
- [40] Katiyar A, Duncan RL, Sarkar K. Ultrasound stimulation increases proliferation of MC3T3-E1 preosteoblast-like cells. *Journal of Therapeutic Ultrasound*. 2014;**2**(1):1-10. DOI: 10.1186/2050-5736-1182-1181
- [41] Ingber D. Integrins as mechanochemical transducers. *Current Opinion in Cell Biology*. 1991;**3**(5):841-848
- [42] Liedert A, Claes L, Ignatius A. Signal transduction pathways involved in mechanotransduction in osteoblastic and mesenchymal stem cells. In: *Mechanosensitive Ion Channels*. Springer; 2008. pp. 253-265
- [43] Gillespie PG, Walker RG. Molecular basis of mechanosensory transduction. *Nature*. 2001;**413**(6852):194-202
- [44] Padilla F, Puts R, Vico L, Raum K. Stimulation of bone repair with ultrasound: A review of the possible mechanic effects. *Ultrasonics*. 2014;**54**(5):1125-1145
- [45] Sato M, Nagata K, Kuroda S, Horiuchi S, Nakamura T, Karima M, et al. Low-intensity pulsed ultrasound activates integrin-mediated mechanotransduction pathway in synovial cells. *Annals of Biomedical Engineering*. 2014;**42**(10):2156-2163
- [46] Argintar E, Edwards S, Delahay J. Bone morphogenetic proteins in orthopaedic trauma surgery. *Injury International Journal*. 2011;**42**(8):730-734
- [47] Tang CH, Yang RS, Huang TH, Lu DY, Chuang WJ, Huang TF, et al.

- Ultrasound stimulates cyclooxygenase-2 expression and increases bone formation through integrin, focal adhesion kinase, phosphatidylinositol 3-kinase, and Akt pathway in osteoblasts. *Molecular Pharmacology*. 2006;**69**(6):2047-2057
- [48] Watabe H, Furuhashi T, Tani-Ishii N, Mikuni-Takagaki Y. Mechanotransduction activates $\alpha 5 \beta 1$ integrin and PI3K/Akt signaling pathways in mandibular osteoblasts. *Experimental Cell Research*. 2011;**317**(18):2642-2649
- [49] Zhou S, Schmelz A, Seufferlein T, Li Y, Zhao J, Bachem MG. Molecular mechanisms of low intensity pulsed ultrasound in human skin fibroblasts. *Journal of Biological Chemistry*. 2004;**279**(52):54463-54469
- [50] Ren L, Yang Z, Song J, Wang Z, Deng F, Li W. Involvement of p38 MAPK pathway in low intensity pulsed ultrasound induced osteogenic differentiation of human periodontal ligament cells. *Ultrasonics*. 2013;**53**(3):686-690
- [51] Whitney NP, Lamb AC, Louw TM, Subramanian A. Integrin-mediated mechanotransduction pathway of low-intensity continuous ultrasound in human chondrocytes. *Ultrasound in Medicine and Biology*. 2012;**38**(10):1734-1743
- [52] Kang KS, Lee SJ, Lee H, Moon W, Cho DW. Effects of combined mechanical stimulation on the proliferation and differentiation of pre-osteoblasts. *Experimental and Molecular Medicine*. 2011;**43**(6):367-373
- [53] Pitt WG, Ross SA. Ultrasound increases the rate of bacterial cell growth. *Biotechnology Progress*. 2003;**19**(3):1038-1044
- [54] Kleinheinz J, Stratmann U, Joos U, Wiesmann H-P. VEGF-activated angiogenesis during bone regeneration. *Journal of Oral and Maxillofacial Surgery*. 2005;**63**(9):1310-1316
- [55] Laranjeira MS, Fernandes MH, Monteiro FJ. Reciprocal induction of human dermal microvascular endothelial cells and human mesenchymal stem cells: Time-dependent profile in a co-culture system. *Cell Proliferation*. 2012;**45**(4):320-334
- [56] Matsumoto T, Goto D, Sato S. Subtraction micro-computed tomography of angiogenesis and osteogenesis during bone repair using synchrotron radiation with a novel contrast agent. *Laboratory Investigation*. 2013;**93**(9):1054-1063
- [57] Chen P, Yin H, Wang Y, Wang Y, Xie L. Inhibition of VEGF expression and corneal neovascularization by shRNA targeting HIF-1 α in a mouse model of closed eye contact lens wear. *Molecular Vision*. 2012;**18**:864-873
- [58] Shiraishi R, Masaki C, Toshinaga A, Okinaga T, Nishihara T, Yamanaka N, et al. The effects of low-intensity pulsed ultrasound exposure on gingival cells. *Journal of Periodontology*. 2011;**82**(10):1498-1503
- [59] El-Bialy TH, Royston TJ, Magin RL, Evans CA, Zaki AE-M, Frizzell LA. The effect of pulsed ultrasound on mandibular distraction. *Annals of Biomedical Engineering*. 2002;**30**(10):1251-1261
- [60] De Almeida MS, Maciel CD, Pereira JC. Proposal for an ultrasonic tool to monitor the osseointegration of dental implants. *Sensors*. 2007;**7**(7):1224-1237
- [61] Komatsu DE, Warden SJ. The control of fracture healing and its

therapeutic targeting: Improving upon nature. *Journal of Cellular Biochemistry*. 2010;**109**(2):302-311

[62] Rubin C, Bolander M, Ryaby JP, Hadjiargyrou M. The use of low-intensity ultrasound to accelerate the healing of fractures. *The Journal of Bone and Joint Surgery. American Volume*. 2001;**83**(2):259-259

[63] Duarte L. The stimulation of bone growth by ultrasound. *Archives of Orthopaedic and Traumatic Surgery*. 1983;**101**(3):153-159

[64] Turner-Walker G, Nielsen-Marsh C, Syversen U, Kars H, Collins M. Sub-micron spongiform porosity is the major ultra-structural alteration occurring in archaeological bone. *International Journal of Osteoarchaeology*. 2002;**12**(6):407-414

[65] Kerr EN, Mealey BL, Noujeim ME, Lasho DJ, Nummikoski PV, Mellonig JT. The effect of ultrasound on bone dimensional changes following extraction: a pilot study. *Journal of periodontology*. 2008;**79**(2):283-290

[66] Wilderman MN, Pennel BM, King K, Barron JM. Histogenesis of repair following osseous surgery. *Journal of Periodontology*. 1970;**41**(10):551-565

[67] Wennström JL, Ekestubbe A, Gröndahl K, Karlsson S, Lindhe J. Implant-supported single-tooth restorations: A 5-year prospective study. *Journal of Clinical Periodontology*. 2005;**32**(6):567-574

[68] Sakka S, Baroudi K, Nassani MZ. Factors associated with early and late failure of dental implants. *Journal of Investigative and Clinical Dentistry*. 2012;**3**(4):258-261

[69] Pommer B, Frantal S, Willer J, Posch M, Watzek G, Tepper G. Impact of dental implant length

on early failure rates: A meta-analysis of observational studies. *Journal of Clinical Periodontology*. 2011;**38**(9):856-863

[70] Romeo E, Ghisolfi M, Rozza R, Chiapasco M, Lops D. Short (8-mm) dental implants in the rehabilitation of partial and complete edentulism: A 3-to 14-year longitudinal study. *International Journal of Prosthodontics*. 2006;**19**(6):586-592

[71] Cardaropoli G, Araújo M, Hayacibara R, Sukekava F, Lindhe J. Healing of extraction sockets and surgically produced-augmented and non-augmented-defects in the alveolar ridge. An experimental study in the dog. *Journal of Clinical Periodontology*. 2005;**32**(5):435-440

[72] Doan N, Reher P, Meghji S, Harris M. In vitro effects of therapeutic ultrasound on cell proliferation, protein synthesis, and cytokine production by human fibroblasts, osteoblasts, and monocytes. *Journal of Oral and Maxillofacial Surgery*. 1999;**57**(4):409-419

[73] Dinno M, Dyson M, Young S, Mortimer A, Hart J, Crum L. The significance of membrane changes in the safe and effective use of therapeutic and diagnostic ultrasound. *Physics in Medicine and Biology*. 1989;**34**(11):1543-1552

[74] Pilla A, Mont M, Nasser P, Khan S, Figueiredo M, Kaufman J, et al. Non-invasive low-intensity pulsed ultrasound accelerates bone healing in the rabbit. *Journal of Orthopaedic Trauma*. 1990;**4**(3):246-253

[75] Kamath JB, Jayasheelan N, Reddy B, Muhammed S, Savur A. The effect of low-intensity pulsed ultrasound therapy on fracture healing. *Muller Journal of Medical Sciences and Research*. 2015;**6**(1):49-53

- [76] Erdogan Ö, Esen E. Biological aspects and clinical importance of ultrasound therapy in bone healing. *Journal of Ultrasound in Medicine*. 2009;**28**(6):765-776
- [77] Miller DL, Smith NB, Bailey MR, Czarnota GJ, Hynynen K, Makin IRS. Overview of therapeutic ultrasound applications and safety considerations. *Journal of Ultrasound in Medicine*. 2012;**31**(4):623-634
- [78] Allen RJ. Physical agents used in the management of chronic pain by physical therapists. *Physical Medicine and Rehabilitation Clinics of North America*. 2006;**17**(2):315-345
- [79] Angle S, Sena K, Sumner D, Viridi A. Osteogenic differentiation of rat bone marrow stromal cells by various intensities of low-intensity pulsed ultrasound. *Ultrasonics*. 2011;**51**(3):281-288
- [80] Ebadi S, Ansari NN, Henschke N, Naghdi S, van Tulder MW. The effect of continuous ultrasound on chronic low back pain: Protocol of a randomized controlled trial. *BMC Musculoskeletal Disorders*. 2011;**12**(1):1-6. DOI: 10.1186/1471-2474-1112-1159
- [81] Isoda K, Ayukawa Y, Tsukiyama Y, Sogo M, Matsushita Y, Koyano K. Relationship between the bone density estimated by cone-beam computed tomography and the primary stability of dental implants. *Clinical Oral Implants Research*. 2012;**23**(7):832-836
- [82] Reher P, Doan N, Bradnock B, Meghji S, Harris M. Effect of ultrasound on the production of IL-8, basic FGF and VEGF. *Cytokine*. 1999;**11**(6):416-423
- [83] Ramli R, Peter R, Malcolm H, Sajeda M. The effect of ultrasound on angiogenesis: An in vivo study using the chick chorioallantoic membrane. *The International Journal of Oral and Maxillofacial Implants*. 2009;**24**:591-596
- [84] Maddi A, Hai H, Ong S-T, Sharp L, Harris M, Meghji S. Long wave ultrasound may enhance bone regeneration by altering OPG/RANKL ratio in human osteoblast-like cells. *Bone*. 2006;**39**(2):283-288
- [85] Ganzorig K, Kuroda S, Maeda Y, Mansjur K, Sato M, Nagata K, et al. Low-intensity pulsed ultrasound enhances bone formation around miniscrew implants. *Archives of Oral Biology*. 2015;**60**(6):902-910
- [86] Miura K, Motoyoshi M, Inaba M, Iwai H, Karasawa Y, Shimizu N. A preliminary study of the effects of low-intensity pulsed ultrasound exposure on the stability of orthodontic miniscrews in growing rats. *The European Journal of Orthodontics*. 2014;**36**(4):419-424
- [87] Monden K, Sasaki H, Yoshinari M, Yajima Y. Effect of low-intensity pulsed ultrasound (LIPUS) with different frequency on bone defect healing. *Journal of Hard Tissue Biology*. 2015;**24**(2):189-198
- [88] Chen YJ, Wangb CJ, YangL KD, Chang PR, Huangb HC, Sunc Y-THYC, et al. Pertussis toxin-sensitive Gai protein and ERK-dependent pathways mediate ultrasound promotion of osteogenic transcription in human osteoblasts1. *FEBS Letters*. 2003;**554**:154-158
- [89] Mukai S, Ito H, Nakagawa Y, Akiyama H, Miyamoto M, Nakamura T. Transforming growth factor- β 1 mediates the effects of low-intensity pulsed ultrasound in chondrocytes. *Ultrasound in Medicine & Biology*. 2005;**31**(12):1713-1721
- [90] Huang W, Hasegawa T, Imai Y, Takeda D, Akashi M, Komori T. Low-intensity pulsed ultrasound enhances

bone morphogenetic protein expression
of human mandibular fracture
haematoma-derived cells. *International
Journal of Oral and Maxillofacial
Surgery*. 2015;**44**(7):929-935

[91] Sun JS, Hong RC, Chang WHS,
Chen LT, Lin FH, Liu HC. In vitro
effects of low-intensity ultrasound
stimulation on the bone cells. *Journal
of Biomedical Materials Research*.
2001;**57**(3):449-456

[92] Lu H, Qin L, Lee K, Cheung W,
Chan K, Leung K. Identification of
genes responsive to low-intensity
pulsed ultrasound stimulations.
*Biochemical and Biophysical Research
Communications*. 2009;**378**(3):569-573

[93] Iwanabe Y, Masaki C, Tamura A,
Tsuka S, Mukaibo T, Kondo Y, et al.
The effect of low-intensity pulsed
ultrasound on wound healing using
scratch assay in epithelial cells.
Journal of Prosthodontic Research.
2016;**60**(4):308-314. DOI: 10.1016/j.
jpor.2016.03.002

[94] Li J, Chang W, Lin J, Ruaan R,
Liu H, Sun J. Cytokine release
from osteoblasts in response to
ultrasound stimulation. *Biomaterials*.
2003;**24**(13):2379-2385

[95] Barzelai S, Sharabani-Yosef O,
Holbova R, Castel D, Walden R,
Engelberg S, et al. Low-intensity
ultrasound induces angiogenesis
in rat hind-limb ischemia.
Ultrasound in Medicine and Biology.
2006;**32**(1):139-145