

We are IntechOpen, the world's leading publisher of Open Access books Built by scientists, for scientists

6,900

Open access books available

186,000

International authors and editors

200M

Downloads

Our authors are among the

154

Countries delivered to

TOP 1%

most cited scientists

12.2%

Contributors from top 500 universities



WEB OF SCIENCE™

Selection of our books indexed in the Book Citation Index
in Web of Science™ Core Collection (BKCI)

Interested in publishing with us?
Contact book.department@intechopen.com

Numbers displayed above are based on latest data collected.
For more information visit www.intechopen.com



The Basics of Splinting in Dentoalveolar Traumatology

Naida Hadziabdic

Abstract

Dentoalveolar trauma is considered an emergency condition and is challenging for every dentist. As primary and permanent teeth may suffer repercussions from an injury, a therapist must be mindful of which situations the use of splinting methods is required. In dentistry, a splint is a rigid or flexible device with the function of supporting, protecting, and immobilizing teeth that have been weakened (endodontically, periodontally), traumatically injured, replanted, or fractured. Generally, splinting is not recommended for primary teeth injuries such as luxation and avulsion. In permanent dentition, splint appliances are indicated for periodontal injuries, such as subluxation, luxation and avulsion, and hard tissue injuries such as class IV root fractures. Nowadays, there are many appliances that may be used for immobilization of traumatized teeth. Since this issue may sometimes be confusing for dental practitioners, this chapter deals with splint classification (rigid and flexible), the basic characteristics of splints, the indications, and methods of application.

Keywords: splinting, traumatized teeth, dentoalveolar trauma, immobilization

1. Introduction

Since any dentoalveolar trauma is an emergency condition, it is a challenge for all dentists. Since both primary and permanent teeth may suffer injury, a dental therapist must first of all know the situations in which the use of a splint is indicated as a means of immobilization [1–4].

However, first of all, let us look at what a splint is.

A splint is a rigid or flexible device/aid used to support, protect, and immobilize teeth that have been weakened (endodontically or periodontally), traumatized, replanted, or fractured [5–7].

In order to even consider the use of a splint, it is necessary to know whether the traumatized tooth is primary or permanent and what kind of injury it has suffered.

In general, the use of a splint is not recommended for injuries to milk teeth, such as luxation or avulsion. Luxated milk teeth are most often extracted. Repositioning is not recommended because there is a risk of infection which could endanger the tooth bud of the permanent tooth. An avulsed milk tooth is not replanted [4, 8, 9].

In permanent dentition, the use of a splint is indicated for [10]:

- Injuries to the periodontal tissue (subluxation, luxation, and avulsion)
- Injuries to the hard dental tissue (class IV root fractures)

2. Types of splint

Splints are categorized as:

- Rigid splints
- Nonrigid/semirigid/flexible splints

This categorization of splints is based on the possibility of the physiological mobility of the tooth [11]. Thus, a rigid splint does not permit any physiological mobility of the tooth and thereby creates the conditions for complications in the sense of ankylosis or external resorption [5].

In the case of a nonrigid or semirigid splint, the physiological functional mobility of the traumatized tooth is possible, which is more favorable for the healing of the periodontal ligament (PDL), and thereby the risk of ankylosis or external resorption of the tooth root is reduced [12].

2.1 Types of rigid and semirigid splints

Rigid splints:

- Suture splints
- Arch bar splints
- Acrylic splints
- Composite splints

Semirigid splints:

- Orthodontic brackets and arches
- Wire and composite splints
- Fiber splints
- Titanium trauma splints (TTS)

2.1.1 Rigid splints

2.1.1.1 Suture splints

Soft wire and surgical thread can be used as materials for this type of splint [13–15]. The use of soft wire is indicated for mixed dentition. The wire is woven around the traumatized and neighboring teeth (**Figure 1**). Immobilization of this kind should be brief—only a few days. The weaknesses of this type of immobilization are that the metal thins and breaks with chewing, and it also prevents good oral hygiene, which leads to gingivitis [16].

When there are no neighboring teeth to which the splint may be fixed, the use of a surgical suture is indicated for the sake of immobilization (**Figure 2**).

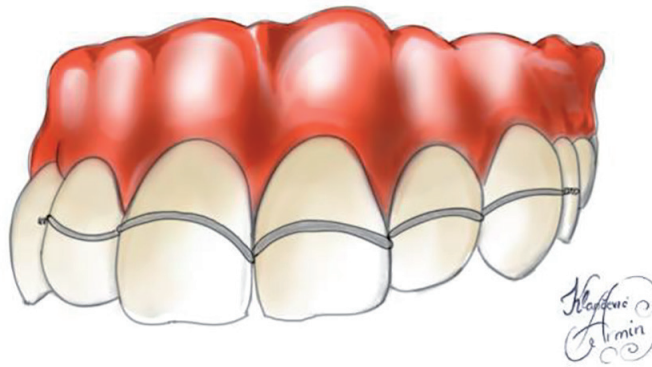


Figure 1.
Wire acting as a suture splint.

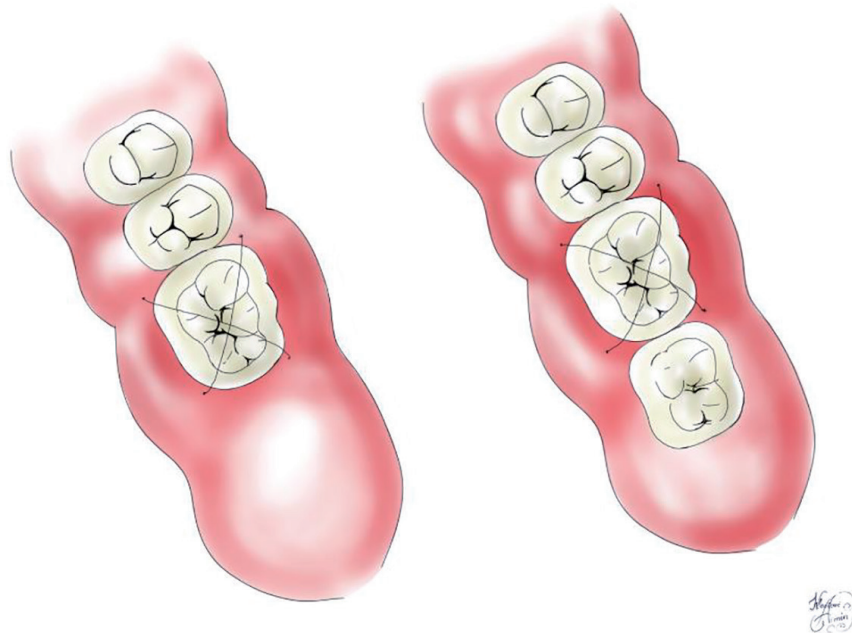


Figure 2.
A surgical suture used as a suture splint.

2.1.1.2 Arch bar splints

These are ready-made metal bars with hooks onto which the wire is woven which fixes the metal brackets to the teeth [17] (**Figure 3**). The bars are placed right up against the gums which cause irritation, and they are therefore impractical for everyday use [18].

2.1.1.3 Acrylic splints

As their name suggests, these splints are made from acrylic material [19, 20]. They are not used for isolated dental traumas. They are indicated in cases of luxation of a tooth in combination with a fracture of the alveolar bone. The best-known splint of this type is the Pfeiffer splint.

This splint may be made in two ways:

- The direct method
- The indirect method

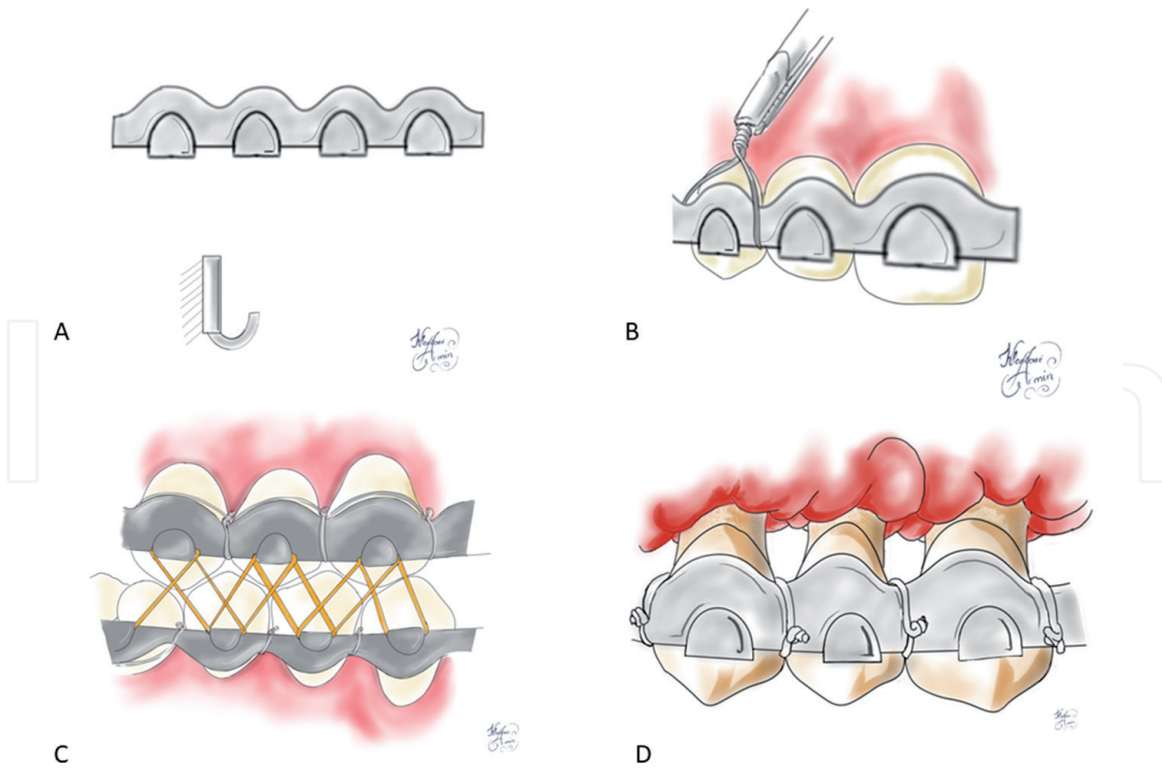


Figure 3.
(A) Ready-made metal arch, (B) metal arch fixed with wire to the upper teeth, (C) intermaxillary fixation, and (D) the appearance of gums after being irritated from the use of a ready-made splint.

2.1.1.3.1 The direct method

This method is performed directly in the patient's mouth, and for that reason, it is very uncomfortable because the acrylic sets in the mouth, creating an unpleasant warm reaction.

The following materials are needed for this method (**Figure 4**):

- Vaseline
- Self-adhesive acrylic (powder and liquid)
- A container for mixing the acrylic
- A piece of sterile gauze
- Glass for mixing
- A spatula for mixing
- Scissors
- Pliers
- Grinder

The procedure (**Figure 5**):

- First of all, establish the type of injury and decide if using a Pfeiffer splint is indicated.
- Check the position of the teeth in central occlusion and remember those positions.
- Blend the acrylic.
- Pour the blended acrylic onto the piece of sterile gauze.
- Use the scissors to cut the edge of the gauze to create a rectangular shape, so the future splint will cover two neighboring teeth on each side of the injured tooth.
- Protect the gums with Vaseline.
- Shape the splint over the vestibular and palatal surfaces of the tooth, tell the patient to bite down, and check the occlusion.
- Once it has set, remove the splint from the mouth.
- Use the grinder on the internal side of the splint to make room for the phosphate cement. In addition, it is necessary to use the grinder to work on the vestibular part of the splint so the cervical third of the crown is exposed, which will make it possible to test the vitality of the tooth while the splint is in place.
- The blended phosphate cement is poured into the prepared splint after which the splint is cemented in the patient's mouth, with verification of the central occlusion.

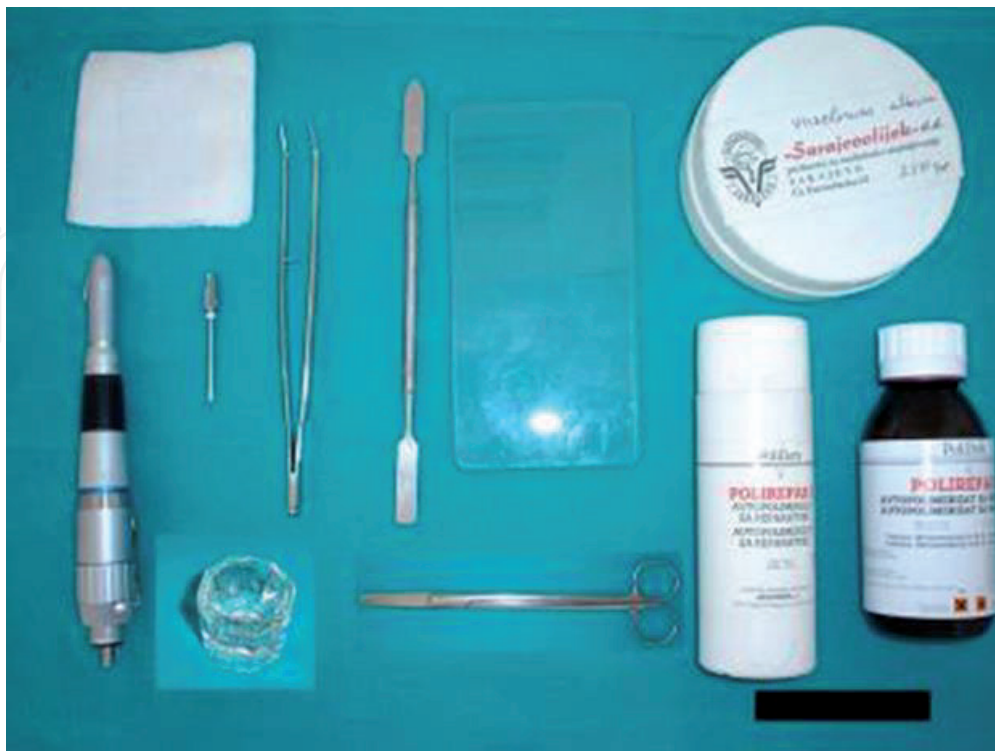

Figure 4.
Equipment for creating an acrylic Pfeiffer splint.

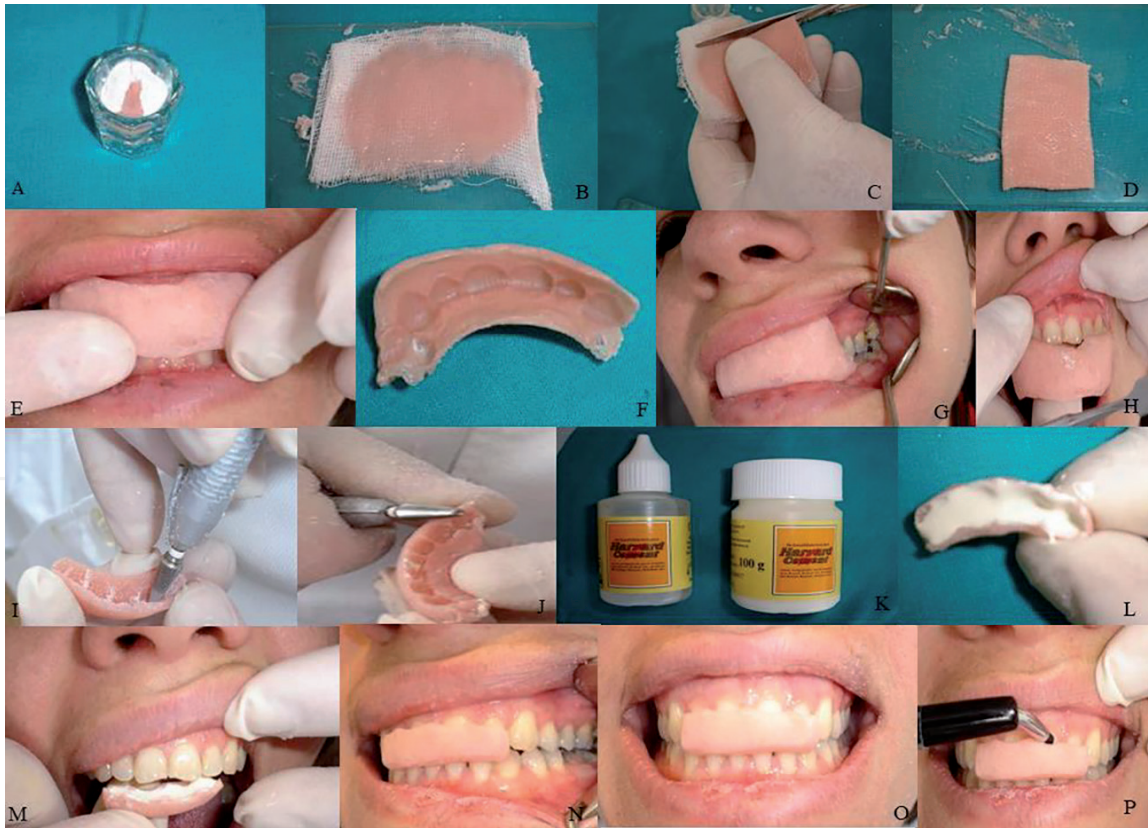

Figure 5.
Creating a Pfeiffer splint using the direct technique: (A) blending the acrylic, (B) pouring the blended acrylic onto the sterile gauze, (C) cutting the edges of the gauze onto which the acrylic was poured, (D) the rectangular-shaped gauze, (E) adjusting the splint over the vestibular and palatal surface of the tooth, (F) the inside of the splint, (G) verification of the splint in central occlusion, (H) removing the splint for processing, (I) creating space for the cement, (J) processing-cutting the edges of the splint, (K) phosphate cement, (L) the final appearance of the splint with the cement inside, (M) cementing the splint, (N) inserting the splint with verification of the central occlusion (side view), (O) the centered splint in the mouth (front view), and (P) testing the vitality of the tooth.

2.1.1.3.2 The indirect method

This method differs from the previous one in how it is executed (**Figure 6**):

- First an impression is taken of the jaw in alginate.
- Various models are created in the laboratory.

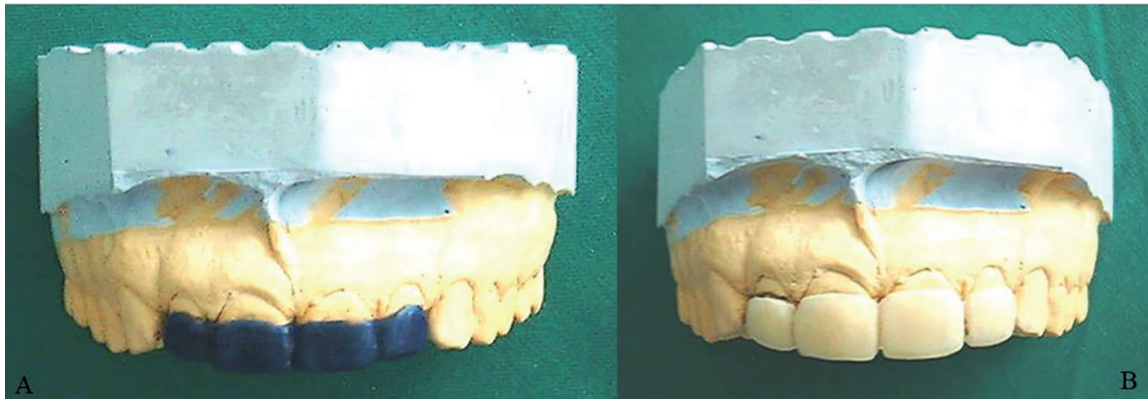


Figure 6.
The indirect method of creating a Pfeiffer splint: (A) the wax model and (B) the acrylic splint on the model.

- On the basis of the models, a splint is created in wax so that the cervical part of the crown of the tooth remains uncovered.
- The wax model is exchanged for acrylic.
- The splint is cemented in the same way as in the previous method.

2.1.1.4 Composite splints

Only composite materials are used to make this kind of splint (**Figure 7**). The technique is very simple because it consists of working with composite material in the classical way:

- Conditioning of the enamel of the injured and neighboring teeth
- Application of the adhesive and composite material with polymerization

The weakness of a composite splint is its tendency to split due to the action of interdental occlusal forces. It also may irritate the surrounding gums if it is placed very close to them.

A so-called interapproximal composite splint is a sub-type of this splint. The specific feature of this splint is that composite material is also placed on the approximal surface of the traumatized and neighboring teeth. This kind of splint is quite insecure and may only be used in cases when there has not been any major damage caused by avulsion and when the neighboring teeth are intact.

2.1.2 Semirigid splints

2.1.2.1 Orthodontic splints

For this type of splint, orthodontic brackets and orthodontic wire are needed [21] (**Figure 8**). The brackets are placed in the middle third of the labial surface of the tooth. They are connected by orthodontic wire, 0.016 mm in diameter, which is passively adapted. There are some who claim that orthodontic wire is not “passive” and that the action of orthodontic forces is possible.

The advantage of immobilization using an orthodontic splint is the possibility of synchronizing the movement of the teeth, which is particularly important in cases of intrusion. The weakness is the irritation of the lips, which can be avoided by applying wax.

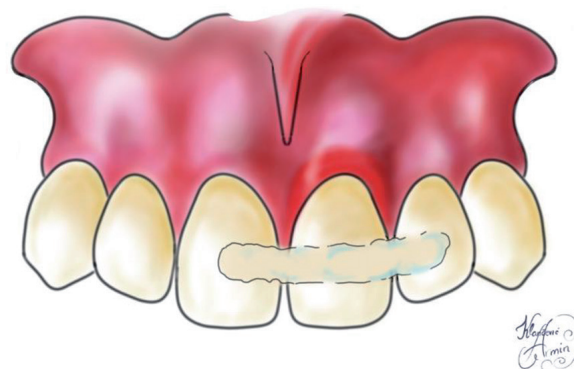


Figure 7.
A splint made exclusively from composite material.

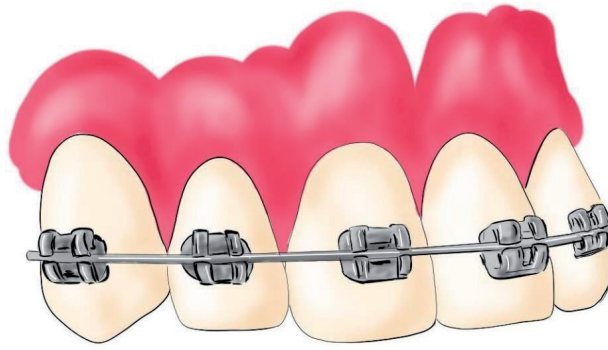


Figure 8.
An orthodontic splint.

2.1.2.2 Wire-composite splints

The splint that is used most often in everyday practice is a wire-composite splint [6, 22]. To make it, any composite material and orthodontic wire, 0.3–0.4 mm in diameter, are needed. It is indicated in all cases of traumatic injuries (**Figure 9**). Contraindications for the use of a wire and composite splint are when the teeth have artificial crowns and large fillings or in the teeth with exceptionally small crowns.

The technique for making one is quite simple:

- Orthodontic wire of the selected length is shaped directly in the patient's mouth to cover 2–3 teeth on each side of the injured tooth.
- The labial surface is conditioned using orthophosphoric acid.

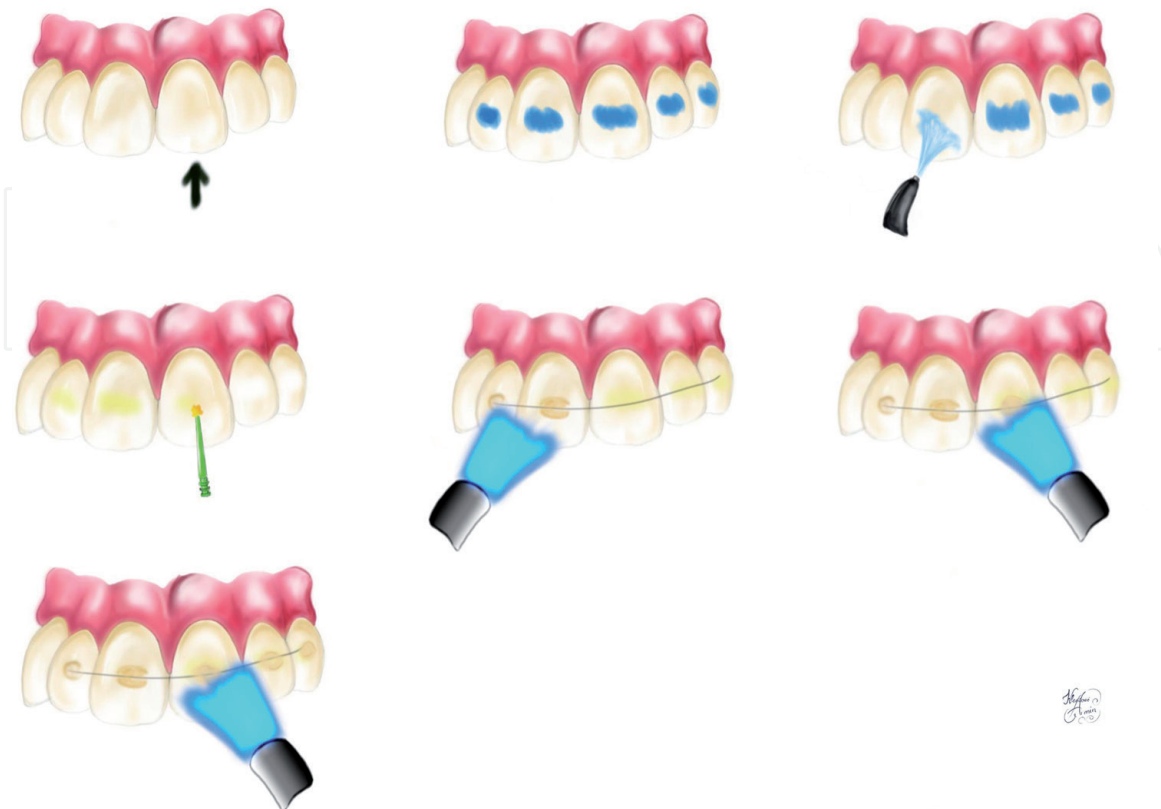

Figure 9.
Making a wire-composite splint.

- After rinsing and drying, they are coated with the bonding substance and light cured for about 10 s.
- The composite material is placed over the tooth and over that an arch, braces, or wire are positioned.
- Light curing should first be performed on the healthy teeth on one side; then the tooth should be repositioned, followed by light curing (polymerization); and then the wire should be light cured on the healthy teeth on the other side.
- In order to avoid shifting a replanted tooth while polymerizing the wires, the splint may also be fixed as follows: after repositioning, the patient bites down on softened wax (as when taking an impression for prosthetics-bite registration). The tooth remains in the desired position during the fixation of the splint to the tooth.

2.1.2.3 Fiber splints

These types of splint include [6, 23, 24]:

- Fishing line [25] (**Figure 10**)
- Glass-ionomer fiber
- Ribbond splint
- Kevlar fiber

Fishing line and glass-ionomer fiber are used in the same way as in a wire-composite splint.

2.1.2.3.1 Ribbond splint

This type of splint relies on the use of special polyethylene fibers, Ribbond fibers, and composite materials [6, 26] (**Figure 11**). In dental traumatology, Ribbond fiber splints are fixed and extra-coronary. They are used intracoronarily in cases of periodontitis, where it is necessary to create cavities in the teeth to place the fiber.

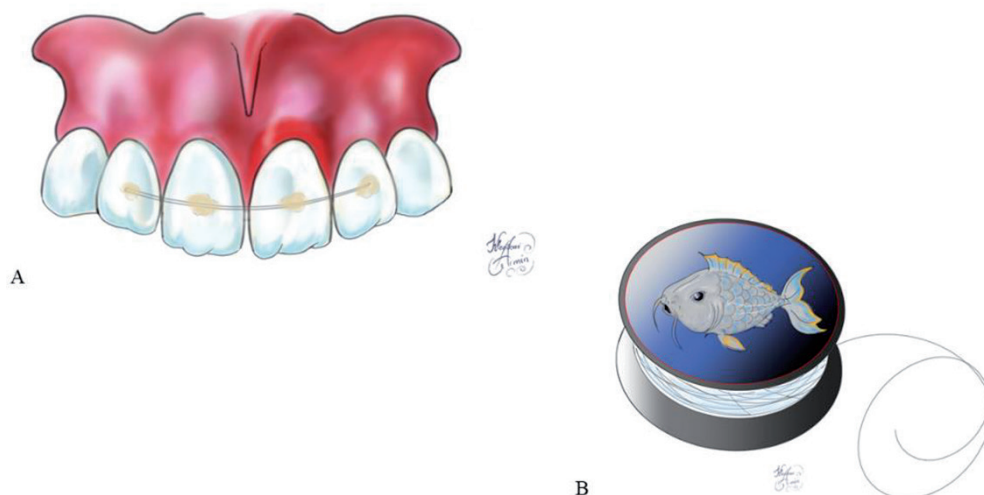


Figure 10.
(A) Fishing line used as a splint and (B) fishing line.

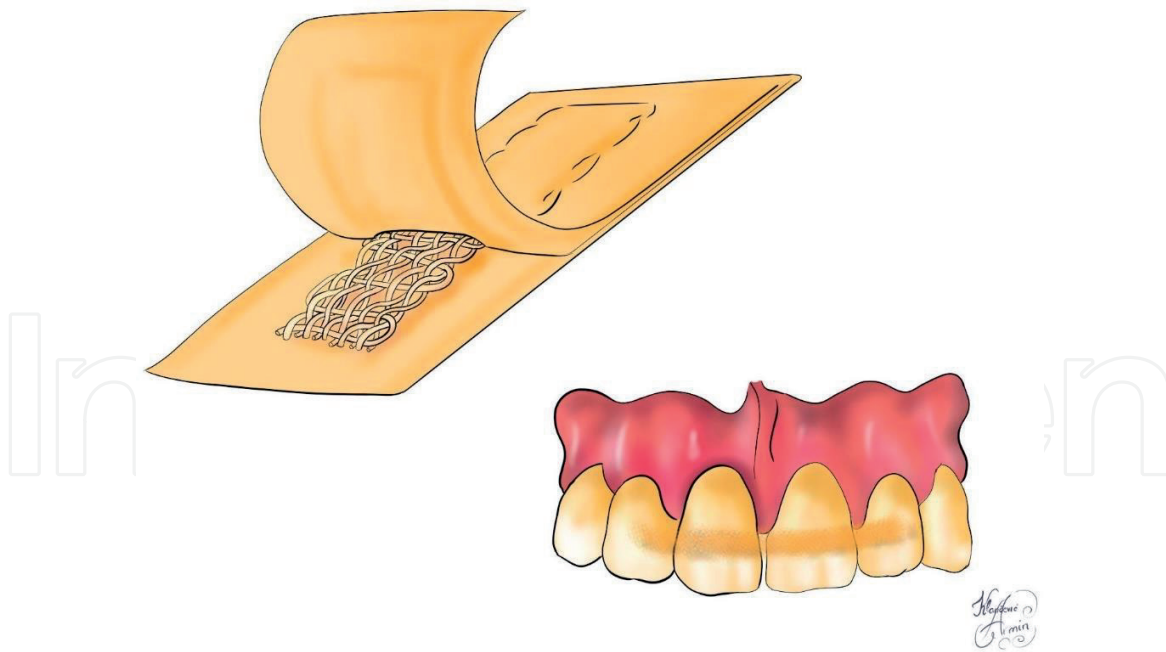


Figure 11.
A Ribbond splint.

Ribbond fibers are popular as a form of immobilization due to their properties:

- They are exceptionally strong, thanks to the special way they are woven.
- The surface of the fiber is treated using an electrochemical plasma procedure, so the mechanical properties of the fibers are improved, as well as bonding to the composite resin.
- Their permeability to light makes work possible with any form of composite material.
- They have excellent properties relating to manipulation.

The technique for placing a Ribbond splint:

- Clean the vestibular surface of the tooth.
- Determine the length of the Ribbond tape (measure the length with dental floss).
- Cut the Ribbond tape using special scissors. In this process the tape must not be touched by hand to avoid contamination. The tape should be held with tweezers or cotton gloves until it is impregnated.
- The tape is impregnated with bonding agent or fissure sealant material.
- Store the tape in a dark place.
- Parts of the vestibular surfaces of the injured and neighboring teeth are conditioned with orthophosphoric acid for 30 s.
- Wash the acid off with water, and dry.

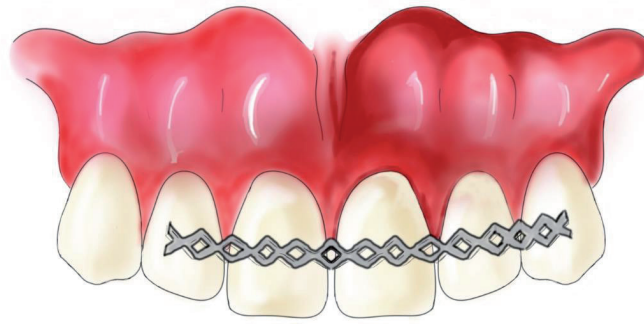

Figure 12.
Titanium trauma splint (TTS).

- Apply the adhesive on the conditioned surface of the teeth.
- Apply the flowable composite material to the tooth and then the Ribbond tape, which is pressed into the composite applied and smoothed, and excess composite material is removed. Each tooth is then light cured for 30–40 s.
- Using a drill, we remove the excess composite material and polish the surface of the composite.

2.1.2.3.2 Kevlar fiber

Kevlar fiber, poly-paraphenylene terephthalamide, is a synthetic, organic fiber of exceptional strength (five times stronger than metal). As well as being used to make bulletproof vests and in the aero-industry, it is used in dental traumatology as a means of immobilizing teeth [6]. It has the identical features, therapeutic effect, and manner of application as Ribbond splints.

2.1.2.4 Titanium trauma splint (TTS)

A TTS is a more recent splint, made from pure titanium, only 0.2 mm in thickness, which makes it significantly easier to apply to the tooth [6, 23, 27–29]. It is available in 52 and 100 mm lengths. It is designed in the form of a rhomboid mesh, which makes it easier to be fixed and makes it flexible in all dimensions (**Figure 12**). The size of the rhomboid opening, 1.8×2.8 mm, reduces the quantity of composite material used to fix it to the surface of the tooth, making it easier to remove the splint. It is fixed to the tooth in the same way as a wire-composite splint. The weakness of this splint system is that it is very expensive in comparison with a wire-composite splint.

3. The features of an acceptable splint

In view of the diversity of splints which may be used for traumatized teeth, the following features of a good splint should be used as guidelines in selection [4]:

- It is simple to create and put in place.
- It prevents further traumatization of the injured tooth.

- It enables physiological movement and therefore healing.
- It does not obstruct occlusion.
- It makes maintenance of oral hygiene possible.
- It makes it possible to monitor vitality.
- It does not obstruct endodontic treatment when necessary.
- It is aesthetic.
- It is easily removed.

4. Recommendations for the type and duration of immobilization depending on the type of trauma

In dentoalveolar traumatology, answers have not been found for all the questions that arise, especially regarding the duration of the use of splints. The effect of the duration of immobilization, that is, keeping a splint in place during the healing of the periodontal ligament, has still not been explained in clinical studies. The long-term use of a splint leads to ankylosis and replacement resorption. On the other hand, it has not been confirmed that there is a better outcome of healing in the case of the short-term use of a splint [30].

The current trends in dentoalveolar traumatology recommend the use of a splint in cases of luxation and avulsion of a tooth and in fractures of the root and alveolar ridge [31]. **Table 1** shows basic guidelines for the use of splints, in relation to the type of trauma, the duration of mobilization, and the type of splint.

Type of trauma	Duration of immobilization	Type of splint
Subluxation	2 weeks	Flexible
Extrusive luxation	2 weeks	Flexible
Avulsion	2 weeks	Flexible
Lateral luxation	4 weeks	Flexible
Fracture of the central third of the root	4 weeks	Rigid
Fracture of the cervical third of the root	4 weeks	Rigid
Fracture of the alveolar process	4 months	Rigid

Table 1.
Recommendations for the type and duration of immobilization depending on the type of trauma.

5. Conclusions

There is a large selection of splints which are indicated for tooth trauma (**Table 2**).

Modern trends in dentoalveolar traumatology support the use of functional and flexible splints for luxation and avulsion.

Type of splints		Indications	Contraindications	Advantages	Disadvantages	
RIGID SPLINTS	Wire ligature splints	Mixed dentition	Generally avoided in case of availability of other methods	Useful for oral surgeons when other splinting methods are not available	Gingival irritation and inflammation	
	Surgical suture	No neighboring teeth to which splint may be fixed	When other splinting methods would be better choice	Useful for oral surgeons as an alternative splint	Early suture loosening	
	Arch bar splint	Jaw fractures	Dento-alveolar trauma where repair of PDL is expected	none	Gingival irritation and inflammation	
	Acrylic splints	Luxation of tooth in combination with fracture of alveolar bone	Isolated dental trauma	Individual splint that can be made with direct and indirect technique	Direct method creates warm reaction	
	Composite splint	When neighboring teeth are intact	Artificial crowns/ large fillings	Every dental office have it, Easy to apply	Tendency to split due to occlusal forces	
SEMI-RIGID/FLEXIBLE SPLINTS	Orthodontic brackets and arches		When injured tooth is intruded and must be repositioned later by orthodontic forces	When there is a doubt that orthodontic forces will disturb the healing process of injured tooth	Possibility of synchronizing movement of teeth	Tricky to use for non orthodontic specialist, possible irritation of the lips which can be avoid by applying the wax,
	Wire - composite splints		All cases of traumatic injuries except for alveolar fracture	Artificial crowns/ large fillings	Easy to apply, most commonly available dento-alveolar splint	Problems with removing the splint
	Fibre splints	Fishing line		Alveolar fracture	Easy to manipulate/apply Favorable healing outcomes	none
		Glass-ionomer fibre				
		Ribbond splints				
		Kevlar fibre				
	Titanium trauma splint			Reduce the quantity of composite material, easy to apply and remove	High cost	
Conclusion		Current trends in dento-alveolar traumatology support the use of flexible splints in all types of luxation and tooth avulsion. Rigid splints are recommended in case of a root fracture and fracture of the alveolar process. Following right indication any kind of splint is better than no splint at all				

Table 2.
Classification of splints with indications, contraindications, advantages, and disadvantages.

The prognosis for traumatized teeth is more determined by the type of trauma than the type of splint selected.

The type of splint and the duration of immobilization, therefore, may not be considered significant variables in terms of the outcome of healing.

Acknowledgements

The author would like to thank Armin Klančević, DMD, for his contribution of drawing all the figures for this chapter.

Conflict of interest

The authors declare there is no conflict of interest.

Author details

Naida Hadziabdic
Department of Oral Surgery, Faculty of Dental Medicine, University of Sarajevo,
Sarajevo, Bosnia and Herzegovina

*Address all correspondence to: nsulejma@yahoo.com

IntechOpen

© 2020 The Author(s). Licensee IntechOpen. This chapter is distributed under the terms of the Creative Commons Attribution License (<http://creativecommons.org/licenses/by/3.0>), which permits unrestricted use, distribution, and reproduction in any medium, provided the original work is properly cited. 

References

- [1] Rao A, Rao A, Shenoy R. Splinting—When and how? *Dental Update*. 2011;**38**:341-342, 344-6. DOI: 10.12968/denu.2011.38.5.341
- [2] Andreasen JO, Ahrensburg SS, Tendal B. Inappropriate use of meta-analysis in an evidence-based assessment of the clinical guidelines for replanted avulsed teeth. Timing of pulp extirpation, splinting periods and prescription of systemic antibiotics. *Dental Traumatology*. 2010;**26**:451-452. DOI: 10.1111/j.1600-9657.2010.00911.x
- [3] Andreasen JO, Lauridsen E, Andreasen FM. Contradictions in the treatment of traumatic dental injuries and ways to proceed in dental trauma research. *Dental Traumatology*. 2010;**26**:16-22. DOI: 10.1111/j.1600-9657.2009.00818.x
- [4] Brown CL, Macie IC. Splinting of traumatized teeth in children. *Dental Update*. 2003;**30**:78-82. DOI: 10.12968/denu.2003.30.2.78
- [5] Ben Hassan MW, Andersson L, Lucas PW. Stiffness characteristics of splints for fixation of traumatized teeth. *Dental Traumatology*. 2016;**32**:140-145. DOI: 10.1111/edt.12234
- [6] Kahler B, Hu JY, Marriot-Smith CS, Heithersay GS. Splinting of teeth following trauma: A review and a new splinting recommendation. *Australian Dental Journal*. 2016;**61**:59-73. DOI: 10.1111/adj.12398
- [7] Kahler B, Heithersay GS. An evidence-based appraisal of splinting luxated, avulsed and root-fractured teeth. *Dental Traumatology*. 2008;**24**:2-10. DOI: 10.1111/j.1600-9657.2006.00480.x
- [8] Cho WC, Nam OH, Kim MS, Lee HS, Choi SC. A retrospective study of traumatic dental injuries in primary dentition: Treatment outcomes of splinting. *Acta Odontologica Scandinavica*. 2018;**76**:253-256. DOI: 10.1080/00016357.2017.1414956
- [9] Malmgren B, Andreasen JO, Flores MT, Robertson A, Diangelis AJ, Andersson L, et al. International Association of Dental Traumatology guidelines for the management of traumatic dental injuries: 3. Injuries in the primary dentition. *Dental Traumatology*. 2012;**28**:174-182. DOI: 10.1111/j.1600-9657.2012.01146.x
- [10] Andersson L, Andreasen JO, Day P, Heithersay G, Trope M, DiAngelis AJ, et al. International Association of Dental Traumatology guidelines for the management of traumatic dental injuries: 2. Avulsion of permanent teeth. *Dental Traumatology*. 2012;**28**:88-96. DOI: 10.1111/j.1600-9657.2012.01125.x
- [11] Mazzoleni S, Meschia G, Cortesi R, Bressan E, Tomasi C, Ferro R, et al. In vitro comparison of the flexibility of different splint systems used in dental traumatology. *Dental Traumatology*. 2010;**26**:30-36. DOI: 10.1111/j.1600-9657.2009.00843.x
- [12] Burcak Cengiz S, Stephan Atac A, Cehreli ZC. Biomechanical effects of splint types on traumatized tooth: A photoelastic stress analysis. *Dental Traumatology*. 2006;**22**:133-138. DOI: 10.1111/j.1600-9657.2006.00339.x
- [13] Gupta S, Sharma A, Dang N. Suture splint: An alternative for luxation injuries of teeth in pediatric patients—A case report. *The Journal of Clinical Pediatric Dentistry*. 1997;**22**:19-21
- [14] Neaverth EJ, Georig AC. Technique and rationale for splinting. *Journal of the American Dental Association*. 1980;**100**:56-63. DOI: 10.14219/jada.archive.1980.0026
- [15] Lin S, Emodi O, Abu El-Naaj I. Splinting of an injured tooth as part

of emergency treatment. *Dental Traumatology*. 2008;**24**:370-372. DOI: 10.1111/j.1600-9657.2007.00530.x

[16] Lello JL, Lello GE. The effect of interdental continuous loop wire splinting and intermaxillary fixation on the marginal gingiva. *International Journal of Oral and Maxillofacial Surgery*. 1988;**17**:249-252. DOI: 10.1016/s0901-5027(88)80050-x

[17] Berthold C, Thaler A, Petschelt A. Rigidity of commonly used dental trauma splints. *Dental Traumatology*. 2009;**25**:248-255. DOI: 10.1111/j.1600-9657.2008.00683.x

[18] Oikarinen K. Comparison of the flexibility of various splinting methods for tooth fixation. *International Journal of Oral and Maxillofacial Surgery*. 1988;**17**:125-127. DOI: 10.1016/s0901-5027(88)80166-8

[19] Oikarinen K. Tooth splinting: A review of the literature and consideration of the versatility of a wire-composite splint. *Endodontics & Dental Traumatology*. 1990;**6**:237-250. DOI: 10.1111/j.1600-9657.1990.tb00426.x

[20] Alexander PC. Replantation of teeth. *Oral Surgery, Oral Medicine, and Oral Pathology*. 1956;**9**:110-114. DOI: 10.1016/0030-4220(56)90181-5

[21] Dawoodbhoy I, Valiathan A, Lalani ZS, Cariappa KM. Splinting of avulsed central incisors with orthodontic wires: A case report. *Endodontics & Dental Traumatology*. 1994;**10**:149-152. DOI: 10.1111/j.1600-9657.1994.tb00541.x

[22] Croll TP, Helpin ML. Use of self-etching adhesive system and compomer for splinting traumatized incisors. *Pediatric Dentistry*. n.d.;**24**:53-56

[23] von Arx T. Splinting of traumatized teeth with focus on adhesive techniques. *Journal of the California Dental Association*. 2005;**33**:409-414

[24] Kargul B, Caglar E, Kabalay U. Glass fiber-reinforced composite resin as fixed space maintainers in children: 12-Month clinical follow-up. *Journal of Dentistry for Children (Chicago, Ill.)*. 2005;**72**:109-112

[25] Marriot-Smith C, Marino V, Heithersay GS. A preclinical dental trauma teaching module. *Dental Traumatology*. 2016;**32**:247-250. DOI: 10.1111/edt.12251

[26] Yildirim Öz G, Ataoğlu H, Kir N, Karaman AI. An alternative method for splinting of traumatized teeth: Case reports. *Dental Traumatology*. 2006;**22**:345-349. DOI: 10.1111/j.1600-9657.2005.00364.x

[27] Filippi A, Von Arx T, Lussi A. Comfort and discomfort of dental trauma splints—A comparison of a new device (TTS) with three commonly used splinting techniques. *Dental Traumatology*. 2002;**18**:275-280. DOI: 10.1034/j.1600-9657.2002.00121.x

[28] Stellini E, Avesani S, Mazzoleni S, Favero L. Laboratory comparison of a titanium trauma splint with three conventional ones for the treatment of dental trauma. *European Journal of Paediatric Dentistry*. 2005;**6**:191-196

[29] Von Arx T, Filippi A, Lussi A. Comparison of a new dental trauma splint device (TTS) with three commonly used splinting techniques. *Dental Traumatology*. 2001;**17**:266-274. DOI: 10.1034/j.1600-9657.2001.170605.x

[30] Hinckfuss SE, Messer LB. Splinting duration and periodontal outcomes for replanted avulsed teeth: A systematic review. *Dental Traumatology*. 2009;**25**:150-157. DOI: 10.1111/j.1600-9657.2008.00761.x

[31] Qin M, Ge L, Bai R. Use of a removable splint in the treatment of subluxated, luxated and root fractured anterior permanent teeth in children. *Dental Traumatology*. 2002;**18**:81-85. DOI: 10.1034/j.1600-9657.2002.180207.x