

# We are IntechOpen, the world's leading publisher of Open Access books Built by scientists, for scientists

6,900

Open access books available

185,000

International authors and editors

200M

Downloads

Our authors are among the

154

Countries delivered to

TOP 1%

most cited scientists

12.2%

Contributors from top 500 universities



WEB OF SCIENCE™

Selection of our books indexed in the Book Citation Index  
in Web of Science™ Core Collection (BKCI)

Interested in publishing with us?  
Contact [book.department@intechopen.com](mailto:book.department@intechopen.com)

Numbers displayed above are based on latest data collected.  
For more information visit [www.intechopen.com](http://www.intechopen.com)



# Revascularisation Strategies in OPCAB (Off Pump Coronary Artery Bypass)

*Murali P. Vettath, Kannan A. Vellachamy,  
Nitin Ganagadharan, Madhu Ravisankar, Smera Korothe  
and Gopalakrishnan Raman*

## Abstract

OPCAB was performed before the advent of heart lung machine. But with the development of stabilizers, coronary artery bypass grafting has been performed over the last two decades successfully in many centres around the world. But still 80% of bypass surgeries are done on the heart lung machine. We were one of the few teams who have been performing this OPCAB for the past 18 years. All along, we have been innovating, fabricating and developing and patenting instruments, techniques and technology to help us perform OPCAB in 100% of all our coronary patients. That too being able to reduce the mortality of bypass surgery to less than 0.5%. In this chapter, we have attempted to write down our strategy, in order to successfully perform OPCAB in all our patients, so that the coming generation can benefit from it.

**Keywords:** OPCAB, CABG, arterial graft, venous graft, bilateral mammary grafting, IABP, mammary patch, VAO, SIMS, stabilizer

## 1. Introduction

OPCAB has been the procedure of choice in quite a few centres around the world. Though, the numbers of surgeons performing 100% of their CABGs off pump are still miniscule. The main issue is that performing OPCAB in all patients becomes quite strenuous for some surgeons because in OPCAB, the margin of error is very low. And that when a patient is converted to the heart lung machine then the morbidity and the mortality is high. The learning curve is very steep in order to master this technique. Our team had to perform over 500 OPCABs till the team became comfortable to perform this procedure in all patients who needed coronary revascularisation. There are two important issues that have to be tackled before a team gets to be able to perform 100% OPCABs over a decade [1]. One is the mind set and another is team work. If one achieves these two goals, then the rest is only a question of time, when the team could achieve it. Every team player has to become confident that we would be able re-vascularise every patient without going on pump. That confidence and strategy is the key to the success of the surgery. Apart from preparing for surgery, and planning for difficult cases, the execution,

intraoperative and post-operative management till he returns to his room and to his further follow up, all are to be planned and executed with precision. Every patient needs to get a tailor made surgical approach. As, no two coronaries are same. Likewise no two grafting are same. Accordingly no two patients would have same postoperative course. Hence there should be no slackness on the part of the team thinking that it is just a straight forward case and we can relax. We have always found that we make mistakes when we are not agile or when we take things for granted. As every patient is important. Hence, we should care for him like we care for our parents or our colleague. Once we are able to achieve this, then success can be assured.

## **2. Surgical strategy**

In this chapter, we would like to present our view on how we plan our surgical strategy. Starting from the type of surgery, which the patient is going to undergo, to the revascularisation techniques which we plan are going to be discussed here. As we said, every patient needs to have his surgery tailor made according to his specific needs. Our main aim is to perform complete revascularisation on all patients, then, the next priority is to perform the coronary bypass without using the heart lung machine. Then our priority is to use arterial grafts where ever possible. The use of left internal mammary artery (LIMA) to the left anterior descending artery (LAD) is a rule or standard for all patients. We have noticed that as the LAD is the most important artery in the heart, if the LIMA remains patent over 10 years then it usually remains open for life [2]. The presence of nitric oxide in LIMA in fact does not allow any clot formation inside it and that even a small LIMA remains patent as long as the run off of the LAD is good. And that once we anastomose a LIMA to the LAD, then it is unlikely that the LAD distal to the anastomosis would develop atherosclerosis. This is because of the nitric oxide that is secreted from the LIMA which prevents the development of atherosclerosis being formed in that region. This is unlike in case of drug eluting stent where we see narrowing of the vessel distal to the stent.

## **3. Preoperative preparation in OPCAB**

Preparation of patients in OPCAB is rather less cumbersome than in patients with on-pump CABG. That is, we do not have to stop the antiplatelet medication in patients who are going to undergo OPCAB. Hence in patients with acute coronary syndrome we have the advantage of continuing the antiplatelet and the injection heparin till the day of surgery. Thereby avoiding ischemia in these patients. The only medicine we stop is beta blockers on the day of surgery. As we do not wish to reduce the heart rates unlike in other centres, we in fact like to increase the heart rate so as to increase the cardiac output in turn. This is how we are able to avoid the use of inotropes in all our patients during the positioning of the heart before grafting [1]. Apart from this there are no changes in the management of patients in either groups.

## **4. Anaesthesia management**

Anaesthetic management of patient being induced for OPCAB is similar in line, as for all cardiac surgical patients, except that they are not totally ironed out.

This is to make sure that the mean blood pressure is maintained above 75 mm of Hg, all through the procedure, though this warrants a separate chapter.

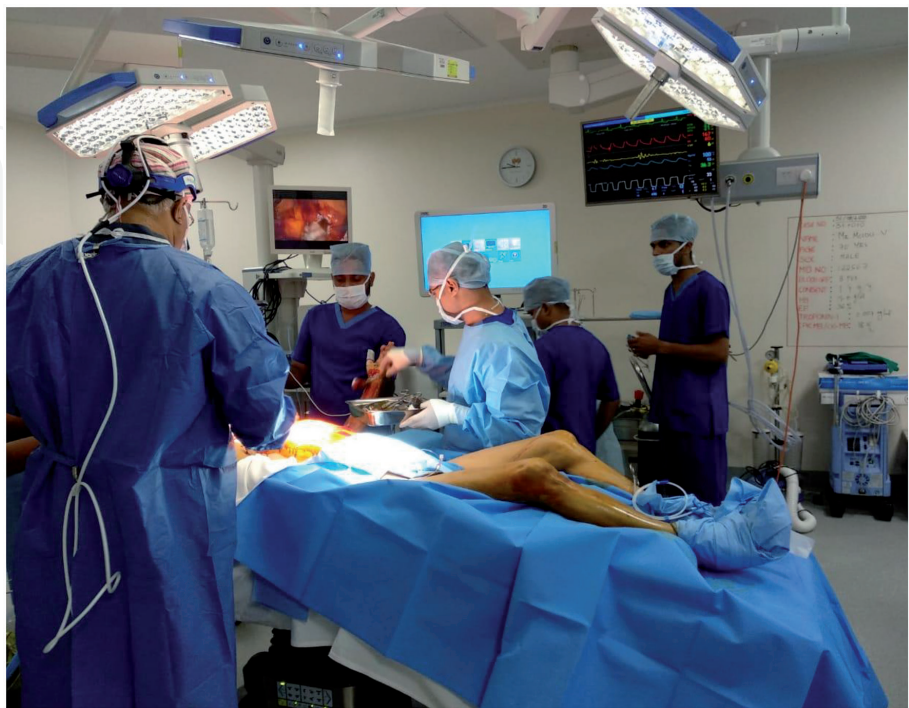## 5. Surgical techniques in OPCAB

### 5.1 Harvesting of the conduit

Once the patient is positioned, painted and draped (**Figures 1 and 2**).

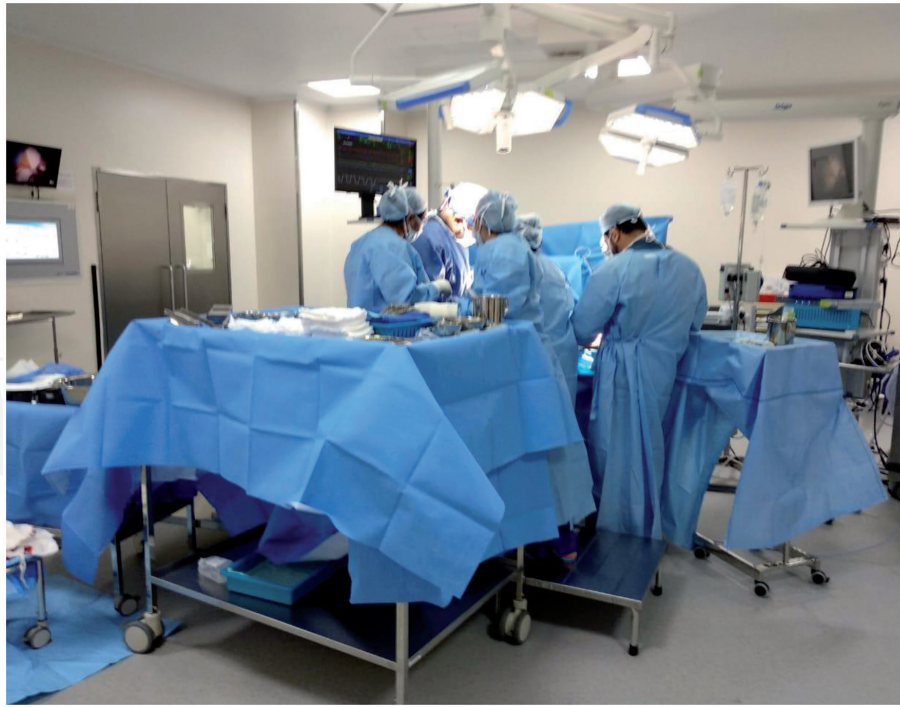The idea is to harvest the arterial grafts first and then the vein graft if necessary. The skin incision extends from 2 cm below the sternal notch to 1 cm above the xiphoid process. We usually dissect the xiphoid process out from both sides and its attachment below from the diaphragm using diathermy (which is at 70 coagulation and zero on the cutting—that is our setting on the diathermy). Hence the sternotomy starts by cutting the xiphoid out first and then starting the sternotomy as usual. The chest is opened as usual and the pericardium is slit longitudinally to expose the heart. The pericardium near the diaphragm is cut along the diaphragm up to the inferior vena cava (IVC). This is done after the right pleura is opened and the thymus is tied up near the superior vena cava (SVC). This helps in allowing the heart to lie freely when the heart is being positioned during grafting of the lateral wall vessels.

It is very important to maintain strict haemostasis all through the opening of the sternum till grafting at least—as all these patients are on antiplatelet medications and/or on heparin, so any bleeding site left unattended at this stage would cause unnecessary blood loss (photo of chest opened before harvesting the mammary). Hence, if we spend time for haemostasis during opening of the chest, then the closing becomes easy and tidy.

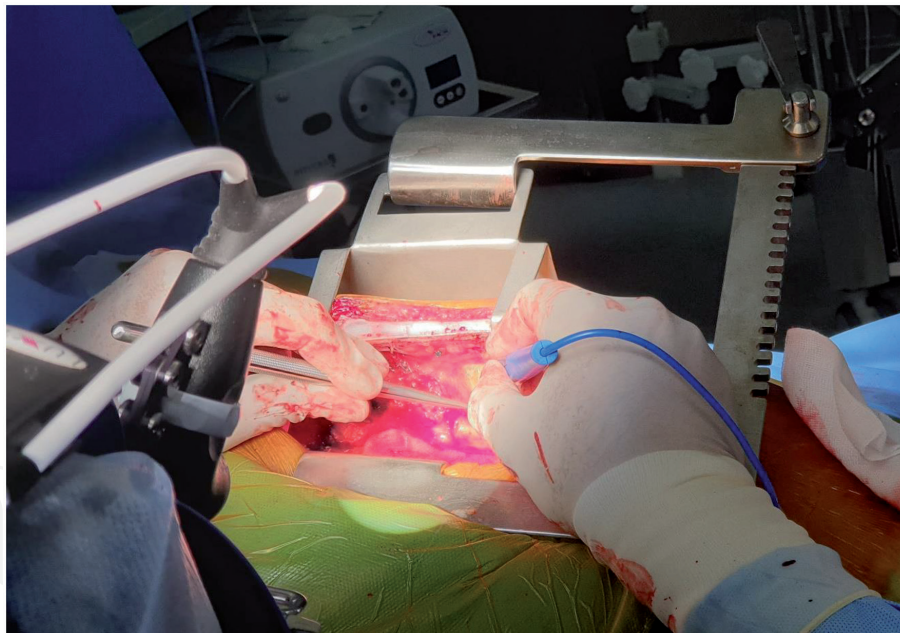


**Figure 1.**  
*Patient on the table with left arm on the side for radial artery harvesting.*





**Figure 2.**  
*Shows the patient after draping and the surgery in progress, with chest being opened and the radial artery being harvested simultaneously.*



**Figure 3.**  
*Shows the IMA retractor in position.*

## 5.2 Harvesting the LIMA

The internal mammary artery (IMA) of the left side is the most important artery and that we need to harvest it with caution. And it is important to maintain hemodynamic all through this dissection, so that we can do a good job, as it is important to remember that the patient's longevity depends on the patency of LIMA anastomosis being patent all through. Earlier we used to dissect the LIMA as a pedicle, but for the last 2 years we have mastered this technique of Skeletonised mammary dissection, with a cold cautery technique, which does not allow the

LIMA to go into spasm during the harvesting. The cautery is usually set at 40 coagulation and no cutting during the mammary harvesting. The blood pressure is maintained at a systolic blood pressure between 130 and 140 mm during the dissection, so that we have a good pressure head and the mammary pulsates during the dissection.

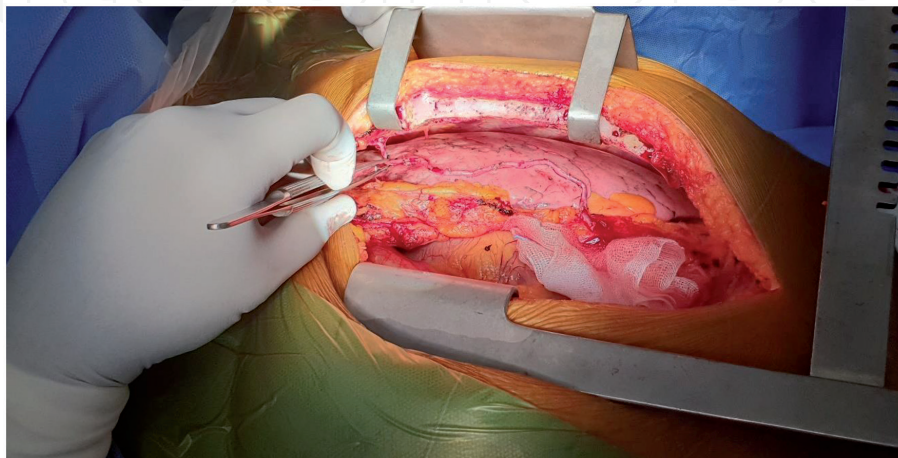
After the lift sternum is lifted (IMA retractor in position **Figure 3**).

The left pleura is opened longitudinally parallel to the sternum up to the top, after the branches crossing it are clipped and cut with a forehand scissors. The LIMA dissection starts from the xiphoid region. The Thoracic fascia is dissected using the diathermy by making a parallel incision on it medial to the LIMA all along the sternal edge. Then the cautery tip is now used as a cold cautery for all the dissections from now on. The tip is used to dissect the LIMA away from the thoracic fascia by moving the tip upward towards the LIMA and then used the tip on the diathermy to push the tissues up and away from the LIMA again, pushing the LIMA down from the chest wall to expose the intercostal branches, would cause avulsion of these branches at its base, which would end up in dissection of the LIMA. Once the distal end is dissected at the LIMA bifurcation, the two branches are clipped using two clips on the distal end and one liga clip on the proximal end, and then cutting it with the forward cutting Castroviejo scissors. At this stage no heparin is given. Dilute injection Papaverine is sprayed on the dissected end and the dissection is continued all through till the first branch of LIMA (LIMA dissection **Figure 4**).

In fact the IMA does not clot as its wall exudes nitric oxide and because it is clipped at the end and the blood pressure is maintained above 130 mm systolic it gets bigger by the time the dissection is over. The video of skeletonised LIMA is seen in the following link; SKELTONISED LIMA DISSECTION USING COLD CAUTERY TECHNIQUE. <https://youtu.be/m7mYWLQsDAE>.

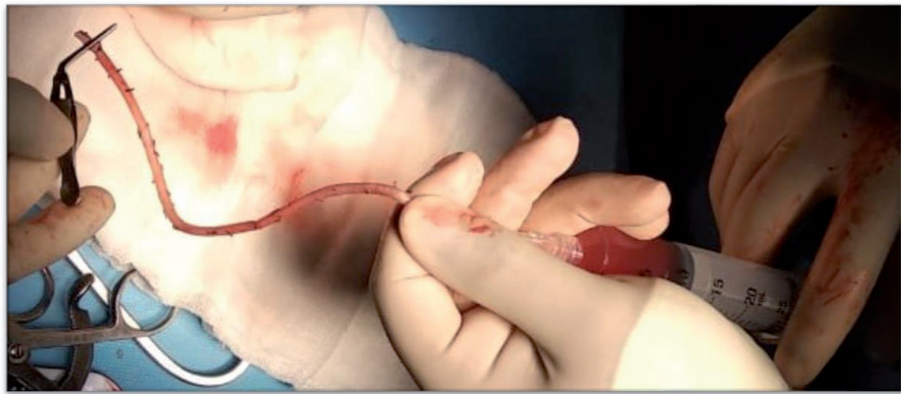
Once LIMA is dissected, then RIMA is also dissected depending on the revascularisation strategy.

Simultaneously, the radial artery from the left hand is harvested. This is also taken down as a skeletonised artery and it is dilated with injection papaverine, which is injected intraluminally and clipped at end and stored in warm heparinised saline in a bowl. The important point to make sure in patients whose radial artery is harvested is to make sure that the pulse-oxymeter saturation of the thumb should always show the wave form and that it should be 100% at any given time. The arm has to be closed only after perfect haemostasis, and to make sure that the

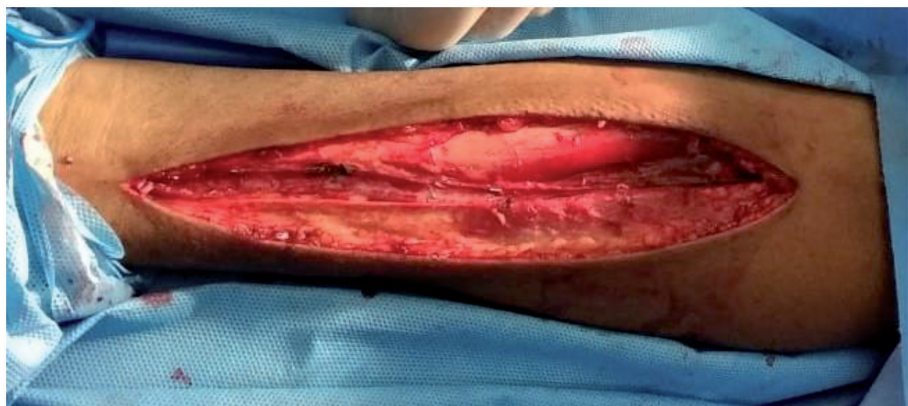

**Figure 4.**  
*Shows skeletonised LIMA after dissection.*





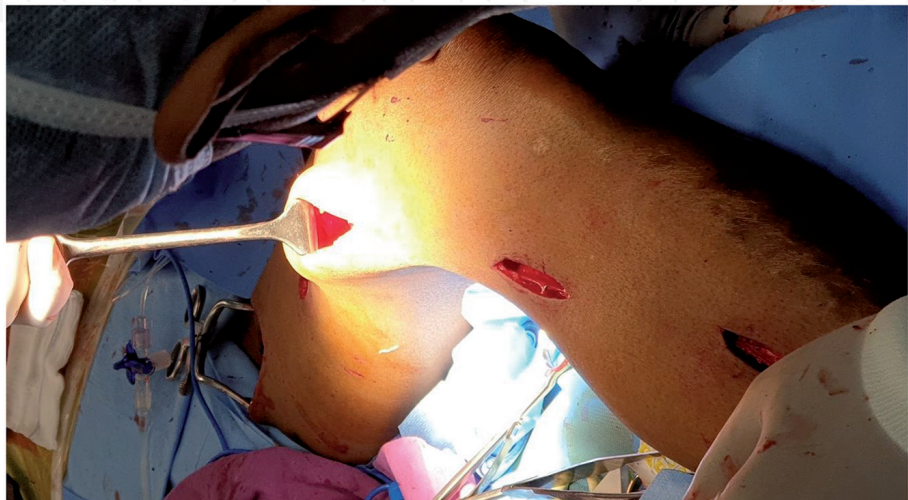
**Figure 5.**  
*Showing skeletonised radial artery.*



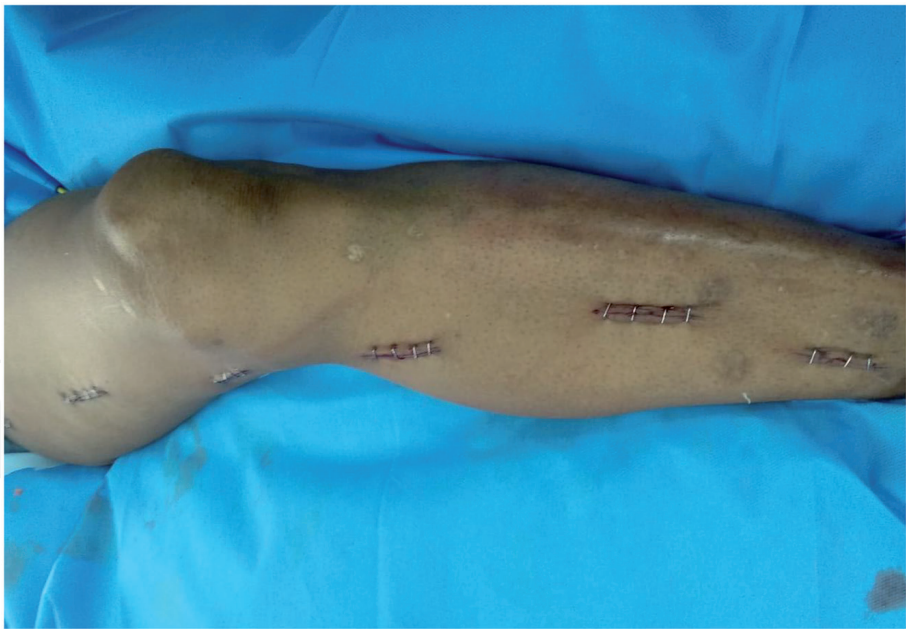**Figure 6.**  
*Showing the haemostasis in the forearm after the radial artery is harvested.*

crepe bandage applied is not too tight. We do not use any specific vasodilators like nitroglycerin or post-operative Diltiazem, as we make sure that the Radial artery is grafted only on coronaries with more than 80% lesions for sure (**Figure 5**, showing the skeletonised radial artery) (**Figure 6**).

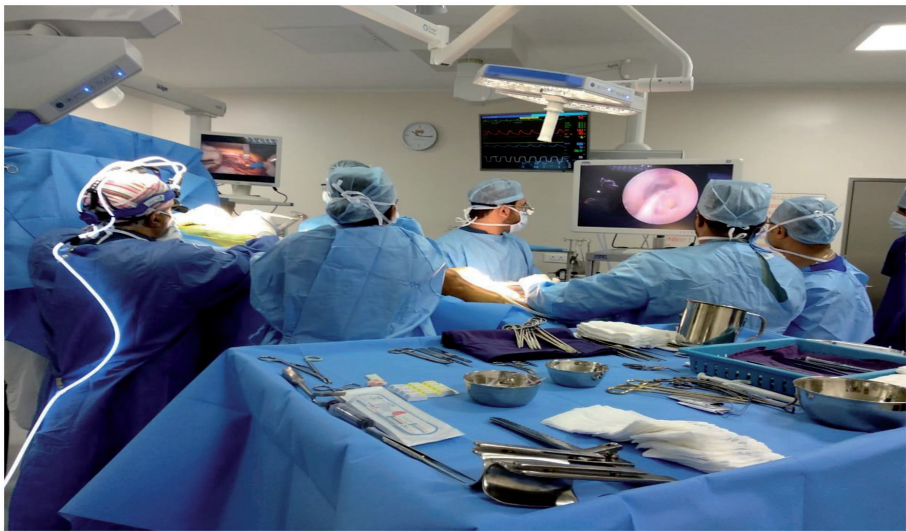The radial artery dissection video is seen in the following link: <https://youtu.be/19YY37hpeTs>—radial artery dissection.



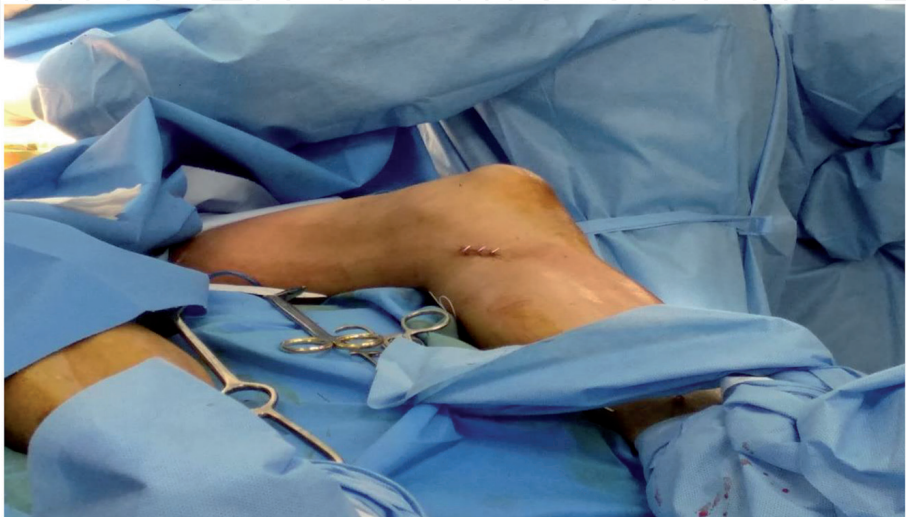**Figure 7.**  
*Showing the skip technique of SVG being harvested.*



**Figure 8.**  
*Showing the skip incisions on the lower limb after closing with clips.*



**Figure 9.**  
*Showing EVH being done.*



**Figure 10.**  
*Showing the single small scar after EVH technique... but this comes with a cost.*



The third conduit that is harvested is usually the long saphenous vein (SVG). It is either harvested from the thigh or from the leg. It is dissected as an open technique or by a skip technique (**Figures 7 and 8**), showing the skip technique of SVG being harvested (avoiding a continuous incision and the wound afterward) which does not need any extra instrumentation.

The other technique is to use endoscopic vein harvesting technique (EVH) **Figures 9 and 10**.

### 5.3 Grafting sequence

The first artery to be grafted is usually the LAD (left anterior descending), and always by LIMA unless there is an issue. This is the link that shows our grafting pattern.

The video link of the play list is: <https://www.youtube.com/playlist?list=PLmnb6npEfabinhlatq8IYLBz8WlHo8bu1>.

In case there is an issue with the LIMA, like it is short, due to dissection or injury, either we use the R(right)IMA (**Figure 11**, RIMA to LAD) or the radial artery or the vein piece hooked to the LIMA to reach the LAD.

This link shows: LIMA TO RADIAL ANASTOMOSED TO LAD, DIAGONAL AND MARG CIRC as a 'C' graft: <https://youtu.be/OaOjXlRk7Nk>.

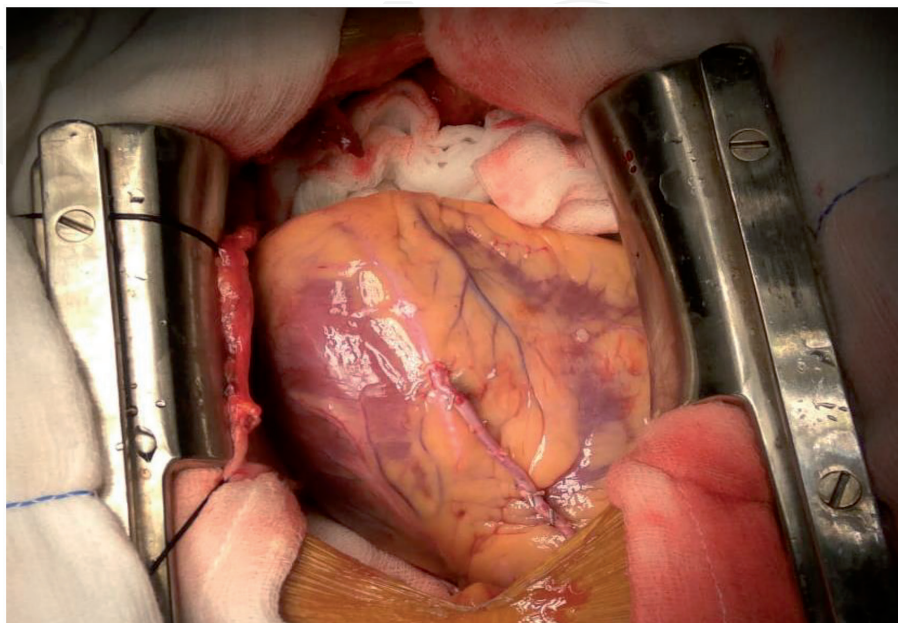
Sometimes when we use RIMA to LAD, if it is long enough, then we use LIMA to radial and skip to all the coronaries. If we plan for a total arterial grafting, the preference is to have two inflows to the coronaries if both the left and the right coronary artery need grafting. But if it is only the left system that need grafting and if we plan for a total arterial grafting with no touch technique of the aorta, then LIMA—RIMA Y or LIMA—radial Y is used.

Video links showing:

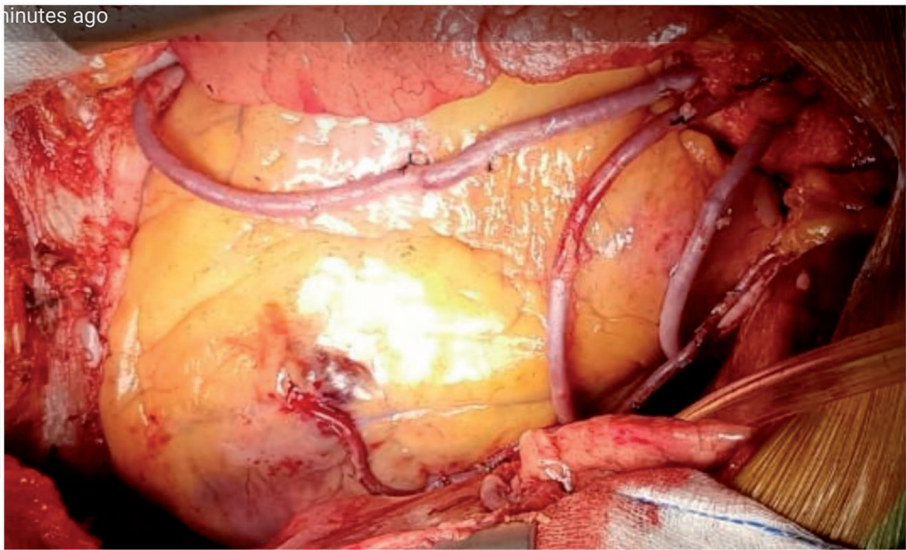
BIMA-LIMA TO DIAGONAL AND LAD. RIMA TO RADIAL SKIP TO PDA AND PLV: <https://youtu.be/96LLBz1hS5k>.

BIMA-LIMA TO DIAGONAL-LAD. RIMA TO RADIAL SKIP TO RAMOS, OM & PDA: [https://youtu.be/fj\\_kLZmQV6I](https://youtu.be/fj_kLZmQV6I).

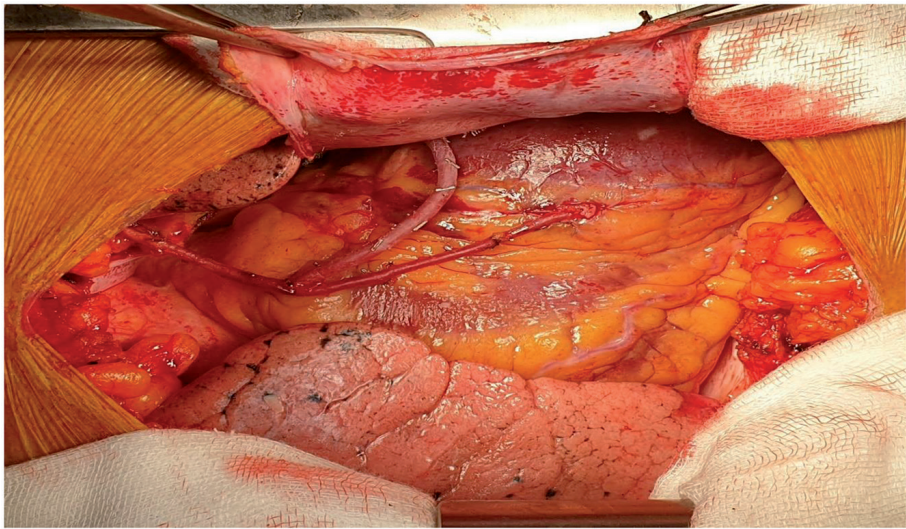
BIMA-LIMA TO DIAGONAL AND LAD. RIMA TO RADIAL SKIP TO OM & PDA: <https://youtu.be/SN1F8YjPiUA>




**Figure 11.**  
*Shows RIMA anastomosed to LAD.*



**Figure 12.**  
*Shows the usual OPCAB × 5 (LIMA to diagonal skip to LAD and SVG to OM1, OM2 and PDA).*



**Figure 13.**  
*Shows LIMA—radial Y graft.*



**Figure 14.**  
*Shows the VAO (Vettath's anastomotic obturator).*



BIMA and radial. LIMA TO LAD, LIMA-RADIAL TO DIAGONAL, RIMA TO RADIAL TO PDA: <https://youtu.be/sWa2N3qlCm4>.

Most of the elderly patients (above 75–80 years of age) we stick to LIMA and vein grafts.

(**Figure 12**), or LIMA—Radial Y if only left system is involved (**Figure 13**)

The only difference is that the vein grafts are connected to the aorta without using the side clamp. In such patients who has some island of soft aortic wall left, or if they have a patch of non-calcified aorta left, we use the VAO (Vettath's anastomotic obturator) (**Figure 14**, showing the VAO).

This is one of our earliest innovations, way back in 2004, which was published in HSF [3–5]. **Figure 15**, showing the vein graft being anastomosed to the aorta using VAO.

This is the video link of the VAO being used: <https://youtu.be/10eNQbPhLR0>.

Because of the increasing number of diabetic patients and patients with diffusely diseased coronary arteries and with increasing amount of patients undergoing triple vessel stenting, cardiac surgeons end up getting the worst set of patients who needs a CABG. Hence, in this scenario we had developed our own technique of mammary patch on diffusely diseased LAD without endarterectomy on beating heart [6, 7].

The link of the video showing mammary patch is as follows:

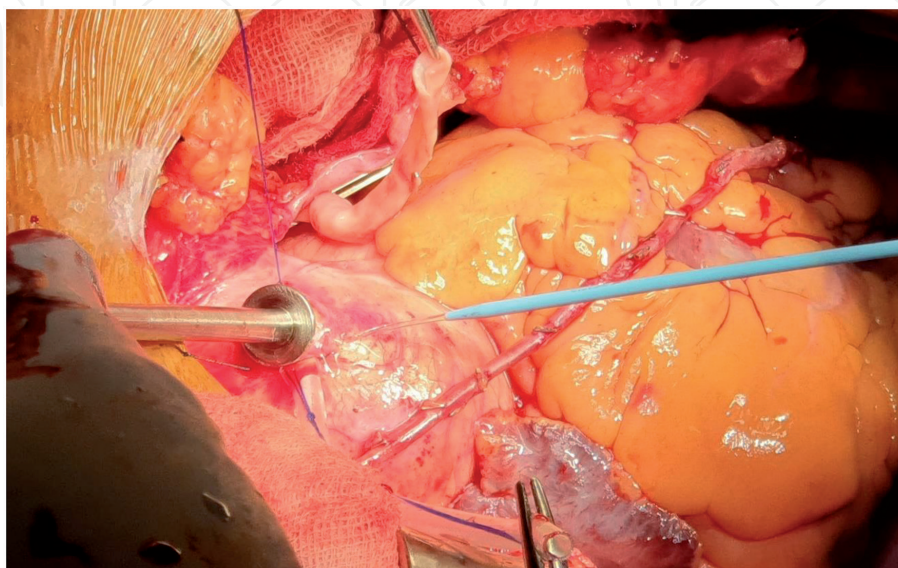
<https://youtu.be/bLNj2Xfjt9w> Mammary Patch using Aorto Coronary Shunt.

<https://youtu.be/vEQflcsarG8> MAMMARY PATCH angioplasty using long intra coronary Shunt.

<https://youtu.be/peoxcDu67m0> Long Mammary Patch angioplasty using Double Stabilizer.

It is very important to understand that when we do a mammary patch using the left IMA, then, this LIMA should never be shared with any other conduit. It should be dedicated only to the LAD.

In patients with buried coronary arteries, it is important to identify them using all the techniques we do while we are on pump, and use it in off pump. It is important to position the heart first so that it does not cause any hemodynamic compromise during stabilisation and grafting (video link as for SIMS). The LIMA stitch, of putting a stay in the pericardium using a dextron stitch and lifting the pericardium



**Figure 15.**  
*Shows RIMA-radial to LAD, SVG to obtuse marginal artery, which is attached to aorta using the VAO.*



to expose the lateral wall of the heart without compromising the haemodynamics is very useful to avoid conversions.

In patients who are ischaemic and unstable with big lateral wall vessels which are tightly stenosed, or in patients with dilated myocardium or huge heart, we end up using an intra-aortic balloon pump (IABP).

Usually in an ischaemic patient we notice that the ST segments go down by the time we are half way through the IMA dissection and then when the blood pressure drops, we end up putting the head end of the patient down, so as to increase the preload. When we do that, we see that the heart distends and the Pulmonary artery pressure goes up and then the patient becomes more ischaemic as his end diastolic pressure goes up and he develops sub-endocardial ischemia. In such patients irrespective of the systemic pressure its better off having the head end of the patient up, which empties the heart a bit and pulmonary artery pressure comes down and it is important to increase the heart rate so that it also helps in increasing stroke volume and the cardiac output. But in case that does not work, then we have to insert an IABP to salvage the situation. Because every patient who undergo OPCAB in our centre has two arterial lines, one in the Radial artery and another in the Femoral artery. The one in the femoral region is exchanged to an IABP using the Seldinger technique [8]. This has been a boon for us, as we are able to place the IABP immediately, and then go on with the grafting without going on the heart lung machine (HLM).


Over the last 15 years we have noticed that we were able to remove the IABP from the patient after the grafting is complete and after reversal of heparin. This innovation has worked so far and we never had to reinsert one in the ICU again on these patients (**Table 1**).

OPCAB statistics					
From	To	OPCAB	Conversion	IABP removed in OT	Mortality no
01-2003	12-2003	177	12	0	0
01-2004	12-2004	238	6	0	1
01-2005	12-2005	299	0	0	3
01-2006	12-2006	284	0	4	5
01-2007	12-2007	260	1	8	0
01-2008	12-2008	225	0	11	2
01-2009	12-2009	280	0	8	0
01-2010	12-2010	358	0	22	0
01-2011	12-2011	413	0	24	0
01-2012	12-2012	425	0	23	2
01-2013	12-2013	429	0	18	2
01-2014	12-2014	312	0	6	3
01-2015	12-2015	317	0	6	2
01-2016	12-2016	228	0	11	3
01-2017	12-2017	109	0	0	0
01-2018	12-2018	196	0	0	0
Total		4550	19 (0.4%)	144 (3.1)	20 (0.43%)

**Table 1.**  
Showing our OPCAB results.



**Figure 16.**  
*Shows stabilizer with pods.*



**Figure 17.**  
*Shows combo device, which comes in a box.*

#### 5.4 Simple indigenous metallic stabilizer (SIMS)

We have been using our own simple indigenous (Indian made) metallic stabilizer (SIMS) for the last 5 years or so (**Figure 16**, stabilizer and pods). It was innovated to avoid the conventional disposable plastic stabilizer that had to be changed either after every case or like in India, to change it after 10 or 20 cases. Hence we developed our own reusable, re-sterilisable metallic stabilizer, which we have used for the last 5 years even without changing the main part. The only part that has to be changed is the Pods. The pods would cost about 10–15 dollars for one pod. This has in fact reduced our carbon footprint which we leave when we do cardiac surgery [9].

The link of videos showing the SIMS in action: <https://www.youtube.com/playlist?list=PLmnb6npEfabinhlatq8IYLBz8WlHo8bu1>.

The SIMS comes as a combo device (**Figure 17**, shows the box, which comes with the sternal spreader and the stabilizer and its parts), which is made of a sternal spreader with a railing on both sides over which a vertical 2 inch metallic rod could be fixed with a screw and its position could be moved according to the position of the coronary artery which needed to be bypassed. Over this metal rod, we have the stabilizer rod that is fixed at its base with another clamp, which in turn could be moved over the metal rod to which ever position we need. The stabilizer rod is in fact a curved hollow metallic tube which houses another curved metal rod inside. The curved outer tube has a distal metal end that holds a housing in which the pod head could be moved around. This housing has three slots which allows the pod to move in them until it is positioned. The proximal end of the outer tube has a screw which when screwed, would tighten the inner rod. The inner rod at its distal end is convex and this moves on the concave end of the interlocking rod in front of it. The interlocking rod is the crux of the stabilizer (sent for patenting). This is a half a centimetre piece of metal which is concave on both ends. The proximal concave end allows the metal rod to push it forward or distally, and the distal concave bit allows the head of the pod to rest on it. Hence when the pod is placed parallel to the coronary artery, we first tighten the rod in the intended position and the pod is positioned by tightening the screw at the proximal end. This screw in turn pushes the inner rod forward, which in turn pushes the interlocking rod which tighten and stabilizes the head of the pod in the desired position. This, once positioned is so stable that it does not move at all. The pod has suckers like in the conventional stabilizers, which could be attached to the suction apparatus and can be used as suction stabilizer as well. Over time, once we get used to the stabilizer we can avoid the suction unless it is absolutely needed, like in positioning for right coronary artery grafting.

## 6. Conclusion

Revascularisation strategy is the most important part of planning for CABG. Whether it is done on the heart lung machine, or it is performed without the use of heart lung machine, it is important to first deliver a patent anastomosis. Just because some surgeons are able to do a good job, does not mean that everyone can do it. Hence one has to tailor make his own strategy of coronary revascularisation. Only by performing more and more such procedure, can we become confident on that technique. Just because the studies tell that arterial grafts have a better long term patency, and if we by performing this surgery on a patient are not able to provide a safe surgery, we should not do it. No wonder only 5% of surgeons perform total arterial grafting, and that only a handful of surgeons perform them on all patients. Likewise, just because we have been performing OPCAB in 100% of our patients over the last 12 years and that we have had no conversions on to the pump, does not mean that it is possible for all surgeons to do it [10]. Unless they have a mind-set and work hard for it to happen and that the team has been geared to perform without much issues, OPCAB would not be possible. It is important to watch such a team perform, by staying with them for at least a few weeks to learn this technique. Once the OPCAB technique is mastered, we could then strategize on what conduits to use and what permutations and combinations of conduits could be used. If we are able to perform a good OPCAB procedure then there is no need to use inotropes post operatively and that the hospital stay itself gets shortened. We have totally avoided inotropes in any patient who has undergone OPCAB in our centre, over the last 15 years.



IntechOpen

IntechOpen

### Author details

Murali P. Vettath\*, Kannan A. Vellachamy, Nitin Ganagadharan, Madhu Ravisankar, Smera Koroth and Gopalakrishnan Raman  
Department of CVTS, Meitra Hospital, Kozhikode, Kerala, India

\*Address all correspondence to: murali.vettath@gmail.com

### IntechOpen

© 2019 The Author(s). Licensee IntechOpen. This chapter is distributed under the terms of the Creative Commons Attribution License (<http://creativecommons.org/licenses/by/3.0>), which permits unrestricted use, distribution, and reproduction in any medium, provided the original work is properly cited. 

## References

- [1] Vettath MP. Re-engineering in OPCAB—A Vettath's perspective. *World Journal of Cardiovascular Disease*. 2013;**2013**(3):33-44. DOI: 10.4236/wjcd.2013.34A006
- [2] Takanashi S, Fukui T, Hosoda Y, Shimizu Y. Off-pump long onlay bypass grafting using left internal mammary artery for diffusely diseased coronary artery. *The Annals of Thoracic Surgery*. 2003;**76**:635-637
- [3] Vettath MP. Vettath's anastomotic obturator: A simple proximal anastomotic device. *The Heart Surgery Forum*. 2003;**6**(5):366-368. Available from: [www.hsforum.com/vol6/issue5/2003-73305.html](http://www.hsforum.com/vol6/issue5/2003-73305.html)
- [4] Vettath MP, Kannan AV, Sheen Peecheeyen CS, Baburajan AK, Vahab A, Sujith MP. Vettath's anastomotic obturator—Our experience of 269 proximal anastomosis. *Heart, Lung & Circulation*. 2004;**13**:288-290
- [5] Vettath MP, Ismail EK, Kannan AV. Extended use of Vettath's anastomotic obturator (vao). *Surgical Science*. 2011;**2**:451-452. Available from: <http://www.scirp.org/journal/ss>
- [6] Prabhu AD, Thazhkuni IE, Rajendran S, Thamaran RA, Vellachamy KA, Vettath MP. Mammary patch reconstruction of left anterior descending coronary artery. *Asian Cardiovascular & Thoracic Annals*. 2008a;**16**:313-317
- [7] Prabhu AD, Karim RA, Rajendran S, Thazhkuni IE, Thamaran RA, Vellachami KA, et al. Vettath's technique of long mammary patch reconstruction of a diffusely diseased left anterior descending coronary artery without endarterectomy on the beating heart. *The Heart Surgery Forum*. 2008;**11**(2):64-67. DOI: 10.1532/HSF98.20071155. Available from: <http://cardenjennings.metapress.com>
- [8] Vettath M et al. Role of intra aortic balloon pump in off pump coronary artery bypass—A Vettath modification. *World journal of cardiovascular disease*. 2016;**6**:188-195. DOI: 10.4236/wjcd.2016.66020. Available from: <http://www.scirp.org/journal/wjcd>
- [9] Vettath MP, Kannan AV, Nitin G, Ravisankar M, Smera K, Gopalakrishnan R. Development of SIMS (simple indigenous metallic stabilizer) for OPCAB. *World Journal of Cardiovascular Diseases*. 2019;**9**:324-330. DOI: 10.4236/wjcd.2019.9324. ISSN Online: 2164-5337 ISSN. Available from: <http://www.scirp.org/journal/wjcd>
- [10] Vettath MP, Ravisankar M, Kopjar T, Kannan AV, Gangadharan N. Off-pump coronary artery bypass grafting improves early clinical outcomes including operative mortality. *The Heart Surgery Forum*. 2018;**21**(3):E151-E157. DOI: 10.1532/hsf.2007