

We are IntechOpen, the world's leading publisher of Open Access books Built by scientists, for scientists

6,900

Open access books available

185,000

International authors and editors

200M

Downloads

Our authors are among the

154

Countries delivered to

TOP 1%

most cited scientists

12.2%

Contributors from top 500 universities



WEB OF SCIENCE™

Selection of our books indexed in the Book Citation Index
in Web of Science™ Core Collection (BKCI)

Interested in publishing with us?
Contact book.department@intechopen.com

Numbers displayed above are based on latest data collected.
For more information visit www.intechopen.com



Application of Medical Imaging in Diagnosis and Assessment of Myocarditis and Pericarditis

Yousif Mohamed Y. Abdallah and Nouf H. Abuhadi

Abstract

Medical imaging is one of the most essential means in the investigation of cardiac disorders. In patients, the detection of the whole heart and its adjacent tissues is a crucial procedure since it helps in myocarditis and pericarditis management. Weekly, there are millions of cardiac imaging performed globally. Medical imaging and processing techniques such as image segmentation, augmentation, and scrutiny can detect cardiac lesions rapidly and precisely. This chapter discusses the application of medical imaging in the diagnosis of myocarditis and pericarditis. This chapter also summarizes how to demonstrate image interpretation challenges using diverse image processing procedures and techniques.

Keywords: medical imaging, diagnosis, myocarditis, pericarditis

1. Introduction

The pericardium is a muscular sac that covers the heart and cases its major blood vessels. It facilitates and greases the heart motions [1–3]. In embryonic stage, the internal layer of the pericardium forms the myocardium prior fused with the exterior layer of the fibrous layer [4–7]. Those layers are a few millimeters thick and they are separated from each other. The pericardium gets the blood from inner mammary arteries and its inversion from the phrenic nerve [8, 9]. The pericardium separates from the sternum, vertebral bodies, and diaphragm through many ligaments (**Figure 1**) [10].

The symptoms of myocarditis are common especially in middle-aged patients [11]. Those diseases can cause discomfort, chest pain, tiredness, breathlessness, and repeated visits to clinics. The coronary vessel disease is one of the causes of myocarditis and pericarditis [12–14]. The virus infection is the main cause of myocarditis. This infection is usually associated with severe viral infection. This infection may cause the injury to the myocardium tissues, and it is associated with the accumulation of fluid and local death of tissue, contingent on its nature and extent [15–18]. Fungal infections are infrequent and include aspergillosis, blastomycosis, and candidiasis. The tissue can be recovered within days. In acute cases, complete functional tissues work within weeks [19]. Cardiomyopathy may cause the consequences of the chronic inflammatory process (**Figure 2**) [20, 21].

The causes of occurrence of acute myocarditis are idiopathic. Pericarditis is an inflammatory process that affects the pericardium tissues. The signs of pericarditis

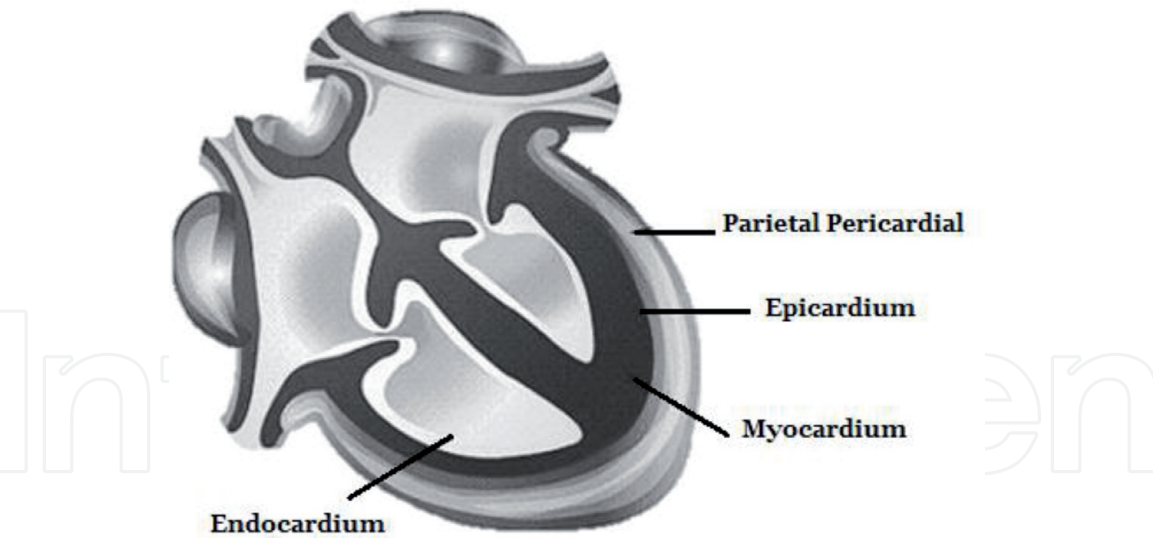


Figure 1.
Shows the pericardium layers.

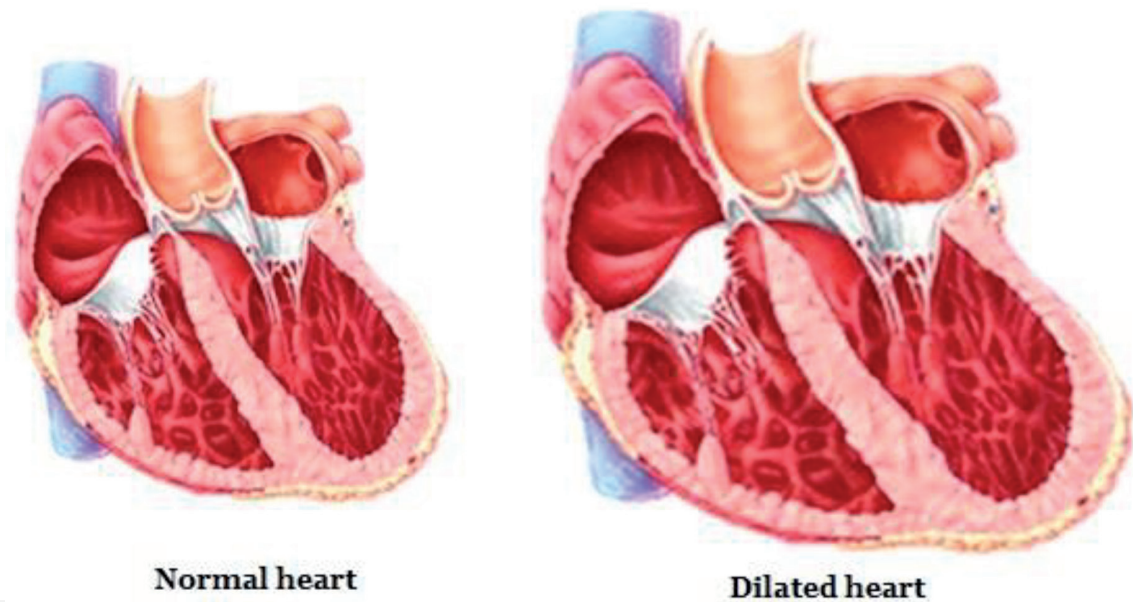


Figure 2.
Shows dilated heart.

are rub, abnormal ECG findings and possible pericardial effusion, chest discomfort, and breathing difficulties. The pericardial rub is best heard at the end of the expiration phase with patient sloping frontward [22–24]. About 30% of patients with myocarditis might be accompanied with pericarditis. Pericarditis is difficult to detect. Some postmortem studies suggest that pericarditis is a subclinical type. Pericarditis accounts for 5% of patients who are attending to emergency rooms due to myocardial infraction and chest discomfort [25–29]. On laboratory results, pericarditis can be detected in a troponin I test. Nevertheless, the elevation of troponin (I) is not used as the adverse prognosis of the disease [30, 31]. Serology may approve the cause as infectious or autoimmune pericarditis. Acute pericarditis onsets with mild signs and symptoms and its treatment lasts for 6 weeks. The infection symptoms might reoccur within 4–6 weeks [32, 33]. The prevalence of pericarditis may include idiopathic, tuberculosis, viral (HIV infection) or systemic infection, cancer (breast, leukemia, lymphoma, and lung), radiation therapy (about 4% of mediastinal Hodgkin’s disease), cardiac surgery (20% of the cases

of bypass graft surgery), and percutaneous heart examinations [34–36]. The bacterium spreads to the pericardium by blood or direct extension of the adjacent organs. Incidence of myocarditis has been stated after smallpox immunization. The neoplastic pericardium is a secondary cause of the pericarditis [37]. Patients with acute pericarditis have progressive disease and discomfort. This discomfort gets worse when the patient is lying supine. The pain in the area refers to the trapezius muscles and phrenic nerve. Fever might accompany the viral pericarditis [38–40]. Electrocardiogram (ECG) is the most frequent tool for acute pericarditis study. It shows a saddle shape that reflects subepicardium infection. In ECG graph, acute pericarditis shows no Q-wave and loss of R-wave. Imaging of the cardiac tissue has a limited role especially in uncomplicated acute pericarditis. Chest radiographs show the cardiomegaly and pericardial effusion (250 mL). Ultrasound imaging (M-mode and Doppler) is used to differentiate constrictive and restrictive cardiomyopathy. In the pediatric, a transesophageal probe is used to detect diastolic dysfunction. Cytological examinations of pericarditis include glucose, protein, cell count, bacteria and virus culture, and gram and Ziehl-Neelsen stain test. Myolemma and sarcolemma can detect immune-mediated pericarditis. In neoplastic conditions, the high level of the carcinoembryonic antigen is detected. Pericardial biopsy is performed in the granulomatous or malignant suspicion [41–43].

2. Clinical presentation of myocarditis and pericarditis

The medical signs of acute pericarditis and myocarditis include malaise, rash, tiredness, arthralgias, and respiratory and digestive syndromes. The acute infection continues for few weeks. Patients might attend the clinic with chest discomfort, breathlessness, tiredness, and syncope. Cardiac beat disorders are common and include both atrial and ventricular with the possibility of atrioventricular blockage. The European study of the inflammatory disease showed that 72% had dyspnea and 32% chest discomfort. The medical signs in pediatric patients differ according to their age. Kids may have anxiety, tiredness, raised temperature, loss of appetite, increased breath rate, increased heartbeats, and blue skin due to lack of oxygen. Symptoms in toddlers might comprise of chest and abdominal discomfort, muscle pain, tiredness, cough, and fluid accumulation in tissues. The degree of symptoms is reliant on the age of the kid. Toddlers often have and might require progressive cardiovascular and respiratory care in the initial phases of their disease than adults [44].

3. Medical imaging in diagnosis and assessment of myocarditis and pericarditis

3.1 Electrocardiography

Echocardiography is beneficial for assessing cardiac tissue dimensions, wall width, systolic and diastolic, and intracavitary thrombi. This technique can assess cardiac failure. Myocarditis has no special radiographic features in this technique. Nevertheless, myocarditis is characterized by widened, enlarged, and ischemic cardiomyopathies. This technique is commonly used as a diagnostic tool. The accuracy of electrocardiography for pericarditis and myocarditis is about 47% because ECG findings are basic T-wave deviations (**Figure 3**) [45].

The classical ECG examination is comprised of four stages of changes and it is described in about 50% of cases.

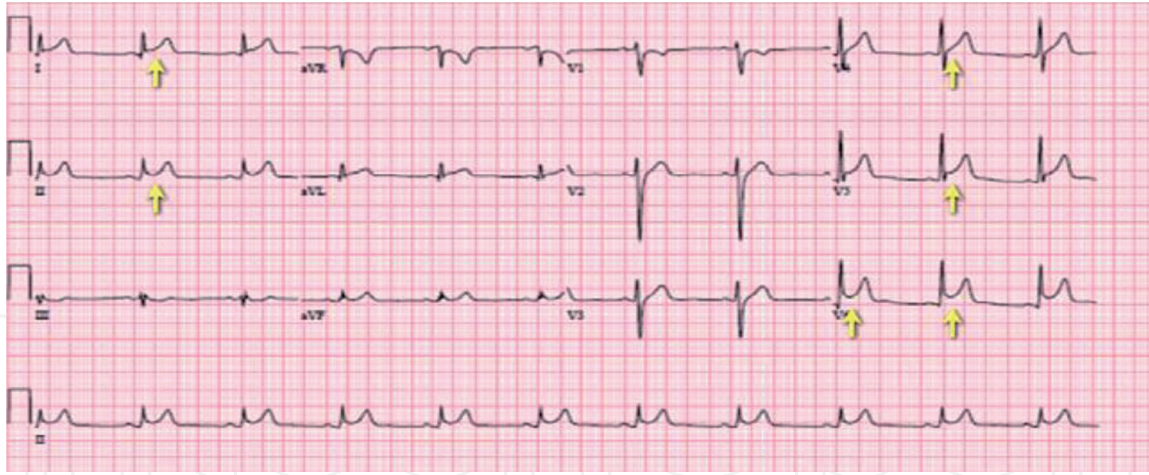


Figure 3.
Shows the ECG scan of myocarditis and pericarditis.

Those stages are:

Stage 1: (hours to a few days): the ST elevation and depression of the PR segment.

Stage 2: (first week): control of the ST and PR segments.

Stage 3: T-wave inversions.

Stage 4: standardization of ECG [46, 47].

3.2 Chest X-ray

Chest radiograph is a radiographic procedure that uses low-energy ionizing radiation (X-rays) to visualize the chest organs. This procedure is very crucial in the assessment of lung and heart signs and symptoms such as cough, chest infection, injury, and discomfort [48]. This procedure is used to evaluate and screen heart inflammatory diseases such as myocarditis and pericarditis. This procedure is noninvasive and does not require special patient preparation. Chest radiography is a standard procedure for myocarditis and pericarditis patients. A distended cardiac shadow might be identified with accumulated fluids. Chest X-ray shows cardiac enlargement as a result of chamber dilatation, pericardial effusion, interstitial infiltrates, and pleural effusions (**Figure 4**) [49–51].

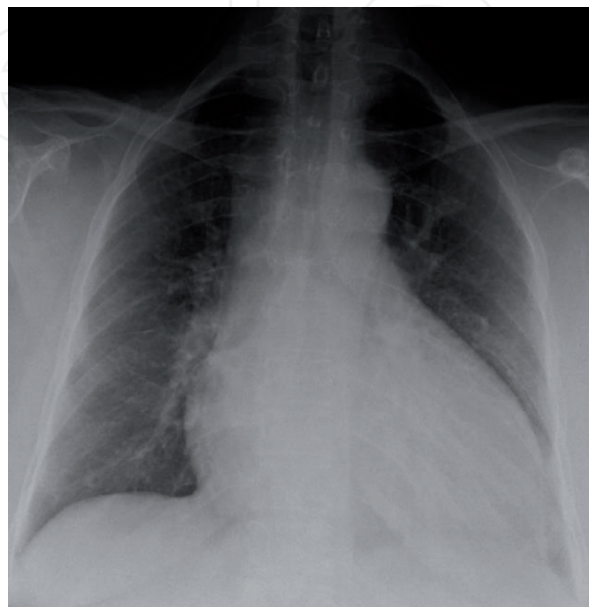


Figure 4.
Shows chest radiograph of myocarditis patient.

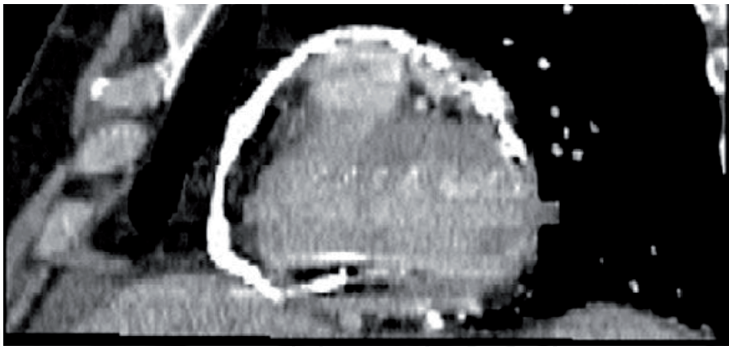


Figure 5.
Shows computed tomography of the pericardium.

3.3 Computed tomography (CT)

Computed tomography provides clear images of pericardium space and infection complications. Nuclear cardiology can delimit the pericarditis. Pericardiocentesis is indicated for pericardial effusion, pus-filled pericarditis, and suspected tumor (Figure 5) [52].

3.4 Nuclear medicine

FDG PET-CT can be used for visualization of myocarditis and pericarditis. This technique helps to differentiate between the acute and chronic cardiomyopathy diseases. Recently PET/MRI is used for detecting myocarditis and pericarditis [53]. The evaluation of myocarditis using nuclear scanning had started in the early 1970s. This scanning technique had started by using gallium-67 to visualize the internal

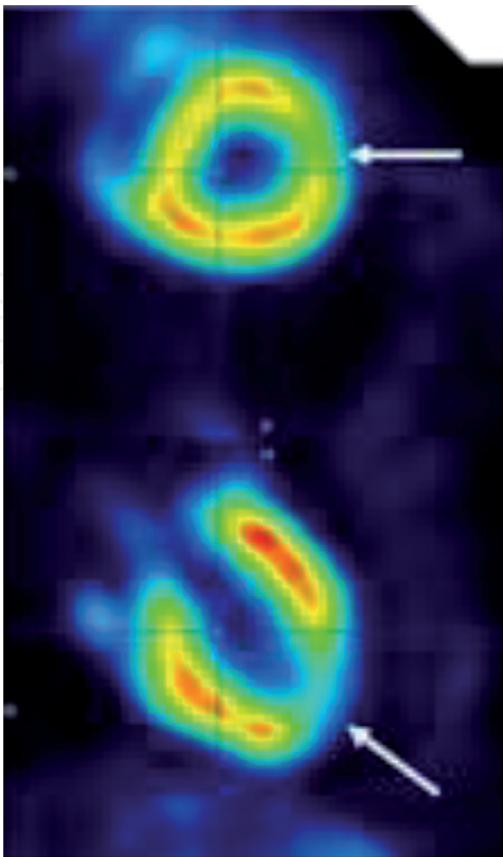


Figure 6.
Shows the nuclear medicine image of myocarditis.

muscles of the heart. In the early 1980s, the utilization of SPECT enhanced the results of detection of the myocardial tissues. So the detection of the myocarditis and pericarditis became easier than using planar scanner. The radioiodine-labeled (I-111) was introduced in the 1970s. This radioactive test was used to detect monoclonal antimyosin antibodies because of its ability to detect the necrotic area (**Figure 6**) [54].

4. Using cardiovascular magnetic resonance (CMR) in the assessment of myocarditis and pericarditis

Recently, CMR has become a crucial tool for acute myocardial tissue damage. In Europe, CMR represents the differential diagnosis of 1/3 of the cardiac cases [55]. CMR is used to detect the features of myocarditis edema and is related with pericardial fluids, which might be visualized together in images. CMR enables the evaluation of myocardial fluid accumulation and infection process. The CMR gives high accuracy and recognition of the acute inflammatory process, regardless of image quality differences due to the scanner and applied procedure [56, 57]. CMR might detect the accumulation of fluids which represents [58]. The body coil might help in the reduction of acquiesced signal noise, signal scattering, flow suppression, suitable slice width, and sufficient scanning time. Sixteen short-axis views are suggested to decrease the artifacts associated with the sluggish transplanar blood stream. In females, the mild edema is scanned using the signal that normalizes to skeletal muscle in similar slice. The gadolinium (Gd) might increase the recognition of the myocarditis edema especially after using contrast media-sensitive sequence and T1-weighted image. The comparison between the signals, prior and throughout the contrast-enhanced scanning, might show the large volume of edema. Consequently, using the adjacent muscle as reference helps in detecting of the edema area [61–63]. Recently, many studies showed that using Lake Louise criteria does not affect the diagnosis, but they increase the possibilities of the false-positive probability rate (**Figure 7**) [59].

Other studies showed that an amplified Gd enhancement ratio of more than 4.0 is related to patient complications and disease prognosis [60]. T2-weighted images might be used to detect myocardial edema, which indicates the presence of myocarditis. This technique had shown high precision and accuracy. The patients'

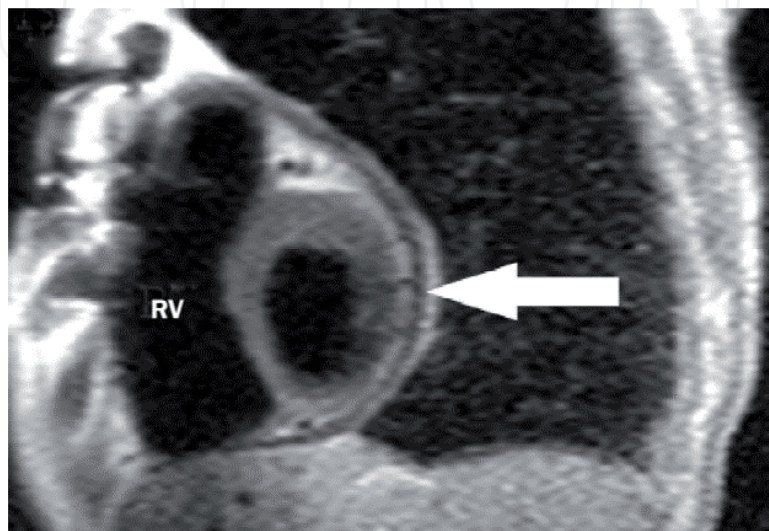


Figure 7.
Shows cardiovascular magnetic resonance of the pericardium.

movements and image artifacts affect the quality of the images. The new scanning protocol overcomes those problems by using the short acquisition time [61–63].

5. Conclusion

Myocardium inflammation is considered as a serious condition that affects both pediatric and adult patients with fetal consequences disease. The chronic myocardial inflammation might eventually lead to cardiac failure. Recently, the evolution in tools of diagnosis, screening, and treatment might decrease the morbidity rate of myocarditis and pericarditis.

About 10% of myocarditis has been discovered in autopsy. Many studies had shown that the best modality to diagnose the myocarditis is a biopsy. Many imaging techniques might be used to diagnose myocarditis and pericarditis; nevertheless, the CMR is the most crucial and precise analytical modality. CMR might help in differentiating between the myocardial infraction, inflammation, and injuries and the degree of severity. The fluoroscopic endomyocardial procedures have low complications compared with other invasive tools. The advance CMR protocols are used to improve the diagnosis and reduce the morbidity.

Acknowledgements

The authors are thankful to the Deanship of Scientific Research, at Majmaah University, for funding this research.

Conflict of interest

There are no conflicts of interest.

Author details

Yousif Mohamed Y. Abdallah^{1*} and Nouf H. Abuhadi²

1 Radiological Science and Medical Imaging Department, College of Applied Medical Science, Majmaah University, Majmaah, Saudi Arabia

2 Diagnostic Radiology Department, College of Applied Medical Science, Jazan University, Jazan, Saudi Arabia

*Address all correspondence to: y.yousif@mu.edu.sa

IntechOpen

© 2019 The Author(s). Licensee IntechOpen. This chapter is distributed under the terms of the Creative Commons Attribution License (<http://creativecommons.org/licenses/by/3.0>), which permits unrestricted use, distribution, and reproduction in any medium, provided the original work is properly cited. 

References

- [1] Assomull RG, Lyne JC, Keenan N, Gulati A, Bunce NH, Davies SW, et al. The role of cardiovascular magnetic resonance in patients presenting with chest pain, raised troponin, and unobstructed coronary arteries. *European Heart Journal*. 2007;**28**:1242-1249
- [2] Cooper LT Jr. Myocarditis. *The New England Journal of Medicine*. 2009;**360**:1526-1538
- [3] Kindermann I, Barth C, Mahfoud F, Ukena C, Lenski M, Yilmaz A, et al. Update on myocarditis. *Journal of the American College of Cardiology*. 2012;**59**:779-792
- [4] Cooper LT, Baughman KL, Feldman AM, Frustaci A, Jessup M, Kuhl U, et al. American Heart Association; American College of Cardiology; European Society of Cardiology. The role of endomyocardial biopsy in the management of cardiovascular disease: A scientific statement from the American Heart Association, the American College of Cardiology, and the European Society of Cardiology. *Circulation*. 2007;**116**:2216-2233
- [5] Jeserich M, Konstantinides S, Pavlik G, Bode C, Geibel A. Non-invasive imaging in the diagnosis of acute viral myocarditis. *Clinical Research in Cardiology*. 2009;**98**:753-763
- [6] Morimoto S, Kato S, Hiramitsu S, Uemura A, Ohtsuki M, Kato Y, et al. Role of myocardial interstitial edema in conduction disturbances in acute myocarditis. *Heart and Vessels*. 2006;**21**:356-360
- [7] Goitein O, Matetzky S, Beinart R, Di Segni E, Hod H, Bentancur A, et al. Acute myocarditis: Noninvasive evaluation with cardiac MRI and transthoracic echocardiography. *AJR. American Journal of Roentgenology*. 2009;**192**:254-258
- [8] Mendes LA, Dec GW, Picard MH, Palacios IF, Newell J, Davidoff R. Right ventricular dysfunction: An independent predictor of adverse outcome in patients with myocarditis. *American Heart Journal*. 1994;**128**:301-307
- [9] Bruder O, Wagner A, Lombardi M, Schwitter J, van Rossum A, Pilz G, et al. European cardiovascular magnetic resonance (EuroCMR) registry—multi national results from 57 centers in 15 countries. *Journal of Cardiovascular Magnetic Resonance*. 2013;**15**:9
- [10] Abdel-Aty H, Boyé P, Zagrosek A, Wassmuth R, Kumar A, Messroghli D, et al. Diagnostic performance of cardiovascular magnetic resonance in patients with suspected acute myocarditis: Comparison of different approaches. *Journal of the American College of Cardiology*. 2005;**45**:1815-1822
- [11] Ong P, Athansiadis A, Hill S, Kispert EM, Borgulya G, Klingel K, et al. Usefulness of pericardial effusion as new diagnostic criterion for noninvasive detection of myocarditis. *The American Journal of Cardiology*. 2011;**108**:445-452
- [12] Grün S, Schumm J, Greulich S, Wagner A, Schneider S, Bruder O, et al. Long-term follow-up of biopsy-proven viral myocarditis: Predictors of mortality and incomplete recovery. *Journal of the American College of Cardiology*. 2012;**59**:1604-1615
- [13] Chu GC, Flewitt JA, Mikami Y, Vermes E, Friedrich MG. Assessment of acute myocarditis by cardiovascular MR: Diagnostic performance of shortened protocols. *The International Journal of Cardiovascular Imaging*. 2013;**29**:1077-1083

- [14] Friedrich MG, Sechtem U, Schulz-Menger J, Holmvang G, Alakija P, Cooper LT, et al. International consensus group on cardiovascular magnetic resonance in myocarditis. Cardiovascular magnetic resonance in myocarditis: A JACC White paper. *Journal of the American College of Cardiology*. 2009;**53**:1475-1487
- [15] American College of Cardiology Foundation Task Force on Expert Consensus Documents, Hundley WG, Bluemke DA, Finn JP, Flamm SD, Fogel MA, et al. ACCF/ACR/AHA/NASCI/SCMR 2010 Expert Consensus Document on Cardiovascular Magnetic Resonance: A Report of the American College of Cardiology Foundation Task Force on Expert Consensus Documents. Vol. 552010. pp. 2614-2662
- [16] Friedrich MG, Larose E, Patton D, Dick A, Merchant N, Paterson I. Canadian society for CMR. Canadian Society for Cardiovascular Magnetic Resonance (CanSCMR) recommendations for cardiovascular magnetic resonance image analysis and reporting. *The Canadian Journal of Cardiology*. 2013;**29**:260-265
- [17] Zagrosek A, Wassmuth R, Abdel-Aty H, Rudolph A, Dietz R, Schulz-Menger J. Relation between myocardial edema and myocardial mass during the acute and convalescent phase of myocarditis—A CMR study. *Journal of Cardiovascular Magnetic Resonance*. 2008;**10**:19
- [18] Ferreira VM, Piechnik SK, Dall'Armellina E, Karamitsos TD, Francis S, Moore JM, Ntusi N, Holloway C Choudhury RP, Kardos A, Robson MD, Friedrich MG*, Neubauer S. T1-mapping for the Diagnosis of Acute Myocarditis Using Cardiovascular Magnetic Resonance: Comparison to T2-weighted and Late Gadolinium Enhancement. *JACC: Cardiovascular Imaging*. 2013;**6**(10):1048-1058
- [19] Eitel I, von Knobelsdorff-Brenkenhoff F, Bernhardt P, Carbone I, Muellerleile K, Aldrovandi A, et al. Clinical characteristics and cardiovascular magnetic resonance findings in stress (takotsubo) cardiomyopathy. *JAMA*. 2011;**306**:277-286
- [20] Dall'Armellina E, Piechnik SK, Ferreira VM, Si QL, Robson MD, Francis JM, et al. Cardiovascular magnetic resonance by non contrast T1-mapping allows assessment of severity of injury in acute myocardial infarction. *Journal of Cardiovascular Magnetic Resonance*. 2012;**14**:15
- [21] O h-Ici D, Ridgway JP, Kuehne T, Berger F, Plein S, Sivananthan M, et al. Cardiovascular magnetic resonance of myocardial edema using a short inversion time inversion recovery (STIR) black-blood technique: Diagnostic accuracy of visual and semi-quantitative assessment. *Journal of Cardiovascular Magnetic Resonance*. 2012;**14**:22
- [22] Monney PA, Sekhri N, Burchell T, Knight C, Davies C, Deaner A, et al. Acute myocarditis presenting as acute coronary syndrome: Role of early cardiac magnetic resonance in its diagnosis. *Heart*. 2011;**97**:1312-1318
- [23] Ferreira VM, Piechnik SK, Dall'Armellina E, Karamitsos TD, Francis JM, Choudhury RP, et al. Noncontrast T1-mapping detects acute myocardial edema with high diagnostic accuracy: A comparison to T2-weighted cardiovascular magnetic resonance. *Journal of Cardiovascular Magnetic Resonance*. 2012;**14**:42
- [24] Cocker MS, Abdel-Aty H, Strohm O, Friedrich MG. Age and gender effects on the extent of myocardial involvement in acute myocarditis: A cardiovascular magnetic resonance study. *Heart*. 2009;**95**:1925-1930
- [25] Jerosch-Herold M, Sheridan DC, Kushner JD, Nauman D, Burgess D,

- Dutton D, et al. Cardiac magnetic resonance imaging of myocardial contrast uptake and blood flow in patients affected with idiopathic or familial dilated cardiomyopathy. *American Journal of Physiology. Heart and Circulatory Physiology*. 2008;**295**:H1234-H1242
- [26] Wagner A, Schulz-Menger J, Dietz R, Friedrich MG. Long-term followup of patients with acute myocarditis by magnetic resonance imaging. *Magma*. 2003;**16**:17-20
- [27] Mavrogeni S, Spargias C, Bratis C, Kolovou G, Markussis V, Papadopoulou E, et al. Myocarditis as a precipitating factor for heart failure: Evaluation and 1-year follow-up using cardiovascular magnetic resonance and endomyocardial biopsy. *European Journal of Heart Failure*. 2011;**13**:830-837
- [28] Eitel I, Kubusch K, Strohm O, Desch S, Mikami Y, de Waha S, et al. Prognostic value and determinants of a hypointense infarct core in T2-weighted cardiac magnetic resonance in acute reperfused ST infarction. *Circulation. Cardiovascular Imaging*. 2011;**4**:354-362
- [29] Kabbani SS, LeWinter MM. Pericardial diseases. *Current Treatment Options in Cardiovascular Medicine*. 2002;**4**:487-495
- [30] Spodick DH. Colchicine effectively and safely treats acute pericarditis and prevents and treats recurrent pericarditides. *Heart*. 2012;**98**:1035-1036
- [31] Spodick DH. Risk prediction in pericarditis: Who to keep in hospital? *Heart*. 2008;**94**:398-399
- [32] Lilly LS. Treatment of acute and recurrent idiopathic pericarditis. *Circulation*. 2013;**127**:1723-1726
- [33] Imazio M. Contemporary management of pericardial diseases. *Current Opinion in Cardiology*. 2012;**27**:308-317
- [34] Imazio M. Pericardial involvement in systemic inflammatory diseases. *Heart*. 2011;**97**:1882-1892
- [35] Imazio M, Brucato A, Barbieri A. Good prognosis for pericarditis with and without myocardial involvement: Results from a multicenter, prospective cohort study. *Circulation*. 2013;**128**:42-49
- [36] Imazio M, Cooper LT. Management of myopericarditis. *Expert Review of Cardiovascular Therapy*. 2013;**11**:193-201
- [37] Soler-Soler J, Sagristà-Sauleda J, Permanyer-Miralda G. Relapsing pericarditis. *Heart*. 2004;**90**:1364-1368
- [38] Imazio M, Brucato A, Cemin R, et al. ICAP investigators. A randomized trial of colchicine for acute pericarditis. *The New England Journal of Medicine*. 2013;**369**:1522-1528
- [39] Hoit BD. Management of effusive and constrictive pericardial heart disease. *Circulation*. 2002;**105**:2939-2942
- [40] Sagristà-Sauleda J, Angel J, Sánchez A, et al. Effusive-constrictive pericarditis. *The New England Journal of Medicine*. 2004;**350**:469-475
- [41] Imazio M, Cecchi E, Demicheli B, et al. Myopericarditis versus viral or idiopathic acute pericarditis. *Heart*. 2008;**94**:498-501
- [42] Syed FF, Ntsekhe M, Gumedze F, et al. Myopericarditis in tuberculous pericardial effusion: Prevalence, predictors and outcome. *Heart*. 2014;**100**:135-139
- [43] Ntsekhe M, Mayosi BM. Tuberculous pericarditis with and without HIV. *Heart Failure Reviews*. 2013;**18**:367-373

- [44] Permanyer-Miralda G. Acute pericardial disease: Approach to the aetiologic diagnosis. *Heart*. 2004;**90**:252-254
- [45] Snyder MJ, Bepko J, White M. Acute pericarditis: diagnosis and management. *American Family Physician*. 2014;**89**:553-560
- [46] Rossello X, Wiegerinck RF, Alguersuari J. New electrocardiographic criteria to differentiate acute pericarditis and myocardial infarction. *The American Journal of Medicine*. 2014;**127**:233-239
- [47] Klein AL, Abbata S, Agler DA, et al. American Society of Echocardiography clinical recommendations for multimodality cardiovascular imaging of patients with pericardial disease: Endorsed by the Society for Cardiovascular Magnetic Resonance and Society of cardiovascular computed tomography. *Journal of the American Society of Echocardiography*. 2013;**26**:965-1012
- [48] Rigante D, Cantarini L, Imazio M, et al. Autoinflammatory diseases and cardiovascular manifestations. *Annals of Medicine*. 2011;**43**:341-346
- [49] Cantarini L, Rigante D, Merlini G, et al. The expanding spectrum of low-penetrance TNFRSF1A gene variants in adults presenting with recurrent inflammatory attacks: Clinical manifestations and long-term follow-up. *Seminars in Arthritis and Rheumatism*. 2014;**43**:818-823
- [50] Abu Fanne R, Banai S, Chorin U, et al. Diagnostic yield of extensive infectious panel testing in acute pericarditis. *Cardiology*. 2011;**119**:134-139
- [51] Lazaros G, Vlachopoulos C, Stefanadis C. Extensive infectious panel testing for acute pericarditis: A ghost hunt? *Cardiology*. 2011;**119**:131-133
- [52] Sagristá Sauleda J, Almenar Bonet L, Angel Ferrer J, et al. The clinical practice guidelines of the Sociedad Española de Cardiología on pericardial pathology. *Revista Española de Cardiología*. 2000;**53**:394-412
- [53] Yared K, Baggish AL, Picard MH, et al. Multimodality imaging of pericardial diseases. *JACC: Cardiovascular Imaging*. 2010;**3**:650-660
- [54] Verhaert D, Gabriel RS, Johnston D, et al. The role of multimodality imaging in the management of pericardial disease. *Circulation. Cardiovascular Imaging*. 2010;**3**:333-343
- [55] Horneffer PJ, Miller RH, Pearson TA, et al. The effective treatment of postpericardiotomy syndrome after cardiac operations. A randomized placebo-controlled trial. *The Journal of Thoracic and Cardiovascular Surgery*. 1990;**100**:292-296
- [56] Lotrionte M, Biondi-Zoccai G, Imazio M, et al. International collaborative systematic review of controlled clinical trials on pharmacologic treatments for acute pericarditis and its recurrences. *American Heart Journal*. 2010;**160**:662-670
- [57] Vianello F, Cinetto F, Cavarero M, et al. Azathioprine in isolated recurrent pericarditis: A single Centre experience. *International Journal of Cardiology*. 2011;**147**:477-478
- [58] Abdallah Y. Improvement of sonographic appearance using HAT-TOP methods. *International Journal of Science and Research (IJSR)*. 2015;**4**(2):2425-2430
- [59] Abdallah Y. Increasing of edges recognition in cardiac Scintigraphy for ischemic patients. *Journal of Biomedical Engineering and Medical Imaging*. 2016;**2**(6):39-40

[60] Abdallah Y. Increasing of Edges Recognition in Cardiac Scintography for Ischemic Patients. Berlin, Germany: Lambert Publishing Press GmbH & Co. KG; 2011. pp. 123-125

[61] Abdallah YM. History of medical imaging. Archives of Medicine and Health Sciences. 2017;5:275-278

[62] Abdallah Y. An Introduction to PACS in Radiology Service: Theory and Practice. Vol. 2. Berlin, Germany: LAP LAMBERT Academic Publishing; 2012. pp. 140-153

[63] Abdallah Y, Wagiallah E, Yousef M. Improvement of nuclear cardiology images for ischemic patients using image processing techniques. SMU Medical Journal. 2015;2(2):2415-2419