

We are IntechOpen, the world's leading publisher of Open Access books Built by scientists, for scientists

6,900

Open access books available

185,000

International authors and editors

200M

Downloads

Our authors are among the

154

Countries delivered to

TOP 1%

most cited scientists

12.2%

Contributors from top 500 universities



WEB OF SCIENCE™

Selection of our books indexed in the Book Citation Index
in Web of Science™ Core Collection (BKCI)

Interested in publishing with us?
Contact book.department@intechopen.com

Numbers displayed above are based on latest data collected.
For more information visit www.intechopen.com



Tooth Morphology Overview

*Abeer ALShami, Shatha ALHarthi, Munerah Binshabaib
and Monika Wahi*

Abstract

This chapter provides an overview of tooth morphology, including a review of tooth anatomy, tooth development, and associated nomenclature and numbering systems. First, basic tooth morphology nomenclature is presented. Next, various tooth numbering systems are described and discussed, and the Federation Dentaire Internationale (FDI) system is detailed. Third, tooth surfaces and ridges are explained along with terminology, followed by an explanation of tooth crown and root anatomy. Fourth, the stages of tooth formation are described, starting with the bud stage, and followed by the cap stage, bell stage, and maturation. Annotated diagrams are presented for clarity. Finally, two currently accepted hypotheses explaining tooth formation are presented.

Keywords: tooth, tooth components, odontogenesis

1. Introduction

In order to understand tooth morphology, it is necessary to understand the anatomy of the structures within the tooth. In order to understand these, it is helpful to understand tooth development. Therefore, this chapter will cover tooth development and explain the tissues and structures involved in tooth growth. Because teeth take a variety of forms, it is necessary to enumerate them with numbering systems and apply nomenclature; these will be described as well.

To be most understandable, this chapter will begin by presenting the nomenclature associated with tooth morphology. Next, tooth numbering systems will be described and presented. Third, the anatomy of the crown and root of the tooth will be covered, and an explanation of tooth surfaces and ridges presented. Finally, an overview of tooth development will be provided, following the tooth through the bud stage, cap stage, bell stage, and maturation. Finally, two hypotheses behind tooth formation will be explained.

2. Nomenclature

In order to understand tooth morphology, it is important to understand both the nomenclature and the associated anatomy. To begin, the human jaw consists of two parts: the maxillary, referring to the upper jaw, and the mandibular, referring to the lower jaw (see **Figure 1**) [1]. The maxillary is divided into two quadrants called the upper left quadrant and the upper right quadrant. The mandibular is divided into the lower left quadrant and the lower right quadrant.

Humans have two sets of teeth during their lifetime. The first set is called the primary teeth (also called deciduous dentition), and are the first teeth to appear in the mouth. The primary teeth are replaced later on in childhood with permanent teeth (also referred to as succedaneous teeth) [1]. **Figure 1** shows a diagram of an adult human jaw with complete teeth.

Adult humans have four types of teeth: molars, premolars, canine teeth, and incisors (see **Figure 2**). As seen in **Figure 2**, in the adult jaw, there are a total of 32 teeth [1]. Both the mandibular and the maxillary have two front teeth, and these are called the central incisors. On either side of the pair of central incisors is a lateral incisor [1]. The lateral incisor on each side is followed by one canine tooth, which is followed by two premolars, which are then followed by three molars. In primary teeth, there are a total of 20 teeth [2]. Like with adults, primary teeth have the same central incisors, lateral incisors, and canines [2]. However, in primary teeth, the canines are followed by a first molar and second molar [2]. The first molar will eventually be exfoliated and replaced by the two premolars, and the second molar will eventually be exfoliated and replaced by the three molars [2].

As seen in **Figure 1**, the jaw is divided into quadrants. The teeth are numbered by quadrant using the Federation Dentaire Internationale (FDI) system, which will be explained in the next section.

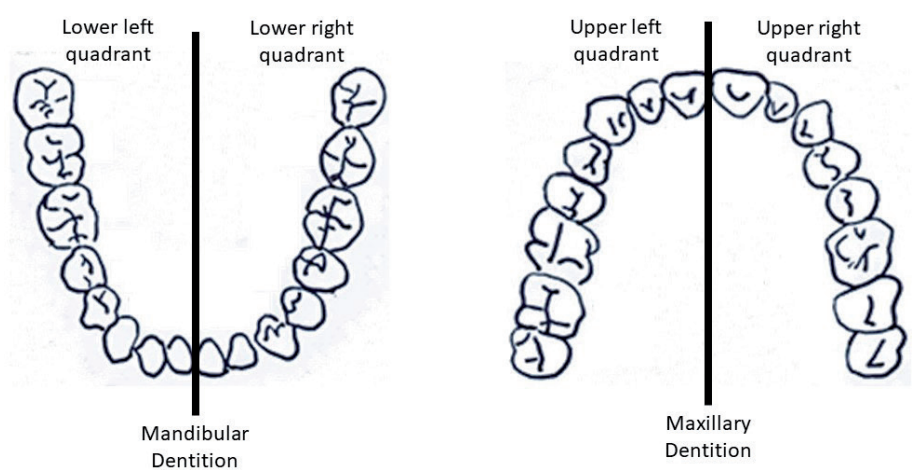


Figure 1.
Adult human jaw with quadrants.

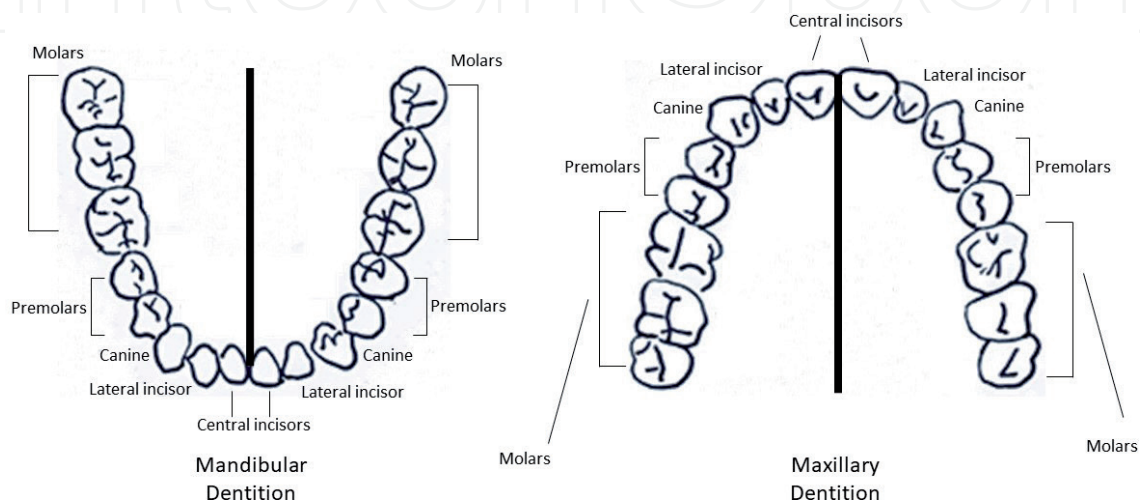


Figure 2.
Adult human jaw with tooth types.

2.1 Tooth numbering systems

Several systems are used in clinical practice for dental notation. In the late 1800s, the Zsigmondy-Palmer system, which is an “eight numerical quadrant system,” came into use [3]. However, the coding involved complex symbols and was hard to adopt [3]. Next, the Universal System was proposed, and has been adopted by the American Dental Association (ADA) since 1975 [3]. Unfortunately, this system has the weakness of lacking an anatomic reference, so matching teeth and quadrants can be confusing [3].

In 1966, the FDI System was introduced [3]. Unlike the previous systems, it is simple and accurate while still being easy to memorize and apply [3]. Hence, it was adopted in 1970 by the FDI and later in 1994 by the International Standard Organization (ISO) [3, 4]. The main drawback of the FDI system is that with respect to primary teeth, it can be confusing and challenging to memorize [3]. However, this chapter will focus mainly on adult tooth morphology, so we will use the terminology from the FDI system.

2.1.1 The FDI system for primary teeth

Figure 3 shows the FDI numbering system for primary teeth. Each tooth is assigned a two-digit number. The first digit refers to the quadrant, with five representing the maxillary right quadrant, six representing the maxillary left quadrant, and seven and eight representing the mandibular right and left quadrants, respectively [4]. The second digit in the number represents the tooth number [4]. As an example, tooth 62 represents the maxillary left lateral incisor, and tooth 85 represents the mandibular right second molar. The pronunciation of the numbers is by digits; so tooth 62 is pronounced as “six, two,” not “sixty-two,” and tooth 85 is pronounced as “eight, five,” not “eighty-five.”

Upper Right					Upper Left				
55	54	53	52	51	61	62	63	64	65
85	84	83	82	81	71	72	73	74	75
Lower Right					Lower Left				

Figure 3.
FDI system for primary teeth.

2.1.2 The FDI system for permanent teeth

Figure 4 shows the FDI system for permanent teeth. As with primary teeth, the first digit represents the quadrant, so one represents the maxillary right quadrant, two represents the maxillary left quadrant, and three and four represent the mandibular right and left quadrants, respectively [4]. The second digit in the number represents the tooth number; so tooth 35 would be the mandibular left second premolar and tooth 17 would be the maxillary right second molar.

Upper Right								Upper Left							
18	17	16	15	14	13	12	11	21	22	23	24	25	26	27	28
48	47	46	45	44	43	42	41	31	32	33	34	35	36	37	38
Lower Right								Lower Left							

Figure 4.
FDI system for permanent teeth.

2.2 Tooth surfaces and ridges

Permanent teeth are divided into two groups: anterior teeth and posterior teeth. Anterior teeth include the teeth toward the front of the mouth, including the central incisors, the lateral incisors, and the canines, while posterior teeth, or the teeth toward the back of the mouth, include the premolars and molars [1]. The difference between these types of teeth will be described in the next section.

The crown is the part of the tooth that is visible in the oral cavity. The crowns of anterior teeth have four surfaces and one ridge, while posterior teeth only have surfaces [1] (see **Figure 5**). The surface of a tooth that is facing an adjacent tooth is referred to as a proximal surface. The area of the tooth that contacts the adjacent tooth is called the contact area [1]. In order to determine which proximal surface is being described, imagine a vertical line drawn down the center of the face. The proximal surface closest to that line would be considered as the mesial surface, and the one furthest from the line as the distal surface.

Another way to think about mesial and distal proximal surfaces is to consider them in relation to the palate. The palate refers to the upper portion of the mouth, where the maxillary dentition is housed. The surfaces facing the palate are referred to as palatal surfaces. On both anterior and posterior teeth, the distal surface is the surface facing away from the midline of the palate, and the mesial surface is the surface facing toward the midline of the palate [1].

As shown in **Figure 5**, the surfaces of anterior teeth facing the lips are referred to as labial surfaces, while the surfaces of posterior teeth facing the buccal mucosa are called buccal surfaces. Surfaces of posterior teeth which occlude opposing posterior surfaces are called occlusal surfaces. For example, in **Figure 5**, the occlusolingual line angle is likely on an occlusal surface. In anterior teeth, this situation is referred to as incisal surfaces [1]. In **Figure 5**, the incisocervical dimension would likely be an incisal surface.

In **Figure 5**, on the anterior tooth, a proximal surface would be near the mesiolabial line angle, and the distolingual and distolabial line angles would be away from the proximal surface. On the posterior tooth diagram in **Figure 5**, the mesiobuccal line angle and mesiodistal dimensions would be more likely to be on the proximal surface, while the distolingual and distobuccal line angles would be away from the proximal surface.

2.3 Crown and root anatomy

Each permanent tooth consists of a crown and root (see **Figure 6**). The crown is the part of the tooth that is visible in the oral cavity, while the root is the portion that is firmly embedded in the alveolar bone. The crown and root join at a surface

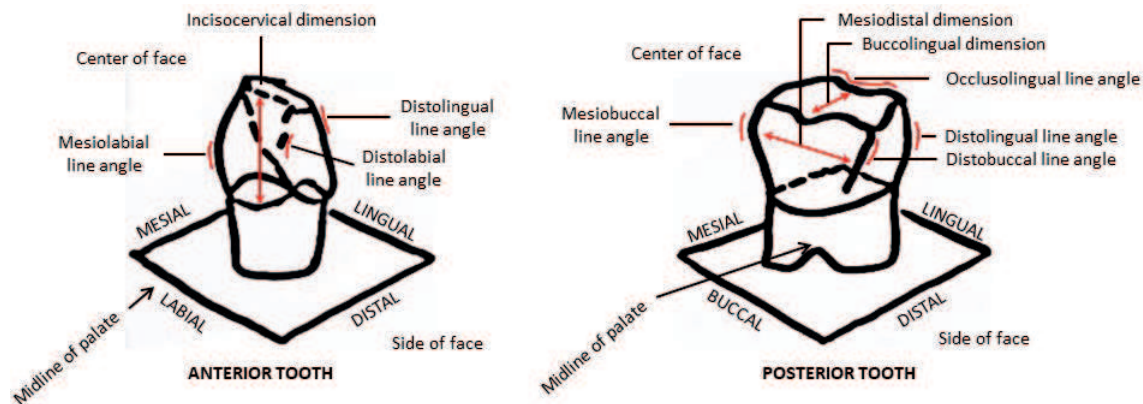


Figure 5.
Surfaces of anterior and posterior teeth.

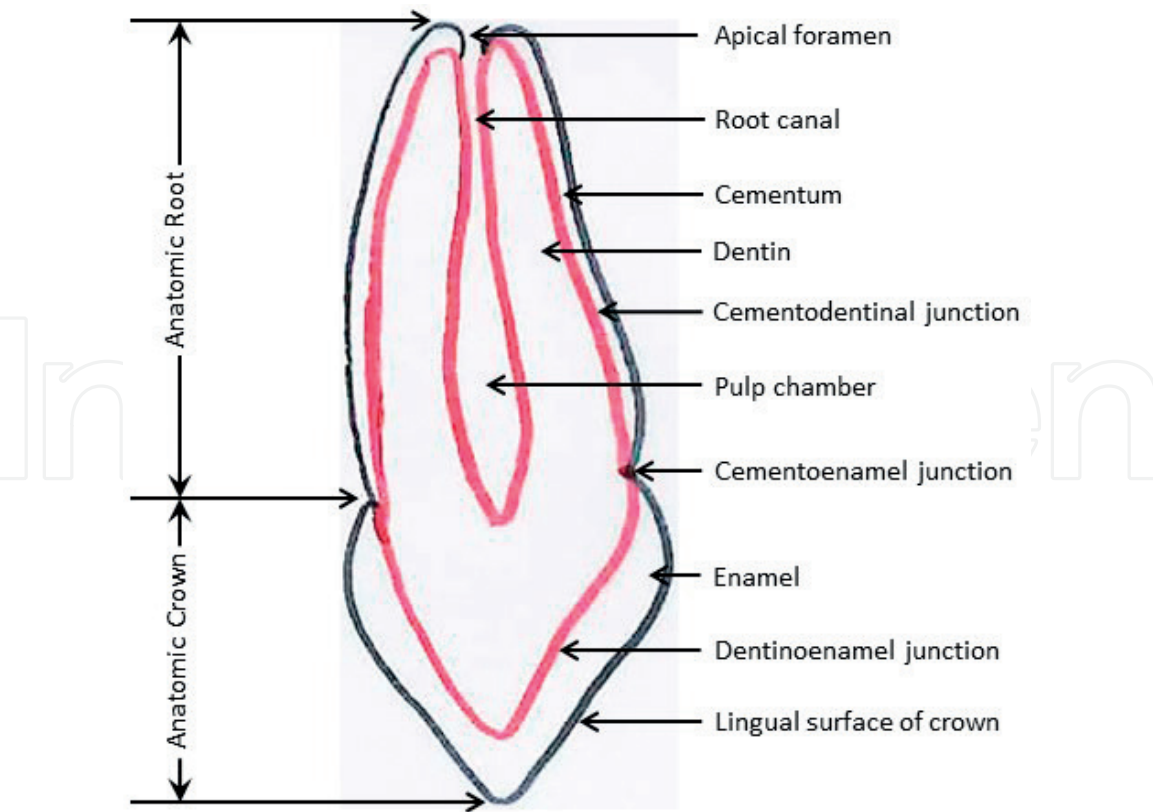


Figure 6.
Crown and root for permanent teeth.

called cementoenamel junction (CEJ) [1]. Please note that in **Figure 6**, the lingual surface of the crown is at the bottom of the diagram.

Human teeth have four types of tissues; the first three are enamel, dentin, and cementum, and these are referred to as hard tissues [1]. The fourth, pulp, is referred to as soft tissue [1]. In terms of the root, as shown in **Figure 6**, the pulp chamber consists of soft connective tissue that enervates and provides the blood supply to the tooth. The pulp chamber is surrounded by dentin, which is the inner portion of the tooth (surrounded by red in the diagram).

Dentin makes up the largest proportion of tissue in the tooth. In the root, the dentin is covered by a layer of cementum. At the top of the root is the apical foramen, where the nerves and blood supply can enter the pulp and transit to the pulp through the root canal. In terms of the crown, the dentin is surrounded by enamel, and where they meet is called the dentinoenamel junction [1].

As described earlier, the crown portion is covered by enamel, and the bulk of the crown is composed of dentin. The crown morphology varies among the dentition. The crowns of anterior teeth, such as central and lateral incisors, have cutting edges. Other teeth in the dentition have cusps to aid in chewing; canines have a single cusp, while premolars and molars have two or more cusps [1].

Regardless of type of tooth—molar, premolar, canine, or incisor—all adult teeth have features labeled with particular terminology. These features are illustrated in **Figure 7** using the example of a canine anterior tooth. Note in **Figure 7**, the apex of the root refers to the tip of the root, and the cusp refers to the opposite end of the tooth. The line between the apex of the root and the tip of the cusp is referred to as the root axis line. Per **Figure 7**, on the front view, the cusp can be said to start at where the slope starts; the distal slope and the mesial slope are labeled, and from here to the tip of the cusp is the cusp. The line that separates the crown from the root is called the cervical line, and the area where the crown meets the root is called the cervix [1].

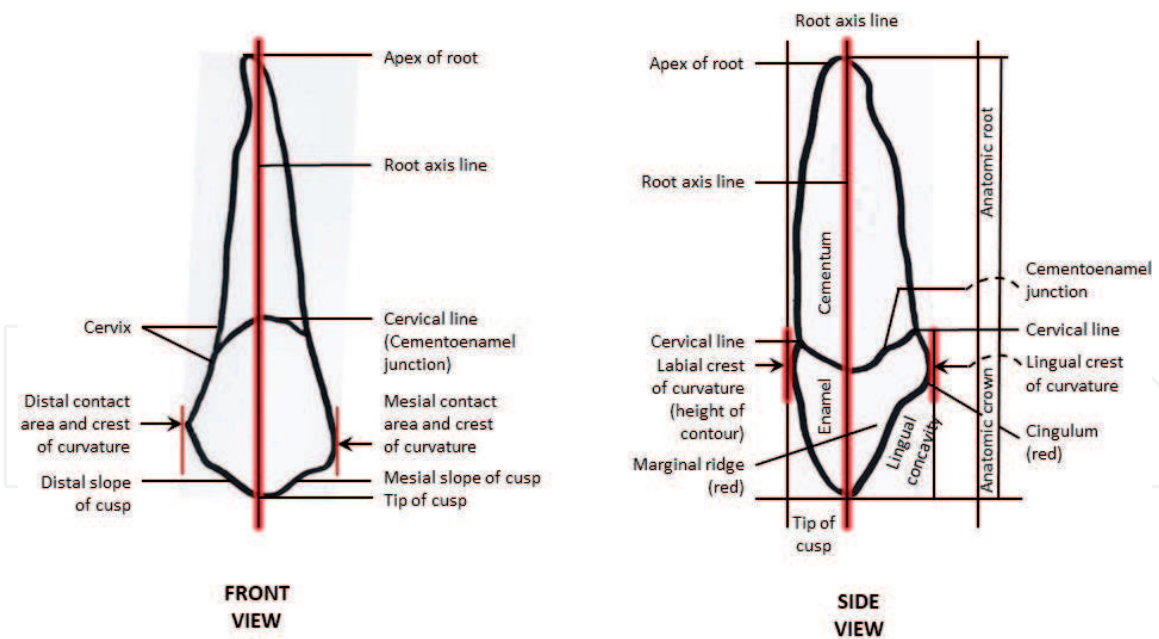


Figure 7.
Diagram of canine anterior tooth.

The curves in the crown are referred to as curvature. **Figure 7** shows the distal contact area and crest along with the mesial contact area and crest of the curvature from the front view, and the labial crest and lingual crest in the side view. Note in the side view that the lingual concavity, marginal ridge, and cingulum refer to the features behind the tooth.

Referring to **Figure 7**, please observe the sharp distal and mesial slopes of the cusp which give the canine tooth its cutting edge and make canine teeth optimized for tearing food [5]. The incisors share similar sharp edges, but are better at cutting food rather than tearing it [5]. Both the premolars and the molars have flatter surfaces; the distance between the tip of the cusp and the apex of the root are much shorter [5].

3. Stages of tooth formation

Tooth development goes through different stages: the bud stage, the cap stage, the bell stage, and finally, maturation. This section will explain the staging of tooth development so it is possible to understand both the embryological and the morphological aspects that take place along a continuum.

3.1 Bud stage

In the bud stage, the tooth bud forms, and the cells from the tooth bud come originally from the ectomesenchyme. The ectomesenchyme originates from the neural crest, which is a group of cells situated in the cranial region during the early development of the vertebrate. This ectomesenchyme layer takes the lead in the formation of the hard tissue in the body that includes bone and teeth. Ectomesenchymal cells congregate deep into the bud, forming an aggregation of cells, which is the initiation of the condensation of the ectomesenchyme [6].

One of the earliest signs in the formation of the tooth that can be seen microscopically is the dental lamina, situated next to the vestibular lamina, which begins to form the tooth bud (see **Figure 8**). The vestibular and dental lamina both originate from the buccopharyngeal membrane [1]. The vestibular lamina is responsible of the creation of the vestibular, which is the area between the junction

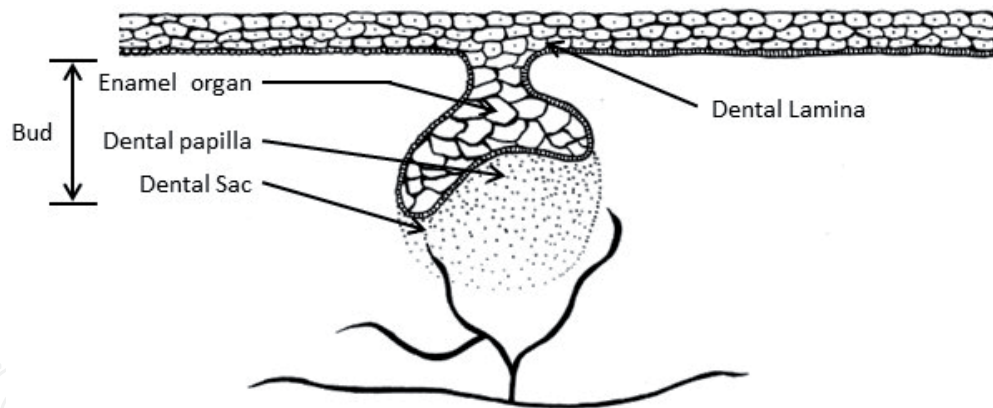


Figure 8.
Bud stage.

of the gingiva and the tissue of the cheek (not shown). It is usually formed after the formation of the dental lamina, around 37 days *in utero*.

The dental lamina is a bundle of epithelium tissue which appears as the earliest sign of tooth development, at 6 weeks *in utero*. When the dental lamina starts forming a tooth bud, it is called the bud stage (or initiation stage) (see **Figure 8**). The dental lamina connects the developing tooth bud to the epithelial layer of the mouth until full separation happens and the tooth forms [6].

As shown in **Figure 8**, first, the tooth bud appears with a random number of cells. Next, the epithelial cells proliferate into the ectomesenchyme of the jaw. This proliferation occurs when the fetus is about 8 weeks old.

From this proliferation, 10 round epithelial structures form. Each one of them will form its own bud, which will then develop into a tooth at the distal aspect of the dental lamina of each arch. This set of 10 teeth will represent the primary teeth of each dental arch. After this, each tooth bud becomes separated from the ectomesenchyme through the development of a basement membrane.

3.2 Cap stage

In the bud stage, the cells are randomly arranged, but once the cap stage is reached, the orderly arrangement of cells takes place (see **Figure 9**). A minor group of ectomesenchymal cells suppresses the production of extracellular substances, which leads to an aggregation of these cells within the dental follicle, forming the

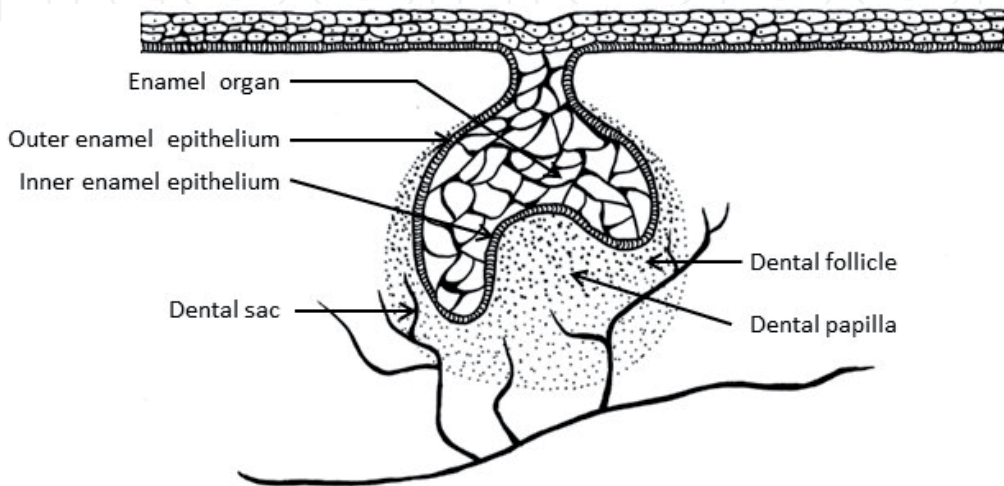


Figure 9.
Cap stage.

dental papilla. At this stage, the tooth bud grows around the dental papilla, forming the appearance of a cap, and becomes the enamel organ covering the dental papilla. Ectomesenchymal cells form the dental sac surrounding the enamel organ and limit the dental papilla. Eventually, the enamel organ will form enamel, the dental papilla will form dentin and pulp, and finally, the dental sac will form all the supporting structures of a tooth, and the periodontium [7].

Notice the Inner enamel epithelium (IEE) in **Figure 9**. During the cap stage, this undergoes rapid division called mitosis to increase cells that will later form the tooth pulp.

3.3 Bell stage

The bell stage is the third stage in the process of odontogenesis, where the enamel organ comes to resemble a bell shape (see **Figure 10**). At this stage, the interior of the enamel organ's cells is called stellate reticulum (SR), because of the star-shaped appearance of the cells. This is also the stage where histodifferentiation and morphodifferentiation take place, in which the different tissues of the tooth form and tooth shapes are established [8]. Notice in **Figure 10**, the SR of the enamel organ is bordered by a layer of ameloblasts, followed by a layer of odontoblasts; these are tissues where histodifferentiation and morphodifferentiation have taken place. Ameloblasts will evolve into enamel, and odontoblasts, which originate in the dental papilla, will later play a role in forming the organic matrix on which minerals will be deposited as part of tooth formation.

The bell stage is divided into two stages: the early bell stage and the late bell stage. They will be described here.

3.3.1 Early bell stage

The early bell stage is when morphodifferentiation and histodifferentiation take place, and the tooth crown assumes its final shape (see **Figure 11**). It has four different layers of epithelial cells. The outer enamel epithelium (OEE) is a layer of cuboidal cells that covers the enamel organ in a developing tooth. The IEE is a layer of columnar cells which covers the recess of the enamel organ in a developing tooth. The stratum intermedium (SI) is the layer of the cells between the IEE and the SR. As described before, the SR is a set of cells situated in the center of the enamel organ of a developing tooth that are shaped like a star. The rim of the enamel organ where the OEE and IEE link on each side is called the cervical loop (see **Figure 11**) [8].

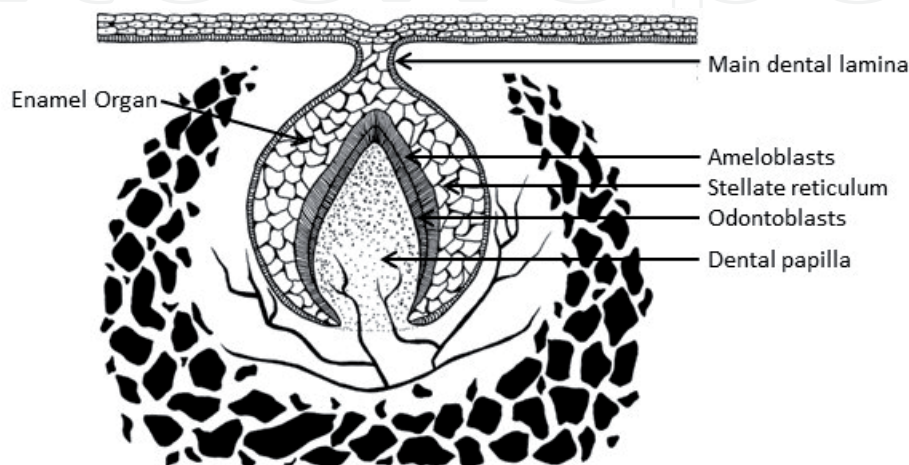


Figure 10.
Bell stage.

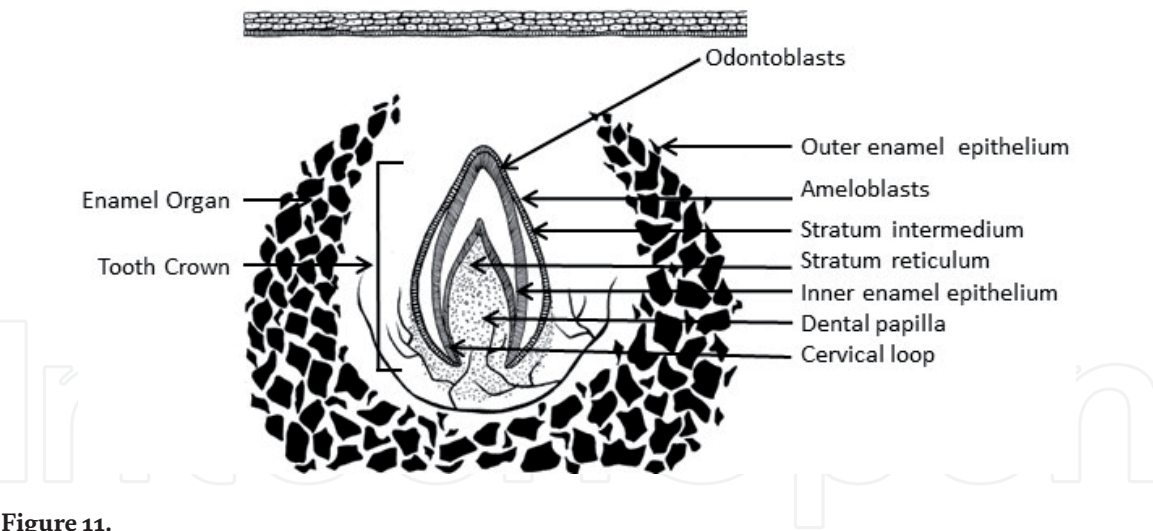


Figure 11.
Early bell stage.

The early bell stage represents sets of tissue that will evolve into the full tooth. The tissue layers that will develop, in order from innermost to outermost, will be composed of dentin, enamel (formed by IEE made of ameloblasts, as they move outward and upward), IEE, and SI. SI are stratified cells that support the synthetic activity of the IEE. Next, as shown in **Figure 11**, is the initial enamel organ, the center of which is made up of SR cells that serve to safeguard the enamel organ. there are all enclosed by the OEE layer [9].

Further events happen during the early bell stage. The dental lamina disintegrates, emancipating the developing tooth, which completely parts from the epithelium of the oral cavity. The developing tooth will remain separated from the epithelium until later, after the late bell stage, when the tooth will erupt into the mouth. During the early bell stage, the crown of the tooth takes shape, guided by the shape of the IEE.

3.3.2 *Advanced bell stage*

Throughout the advanced bell stage, hard tissues, including enamel and dentin, are developed. Some researchers call this phase the “crown stage.” In the advanced bell stage, significant cellular changes occur, and the mitosis that went on during the cap stage is arrested. As shown in **Figure 12**, at this time, the initial mineralized

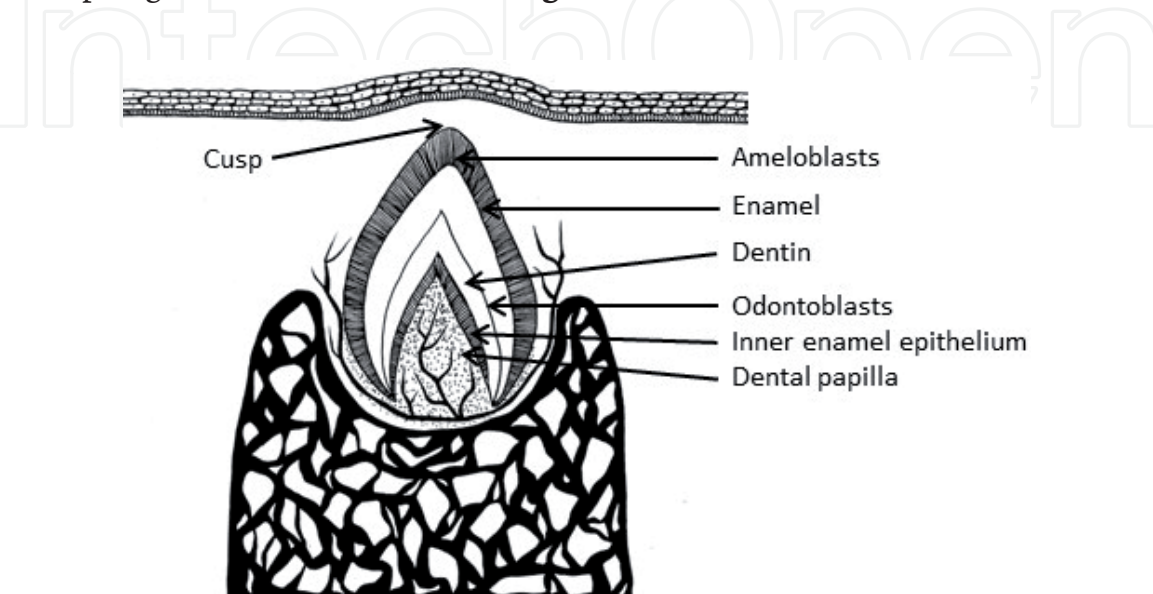


Figure 12.
Advanced bell stage.

hard tissues form into the dentin and the enamel. The IEE cells adjust in shape from cuboidal to columnar and evolve into preameloblasts simultaneously. The nuclei of these preameloblasts move outward, away from the dental papilla as they evolve, and their surface stretches [8].

The cells that form dentin originate in the dental papilla. They randomly grow in size and discern into odontoblasts (see **Figure 12**). Researchers believe that the odontoblasts would not form if it was not for the developments occurring in the IEE. The odontoblasts secrete a substance into their immediate surroundings during development that forms an organic matrix. This reaches the IEE, and the formation of odontoblasts continues from the tip of the cusp [10].

Dentin formation requires materials that are present in the organic matrix. As odontoblasts deposit minerals onto the organic matrix to create predentin, they move toward the center of the dental papilla. Dentin begins forming on the surface nearest to the outside of the tooth and continues inward. In contrast, the enamel grows outward.

Cytoplasmic extensions are left behind as the odontoblasts move inward. The resulting unique tubular microscopic appearance allows for the creation of dentin around these extensions. The cells of the IEE conceal an organic matrix against the dentin after dentin formation begins. This matrix directly mineralizes, and becomes the primary layer of the tooth's enamel. Ameloblasts proliferate to facilitate the final formation of the enamel layer.

3.3.3 Maturation stage

The maturation stage, also called “apposition,” is considered by many as the final stage of tooth formation. However, others do not agree with this nomenclature, as it essentially refers to the final period after the tooth is fully formed.

In the maturation stage, both enamel and dentin increase in thickness, and cementum forms after eruption, and follows the development of the root (see **Figure 13**). This stage is extremely important for crown formation, as any disturbance at this stage will cause a major deformity in crown development. Potential

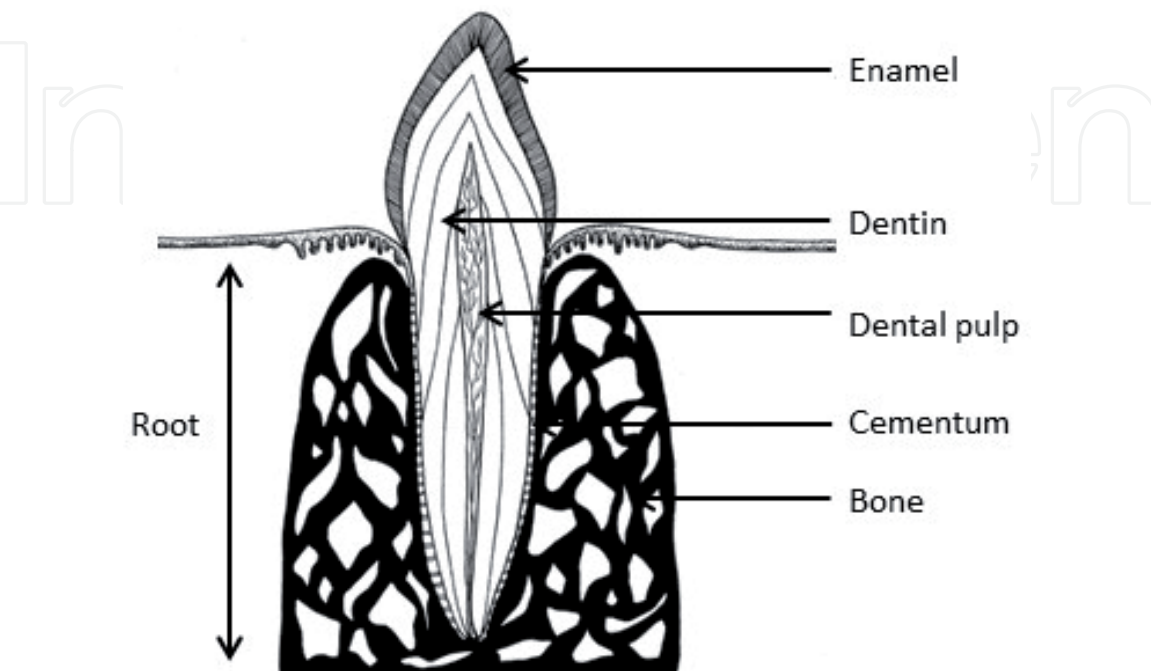


Figure 13.
Maturation stage.

deformities include enamel hypoplasia or hypocalcification, which can manifest clinically as white or yellowish spots on the crown. In addition, tooth development at this stage is very sensitive to any illness in the mother during pregnancy, which can impact primary teeth. Further, illness in the first year of the child's life can impact enamel formation in permanent teeth [11].

4. Tooth morphology hypotheses

Throughout the mouth, though all teeth develop through these stages, it is still not clear why teeth form various crown shapes—for instance, incisors vs. canines. There are two dominant hypotheses. The first is the “field model,” which suggests that the elements for each type of tooth shape originate in the ectomesenchyme during tooth development. The elements for specific kinds of teeth, such as incisors, are localized in one area and dissipate quickly in different parts of the mouth. Therefore, for instance, the “incisor field” has factors that grow teeth into the incisor form, and this field is focused in the central incisor area but decreases rapidly in the canine area [1].

The second dominant hypothesis, the “clone model,” suggests that the epithelium programs a set of ectomesenchymal cells to produce teeth of specific shapes. This set of cells, called a clone, persuades the dental lamina into tooth growth, producing a tooth bud to form. Development of the dental lamina persists in an area called the “progress zone.” As soon as the progress zone travels a certain distance from the first tooth bud, this marks the beginning of the development of a second tooth bud [1, 12].

These two hypotheses are not automatically mutually exclusive, and widely accepted dental science does not see them as contradictory. It is assumed that both models explain tooth development at different times.

5. Conclusion

In conclusion, this chapter presented an overview of tooth morphology. First, nomenclature was defined and then tooth numbering systems were described. After this, the anatomy of the crown and root, as well as explanations of the tooth surfaces and ridges were presented. The next section focused on tooth development, starting with the bud stage. A description of the formation of the tooth continued through the section on the cap stage and the bell stage, and finally, the maturation stage was described. The chapter ended with a discussion of two tooth morphology hypotheses that are thought to help explain tooth development.

In order to grasp the morphology of the human tooth, it is necessary to understand the stages of tooth development. These stages give rise to the final morphology of a variety of human teeth with different surfaces and ridges, which are named using an entomologic system, and enumerated using numbering systems. This chapter provides a guide to the various stages of tooth development and the tissue composition of teeth at various stages of development, and provides insight into the vocabulary and numbering systems used to identify and describe human teeth

Acknowledgements

The authors would like to thank Dr. Hanan Abdulla Al Ghayhab for creating the illustrations for the stages of tooth formation. The authors would also like to thank Ms. Sarah Ibrahim ALHarthi and Ms. Sama Subhi ALHarthi for assisting with the other illustrations.

Conflict of interest

All of the authors declare that they have no conflict of interest with this publication.

Nomenclature

Advanced bell stage	last part of the bell stage, where hard tissues of the tooth are developed; also called the crown stage
Anterior teeth	teeth toward the front of the mouth, including central incisors, lateral incisors, and canines
Apex of the root	tip of the root
Apical foramen	the top of the root, where nerves and blood supply can enter the pulp and transit to the pulp through the root canal
Bell stage	the third stage of tooth formation, where the enamel organ comes to resemble a bell shape
Buccal surfaces	surfaces of posterior teeth facing the buccal mucosa
Bud stage	first stage of tooth development where the tooth bud forms
Canine teeth	one canine tooth is present next to each central incisor in the maxillary and mandibular
Cap stage	stage after bud stage, where orderly arrangement of cells takes place
Cementoenamel junction	where the crown of the tooth meets the root
Cementum	a layer of hard tissue covering dentin in the tooth
Central incisors	the two front teeth in the maxillary and mandibular
Cervical line	line that separates the crown from the root
Cervical loop	the rim of the enamel organ where the outer enamel epithelium and the inner enamel epithelium meet
Cervix	area where the crown meets the root
Clone model	hypothesis of tooth formation that suggests that the epithelium programs a set of ectomesenchymal cells to produce teeth of specific shapes
Crown	the portion of the tooth visible in the oral cavity
Curvature	curves in the crown
Cusp	tip of the tooth; canines have a single cusp, while premolars and molars have two or more cusps
Dental lamina	layer of cells next to the vestibular lamina that begin to form the tooth bud
Dental papilla	formed during the cap stage from an aggregation of cells within the dental follicle
Dental sac	group of ectomesenchymal cells that surround the enamel organ and limit the dental papilla during the cap stage
Dentin	a hard tissue that makes up the largest proportion of the tooth
Distal surface	the proximal surface of a tooth furthest from a vertical line drawn down the center of the face
Early bell stage	first part of the bell stage, where morphodifferentiation and histodifferentiation take place
Ectomesenchymal cells	cells from which tooth formation originates

Enamel	a hard tissue forming the outer layer of the tooth
Federation Dentaire Internationale (FDI) System	tooth numbering system that is easy to memorize and has been adopted by the International Standard Organization
Field model	hypothesis of tooth formation that suggests that the elements for each type of tooth shape originate in the ectomesenchyme during tooth development
Inner enamel epithelium (IEE)	a layer of columnar cells which covers the recess of the enamel organ in a developing tooth
Labial surfaces	surfaces of anterior teeth facing the lips
Lateral incisors	the teeth on either side of the central incisors in the maxillary and mandibular
Lower left quadrant	left portion of the mandibular
Lower right quadrant	right portion of the mandibular
Mandibular	lower jaw
Maturation stage	final stage of tooth formation; also called apposition
Maxillary	upper jaw
Mesial surface	the proximal surface of a tooth closest to a vertical line drawn down the center of the face
Molars	in the adult mouth, three molars follow the two premolars in the maxillary and the mandibular. For primary teeth, there are no premolars, and only two molars. The first molar will be exfoliated and replaced by the two premolars, and the second molar will be exfoliated and replaced by the three molars
Occlusal surfaces	surfaces of posterior teeth which occlude opposing posterior surfaces
Odontoblasts	cells that originate in the dental papilla that ultimately secrete a substance that forms an organic matrix
Outer enamel epithelium	layer of cuboidal cells covering the enamel organ in a developing tooth
Palatal surfaces	surfaces of the tooth facing the palate
Palate	upper portion of the mouth
Permanent teeth	teeth that replace primary teeth later on in childhood; also called succedaneous teeth
Posterior teeth	teeth toward the back of the mouth, including premolars and molars
Preameloblasts	during the advanced bell stage, inner enamel epithe- lium cells evolve into preameloblasts
Predentin	cells created from odontoblasts depositing minerals onto an organic matrix
Premolars	in the adult mouth, next to each canine tooth in the maxillary and mandibular are two premolars
Primary teeth	first set of teeth humans have in their lifetime; also called deciduous dentition
Proximal surface	a surface of a tooth that is facing an adjacent tooth
Pulp	soft tissue in the root of the tooth that enervates and provides blood supply to the tooth
Ridge	a raised area of a tooth
Root	the portion of the tooth between the cemento-enamel junction and the apical foramen
Root axis line	line between the apex of the root and the tip of the cusp

Root canal	canal starting at the apical foramen leading to the pulp chamber that allows nerves and blood supply to enter the pulp
Stellate reticulum	interior of the enamel organ's cells
Stratum intermedium	layer of cells between the inner enamel epithelium and the stellate reticulum
Surface	a flat area of a tooth
Tooth bud	the first stage of tooth formation
Universal System	tooth numbering system adopted by the American Dental Association that lacks an anatomical reference
Upper left quadrant	left portion of the maxillary
Upper right quadrant	right portion of the maxillary
Vestibular lamina	layer of cells next to the dental lamina that begin to form the tooth bud
Zsigmondy-Palmer System	eight numerical quadrant system for tooth numbering used in the late 1800s

Author details

Abeer ALShami¹, Shatha ALHarthi^{1*}, Munerah Binshabaib¹ and Monika Wahi²

1 Princess Nourah Bint Abdulrahman University, Riyadh, Saudi Arabia

2 Laboure College, Milton, Massachusetts, USA

*Address all correspondence to: shsalharthi@pnu.edu.sa

IntechOpen

© 2019 The Author(s). Licensee IntechOpen. This chapter is distributed under the terms of the Creative Commons Attribution License (<http://creativecommons.org/licenses/by/3.0>), which permits unrestricted use, distribution, and reproduction in any medium, provided the original work is properly cited. 

References

- [1] Nelson SJ. Wheeler's Dental Anatomy, Physiology and Occlusion—E-Book. St. Louis, Mo: Elsevier Health Sciences; 2009. p. 401
- [2] Koch G, Poulsen S, Espelid I, Haubek D. Pediatric Dentistry: A Clinical Approach. United Kingdom: John Wiley & Sons; 2017. p. 408
- [3] Havale R, Sheetal BS, Patil R, Hemant Kumar R, Anegundi RT, Inushekar KR. Dental notation for primary teeth: A review and suggestion of a novel system. *European Journal of Paediatric Dentistry*. 2015;**16**(2):163-166
- [4] Turp JC, Alt KW. Designating teeth: The advantages of the FDI's two-digit system. *Quintessence International*. 1995;**26**(7):501-504
- [5] Dental Health Foundation. Tooth Types [Internet]. 2010. Dental Health Foundation. Available from: <https://www.dentalhealth.ie/children/toothdevelopment/types/> [Accessed: 7 April 2019]
- [6] Hovorakova M, Lesot H, Peterka M, Peterkova R. Early development of the human dentition revisited. *Journal of Anatomy*. 2018;**233**(2):135-145
- [7] Sunderland EP, Smith CJ, Sunderland R. A histological study of the chronology of initial mineralization in the human deciduous dentition. *Archives of Oral Biology*. 1987;**32**(3):167-174
- [8] Hovorakova M, Lesot H, Peterka M, Peterkova R. The developmental relationship between the deciduous dentition and the oral vestibule in human embryos. *Anatomy and Embryology*. 2005;**209**(4):303-313
- [9] Fuller JL, Denehy GE, Schulein TM. Concise Dental Anatomy and Morphology. University of Iowa College of Dentistry; 2001. p. 218
- [10] Peterkova R, Hovorakova M, Peterka M, Lesot H. Three-dimensional analysis of the early development of the dentition. *Australian Dental Journal*. 2014;**59**(Suppl 1):55-80
- [11] Robinson C. Enamel maturation: A brief background with implications for some enamel dysplasias. *Frontiers in Physiology*. 2014. p. 388. Available from: <https://www.ncbi.nlm.nih.gov/pmc/articles/PMC4189374/> [Accessed: 13 May 2019]
- [12] Balic A. Concise review: Cellular and molecular mechanisms regulation of tooth initiation. *Stem Cells*. Jan 2018;**37**(1):26-32. DOI: 10.1002/stem.2917. Epub 20 Nov 2018