

We are IntechOpen, the world's leading publisher of Open Access books Built by scientists, for scientists

6,900

Open access books available

186,000

International authors and editors

200M

Downloads

Our authors are among the

154

Countries delivered to

TOP 1%

most cited scientists

12.2%

Contributors from top 500 universities



WEB OF SCIENCE™

Selection of our books indexed in the Book Citation Index
in Web of Science™ Core Collection (BKCI)

Interested in publishing with us?
Contact book.department@intechopen.com

Numbers displayed above are based on latest data collected.
For more information visit www.intechopen.com



Cochlear Implant in Single-Sided Deafness Children and Adults

*Ángel Ramos Macías, Silvia A. Borkoski Barreiro,
Juan Carlos Falcón González and Ángel Ramos de Miguel*

Abstract

Binaural hearing in humans ensures our effective communication as it improves the sound localization, the speech understanding in noise, the spatial awareness, the listening easiness, and the development of spoken language. The majority of the literature on patients with single-sided deafness and cochlear implantation involves adult patients; the cochlear implant is a viable and cost-effective treatment option for this population. So in this chapter, we will emphasize the importance of early treatment of unilateral hearing loss in the pediatric age and the emerging indication of the cochlear implant as a treatment.

Keywords: cochlear implant, single-sided deafness, unilateral hearing loss, tinnitus, children, quality of life, language

1. Introduction

Binaural hearing in humans ensures our effective communication as it improves the sound localization, the speech understanding in noise, the spatial awareness, the listening easiness, and the development of spoken language. Lack of binaural input and diminished audibility negatively affects the abovementioned factors, thereby affecting communication and quality of life [1–3].

The term single-sided deafness (SSD) is defined by the presence of a complete hearing loss in one of the two ears, and thresholds better than 25 dB at all frequencies, in contralateral side.

During the human development, binaural hearing is even more important in young children than in adult. The neural circuit for binaural processing is innate and functional at birth, so the neural consequences of lack of binaural input and diminished audibility should not be underestimated. The asymmetric development promoted by unilateral implant did not eliminate integration of binaural input in the brainstem, but severe impairments were found in perception of binaural cues. Given that binaural processing, at least, at the brainstem, is possible, it can be hypothesized that perception of binaural cues would be established in children receiving bilateral cochlear implants with long-term use but that differences from normal would persist with increasing abnormalities for those children who had experienced longer durations of unilateral implant use [4].

Although the importance of binaural hearing was demonstrated several decades ago, the treatment of SSD has only become an increased focus of attention since the beginning of the last decade [5–8].

There is a paucity of high-level evidence with many studies reporting with cochlear implants that have been used in adult patients with unilateral, severe-profound sensorineural hearing loss with associated disabling tinnitus and normal contralateral hearing with good results [9–15].

While cochlear implant (CI) provision is a well-established and beneficial therapy in an increasing number of countries for adults with acquired SSD, there is less experience with this therapeutic option in children [16–19].

The estimated incidence of sensorineural hearing impairment (>40 dB HL) at birth is 1.86 per 1000 newborns in developed countries and 30–40% of these are unilateral. The prevalence of unilateral hearing loss (UHL) increases with age due to cases of delayed onset before 5 years. At school age, up to 3–6% of children with different grades of UHL could be found [20–22].

2. Consequences of SSD in children

There is evidence that single-sided deafness negatively impacts on the development of children, not only presenting difficulties in locating sounds and understanding speech in noise but also having difficulty in mastering complex skills for spoken language which can cause significant psychosocial difficulties and school problems. Children suffering from SSD that receive a CI have the potential to obtain useful information from an ear that, without the implantation, would contribute poorly or not contribute, thus, increasing the quality of their general communication [23, 24].

2.1 Speech and language

Any degree of hearing loss makes children at risk of producing shorter expressions and being less able to produce verbs related to grammatical morphology. Studies show that children and adults with SSD have worse results in speech recognition in noise and have fewer skills for sound localization [21–25].

Sangen et al. were among the first to study language skills in children with SSD. The study showed differences between children with SSD and normal-hearing children on several language skills (morphology, syntax, and vocabulary tests) and on auditory behavior, presumably due to auditory input interrupted during the time of language acquisition [26].

Difficulties in language oral and reading skills and the worst results in the recognition of words and language, although improving over time, it has been observed that adolescents with SSD continue to present worse results in language tests compared to normal hearing [27].

Ramos et al. in their study show that cochlear implant provides children with congenital SSD with significant audiological and subjective benefits. Children with congenital SSD and implanted after a long hearing deprivation period (>6 years) may not have an important binaural benefit, although bilateral effect can be achieved. Children with post-lingual unilateral deafness and after a short period of hearing deprivation probably integrated the normal acoustic hearing with the cochlear implant electrical signal and showed binaural benefits (**Figure 1**) [19].

Studies performed on children with single-sided deafness have shown that the postoperative hearing benefit was significant in the auditory tests for understanding speech in noise. Most of the studies performed on CI recipients suffering from acquired SSD demonstrate during the postoperative period a significant decrease in location error in the implanted ear [19, 28, 29].

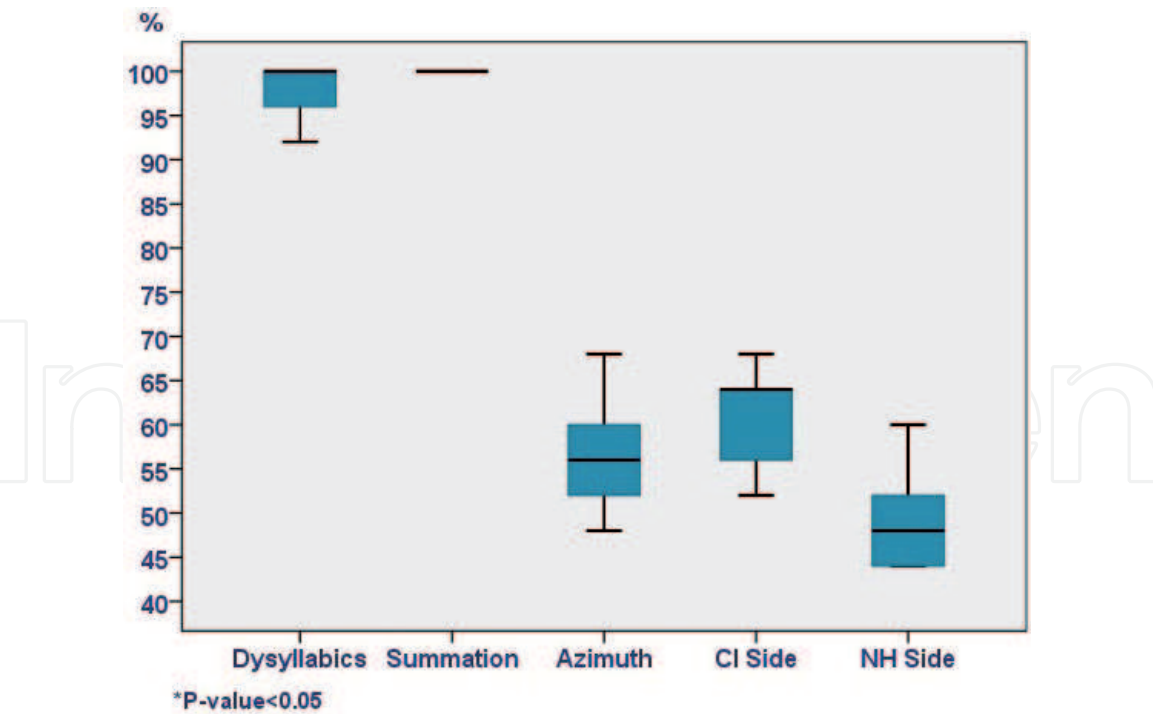


Figure 1.
Ramos et al. acquired SSD: speech test results [19].

Early intervention could prevent such language difficulties and minimize problems with spatial hearing and speech understanding. All the children’s parents in this study confirmed their choice of using a CI. This established a high score in the CI satisfaction parameter by the parents regardless of the age of implantation [19].

2.2 Cognitive functions and neural processing

Unilateral hearing losses in children have traditionally been underappreciated. The common wisdom among medical and educational professionals has been that at least one normal-hearing or near-normal-hearing ear was sufficient for typical speech and language development in children. Different patterns of plasticity occur following partial and profound unilateral deafness, and if it is of congenital etiology, it poses severe challenges for the maturation of the brain [30, 31].

It has been reported both in adults and children with SSD that changes in the auditory cortex and other brain structures as a result of an imbalance in the auditory input have a cascading effect with worsening in neural networks and processes involved in executive function, cognition, attention, and understanding of language [4, 21, 30, 32].

The study of Vila et al. shows significant differences in how sound is processed in the cortex in children with SSD compared to normal-hearing children with functional magnetic resonance studies (fMRI) [33].

2.3 School performance and quality of life

Although children with SSD often function satisfactorily at an early age, many experience difficulties in school; 22–59% experience increased fatigue due to the additional cognitive effort devoted to detecting, decoding, processing, and understanding, which translates most of the time into worse school performance [21, 34, 35].

Studies reveal a decrease in the quality of life in children with SSD in different domains especially in school activities and social interactions, which are especially important for development and learning. Problems in the field of social and emotional behavior continue even in adulthood [2, 27].

Close monitoring and good communication between professionals in different domains are crucial in order to minimize the potential negative effects of UHL.

Although considerable work has been done on the quality of life (QoL) attainment and health economic implications of cochlear implants, further studies are needed to characterize the costs and benefits with respect to the recipients' health, well-being, and contributions to society in cases of unilateral hearing patients.

3. Etiology, diagnosis, and treatment

In bilateral hearing loss, the genetic cause is the most frequent, whereas in SSD it does not occur with the same incidence. Genetic mutations occur in 28% of cases [35]. Although some syndromes (brachi-oto-renal syndrome, Waardenburg) may initially present as SSD, they usually progress toward bilateral hearing loss. Between 35 and 64% of the cases, the UHL is of unknown cause. Hearing loss is progressive in 14 and 32.8%, and this is frequently associated with malformations in the inner ear. Aplasia or hypoplasia of the cochlear nerve occurs more frequently in SSD, up to 50%. Among the postnatal causes, cytomegalovirus (CMV) infection, cranioencephalic trauma, and meningitis are the most frequent causes. It is also important to keep in mind the external and middle ear problems as a probable cause of an HU [36].

Thanks to vaccination schedules, it is rare to find deafness secondary to parotiditis, measles, or rubella, although anti-vaccine currents increase the risk of these old diseases. It is important to always verify during the anamnesis the correct vaccination of children with sensorineural hearing loss.

The criteria for candidacy for SSD cochlear implantation are emerging. Children with unilateral deafness or asymmetric hearing loss who have traditionally not been considered candidates for cochlear implantation should be evaluated individually. The audiological management of these potential candidates is not very different compared to children who are recipients of traditional cochlear implants. The diagnosis requires the exhaustive collection of family and personal history, including risk factors and a detailed physical examination, as well as the realization, when necessary, of the relevant complementary studies (genetic tests, imaging tests, laboratory tests, and other complementary explorations (e.g., EKG)). In the study of the etiology of neonatal hearing loss, it is important to perform a radiological study using computerized tomography and/or magnetic resonance, each of which provides different characteristics for the study of the different anatomical, pathological alterations in the external ear, medium, and internal, as well as in the central auditory pathways. Like any other intervention in medicine, the treatment must be individualized taking into account the characteristics, needs, and expectations of each child and their family (**Figure 2**) [36, 37].

Achieving a binaural hearing and maintaining the auditory pathway of the affected side, avoiding brain reorganization and its consequences, are the main reasons for performing a cochlear implant in a unilateral sensorineural hearing loss of cochlear origin.

In children with SSD who systematically use their CI, we know that bimodal stimulation does not generate any conflict in the auditory integration, nor does it cause the use of an implant in the affected ear while having normal hearing in the other [38, 39].

Children with unilateral CI for SSD need special rehabilitation method by using masking of the normal-hearing ear.

Children with acquired SSD are likely to gain similar positive benefits from cochlear implantation as those recently reported in adults (improved localization and better speech understanding in specific noise conditions). However, implantation of children with prelingual UHL is currently problematic as the impact of UHL may not become apparent until the child enters full-time education, by which time

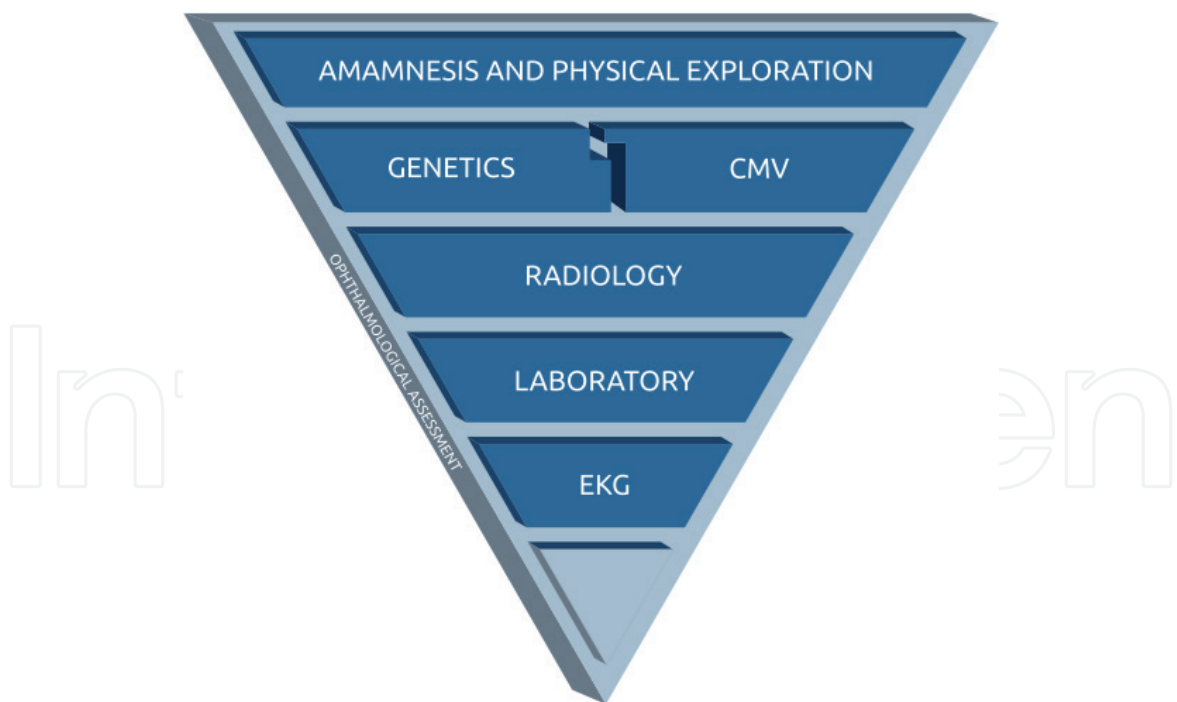


Figure 2.
 Recommended sequence for etiological diagnosis (levels of diagnostic yield, ordered from highest to lowest) [35].

outcomes from cochlear implantation may be suboptimal due to auditory deprivation. In congenital sensorineural UHL, the delay in cochlear implantation may produce nonoptimal results [37].

Special consideration should be given to those unilateral congenital neurosensory hearing loss secondary to CMV and to malformations of the inner ear if these exist in both ears, given the high probability of loss of the contralateral healthy ear [19, 37].

4. What is amblyaudia?

The term amblyaudia describes persistent auditory difficulties in individuals with a history of UHL during the critical period of brain development [37].

Early exposure to sound allows adequate development and maturation of auditory processing centers. The development of the process we know as hearing and perception requires a binaural auditory ability, which makes elements such as redundancy and the shadow effect of the head, suppression, and masking (cocktail party effect) come into play to allow locating sound, spatial hearing, and perception of speech in noise.

The clinical presentation and long-term impact of amblyaudia, being a phenomenon of recent description, are not correctly defined, but it is known that subjects at risk of amblyaudia have a hearing loss with three specific aspects: asymmetric deafness, measurable loss >30 dB, and the loss which occurs during the critical period of development. Its presentation may be subtle and not detected in the usual audiometric tests, so it is important to bear in mind this emergent diagnostic entity and the long-term consequences of unilateral hearing loss and asymmetric hearing loss in childhood [37].

5. Adults with UHL and accompanying severe tinnitus treated with a cochlear implant

Prolonged spontaneous tinnitus of some degree is experienced by up to 20% of the adult population with exact estimates varying according to the tinnitus

definition used. Subjects with tinnitus report poor speech perception, difficulty falling asleep, difficulty concentrating, insecurity, and in many cases depression. For some people their tinnitus is persistent, debilitating, and has a negative impact on their quality of life, even when present in only one ear [38–40].

The use of a CI primarily to suppress tinnitus has been considered for those patients who have incapacitating tinnitus and a UHL and thus would not normally meet the standard criteria for CI. Studies have shown the CI has successfully been used to treat the tinnitus symptoms with the benefits lasting long term [11, 41, 42]. The CI is also able to restore true binaural input for these patients providing them with the advantages of binaural hearing for listening in noise and sound localization.

The impact of cochlear implantation on the reduction of tinnitus is well-established; in addition to improvements in hearing, a statistically and clinically significant reduction in the loudness and disability of tinnitus is reported. Long-term studies reporting results up to 10 years after activation also show continued reduction of tinnitus loudness to very low levels and 100% continued device use. A hypothesis is that routine daily use of the implant leads to residual tinnitus inhibition with prolonged time constants. In some patients this residual inhibition could last overnight (i.e., the switch-off period) and occasionally provides full tinnitus inhibition during day and night as reported regularly in studies with conventional CI candidates with less burdensome tinnitus [43–46].

Patients with tinnitus and SSD feel considerably worse off than those with tinnitus alone and similarly disadvantaged to more traditional implant candidates with bilateral hearing loss. Cochlear implants can reduce or suppress incapacitating tinnitus in patients with unilateral, severe-profound sensorineural hearing loss and normal contralateral hearing. It is a valid and effective therapy when other treatments have failed. The impact on quality of life of the CI on these two groups is equivalent, and a CI should be considered as an effective treatment for this population.

The reduction of tinnitus after cochlear implantation may be due to several mechanisms, such as habituation, acoustic masking, direct stimulation of the cochlear nerve, and reorganization of cortical areas.

The result was more in favor to make CI treatment in cases with short period of tinnitus (<5 years).

6. Conclusions

Limited audibility and atypical hearing experience affects listening skills; good contralateral hearing is not enough to promote normal auditory, linguistic, and cognitive development.

It is accepted that the majority of children with acquired unilateral hearing loss who receive CI as treatment have better performance in hearing and speech performance than those with a no cochlear implant; the lower the age of implantation, the better their performance; and congenital children must be more evaluated in more multicenter studies to clarify the long-term results.

The CI in adults with SSD and severe tinnitus is a valid and effective therapy when other treatments have failed.

Conflict of interest

None declared.

Nomenclature

SSD	single-sided deafness
dB	decibels
CI	cochlear implant
UHL	unilateral hearing loss
fMRI	functional magnetic resonance studies
QoL	quality of life
EKG	electrocardiogram

Author details

Ángel Ramos Macías^{1,2}, Silvia A. Borkoski Barreiro^{1,2*},
Juan Carlos Falcón González^{1,2} and Ángel Ramos de Miguel^{1,2}

1 Department of Otolaryngology Head Neck Surgery, Complejo Hospitalario
Universitario Insular Materno Infantil de Gran Canaria, Las Palmas, Spain

2 Department of Otolaryngology, Psychoacoustic and Balance Laboratory,
Las Palmas University (ULPGC), Las Palmas, Spain

*Address all correspondence to: silviaborkoski@hotmail.com

IntechOpen

© 2019 The Author(s). Licensee IntechOpen. This chapter is distributed under the terms of the Creative Commons Attribution License (<http://creativecommons.org/licenses/by/3.0>), which permits unrestricted use, distribution, and reproduction in any medium, provided the original work is properly cited. 

References

- [1] Jacobs E, Langereis MC, Frijns JH, Free RH, Goedegebure A, Smits C, et al. Benefits of simultaneous bilateral cochlear implantation on verbal reasoning skills in prelingually deaf children. *Research in Developmental Disabilities*. 2016;**58**:104-113
- [2] Roland L, Fischer C, Tran K, Rachakonda T, Kallogjeri D, Lieu JE. Quality of life in children with hearing impairment: Systematic review and metaanalysis. *Otolaryngology and Head and Neck Surgery*. 2016;**155**(2):208-219
- [3] Sladen DP, Frisch CD, Carlson ML, Driscoll CL, Torres JH, Zeitler DM. Cochlear implantation for single-sided deafness: A multicenter study. *Laryngoscope*. 2017;**127**(1):223-228
- [4] Tillein J, Hubka P, Kral A. Monaural congenital deafness affects aural dominance and degrades binaural processing. *Cerebral Cortex*. 2016;**26**(4):1762-1777
- [5] MacKeith NW, Coles RR. Binaural advantages in hearing of speech. *The Journal of Laryngology and Otology*. 1971;**85**:213-232
- [6] Bronkhorst AW, Plomp R. Binaural speech intelligibility in noise for hearing-impaired listeners. *The Journal of the Acoustical Society of America*. 1989;**86**:1374-1383
- [7] Colburn HB, Shinn-Cunningham B, Kidd G Jr, Durlach N. The perceptual consequences of binaural hearing. *International Journal of Audiology*. 2006;**45**(Suppl 1):34-44
- [8] Firszt JB, Reeder RM, Skinner MW. Restoring hearing symmetry with two cochlear implants or one cochlear implant and a contralateral hearing aid. *Journal of Rehabilitation Research and Development*. 2008;**45**:749-767
- [9] Buechner A, Brendel M, Lesinski-Schiedat A, Wenzel G, Frohne-Buechner C, Jaeger B, et al. Cochlear implantation in unilateral deaf subjects associated with ipsilateral tinnitus. *Otology & Neurotology*. 2010;**31**:1381-1385
- [10] Masgoret E, Meran J, Moreno C, Falcón JC, Artiles O, Ramos A. Acúfeno e implante coclear. Experiencia preliminar. *Acta Otorrinolaringológica Española*. 2010;**61**:405-411
- [11] Ramos Á, Polo R, Masgoret E, Artiles O, Lisner I, Zaballos ML, et al. Implante coclear en pacientes con hipoacusia súbita unilateral y acúfeno asociado. *Acta Otorrinolaringológica Española*. 2012;**63**:15-20
- [12] Ramos Macías A, Falcón-González JC, Manrique Rodríguez M, Morera Pérez C, García-Ibáñez L, Cenjor Español C, et al. One year results for patients with unilateral hearing loss and accompanying severe tinnitus and hyperacusis treated with a cochlear implant. *Audiology & Neuro-Otology*. 2018;**23**(1):8-19. DOI: 10.1159/000488755
- [13] Holder JT, O'Connell B, Hedley-Williams A, Wanna G. Cochlear implantation for single-sided deafness and tinnitus suppression. *American Journal of Otolaryngology*. 2017;**38**:226-229
- [14] Mertens G, De Bodt M, Van de Heyning P. Evaluation of long-term cochlear implant use in subjects with acquired unilateral profound hearing loss: Focus on binaural auditory outcomes. *Ear and Hearing*. 2017;**38**:117-125
- [15] Mertens G, De Bodt M, Van de Heyning P. Cochlear implantation as a long-term treatment for ipsilateral incapacitating tinnitus in subjects with

unilateral hearing loss up to 10 years. *Hearing Research*. 2016;**331**:1-6

unilateral hearing loss. *Laryngoscope*. 2012;**122**:2088-2095

[16] Plontke SK, Heider C, Koesling S, et al. Cochlear implantation in a child with posttraumatic single-sided deafness. *European Archives of Oto-Rhino-Laryngology*. 2013;**270**:1757-1761

[24] Anne S, Lieu JEC, Cohen MS. Speech and language consequences of unilateral hearing loss: A systematic review. *Otolaryngology and Head and Neck Surgery*. 2017;**157**(4):572-579

[17] Hassepass F, Aschendorff A, Wesarg T, Kröger S, Laszig R, Beck RL, et al. Unilateral deafness in children: Audiologic and subjective assessment of hearing ability after cochlear implantation. *Otology & Neurotology*. 2013;**34**(1):53-60

[25] Koehlinger K, Van Horne AO, Oleson J, McCreery R, Moeller MP. The role of sentence position, allomorph, and morpheme type on accurate use of s-related morphemes by children who are hard of hearing. *Journal of Speech, Language, and Hearing Research*. 2015;**58**(2):396-409

[18] Kitoh R, Moteki H, Nishio S, Shinden S, Kanzaki S, Iwasaki S, et al. The effects of cochlear implantation in Japanese single-sided deafness patients: Five case reports. *Acta Oto-Laryngologica*. 2016;**136**:460-464

[26] Sangen A, Royackers L, Desloovere C, Wouters J, van Wieringen A. Single-sided deafness affects language and auditory development—A case control study. *Clinical Otolaryngology*. 2017;**42**(5):979-987

[19] Ramos Macías A, Borkoski Barreiro SA, Falcón González JC, de Miguel Martínez I, Ramos de Miguel A. Single-sided deafness and cochlear implantation in congenital and acquired hearing loss in children. *Clinical Otolaryngology*. 2019;**44**(2):138-143. DOI: 10.1111/coa.13245

[27] Krishnan LA, Van Hyfte S. Management of unilateral hearing loss. *International Journal of Pediatric Otorhinolaryngology*. 2016;**88**:63-73

[20] van Wieringen A, Boudewyns A, Sangen A, Wouters J, Desloovere C. Unilateral congenital hearing loss in children: Challenges and potentials. *Hearing Research*. 2019;**372**:29-41. DOI: 10.1016/j.heares.2018.01.010

[28] Arndt S, Aschendorff A, Laszig R, et al. Comparison of pseudobinaural hearing to real binaural hearing rehabilitation after cochlear implantation in patients with unilateral deafness and tinnitus. *Otology & Neurotology*. 2011;**32**:39-47

[21] Lieu JE. Management of children with unilateral hearing loss. *Otolaryngologic Clinics of North America*. 2015;**48**(6):1011-1026

[29] Arndt S, Prose S, Laszig R, Wesarg T, Aschendorff A, Hassepass F. Cochlear implantation in children with single-sided deafness: Does aetiology and duration of deafness matter? *Audiology & Neuro-Otology*. 2015;**20**:21-30

[22] Ross DS, Visser SN, Holstrum WJ, Qin T, Kenneson A. Highly variable population-based prevalence rates of unilateral hearing loss after the application of common case definitions. *Ear and Hearing*. 2010;**31**(1):126-313

[30] Kral A, O'Donoghue GM. Profound deafness in childhood. *The New England Journal of Medicine*. 2010;**363**(15):1438-1450

[23] Lieu JE, Tye-Murray N, Fu Q. Longitudinal study of children with

[31] Maslin MR, Munro KJ, El-Deredy W. Evidence for multiple mechanisms of cortical plasticity: A study of humans

with late-onset profound unilateral deafness. *Clinical Neurophysiology*. 2013a;**124**(7):1414-1421

[32] Propst EJ, Greinwald JH, Schmithorst V. Neuroanatomic differences in children with unilateral sensorineural hearing loss detected using functional magnetic resonance imaging. *Archives of Otolaryngology—Head & Neck Surgery*. 2010;**136**(1):22-26

[33] Vila PM, Lieu JE. Asymmetric and unilateral hearing loss in children. *Cell and Tissue Research*. 2015;**361**:271-278

[34] Kuppler K, Lewis M, Evans AK. A review of unilateral hearing loss and academic performance: Is it time to reassess traditional dogmata? *International Journal of Pediatric Otorhinolaryngology*. 2013;**77**:617-622

[35] Nuñez F, Jaúdenes C, Sequí, JM, Vivanco A, José Z. Diagnóstico y tratamiento precoz de la hipoacusia unilateral o asimétrica en la infancia: recomendaciones CODEPEH 2017. *Revista Fiapas* 2017; 163, Especial

[36] Kaplan AB, Kozin ED, Remenschneider A, Eftekhari K, Jung DH, Polley DB, et al. Amblyaudia: Review of pathophysiology, clinical presentation, and treatment of a new diagnosis, otolaryngology. *Otolaryngology and Head and Neck Surgery*. 2016 Feb;**154**(2):247-255

[37] Boyd PJ. Potential benefits from cochlear implantation of children with unilateral hearing loss. *Cochlear Implants International*. 2015;**16**(3):121-136. DOI: 10.1179/1754762814Y.0000000100

[38] Polonenko MJ, Papsin BC, Gordon KA. Children with single-sided deafness use their cochlear implant. *Ear and Hearing*. 2017;**38**(6):681-689. DOI: 10.1097/AUD.0000000000000452

[39] Ramos Macías A, Borkoski Barreiro S, Falcón González JC, Ramos de

Miguel A. AHL, SSD and bimodal CI results in children. *European Annals of Otorhinolaryngology, Head and Neck Diseases*. 2016;**133**(Suppl 1):S15-S20

[40] Van de Heyning P, Vermeire K, Diebl M, Nopp P, Anderson I, De Ridder D. Incapacitating unilateral tinnitus in single-sided deafness treated by cochlear implantation. *The Annals of Otolaryngology, Rhinology, and Laryngology*. 2008;**117**:645-652

[41] Vielsmeier V, Kreuzer PM, Haubner F, Steffens T, Semmler PR, Kleinjung T, et al. Speech comprehension difficulties in chronic tinnitus and its relation to hyperacusis. *Frontiers in Aging Neuroscience*. 2016;**8**:293

[42] Weidt S, Delsignore A, Meyer M, Rufer M, Peter N, Drabe N, et al. Which tinnitus-related characteristics affect current health-related quality of life and depression? A cross-sectional cohort study. *Psychiatry Research*. 2016;**237**:114-121

[43] Pan T, Tyler RS, Ji H, Coelho C, Gehringer AK, Gogel SA. Changes in the tinnitus handicap questionnaire after cochlear implantation. *American Journal of Audiology*. 2009;**18**:144-151

[44] Peters JP, van Zon A, Smit AL, van Zanten GA, de Wit GA, Stegeman I, et al. CINGLE-trial: Cochlear implantation for siNGLE-sided deafness, a randomised controlled trial and economic evaluation. *BMC Ear, Nose and Throat Disorders*. 2015;**15**:3

[45] Baguley DM, Atlas MD. Cochlear implants and tinnitus. *Progress in Brain Research*. 2007;**166**:347-355

[46] Arts RA, George EL, Janssen M, Griessner A, Zierhofer C, Stokroos RJ. Tinnitus suppression by intracochlear electrical stimulation in single sided deafness—A prospective clinical trial: Follow-up. *PLoS ONE*. 2016;**11**:e0153131